This is a digital copy of a book that was preserved for generations on library shelves before it was carefully scanned by Google as part of a project to make the world's books discoverable online.

It has survived long enough for the copyright to expire and the book to enter the public domain. A public domain book is one that was never subject to copyright or whose legal copyright term has expired. Whether a book is in the public domain may vary country to country. Public domain books are our gateways to the past, representing a wealth of history, culture and knowledge that's often difficult to discover.

Marks, notations and other marginalia present in the original volume will appear in this file - a reminder of this book's long journey from the publisher to a library and finally to you.

Usage guidelines

Google is proud to partner with libraries to digitize public domain materials and make them widely accessible. Public domain books belong to the public and we are merely their custodians. Nevertheless, this work is expensive, so in order to keep providing this resource, we have taken steps to prevent abuse by commercial parties, including placing technical restrictions on automated querying.

We also ask that you:

+ *Make non-commercial use of the files* We designed Google Book Search for use by individuals, and we request that you use these files for personal, non-commercial purposes.
+ *Refrain from automated querying* Do not send automated queries of any sort to Google's system: If you are conducting research on machine translation, optical character recognition or other areas where access to a large amount of text is helpful, please contact us. We encourage the use of public domain materials for these purposes and may be able to help.
+ *Maintain attribution* The Google "watermark" you see on each file is essential for informing people about this project and helping them find additional materials through Google Book Search. Please do not remove it.
+ *Keep it legal* Whatever your use, remember that you are responsible for ensuring that what you are doing is legal. Do not assume that just because we believe a book is in the public domain for users in the United States, that the work is also in the public domain for users in other countries. Whether a book is still in copyright varies from country to country, and we can't offer guidance on whether any specific use of any specific book is allowed. Please do not assume that a book's appearance in Google Book Search means it can be used in any manner anywhere in the world. Copyright infringement liability can be quite severe.

About Google Book Search

Google's mission is to organize the world's information and to make it universally accessible and useful. Google Book Search helps readers discover the world's books while helping authors and publishers reach new audiences. You can search through the full text of this book on the web at `http://books.google.com/`

LANE MEDICAL LIBRARY STANFORD
2 45 0163 7821

LANE

MEDICAL LIBRARY

LEVI COOPER LANE FUND

A TEXT-BOOK

OF

OPERATIVE SURGERY

COVERING THE SURGICAL ANATOMY AND OPERATIVE TECHNIC INVOLVED IN THE OPERATIONS OF GENERAL SURGERY

WRITTEN FOR STUDENTS AND PRACTITIONERS

BY

WARREN STONE BICKHAM, Phar.M., M.D.

Assistant Instructor in Operative Surgery, College of Physicians and Surgeons, New York; Late Visiting Surgeon to Charity Hospital, New Orleans; Late Demonstrator of Operative Surgery, Medical Department, Tulane University of Louisiana, New Orleans

THE NEW YORK ACADEMY OF MEDICINE LIBRARY

With 559 Illustrations

LANE MEDICAL LIBRARY
.0778
SAN FRANCISCO

PHILADELPHIA, NEW YORK, LONDON

W. B. SAUNDERS & COMPANY

1903

LANE LIBRARY

COPYRIGHT, 1903, BY W. B. SAUNDERS & COMPANY

REGISTERED AT STATIONERS' HALL, LONDON, ENGLAND

PRESS OF
W. B. SAUNDERS & COMPANY.

B57
1903

IN REVERED MEMORY OF MY FATHER

Charles Jasper Bickham

WHOSE DAILY LIFE EMBODIED THE HIGHEST IDEALS OF CHRISTIAN PHYSICIAN, I LOVINGLY DEDICATE THIS WORK

[illegible]

[illegible]

by
by
o-
w,
al,
bid
ove
-al,
-ior
on,
rse-
by
part
rior
ular,

and
, by
ular
66—
and,
-ficial
sub-

-minal
iliac
retro
ame
88
aspe

ality
1, 9
polit
, f
r

PREFACE.

THE sub-title of the present volume sufficiently designates its intended scope—"The Surgical Anatomy and Operative Technic involved in the Operations of General Surgery." The work is planned to be a presentation to the Student and Practitioner of the best *technic* of modern Surgeons in the operations mentioned—accompanied by a brief summary of the descriptive and surgical anatomy of the structures involved.

The clinical aspect of Operative Surgery has been less fully dealt with—and in generalizations in connection with groups of operations, rather than specifically in connection with individual operations.

An apology for the amount of Anatomy given may seem, to some, necessary. From the standpoint of the pure technician, Operative Surgery is, largely, Applied Anatomy—the application of the facts of Surgical Anatomy during the progress of Surgical Manipulations—the resulting Operative Technic being more or less perfect as the *knowledge* of the Surgical Anatomy and the *conduction* of the Surgical Manipulations are more or less perfect. Theoretically, it is proper to expect fourth-year Students to come into the Operating Room with their Anatomy in an available form for surgical work—practically, this is rarely found—and is often absent in seasoned Operators.

In the arrangement of this work the subjects have been grouped under, The Operations of General Surgery (Part I), and, The Operations of Special Surgery (Part II)—as further detailed in the especially full Contents. In dealing with each group of tissues, or class of operations (in Part I), or with each organ (in Part II), the following divisions of the subjects are taken up, in order:—(1) Surgical Anatomy (of the region or organ); (2) Surface Form and Landmarks; (3) General Surgical Considerations (in operating upon that region or organ); (4) Instruments (used in such operations)—all being introductory to the specific operations,—after which each operation is taken up in turn, under the following headings:—(1) Title of Operation; (2) Description of Operation (including its general indications); (3) Preparation of Patient; (4) Position of Patient, Surgeon, and Assistant; (5) Landmarks of Operation; (6) Incision for Operation; (7) Steps of Operation; (8) Comments.

In the description of the technic of the operations the "Incision" is given a heading to itself—to emphasize the importance of this step of the operation—recognizing that the Operator who starts out aright is a long way ahead of the man who takes his initial step erroneously. Under "Operation" the various steps are given in numbered paragraphs—the different paragraphs usually indicating, in a general way, some change in the technic or in the stage of the operation.

The Principles of Operative Surgery, and Anesthesia, as well as the Operations of Plastic Surgery, many of the operations more properly classed as the operations of Special Branches of Surgery, and some of the many variations of the operations of General Surgery, have been omitted.

In the preparation of these pages, obligations are hereby gratefully and fully acknowledged to the writings of many well-known Surgeons in the standard works of the day upon Operative Surgery, and in the current surgical literature, whose pages have been freely consulted—and to the work of many Surgeons, here and abroad, whose operative technic it has been the privilege of the author to witness—and to writings upon Anatomy.

The name of the deviser of an operation is given, in brackets, after the title of the operation, wherever known to the author. Where slight departures from the manner of doing the operation as performed by its originator occur, such omission is accidental—or, where the original description is ambiguous, the operation is given as it seems to be interpreted by the majority of Surgeons.

Appreciation of encouragement shown during the preparation of the manuscript is gratefully acknowledged to Professors Bull, Dennis, Halsted, Hartley, Matas, Richardson, Senn, Weir, and Wyeth—and to my co-workers, Doctors Peck, Schmitt, and Taylor, in the Department of Operative Surgery at the College of Physicians and Surgeons—and to Doctor Gessner, my former co-worker in the Laboratory of Operative Surgery of Tulane University—and to Doctors Armstrong and LeBeuf—and to other friends whose kindly words have aided and lightened the work of preparation.

The author feels deeply indebted to Miss Eleanora Fry, who has drawn, under his close directions, all the illustrations for the book, during many weeks of conscientious work and unflagging interest—the large majority of the five-hundred and fifty-nine illustrations being original, and the remainder so largely modified as to be, in many instances, practically new pictures.

I wish to thank the Publishers for the courteous consideration they have shown my every expression of wish throughout—for their interest in the manuscript—and for the quality of their finished work.

I desire to express my high valuation of my Wife's ever-ready and untiring aid in all the proof-readings of the manuscript during the many months of its preparation.

The imperfections of the present work are very fully realized—and the author will be glad to receive all criticisms which may tend to the bettering of the text and illustrations.

WARREN STONE BICKHAM.

922 MADISON AVENUE, CORNER OF 73D STREET, NEW YORK CITY.

August, 1903.

THE NEW YORK LIBRARY. ACADEMY OF MEDICINE.

CONTENTS.

PART I.

THE OPERATIONS OF GENERAL SURGERY.

CHAPTER I.

OPERATIONS UPON ARTERIES.

I. Ligation of arteries—General considerations, 17.

II. Surgical Anatomy and Ligation of following Arteries of Head and Neck:—Innominate, by angular incision, Mott's operation, 26—By oblique incision, 28—By partial bony resection, 29—By partial bony resection, Bardenheuer's operation, 30—By splitting of manubrium sterni, 30—Common carotid, above omohyoid, 33—Below omohyoid, 34—External carotid, below digastric, 35—Above digastric, behind ramus of jaw, 36—Superior thyroid, 37—Lingual, near origin, 38—Beneath hyoglossus, 38—Facial, near origin, 40—Over inferior maxilla, 40—Occipital, near origin, 41—Behind mastoid process, 41—Posterior auricular, near origin, 42—Behind ear, 42—Temporal, just above zygoma, 43—Internal maxillary (surgical anatomy), 44—Trunk of middle meningeal, in cranium, through trephine-opening exposed by curved oblique incision, 47—Anterior branch of middle meningeal, through trephine-opening exposed by horseshoe incision, 48—Posterior branch of middle meningeal, through trephine-opening exposed by horseshoe incision, 49—Internal carotid, near origin, 50—First part of right subclavian, by angular incision, 52—First part of left subclavian, by angular incision, 53—Second part of subclavian, 53—Third part of subclavian, 54—Vertebral, near origin, 56—Inferior thyroid, 57—Transversalis colli, at outer margin of sternomastoid, 58—Suprascapular, at outer margin of sternomastoid, 59.

III. Surgical Anatomy and Ligation of following Arteries of Upper Extremity and Thorax:—Internal mammary, in second intercostal space, 60—First part of axillary, by curved transverse incision below clavicle, 62—Third part of axillary, 63—Subscapular along posterior axillary fold, 64—Brachial, in mid-arm, 65—At bend of elbow, 66—Radial, in upper third, 69—In middle third, 70—In lower third, 70—On back of hand, 71—Deep palmar arch, 72—Ulnar, in middle third, 74—In lower third, 76—Superficial palmar arch, 76—Intercostal, by intercostal incision, 76—Intercostal, by partial subperiosteal excision of rib, by Hartley's method, 78.

IV. Surgical Anatomy and Ligation of following Arteries of Trunk:—Abdominal aorta, by transperitoneal method, 80—By retroperitoneal method, 81—Common iliac, by retroperitoneal method, 82—By transperitoneal method, 84—Internal iliac, by retroperitoneal method, 84—By transperitoneal method, 84—Obturator, at thyroid foramen, 85—Sciatic, upon buttock, 86—Internal pudic, upon buttock, 88—In perineum, 88—Gluteal, on buttock, 89—External iliac, by retroperitoneal method, 90—By transperitoneal method, 92—Deep epigastric, near origin, 93.

V. Surgical Anatomy and Ligation of following Arteries of Lower Extremity:—Common femoral, at base of Scarpa's triangle, 95—Profunda femoris, near origin, 97—Superficial femoral, at apex of Scarpa's triangle, 97—In Hunter's canal, 98—Popliteal, in upper part of popliteal space, from behind, 100—In upper part of popliteal space, from inner side of thigh, Jobert's operation, 100—In lower part of popliteal space, 101—

Anterior tibial, in upper third, 104—In middle third, 105—In lower third, 105—Dorsalis pedis, just below ankle-joint, 107—Posterior tibial, in upper third, above peroneal branch, 109—In middle third, 109—In lower third, 110—Behind internal malleolus, 111—Peroneal, in middle of leg, 112—External plantar, at origin, 114—In sole of foot, 115—Internal plantar, at origin, 115—In sole of foot, 115.

VI. Temporary ligation, 116—Intermediate ligation, 117—Arteriorrhaphy, 117—Arterial forcipressure, 119—Arteriostrepsis, 120—Ligation for radical cure of aneurism, 120—Operation for radical cure of aneurism based upon Arteriorrhaphy, Matas's method, 121—Other operations for radical cure of aneurism, 124—Wyeth's treatment of vascular angeiomata, 125.

CHAPTER II.

OPERATIONS UPON VEINS.

Phlebotomy, 126—Phleborrhaphy, 126—Lateral ligation of veins, 127—Transverse ligation of veins, 128—Temporary ligation of veins, 128—Venous ligation en masse, 129—Venous forcipressure, 129—Phlebostrepsis, 129—Acupressure of veins, 129—Phlebectomy, 129—Intravenous infusion of normal salt solution, 130.

CHAPTER III.

OPERATIONS UPON LYMPHATIC GLANDS AND VESSELS.

Surgical anatomy of thoracic duct, 132—Suture of thoracic duct, 132—Ligation of thoracic duct, 133—Surgical anatomy of antero-lateral aspect of neck, 133—Removal of lymphatic glands of neck, 135—Surgical anatomy of axillary region, 138—Removal of axillary lymphatic glands, 139—Surgical anatomy of Scarpa's triangle, 139—Removal of inguinal lymphatic glands, 140.

CHAPTER IV.

OPERATIONS UPON NERVES, PLEXUSES, AND GANGLIA.

I. Neurotomy, 141—Neurectomy, 142—Neurectasy, 142—Nerve-avulsion, 143—Neurorrhaphy, 144—Neuroplasty, 147—Nerve-grafting, 149—Operation for relief of nerve compressed by bony or fibrous cicatricial tissue, 151—Intraneural infiltration for regional anesthesia, 151—Para-neural infiltration for regional anesthesia, 153.

II. Surgical Anatomy and Exposure of following Nerves and Ganglia of Head and Neck:—Gasserian ganglion and three divisions of fifth, by intracranial exposure, Hartley-Krause method, 155—Same, by extracranial exposure, Rose's method, 158—Supraorbital, at supraorbital foramen, 160—Meckel's ganglion and superior maxillary, by antral route, Carnochan's operation, 161—Same, by orbital route, 162—Same, by pterygo-maxillary route, Braun-Loessen operation, 162—Infraorbital, at infraorbital foramen, 163—Inferior maxillary nerve and otic and submaxillary ganglia (surgical anatomy), 164—Inferior maxillary, at foramen ovale, 164; or superior maxillary, at foramen rotundum, Mixter's operation, 164—Inferior dental, in mouth, Paravicini's intrabuccal method, 166—Through ascending ramus of inferior maxilla, 167—At mental foramen, from within mouth, 168—Lingual (gustatory) of inferior maxillary, in mouth, 168—Facial, in front of mastoid process, Baum's operation, 169—Spinal accessory, at anterior border of sternomastoid, 170—Occipitalis major, beneath complexus, 171—Posterior divisions of first, second, and third cervical nerves, Keen's operation, 171—Brachial plexus, in neck, 172.

III. Surgical Anatomy and Exposure of following Nerves of Upper Extremity and Thorax:—Circumflex, on back of arm, 173—Musculocutaneous, in upper part of arm, 173—Median, in middle of arm, 174—At bend of elbow, 174—Ulnar, above middle of arm, 175—Just above internal condyle of humerus, 175—Musculospiral, below middle of arm, 176—Radial, at origin, 177—Posterior interosseous, at origin, 177—Intercostal between angle and middle of rib, 178.

IV. Surgical Anatomy and Exposure of following Nerves of Lower Extremity:—Anterior crural, below Poupart's ligament, 178—Obturator, at thyroid foramen, 179—Superior gluteal, upon buttock, 179—Pudic, upon buttock, 179—Great sciatic, at lower border of gluteus maximus, 179—Internal Popliteal, at lower part of popliteal space, 180—Posterior tibial, between origin and ankle, 180—Behind internal malleolus, 181—

External popliteal (peroneal), behind tendon of biceps, 181—Anterior tibial, near origin, 182.

V. Surgical Anatomy of Cervical Sympathetic Ganglia and Cord, 182—Total excision of cervical sympathetic ganglia and cord, Jonnesco's operation, 183.

CHAPTER V.

OPERATIONS UPON BONES.

Osteotomy in general, 184—Linear osteotomy, by subcutaneous method, 185—Linear osteotomy, by open method, 187—Cuneiform osteotomy, 187—Operations for recent or ununited fractures, in general, 188—Operations for recent or ununited fractures, by resection of ends of bones, with retention of coaptated ends by immobilizing splints, 189—Same, by wiring of ends of bones, with or without resection, 191—Same, by suturing, with or without resection, 193—Same, by nailing, pegging, or screwing ends of bones, with or without resection, 193—Same, by Parkhill's clamp, 194—Other operations for recent or ununited fractures, 195—Operation for recent or ununited fracture of patella, by Stimson's method of mediate suture, 197—Same, by wiring or suturing, 198—Operation for recent or ununited fracture of olecranon, by wiring or suturing, 200—Sequestrotomy, 201—Osteoplasty 202—Excision, 203.

CHAPTER VI.

OPERATIONS UPON JOINTS.

Arthrotomy, 204—Puncture of joints, 204—Erasion, or arthrectomy, 204—Excision 206.

CHAPTER VII.

OPERATIONS UPON MUSCLES.

Myotomy 207—Myorrhaphy, 207—Muscle-lengthening, 208.

CHAPTER VIII.

OPERATIONS UPON TENDONS AND TENDON-SHEATHS.

Tenotomy, 211—Tenorrhaphy, 213—Tendon-lengthening, 216—Tendon-shortening, 220—Tendon-grafting, 221—Repair of ruptured or divided tendon-sheaths, 223—Excision of tendon-sheaths, 224

CHAPTER IX.

OPERATIONS UPON LIGAMENTS.

Syndesmotomy, 226—Suturing of ligaments, 226—Lengthening of ligaments, 226—Shortening of ligaments, 226.

CHAPTER X.

OPERATIONS UPON FASCIÆ.

Fasciotomy, 227.

CHAPTER XI.

OPERATIONS UPON BURSÆ.

Puncture of bursæ, 228—Incision of bursæ, 228—Excision of bursæ, 228.

CHAPTER XII.

AMPUTATIONS AND DISARTICULATIONS.

I. General considerations, 229—The general technic in amputating, 232—Location of line of bone-section, or disarticulation, 232—Location of limits of skin incisions, 233—Incision of skin and fascia, 234—Freeing of skin and fascia, 237—Retraction of skin and fascia, 238—Division of muscles in circular methods of amputation 239—Divi-

sion of muscles in flap methods of amputation, 242—Freeing and retracting of muscles, 246—Making musculo-periosteal, or periosteo-capsular, covering for end of bone, 247—Retraction of soft parts preparatory to sawing bone, 250—Sawing bone or bones, 251—Removing splintered bone, 252—Ligating arteries and veins, 253—Treatment of nerves, tendons, and tags of muscle, fascia, and skin, 255—Trimming of flaps, 255—Re-amputation for improperly made flaps, 255—Adjustment and suturing of musculo-periosteal, or periosteo-capsular, covering, 255—Quilting of muscles, 256—Drainage, 258—Suturing of stump, 258—Dressing of wound, 259—Removal of dressings, 259.

II. The methods of amputation, 259—The evolution of amputation methods, 259—Summary of amputation methods, 261—Circular methods of amputation, 261—Ordinary circular amputation (Amputation circulaire infundibuliforme), 261—Cuff method of circular amputation (Circular amputation à la manchette), 263—Modified circular amputation (Mixed method), 264—Oval method, 265—Racket method, 266—Flap methods of amputation, 267—Amputating by single flap of skin and muscle, 267—By single flap of skin, 269—By equal flaps of skin and muscle, 269—By equal flaps of skin, 270—By unequal flaps of skin and muscle, 271—By unequal flaps of skin, 272—By unequal rectangular flaps of skin and muscle (Teale's method), 272—Elliptical method, 273—Irregular methods of amputation, 275—Selection of amputation method, 275.

III. The amputation stump, 276—Qualities of a good stump, 276—Characteristics of a bad stump, 277—Conditions influencing vitality of stump, 277—Contractility of tissues of stump, 277—Position of stump cicatrices, 278—Function of amputation-stumps, 278.

IV. Surgical Anatomy, Surface Form and Landmarks, General Surgical Considerations and Methods in Amputations and Disarticulations about the Fingers:—Amputation through last phalanx, by palmar flap, 283—At second phalangeal joint, by palmar flap, 284—Same, by short dorsal and long palmar flaps, 284—Through second phalanx, by palmar flap, 285—Same, by short dorsal and long palmar flaps, 285—At first phalangeal joint, by palmar flap, 286—Same, by short dorsal and long palmar flaps, 286—Through first phalanx, by palmar flap, 286—Same, by short dorsal and long palmar flaps, 287—At metacarpo-phalangeal joints of fingers in general, by oval method, 287—Same of thumb, by oval method, 289—Same of thumb, by oblique palmar flap (Farabeuf), 290—Same of index, by externo-palmar flap (Farabeuf), 290—Same of little finger, by interno-palmar flap (Farabeuf), 291.

V. Same, in Amputations and Disarticulations about the Hand:—Amputation of finger, in general, with part of its metacarpals, by racket method, 295—Of thumb with part of its metacarpal, by racket, 296—Of little finger with part of its metacarpal, by racket, 296—Of two contiguous inside fingers, with part of their metacarpals, by racket, 296—Of three innermost fingers, with parts of their metacarpals, by racket, 296—Same, by equal dorsal and palmar flaps, 297—Of all fingers (except thumb) with parts of their metacarpals, by anterior ellipse, 297—Of an inner finger, with its metacarpal, by racket, 297—Of index, with its metacarpal, by racket, 298—Of little finger, with its metacarpal, by racket, 298—Of thumb, with its metacarpal, by racket, 298—Of two contiguous inside fingers, with their metacarpals, by racket, 299—Of three inside fingers, with their metacarpals, by racket, 299—Of three inner fingers, with their metacarpals, by equal dorsal and palmar flaps, 300—Of all fingers (except thumb) with their metacarpals, by anterior ellipse, 301—Of fingers and thumb, at carpo-metacarpal articulation, by palmar flap, 302.

VI. Same, in Disarticulations about the Wrist-joint:—Disarticulation at wrist-joint by anterior ellipse 304—By palmar flap, 305—By external lateral, or radial, flap (Dubrueil's method), 306.

VII. Same, in Amputations about the Forearm:—Through lower third, by modified circular, 309—By circular (cuff variety), 310—Through upper two-thirds, by equal anterior and posterior flaps, 311.

VIII. Same, in Disarticulations about Elbow-joint:—Disarticulation of elbow-joint, by anterior ellipse (Farabeuf), 314—By posterior ellipse, 315—By long antero-internal and short postero-external flaps, 316.

IX. Same, in Amputations about the Arm:—Amputation through lower third, by modified circular, 320—Through upper two-thirds, by long anterior and short posterior flaps, 321—Through surgical neck, by single external flap, 322.

X. Same, in Disarticulations about the Shoulder-joint:—Disarticulation at

shoulder-joint by anterior racket (Spence's operation), 327—By external racket (Larrey's operation), 329—By external or deltoid flap, 330.

XI. Amputation of Upper Limb, together with Scapula and part of Clavicle, by antero-inferior (or pectoro-axillary) and postero-superior (or cervico-scapular) flaps (Berger's operation), 331.

XII. Surgical Anatomy, Surface Form and Landmarks, General Surgical Considerations, and Methods in Amputations and Disarticulations about the Toes:—Amputation through last phalanx, by plantar flap, 336—At second phalangeal joint, by plantar flap, 337—Through second phalanx, by plantar flap, 338—At first phalangeal joint, by oval, 338—Through first phalanx, by oval, 339—Same, by circular, 340—At metatarso-phalangeal joints of toes in general, by oval method, 340—At same of great toe, by interno-plantar flap (Farabeuf), 341—At same of little toe, by externo-dorsal flap (Farabeuf), 341—Disarticulation of two adjoining toes at metatarso-phalangeal joints, by oval method, 342—Of toes en masse, at metatarso-phalangeal joint, by equal short dorsal and plantar flaps, 342.

XIII. Same, in Amputations and Disarticulations about Foot:—Amputation of all toes through the metatarsus, by short dorsal and long plantar flaps (Metatarsal amputation), 348—Disarticulation of toe, with its entire metatarsal, by racket method, 350—Of great toe and its metatarsal, by racket, 350—Of little toe and its metatarsal, by racket, 352—Of two or three contiguous toes with their entire metatarsals, by oval or racket, 353—Of all toes, at tarso-metatarsal joints, by short dorsal and long plantar flaps (Lisfranc's operation), 353—Of all toes, at tarso-metatarsal joints, with sawing off of end of internal cuneiform, by short dorsal and long plantar flaps (Hey's operation), 354—Of anterior part of foot at medio-tarsal joint, by short dorsal and long plantar flaps (Chopart's operation), 355—Of foot at astragalo-scaphoid and astragalo-calcaneal joints, subastragaloid disarticulation, by large interno-plantar flap (Farabeuf), 356—Of foot at astragalo-scaphoid and astragalo-calcaneal joints, subastragaloid disarticulation, by heel-flap, 358.

XIV. Same, in Disarticulations about Ankle-joint:—Disarticulation of foot at ankle-joint, with removal of malleoli and articular surface of tibia, by heel-flap (Syme's operation), 360—Disarticulation of foot at ankle-joint, with removal of malleoli, articular surface of tibia, and anterior part of os calcis, by heel-flap (Pirogoff's osteoplastic amputation), 361.

XV. Same, in Amputation about the Leg:—Through supramalleolar region, by oblique elliptical incision (Guyon's supramalleolar operation), 365—Through lower third, by large posterior and small anterior flaps (Farabeuf), 365—Through middle third, by long posterior and short anterior flaps (Hey's operation), 367—Through upper third, by large external flap (Farabeuf), 368—Same, by bilateral hooded flaps (Stephen Smith's method), 370.

XVI. Same, in Disarticulations about the Knee-joint:—Disarticulation at knee-joint by bilateral hooded flaps (Stephen Smith), 374.

XVII. Same, in Amputations about the Thigh:—Through condyles of femur, transcondyloid amputation, by shorter anterior and longer posterior flaps (Lister's modification of Carden's transcondyloid operation), 379—Just above condyles of femur, with splitting of patella (supracondyloid osteoplastic amputation of Gritti-Stokes) by longer anterior and shorter posterior flaps, 380—Through lower third of thigh, by oblique circular method, 382—Through thigh in general, by long anterior and short posterior flaps, 382—Same, by equal anterior and posterior flaps, 384—Through thigh just below trochanters, by external oval method, 386.

XVIII. Same, in Excisions about the Hip-joint:—Disarticulation at hip-joint by Wyeth's method, 390—By external racket, 392—By anterior racket, 393

XIX. Osteoplastic Amputations, 394.

CHAPTER XIII.

EXCISIONS.

I. General Considerations, 397—Excision by subperiosteal method, 398—Excision by open method, 401.

II. Surgical Anatomy, Surface Form and Landmarks, General Surgical Considera-

tions, and Methods in Excisions about the Fingers:—Excision of terminal phalanges, by U-shaped incision, 403—Of second phalangeal joints, by two lateral incisions, 403—Of second phalangeal joint of index, by dorso-external incision, 404—Of second phalangeal joint of little finger, by dorso-internal incision, 405—Of second phalanges of fingers in general, by dorso-lateral incision, 405—Of second phalanx, by dorso-external incision, for index-finger, 405—Of second phalanx of little finger, by dorso-internal incision, 406—Of first phalangeal joints, by same methods as for second phalangeal joints, 406—Of first phalanges of fingers in general, 406.

III. Same, in Excisions about Hand:—Excision of metacarpo-phalangeal joints of fingers, in general, by dorso-lateral incision, 406—Of metacarpals, in general, by dorsal incision, 407—Of metacarpal of thumb, by dorso-external incision, 408—Of metacarpal of little finger, by dorso-internal incision, 408.

IV. Same, in Excisions about Wrist-joint:—Excision of wrist by radial and ulnar dorsal incisions (Ollier), 409—Same, by single dorso-radial incision (Boeckel-Langenbeck), 410

V. Same, in Excisions about Bones of Forearm:—Total excision of ulna, by long posterior incision, 411—Same, of radius, by long externo-dorsal incision, 412.

VI. Same, in Excisions about Elbow-joint:—Excision of elbow-joint, by posterior median incision (Langenbeck), 413—Same by posterior bayonet-shaped incision, with or without an additional short vertical ulnar incision (Ollier), 415—Excision of superior radio-ulnar articulation, by posterior vertical incision, 416.

VII. Same, in Excisions about Humerus:—Excision of humerus, by long external incision, 417.

VIII. Same, in Excisions about Shoulder-joint and vicinity: Excision of shoulder-joint, by anterior oblique incision, 418—Total excision of clavicle, by long axial incision, 420—Total excision of scapula, by straight incisions along spine and vertebral border, forming superior and inferior flaps, 421.

IX. Same, in Excisions about the Toes:—Excision of terminal phalanges, 423—Of second phalangeal joints, 423—Of second phalanges, 423—Of first phalangeal joint, 423—Of first phalanges, 424.

X. Same, in Excisions about Foot:—Excision of metatarso-phalangeal joints, 424—Of metatarsals, 424—Of astragalus, by external curved incision, 424—Same, by external angular and internal curved incisions, 425—Of os calcis, by horizontal curved and vertical incisions, 427.

XI. Same, in Excisions about Ankle-joint:—Excision of ankle-joint, by transversely curved external incision (Lauenstein), 428—Same, by external curved and internal angular incisions, 429.

XII. Same, in Excisions about Bones of Leg:—Total excision of tibia, by internal vertical incision, 430—Total excision of fibula, by posterior vertical incision, 431—Total excision of patella, by vertical incision, 432.

XIII. Same, in Excisions about the Knee-joint:—Excision of knee-joint, by curved transverse anterior incision, 433.

XIV. Same, in Excisions about Femur:—Excision of parts of diaphysis, by external vertical incision, 435.

XV. Same, in Excisions about Hip-joint:—Excision of hip-joint, by external straight incision (Langenbeck), 436—Same, by anterior straight incision (Barker), 438—Same, by posterior angular incision (Kocher), 439.

XVI. Same, in Excisions about Head:—Excision of superior maxilla, by median incision (Fergusson), 441—Of temporomaxillary articulation, by angular incision, 444—Of inferior maxilla, by single incision along inferior and posterior borders, 445.

XVII. Same, in Excisions about Trunk:—Excision of entire rib and costal cartilage by parallel incision over center of rib, 447—Of coccyx, by posterior median incision, 448.

XVIII. Osteoplastic Resection of Bones and Joints:—Of anterior tarsus and tarso-metatarsus, by internal and external dorso-lateral incisions, 449—Of mid-tarsus, by external transverse curved incision, 450—Of posterior tarsus, by external curved incision, 451—Osteoplastic resection of foot, by transverse upper and lower, and oblique lateral incisions (Wladimiroff-Mikulicz operation), 452—Total excision of tarsus, or osteoplastic resection of foot, by externo-lateral curved incision (modification of Wladimiroff-Mikulicz operation), 453—Osteoplastic resection of superior maxilla, by

vertical and horizontal incisions, 454—Chondro-plastic resection of nasal cartilages, to expose nose and anterior nasopharynx by nasal route, by transverse incision (Rouge), 455—Osteoplastic resection of superior maxilla, to expose nasopharynx by palatine route, by transverse and median incisions (Annandale), 455—Same, to expose nasopharynx by maxillary route, by two semilunar incisions (Langenbeck), 456—Osteoplastic resection of inferior maxilla, to expose structures in front of fauces through divided symphysis, by median incision, 457.

PART II.

THE OPERATIONS OF SPECIAL SURGERY.

CHAPTER I.

OPERATIONS UPON THE HEAD.

I. Cranio-cerebral Region:—Surgical anatomy of scalp, skull, and brain, 459—Chief cranial landmarks, 463—Cranio-cerebral topography, 464—Localization of brain areas, 469—Chipault's method of cranio-cerebral localization, 472—Reid's method of same, 476—Chiene's method of determining Rolandic fissure, 478—General surgical considerations in cranio-cerebral operations, 478—Instruments, 480—Craniotomy, in general, 480—Trephining, or circular craniotomy, 481—Osteoplastic resection of skull, 483—Linear craniotomy, 487—Partial craniectomy, 487—Exploratory puncture of brain, 488—Operation for intracranial hemorrhage, 489—Ligation of middle meningeal artery and its anterior and posterior branches, 490—Ligation of longitudinal or lateral sinuses, 490—Operation for thrombosis of lateral sinus, 492—Trephining for fracture of skull 492—Operation for bullet-wound of brain, 493—Operation for exposure of a motor center, 494—Puncture and drainage of lateral ventricles, 495—Incision of cerebellar subarachnoid space for drainage (Parkin), 496—Operation for cerebral abscess, 496—For cerebellar abscess, 497—For cerebral tumor, 498—For cerebellar tumor, 499—Operations upon mastoid antrum and cells, 499—Operations upon gasserian ganglion, 499.

II. Bony (Air) Sinuses of Head and Face:—Operations upon mastoid antrum and cells, 500—Surgical anatomy, 500—Surface form and landmarks, 502—General surgical considerations, 503—Operation for exposure of mastoid antrum and cells (Antrum operation of Schwartze), 504—Operation for exposing mastoid antrum and cells, together with interior of tympanum and meatus, and the exenteration of middle-ear cavities (the tympano-mastoid exenteration, or radical operation, of Schwartze-Stacke, or Schwartze-Zaufal), 506—Operations upon frontal sinuses, 508—Surgical anatomy, surface form and landmarks, and general surgical considerations, 508, 509—Instruments, 510—Exposure and drainage of frontal sinuses, 510—Operations upon maxillary sinuses, 511—Surgical anatomy, surface form and landmarks, and general surgical considerations, 511, 512—Instruments, 513—Opening of maxillary sinus through its facial aspect, above alveolar margin, 513—Opening through socket of second molar tooth, 514.

III. Eyeball and Orbit:—Operations upon the eyeball, 514—Surgical anatomy of orbit, 514—Enucleation of eyeball, 515—Evisceration of eyeball, 516.

IV. Ear and Eustachian Tube:—Surgical anatomy of membrana tympani, 516—Introduction of ear speculum for examination of membrana tympani, 517—Paracentesis tympani, 517—Introduction of eustachian catheter, 517.

V. Nose and Nasal Cavities, 518.

VI. Tongue:—Surgical anatomy, 518—General surgical considerations, 518—Instruments, 519—Excision of limited portions of tongue, 520—Excision through mouth, without preliminary ligation of lingual arteries (Whitehead), 520—Excision through mouth, after preliminary ligation of linguals in neck, 522—Excision of tongue, together

with cervical and submaxillary glands, by an incision in neck, after preliminary tracheotomy and ligation of lingual and facial arteries (Kocher), 522.

CHAPTER II.

OPERATIONS UPON THE SPINE AND SPINAL CORD.

Surgical anatomy, 526—Surface form and landmarks, 527—General surgical considerations, 528—Instruments, 530—Laminectomy, 530—Osteoplastic resection of spine-534—Subarachnoid puncture for spinal anesthesia, 538—Spinal puncture for drainage of subarachnoid space, 539—Operation for removal of tumors of spinal cord, 539—Intraspinal partial neurectomy of posterior nerve-roots, 539.

CHAPTER III.

OPERATIONS UPON THE NECK.

I. Larynx:—Surgical anatomy of neck, 541—Surgical anatomy of larynx, 541—Surface form and landmarks, 541—Instruments, 542—Laryngotomy, 543—Thyrotomy, 544—Complete laryngectomy, 545—Partial laryngectomy, 546—Intubation of larynx (O'Dwyer), 547—Other operations, 548.

II. Trachea:—Surgical anatomy, 548—Surface form and landmarks, 549—General surgical considerations, 549—Instruments, 550—High tracheotomy, 550—Low tracheotomy, 552—Other operations, 552.

III. Pharynx:—Surgical anatomy, 553—Instruments, 553—Median pharyngotomy, by median vertical incision through mouth, 554—Lateral pharyngotomy, by curved lateral incision through neck (Kocher), 554—Subhyoid pharyngotomy, by transverse curved incision through neck, 555—exposure of retro-pharyngeal space, by lateral cervical incision along posterior border of sternomastoid (Chiene), 556.

IV Esophagus:—Surgical anatomy, 557—General surgical considerations, 558—Instruments, 558—Internal cervical esophagotomy, 558—Cervical esophagostomy, 560—Partial cervical esophagectomy, 560—Introduction of esophageal bougie, 561—Other operations, 561.

V. Tonsils:—Surgical anatomy, 563—General surgical considerations, 563—Instruments, 563—Tonsillotomy, 563—Partial tonsillectomy through mouth 564—Complete tonsillectomy through mouth, 564—Complete tonsillectomy through neck (Cheever), 565.

VI. Parotid Gland and Stenson's Duct:—Surgical anatomy, 567—Instruments. 568—Excision, 568.

VII. Submaxillary Gland and Wharton's Duct:—Surgical anatomy, 570—Instruments, 570—Excision, 571.

VIII. Sublingual Gland and Duct of Bartholin:—Surgical anatomy, 572—Instruments, 572—Excision, through floor of mouth, 572.

IX. Thyroid Gland:—Surgical anatomy, 573—Instruments, 573—Partial thyroidectomy, by angular incision (Kocher), 573—Complete thyroidectomy, by transverse curved incision (Kocher), 575.

CHAPTER IV.

OPERATIONS UPON THE THORAX.

I. Thoracic Wall and Contents:—Surgical anatomy, 576—Surface form and landmarks, 578—Instruments, 579.

II. Female Mammary Gland:—Surgical anatomy, 579—Surface form and landmarks, 580—General surgical considerations, 580—Incision of breast, 580—Partial excision of breast by elliptical incision, 581—Radical excision, by Halsted's method, 582—Radical excision, by Warren's method, 584—Ordinary excision, by elliptical incision, 585—Subcutaneous excision, by inferior curved incision, 586.

III. Superior Mediastinum:—Surgical anatomy, 587—Surface form and landmarks, 587—General surgical considerations, 587.

IV. Anterior Mediastinum:—Surgical anatomy, 588—Anterior mediastinal thoracotomy, by long median incision (Milton's anterior mediastinotomy), 588—Anterior

mediastinal thoracotomy, by osteoplastic resection of part of sternum corresponding with third, fourth, and fifth costal cartilages, 590—Other operations, 592.

V. Middle Mediastinum:—Surgical anatomy, 592—Operations upon middle mediastinum, 592.

VI. Posterior Mediastinum:—Surgical anatomy, 592—Posterior mediastinal thoracotomy, by thoracoplastic flap (Bryant), 593.

VII. Diaphragm:—Surgical anatomy 595—Transthoracic exposure of diaphragm, by partial excision of two or three ribs, 596.

VIII. Pleuræ:—Surgical anatomy, 599—Surface form and landmarks, 600—Paracentesis thoracis, 601—Intercostal thoracotomy, 601—Thoracotomy, by partial excision of one or more ribs, 602—Thoracoplasty (Estlaender's operation), 604—Thoracoplasty (Schede's operation), 607—Other operations, 609.

IX. Lungs:—Surgical anatomy, 609—Pneumotomy, through a thoracoplastic flap, 611—Partial pneumectomy, through an osteo-thoracoplastic flap, 612.

X. Pericardium:—Surgical anatomy, 614—Surface form and landmarks 615—Paracentesis pericardii, 615—Pericardiotomy, through intercostal incision, 616—Exposure of pericardium and heart, by excision of left fifth costal cartilage, 617—Exposure of pericardium and heart, by osteo-thoracoplastic resection of anterior chest-wall, 619—Pericardiorrhaphy, 619.

XI. Heart:—Surgical anatomy, 619—Paracentesis of right auricle, 620—Paracentesis of right ventricle, 621—Cardiorrhaphy, 621.

XII. Thoracic Trachea:—Surgical anatomy, 622—Thoracic tracheotomy, 622.

XIII. Bronchi:—Surgical anatomy, 622—Bronchotomy, 623.

XIV. Thoracic Esophagus, 623—Surgical anatomy, 623—Thoracic esophagotomy, by posterior mediastinal osteoplastic flap operation, 623.

CHAPTER V.

OPERATIONS UPON THE ABDOMINO-PELVIC REGION.

I. Abdomino-pelvic Wall:—Surgical anatomy, 624—Surface form and landmarks, 627—General surgical considerations, 629—Instruments, 631—Median abdominal section, 631—Anterolateral abdominal section, by McBurney's intramuscular "gridiron" incision, 637—Anterolateral abdominal section, by Weir's prolongation of the anterolateral intra-muscular incision through rectal sheath, with temporary displacement of rectus, 639—Anterior abdominal section through rectal sheath, with temporary displacement of rectus, by the Battle-Jalaguier-Kammerer method 641—Median inferior abdominal section by Pfannenstiel's superficial transverse curved, and deep vertical incisions, 643—Inferior anterolateral abdominal section, by Meyer's "hockey stick" incision, 644—Inferior anterolateral abdominal section, by Fowler's angular incision, 645—Superior anterolateral abdominal section, by oblique subcostal incision, 646—Lateral abdominal section by Vischer's lumbo-iliac incision, 646

II. Peritoneum:—Surgica lanatomy, 647—General surgical considerations, 649—Operations for separation, division, or ligation of peritoneal adhesions, 649—Paracentesis abdominis, 651.

III. Omentum:—Surgical anatomy, 652—General surgical considerations, 653—Ligation of omentum, 653—Omental grafting, 654.

IV. Mesentery:—Surgical anatomy, 654—General surgical considerations, 655—Partial excision, 655—Suturing, 655.

V. Intestines:—Surgical anatomy of small intestines, 655—Surface form and landmarks of small intestines 658—Surgical anatomy of large intestines, 658—Surface form and landmarks of large intestines, 661—General surgical considerations in operations upon the intestines 662—Instruments, 662—Enterotomy, 663—Enterorrhaphy, in general, 663—By Lembert's interrupted suture, 665—By Czerny-Lembert interrupted suture, 666—By Halsted's interrupted quilt or mattress suture, 667—By Lembert's continuous suture, 668—By Cushing's right-angled continuous suture, 668—By combined overhand continuous suture of all coats, followed by interrupted Lembert suturing of outer coats, 670—Enterorrhaphy for wounds of intestine, 670—Partial enterectomy, 672—Entero-enterostomy (intestinal anastomosis, approximation, and implantation) in general, 675—(A) Entero-enterostomy by methods of simple suturing, in general, 676—By simple con-

tinuous overhand suture of all coats, followed by interrupted or continuous Lembert sutures of outer coats, by author's method, 677—By Czerny-Lembert interrupted suture, 685—By Halsted's method of interrupted mattress or quilt sutures, 686—By Maunsell's invagination method. 688—(B) Entero-enterostomy by means of absorbable mechanical devices left within the intestines in general, 696—By means of absorbable bobbins, 697—By absorbable buttons, 698—By Ullmann's modification of Maunsell's method, 699—By Coffey's method, 701—(C) Entero-enterostomy by means of non-absorbable mechanical devices left within the intestinal canal, in general, 702—By means of the Murphy button. 703—(D) Entero-enterostomy by mechanical means temporarily used for approximating the intestinal edges during suturing, in general, 710—By means of Halsted's inflatable rubber cylinder, 710—By Lee's intestinal holder, 714—By Laplace's intestinal anastomosis forceps, 718—Excision of ilio-cæcum, 720—Appendicectomy, by McBurney's intramuscular operation, 722—Appendicectomy, by the ordinary method, 727—Enterostomy, in general, 727—Right inguinal enterostomy (or ileostomy) for establishment of temporary fecal fistula, 728—Right inguinal enterostomy (or ileostomy) for establishment of permanent artificial anus, 730—Colostomy, in general, 731—Left inguinal colostomy, 732—Left lumbar colostomy, 736—Operation for closure of fecal fistula and artificial anus, 739—Enteroplasty, 742—Colopexy, by Bryant's method, 742—Rectopexy, by Verneuil's method, 743—Internal rectotomy, 744—External rectotomy, 744—Excision of rectum, in general, 745—Excision by sacral route by partial excision of sacrum (Kraske's operation), 745—Excision by sacral route, by the Rehn-Rydygier osteoplastic flap method, 750—Excision of lower part of rectum by perineal route, 752—Operation for cure of hemorrhoids by ligation and excision (Allingham's method), 754—Operation for cure of hemorrhoids by excision (Whitehead's method), 755—Operation for cure of hemorrhoids by clamp and cautery, 756—Operation for cure of fistula-in-ano by incision, 757.

VI Stomach:—Surgical anatomy, 760—Surface form and landmarks, 761—General surgical considerations, 761—Instruments, 762—Introduction of stomach-tube, 762—Gastrotomy, by median incision, 762—Gastrotomy by oblique subcostal incision, 764—Gastrorrhaphy, 765—Gastrostomy, in general, 766—Gastrostomy, by Ssabanajew-Franck's method, 767—Same, by Witzel's method, 769—Same, by Marwedel's method, 772—Same, by Kader's method, 774—Gastro-enterostomy, in general, 776—Anterior gastro-enterostomy, by simple suturing (Wölfler's method), 777—Same by the Murphy button, followed by single or multiple intestinal anastomosis by the Jaboulay-Braun method, 781—Posterior gastro-enterostomy, by Von Hacker's method, 783—Same, by the Murphy button, 785—Gastrogastrostomy by Wölfler's method, 785—Gastroplication, by Weir's modification of Bircher's method, 787—Gastropexy, 788—Gastrolysis, 789—Gastroplasty, 789—Pyloroplasty, by Heineke-Mikulicz method, 789—Divulsion of pyloric orifice of stomach, by Loreta's method, 791—Dilatation of cardiac orifice of stomach, 791—Pylorectomy, in general, 791—Pylorectomy, followed by posterior gastroduodenostomy, by Kocher's method, 792—Pylorectomy followed by end-to-end gastro-enterostomy, by Billroth's method, 795—Partial gastrectomy, followed by gastrojejunostomy, together with closure of duodenum, and jejunojejunostomy, 798—Total gastrectomy, 799—Operation for gastric ulcer, 800.

VII. Liver:—Surgical anatomy, 800—Surface form and landmarks, 802—General surgical considerations, 802—Instruments, 804—Exploratory puncture of liver, 804—Hepatotomy, in general, 805—Anterior subcostal transperitoneal hepatotomy, by anterior oblique incision parallel with costal arch, 806—Exposure of liver by anterior subcostal transperitoneal route, by anterior vertical incision through right linea semilunaris, 808—Exposure of liver by lateral subcostal transperitoneal route, by lateral horizontally curved incision below right twelfth rib, 809—Exposure of liver by intercostal subpleural route, by intercostal incision below level of pleura, 809—Exposure of liver by subpleural route, by partial excision of one or more ribs below level of the pleura, 810—Exposure of liver by subpleural route, by partial excision of one or more ribs opposite the pleura, 810—Exposure of liver by transpleural route, by partial excision of one or more ribs opposite the pleura, 812—Exposure of liver by chondroplastic resection of right costal arch, by anterior oblique subcostal incision, 813—Hepatorrhaphy, 813—Hepatopexy, 814—Partial hepatectomy, 814.

VIII. Gall-bladder:—Surgical anatomy, 815—Surface form and landmarks, 816—General surgical considerations, 816—Instruments, 816—Cholecystotomy, by oblique sub-

costal incision, 816—Cholecystotomy, by oblique or vertical subcostal incision, 817—Cholecystendysis, by oblique or vertical subcostal incision, 819—Cholecystenterostomy, by Murphy button, 819—Cholecystenterostomy, by simple suturing, 820—Cholecystolithotrity, 821—Cholecystectomy, 821.

IX. Gall-ducts:—Surgical anatomy, 823—Surface form and landmarks, 823—General surgical considerations, 823—Instruments, 823—Choledochotomy, 824—Cholelithotrity, 826.

X. Spleen:—Surgical anatomy, 827—Surface form and landmarks, 828—General surgical considerations, 828—Instruments, 828—Exploratory puncture, 828—Splenotomy, by oblique subcostal incision, 829—Exposure of spleen by subpleural route, by partial excision of one or two ribs, 829—Splenorrhaphy, 830—Splenopexy, 830—Partial splenectomy, by subcostal incision parallel with ribs, 831—Total splenectomy, by vertical incision in left linea semilunaris, 831.

XI. Pancreas:—Surgical anatomy, 833—Surface form and landmarks, 834—General surgical considerations, 834—Instruments, 835—Pancreatotomy, by gastrocolic route, 835—Partial pancreatectomy, by gastrocolic route, 836.

XII. Kidneys:—Surgical anatomy, 837—Surface form and landmarks, 839—General surgical considerations, 841—Instruments, 841—Retroperitoneal exposure of kidney by oblique lumbar incision, 841—Retroperitoneal exposure of kidney, by Koenig's angular lumbo-abdominal incision, 844—Retroperitoneal exposure of kidney, by lumbar intramuscular method, 845—Transperitoneal exposure of kidney, by vertical incision in linea semilunaris, Langenbuch's operation, 845—Transperitoneal exposure of kidney by median abdominal section, 847—Exposure of kidney by combined abdominolumbar operation, by anterior transperitoneal and posterior retroperitoneal incisions, 847—Exploratory puncture of kidney, 848—Nephrotomy, 849—Pyelotomy, 850—Nephrolithotomy, 850—Nephrorrhaphy, 851—Nephropexy, by suturing split and everted proper capsule of kidney to lumbar wall, Edebohls's operation, 852—Nephropexy, by suturing split proper capsule and parenchyma of kidney to lumbar wall, by oblique lumbar incision, Tuffier's operation, 856—Nephropexy, by simple suturing, 857—Total nephrectomy, by oblique lumbar incision, 858—Partial nephrectomy, by oblique lumbar incision, 859—Subcapsular nephrectomy, 860—Total nephrectomy by anterior transperitoneal method, 860.

XIII. Ureters:—Surgical anatomy, 861—Surface form and landmarks, 862—General surgical considerations, 862—Instruments, 863—Exposure of ureters, 863—Ureterotomy, 864—Ureterorrhaphy, 865—Uretero-ureteral anastomosis (uretero-ureterostomy), 865—Implantation of ureters, in general, 868—Implantation of ureters into bladder (ureterocystostomy), 869—Implantation of ureters into large intestine (ureterorectostomy) by Fowler's method, 870—Implantation of ureters upon skin, 873—Ureterectomy, in general, 873—Partial ureterectomy, by oblique lumbar incision, 874—Total ureterectomy, together with removal of kidney, by anterior median abdominal section 874.

XIV. Bladder:—Surgical anatomy, 875—Surface form and landmarks, 876—General surgical considerations, 877—Instruments, 878—Introduction of sound or catheter, 878—Paracentesis vesicæ, 879—Cystotomy, in general, 880—Suprapubic cystotomy, 880—Lateral perineal cystotomy, for removal of vesical calculus, 883—Median perineal cystotomy, for removal of vesical calculus, 886—Cystorrhaphy, 887—Lithotrity, 888—Lithola-paxy, 888—Vesical drainage, 892—Partial cystectomy, 893—Total cystectomy, by suprapubic median vertical and transverse incisions, 894.

CHAPTER VI.

OPERATIONS UPON THE MALE GENITAL ORGANS.

I. Penis:—Surgical anatomy, 895—Instruments, 895—Circumcision, 896—Partial amputation of penis, by flap method, 898—Total amputation, 900.

II. Urethra:—Surgical anatomy of male urethra, 902—Surgical anatomy of female urethra, 903—Surface form and landmarks, 903—General surgical considerations, 903—Instruments, 904—Introduction of sound or catheter, 904—Meatotomy, 904—Urethrotomy, in general, 904—Internal urethrotomy, by dilating urethrotome, 905—External perineal urethrotomy, upon grooved staff (Syme's operation), 907—External perineal urethrotomy, upon filiform guide (Gouley's operation), 908—External perineal urethrot-

omy upon grooved staff passed down to stricture (Wheelhouse's operation), 909—Perineal section, or external perineal urethrotomy without a guide (Cock's operation), 910—Urethrorrhaphy, 911—Urethrostomy, 911.

III. Scrotum and Testes:—Surgical anatomy, 912—Paracentesis tunicæ vaginalis, 913—Partial excision of scrotum, 913—Operation for hydrocele, by incision of tunica vaginalis, Volkmann's operation, 914—Operation for hydrocele, by incision, with partial excision of tunica vaginalis, Von Bergmann's operation, 915—Orchidectomy, 916.

IV. Spermatic Cord:—Surgical anatomy, 917—Instruments, 918—Partial vasectomy, 918—Operation for radical cure of varicocele, Bennett's modification of Howse's operation, 919.

V. Vesiculæ Seminales and Ejaculatory Ducts:—Surgical anatomy, 920—Instruments, 921—Total excision of vesiculæ seminales and part of ejaculatory ducts, by suprapubic retrocystic extraperitoneal route, Young's operation, 921.

VI. Prostate Gland:—Surgical anatomy, 922—Instruments, 923—Prostatotomy—Prostatectomy, in general, 923—Suprapubic prostatectomy, by median vertical incision, 924—Perineal prostatectomy, by transverse curved incision, 925—Prostatectomy by the combined median suprapubic and median perineal incisions, Alexander's operation, 926—Note, 928.

CHAPTER VII.

OPERATIONS UPON THE FEMALE GENITAL ORGANS.

I. Uterus:—Surgical anatomy of uterus, broad ligaments, round ligaments, and vagina, 929—Surface form and landmarks, 932—Instruments, 932—Partial abdominal hysterectomy, together with removal of ovaries and tubes (partial abdominal hysterosalpingo-oöphorectomy), 933—Total abdominal hysterectomy, together with removal of ovaries and tubes (total abdominal hysterosalpingo-oöphorectomy), 935—Total vaginal hysterectomy, 935.

II. Ovaries:—Surgical anatomy of ovaries, fallopian tubes, 941—Ovariectomy, or oöphorectomy, with removal of fallopian tube (salpingo-ovariectomy, or salpingo-oöphorectomy), 942—Note, 944.

CHAPTER VIII.

OPERATIONS FOR HERNIÆ.

I. Inguinal Hernia, 945—Surgical anatomy, 945—General surgical considerations, 946—Instruments, 948—Operation for radical cure of oblique inguinal hernia, Bassini's method, 948—Operation for radical cure of same, Halsted's method, 953.

II. Femoral Hernia, 955—Surgical anatomy, 955—General surgical considerations, 957—Operation for radical cure of femoral hernia, Bassini's method, 957.

III. Umbilical Hernia, 958—Surgical anatomy, 958—Operation for radical cure of umbilical hernia by excision of sac and suturing of freshened edges of ring, 959.

INDEX 961

THE NEW YORK
LIBRARY.
ACADEMY OF MEDICINE

A TEXT-BOOK

OF

OPERATIVE SURGERY

BICKHAM

LIBRARY.

THE NEW YORK LIBRARY. ACADEMY OF MEDICINE.

PART I.

THE OPERATIONS OF GENERAL SURGERY.

CHAPTER I.

OPERATIONS UPON THE ARTERIES.

LIGATION OF ARTERIES.

GENERAL CONSIDERATIONS.

Description.—The ligation of an artery signifies the tying of the artery for the purpose of controlling the circulation in that vessel.

Varieties of Ligation.—A ligation may be "terminal," where the cut end of an artery is tied;—"in continuity," where tied in its unbroken course;—"single," where but one ligation is used;—"double," where two are applied (as in dividing a vessel between ligatures);—"immediate," where applied directly to the artery proper;—"intermediate," where the ligature passes around more or less connective or other tissue surrounding the artery (as in ligation for parenchymatous hemorrhage);—"permanent," where applied to remain;—or "temporary," where applied for momentary arrest of circulation.

Indications for Ligation of Arteries.—Wounds; aneurisms; hemorrhage, from main trunk near site of ligation, or from either main trunk or one of its branches at a distance from site of ligation; rupture of vessels; angiomata; to control hemorrhage in operations distal to site of ligation; to lessen nutrition of inoperable tumors; to cause atrophy of an organ by diminishing its blood-supply (as in ligation of internal iliac for enlarged prostate gland).

Preparation.—(1) General;—none is necessary for the smaller ligations. In the case of the ligation of the larger arteries, the constitutional state of the patient should be looked after as in other major operations. (2) Local;—the usual antiseptic preparation of the part—the patient coming to the table with the site of operation in an aseptic dressing.

Position.—Patient upon table of proper height, and so placed as to bring the involved artery most conveniently and advantageously before the surgeon. Surgeon stands where he can best manipulate, which is generally on the side of the operation, and usually cuts downward on the right, and upward on the left. Assistant generally stands opposite the surgeon, and exposes the field of operation by retraction, or assists in the steps of the ligation. The position of patient, surgeon, and assistant will vary according to the artery operated upon, and will be given in the individual operations.

Instruments.—Esmarch bandage and tourniquet; scalpels, heavy and

light; scissors, straight and curved, sharp-pointed and blunt; forceps, dissecting and toothed; hemostatic forceps; grooved director; tenacula; retractors, various sizes and shapes; aneurism-needles, large and small, straight and laterally curved; ligature-carrier; ligaturing and suturing material (v. i.); needles, straight and curved, surgeon's and Hagedorn; needle-holder; wound-hooks; drainage materials (for special emergencies); means of illuminating deep wounds.

Ligature Materials.—Plain catgut; chromicized catgut; kangaroo tendon; ox aorta; silk, plain and floss. For the closure of skin-wounds, silkworm-gut or silk sutures.

(1) For the ligation of smaller arteries—plain catgut. (2) For medium arteries—chromicized catgut. (3) For largest arteries—kangaroo tendon (flat); ox aorta (flat); chromicized catgut; soft floss-silk.

Steps of the Operation of Ligation.—For the satisfactory carrying out of a ligation, a systematic course should be followed in all cases, the proper steps of which are given below, in order.

(a) **Control of Circulation Preliminary to Operation.**—In ligating the arteries of the head, neck, and trunk, no attempt is usually made to control the circulation by any means of pressure. In the limbs, also, it is rarely absolutely necessary. But where its use is preferred,—and the satisfaction of operating in a dry field is unquestionable,—the limb is first elevated, the soft parts massaged toward the trunk, and the tourniquet of Esmarch (without the previous use of the Esmarch rubber bandage) is applied around the limb, as high up as indicated. The sacrifice of the guiding pulsation (necessitated by the use of any form of constrictor) is counterbalanced by the dryness of the field, especially in prolonged and difficult operations.

(b) **Line of Artery.**—This is determined in advance of any operative step, and is based upon a knowledge of the anatomy of the part. A knowledge of the chief variations in the course of the arteries should also be possessed. Acquaintance with the line of the special artery is an absolute pre-requisite—a correct line, properly followed, leading directly and expeditiously to the goal of the operation;—an incorrect line, once taken, often plunging the operator into unnecessary difficulties from the start, frequently requiring loss of time, retracing of steps, unnecessary injury to structures, and the regaining of the right path finally after considerable and humiliating bungling. This line of the artery may be marked out upon the body with a sterilized dermographic pencil (or nitrate of silver stain)—but such marking is generally unnecessary. (1) The line of the artery is frequently modified by the position of the limb, and, in such cases, a constant position should be understood to apply in speaking of such arteries (for instance, the line of the brachial artery is one thing, if the arm be lying out supine at a right angle to the body; and another, if resting on its inner border parallel with the thorax) (Fig. 19). On the other hand, no change in the position of the foot causes a change in the line of the dorsalis pedis (Fig. 42). (2) The line of an artery often coincides so nearly with muscular or tendinous landmarks that these landmarks are often given instead of the line itself (for instance, one may speak of ligating the brachial artery by incising along a line extending from the junction of the anterior and middle thirds of the outer axillary boundary, to the middle of the bend of the elbow, the arm being at a right angle to the body and on its extensor surface; or one may also speak of ligating this artery by incising along the inner border of the coracobrachialis muscle above, and the biceps below, Fig. 19). It is well to know both the commonly accepted "line" and the natural muscular or other markings—the former is usually the more

accurate guide to the vessel (for instance, in the above case, the brachial artery is often considerably overlapped by the biceps in a well-developed subject), though the latter are the natural boundaries, which generally have to be encountered and manipulated before finally reaching the artery. (3) In other cases the line bears no relation whatever to external muscular or tendinous elevations or furrows, and, in such cases, the line alone has to be blindly followed, in the early part of the operation, as a guide to the course of the artery (as in the case of the upper portion of the ulnar artery, Fig. 23).

(c) **Incision.**—(1) Position and Direction of Incision:—In the great majority of cases the line of incision coincides with the line of the artery, from beginning to end of operation, superficially and in the deeper layers (as in ligation of the popliteal artery in the middle of the popliteal space), and should be so placed as to have its center over the site of ligation. In other cases the line of incision will follow a muscular marking, even if at a slight variance with the recognized "line of artery" (*e. g.*, in ligating the common carotid above the omohyoid, the incision is made parallel with the inner margin of the sternomastoid, which, in muscular and well-developed necks, is known to overlap and lie slightly to the inner side of the artery, Fig. 7, F). In other cases the incision follows neither line of artery nor muscular marking, but lies in a course parallel with both line of artery and muscular fibers, and is so placed as to reach the vessel most advantageously and with least damage to neighboring structures (*e. g.*, ligation of posterior tibial artery in middle of leg, Fig. 39, I). In other cases the incision may coincide with the line of artery but cross an overlying muscle at a right angle (*e. g.*, ligation of lingual artery beneath the omohyoid muscle) (Fig. 7, L). In still other cases the incision may cross the course of the artery at a right angle (*e. g.*, ligation of external iliac extraperitoneally, by an incision parallel with Poupart's ligament, Fig. 35). (2) Superficial Incision:—Having chosen the line of incision as free from superficial vessels and nerves as circumstances permit, steady the area of incision by means of the left thumb and forefinger, which, by their separation, put the parts under slight tension and give room for the knife-cut between them. Grasp the scalpel in the "pen-position" for finer, more limited cuts, and in the "dinner-knife position" for heavier, longer cuts. Enter the point of the scalpel at a right angle to the skin surface—traverse the line of incision with the knife-handle at about 45 degrees—and withdraw the knife with the point of blade again at a right angle to the surface, thereby cutting to equal depth throughout. This incision should pass through skin and superficial fascia, and, while not unnecessarily long, should be amply long enough to enable subsequent manipulations to be carried on without injury to the structures. The length of the incision should rather be determined by the depth of the artery and the nature of the parts to be encountered, than by any attempt to remember an arbitrary length of incision for each artery. The deep fascia is similarly divided in the original line—avoiding, where possible, superficial vessels, and, especially, nerves. (3) Deep Incision:—Having passed through all overlying fascia in the superficial incision, the muscle and tendinous landmarks now come to both sight and touch. Generally no further cutting is necessary—the rest of the approach and exposure of the artery being accomplished by blunt dissection. In by far the majority of cases arteries are henceforth reached by following down between muscular planes, it being very rare that muscle-fibers are separated, and rarer still that muscles are cut transversely. At this stage of the operation the muscular or tendinous boundaries are recognized and followed to the known position of the artery, the intermuscular planes being separated by the handle of the

scalpel rather than by the blade, and this separation being carried out to correspond with the length of the superficial wound. The three best means of recognizing intermuscular planes, in the order of their reliability, are:—sense of touch of tip of left index-finger (which flexion of the limb may aid);—following down of intermuscular branches of the artery;—the white fascial, or yellow fatty, so-called "line" in the intermuscular spaces. It is of great importance to recognize the proper intermuscular space at the start, as, once in a wrong intermuscular interval, one may wander on indefinitely, completely off the track, missing the artery and doing much damage to the parts (and injury to one's own feelings). Good retraction should be freely used at this stage, and muscles and tendons should be drawn to their proper sides (flexing the limb often aiding considerably in this retraction). Important vessels, nerves, and other structures should be guarded during this separation of the parts, and, when in the way, should be displaced to the more convenient side of the operation field—always remembering that nerves are the most important structures to be safeguarded, in the great majority of cases. If an Esmarch have not been used, the wound is kept comparatively dry by frequent sponging of the field with dry gauze-pads.

(d) **Exposure of Artery.**—Having gotten down into the region of muscles and tendons, these should be clearly identified, and the artery sought by its known relation to these structures. The muscles and tendons are the rallying-points in the depth of the wound. Three structures, outwardly more or less similar in appearance, and often in sensation, are to be distinguished:—(1) Arteries are recognized by their known course; their pulsation, when no proximal constriction is used (and by the hard, unyielding plaster or starch injection in the cadaver); their swelling proximally when compressed distally (where no constrictor is used); their firm, round, resisting, elastic, cord-like feeling; their peculiar sensation when compressed between the fingers, presenting a central depression and two lateral, elevated ridges; their thinner walls; their rubber-tube-like feeling when touched and tendency to glide from beneath the fingers; the force required to compress them; their regular outline; their pinkish or pinkish-yellow color. Of these means of recognition, pulsation is the conclusive test, provided there can be eliminated all possibility of error caused by pulsation transmitted through contact (as a vein or a nerve made to rise and fall by an artery beating beneath or to one side of it). (2) Veins are recognized by not pulsating (where no Esmarch is used); by having thinner coats; by swelling toward the periphery when compressed centrally (no constrictor being used); by being softer and less resisting to touch; by the flat, ribbon-like feeling throughout their whole width when compressed between the fingers; by their purplish color; by their wavy, irregular contour; by their accompanying the arteries, in many regions, in pairs or companion veins; by their larger size than the corresponding arteries; by the ease with which they are compressed. It may be mentioned here, in connection with the companion veins, that two venæ comites are to be found accompanying all arteries below the axilla; all arteries below the knee; most of the small and medium-sized arteries of the trunk; and that the arteries of the head and neck are accompanied by single veins. These veins generally run on either side of the artery, communicating across the artery at frequent intervals,—generally lying in front of and behind the artery when the intermuscular plane enclosing the artery lies anteroposteriorly,—and usually lying to the right and left of the artery when the intermuscular plane runs transversely. (3) Nerves are distinguished by their known position; their white color; their round contour, unyielding consistency, and non-compressibility; their

appearance of being made up of parallel bundles; their swelling neither proximally, like arteries, nor peripherally, like veins, when compressed (no constrictor being used).

(e) **Opening the Sheath.**—Having identified this structure and brought it well within the field, its wall is to be opened and the contained artery exposed—for the purpose of clearing a path for the aneurism-needle (Fig. 1). Only the main vessels have a distinct sheath of connective tissue, and the larger the artery, the more distinct the sheath. In some cases the accompanying vein and nerve are included in a common sheath, together with the artery—the sheath being composed of more or less condensed connective tissue. The smaller arteries are surrounded by a less distinct layer of areolar tissue, generally not demonstrable as a sheath. The sheath should be opened at least 1.3 cm. (½ inch) from any branch. With a pair of finely pointed forceps, pick up the sheath where it is desired to pass the ligature, and in such a way as to raise the sheath in a fold parallel with the long axis of the

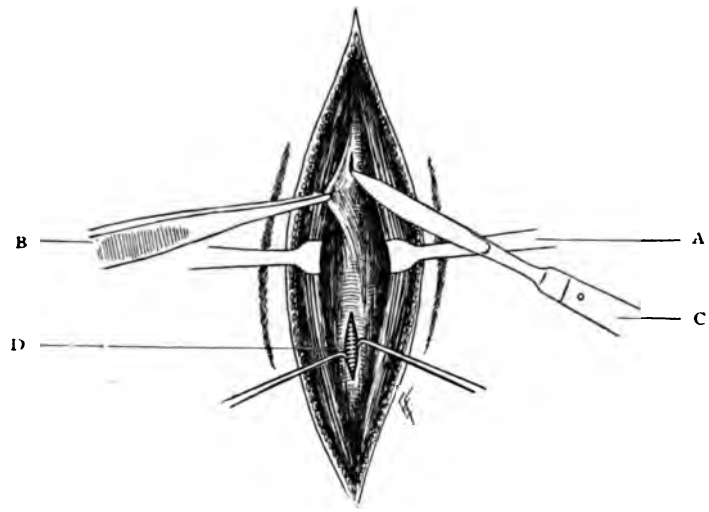

Fig. 1.—Ligation of an Artery. Opening the sheath. A, Retraction of adjacent muscles; B, Toothed forceps raising sheath of artery in a longitudinal fold; C, Incising sheath in long axis of artery; D, Artery visible through incised sheath.

vessel (Fig. 1, B). Let the forceps pick up the sheath upon its anterior aspect, but slightly to one side of the median longitudinal line, thereby leaving space to incise the sheath exactly in the middle line. After grasping the sheath, shift the forceps gently up and down to see that the sheath, held in the bight of the forceps, glides over the contained vessel, proving, thereby, that no part of the artery itself is picked up. This longitudinal fold of the sheath, while held by the forceps and lifted up from the artery, is incised in the long axis of the artery, for a distance of about 6 to 8 mm. (¼ to ⅓ inch) (the shorter the distance of separation of the sheath the better, to preserve the vasa vasorum), the flat surface of the knife being turned to the artery (Fig. 1, C). As soon as the incision is made in the sheath, a gap appears between the wall of the artery and the wall of the sheath (Fig. 1, D). The hold of the forceps upon the wall of the sheath should be retained, not being relaxed after once grasping the fold of sheath. In ligating smaller

arteries, which have no well-defined sheath, the vessel is simply freed of all visible connective tissue. (This axial division of the sheath of the artery is preferable to the transverse division so often advised.)

(f) **Clearing the Artery.**—A path for the passing of the ligature between the outer wall of the artery and the inner wall of the sheath is now to be made, and the best instrument with which to make it is the dull, flat end of a curved aneurism-needle (Fig. 2). Having retained the original hold of the forceps upon the sheath, insinuate the end of the needle between this wall of the sheath and the artery, and while drawing this lip of the sheath gently away from the artery, carefully work the point of the needle around one-half of the circumference of the artery, in the connective-tissue plane between artery and sheath, by a combination of forward movement, on the part of the tip of the needle, with a side to side movement, on the part of the lateral margins of the curved tip, over a distance of from 6 to 8 mm. ($\frac{1}{4}$ to $\frac{1}{3}$ inch) (Fig. 2,

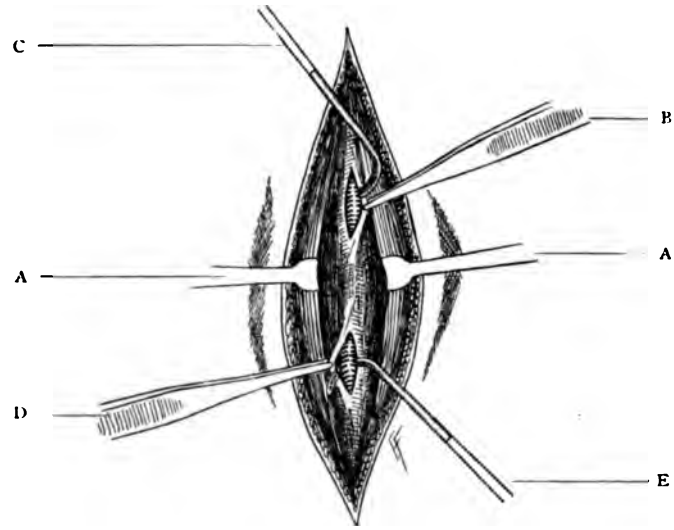

Fig. 2.—Ligation of an Artery. Clearing the artery. A, A, Retraction of adjacent muscles; B, Forceps grasping nearer lip of sheath; C, Aneurism-needle clearing artery in its passage between sheath and vessel; D, Forceps grasping further lip of sheath; E, Aneurism-needle emerging between artery and further lip of sheath.

C). Having thus cleared a path around half the vessel, and still holding the tip of the needle in the path already cleared, the forceps for the first time relinquishes its hold on the lip of the sheath originally grasped, and grasps the opposite lip of the sheath and similarly draws this part of the sheath away from the artery (Fig. 2, D), at the same time also similarly working the point of the needle onward and from side to side, until it clears a way completely around the artery and appears between the vessel and the further lip of the sheath (Fig. 2, E). Throughout this entire manœuvre the handle of the needle is held approximately at a right angle to the vessel, and the tip of the needle hugs the wall of the artery, especially while working under its deepest part, particularly where a common sheath contains other structures, and thereby is prevented from penetrating the sheath and injuring the vessels, nerves, or viscera beyond.

(g) **Passing the Ligature.**—Once a passage has been cleared between

artery and sheath, the aneurism-needle readily traverses it—so that as soon as the needle has appeared on the further side of the artery, it is withdrawn. The needle is now threaded and carefully passed between vessel and sheath, through the previously cleared way, following precisely the same course and carrying out the same steps—first opening the entrance to the passage by drawing the sheath away with forceps—then hugging the vessel in making the circuit—and finally emerging on the opposite side between the vessel and the further lip of the sheath, which the forceps have now grasped and drawn away (Fig. 3). An aneurism-needle may be passed with a fine silk ligature-loop as a carrier, and through this "carrier" the proper ligature may be threaded and drawn back. There is no fixed rule for the direction in which

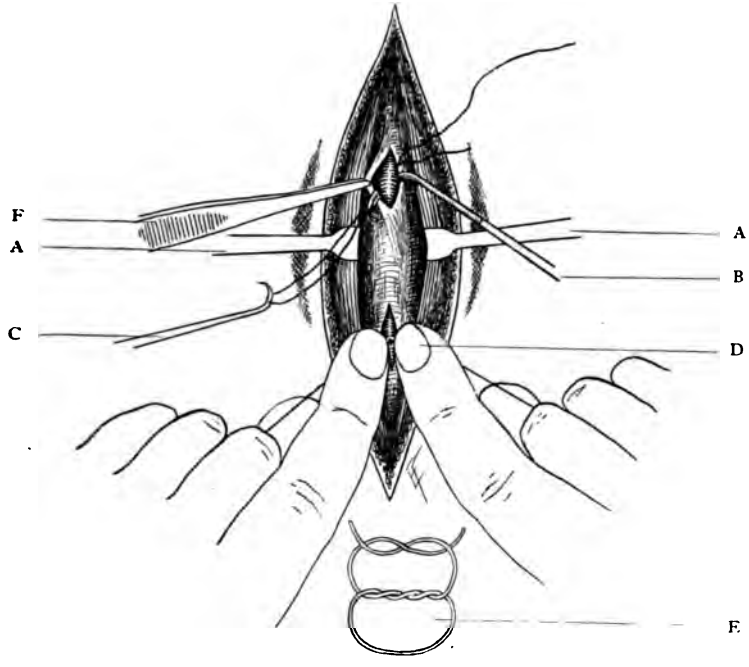

Fig. 3.—Ligation of an Artery. Passing the ligature and tying the knot. A, A, Retraction of neighboring parts; B, Aneurism-needle carrying ligature beneath artery; C, Tenaculum drawing one end of ligature under artery, while aneurism-needle is being withdrawn; D, Tying the knot; F, Retracting lip of sheath.

Fig. 4.—Knot Used in Ligating Medium and Large Arteries. E, Two turns of a friction-knot followed by a reef-knot.

the needle should be passed in each case; the rule should be that the needle is to be passed from the more important structures toward the least important, or from the structures more difficult to avoid toward those more easily avoided. Therefore the needle may enter the sheath in the reverse order to that in which it has been freed from the artery, or vice versa, as seems safest and easiest. Having passed the needle completely around the vessel, until its threaded eye protrudes on the opposite side, grasp one of the threads of the looped ligature with forceps, and, while it is being held in the grasp of the forceps, carefully withdraw the needle, following the curve of the artery (Fig. 3, B, C). Thus a single thread is left beneath the vessel—an end coming out between artery and sheath on either side. Some surgeons pass

the needle unthreaded, and thread the eye on the opposite side, then, holding one arm of the ligature with forceps, withdraw the needle—with the same result. There is no objection to this method in simple cases where the artery is accessible and the threading easily done with the needle *in situ* (as in the lower third of the radial), but it should not be attempted in a region where the exposure is difficult (as in the retroperitoneal ligation of the common iliac). Such an instrument as the Cleaveland needle (ligature-carrier) is preferred to the common aneurism-needle by some—the instrument, being passed under the artery empty, grasps the ligature on the opposite side, and draws back one end under the vessel. In arteries too small to have sheaths the ligature is simply carried under and around the artery, which has been freed of all connective tissue, the general method being the same as just described.

(h) Tying the Knot.—The largest arteries are most safely and satisfactorily tied with the "stay-knot" of Ballance and Edmunds. The stay-knot of these surgeons is made by conducting two bundles of soft floss-silk around the artery, parallel with each other and side by side;—the first stage of a reef-knot is then tied in each bundle, so that two knots lie side by side, the force to tie them having been sufficient to closely approximate the inner and middle coats of the artery and completely stop the flow, but without rupturing these coats (Fig. 5, A). After tying these at first lightly, they are both taken up together and gently tightened simultaneously. The two ends of the two bundles are then taken up on the one side, and the two ends of the other two bundles on the opposite side,—the two bundles on each side now being regarded as one,—and these two bundles are tied in a single knot, after the manner of the second step of a reef-knot (Fig. 6, B). Thus a knot is formed the first part of which will not slip while the second is being tied (which is apt to be the case in large arteries, especially if they be pulsating at the time, thus allowing the establishment of a small stream of blood). By this method a broad compression and approximation of the arterial coats will be accomplished, which will add strength to the site of ligation against secondary hemorrhage. This simple approximation is sufficient to excite endothelial proliferation and union of the opposed surfaces. It is hard to draw such a ligature tight enough to rupture the inner coats. An artery with its two inner coats ruptured by ligation has only the strength of its outer coat to withstand the strain of the circulation until the secondary phenomena take place, which permanently strengthen the site—prior to which secondary hemorrhage may occur. Several parallel strands of smaller-sized chromic catgut, led under the artery by a carrier, are sometimes used, thus securing width for the ligature and the consequent distribution of pressure. All

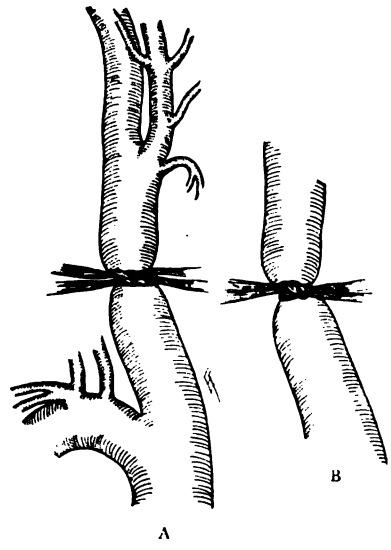

Figs. 5 and 6.—Floss-silk Stay-knot of Ballance and Edmunds. A, First stage; B, Second stage.

medium-sized arteries should be tied with a surgeon's knot (a friction-knot followed by the second step of a reef-knot) (Fig. 4, E). All small arteries are safely tied with the reef-knot alone In making tension upon the ends of the ligature, special care should be taken not to lift the artery out of its sheath. To avoid this, the tips of the right and left forefingers should come together, end to end, directly upon the knot in the act of being tied, and the tightening should be done by putting the terminal and middle knuckles of the index-fingers in apposition, back to back, and using them as fulcra (Fig. 3, D). The thumbs may be similarly used, instead of the forefingers. It is a disputed point as to how much tension should be used in tightening a ligature. It may be said that it is best to tighten the ligature upon all large vessels sufficiently to thoroughly approximate their inner wall in pleats, thereby completely closing the lumen, without rupturing their two inner coats. The same holds true of all diseased vessels, independently of their size. All medium vessels may be similarly ligated. The smaller arteries generally have their ligatures tightened sufficiently to rupture their inner and middle coats. A tightening almost sufficient to sever all coats, especially when using silk, is distinctly to be avoided. Secondary hemorrhage seems less frequent, and the strength of the vessel greater, where the vessels are only tightened enough to closely approximate the two inner coats, without causing their rupture. All knots should be cut comparatively short. A round ligature tightly drawn will rupture the inner coats; a broad ligature will do so far less readily.

(i) **Closure of Wound.**—Where a large, well-marked sheath has been opened in exposing the artery, although not absolutely necessary, it is well to unite the edges of the sheath by one or two fine catgut sutures. Where any muscle tissue has been incised in order to reach the artery, it is usually best to repair the divided muscle tissue by catgut sutures passed through the lips of the muscle wound—which suture becomes buried in the final steps of the operation. Where deep intermuscular planes have been opened up, and dead spaces are apt to be left, it is advisable to put in a few buried catgut sutures through the muscle tissue, drawing together the muscles into their normal intermuscular cleavage line. Where no muscle has been wounded, —and in the final step of those cases where muscle has been incised and sutured,—complete closure of the wound is accomplished by a line of interrupted silkworm-gut or silk sutures, or by a continuous silk suture—the suturing, in either case, being materially aided by putting the wound on the stretch by a wound-hook in either end. No form of drainage is used in clean cases. A simple gauze and cotton dressing, held in place by a bandage, completes the dressing.

(j) **After-treatment.**—Very little after-treatment is indicated in the ligation of the smaller arteries. Where a large artery is ligated, a splint should be incorporated in the dressing where feasible, in order to control all movement of the part. In the case of the main artery of a limb, the limb should be encased in cotton, and artificial warmth applied in addition, until the new circulation is established. The limb is elevated in bed to favor venous return. The skin sutures are removed on the seventh or eighth day. A rest in bed of from two to four weeks is required in the ligation of the larger arteries.

Local Results of Ligation.—Obliteration of artery at site of ligation. Establishment of a new (collateral) circulation.

Chief Dangers in Ligation of Arteries.—Secondary hemorrhage. Gangrene.

Comment.—(1) Where it is difficult or impossible to separate one or more veins from the artery, the artery and vein, or veins, may be included in the one ligature. (2) Especial care should be taken to avoid the inclusion of the smallest nerve in the ligature. (3) When a large vein is wounded, the wound should be at once closed by lateral ligature (Fig. 70), or by suturing (Fig. 69), preferably the former. If this be not feasible, the vein should be ligated. All medium and small veins should be ligated if wounded. If the ligation of the artery can be accomplished without the likelihood of again wounding the vein, it should be completed at the original site. If there be danger of further complication, a new site should be chosen just above or below the one originally selected. (4) It is held by some that secondary hemorrhage is less likely if an artery be ligated in two places, from 2.5 to 5 cm. (1 to 2 inches) apart, and then divided between these two ligatures, allowing each end to retract—upon the principle that the arteries of the body are constantly under longitudinal tension, and, when ligated in continuity (especially where the inner coats are severed), there are present the conditions calculated to predispose to secondary hemorrhage. Practical experience seems to have borne out the claim of the double ligature with division, but the operation is not always feasible, especially in the deeper, larger vessels. (5) All ligature material should be thoroughly pliable before being used.

SURGICAL ANATOMY OF INNOMINATE ARTERY.

Description.—Largest branch of arch of aorta. From 3.8 to 5 cm. (1½ to 2 inches) in length. Arises from beginning of arch of aorta, opposite fourth dorsal vertebra; runs upward, forward, and to right, to upper border of right sternoclavicular articulation, where it divides into right common carotid and right subclavian.

Relations.—**Anteriorly:** manubrium; origin sternohyoid; origin sternothyroid; right sternoclavicular joint; remains of thymus gland; left innominate vein; right inferior thyroid vein; inferior cervical cardiac branches of right pneumogastric. **Posteriorly:** trachea; right pleura. **To right:** right innominate vein; right pneumogastric nerve; right pleura. **To left:** left common carotid; remains of thymus gland; left inferior thyroid vein; trachea.

Branches.—Thyroidea ima (sometimes); thymic branch (sometimes); bronchial branch (sometimes).

Line of Artery.—From center of manubrium, to center of right sternoclavicular joint.

Indications for Ligation.—Aneurism of right carotid, subclavian, and of innominate itself.

Sites of Ligation.—From 1.3 to 2 cm. (½ to ¾ inch) below bifurcation (Fig. 7).

LIGATION OF INNOMINATE ARTERY

BY ANGULAR INCISION (MOTT'S OPERATION).

Position.—Patient supine, chest raised, head backward and to opposite side. Surgeon to outer side of shoulder. Assistant opposite surgeon.

Landmarks.—Clavicle; sternomastoid muscle; sternoclavicular joint.

Incision.— ⅄-shaped (on right—reversed on left). Horizontal portion

of incision is made along upper margin of inner third of clavicle, for a distance of about 7.5 cm. (3 inches). Vertical portion (meeting horizontal at an acute angle) is made along anterior margin of sternomastoid, for about 7.5 cm. (3 inches) (Fig. 7, A).

Fig. 7.—Incisions for Ligation of Chief Arteries of Head and Neck:—A, A, Innominate by angular incision; B, B, Same, by oblique incision; C, C, Same, by partial bony resection, through an oblique incision; D, D, Same, by partial bony resection (Bardenheuer's operation); E, Same, by splitting manubrium; F, Common carotid, above omohyoid; G, Same, below omohyoid; H, External carotid, below digastric; I, Same, above digastric; J, Thyroid, at origin; K, Lingual, at origin; L, Lingual, beneath hyoglossus; M, Facial, over inferior maxilla; N, Occipital, behind mastoid process; O, Temporal, just above zygoma; P, Trunk of middle meningeal, by trephine-opening exposed by curved oblique incision (lower of two trephine-openings); Q, Anterior branch of middle meningeal, by trephine-opening exposed by horseshoe incision (higher of two trephine-openings); R, Posterior branch of middle meningeal, by trephine opening exposed by horseshoe incision; S, Internal carotid, near origin; T, Third part of subclavian; U, Transversalis colli and suprascapular, at outer margin of sternomastoid; V, Internal mammary, in second intercostal space; W, First part of axillary, by curved transverse incision below clavicle.

Operation.—Having incised skin and superficial fascia, this triangular flap is dissected upward. Cut the sternal and clavicular attachments of the sternomastoid, as far as exposed. The sternohyoid and sternothyroid muscles are also cut, or are nicked and drawn well inward. Expose, ligate doubly, and cut the anterior jugular vein between its two ligatures, lying beneath the sternomastoid; and also the right inferior thyroid vein. Divide the deep cervical fascia along the original lines of incision, thus exposing the common carotid. Open its sheath and follow to its origin, avoiding the recurrent laryngeal nerve. Thus guided to the innominate, clear its trunk—with especial care on the outer side, of the pneumogastric nerve, right innominate vein, and pleura—and pass the needle from these structures.

Comment.—(1) As the chief source of failure is secondary hemorrhage, the common carotid and vertebral arteries are also tied—being the chief sources through which the recurrent flow occurs. (2) This free section of muscles leaves, by their retraction, a deep gap at the root of the neck for infection and slow filling-up. As much repairing of cut muscle tissue as possible, by suturing, should, therefore, be done in completing the operation. (3) Artificial illumination is desirable in this operation.

Collateral Circulation.—First aortic intercostal, with superior intercostal of subclavian. Upper aortic intercostals, with thoracic branches of axillary and intercostals of internal mammary. Phrenic, with musculophrenic of internal mammary. Deep epigastric, with superior epigastric of internal mammary. Free communication of vertebrals and internal carotids of opposite side, inside of skull. Communication of branches of opposite external carotids in middle line of face and neck (MacCormac).

LIGATION OF INNOMINATE ARTERY

BY OBLIQUE INCISION.

Position—Landmarks.—As for Mott's operation (page 26).

Incision.—Begin at junction of middle and lower thirds of anterior border of right sternomastoid muscle—pass down along the lower third of its anterior margin—thence sweep over upper edge of the episternal notch onto the manubrium sterni (Fig. 7, B, B).

Operation.—Incise skin, superficial fascia, platysma, and deep fascia (Fig. 8). Tie anterior jugular vein between two ligatures—also ligate the transverse branch between the two anterior jugulars, if in the way. Draw the sternomastoid outward—and, if necessary, its inner, sternal portion may be divided. Draw inward the sternohyoid and sternothyroid muscles—and, if necessary, their sternal attachments may be partly or entirely cut. Incise the deep cervical fascia over the carotid sheath. Open the sheath and follow the common carotid behind the sternoclavicular articulation to the subclavian and to the innominate, guarding the recurrent laryngeal nerve behind the common carotid sheath. Ligate the right inferior thyroid vein. Clear the innominate, avoiding the left innominate vein in front—the right pleura behind—and the right pneumogastric nerve, right innominate vein, and right pleura to the right.

Comment.—(1) As above mentioned, under Mott's operation, the common carotid and vertebral arteries should also be tied—which can be done through this incision (2) By this separation and retraction of muscles (or partial division) less damage is done to the parts and less of a cavity is left.

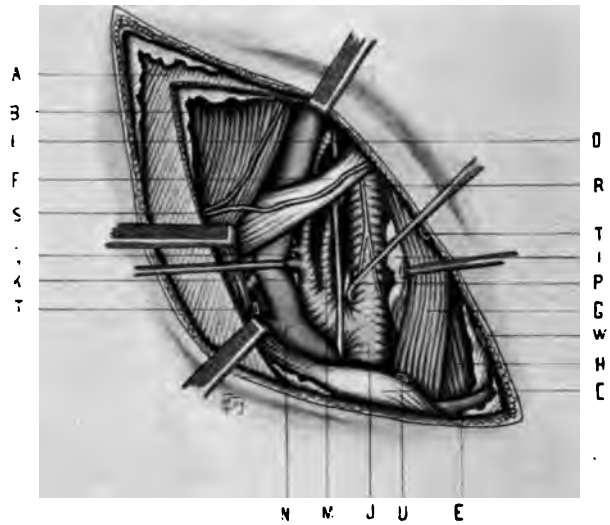

Fig. 8.—Ligation of Innominate by Oblique Incision; Also of Right Common Carotid below Omohyoid; Vertebral Near Origin; and Inferior Thyroid Near Origin:—A, Platysma; B, Sternomastoid retracted outward and downward; C, Right sternoclavicular articulation; E, Manubrium sterni; F, Omohyoid; G, Sternohyoid; H, Sternothyroid; I, Thyroid gland; J, Innominate artery dividing into common carotid and subclavian (hook is seen retracting common carotid, so as to draw innominate upward and inward); K, Thyroid axis; L, Inferior thyroid; M, Vertebral; N, Right innominate vein, with subclavian and internal jugular (last, drawn outward); O, Pneumogastric; P, Recurrent laryngeal; Q, Phrenic; R, Nerves from loop between communicans and descendens hypoglossi; S, Superficial cervical nerves; T, T, Anterior jugular vein; U, W, Inferior thyroid vein. The suprascapular and transversalis colli arteries are seen crossing scalenus anticus, behind internal jugular vein.

LIGATION OF INNOMINATE ARTERY

BY PARTIAL BONY RESECTION—THROUGH OBLIQUE INCISION.

Description.—The right sternoclavicular articulation, upper part of manubrium, and sternal end of first right rib are excised through an oblique incision—thus exposing the artery.

Position.—As in Mott's operation (page 26).

Landmarks.—Cricoid cartilage; sternomastoid muscle; manubrium.

Incision.—An oblique incision, beginning over the anterior margin of the right sternomastoid muscle, on a level with the cricoid cartilage—and passing down the anterior border of the sternomastoid, over the right sternoclavicular articulation, onto the manubrium—and down to the gladiolus (Fig. 7, C, C).

Operation.—Incise skin, superficial fascia, platysma, and deep fascia. Tie the anterior jugular vein between two ligatures. Protect the large veins by a spatula slipped behind the sternum. Having retracted the overlying parts, remove, with Gigli saw, rongeur, bone-cutting forceps, or chisel, the right sternoclavicular articulation, upper part of the manubrium, and insertion of the first right rib. Ligate the inferior thyroid veins. Separate the areolar tissue from the vessels,—guarding the neighboring structures as mentioned in the preceding operations,—when the innominate will be fully exposed to sight and touch. Temporary drainage is used in this, as in all ligations of the innominate

Comment.—The common carotid and vertebral are also tied.

LIGATION OF INNOMINATE ARTERY

BY PARTIAL BONY RESECTION—THROUGH TRANSVERSE AND VERTICAL INCISIONS—(BARDENHEUER'S OPERATION).

Description.—The following parts are excised through a combined transverse and vertical incision:—the right and left sternoclavicular articulations, sternal ends of right and left first ribs, sternal end of right second rib, and upper 2.5 cm. (1 inch) of manubrium—thus exposing the innominate.

Position.—As in Mott's operation (page 26).

Landmarks.—Suprasternal notch and manubrium; sternal ends of clavicles; inferior margin of thyroid cartilage.

Incisions.—(1) Transverse incision—along upper border of sternum and over the surfaces of the inner thirds of both clavicles. (2) Vertical incision —from lower border of larynx, down the median line, and well onto the manubrium sterni (Fig. 7, D, D).

Operation.—Carry both incisions through skin, superficial and deep fasciæ. In the transverse incision, divide sternomastoids, sternohyoids, and sternothyroids. Subperiosteally resect (with Gigli saw, rongeur, bone-cutting forceps, or chisel) the inner extremities of the left clavicle and left first rib—for about 1.3 cm. (½ inch) of their extent. Having made this exposure of the upper and outer portion of the manubrium upon its left aspect, free, through this approach, the posterior surface of the manubrium subperiosteally. The manubrium is then cut transversely through at a level about 2.5 cm. (1 inch) below its upper border—the division being accomplished, preferably, by a Gigli saw conducted beneath the bone, between it and the periosteum. The sternal ends of the right clavicle and the right first and second ribs, after having been well cleared, are divided close to the outer margin of the sternum, in the same manner as the manubrium was divided. The mass of bone detached by the above cuts is now removed. The periosteum is then incised in the median line—the inferior thyroid veins ligated—the left innominate vein depressed—the right innominate vein retracted—the right pneumogastric nerve and pleura guarded on the outer side and behind—the innominate artery cleared—and the ligature passed from the pleura and pneumogastric.

LIGATION OF INNOMINATE ARTERY

BY SPLITTING OF MANUBRIUM STERNI.

Description.—The manubrium is exposed by a transverse incision—divided transversely at its junction with the gladiolus—then split vertically at its center—followed by the separation of the two halves of the manubrium and the exposure of the innominate. Upon completing the operation, the bony parts are returned to their normal positions—with or without suturing of the edges of the vertically divided manubrium into apposition.

Position.—Patient supine; shoulders raised; neck prominent. Surgeon to right side. Assistant opposite.

Landmarks.—Sternoclavicular articulations; lower border of manubrium (marked by line extending transversely across between the articulations of the second ribs).

Incision.—Curved transverse incision—passing from inner third of anterior surface of one clavicle to the inner third of the anterior surface of

the opposite clavicle, and passing down over the manubrium to the junction of its upper and middle thirds (Fig. 7, E).

Operation.—Having incised skin, fascia, and anterior borders of the platysma down to the bone, clamp and tie all bleeding vessels. Free the manubrium subperiosteally over its anterior surface, downward to the junction of the manubrium and gladiolus, and upward to its superior border. Follow the superior border backward and downward along its posterior aspect—also freeing this surface subperiosteally as far as the junction of manubrium and gladiolus. Retract the overlying soft parts on the anterior aspect of the manubrium and divide the sternum along the manubrio-gladiolar junction—accomplishing the division with a Gigli saw, if one can be conducted across beneath the bone, or by bone-cutting forceps. Through the opening thus made by the transverse division, carry a Gigli saw from the center of the lower border of the divided manubrium to the center of the suprasternal notch—and divide the manubrium vertically in its center, cutting from the manubrio-gladiolar junction upward toward the free superior border—the Gigli saw traveling between the posterior surface of the manubrium in front, and its periosteum posteriorly. After the completion of the vertical section, retract the two halves of the manubrium laterally—incise the posterior periosteum—ligate the inferior thyroid veins—depress the left innominate vein, retract the right innominate vein—guard the right pneumogastric and pleura externally and posteriorly—clear the innominate—and pass the ligature from the pleura and pneumogastric.

Comment.—Where it is wished to suture together the vertical borders of the split manubrium, two or three holes should be drilled on each side as soon as the manubrium has been exposed anteriorly and posteriorly, and before its division—the soft parts below being protected by some thin, flat metallic instrument during the drilling.

Comparison of Methods of Exposure of the Innominate.—Choice would be given to methods of non-division of muscles, with retraction—the oblique incision thus being preferable to the angular one—where these incisions promise sufficient room for manipulation. Where more room is necessary, especially from abnormal displacement of the parts (as from aneurism), the angular incision, or the methods of partial resection, give more space for the safe carrying-out of the necessary steps; and of these latter, the method of partial resection upon the right aspect of the manubrio-clavicular region is applicable to cases where a more limited sacrifice of bone will suffice; and Bardenheuer's operation—or the splitting of the manubrium—where the maximum space is required. The innominate has also been ligated through a trephine-opening made through the manubrium sterni, after turning back a flap of soft parts.

SURGICAL ANATOMY OF COMMON CAROTID ARTERIES.

Description.—(a) Right Common Carotid: About 9.5 cm. (3¾ inches) in length. Arises from bifurcation of innominate, behind right sternoclavicular articulation—passes upward and outward and slightly backward to upper border of thyroid cartilage (opposite fourth cervical vertebra, according to Morris;—third cervical vertebra, according to Gray)—there dividing into external and internal carotids. In its course it is contained within a common sheath of connective tissue, which also includes internal jugular vein and pneumogastric nerve, each separated by a fibrous septum—the vein lying to

outer side and slightly overlapping artery, and the pneumogastric lying between and posterior to both. The omohyoid muscle crosses common carotid opposite lower border of cricoid cartilage, and divides the artery, surgically, into a lower part, deeply placed—and an upper part, superficially placed. **(b) Left Common Carotid:** About 11.5 cm. (4¾ inches) in length. Arises from middle of transverse portion of arch of aorta—ascends upward and outward behind, but at some distance from, manubrium sterni, overlapped by left lung and pleura, and in front of trachea, to left sternoclavicular articulation—whence its course, relations, and terminations are same as for right common carotid. The crossing and relations of the omohyoid muscle are also similar.

Relations.—(a) Left Common Carotid in Thorax: Anteriorly—manubrium sterni; origin sternohyoid; origin sternothyroid (above three structures being at some distance); remains of thymus; fatty areolar tissue of superior mediastinum; left innominate vein. **Posteriorly** (from below upward)—trachea; esophagus; thoracic duct; recurrent laryngeal nerve. **External (to left)**—left pleura and lung (slightly overlapping); left pneumogastric; left subclavian (both of latter being somewhat posterior). **Internally (to right)**—innominate artery; trachea; remains of thymus gland; left inferior thyroid vein. **(b) Both Common Carotids in Neck: Anteriorly**—skin; superficial fascia; platysma; deep fascia; sternomastoid; sternohyoid; sternothyroid; omohyoid; anterior jugular vein; thyroid body (often overlaps); middle thyroid vein; superior thyroid vein; lingual vein; facial vein; middle sternomastoid artery; descendens hypoglossi nerve (generally upon, sometimes within, sheath); communicantes hypoglossi; lymphatic glands. **Posteriorly**—pneumogastric nerve; sympathetic nerve; cervical cardiac branches of sympathetic and pneumogastric nerves; recurrent laryngeal nerve; inferior thyroid artery; longus colli; rectus capitis anticus major. **Externally**—internal jugular vein; pneumogastric nerve. (On right side a space is left at root of neck by divergence of vein, in which pneumogastric nerve and vertebral artery are found; on left side the internal jugular vein overlaps this space). **Internally** (from below upward)—trachea; esophagus; recurrent laryngeal nerve; branches of inferior thyroid artery; lateral lobe of thyroid body; cricoid cartilage; thyroid cartilage; lower part of pharynx; carotid glands.

Branches.—None, ordinarily.

Line.—(With head turned moderately to opposite side and upward)—from sternoclavicular articulation to a point midway between angle of jaw and tip of mastoid process—that portion of this line between the sternoclavicular articulation and the level of the upper border of the thyroid cartilage representing the common carotid. From the clavicle a little external to the sternoclavicular articulation would more accurately represent the line. The anterior margin of the sternomastoid muscle overlaps the carotid throughout. The omohyoid muscle crosses the carotid opposite and directly over Chassaignac's "carotid tubercle" (costal process of sixth cervical vertebra)—which is about 6.3 cm. (2½ inches) above the clavicle.

Indications for Ligation.—Wounds of itself and branches of external and internal carotid; distal and proximal aneurism; distal angiomata; as a temporary ligature; to limit growth of inoperable tumors; hemorrhage from areas supplied by distal branches.

Sites of Ligation.—Above the omohyoid muscle—place of election. Below the omohyoid—depth of artery and nature of relations make the operation more difficult and more fatal (Fig. 7, F and G).

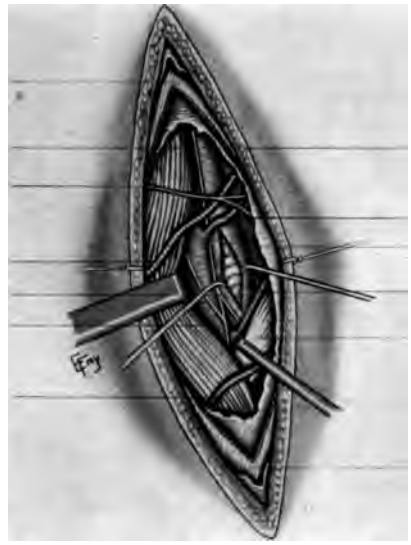

Fig. 9.—LIGATION OF RIGHT COMMON CAROTID ABOVE OMOHYOID:—A, A Platysma; B, Sternomastoid (retracted outward); C, Omohyoid (retracted downward); D, Sternothyroid; E, Common carotid (its sheath incised above omohyoid); F, Sternomastoid artery; G, Internal jugular vein; H, Superior thyroid vein; I, Inferior thyroid vein; J, Communicating vein between anterior and external jugular; K, One of transversalis colli nerves; L, Nerves from loop between descendens and communicans hypoglossi.

LIGATION OF COMMON CAROTID ARTERY

ABOVE THE OMOHYOID MUSCLE.

Position.—Patient supine; shoulders elevated; neck prominent; chin upward and to opposite side. Surgeon on side of operation, or on the right for both sides.

Landmarks.—Line of artery; anterior border of sternomastoid; cricoid cartilage.

Incision.—About 7.5 cm. (3 inches) in length, with center at level of cricoid cartilage—the incision lying in the line of the artery (Fig. 7, F).

Operation.—Incise skin, superficial fascia, and platysma. Superficial veins connecting anterior and external jugulars, and sometimes intercommunicating veins between facial and anterior jugular, as well as cutaneous nerves, are encountered (Fig. 9). Divide the deep fascia along the anterior border of the sternomastoid and open up the cellular tissue. The upper border of the omohyoid is here exposed, either by direct incision or by following up the anterior border of the sternomastoid. Having identified the intersection of sternomastoid and omohyoid, the omohyoid is retracted downward (or may be divided if in the way)—and the sternomastoid outward. Flexing the chin aids during these manipulations, by relaxing the parts. The common carotid is now located as it crosses the "carotid tubercle" (see Anatomy, "Line," page 32). Clear its sheath, avoiding or tying the sternomastoid artery and the superior and middle thyroid veins. Carefully incise the sheath, approaching from the inner side, to avoid the descendens

hypoglossi nerve (generally on the antero-external side of the sheath) and the internal jugular vein, and see that artery is freed from its sheath in its entire circumference. Pass the needle from the internal jugular and pneumogastric nerve.

Collateral Circulation.—Inferior thyroid, with superior thyroid. Deep cervical, with occipital. Transversalis colli, with occipital. Branches of two vertebrals, with branches of two external carotids. Circle of Willis.

LIGATION OF COMMON CAROTID ARTERY

BELOW THE OMOHYOID MUSCLE.

Position—Landmarks.—As in the ligation above the omohyoid.

Incision.—About 7.5 cm. (3 inches) in length, in line of artery—from just below cricoid cartilage to just above sternoclavicular articulation (Fig. 7, G).

Operation.—Incise skin, superficial fascia, and platysma. Here are encountered the superficial veins between the facial, anterior and external jugular veins, and the cutaneous cervical nerves. Divide the deep fascia along the anterior border of the sternomastoid. Expose the inner border of this muscle, flexing the head to relax the parts. The sternohyoid is then exposed, and sometimes the underlying sternothyroid. The omohyoid is, ordinarily, not brought into the field of operation. These muscles, if encountered, are retracted in their respective directions, or may be divided as far as necessary. Tie the inferior thyroid veins. The sheath is to be exposed as, and with the precautions, mentioned in the above operation. The recurrent laryngeal nerve and the inferior thyroid artery are to be especially guarded in operating at this site.

Comment.—The ligation of the common carotid is more difficult on the left side, owing to the nearness of the internal jugular vein (see Anatomy, "Relations," page 32), and the operation is less frequently done than on the right side.

SURGICAL ANATOMY OF EXTERNAL CAROTID ARTERY.

Description.—The smaller of the two divisions of the common carotid. About 6.3 cm. (2½ inches) in length. Begins opposite upper border of thyroid cartilage; passes upward, forward, and then backward, under the stylohyoid and posterior belly of the digastric, to the interval between neck of condyle of inferior maxilla and the external auditory meatus, where it divides, in the substance of the parotid gland, into the internal maxillary and temporal arteries.

Relations.—Anteriorly: skin; superficial fascia; platysma; deep fascia; anterior border of sternomastoid; hypoglossal nerve; lingual vein, facial vein; posterior belly of digastric; stylohyoid; temporomaxillary vein; superior cervical lymphatic glands; branches of facial nerve; parotid gland. **Posteriorly:** internal carotid artery; styloglossus; stylopharyngeus; glossopharyngeal nerve; pharyngeal branch of pneumogastric; stylohyoid ligament; parotid gland; superior laryngeal nerve. **Externally:** internal carotid artery. **Internally:** hyoid bone; pharynx; ramus of inferior maxilla; stylomaxillary ligament; submaxillary gland; parotid gland.

Branches (from below).—Ascending pharyngeal; superior thyroid; lingual; facial; occipital; posterior auricular; temporal; internal maxillary.

Line.—Upper part of line of common carotid artery (page 32).

Indications for Ligation.—Wounds and aneurism of trunk and branches; hemorrhage from areas of branches; palliative in malignant growths; preliminary to operations; aneurism by anastomosis in the regions of the trunks.

Sites of Ligation.—Below the digastric (between the superior thyroid and lingual branches)—place of election—the operation is easier and more branches are thus controlled. Above the digastric—the operation is more difficult and more apt to involve branches of the facial nerve. Note:—The digastric muscle crosses the artery about 3.2 cm. (1¼ inches) above its origin, opposite the upper border of the thyroid cartilage. The lingual arises opposite the great cornu of the hyoid bone (Fig. 7, H and I).

Comment.—(1) The external carotid may be distinguished from the internal carotid by the presence of its branches and by being to the inner side of the external carotid. (2) The ligation of the external carotid is now generally done where formerly the common carotid was ligated for conditions of the former vessel and its branches—the practicability and desirability of the operation having been demonstrated by the work of Wyeth.

LIGATION OF EXTERNAL CAROTID ARTERY

BELOW THE DIGASTRIC MUSCLE.

Position.—As for the common carotid (page 33).

Landmarks.—Sternomastoid; thyroid cartilage; angle of jaw.

Incision.—About 7.5 cm. (3 inches)—along the anterior border of the sternomastoid, or slightly in front of border—from level of middle of thyroid cartilage, to near angle of jaw (Fig. 7, H).

Operation.—Incise skin, superficial fascia, and platysma (Fig. 10). Tie any veins which may lie in the line of incision. Divide the deep fascia and expose the anterior border of the sternomastoid and draw it outward. Find the posterior belly of the digastric at the upper angle of the wound. Next, locate the hypoglossal nerve crossing the external carotid below the origin of the occipital artery. Locate the tip of the great cornu of the hyoid bone, opposite which the lingual artery arises. Having fixed the location of these three structures, and avoiding the superior thyroid, facial, and lingual veins; expose the artery opposite the tip of the great cornu of the hyoid. Clear the sheath and pass the ligature between the superior thyroid and lingual branches—guarding the descendens hypoglossi nerve in front, and the superior laryngeal nerve passing behind the artery—directing the needle from the internal carotid.

Comment.—(1) The operation is not an easy one, and it is often difficult to recognize the branches. (2) Jacobson advises simultaneous ligation of the superior thyroid, the lingual, and, if possible, the ascending pharyngeal branches—on account of secondary hemorrhage. (3) Through this same incision the superior thyroid, lingual, facial, occipital, and ascending pharyngeal may be ligated.

Collateral Circulation.—Same as for the ligation of the common carotid above the omohyoid (page 34).

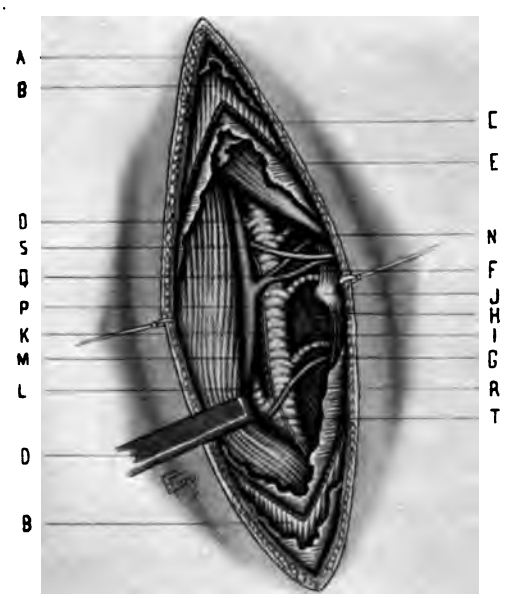

Fig. 10.—Ligation of Right External Carotid below Digastric; and also of Internal Carotid, Superior Thyroid, Lingual, Facial and Occipital, near Origin:—A, Superficial fascia; B, B, Platysma; C, Cervical fascia; D, Sternomastoid (retracted outward); E, Posterior belly of digastric; F, Hyoglossus, with lingual artery disappearing beneath it; G, Thyrohyoid M.; H, Middle constrictor M.; I, Inferior constrictor M.; J, Tip of great cornu of hyoid bone; K, External carotid A.; L, Internal carotid; M, Superior thyroid; N, Facial; O, Occipital; P, Internal jugular V.; Q, Lingual and facial veins emptying into internal jugular; R, Superior thyroid V.; S, Hypoglossal N.; T, Descendens noni N.

LIGATION OF EXTERNAL CAROTID ARTERY

ABOVE DIGASTRIC MUSCLE AND BEHIND RAMUS OF JAW.

Position.—As for the common carotid.

Landmarks.—Line of artery; ramus of inferior maxilla.

Incision.—From tragus of ear, to below angle of inferior maxilla, and placed just behind the ramus of the jaw, in the line of the artery (Fig. 7, I).

Operation.—Incise skin and superficial fascia. Avoid, or doubly ligate and incise, the tributaries of the external jugular and facial veins. Divide the deep fascia. Expose the anterior border of the sternomastoid and retract outward. Expose the posterior belly of the digastric and stylohyoid and draw downward—partially or entirely dividing them if necessary. Avoid the branches of the facial nerve. Expose the parotid gland and draw upward and forward—thus exposing the vessel. Clear the artery and open its sheath —and pass the ligature around the artery prior to its entrance into the substance of the parotid gland. Repair, by suturing, whatever muscles may have been incised.

SURGICAL ANATOMY OF SUPERIOR THYROID BRANCH OF EXTERNAL CAROTID.

Description.—The second in order and an anterior branch of the external carotid. Runs forward and a little upward beneath the great cornu of the hyoid bone, lying in the superior carotid triangle and covered by the skin, fascia, and platysma—then runs inward and downward, passing under the omohyoid, sternohyoid, and sternothyroid to the upper part of the thyroid gland. The superior thyroid vein runs beneath the artery on its way to the internal jugular vein. The superior laryngeal nerve is in close relation posteriorly.

LIGATION OF SUPERIOR THYROID BRANCH OF EXTERNAL CAROTID.

Position—Landmarks.—As for ligation of external carotid below the digastric (page 35).

Incision.—About 5 cm. (2 inches) in length—along the line of the external carotid artery, with its center on a level with the upper border of the thyroid cartilage (Fig. 7, J).

Operation.—Practically the same as for the ligation of the external carotid below the digastric, the main trunk being first exposed, and the superior thyroid branch being then located. Guard the superior laryngeal nerve. Place the ligature between the external carotid and the hyoid branch, or beyond the sternomastoid branch.

SURGICAL ANATOMY OF LINGUAL BRANCH OF EXTERNAL CAROTID.

Description.—The third in order, and an anterior branch of the external carotid. Arises opposite, or a little below, the great cornu of the hyoid bone, about 2 cm. (¾ inch) above the bifurcation of the common carotid. (**a**) First or Oblique Portion:—lies in superior carotid triangle, extending obliquely upward to the external border of the hyoglossus,—being covered by skin, superficial fascia, platysma, deep fascia, and hypoglossal nerve,—and resting on the middle constrictor and laryngeal nerve. (**b**) Second or Horizontal Portion:—lies in the digastric triangle, running horizontally beneath the hyoglossus muscle, along the superior border of the hyoid bone,—being covered by the hyoglossus muscle (which separates the artery from the hypoglossal nerve, posterior belly of the digastric, stylohyoid muscle, and lingual vein), —and resting upon the middle constrictor of the pharynx and geniohyoglossus. (**c**) Third or Ascending Portion:—ascends between the hyoglossus and geniohyoglossus to the inferior surface of the tongue. (**d**) Fourth or Terminal Portion:—runs forward to tip of tongue, lying between the lingualis and geniohyoglossus, and covered only by mucous membrane. Two venæ comites accompany the lingual artery beneath the hyoglossus. The ranine vein runs on the superficial surface of the hyoglossus, below the hypoglossal nerve. Several veins follow the dorsalis linguæ artery.

Sites of Ligature.—Its first or second portions are the parts usually tied—and of these, the second is preferable (Fig. 7, K and L).

LIGATION OF LINGUAL BRANCH OF EXTERNAL CAROTID

NEAR ITS ORIGIN.

Position—Landmarks.—As for ligation of external carotid below the digastric (page 35).

Incision.—In line of external carotid, with its center opposite the body of the hyoid bone (Fig. 7, K)

Operation.—Same, practically, as for ligation of external carotid below the digastric, the main vessel being first exposed and the origin of the lingual then located.

Comment.—The first part of the lingual may also be tied, though less readily, by a transverse incision extending from the level of the body of the hyoid bone to the anterior border of the sternomastoid, the artery being exposed and tied just before passing under the hyoglossus muscle.

LIGATION OF LINGUAL BRANCH OF EXTERNAL CAROTID

BENEATH THE HYOGLOSSUS.

Position.—Patient supine; shoulders raised; neck prominent; head to opposite side and chin upward. Surgeon on side of operation, cutting from before backward on the right, and vice versa.

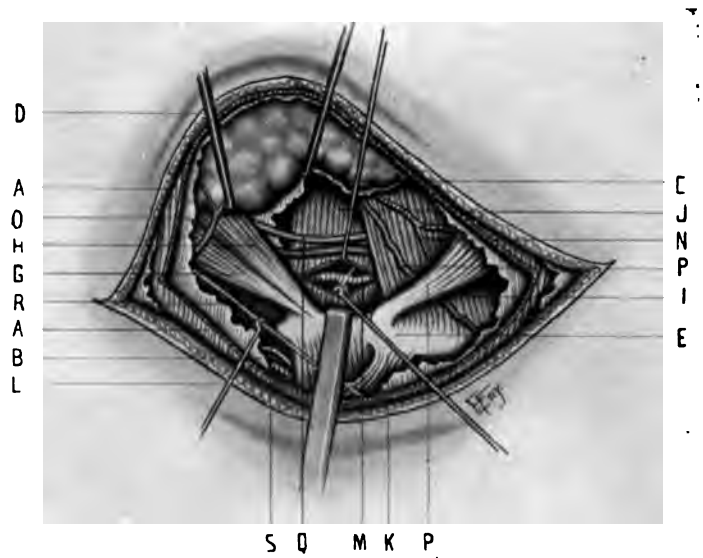

Fig. 11.—Ligation of Right Lingual Artery beneath Hyoglossus:—A, A, Platysma; B, Transverse cervical fascia over submaxillary gland; C, Deep transverse cervical fascia under submaxillary gland; D, Submaxillary gland; E, Hyoid bone; P (at bottom of illustration), Anterior belly of digastric; G, Posterior belly of digastric; H, Stylohyoid; I, Mylohyoid; J, Hyoglossus; K, Omohyoid; L, Thyrohyoid; M, Lingual artery seen through incision in hyoglossus; N, Submental A.; O, Tributary of temporomaxillary V.; P (at right margin of illustration), Tributary of anterior jugular V.; Q, Hypoglossal N. (above) and ranine V. (below); R, Transverse cervical nerve; S, Superior laryngeal nerve and vessels.

Landmarks.—Lower border of inferior maxilla; facial artery crossing inferior maxilla; hyoid bone.

Incision.—Curved incision—beginning just below and external to symphysis menti—and ending just below and internal to crossing of facial artery over inferior maxilla—its center being just above the greater cornu of the hyoid bone (Fig. 7, L).

Operation.—Incise skin, superficial fascia, platysma, and deep fascia. Avoid or ligate tributaries of facial, anterior jugular, or temporomaxillary veins. Incise the transverse cervical fascia over the submaxillary gland—exposing the gland and retracting it upward, out of its bed, over the margin of the lower jaw (Fig. 11). Incise transversely the deep cervical fascia exposed by lifting out the submaxillary gland—and identify the mylohyoid muscle in the anterior aspect of the wound. Expose the two bellies of the digastric and firmly retract them downward at their point of attachment to the hyoid bone—which steadies the parts and renders the hyoglossus more prominent. Clear the surface of the hyoglossus and identify the hypoglossal nerve crossing its anterior aspect. The ranine vein crosses the same surface just below and parallel with the nerve and at about the same level as the artery lies on the opposite side of the muscle. Retract both hypoglossal nerve and ranine vein upward. Divide the hyoglossus transversely for about 1.3 cm. (½ inch) just above and parallel with the hyoid bone. This incision falls just over the artery, which generally bulges into the opening as soon as it is made, or through which it is easily reached. Having isolated the artery, trace it backward until the dorsalis linguæ branch is reached, so that the ligature may be placed upon its proximal side. Having passed the ligature, replace the submaxillary gland and close the wound.

Comment.—The fascia of the submaxillary gland may be sutured over it, and the incision in the hyoglossus may be repaired by suturing, if either be considered indicated.

SURGICAL ANATOMY OF FACIAL BRANCH OF EXTERNAL CAROTID.

Description.—The fourth in order, and an anterior branch of the external carotid. The Cervical Portion passes upward and forward in the posterior part of submaxillary triangle, under the digastric, stylohyoid, submaxillary gland, and horizontal ramus of inferior maxilla. The Facial Portion curves over lower border of inferior maxilla at the anterior border of masseter muscle—and, running forward and upward, crosses the cheek to the angle of mouth—thence upward along side of nose to end at internal canthus of eye.

Relations.—**Cervical portion** rests on (from below upward) styloglossus; mylohyoid; submaxillary gland (in or under it);—and is covered by (from below upward) posterior belly of digastric; stylohyoid; hypoglossal nerve (generally); submaxillary gland (beneath or in its substance); inferior maxilla; lymphatic glands; fascia; platysma; skin. **Facial portion** rests on (from below upward) inferior maxilla; buccinator; levator anguli oris; levator labii superioris (sometimes); infraorbital branches of fifth nerve;—and is covered by (from below upward) risorius; zygomatici major and minor; supramaxillary and buccal branches of facial nerve; levator labii superioris; levator labii superioris alæque nasi; infraorbital branches of facial. The cervical portion of the facial vein is more direct than the artery, and separated from it by submaxillary gland, posterior belly of digastric, stylohyoid muscle, and hypoglossal nerve. The facial portion of the facial vein is also more

direct than the facial portion of the facial artery, and is separated from its artery by the zygomatici major and minor.

Sites of Ligation.—Near origin (less frequently),—over lower jaw (the usual selection) (Fig. 7, M).

LIGATION OF FACIAL BRANCH OF EXTERNAL CAROTID

NEAR ORIGIN.

Position—Landmarks—Incision—Operation.—Practically the same as for ligation of the external carotid below the digastric.

LIGATION OF FACIAL BRANCH OF EXTERNAL CAROTID

OVER INFERIOR MAXILLA.

Position.—Patient supine; shoulders raised; head thrown back and to opposite side. Surgeon on side of operation, or on right for both sides.

Landmarks.—Anterior margin of masseter muscle; horizontal portion of inferior maxilla.

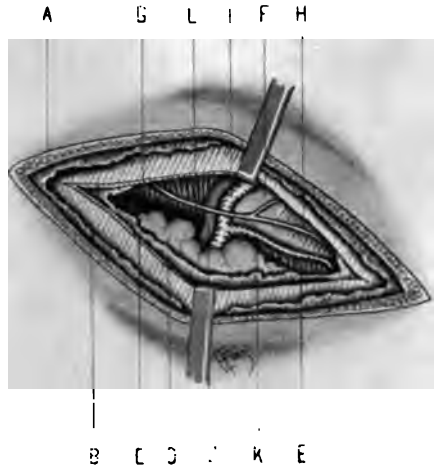

Fig. 12.—Ligation of Right Facial over Border of Inferior Maxilla:—A, Cervical fascia; B, Platysma; C, Deep cervical fascia; D, Submaxillary gland; E, Mylohyoid muscle; F, Inferior maxilla; G, Masseter M.; H, Depressor anguli oris; I, Facial A.; J, Facial V.; K, Submental A.; Supramaxillary N.

Incision.—About 2.5 cm. (1 inch) in length—placed along and under cover of lower border of lower jaw, with its center over the course of the artery (at the anterior margin of the masseter muscle) (Fig. 7, M).

Operation.—Incise skin, superficial fascia, platysma, and deep fascia, when the artery should come into view—with the facial vein just posterior to it. Avoid branches of the facial nerve (Fig. 12).

SURGICAL ANATOMY OF OCCIPITAL BRANCH OF EXTERNAL CAROTID.

Description.—The fifth in order, and a posterior branch of the external carotid—passing upward and backward to the interval between mastoid process of temporal and transverse process of atlas—thence horizontally backward in the occipital groove—thence upward onto the scalp.

Relations.—First Part (internal to sternomastoid)—covered by skin, fascia, posterior belly of digastric; parotid gland; temporomaxillary vein; hypoglossal nerve;—and rests on internal carotid artery; hypoglossal nerve; pneumogastric nerve; internal jugular vein, and spinal accessory nerve. Second Part (beneath sternomastoid)—covered by sternomastoid; splenius capitis; trachelomastoid; origin of digastric;—and rests on capitis lateralis, in occipital groove of mastoid process of temporal, and on the insertion of superior oblique muscle. Third Part (external to sternomastoid)—covered by skin, aponeurosis uniting occipital attachments of sternomastoid and trapezius—and resting upon the complexus. It perforates this aponeurosis just mentioned, or the posterior belly itself of the occipitofrontalis, together with the great occipital nerve—and follows, roughly, the line of the lambdoid suture, between the integument and the cranial aponeurosis. Two venæ comites accompany the occipital artery.

Sites of Ligation.—Near its origin—and behind the mastoid process of the temporal—according to site of lesion requiring ligature (Fig. 7, N).

LIGATION OF OCCIPITAL BRANCH OF EXTERNAL CAROTID

NEAR ORIGIN.

Position—Landmarks—Incision—Operation.—As for ligation of the external carotid below the digastric (page 35).

LIGATION OF OCCIPITAL BRANCH OF EXTERNAL CAROTID

BEHIND MASTOID PROCESS.

Position.—Patient supine; shoulders and head elevated; head turned well to opposite side (or patient resting slightly to one side). Surgeon stands behind, on side of operation.

Landmarks.—Mastoid process; external occipital protuberance.

Incision.—About 5 cm. (2 inches) in length—beginning from tip of mastoid process and extending toward the external occipital protuberance (Fig. 7, N).

Operation.—Having incised skin and fascia, divide the posterior half of the sternomastoid and its strong aponeurosis—then the splenius capitis—then as many fibers of the trachelomastoid as are in the way (Fig. 13). Relax and retract the muscles by turning the head to the side of the operation. Expose the artery deep down between the mastoid process of the temporal and the transverse process of the atlas, resting upon the superior oblique and complexus muscles. Having separated from it the accompanying veins, and having guarded the veins from the mastoid foramen, the ligature is passed. The lesser occipital nerve runs on the posterior surface of the sterno-

Fig. 13.—Ligation of Right Occipital Artery behind Mastoid Process:—A, Posterior cervical fascia; B, Trapezius muscle; C, Sternomastoid; D, Splenius capitis; E, Trachelomastoid; F, Occipital artery and venæ comites, lying upon complexus muscle; G, Great occipital nerve; H, Lesser occipital nerve; I, Posterior external jugular vein.

mastoid, near its posterior border, and the great occipital nerve pierces the trapezius muscle near its outer border.

SURGICAL ANATOMY OF POSTERIOR AURICULAR BRANCH OF EXTERNAL CAROTID.

Description.—The sixth in order, and a posterior branch of the external carotid—arising generally just above posterior belly of digastric (sometimes under digastric), about on a level with tip of styloid process. Runs upward and backward in parotid gland to notch between cartilage of ear and mastoid process, and there divides into branches—crossing, in its course, the spinal accessory nerve—and being crossed by the facial nerve.

LIGATION OF POSTERIOR AURICULAR BRANCH OF EXTERNAL CAROTID

NEAR ORIGIN.

Position—Landmarks—Incision—Operation.—As for ligation of external carotid above the digastric (page 36).

LIGATION OF POSTERIOR AURICULAR BRANCH OF EXTERNAL CAROTID

BEHIND EAR.

Position.—Patient supine; shoulders elevated; head turned to opposite side. Surgeon behind, on side of operation.

Landmarks.—Pinna of ear; mastoid process.

Incision.—About 3.8 cm. (1½ inches) in length, between posterior aspect of pinna of ear and anterior border of base of mastoid process.

Operation.—Having incised skin and fascia and avoided facial and posterior auricular nerves, the artery is found, with accompanying vein, in the groove between the cartilage of the ear and the base of the mastoid process (Fig. 14).

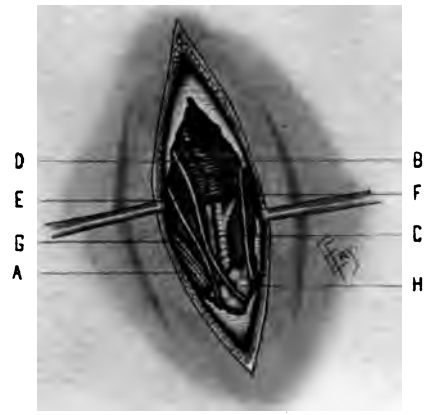

Fig. 14.—Ligation of Right Posterior Auricular behind Ear:—A, Sternomastoid; B, Retrahens aurem; C, Posterior auricular artery and vein; D, Same, beneath retrahens aurem; E, Branch of occipitalis minor nerve; F, Auricularis magnus nerve; G, Posterior auricular branch of facial; H, Parotid gland.

SURGICAL ANATOMY OF TEMPORAL BRANCH OF EXTERNAL CAROTID.

Description.—The seventh in order and the smaller but more direct of the two terminal branches of the external carotid. Arises in substance of parotid gland, opposite neck of inferior maxilla—and runs upward, beneath parotid gland, between condyle and external auditory meatus—thence upward, crossing the posterior root of the zygoma—and continuing upward under the attrahens aurem muscle and temporal aponeurosis for 3.8 cm. to 5 cm. (1½ to 2 inches), where it divides into anterior and posterior branches. A plexus of sympathetic nerves surrounds the vessel—it is crossed by the temporofacial division of the facial nerve—and is accompanied by the auriculotemporal nerve.

Sites of Ligation.—Just above root of zygoma. The anterior and posterior branches may be ligated at their bifurcation, about 3.8 to 5 cm. (1½ to 2 inches) above the zygoma.

LIGATION OF TEMPORAL BRANCH OF EXTERNAL CAROTID

JUST ABOVE ZYGOMA.

Position.—Patient supine; shoulders raised; head to opposite side. Surgeon on side of operation, cutting from above downward on right, and vice versa (or on right for both operations, cutting from above downward).

Landmarks.—Tragus of ear; condyle of jaw; zygoma.

Incision.—Vertical, about 2.5 to 3.8 cm. (1 to 1½ inches) in length, over line of artery, with center over zygoma, and extending downward in the interval between the tragus of the ear and the condyle of the lower jaw (Fig. 7, O).

Operation.—Incise skin and dense subcutaneous tissue and parotid fascia—when the artery will be exposed lying quite superficial as it crosses the zygoma. Avoid the accompanying vein posteriorly—also avoid the branches of the temporofacial division of the facial nerve and the auriculotemporal nerve (Fig. 15).

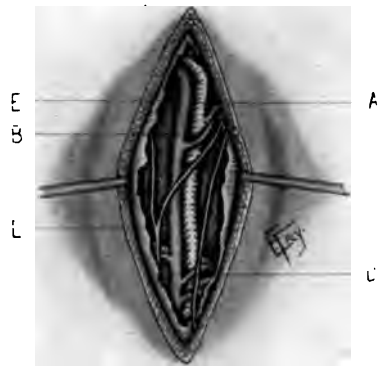

Fig. 15.—Ligation of Right Temporal Just above Zygoma:—A, Temporal artery, with its anterior and posterior bifurcations, and its transverse facial, middle temporal, and anterior auricular branches; B, Temporal vein, with branches corresponding to those of artery; C, Temporal branches of auriculotemporal nerve; D, Branch of temporofacial division of facial nerve; E, Temporal fascia.

SURGICAL ANATOMY OF INTERNAL MAXILLARY BRANCH OF EXTERNAL CAROTID.

Description.—The eighth in order and the larger of the two terminal branches of the external carotid, arising opposite neck of jaw, in substance of parotid gland.

Course and Relations.—First or **maxillary portion:**—passes inward and forward between neck of inferior maxilla and internal lateral ligament, surrounded by deep part of parotid gland. Runs parallel with and just below auriculotemporal nerve and external pterygoid muscle, crossing the inferior dental nerve. Second or **pterygoid portion:**—takes one of two courses: (**a**) "Either runs between the two pterygoid muscles and ramus of jaw, and then turns up over outer surface of external pterygoid beneath the temporal muscle to gain the two heads of the external pterygoid, between which it sinks into the sphenomaxillary fossa—or (**b**) it passes behind and internal to the external pterygoid, and is covered by that muscle till it reaches the interval between its two heads, where it then often forms a projecting loop as it turns into the sphenomaxillary fossa" (Morris). Third or **sphenomaxillary portion:**—enters sphenomaxillary fossa, between two heads of external pterygoid, and is placed beneath the superior maxillary division of the fifth nerve and in relationship with Meckel's ganglion—and here it divides into its terminal branches.

Sites of Ligation.—When the ligation of the internal maxillary is indicated, the external carotid is tied, as being more easily and safely reached.

The middle meningeal branch is tied within the cranium for intracranial hemorrhage.

SURGICAL ANATOMY OF MIDDLE MENINGEAL BRANCH OF INTERNAL MAXILLARY BRANCH OF EXTERNAL CAROTID.

Description.—The largest branch of the first or Maxillary Portion of the internal maxillary. Arises between internal lateral ligament and neck of inferior maxilla—and, under cover of external pterygoid, passes upward between the two roots of the auriculotemporal nerve to the foramen spinosum, being crossed by the chorda tympani nerve. It enters the skull through this foramen and ascends in the groove on the great wing of the sphenoid, where it divides into anterior and posterior branches which ramify between the bone and the dura. The point of bifurcation is generally given by anatomists as corresponding, on the exterior of the skull, with a point 3.8 cm. ($1\frac{1}{2}$ inches) behind the external angular process of the frontal bone, and 3.8 to 4.5 cm. ($1\frac{1}{2}$ to $1\frac{3}{4}$ inches) above the zygoma. The Anterior Branch runs in a groove on the great ala of the sphenoid and the anterior inferior angle of the parietal. The Posterior Branch crosses the squamous portion of the temporal and then enters the groove on the posterior inferior angle of the parietal bone. In the young these measurements are less.

Indications for Ligation.—Intracranial hemorrhage.

Sites of Ligation.—The common trunk, or the anterior or posterior branch, as indicated (Fig. 7, P, Q, R).

Note.—Because of the practical surgical bearing of the middle meningeal artery and its branches, and because of the wide variations from each other in the descriptions of the intracranial portion of the middle meningeal artery and its branches in various anatomies, and because of the equally wide variations of the artery and its branches, as actually found in the skull, from the text-book descriptions,—the following summary is given of the outcome of special research upon the subject made upon fifty dried skulls and thirty cadavera (representing 160, upon the two sides) by S. C. Plummer. In the following data it is to be remembered that, owing to beveling, the lower part of the coronal suture is 5 mm. to 1 cm. ($\frac{3}{16}$ to $\frac{3}{8}$ inch) more posterior on the inner than outer side of skull, and that the squamoparietal suture is from 1 to 1.5 cm. ($\frac{3}{8}$ to $\frac{5}{8}$ inch) lower on the inner than the outer side.

Covering of Artery.—Instead of lying between dura and bone (as generally understood) the artery is really covered by a thin process of dura on its outer surface; hence its adherence to the dura in separation of the latter from the bone.

Trunk of Middle Meningeal Artery.—(**1**) Present in 95 per cent. In 50 per cent., anterior and posterior branches entered separately, or the trunk divided at the foramen spinosum. (**2**) Point of Division into Anterior and Posterior Branches:—2 mm. to 5.5 cm. (little more than $\frac{1}{16}$ to $2\frac{1}{8}$ inches) from foramen spinosum in a direct line—(less than 1 cm. or $\frac{7}{16}$ inch) in 16 cases—between 1 and 3 cm. ($\frac{7}{16}$ and $1\frac{3}{16}$ inches) in 60 cases—over 3 cm. ($1\frac{3}{16}$ inches) in 19 cases. Bifurcation was 58 times upon squamous part of temporal—21 upon sphenoid—15 upon squamosphenoidal suture—once on sphenoparietal suture. (Steiner, another investigator, found a common trunk present in only 43 per cent.—and found that bifurcation occurred in 57 per cent. at the foramen spinosum.) (**3**) Length:—corresponds with point of bifurcation,

when point of bifurcation is not more than 2 cm. ($\frac{3}{4}$ inch) above the foramen spinosum,—and from 1 mm. to 1.2 cm. ($\frac{1}{25}$ to $\frac{1}{2}$ inch) greater when the point of bifurcation is more than 2 cm. ($\frac{3}{4}$ inch) above the foramen spinosum (due to curve in artery). (In Steiner's cases the length was from 1 to 3.5 cm., or $\frac{3}{8}$ to $1\frac{3}{8}$ inches, in 43 cases—and from 3.5 to 5 cm., or $1\frac{3}{8}$ to 2 inches, in 8 cases.) (4) Direction:—almost invariably outward—and more frequently outward and forward than outward and backward. Generally runs outward for 2 mm. to 1.7 cm. (little more than $\frac{1}{16}$ to $\frac{1}{2}$ inch) and thence outward and forward—running in a gentle curve. (5) Location:—almost always runs from foramen spinosum onto the temporal (sometimes first runs onto the sphenoid, or squamosphenoidal suture)—generally running from 5 mm. to 1 cm. ($\frac{3}{16}$ to $\frac{3}{8}$ inch) posterior to the squamosphenoidal suture; thence a long trunk generally runs onto the squamosphenoidal suture—and then onto the great wing of the sphenoid.

Anterior Branch of Middle Meningeal Artery.—(1) Relative Size:—Generally the main branch and larger than the posterior. (2) Direction and Location:—Beginning at point at which lowest bifurcation occurs (v. s.), the anterior branch, after bifurcating on the squamous, squamosphenoidal suture, sphenoid, or on the sphenoparietal suture, as the case may be, passes forward and upward across the anterior and lower part of the squamous;—thence almost invariably crosses the upper part of the great wing of the sphenoid;—thence passes backward across the sphenoparietal suture onto the parietal—and runs thence generally upward and backward about parallel with the coronal suture, and generally within 2 mm. to 3 cm. (little more than $\frac{1}{16}$ to $1\frac{8}{16}$ inches) of it. Practically, the most constant position of the anterior branch is where it crosses the sphenoparietal suture—the crossing may be at any part of its 1.5 cm. (nearly $\frac{5}{8}$ inch) length, but is usually on its anterior half. (3) As to Branches of Anterior Branch:—The anterior branch did not divide in 44 per cent. In the 56 per cent. in which it did divide, it divided 25 times on the right and 31 on the left. There were 2 branches in 49 cases—3 branches in 5 cases—4 branches in 2 cases;—and these divisions occurred 51 times on the parietal, 3 times on the sphenoparietal suture, and 2 times on the sphenoid. Kroenlein considers that the anterior branch, in the average case, divides into two branches, one of which runs up in front and one behind the rolandic fissure. Where the anterior branch divides into branches, one branch generally runs parallel with and within 2 cm. ($\frac{3}{4}$ inch) of the coronal suture. (4) Bony Canal:—In from 38 per cent. (Steiner) to 60 per cent. (Plummer), the anterior branch was found to run through a bony canal upon the anterior inferior angle of the parietal bone—the canal sometimes beginning upon the sphenoid—being from 3 mm. to 2.8 cm. ($\frac{1}{8}$ to $1\frac{7}{8}$ inches) long.

Posterior Branch of Middle Meningeal Artery.—(1) Much less constant in size and position than anterior branch. Generally smaller—often appearing as, and mistaken for, a branch of the anterior branch. Sometimes appears to be a continuation of the trunk and larger than the anterior—and sometimes is larger without appearing to be main trunk. (2) Direction:—At first outward and backward, or upward and backward—rarely directly backward. Subsequently, in majority of cases, it passes horizontally backward—exceptionally, downward and backward. (3) Location:—(a) In Majority of Cases:—it runs approximately parallel with squamoparietal suture, generally within 1 cm. ($\frac{3}{8}$ inch), never more than 2 cm. ($\frac{3}{4}$ inch) from it—gradually approaching it—crossing it (unless its terminal branches are given off on the temporal bone) generally within 2 cm. ($\frac{3}{4}$ inch) of its posterior end, passing

thence onto the parietal bone—its small branches running onto the occipital. (It may at first run parallel with the squamosphenoidal suture. It may cross the squamoparietal suture onto the parietal bone at any point.) (b) In Other Cases:—sometimes it runs outward and backward over the squamopetrosal suture, or upon the squamous parallel with and generally within 1 cm. of the squamopetrosal suture—passing back over the base of the petrous bone, crossing the squamoparietal suture near its posterior end—thence back onto the parietal bone, superiorly to and parallel with the mastoparietal suture. (4) Branches of Posterior Branch:—In majority of cases the posterior branch divides into two branches—on the temporal bone, most frequently —on the parietal bone, next most frequently—and on the squamoparietal suture, least frequently.

Summary.—(1) That no parts of the middle meningeal artery or its anterior or posterior branches have fixed relations, except the main trunk at its exit from the foramen spinosum, and the anterior branch where it crosses the sphenoparietal suture to reach anterior inferior angle of parietal. (2) That the common trunk is generally present. (3) That the anterior branch may be given off from the orbital branch of the lachrymal branch of the ophthalmic. (4) That a tendency to symmetry exists upon the two sides of the skull, but is not constant. (5) That the anterior branch runs through a bony canal in the anterior inferior angle of the parietal bone in the majority of cases.

LIGATION OF TRUNK OF MIDDLE MENINGEAL ARTERY IN THE CRANIUM

THROUGH TREPHINE-OPENING EXPOSED BY CURVED OBLIQUE INCISION.

Position.—Patient supine; head supported, shaved and turned to opposite side; surgeon on side of operation.

Landmarks.—A point is selected as the center of the trephine-opening which will fall over the trunk of the artery proximal to its bifurcation,—and which is taken to be about 3.8 cm. (1½ inches) behind the external angular process of the frontal bone and 2.5 cm. (1 inch) above the zygoma.

Incision.—Begins at external angular process of frontal bone—passes obliquely downward and backward to the posterior end of the zygoma—and from this point upward and backward above the auricle (Fig. 7, P).

Operation.—(1) Having incised skin and temporal fascia, ligate the superficial temporal artery and vein, guarding the auriculotemporal nerve and branches of the facial (Fig. 16). Then carry the incision along the posterior border of the temporal muscle through the periosteum to the bone. Detach the temporal muscle forward subperiosteally, baring parts of the squamous, parietal, and sphenoid bones—guarding the deep temporal arteries. Firmly retract the soft parts thus freed upward and forward. (2) Using a trephine about 3.8 cm. (1½ inches) in diameter, place its center over a point about 3.8 cm. (1½ inches) behind the external angular process and 2.5 cm. (1 inch) above the zygoma. Having removed the disc of bone (which is here thin), expose the artery—and pass the needle carefully, to avoid wounding the brain. (3) In completing the operation, the disc of bone may be replaced, or not, according to the individual ideas of the surgeon. Allow the periosteum and soft parts to re-occupy their normal positions. Suture the margins of severed periosteum with buried catgut. Repair by gut-suturing any muscle tissue which may have been cut and close the skin incision.

Comment.—(1) This incision of Kocher, together with the subsequent

retraction of the soft parts, involves less injury to the parts than the turning downward or upward of a semilunar or horseshoe flap, which is the method of approach most frequently adopted. (2) According to the researches of Plummer (v. s.), the osteoplastic flap operation of Hartley-Krause furnishes

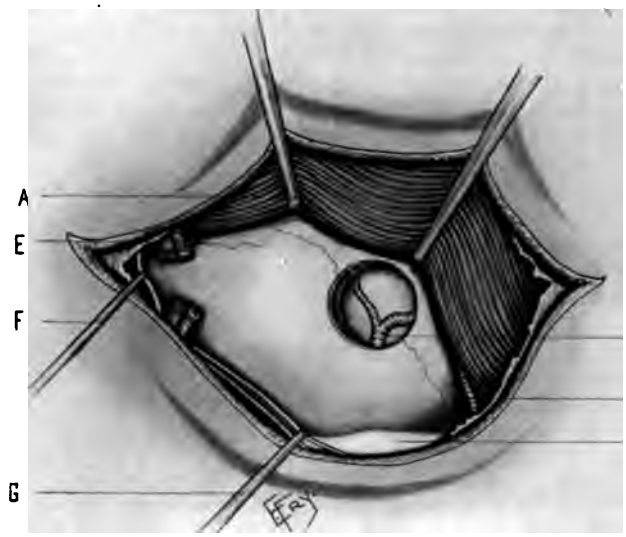

Fig. 16.—Ligation of Trunk of Right Meningeal through Trephine-opening in Temporal Fossa by Curved Oblique Incision:—A, Temporal muscle (its anterior border retracted upward and backward); B, Zygomatic arch, and temporal fossa just above; C, Main trunk and anterior and posterior branches of middle meningeal, exposed through trephine-opening (which is here shown somewhat too high); D, Deep temporal artery; E, Superficial temporal artery and vein; F, Auriculotemporal nerve (retracted backward); G, Branches of facial nerve (retracted downward and backward).

the best method of exposing the main trunk of the middle meningeal artery and its branches. (3) If the above trephine-opening expose the artery inconveniently near its circumference, the opening may be enlarged in the direction of the artery with rongeur forceps.

LIGATION OF ANTERIOR BRANCH OF MIDDLE MENINGEAL ARTERY IN THE CRANIUM

THROUGH TREPHINE-OPENING EXPOSED BY A HORSESHOE INCISION.

Position.—As for ligation of main trunk.

Landmarks.—A point is selected as the center of the trephine-opening which will fall over the anterior branch just beyond its bifurcation—and is taken to be about 3.8 cm. (1½ inches) behind the external angular process of the frontal bone, and from 3.8 to 4.5 cm. (1½ to 1¾ inches) above the zygoma.

Incision.—A horseshoe incision with its center over the above point and its convexity upward is outlined—its anterior limb being just behind the external angular process, and the posterior limb corresponding with a line extending vertically upward from the auditory meatus (Fig. 7, Q).

Operation.—The incision is carried, throughout, through skin, temporal fascia, temporal muscle, and periosteum to bone. These soft parts are

raised subperiosteally and turned downward. A trephine of about 3.8 cm. ($1\frac{1}{2}$ inches) diameter is applied with its center over the above point. The steps of the operation are, henceforth, the same, practically, as those for the main trunk (page 47).

Comment.—(1) See the surgical anatomy of the middle meningeal artery and its branches for variations in the course of the anterior branch. (2) According to Chipault's method of cranio-cerebral localization (page 472), the anterior branch of the middle meningeal crosses the second tenths of the three primary lines. In following which method, therefore, the trephine should have its center placed over a line which will cross these tenths at about their middle. (3) According to the researches of Plummer (page 45), who recommends Kroenlein's method of locating the anterior branch as the best of several, the following points are of practical value:—(A) That site should be chosen—(*a*) Which is high enough to avoid missing the anterior branch in case it originates from the orbital branch;—(*b*) which is high enough to be above the orbital branch when that branch is only a communicating branch;—(*c*) which is least apt to fall over the bony canal in the anterior inferior angle of the parietal, and over the bony ridge along the lower portion of the coronal suture:—(B) That a 2.5 cm. (1 inch) trephine-opening placed just behind any portion of the coronal suture will almost certainly strike the anterior branch, or a branch of the anterior branch. (4) According to Kroenlein's method, Reid's base line (page 476) is first drawn—then a higher line is drawn parallel with it and on a level with the supraorbital border. On the latter line a point is taken 3 or 4 cm. ($1\frac{3}{16}$ to $1\frac{9}{16}$ inches) behind the external angular process. The center of the trephine will rest on the sphenoid in the majority of cases. (This corresponds, practically, with the data often given, of fixing upon a point from 3.2 to 3.8 cm. ($1\frac{1}{4}$ to $1\frac{1}{2}$ inches), according to the size of the head, behind the external angular process—and from 3.8 to 4.5 cm. ($1\frac{1}{2}$ to $1\frac{3}{4}$ inches) above the zygoma.

LIGATION OF POSTERIOR BRANCH OF MIDDLE MENINGEAL ARTERY IN THE CRANIUM

THROUGH TREPHINE-OPENING EXPOSED BY A HORSESHOE INCISION.

Position.—As in ligating the main trunk.

Landmarks.—A point is selected as the center of the trephine-opening which will fall over the posterior branch in the groove of the parietal bone—and is taken to be at the intersection of a line drawn horizontally backward on a level with the roof of the orbit, and one drawn vertically upward from directly behind the mastoid process—which point of intersection lies just below the parietal eminence (Jacobson).

Incision.—A horseshoe incision with its center over the above point, its convexity upward, and its limbs being from 5 to 5.7 cm. (2 to $2\frac{1}{2}$ inches) apart (Fig. 7, R).

Operation.—Performed in the same general manner as for ligation of the anterior branch.

Comment.—(1) According to the researches of Plummer (page 45), who recommends Steiner's method as the best of several for locating the posterior branch, the following points are of practical value:—(A) The posterior branch is incapable of being located with as much certainty as the anterior branch:—(B) The lateral sinus is to be guarded in exposing the posterior branch. (2) According to Steiner's method, Reid's base-line is first drawn—

then a second higher line is drawn parallel with it and on a level with the supraorbital border. A third line is drawn vertically upward along the anterior border of the mastoid (drawing the ear forward). The intersection of the third with the second line marks a convenient site for reaching the posterior branch. The trephine-pin rests on the squamoparietal suture. When the posterior branch itself is not encountered, its two branches usually are.

SURGICAL ANATOMY OF INTERNAL CAROTID ARTERY.

Description.—The larger of the two branches of the common carotid. Arises opposite upper border of thyroid cartilage (on level with fourth cervical vertebra)—at first comparatively superficial, and lies slightly external to external carotid, then sinks more deeply in neck and passes posteriorly to that vessel—ascending neck in front of transverse processes of upper cervical vertebræ to enter the carotid canal. The relations of its different portions are as follows:

Relations.—(1) First or **Cervical Portion:—Anteriorly** (from below upward)—skin; superficial fascia; platysma; deep fascia; sternomastoid; posterior belly of digastric; stylohyoid; hypoglossal; occipital artery; posterior auricular artery; external carotid; styloglossus; stylopharyngeus; glossopharyngeal nerve; pharyngeal branch of pneumogastric; stylohyoid ligament. **Posteriorly**—rectus capitis anticus major; transverse processes of three upper cervical vertebræ; superior cervical ganglion; pneumogastric nerve; hypoglossal nerve; glossopharyngeal nerve; spinal accessory nerve; internal jugular vein. **Externally**—internal jugular vein; pneumogastric nerve. **Internally**—pharynx; superior constrictor; tonsil; ascending pharyngeal artery; ascending palatine artery; eustachian tube; levator palati. (2) Second or **Petrous Portion:**—Within carotid canal in petrous portion of temporal bone. (3) Third or **Cavernous Portion:**—Between layers of dura mater, forming cavernous sinus. (4) Fourth or **Cerebral Portion:**—Enters inner extremity of fissure of Sylvius and gives off its branches.

Branches.—From cervical portion—none. From petrous portion—tympanic; vidian. From cavernous portion—arteria receptaculi; pituitary; gasserian; anterior meningeal; ophthalmic. From cerebral portion—anterior cerebral; middle cerebral; posterior communicating; anterior choroid.

Line.—Same, practically, as for the external carotid,—or possibly a little to the outer side of that line at its lower part.

Indications for Ligation.—Wounds; aneurism.

Sites of Ligation.—Near origin (Fig. 7, S).

LIGATION OF INTERNAL CAROTID ARTERY

NEAR ORIGIN.

Position—Landmarks.—As for ligation of external carotid below the digastric (page 35).

Incision.—Slightly posterior to the incision for the external carotid artery—that is, along the anterior border of the sternomastoid, instead of just in front of it—with the center of the incision about 1.3 cm. (½ inch) above the upper border of the thyroid cartilage (Fig. 7, S).

Operation.—The steps are, at first, the same as those for exposing the external carotid below the digastric. This artery (external carotid) is first

sought (all the structures mentioned in that operation being encountered) and traced to its bifurcation, and thus the internal carotid is exposed—the external carotid being drawn inward and the digastric upward. In opening the sheath special care must be taken to guard the internal jugular vein, pneumogastric nerve, cervical sympathetic, ascending pharyngeal artery—the needle being passed from the vagus and internal jugular vein.

Collateral Circulation.—Circle of Willis.

SURGICAL ANATOMY OF SUBCLAVIAN ARTERY.

Description.—Subclavian artery on right side, about 7.5 cm. (3 inches) in length, arises from the innominate; and, on the left, about 10 cm. (4 inches) in length, arises from arch of aorta—arching, in both cases, across the root of neck, over the dome of the lung and pleura, to the lower border of the first rib, where it becomes the axillary artery. That portion of the subclavian internal to inner border of scalenus anticus being the first part—that portion behind this muscle being the second part—and that portion external to the outer border of scalenus anticus being the third part. The subclavian vein lies below and anterior to artery, the scalenus anticus intervening. The posterior border of the sternomastoid corresponds with the external border of the scalenus anticus.

Relations.—(a) **First Portion of Right Subclavian:**—About 1.7 cm. (1¼ inches) in length—arises from bifurcation of innominate, behind upper border of right sternoclavicular articulation—curves upward and outward (with convexity upward) at a variable distance above clavicle, over apex of right lung and pleura, to inner border of right scalenus anticus, having following relations:—**Anteriorly**—skin; superficial fascia; platysma; anterior layer of deep fascia; clavicular origin of sternomastoid; sternohyoid; sternothyroid; sternohyoid; deep cervical fascia; right innominate vein; internal jugular vein; vertebral vein; pneumogastric nerve; phrenic nerve; superior cardiac branches of sympathetic nerve:—**Posteriorly**—areolar tissue; longus colli; transverse process of seventh cervical and first dorsal vertebra; sympathetic nerve; inferior cardiac nerves; recurrent laryngeal nerve; apex of right lung and pleura; neck of first rib:—**Inferiorly**—pleura and lung; recurrent laryngeal nerve; subclavian vein. (b) **First Portion of Left Subclavian:**—Much longer than that of right—arises from distal end of transverse part of arch of aorta, opposite fourth dorsal vertebra, to left and slightly posterior to left common carotid—ascending, at first, almost vertically—then arching further upward and outward over apex of left lung and pleura to inner border of left scalenus anticus—having following relations:—**Anteriorly**—left pleura and lung; sternothyroid; sternohyoid; sternomastoid; left innominate vein; internal jugular vein; vertebral vein; subclavian vein; phrenic nerve; pneumogastric nerve; left cervical cardiac nerves of sympathetic; left common carotid; thoracic duct:—**Posteriorly**—esophagus; thoracic duct; inferior cervical sympathetic ganglion; longus colli; vertebral column; left pleura and lung:—**Externally**—left pleura and lung:—**Internally**—trachea; recurrent laryngeal nerve; esophagus; thoracic duct. (c) **Second Portions of Both Subclavian Arteries:**—Highest part of the vessel—about 2 cm. (¾ inch) in length—lies behind scalenus anticus, which separates the artery from the subclavian vein—and has following relations:—**Anteriorly**—skin; superficial fascia; platysma; anterior layer of deep fascia; clavicular origin of sternomastoid; deep layer of deep fascia; phrenic nerve; subclavian vein;

scalenus anticus:—**Posteriorly**—apex of lung and pleura; scalenus medius:—**Superiorly**—brachial plexus:—**Inferiorly**—lung and pleura. (d) **Third Portions of Both Subclavians**:—Lie in subclavian triangle (of sternomastoid, omohyoid, and clavicle). Extend from outer border of scalenus anticus downward and outward to lower border of first rib, and have following relations:—**Anteriorly**—skin; superficial fascia; platysma; clavicular branches of descending portion of cervical plexus; anterior layer of deep fascia (from omohyoid to clavicle); posterior layer of deep fascia (from omohyoid to first rib); fatty areolar tissue between layers of deep cervical fascia; suprascapular artery; external jugular vein; suprascapular vein; transversalis colli vein; other tributary veins to external jugular; nerve to subclavius muscle; sternomastoid (sometimes); clavicle; subclavius muscle:—**Posteriorly**—scalenus medius; cord of brachial plexus formed by eighth cervical and first dorsal:—**Superiorly**—brachial plexus; posterior belly of omohyoid:—**Inferiorly**—first rib.

Branches.—From First Portion:—vertebral, thyroid axis (inferior thyroid, transversalis colli, suprascapular), internal mammary. From Second Portion:—superior intercostal. From Third Portion:—No branches, ordinarily.

Line.—A curve, with convexity upward, at base of posterior triangle—beginning at sternoclavicular articulation and ending at center of inferior border of clavicle—its mid-point being about 1.3 cm. (½ inch) above the superior border of clavicle.

Indications for Ligation.—Wounds; aneurism; preliminary to extensive operations about the shoulder and upper extremity.

Sites of Ligation.—Only three successful cases are recorded, as far as known by the writer, of ligature of the first portion of the right subclavian, and but one of the left—the ligation being particularly hazardous, especially upon the latter side. Nor is ligature of the second portion to be recommended, owing to the depth and relations of the artery. The third portion is the part of the artery usually selected for ligation (Fig. 7, T).

LIGATION OF FIRST PORTION OF RIGHT SUBCLAVIAN

BY ANGULAR INCISION.

Position—Landmarks—Incision.—As for ligation of innominate by angular incision (page 26).

Operation.—Having incised skin and superficial fascia, this triangular flap is dissected up, as in ligation of the innominate. The anterior jugular vein is doubly ligated and divided, and the external jugular similarly treated, if in the way. Divide the deep fascia. Expose and sever the sternal and clavicular heads of the sternomastoid. Divide the sternohyoid and sternothyroid either in whole or in part. Expose the common carotid, carefully retracting the internal jugular vein and pneumogastric nerve outward and displacing or doubly ligating any overlying veins. Identify the subclavian vein by following down the common carotid on its postero-external aspect to the bifurcation. Clear the subclavian artery, carefully guarding the recurrent laryngeal and phrenic nerves and vertebral artery. Displace the pleura downward and outward with tip of finger, and pass the needle from below (from the pleura). The vertebral should also be secured at the same time and through the same incision—to accomplish which, the internal jugular and pneumogastric nerve are now retracted inward and the vertebral exposed by a few strokes of the knife as it lies between the longus colli and

scalenus, guarding the phrenic and recurrent laryngeal nerves and the inferior thyroid artery.

Comment.—Excision of the right sternoclavicular articulation may be done when necessary, as in the ligation of the innominate by partial bony resection.

Collateral Circulation.—Superior thyroid, with inferior thyroid; one vertebral, with opposite vertebral. Internal mammary, with deep epigastric and aortic intercostals. Superior intercostal, with aortic intercostals. Profunda cervicis, with princeps cervicis. Scapular branches of thyroid axis, with branches of axillary. Thoracic branches of axillary, with aortic intercostals.

LIGATION OF FIRST PORTION OF LEFT SUBCLAVIAN

BY ANGULAR INCISION.

Position—Landmarks—Incision.—As for ligation of innominate by angular incision, except that the operation is placed upon the left side.

Operation.—The steps of the operation are similar to those for ligation of the first portion of the right subclavian—up to the exposure of the common carotid and internal jugular. Here the common carotid and pneumogastric are retracted inward, the internal jugular is drawn outward and downward, and, with it, the left innominate vein. At this stage the head is bent forward to relax the parts. Special care is here given to identifying the thoracic duct before proceeding—the duct arching from the seventh cervical vertebra forward and downward over the subclavian artery in front of the scalenus anticus, and emptying into the left subclavian vein at the junction with it of the left internal jugular, being embedded in the loose areolar tissue of the part, making it often difficult to find, and sometimes dividing into several branches. Having safeguarded the important neighboring structures, follow down the common carotid with the finger until the subclavian is identified, on a plane posterior and external to that of the former vessel. The artery is then to be freed, carefully guarding the pleura; the sheath is opened and the needle passed from the pleura.

Comment.—If more room be required than given by the above incision, or if it be required to ligate the vessel nearer the arch, an excision of the sternoclavicular articulation can be done. No successful case of ligation of the first part of the left subclavian is known to the writer.

Collateral Circulation.—See Ligation of First Part of Right Subclavian.

LIGATION OF SECOND PORTION OF SUBCLAVIAN ARTERY.

Position—Landmarks—Incision.—As for ligation of third portion of subclavian.

Operation.—The steps of this operation, up to the division of the deep cervical fascia and the recognition of the outer border of the scalenus anticus (which lies directly under the outer border of the sternomastoid), are identical with those for the exposure of the third part of the subclavian. The further steps consist in the inward retraction of the scalenus anticus (and overlying sternomastoid), with the division of as many of their fibers as necessary, when the artery will be exposed and may be ligated. Especial care is taken to guard the phrenic nerve, which crosses obliquely the lower anterior surface of the scalenus anticus,—as well as the transversalis colli and suprascapular

arteries, which cross the scalenus anticus transversely,—and the external jugular vein, running parallel with the anterior scalene muscle.

Comment.—This operation is often merely a proximal continuation of the operation for the exposure of the third part of the subclavian, when the application of a ligature to the third part is impracticable.

LIGATION OF THIRD PORTION OF THE SUBCLAVIAN.

Position.—Patient supine; shoulders raised; head thrown back and to opposite side; shoulder depressed by arm drawn downward and placed under the back (to open out the posterior cervical triangle). Surgeon in front of shoulder.

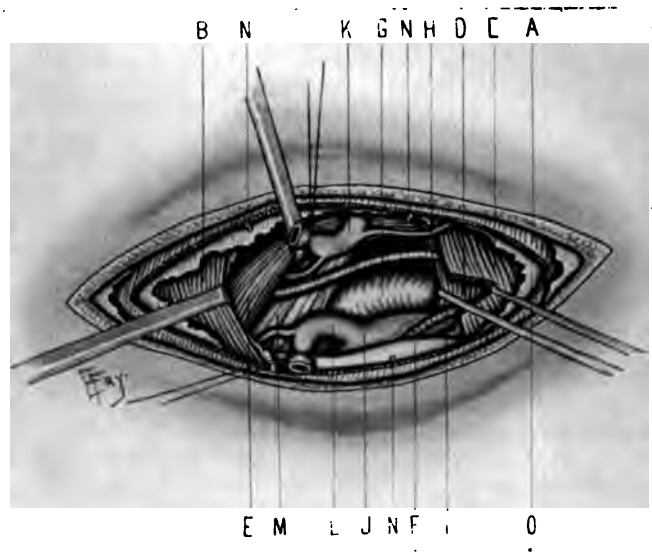

Fig. 17.—LIGATION OF THIRD PART OF RIGHT SUBCLAVIAN:—A, Platysma; B, Trapezius; C, Sternomastoid (posterior border incised); D, Scalenus anticus; E, Posterior belly of omohyoid (retracted upward); F, Clavicle; G, Third part of subclavian; H, Transversalis colli A.; I, Suprascapular A.; J, Subclavian vein; K, Upper end of external jugular V. (divided and retracted), with transversalis colli V. and communicating branch to anterior jugular; L, Lower end of external jugular (divided and retracted), with suprascapular branch; M, Brachial plexus; N, N, N, Supraclavicular nerves; O, Deep cervical fascia.

Landmarks.—Posterior border of sternomastoid (which corresponds with the outer border of the scalenus anticus); anterior border of trapezius; middle of clavicle.

Incision.—With the skin of the posterior cervical triangle drawn down over the clavicle by the left hand, an incision about 7.5 cm. (3 inches) is made transversely over the clavicle down to the bone, from the posterior border of the sternomastoid to the anterior border of the trapezius, and with its center about 2.5 cm. (1 inch) internal to the center of the superior border of the clavicle (Fig. 7, T).

Operation.—(1) This incision will divide the skin, fascia, platysma, some supraclavicular nerves, and maybe a connecting vein between the cephalic and internal jugular—but will avoid the external jugular, which

passes through the deep fascia above the clavicle. The incision will lie about 2.5 cm. (½ inch) above the clavicle when the tension upon the skin is relaxed (Fig. 17). (2) The margins of the sternomastoid and trapezius will be exposed, and, if more room be needed, may be divided along the clavicle as far as necessary. (3) The deep cervical fascia is next incised, the external jugular vein being carefully exposed and retracted, or divided between double ligatures. Tributary veins of the external jugular are to be similarly treated, especially the transversalis colli and suprascapular. (4) Generally the transversalis colli artery lies transversely above the incision, and the suprascapular transversely below it, under the clavicle and out of the way; but one or both may present in the field, and are to be carefully preserved for collateral circulation. Retract the posterior belly of the omohyoid upward if in the way. Identify the outer margin of the scalenus (just under the outer margin of the sternomastoid) as a guide to the artery, and follow its outer border downward until the finger reaches the tubercle on the upper border of the first rib, which lies between the subclavian vein in front, and the subclavian artery behind—when the artery will be recognized and may be traced upward. (5) Expose the lowest cord of the brachial plexus—for the purpose of henceforth avoiding it (as it has been mistaken and ligated for the artery). The subclavian vein will lie anteriorly and inferiorly to the artery. (6) Open the sheath—clear the artery—and pass the needle from the brachial plexus, guarding the subclavian vein and the pleura.

Collateral Circulation.—(When the second or third part is tied):—Suprascapular and posterior scapular above, with acromiothoracic, infrascapular, subscapular, and dorsalis scapulæ below; internal mammary, superior intercostals, aortic intercostals above, with long thoracic and scapular arteries below; plexiform vessels from branches of subclavian above, with branches of axillary below.

SURGICAL ANATOMY OF VERTEBRAL ARTERY.

Description.—Largest and generally first branch of subclavian. Arises from upper and posterior portion of first part of subclavian, near inner border of scalenus anticus—ascends upward, backward, and outward, in interval between scalenus anticus and longus colli, to foramen in transverse process of sixth cervical vertebra—passes through foramina in all vertebræ above this—emerging from foramen in transverse process of atlas, it runs in groove on posterior arch of atlas, lying in the suboccipital triangle, and pierces the occipito-atloid ligament and dura mater—and passes into cranium through foramen magnum—upward upon lateral aspect of medulla to its anterior aspect, where it unites with its fellow to form the basilar.

Relations.—(a) **First or Cervical Part**:—from origin to transverse process of sixth cervical vertebra, lying between scalenus anticus and longus colli. **Anteriorly**—vertebral vein; internal jugular vein; inferior thyroid artery; thoracic duct (left side). **Posteriorly**—transverse process of seventh cervical vertebra; sympathetic nerve. **Externally**—scalenus anticus. **Internally**—longus colli. (b) **Second or Vertebral Portion**:—runs in osseomuscular canal formed by intervertebral foramina and intertransverse muscles, surrounded by plexus of veins and branches of sympathetic nerve. (c) **Third or Occipital Portion**:—lies in suboccipital triangle, which is formed, superiorly and internally, by rectus capitis posticus major; superiorly and externally, by obliquus capitis superior; inferiorly and externally, by obliquus

capitis inferior; covered by complexus muscle; and floor formed by posterior occipito-atlantal ligament, posterior arch of atlas and posterior atlanto-axial ligament;—the triangle containing the vertebral artery and suboccipital nerve, the latter passing between the artery and arch of the atlas. **Anteriorly**—rectus capitis lateralis; articular process of atlas; occipito-atloid ligament. **Posteriorly**—superior oblique; rectus capitis posticus major; complexus. (d) **Fourth or Intracranial Portion**:—from opening in dura to lower border of pons, where it unites with its fellow to form basilar artery.

Indications for Ligation.—Wounds; traumatic aneurism; in connection with ligation of innominate (to prevent secondary hemorrhage).

Sites of Ligation.—In the first or cervical portion (usual site); in third or occipital portion (rarely).

LIGATION OF VERTEBRAL BRANCH OF SUBCLAVIAN

NEAR ITS ORIGIN.

Position.—Patient supine; shoulders raised; neck prominent; head to opposite side; surgeon on right, in operating on either vertebral.

Landmarks.—Anterior border of sternomastoid.

Incision.—About 7.5 cm. (3 inches) in length, extending along the anterior border of the sternomastoid, ending below at the clavicle. (As for ligation of the common carotid below the omohyoid.)

Operation.—(1) Having divided skin, superficial fascia, and the anterior portion of the platysma, branches of the superficial cervical nerve, and communicating veins between the anterior and external jugular veins, are encountered and are treated as indicated. (2) Incise the deep cervical fascia, exposing the anterior border of the sternomastoid, which is to be drawn outward; and the omohyoid, which is to be retracted downward and inward; and also the sternohyoid, which is drawn inward. (3) Having freed the attachment of the inner aspect of the common sheath, the carotid, internal jugular, and pneumogastric are drawn outward from over the vertebral artery. The prevertebral fascia is then incised vertically between the carotid tubercle (transverse process of sixth cervical vertebra) and the arch of the inferior thyroid artery (where it turns inward to the posterior surface of the thyroid gland)—where the vertebral artery will be found ascending, partly covered by the longus colli, to the foramen in the transverse process of the sixth cervical vertebra, having the anterior scalenus muscle and phrenic nerve to its outer side, and the longus colli muscle and recurrent laryngeal nerve to its inner side, and the inferior thyroid artery and vein and the vertebral vein lying over it. All these structures, therefore, are to be displaced in the most convenient directions, as the finger seeks the vertebral artery in the above triangular space. The pleura lies below and internally. The thoracic duct, on the left, crosses the artery from within outward. (4) The artery is to be exposed, and the ligature passed with especial care, in order to avoid, as far as possible, the fibers of the sympathetic, some of which are apt to be included in the ligature.

Comment.—The vertebral artery may also be ligated by an incision made along the posterior border of the sternomastoid, followed by the inward retraction of that muscle (with or without a partial division of its clavicular attachment), but is less simple than the above. The artery may also be ligated in the suboccipital triangle.

SURGICAL ANATOMY OF INFERIOR THYROID BRANCH OF THYROID AXIS OF SUBCLAVIAN ARTERY.

Description and Relations.—Largest branch of thyroid axis (which latter arises from first part of subclavian). Ascends upward and inward to posterior surface of thyroid gland—passing behind common carotid, internal jugular, pneumogastric nerve, and sympathetic nerve (middle cervical ganglion usually resting upon it)—and in front of vertebral artery, recurrent laryngeal nerve (sometimes posterior to it), longus colli muscle. The thoracic duct passes in front of commencement of left vertebral artery.

Indications for Ligation.—Preliminary to thyreoidectomy; and to diminish goiter.

Sites of Ligation.—Just beyond the ascending cervical branch (which arises shortly before the vertebral passes behind the carotid).

LIGATION OF INFERIOR THYROID BRANCH OF THYROID AXIS OF SUBCLAVIAN.

Position.—Patient supine; shoulders elevated; neck prominent; head to opposite side. Surgeon to right side, in either case.

Landmarks.—Anterior border of sternomastoid.

Incision.—About 7.5 cm. (3 inches) in length, along the anterior margin of the sternomastoid (as for the common carotid).

Operation.—Divide skin, superficial fascia, and the platysma, when branches of the superficialis colli nerve and tributaries between the anterior and external jugular veins are met, and are to be dealt with as indicated. Incise the deep cervical fascia and define the anterior border of the sternomastoid, and retract that muscle outward—the omohyoid is drawn downward and inward, and the sternohyoid inward. After freeing the inner attachment of the common sheath, the carotid, internal jugular, and pneumogastric are drawn outward from over the inferior thyroid artery. The artery is then sought by continuing the dissection toward the vertebræ, lying a little way below the carotid tubercle, in the interval covered by the sternothyroid muscle, between the inner border of the retracted carotid sheath and the outer border of the thyroid gland. The gland is raised and displaced inward. The artery is exposed where it arches inward, and where the ascending cervical branch arises. The ligature is applied just beyond this branch—thus avoiding the recurrent laryngeal nerve, which runs along the trachea and behind the thyroid gland; and the vertebral artery, nearly parallel with it below and passing behind the inferior thyroid as the latter bends inward. The sympathetic nerve, which sometimes embraces the artery, and the phrenic, which lies to its outer side, are to be guarded against injury.

SURGICAL ANATOMY OF TRANSVERSALIS COLLI BRANCH OF THYROID AXIS OF SUBCLAVIAN.

Description.—One of three branches of thyroid axis. Runs transversely outward, crossing root of neck a little above the clavicle, and divides, beneath anterior border of trapezius, into posterior scapular and superficial cervical.

Relations.—From its origin outward, it is covered by the platysma,

cervical fascia, sternomastoid, omohyoid, and anterior border of trapezius—and rests on phrenic nerve, scalenus anticus, brachial plexus (or between its cords), and scalenus medius.

Indications for Ligation.—Rare, except for wounds, when the artery, or its branches, are cut down upon and tied where wounded.

Sites of Ligation.—Most conveniently exposed in the subclavian triangle, just below the outer margin of the sternomastoid.

LIGATION OF TRANSVERSALIS COLLI BRANCH OF THYROID AXIS OF SUBCLAVIAN

AT OUTER MARGIN OF STERNOMASTOID.

Position.—As for ligation of inferior thyroid.

Landmarks.—Posterior border of sternomastoid, made evident by manipulating the neck so as to render the margin of the muscle tense.

Incision.—About 5 cm. (2 inches), along posterior border of sternomastoid, extending nearly to clavicle (Fig. 7, W).

Operation.—Having incised skin, superficial fascia, and platysma, branches of the descending superficial cervical nerves may be encountered, as well as the tributaries of the external jugular vein. The external jugular vein itself has to be carefully guarded at the outer edge of the sternomastoid. Having divided the deep cervical fascia and exposed the posterior border of the sternomastoid and the posterior belly of the omohyoid, the latter muscle, if in the way, is retracted upward. The sternomastoid (whose outer border corresponds with the outer border of the scalenus anticus) is then drawn inward, and the artery is found crossing outward between the two muscles to pass beneath the posterior belly of the omohyoid to reach the trapezius. The cords of the brachial plexus are to be guarded in passing the ligature (Fig. 17).

SURGICAL ANATOMY OF THE SUPRASCAPULAR BRANCH OF THE THYROID AXIS OF SUBCLAVIAN.

Description.—Smallest of three branches of thyroid axis. Runs transversely outward across root of neck, at first between scalenus anticus and sternomastoid—thence through lower part of subclavian triangle—behind clavicle and subclavius muscle—beneath posterior belly of omohyoid—over transverse ligament of scapular notch into supraspinous fossa (the suprascapular nerve passing through the notch)—and finally winds around base of spine and neck of scapula to gain the infraspinous fossa. Two venæ comites accompany the artery.

Relations.—From its origin outward, the artery is covered by the skin, platysma, cervical fascia, sternomastoid, trapezius, posterior belly of omohyoid, clavicle, subclavius muscle, supraspinatus, infraspinatus;—and rests upon the phrenic nerve, scalenus anticus, cervical fascia from omohyoid to first rib, subclavian artery, brachial plexus, transverse scapular ligament, scapula.

Indications—Site of Ligation.—As for transversalis colli.

LIGATION OF SUPRASCAPULAR BRANCH OF THYROID AXIS OF SUBCLAVIAN

AT OUTER MARGIN OF STERNOMASTOID.

Position—Landmarks—Incision.—As for ligation of transversalis colli artery (page 58).

Operation.—Practically the same as that for the transversalis colli, the suprascapular artery running almost parallel with it, though on a somewhat lower plane, and soon getting behind the clavicle and subclavius muscle. The site of exposing the artery is in the same vertical line (at the posterior border of the sternomastoid) but nearer the clavicle. The same care is necessary in guarding the external jugular vein, which here enters the subclavian near the site at which the artery is ligated (Fig. 17).

SURGICAL ANATOMY OF INTERNAL MAMMARY BRANCH OF SUBCLAVIAN.

Description.—Arises from lower aspect of first part of subclavian, near to inner margin of scalenus anticus—descends forward and inward, passing behind clavicle to enter thorax posterior to cartilage of first rib—thence runs downward parallel with and about 1.3 cm. ($\frac{1}{2}$ inch) external to margin of sternum, to interspace between sixth and seventh costal cartilages, where it divides into superior epigastric and musculophrenic. Its two venæ comites unite to form one trunk in first intercostal space and empty into the innominate vein. The internal mammary artery, above, is 0.5 to 1.5 cm. ($\frac{1}{5}$ to $\frac{3}{5}$ inch) from border of sternum—and, below, from 1 to 2 cm. ($\frac{2}{5}$ to $\frac{4}{5}$ inch) from the sternal margin. In its upper part it lies between the internal intercostal muscle and costal cartilages, in front; and pleura behind. In its lower part it lies between the costal cartilages in front; and triangularis sterni behind (the latter structure intervening between it and the pleura).

Relations.—(a) **Cervical Part:**—Covered by sternomastoid, subclavian vein, internal jugular vein, phrenic nerve. Rests on pleura, innominate vein. (b) **Thoracic Part:**—Covered by cartilages of first to sixth ribs, pectoralis major, internal intercostal muscles, anterior intercostal membrane. Rests on pleura (above), and triangularis sterni (below).

Arterial Supply of the Antero-lateral Thoracic Wall.—(a) As the internal mammary artery crosses the upper intercostal spaces two branches (superior and inferior anterior intercostal arteries, or superior and inferior branches of the anterior intercostal arteries, where they arise from a common trunk) are given off in each of the five or six upper interspaces—which pass outward between the pleura and the internal intercostal muscles, and then between the internal and external intercostal muscles, running along the lower border of the superior, and the upper border of the inferior rib—to anastomose with the superior and inferior branches of the aortic intercostals. (b) In each of the same upper five or six spaces a single branch, the perforating, or the anterior perforating, is given off between the upper and lower anterior intercostal arteries—which pierce the internal intercostal muscles, between the costal cartilages, and supply the pectoralis major, mammary gland (second, third, and fourth branches), and skin. (c) The anterior intercostal branches for the five or six lower interspaces are given off by the musculophrenic branch, which passes down behind the costal cartilages, piercing the diaphragm opposite the ninth rib, and ending at the tenth or eleventh

interspace by anastomosing with the ascending branch of the deep circumflex iliac. The anterior intercostals anastomose with the lower aortic intercostals.

Indications for Ligation.—Rare, except for wound, when it is usually ligated at the site of injury. If the artery have retracted out of reach, in the interspace above or below.

Sites of Ligations.—Reached most readily in first, second, or third interspaces—especially in the second.

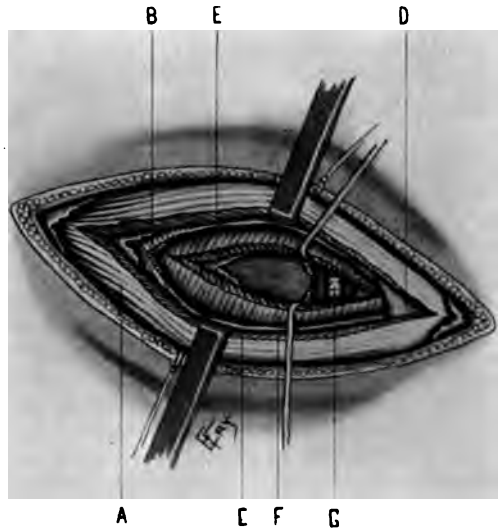

Fig. 18.—Ligation of Right Internal Mammary in Second Intercostal Space:—A, Pectoralis major; B, External intercostal muscle, continued to sternum by anterior intercostal membrane; C, Internal intercostal muscle; D, Margin of sternum; E, Endothoracic fascia; F, Pleura; G, Internal mammary artery and venæ comites.

LIGATION OF INTERNAL MAMMARY BRANCH OF SUBCLAVIAN

IN SECOND INTERCOSTAL SPACE.

Position.—Patient supine; chest supported from behind (to increase width of intercostal spaces). Surgeon on side of operation.

Landmarks.—Outer border of sternum; lower border of second and upper border of third costal cartilages.

Incision.—Transverse in direction and about 6.3 cm. (2½ inches) in length—beginning over center of sternum and passing outward over center of interspace between second and third costal cartilages (Fig. 7, V).

Operation.—Divide skin, fascia, pectoralis major, anterior intercostal membrane (running downward and inward), internal intercostal muscle (running downward and outward), and endothoracic fascia—when the artery is found lying upon the pleura, with the vein to the inner side. Pass the needle from the vein and with great care, to avoid the pleura. (A vena comes may be on either side.) (Fig. 18.)

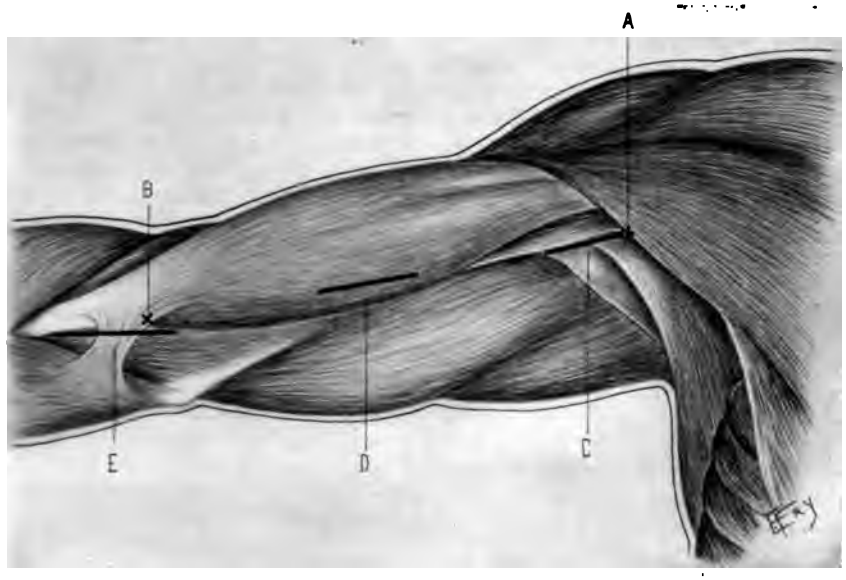

Fig. 19.—INCISIONS FOR LIGATING RIGHT AXILLARY AND BRACHIAL ARTERIES:—A, Junction of anterior and middle thirds of outer axillary wall; B, Center of bend of elbow; C, Ligation of third part of axillary; D, Of brachial in middle of arm; E, Of brachial at bend of elbow.

SURGICAL ANATOMY OF AXILLARY ARTERY.

Description and Relations.—Continuation of subclavian—extending through axilla, from lower border of first rib, on to the arm, at the lower border of the tendon of teres major muscle, where it becomes the brachial. It is divided into three parts: (a) **First Part:**—About 2.5 cm. (1 inch) in length—extending from lower border of first rib to upper border of pectoralis minor, having following relations: **Anteriorly**—skin; superficial fascia; origin of platysma; deep fascia; pectoralis major; clavicle (when shoulder is depressed); subclavius muscle (when shoulder is depressed); costocoracoid membrane; layer of areolar fatty tissue; cephalic vein; acromiothoracic vein; anterior external thoracic nerve; axillary lymphatic trunk. **Posteriorly**—first intercostal space; first intercostal muscle; second (and sometimes third) serrations of serratus magnus; part of second rib; posterior thoracic nerve. **Externally**—brachial plexus. **Internally**—axillary vein; anterior internal thoracic nerve. (b) **Second Part:**—about 3 cm. (1¼ inches) in length—lying behind pectoralis minor muscle, and having following relations: **Anteriorly**—integuments; superficial fascia; pectoralis major; pectoralis minor. **Posteriorly**—posterior cord of brachial plexus; areolar tissue and fat; subscapularis. **Externally**—external cord of brachial plexus; coracoid process (somewhat removed). **Internally**—internal cord of brachial plexus; axillary vein. (c) **Third Part:**—about 7.5 cm. (3 inches) in length—extending from lower border of pectoralis minor to lower border of tendon of teres major (the upper half being in axilla, the lower half on arm), and having following relations: **Anteriorly**—integument; superficial fascia; pectoralis major; deep fascia of arm; internal root of median nerve; external brachial vena comes. **Posteriorly**—musculospiral nerve; circumflex nerve; fatty areolar tissue;

subscapularis; latissimus dorsi; teres major. **Externally**—external root of median nerve; musculocutaneous nerve; coracobrachialis. **Internally**—internal root of median nerve; ulnar nerve; internal cutaneous nerve; lesser internal cutaneous nerve; axillary vein.

Branches.—From first part—superior thoracic, acromial thoracic. From second part—long thoracic, alar thoracic. From third part—subscapular, anterior circumflex, posterior circumflex.

Line of Artery.—(With arm at right angle to trunk and hand supine)—from middle of clavicle to junction of anterior and middle thirds of the outer axillary wall, between the anterior and posterior folds of the axilla.

Sites of Ligation.—Third part, by preference;—first part, if third part not available. Ligation of third portion of subclavian is usually considered preferable to that of first part of axillary (Figs. 19, C, and 7, W).

Comment.—(1) When the arm is at a right angle to the body, the axillary vein is drawn across the first part of the artery. (2) The upper and lower borders of the pectoralis minor correspond, respectively, with lines drawn from the junction of the third rib and its cartilage to the coracoid process; and from the junction of the fifth rib and its cartilage to the coracoid process. (3) Two brachial venæ comites are generally found at the lower part of the artery—and also the basilic vein, unless it have already joined the internal vena comes.

LIGATION OF FIRST PART OF AXILLARY ARTERY

BY CURVED TRANSVERSE INCISION BELOW CLAVICLE.

Position.—Patient on back, at edge of table; upper thorax raised; shoulder backward. Surgeon near thorax on left, for left operation; near head on right, for right operation—(or between abducted limb and body on each side).

Landmarks.—Clavicle; sternoclavicular articulation; coracoid process.

Incision.—Curved incision in infraclavicular fossa—beginning just external to the sternoclavicular joint—dipping, at lowest point, about 1.3 cm. (½ inch) below clavicle—and ending at the coracoid process (Fig. 7, W).

Operation.—Incise skin, platysma, supraclavicular nerves, and fascia. Carefully guard the cephalic vein and branches of acromial thoracic artery at outer part of wound, on account of collateral circulation. Divide the clavicular origin of the pectoralis major throughout the wound. Clear the areolar tissue beneath the pectoralis major. Expose the upper border of the pectoralis minor and draw it downward. Divide vertically, near the coracoid process, the costocoracoid membrane—through which pass the cephalic vein, branches of the acromiothoracic artery, and the anterior thoracic nerves—and displace it upward and outward. The cephalic vein, indicating the position of the axillary vein, is generally closely adherent to the costocoracoid membrane. Expose the sheath and clear the artery—which lies between the axillary vein on the inner side and the brachial plexus on the outer, aided in the exposure by bringing the arm nearer the body, when the axillary vein will be carried from over the artery to its inner side. The ligature is placed above the acromiothoracic branch. The incised pectoralis major muscle is repaired by gut suturing.

Comment.—This is the easiest and most frequent ligation of the first part, in the rare cases in which a ligation at this site is done—a ligation of the third portion of the subclavian being considered preferable. The first

part may be exposed by an oblique incision between pectoralis major and deltoid.

Collateral Circulation.—When ligated between the superior thoracic and acromial thoracic:—Suprascapular and posterior scapular; with acromial thoracic and subscapular. Internal mammary, aortic intercostals, superior intercostal; with long thoracic and subscapular. Plexiform vessels from subclavian; with plexiform vessels from axillary.

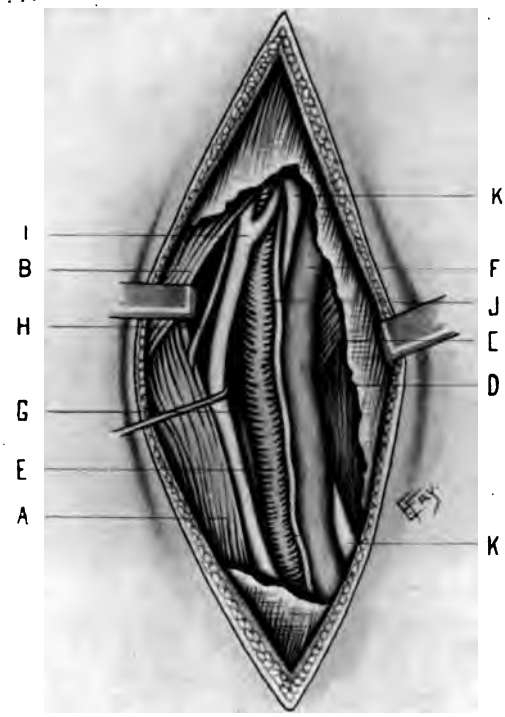

Fig. 20.—Ligation of Third Part of Right Axillary:—A, Coracobrachialis (retracted outward); B, Pectoralis major; C, Teres major; D, Triceps; E, Axillary artery; F, Basilic vein, becoming axillary vein after receiving two brachial venæ comites; G, Right brachial vena comes; H, Musculocutaneous nerve; I, Median N.; J, Internal cutaneous N.; K, K, Ulnar N.

LIGATION OF THIRD PART OF AXILLARY ARTERY.

Position.—Patient supine at edge of table; shoulders raised; arm at right angle to body, and slightly rotated outward. Surgeon between arm and chest, on either side. Axilla to be shaved.

Landmarks.—Junction of anterior and middle thirds of external axillary wall; coracobrachialis.

Incision.—About 7.5 cm. (3 inches) in length—beginning at the middle of the outlet of the axilla, at the junction of the anterior and middle thirds of its outer wall, and passing downward along the inner border of the coracobrachialis (Fig. 19, C).

Operation.—Having incised integument and fascia, expose the inner border of the coracobrachialis (Fig. 20). Draw this muscle and the musculocutaneous nerve outward. The median nerve is exposed and also drawn outward. The internal cutaneous and ulnar nerves are drawn inward. Venæ comites are generally present at the lower part of the axilla and sometimes the basilic vein, which have to be guarded. Again, the axillary vein alone may be present to the inner side of the artery. Pass the needle from the vein, ligating the artery as far from a large branch as possible.

Collateral Circulation.—(a) If tied below the circumflex arteries:—the posterior circumflex above, with the superior profunda below. (b) If tied between subscapular above and two circumflex branches below:—the suprascapular and acromial thoracic above, with posterior circumflex below.

SURGICAL ANATOMY OF SUBSCAPULAR BRANCH OF AXILLARY ARTERY.

Description.—Arises from third part of axillary artery, opposite lower border of subscapularis;—passes downward and inward along the anterior margin of the lower border of that muscle, under cover of the latissimus dorsi to the angle of the scapula, accompanied by the long subscapular nerve and two venæ comites. The dorsalis scapulæ branch is given off about 2.5 cm. (1 inch) from the origin of the main vessel.

LIGATION OF SUBSCAPULAR BRANCH OF AXILLARY ARTERY

ALONG POSTERIOR AXILLARY FOLD.

Position.—Patient supine; limb fully abducted. Surgeon between chest and arm.

Landmarks.—Posterior axillary fold.

Incision.—Begins at the arm and passes along the anterior surface of the posterior axillary fold.

Operation.—Incise skin and superficial fascia. The intercostohumeral nerve may be encountered here. Divide the deep fascia. The artery lies at the upper edge of the insertions of the latissimus dorsi and teres major, which form the posterior axillary wall. Separate the artery from its venæ comites and long subscapular nerve and pass the needle.

Comment.—Through this incision the dorsalis scapulæ artery is also exposed, and at the upper part of this incision the circumflex nerve is seen.

SURGICAL ANATOMY OF BRACHIAL ARTERY.

Description.—Continuation of axillary artery. Extends down inner and anterior aspect of arm, from lower border of tendon of teres major to about 1.3 cm. (½ inch) below center of crease at bend of elbow, and divides, opposite junction of head with neck of radius, into radial and ulnar arteries. The artery lies in the depression at the inner borders of the coracobrachialis and biceps, and then in the groove between the supinator longus and pronator radii teres, passing under the bicipital fascia below. It lies to the inner side of humerus above, and in front of it below.

Relations.—Anteriorly: integument; superficial and deep fascia; median nerve (in middle); median basilic vein and bicipital fascia (at elbow). **Posteriorly:** lies, in order, upon—long head of triceps (musculospiral nerve and superior profunda artery intervening); inner head of triceps; insertion of coracobrachialis; brachialis anticus. **Externally:** in order—coracobrachialis; belly of biceps (both slightly overlapping the artery); tendon of biceps; median nerve, above (crossing artery at middle); external vena comes. **Internally:** internal cutaneous and ulnar nerves (above); median nerve (below); internal vena comes; basilic vein.

Branches.—Superior profunda; inferior profunda; anastomotica magna; nutrient; muscular.

Line of Artery.—(Arm extended and abducted, hand supine.) From junction of anterior and middle thirds of outer wall of axilla to center of bend of elbow (Fig. 19, A and B).

Sites of Ligation.—Middle of arm (preferably); bend of elbow.

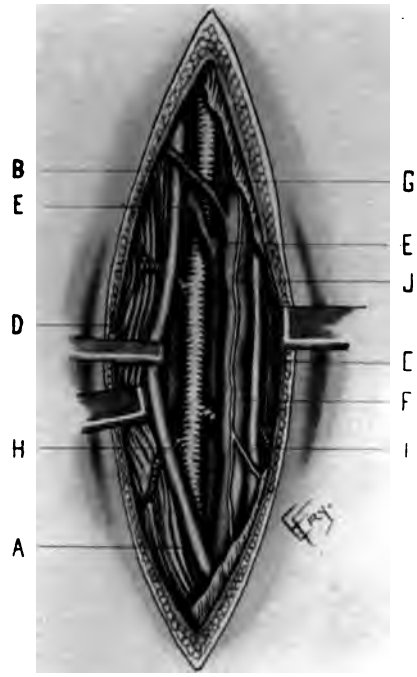

Fig. 21.—LIGATION OF RIGHT BRACHIAL AT MIDDLE OF ARM:—A, Biceps; B, Coracobrachialis (retracted outward); C, Triceps; D, Brachial artery and branches; E, Brachial venæ comites and communicating branches; F, Basilic vein; G, Branch from basilic to cephalic vein; H, Median nerve; I, Ulnar N.; J, Internal cutaneous N.

LIGATION OF BRACHIAL ARTERY

IN MIDDLE OF ARM.

Position.—Limb extended, abducted, and hand supine. Surgeon to outer side of limb, cutting from above downward on right, and from below upward on left.

Landmarks.—Inner border of coracobrachialis and biceps; line of artery.

Incision.—About 5 to 7.5 cm. (2 to 3 inches) in length, extending along inner border of biceps, in line of artery, opposite middle of arm (Fig. 19, D).

Operation.—The skin and fascia having been divided, the inner border of the biceps must be clearly recognized and retracted outward—when the artery is generally found under its inner margin—the median nerve usually crossing the front of the artery at its middle—the internal cutaneous nerve lying to the inner side (Fig. 21). The venæ comites and basilic vein are to be separated from the artery. The needle is passed from the nerve.

Comment.—(1) The artery is not as easily found in this situation as the superficial position would suggest. Its exposure is made easier by an assistant's holding the limb by the wrist, so that it cannot rest on the table, where the triceps is apt to be pushed upward and may protrude the inferior profunda artery and ulnar nerve, instead of the brachial artery and median nerve (Heath). (2) In ligating higher than the middle third, the artery lies to the inner side of the coracobrachialis, the median nerve to the outer side, and the ulnar nerve to the inner.

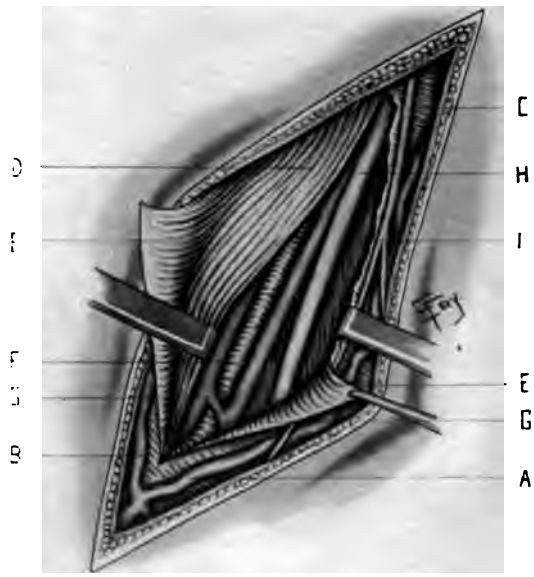

Fig. 22.—Ligation of Right Brachial at Bend of Elbow:—A, Median basilic vein; B, Median cephalic; C, Internal cutaneous nerve and branches; D, Biceps; E, E, Bicipital fascia; F, Brachial artery; G, Brachial venæ comites and communicating branches; H, Median nerve; I, Brachialis anticus muscle.

LIGATION OF BRACHIAL ARTERY

AT BEND OF ELBOW.

Position.—Limb extended (not overextended) and abducted. Surgeon to outer side of limb, cutting from above on right, and from below on left.

Landmarks.—Inner border of biceps tendon.

Incision.—About 5 cm. (2 inches) in length—in the internal bicipital fossa, along the inner border of the biceps tendon—its center corresponding to the "fold of the elbow." This incision will be oblique and its upper end will commence opposite the tip of the internal condyle of the humerus. It is well to compress the veins above, to get an idea of their position at the elbow, and thus avoid them, if possible. Ordinarily the incision will lie above and to the outer side of the median basilic (Fig. 19, E).

Operation.—Having incised skin and superficial fascia, isolate the median basilic vein and accompanying internal cutaneous nerve and retract them inward (Fig. 22). Incise, in the direction of the original wound, the deep fascia and the bicipital fascia—the latter (passing inward and downward) is to be incised to as limited an extent as possible. Beneath the bicipital fascia lies the artery, with its venæ comites—the median nerve generally lying out of the way and to the inner side, nearer the upper than the lower part of the wound. Pass the needle from the side of the ulnar nerve. Resuture the bicipital fascia with gut.

SURGICAL ANATOMY OF RADIAL ARTERY.

Description.—Smaller but more direct of two divisions of brachial. Begins at bifurcation of brachial, about 1.3 cm. (½ inch) below bend of elbow —runs outward and downward along radial side of forearm to styloid process of radius—thence passes around outer side of carpus over external lateral ligament and beneath extensor tendons of thumb, to back of wrist—and enters palm between first and second metacarpal bones, passing between the two heads of first dorsal interosseous muscle—thence crosses metacarpal bones and interossei muscles, anastomosing at ulnar side of hand with deep branch of ulnar, to form deep palmar arch. The artery is accompanied by two venæ comites.

Relations.—(a) **In Forearm:**—The artery runs in outermost intermuscular space, lying between supinator longus and pronator radii teres above, and between supinator longus and tendon of flexor carpi radialis below. **Anteriorly**—skin; fascia; supinator longus (above). Skin; fascia; cutaneous vessels and nerves (below). **Posteriorly**—(from above downward) tendon of biceps; supinator brevis; insertion of pronator radii teres; radial origin of flexor sublimis digitorum; flexor longus pollicis; pronator quadratus; anterior surface of lower end of radius. **Externally**—supinator longus (guide to artery) and external vena comes (throughout); radial nerve (middle third). **Internally**—pronator radii teres (upper third); tendon flexor carpi radialis (lower third); internal vena comes (throughout). (b) **At Wrist:**—The artery winds over outer side of carpus, from a point just below and internal to styloid process of radius, to base of first interosseous space, entering the palm between the two heads of the first dorsal interosseous muscle (abductor indicis) to form the deep palmar arch. It is covered, successively, by extensor ossis metacarpi pollicis; extensor brevis pollicis; branches of radial nerve; superficial radial veins; extensor longus pollicis;—and rests, in order, upon external lateral ligament; scaphoid; trapezium; base of first metacarpal; dorsal carpal ligaments. It is accompanied by two venæ comites and branches of musculocutaneous nerve. (c) **In the Palm:**—Enters palm in upper part of interval between first and second metacarpals, passing between two heads of first dorsal interosseous muscle (abductor indicis)—runs inward between adductor obliquus pollicis and adductor transversus

pollicis—crossing the palm transversely, with slight downward curve, to base of metacarpal of little finger, and there anastomoses with deep branch of ulnar, forming the deep palmar arch. The deep palmar arch, therefore, extends from base of first interosseous space to base of metacarpal of little finger, and is about 2 cm. ($\frac{3}{4}$ inch) nearer the wrist than is the superficial palmar arch. It is covered by the superficial and deep flexor tendons; ad-

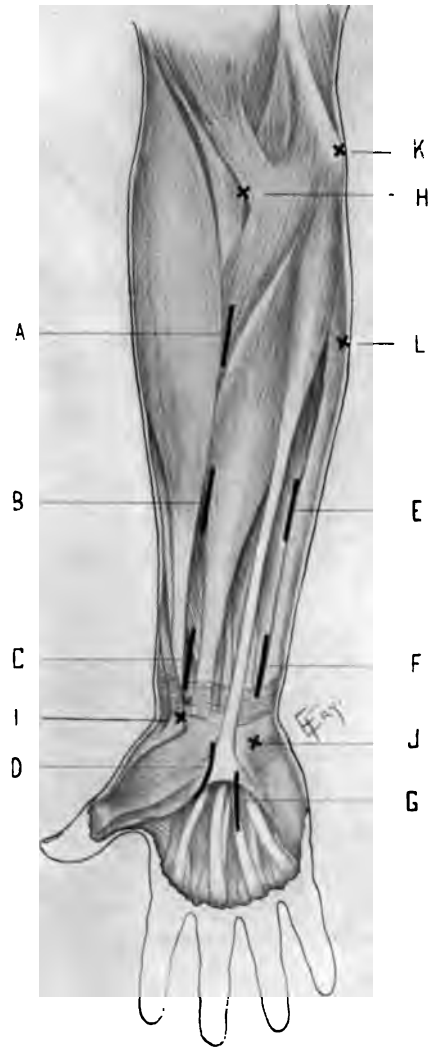

Fig. 23.—Incisions for Ligating Right Radial and Ulnar Arteries, and Superficial and Deep Palmar Arches.—A, Ligation of radial in upper third of forearm; B, of radial in middle third; C, of radial in lower third; D, of deep palmar arch; E, Ligation of ulnar in middle third of forearm; F, of ulnar in lower third; G, of superficial palmar arch; H, Center of bend of elbow; I, Antero-internal aspect of styloid process of radius; J, Radial side of pisiform bone; K, Anterior aspect of inner condyle of humerus; L, Point on inner aspect of forearm at junction of upper and middle thirds.

ductor obliquus pollicis; part of flexor brevis minimi digiti; part of opponens minimi digiti; lumbricales. It rests upon adductor transversus pollicis; carpal extremities of metacarpal bones; interossei muscles. It is accompanied by two venæ comites and the deep branch of the ulnar nerve (running in opposite direction).

Branches.—(**a**) In Forearm—radial recurrent; muscular; anterior radial carpal; superficialis volæ. (**b**) At Wrist—posterior radial carpal; metacarpal (first dorsal interosseous); dorsalis pollicis; dorsalis indicis. (**c**) In Palm—princeps pollicis; radialis indicis; palmar interosseous; recurrent; perforating.

Line of Artery.—(**a**) In Forearm (with hand supine)—from center of bend of elbow, to inner side of forepart of styloid process of radius (Fig. 23, H and I). (**b**) At Wrist—from inner side of forepart of styloid process to base of first interosseous space. (*c*) In Palm—runs about 2 cm. ($\frac{3}{4}$ inch) nearer wrist than does superficial palmar arch (which corresponds with a line continued across on level with lower border of outstretched thumb).

Sites for Ligature.—Upper forearm (rarely); middle forearm; lower forearm (preferably); back of hand (rarely). In palm—the arch may be tied in case of wounds, under which circumstances it may be ligated at any site (Fig. 23, D).

Anatomy of the "Tabatière," or "Snuff-box."—The triangular space on back of hand—bounded, on radial side, by extensor ossis metacarpi pollicis, and extensor brevis pollicis;—on ulnar side, by extensor longus pollicis;—above, by lower edge of posterior annular ligament. Its floor is formed by trapezium, part of scaphoid, base of first metacarpal. It contains radial artery, cephalic vein of thumb, branch of internal division of radial nerve, branch of musculocutaneous nerve.

LIGATION OF RADIAL ARTERY

IN UPPER THIRD OF FOREARM.

Position.—Hand supine; wrist extended. Surgeon stands outside of limb, cutting downward on right and upward on left. Assistant holds fingers with one hand and grasps forearm with other.

Landmarks.—Line of artery; inner border of supinator longus.

Incision.—From 5 to 7.5 cm. (2 to 3 inches), in line of artery—with center over the point to be tied (Fig. 23, A).

Operation.—Having incised skin and superficial fascia, the radial or median vein may be met. Divide the deep fascia and open up the space between the supinator longus (fibers running directly downward) and the pronator radii teres (fibers running downward and outward) (Fig. 24). The artery lies under the edge of the supinator longus and upon the insertion of the pronator radii teres. The radial nerve lies well to the outer side.

Comment.—Unless one recognize the inner margin of the supinator longus, there is possibility of hitting off the wrong intermuscular septum and getting too near the middle of the forearm. The supinator longus (and not its inner border) appears at first, in operating upon the muscular—and this must be well retracted outward.

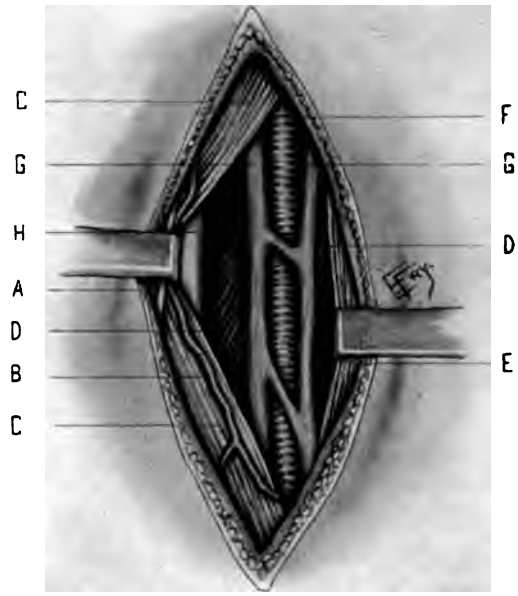

Fig. 24.—LIGATION OF UPPER THIRD OF RIGHT RADIAL:—A, Anterior branch of musculocutaneous nerve; B, Branch of radial vein; C, C, Supinator longus muscle, retracted outward; D, D, Pronator radii teres; E, Flexor carpi radialis; F, Radial artery; G, G, Radial venæ comites; H, Radial nerve.

LIGATION OF RADIAL ARTERY

IN MIDDLE THIRD OF FOREARM.

Position.—As for upper third.

Landmarks.—Line of artery (especially as inner border of supinator longus is not always evident).

Incision.—From 5 to 6 cm. (2 to 2½ inches)—in line of artery, with its center opposite center of forearm, so as to fall between supinator longus and flexor carpi radialis (Fig. 23, B).

Operation.—Having incised skin and superficial fascia, branches of the radial and median veins and anterior branch of the musculocutaneous nerve are generally encountered. Incise the deep fascia and recognize the inner margin of the supinator longus (its fibers running directly downward) and retract outward while elbow is slightly flexed. The artery is found upon the flexor sublimis digitorum and flexor longus pollicis—or, if higher up, upon the insertion of the pronator radii teres, with its venæ comites. Clear the artery and pass the needle from the nearer vein. The radial nerve lies to the radial side of the artery, but may not come into the field.

LIGATION OF RADIAL ARTERY

IN LOWER THIRD OF FOREARM.

Position.—As for upper third.

Landmarks.—Tendons of supinator longus and flexor carpi radialis.

Incision.—From 2.5 to 5 cm. (1 to 2 inches), vertically, in center of interval between tendons of supinator longus and flexor carpi radialis (Fig. 23, C).

Operation.—Having incised skin and superficial fascia, the radial vein, or a large branch, and often the superficialis volæ artery, are met and are

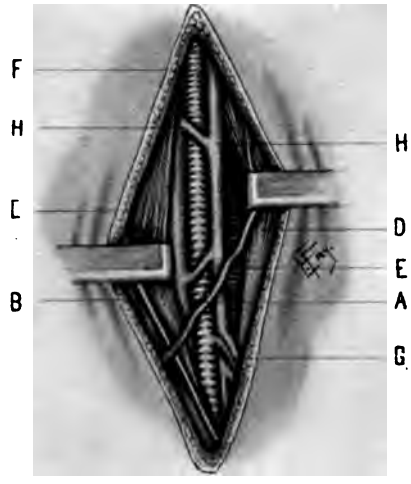

Fig. 25.—LIGATION OF LOWER THIRD OF RIGHT RADIAL (JUST ABOVE WRIST):—A, Radial vein; B, Anterior branch of musculocutaneous nerve; C, Supinator longus tendon; D, Flexor carpi radialis tendon; E, Pronator quadratus; F, Radial artery; G, Superficialis volæ artery; H, H, Radial venæ comites.

displaced to one side (Fig. 25). The deep fascia is divided, and the interval between the tendon of the supinator longus, externally, and the tendon of the flexor carpi radialis, internally, is opened up and the artery and its venæ comites are found between them, accompanied by the anterior branch of the musculocutaneous nerve.

LIGATION OF RADIAL ARTERY

ON BACK OF HAND.

Position.—Limb rests on ulnar margin. Assistant holds thumb extended and abducted, and fingers straight, and so manipulates them as to bring out the boundaries of the snuff-box.

Landmarks.—Tendons of extensor ossis metacarpi pollicis and extensor brevis pollicis, on radial side—and that of extensor longus pollicis, on ulnar side.

Incision.—From 2.5 to 4 cm. (1 to 1½ inches), midway between the two ridges made by the above tendons—beginning on a level with the tip of the styloid process, and extending downward, but stopping short of the lower end of the vessel.

Operation.—Having incised skin and superficial fascia, separate the divided fascia carefully. Avoid the cephalic vein of the thumb and branches of the radial and musculocutaneous nerves. Demonstrate the tendons forming the boundaries of the snuff-box. The artery is found deeply placed and closely surrounded by venæ comites, which may be included in the ligature if necessary.

Comment.—Guard against opening the synovial sheaths of the tendons.

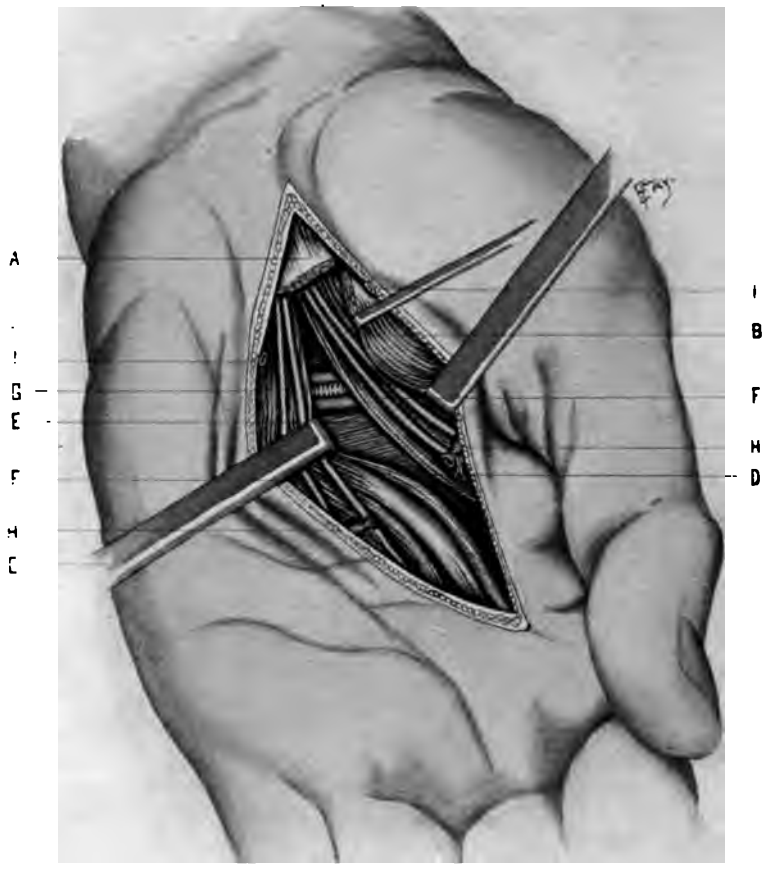

Fig. 25.—Ligation of Left Superficial and Deep Palmar Arches:—A, Annular ligament; B, Flexor brevis pollicis (part of its origin from annular ligament incised); C, Tendons of flexor sublimis digitorum and outer lumbrical (drawn inward); D, Adductor obliquus pollicis; E, Adductor transversus pollicis; F, F, Branches of median nerve; H, H, Superficial palmar arch; G, Deep palmar arch and its venæ comites; I, I, Superficial vein.

LIGATION OF DEEP PALMAR ARCH OF RADIAL ARTERY.

Position.—Limb supine; hand extended. Assistant steadying fingers and wrist. Surgeon cuts from above downward on both sides.

Landmarks. Oblique crease running downward and outward from junction of thenar and hypothenar eminences and partially circumscribing the thenar eminence.

Incision.—From junction of the thenar and hypothenar eminences—and running along the thenar crease toward the metacarpo phalangeal joint of the index finger—with the center of the incision opposite the center of the ball of the thumb (Fig. 23, D).

Operation.—Having incised skin and superficial fascia, expose and ligate the superficial palmar arch (crossing the palm on a level with the lower border of the outstretched thumb) (Fig. 26). The muscles of the thenar eminence are now exposed, and these, with the annular ligament, are incised at the upper part of the wound to as limited an extent as possible. The interval between the flexor tendon of the index-finger and its accompanying lumbrical muscle, on the one hand, and the muscles of the thumb, on the other, is made out and opened up by deep retraction, guarding the branches of the median nerve. In the interval thus exposed by retraction is seen the adductor obliquus pollicis, which is to be divided vertically, when the arch will be found under it, running transversely from between the adductor obliquus pollicis and adductor transversus pollicis onto the deep fascia covering the interossei, and about 2 cm. (¾ inch) nearer the wrist than does the superficial arch. The needle is to be carefully passed in the deep wound, to avoid the nerves and veins.

Comment.—The position for ligating can be located by feeling for the apex of the first interosseous space on the back of the hand.

SURGICAL ANATOMY OF ULNAR ARTERY.

Description.—Larger of two divisions of brachial artery. Begins at bifurcation of brachial, about 1.3 cm. (½ inch) below bend of elbow, and in middle of forearm—runs through upper half of forearm, with slight curve (convexity to ulnar side), to ulnar aspect of limb, passing beneath the pronator radii teres and superficial flexors—thence vertically down the lower half of the forearm, along its ulnar border to the wrist, being slightly overlapped by the flexor carpi ulnaris. It crosses the annular ligament immediately to the radial side of the pisiform bone, and, entering the palm, divides into superficial and deep palmar branches, to help form superficial and deep palmar arches. It is accompanied by two venæ comites. The ulnar nerve comes into contact with the artery at the junction of its upper and middle thirds, and remains in relation with it to the palm, being upon its ulnar side.

Relations.—(A) **In Forearm:**—**Anteriorly**—(**a**) Above—skin; fascia; superficial flexors (pronator radii teres, flexor carpi radialis, palmaris longus, flexor sublimis digitorum); median nerve (separated from artery by deep head of pronator radii teres). (**b**) Upper part of lower half—skin; fascia; and overlapped by tendon of flexor carpi ulnaris. (**c**) Lower part of lower half—skin; superficial fascia; deep fascia; palmar cutaneous branch of ulnar nerve. **Posteriorly**—brachialis anticus; flexor profundus digitorum. **Externally**—flexor sublimis digitorum (in lower two-thirds of artery's course). **Internally**—flexor carpi ulnaris (in lower two-thirds); ulnar nerve (in lower two-thirds). (B) **At Wrist:**—This part of the artery extends from the upper to the lower part of the annular ligament, running in a channel formed by the pisiform and unciform process of unciform bone and by expansion of flexor carpi ulnaris extending from pisiform to unciform process. **Anteriorly**—skin; fascia; expansion of flexor carpi ulnaris from pisiform to unciform process of unciform. **Posteriorly**—anterior annular ligament. **Externally**—unciform process of unciform bone. **Internally**—pisiform bone; ulnar nerve. (C) **In Palm:**—On entering the palm, the ulnar divides into superficial branch and deep branch:—(1) **Superficial branch of ulnar**—direct continuation of ulnar artery—descends short distance toward gap

between fourth and fifth fingers, thence curves outward (with convexity toward fingers) and anastomoses opposite gap between index and middle finger, and at junction of upper and middle thirds of hand, with superficialis volæ of radial (sometimes with branch from radialis indicis of radial) to form superficial palmar arch—having following relations: **Anteriorly**—skin; fascia; and, from ulnar to radial side, by palmaris brevis, palmar branch of ulnar nerve, palmar fascia, palmar branch of median nerve. **Posteriorly**—in order, from ulnar to radial side—annular ligament; short muscles of little finger; digital branches of ulnar nerve; superficial flexor tendons; digital branches of median nerve. (**2**) **Deep (communicating) branch of ulnar artery**—runs deeply inward, between abductor minimi digiti and flexor brevis minimi digiti—anastomosing with termination of radial to form deep palmar arch.

Branches.—(**a**) In Forearm—anterior ulnar recurrent; posterior ulnar recurrent; common interosseous (anterior and posterior interosseous); muscular. (**b**) At Wrist—anterior ulnar carpal; posterior ulnar carpal. (**c**) In Palm—superficial palmar arch; deep (communicating) palmar.

Line of Artery.—Upper third of artery corresponds with line from a point about 1.3 cm. (½ inch) below center of bend of elbow, passing to inner side with gentle curve (convexity to ulnar side), to a point at junction of upper and middle thirds of following line. Lower two-thirds corresponds with line from anterior surface of internal condyle of humerus to radial side of pisiform bone (Fig. 23, H, L, and K, J).

Sites for Ligation.—Upper third of forearm (rarely); middle third; lower third (commonly); superficial palmar arch (for wounds at that site) (Fig. 23).

LIGATION OF ULNAR ARTERY

IN MIDDLE THIRD OF FOREARM.

Position.—As for the radial artery.

Landmarks.—Line of artery. The muscular landmarks at the middle of the forearm are generally difficult to recognize.

Incision.—About 7.5 cm. (3 inches), in line of artery, with its center corresponding with the center of the forearm (E, Fig. 23).

Operation.—Incise skin and superficial fascia. The anterior ulnar vein and anterior branch of internal cutaneous nerve are likely to be encountered (Fig. 27). Divide the deep fascia somewhat to the outer side of the skin incision, as the flexor sublimis digitorum is generally slightly overlapped by the flexor carpi ulnaris. In this deep fascia the intermuscular plane between the flexor carpi ulnaris and flexor sublimis digitorum is sought by exposure and by the sense of touch. A muscular branch will often lead to it. These muscles are retracted well apart, when the ulnar nerve is first encountered between them—and, following inward on the same plane, the artery will be found upon the flexor profundus, surrounded by the venæ comites, and with the ulnar nerve to the ulnar side.

Comment.—It is sometimes exceedingly difficult to hit off the intermuscular space and to find the artery when once in it. Remember that the anterior margin of the flexor carpi ulnaris slightly overlaps the flexor sublimis digitorum at this level. Also remember, when once in the intermuscular space, not to pass below the ulnar nerve, and thus go too deeply on the ulnar side of the forearm, but rather work inward from the level of the nerve.

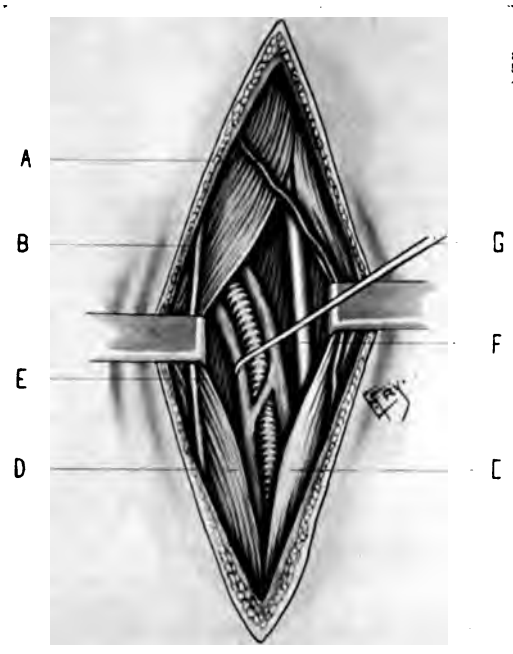

Fig. 27.—LIGATION OF RIGHT ULNAR IN UPPER PART OF MIDDLE THIRD:—A, Anterior ulnar vein; B, Anterior branch of internal cutaneous nerve; C, Flexor carpi ulnaris; D, Flexor sublimis digitorum; E, Flexor profundus digitorum; F, Ulnar nerve; G, Ulnar artery and its venæ comites (drawn to ulnar side).

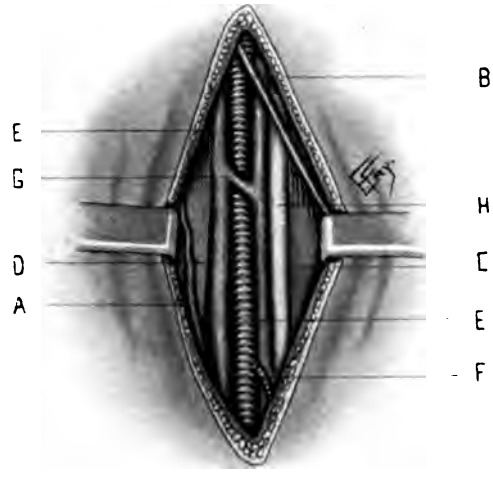

Fig. 28.—LIGATION OF LOWER THIRD OF RIGHT ULNAR (JUST ABOVE THE WRIST):—A, Anterior ulnar vein; B, Anterior branch of internal cutaneous nerve; C, Tendon of flexor carpi ulnaris; D, Tendon of flexor sublimis digitorum; E, Ulnar artery; F, Communicating branch of ulnar; G, Ulnar venæ comites; H, Ulnar nerve.

LIGATION OF ULNAR ARTERY

IN LOWER THIRD OF FOREARM.

Position.—As for radial.

Landmarks.—Outer border of flexor carpi ulnaris.

Incision.—About 5 cm. (2 inches) in length—ending about 2.5 cm. (1 inch) above the pisiform bone—and placed between the tendon of the flexor carpi ulnaris and the innermost tendon of the flexor sublimis digitorum. (As the innermost tendon of the flexor sublimis digitorum is not always recognizable, the incision is generally placed to the outer side of the tendon of the flexor carpi ulnaris.) (Fig. 23, F.)

Operation.—Having incised skin and superficial fascia, avoid the anterior ulnar vein or its branches (Fig. 28). Divide the deep fascia. Partly flex the wrist to relax the structures, and retract the flexor carpi ulnaris outward. The artery will be found upon the flexor profundus digitorum, with the venæ comites closely surrounding it, and the ulnar nerve lying closely to the ulnar side.

LIGATION OF SUPERFICIAL PALMAR ARCH OF ULNAR ARTERY.

Position.—As for the deep palmar arch.

Landmarks.—Junction of thenar and hypothenar eminences.

Incision.—Vertical—extending from junction of thenar and hypothenar eminences toward base of ring-finger, with center opposite a line crossing the palm transversely, on a level with the lower border of the outstretched thumb. The artery lies at the intersection of these two lines (Fig. 23, G).

Operation.—Divide the skin, superficial fascia, and palmar fascia, when the arch will be found in the underlying fat, lying upon the digital branches of the median and ulnar nerves (Fig. 26, H, H).

Comment.—If the arch cannot be found, ligate the artery at the pisiform bone.

SURGICAL ANATOMY OF INTERCOSTAL BRANCHES OF THORACIC AORTA.

Description.—The ten aortic intercostals generally supply from the third to eleventh intercostal spaces inclusive—the first space being supplied by superior intercostal alone—and the second space also by superior intercostal alone, or conjointly by it and the first aortic intercostal. The tenth aortic intercostal runs below the twelfth rib (subcostal artery). (**a**) The Vertebral Portions of the Intercostal Arteries, arising in pairs from the posterior part of the thoracic aorta, pass around the vertebræ—the right being covered by thoracic duct, vena azygos major, pleura, lung, esophagus—the left, by vena azygos minor, left superior intercostal vein, third vena azygos pleura, lung. The arteries here divide into posterior or dorsal, and anterior or intercostal branches. (**b**) The Intercostal Portions run forward and obliquely upward in the intercostal space to the lower border of the superior rib, and divide near the angle of the rib into upper (larger) and lower (smaller) branches—the former, to run in the groove along the lower border of the upper rib and anastomose with the superior intercostal branch of the internal mammary in the upper spaces, and of the musculophrenic in the lower—the

latter, to run along the upper border of the lower rib and anastomose with the inferior branch of the internal mammary in the upper spaces, and of the musculophrenic in the lower. At first these arteries lie between pleuræ, lungs, endothoracic fascia, and infracostals internally—and external intercostal muscles externally—then (from the angles of the ribs) between the external and internal intercostal muscles. The sympathetic nerve crosses them opposite the head of the ribs. The intercostal vein lies above and the intercostal nerve below the intercostal arteries—except in the upper spaces. The arteries of the tenth and eleventh spaces run outward between the abdominal muscles.

LIGATION OF AN INTERCOSTAL ARTERY

BY AN INTERCOSTAL INCISION.

Position.—Patient supine, and so turned as to render site of operation prominent, and chest supported below, so as to increase width of intercostal spaces. Surgeon stands on side of operation. Assistant opposite.

Landmarks.—Lower border of rib in the groove of which the special artery runs; or the upper border, in case it be the lower branch of the intercostal artery.

Incision.—About 5 cm. (2 inches), parallel with and just below the lower border of the indicated rib; or just above the upper border, as the case may be.

Operation.—Incise skin and superficial fascia. As to what muscle, and as to what amount of muscle tissue, as well as fascia, will have to be further incised in the line of the original incision, before the intercostal muscles are reached, will depend upon the site at which the artery is to be exposed. Having passed through the overlying muscle-covering of the thoracic wall, the intercostal fascia is met and incised, then the external intercostal muscle (if operating anywhere between the tubercles of the ribs behind, and the costal cartilages in front). The two cut margins of the external intercostals are then drawn upward and downward and the artery sought as it lies partially or entirely concealed in the inferior intercostal groove, with intercostal nerve below and vein above. The artery may be drawn out of its groove and down into view by the curved tip of the aneurism-needle. The vessel should be doubly ligated (its supply coming from both directions). The incised intercostal muscle and fascia may be sutured with gut in closing the wound.

Comment.—(1) If difficulty in exposing the artery be experienced, the rib may be exposed subperiosteally, as in the following operation. (2) It is to be remembered, in operating posterior to the angle of the rib, that the intercostal artery has not yet reached the inferior groove of the upper rib, but lies between the two ribs, and has not divided into its upper and lower branches. (3) If it be desired to ligate the upper and lower branches of the intercostal (anywhere between the angle and costal cartilages), the incision is made midway between the ribs, and, after retracting the cut external intercostal muscle, the upper branch is sought as above, and the lower branch is found along the upper border of the lower rib. Both are doubly ligated.

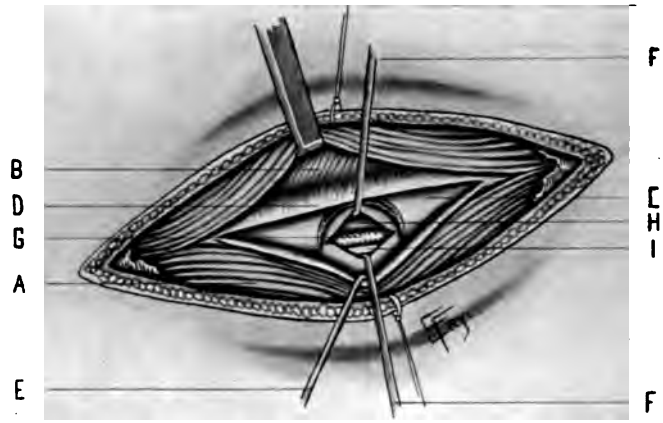

Fig. 29.—LIGATION OF LEFT INTERCOSTAL ARTERY, IN LOWER ANTERIOR THORACIC REGION, BY PARTIAL EXCISION OF A RIB:—A, Thoracic muscles; B, External intercostal muscle; C, Rib, with half-button of bone bitten out with rongeur forceps; D, Periosteum, incised over center of rib; E, Lower half of anterior layer of periosteum retracted downward; F, F, Posterior layer of periosteum incised and retracted upward and downward, showing intercostal vessels beneath; G, Intercostal artery; H, Intercostal vein; I, Intercostal nerve. (Hartley's method.)

LIGATION OF AN INTERCOSTAL ARTERY

BY PARTIAL, SUBPERIOSTEAL EXCISION OF RIB (HARTLEY'S METHOD.)

Position—Landmarks.—As in the preceding operation.

Incision.—About 6 cm. (2½ inches), parallel with and directly over center of rib.

Operation.—The above incision passes through skin, superficial fascia, any overlying thoracic muscles (according to site of operation), deep fascia and periosteum (Fig. 29). With periosteal elevator, free the lower half of the anterior surface, the inferior groove, and the lower half of the posterior surface of the rib, all subperiosteally. Then, with rongeur bone-forceps, bite out a "half-button" of bone from the bared lower half of the rib, being careful to insert the lower blade of the rongeur between the detached periosteum and the rib. After the half-button of bone is removed, the position of the artery is plainly evident—and the vessel is exposed by incising through the periosteal membrane, directly over it.

Comment.—The artery may also be exposed by the ordinary method of subperiosteal excision of about 4 cm. (1½ inches) of rib throughout its entire thickness.

SURGICAL ANATOMY OF ABDOMINAL AORTA.

Description.—Continuation of thoracic aorta. Commences at aortic opening of diaphragm, opposite lower border of twelfth dorsal vertebra—and passes down between pillars of diaphragm, in front of lumbar vertebræ, at first in median line, but deviating to left as it descends, until it lies a little to left of spine at its point of bifurcation, opposite lower border of fourth lumbar vertebra, where it divides into right and left common iliac arteries Its point of bifurcation is represented externally, roughly, by a point about 1.3 cm. (½ inch) below and a little to left of umbilicus—and, more accurately,

by a line crossing the abdomen on a level with the highest points of the iliac crests. The accompanying vena cava is separated from the aorta above by the right crus of the diaphragm, and is on a plane anterior to it. Below, the vein lies in contact with the artery, and on a somewhat posterior plane. The artery is covered only by peritoneum at the site indicated for ligation, but between the serous covering and the artery lie important sympathetic nerve-cords from the aortic plexus (lying along the aorta between the superior and inferior mesenteric arteries) to the hypogastric plexus (lying between the common iliacs).

Relations.—Anteriorly (from above downward, in order): right lobe

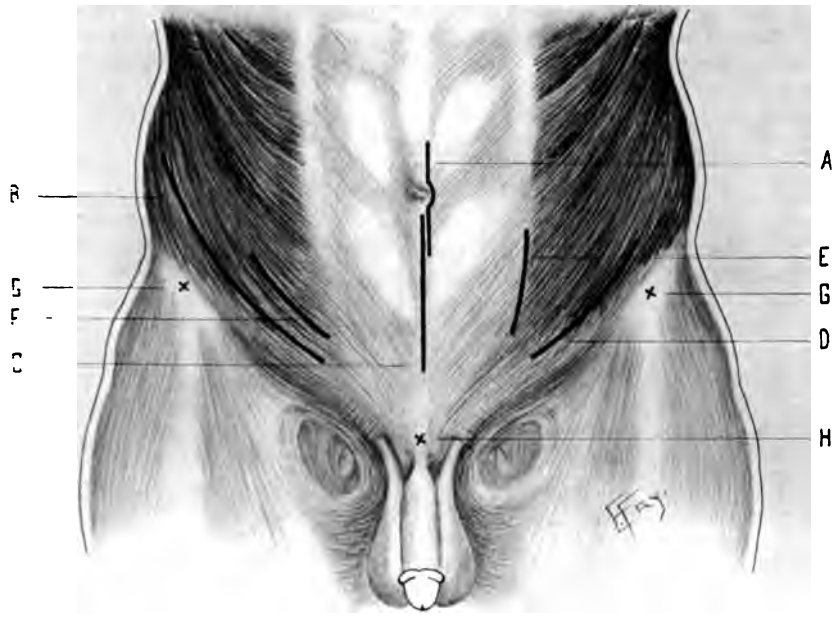

FIG. 30.—INCISIONS FOR LIGATIONS IN THE ABDOMINO-PELVIC REGION:—A, Exposure of abdominal aorta by transperitoneal route, through median incision over umbilicus; B, Exposure of internal iliac, common iliac, and abdominal aorta by retroperitoneal route, through oblique incision parallel with Poupart's ligament; C, Exposure of external, internal, and common iliacs by transperitoneal route, through median incision below umbilicus; D, of external and deep epigastric, retroperitoneally, through oblique incision parallel with Poupart's ligament; E, of common, internal, and external iliacs, transperitoneally, through vertical incision in linea semilunaris; F, of external iliac, transperitoneally, through intramuscular incision; G, G, Anterior superior iliac spines; H, Symphysis pubis.

of liver; solar plexus; lesser omentum; termination of esophagus in stomach; ascending layer of transverse mesocolon; splenic vein (or beginning of vena portæ); pancreas; left renal vein; third part of duodenum; mesentery; aortic plexus of sympathetic; spermatic (or ovarian) arteries; inferior mesenteric artery; median lumbar lymphatic glands and vessels; small intestines. **Posteriorly:** bodies of lumbar vertebræ; intervening intervertebral cartilages; anterior common ligament; left crus of diaphragm; left lumbar veins. **To right:** right crus of diaphragm; great splanchnic nerve; spigelian lobe of liver; receptaculum chyli (on a posterior plane); thoracic duct (on a posterior plane); right semilunar ganglion; inferior vena cava; vena azygos major.

To left: left crus of diaphragm; left splanchnic nerve; left semilunar ganglion; tail of pancreas; small intestines.

Branches.—(From above downward.) Phrenic, cœliac axis (gastric, hepatic, splenic); suprarenals; first lumbars, superior mesenteric; renals; spermatics (ovarians); second lumbars; inferior mesenteric; third lumbars; fourth lumbars; common iliacs; middle sacral.

Line of Artery.—From a point in the anterior median line, on a level with the lower border of twelfth dorsal vertebra, to a point a little to left of umbilicus, on a level with the highest points of the iliac crests.

Indications for Ligation.—Iliac and inguinal aneurisms and primary and secondary hemorrhage—in cases where no other means are possible. More than a dozen cases have been reported—one case living ten days.

Sites for Ligation.—Between the origin of the inferior mesenteric (between 2.5 and 5 cm., or 1 and 2 inches, above the bifurcation) and the bifurcation (Fig. 30).

LIGATION OF ABDOMINAL AORTA

BY TRANSPERITONEAL METHOD.

Description.—The abdomen is opened in the median line, the intestines displaced, and the posterior parietal peritoneum opened over the artery.

Position.—Patient supine; shoulders raised; knees slightly flexed. Surgeon on right. Assistant opposite.

Landmarks.—Median, vertical abdominal line; transverse line on level with highest points of iliac crests.

Incision.—About 10 cm. (4 inches) in length, in linea alba, with its center corresponding with the umbilicus—the incision passing slightly to left of the navel, to avoid the round ligament of the liver and the urachus (Fig. 30, A).

Operation.—The peritoneal cavity having been opened in the usual manner, the small intestines and mesentery are well retracted upward and to the sides. Guided to the artery by its known position and by its pulsation, the peritoneum covering the vessel is carefully divided between the inferior mesenteric and its bifurcation in the iliacs. The clearing of the artery should be done with especial care, as inclusion of the sympathetic nerve-fibers (see Surgical Anatomy) is otherwise apt to take place—and is supposed to have been done in one case, which quickly ended fatally. A flat ligature should be used (kangaroo tendon, chromicized gut and silk, flat and round, have been used). The needle should be of special make and shape, and should be passed from the inferior vena cava.

Comment.—This is the more desirable form of operation, though the case which survived longest was done through a posterior retroperitoneal incision.

Collateral Circulation.—Internal mammary, above; with deep epigastric, below. Inferior mesenteric, above; with internal pudic, below. Possibly by lumbar arteries, above; with branches of internal iliac, below. And, if above the inferior mesenteric, by superior mesenteric, above; with inferior mesenteric, below.

LIGATION OF ABDOMINAL AORTA

BY RETROPERITONEAL OPERATION.

Description.—The artery is here approached from the anterolateral abdominal region, the peritoneum being pushed back from the iliac vessels until the aorta is reached and exposed.

Position—Landmarks—Incision—Operation.—The operation is practically similar to that for the exposure and ligation of the common iliac extraperitoneally, the site being reached by an extension of those steps (Fig. 30, B). The patient is tilted so as to lie upon the sound side, the surgeon standing behind the patient, upon the side of the operation (the left). An extension of the incision employed for the common iliac is carried further upward to give the necessary room; and, if still required, additional room may be gotten by a second incision running parallel with the ribs, at a right angle to the main incision. The separation of the parts and exposure of the common iliac are, otherwise, the same as for the ligation of that vessel. The incision is made upon the left side—its general direction being from just within the anterior superior iliac spine toward the tip of the tenth rib—and the aorta is reached by following up the common iliac in the peeling back of the peritoneum from the iliac fascia. The vessel is thus less satisfactorily exposed than by the intra-abdominal operation, and there is greater difficulty in avoiding the sympathetic nerve-cords that surround the vessel. The ligature is placed upon the same site as in the intra-abdominal operation, and the inferior vena cava is guarded in passing the needle.

SURGICAL ANATOMY OF COMMON ILIAC ARTERIES.

Description.—Arise from bifurcation of the abdominal aorta, opposite lower border of left side of body of fourth lumbar vertebra (corresponding, approximately, to a point about 1.3 cm. [½ inch] below and a little to left of umbilicus—or, more accurately, on a level with a line passing transversely through the highest points of the iliac crests)—and pass thence downward and outward over the body of the fifth lumbar vertebra to margin of pelvis, bifurcating opposite upper border of sacro-iliac synchondrosis, into external and internal iliac arteries. The relations of right and left common iliacs differ slightly.

Relations of Right Common Iliac Artery.—**Anteriorly:** peritoneum; right ureter (a little above its bifurcation); ovaries (in female); termination of ileum; terminal branches of superior mesenteric; branches of sympathetic to hypogastric plexus. **Posteriorly:** right common iliac vein; end of left common iliac vein; beginning of inferior vena cava; and, in less immediate relationship, the following—psoas magnus; sympathetic nerve; lumbosacral cord; obturator nerve; iliolumbar artery. **Externally:** beginning of inferior vena cava; end of right common iliac vein; psoas magnus. **Internally:** right common iliac vein; end of left common iliac vein; hypogastric plexus.

Relations of Left Common Iliac Artery.—**Anteriorly:** peritoneum; small intestines; ureter; ovarian artery (in female); branches of sympathetic to hypogastric plexus; termination of inferior mesenteric artery; sigmoid flexure; sigmoid mesocolon; superior hemorrhoidal artery. **Posteriorly:** lower part of body of fourth lumbar vertebra; fifth lumbar vertebra; intervertebral discs; left common iliac vein; and, in less immediate relationship,

the following—psoas muscle; obturator nerve; lumbosacral cord; iliolumbar artery. **Externally:** psoas muscle. **Internally:** left common iliac vein; hypogastric plexus; middle sacral artery.

Branches.—Peritoneal; subperitoneal; ureteric; internal iliac; external iliac.

Line of Artery.—Draw a line transversely across the abdomen, on level with highest points of iliac crests, which will cross the abdominal aorta at its bifurcation—draw a second line transversely across the abdomen on a level with the anterior superior iliac spines, which will cross the common iliacs at their bifurcation—draw a third line from a point on the first line about 1.3 cm. (½ inch) to the left of its center (which is the linea alba), to a point midway between the anterior superior iliac spine and symphysis pubis. That portion of the third line between the two zones represents the common iliac—and that portion below the lower zone, the external iliac. The right common iliac is about 5 cm. (2 inches) in length; and the left, about 4.5 cm. (1¾ inches).

Site for Ligation.—As nearly midway of its length as possible (Fig. 30).

LIGATION OF COMMON ILIAC ARTERY

BY RETROPERITONEAL OPERATION.

Position.—Patient supine, or slightly turned to one side. The intestines are more easily displaced from the field of operation if the patient be in the Trendelenburg position. Surgeon stands upon side of operation. Assistant opposite.

Landmarks.—Line of external iliac (v. s.); Poupart's ligament; anterior superior spine of ilium; eleventh rib.

Incision.—Begun as for exposure of external iliac (page 90) and continued in the cleavage line of the external oblique as far upward toward the eleventh rib as necessary to furnish sufficient room (Fig. 30, B).

Operation.—The steps of the operation are identical with those for exposure of the external iliac (page 90), with an extension upward, in the present operation, of the separation of the fibers of the external oblique and a division of the fibers of the internal oblique and transversalis as far up toward the eleventh rib as necessary—the incision of the two latter muscles corresponding in direction with the separation of the fibers of the external oblique (Fig. 31). In this higher part of the wound the last dorsal and other dorsal nerves are apt to be encountered between the internal oblique and transversalis, and are to be carefully preserved. The deep circumflex iliac artery and the lumbar arteries are apt to be met here above the crest of the ilium. Having divided the transversalis fascia and separated the peritoneum from the iliac fascia (which overlies the iliacus muscle), detaching it downward and backward to the psoas muscle and then upward to the sacral promontory, the structures in the floor of the iliac fossa are exposed. The external iliac artery is first found, and this is followed up to the common iliac, guarding the deep epigastric. The genitocrural, external cutaneous, and anterior crural nerves, branch of the iliolumbar, and the spermatic arteries cross this area. The ureter crosses either the common iliac, or the external iliac, obliquely, opposite the first piece of the sacrum, having the ileum in front of it on the right, and the sigmoid flexure of the colon in front of it on the left; but in the peeling back of the peritoneum the ureter usually adheres to the peritoneum, and is thus removed from the area of operation

without trouble. The artery having been reached and bared of peritoneum, the needle is passed from the iliac vein.

Comment.—The line of incision may begin further to the outer side of the external iliac than for the typical operation upon that artery, though that vessel is then a little less easily encountered. As to a choice between the extraperitoneal and intraperitoneal operations, the former is to be preferred wherever the relations of the parts are not too much disturbed by disease or injury.

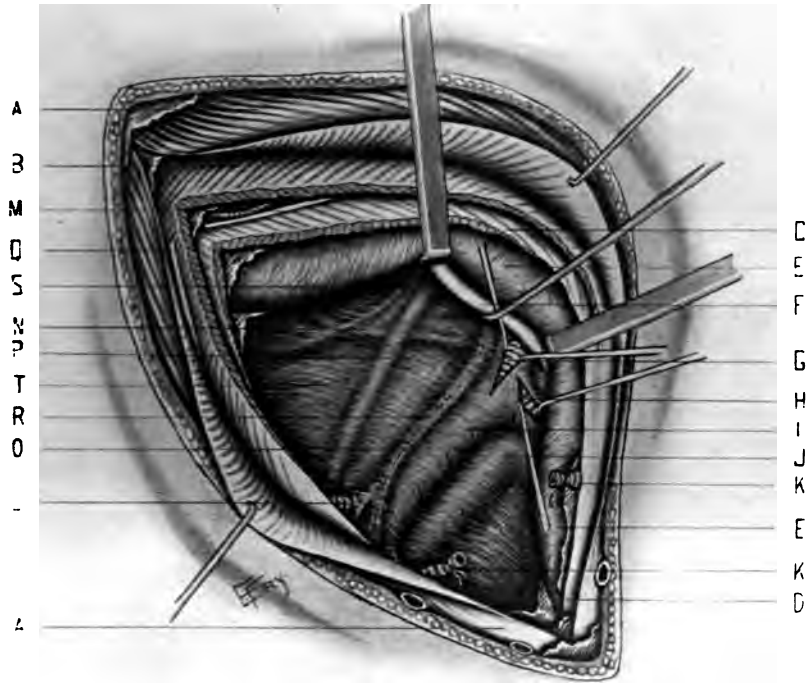

Fig. 31.—Ligation of Right Common and Internal Iliacs, Retroperitoneally:—A, A, External oblique muscle and aponeurosis; B, Internal oblique; C, Transversalis; D, Conjoint tendon; E, E, Peritoneum retracted; F, Ureter, retracted; G, Common iliac artery (sheath incised); H, Internal iliac artery (sheath incised); I, External iliac artery; J, External and internal iliac veins; K, K, Deep epigastric artery; L, Deep circumflex iliac artery; M, Lumbar artery; N, Iliolumbar artery; O, Spermatic artery; P, Anterior crural nerve; Q, Ilio-inguinal nerve; R, Genitocrural nerve; S, External cutaneous nerve; T, Iliac fascia; M, Lumbar artery and iliohypogastric (or dorsal) nerve.

Collateral Circulation.—Internal mammary and lower intercostals above, with deep epigastric below. Lumbar above, with deep circumflex iliac and iliolumbar below. Superior hemorrhoidal above, with middle and inferior hemorrhoidal below. Middle sacral above, with lateral sacral below. Pudic, epigastric, obturator and epigastric branches of one side, with corresponding arteries of other side.

LIGATION OF COMMON ILIAC ARTERY

BY TRANSPERITONEAL OPERATION.

Position—Landmarks—Incision—Operation.—The steps are practically the same as for the transperitoneal ligation of the abdominal aorta, though somewhat less extensive, and with the slight modifications necessitated by the anatomy of the parts (Fig. 30, C). Especial care is taken to recognize the position of the ureter before incising the peritoneum.

SURGICAL ANATOMY OF INTERNAL ILIAC ARTERY.

Description.—About 4 cm. (1½ inches) in length—arising from bifurcation of common iliac, opposite upper border of sacro iliac synchondrosis. Descends in pelvis to upper margin of great sacrosciatic foramen, where it divides into anterior and posterior branches.

Relations.—Anteriorly: peritoneum; ureter. **Posteriorly:** termination of external iliac vein; internal iliac vein; inner border of psoas; lumbosacral cord; obturator nerve; sacrum. **Externally:** psoas. **Internally:** internal iliac vein; peritoneum.

Branches.—From Anterior Trunk:—Hypogastric; superior, middle, and inferior vesical; middle hemorrhoidal; obturator; sciatic; internal pudic; uterine; vaginal. From Posterior Trunk:—Iliolumbar; lateral sacral; gluteal.

Line of Artery.—See under Line of Common Iliac.

Indications for Ligation.—Gluteal and sciatic aneurism; hemorrhage; to cause atrophy of prostate gland.

Sites for Ligation.—Midway between its origin and its bifurcation.

LIGATION OF INTERNAL ILIAC ARTERY

BY RETROPERITONEAL OPERATION.

Position—Landmarks—Incision—Operation.—Same as for the retroperitoneal ligation of the external iliac—which, having been exposed, is followed up to the bifurcation of the common iliac (Fig. 30, B).

Collateral Circulation.—Sciatic above, with superior branch of profunda below. Inferior mesenteric above, with hemorrhoidal arteries below. Pubic branch of obturator of one side, with same of opposite. Branches of pudic of one side, with same of opposite. Circumflex and perforating of profunda above, with sciatic and gluteal below. Middle sacral above, with lateral sacral below. Circumflex iliac above, with iliolumbar and gluteal below.

LIGATION OF INTERNAL ILIAC ARTERY

BY TRANSPERITONEAL OPERATION.

Position—Landmarks—Incision—Operation.—Same as for the transperitoneal ligation of the abdominal aorta, with the modifications necessitated by the anatomy of the parts (Fig. 30, C). Recognize the position of the ureter before incising the peritoneum.

SURGICAL ANATOMY OF OBTURATOR BRANCH OF ANTERIOR DIVISION OF INTERNAL ILIAC.

Description and Relations.—Generally arises from anterior trunk, but often from posterior trunk (and sometimes from the deep epigastric). Runs forward and downward, below brim of pelvis to upper part of obturator foramen, with obturator nerve above, and obturator vein below, lying between peritoneum and pelvic fascia—piercing the pelvic fascia to enter the canal in the upper and outer part of the obturator membrane—being crossed in its course by the vas deferens—and dividing, on its exit from the canal, into external and internal branches, which skirt the external and internal margins of the thyroid foramen.

Sites for Ligation.—At exit from thyroid foramen.

Comment.—When the obturator arises from the deep epigastric, it may pass down in contact with the external iliac vein, on the outer side of the femoral ring—or it may pass along the free margin of Gimbernat's ligament, almost encircling the neck of a hernial sac, and thus be in danger in the usual operation.

LIGATION OF OBTURATOR ARTERY

AT THYROID FORAMEN.

Position.—Patient supine; limb slightly abducted and rotated outward. Surgeon stands to right side, facing patient, on left—and between the limbs, on the right (or leans over from the left).

Landmarks.—Middle of Poupart's ligament.

Incision.—Vertical, made downward from a point about 2 cm. (¾ inch) internal to the center of Poupart's ligament.

Operation.—Divide skin, superficial fascia, and fascia lata. Draw internal saphenous vein outward. Incise fascia over pectineus just internal to femoral vein. Expose the outer border of the pectineus muscle and draw the muscle inward, separating it from the os pubis and fascia of the obturator externus—and divide the fascia over the obturator externus, exposing the muscle. Follow the upper border of the muscle to the inferior margin of the obturator foramen, to the groove for the obturator vessels and nerve—where the artery will be found emerging between the nerve above and vein below.

SURGICAL ANATOMY OF SCIATIC BRANCH OF ANTERIOR DIVISION OF INTERNAL ILIAC.

Description and Relations.—Larger of two terminal branches of anterior trunk. Descends over sacral plexus and pyriformis muscle to lower part of great sacrosciatic foramen, whence it passes out of pelvis between pyriformis and coccygeus muscles, with pudic artery anterior and internal to it. Emerging through great sciatic foramen upon buttock, beneath the gluteus maximus, it descends the thigh midway between trochanter major and tuberosity of ischium, resting upon gemellus superior, obturator internus, gemellus inferior, quadratus femoris and adductor magnus—being to inner side of great sciatic nerve and accompanied by small sciatic nerve.

Line of Artery.—Having rotated the thigh inward and slightly flexed it, draw a line from the posterior superior iliac spine to the outer border of the tuberosity of the ischium. A point on this line, at the junction of its middle and lower thirds, will represent the site at which the sciatic and pudic arteries emerge from the lower part of the sciatic foramen upon the gluteal region (Fig. 32, A, C, E).

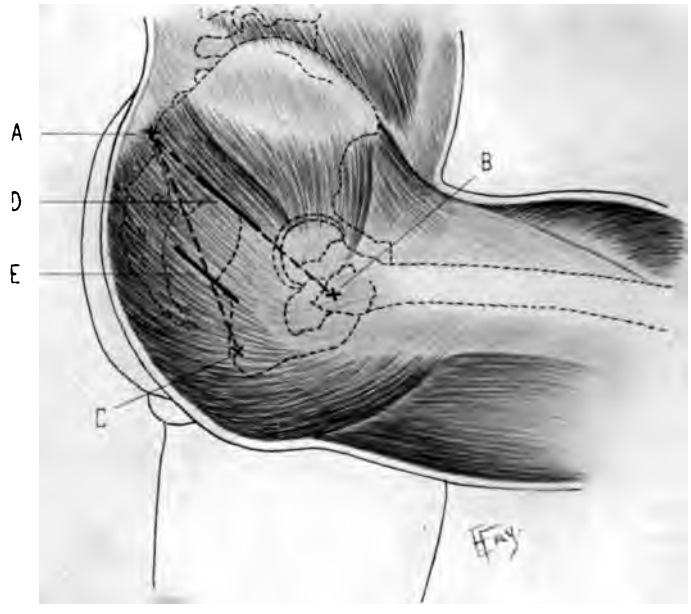

Fig. 32.—Incisions for Ligations about the Buttock:—A, Posterior superior iliac spine; B, Great trochanter; C, Tuberosity of ischium; D, Incision for exposure of gluteal branch of internal iliac at its emergence from upper part of great sacrosciatic notch; E, For exposure of sciatic and internal pudic branches of internal iliac at their emergence from lower part of great sacrosciatic notch.

Indications for Ligation.—Wounds.

Site for Ligation.—At its emergence onto the gluteal region, just below the pyriformis muscle (Fig. 32).

LIGATION OF SCIATIC BRANCH OF INTERNAL ILIAC

UPON THE BUTTOCK.

Position.—Patient upon uninvolved side, rolled nearly onto chest, with knee flexed and thigh rotated in. Surgeon on side of operation; assistant opposite.

Landmarks.—Posterior superior iliac spine; tuberosity of ischium.

Incision.—Having drawn the line given under Anatomy, make an incision about 10 cm. (4 inches) in length, obliquely across this line, in the direction of the fibers of the gluteus maximus (which run from above and behind, downward and forward)—with its center corresponding to the junction of its middle and lower thirds (Fig. 32, E).

Operation.—Having incised skin and thick fatty areolar tissue, divide

the fibers of the gluteus maximus in their cleavage line (Fig. 33, F). Retract the separated margins of this muscle upward and downward, respectively. Expose the lower margin of the pyriformis muscle. Follow the lesser sacrosciatic ligament to the spine of the ischium—when the sciatic artery will be

Fig. 33.—Ligation of Right Internal Pudic and Sciatic Arteries upon the Buttock, below the Pyriformis:—A, A, Gluteus maximus (incised and retracted); B, Pyriformis (lower border retracted upward); C, Obturator internus, with gemellus superior and inferior, above and below; D, Pudic artery and venæ comites; E, Internal pudic nerve; F, Sciatic artery and venæ comites; G, Small sciatic nerve; H, Great sciatic nerve.

found emerging from beneath the pyriformis muscle—passing out of the pelvis above the spine of the ischium, and the lesser sacrosciatic ligament attached to it—and lying posterior and external to the pudic artery.

SURGICAL ANATOMY OF INTERNAL PUDIC BRANCH OF ANTERIOR DIVISION OF INTERNAL ILIAC.

Description.—Smaller of two terminal branches of anterior trunk of internal iliac. Descends over pyriformis and sacral plexus to lower border of great sacrosciatic foramen, lying in front and to inner side of sciatic artery—passes thence out of pelvis between pyriformis and coccygeus—crosses over outer surface of spine of ischium, under gluteus maximus, and re-enters pelvis through lesser sciatic notch—passing, thence, forward over obturator internus muscle, along outer wall of ischiorectal fossa, about 4 cm. (1½ inches) above the lower margin of the tuberosity of ischium, and contained in a canal of the obturator fascia. Gradually approaching the border of the ischial ramus, it runs forward and upward—pierces posterior layer of deep perineal fascia, runs forward along inner margin of ramus of pubis, giving off artery of crus penis and artery of bulb between layers of triangular ligament—piercing anterior layer of deep perineal fascia as the dorsal artery of penis.

Relations.—(a) Within Pelvis:—descends over pyriformis muscle and sacral plexus to lower border of great sacrosciatic notch, whence it emerges between pyriformis and coccygeus muscles, together with sciatic artery, pudic nerve, greater and lesser sciatic nerves, and nerve to obturator internus

muscle. (b) Crossing Spine of Ischium:—is covered by gluteus maximus and edge of great sacrosciatic ligament. A vena comes is on either side, and the nerve to the obturator internus to the outer side and the pudic nerve to the inner side. (c) On Obturator Internus Muscle:—bound to muscle by sheath of obturator layer of pelvic fascia (Alcock's canal), with dorsal nerve of penis above and superficial perineal nerve below. (d) Between Two Layers of Triangular Ligament:—runs near to ramus of pubis, in substance of compressor urethræ muscle.

Line of Artery.—See Surgical Anatomy of Sciatic Artery.

Indications for Ligation.—Wounds.

Sites for Ligation.—Over the spine of the ischium, or in the perineum (Fig. 32).

Comment.—The main trunk of the artery is the same in both sexes.

LIGATION OF INTERNAL PUDIC BRANCH OF INTERNAL ILIAC

UPON THE BUTTOCK.

Position—Landmarks—Incision—Operation.—Same as for Ligation of Sciatic Branch of Internal Iliac upon the Buttock—the arteries lying side by side at their exit from the pelvis, below the lower border of the pyriformis (Fig. 32, E, and Fig. 33, D).

LIGATION OF INTERNAL PUDIC BRANCH OF INTERNAL ILIAC

IN THE PERINEUM.

Position.—Patient in lithotomy position. Surgeon sits facing buttock.

Landmarks.—Tuberosity and ascending ramus of ischium.

Incision.—Begins about 7.5 cm. (3 inches) above inner border of tuberosity of ischium and passes downward along the margin of the ascending ramus of the ischium.

Operation.—Divide skin and fascia, avoiding inferior pudendal nerve beneath the superficial fascia. The erector penis muscle is exposed (in the male). The transversus perinæi is either cut or drawn downward and inward. Divide the base of the triangular ligament and adjacent parietal pelvic fascia—when the artery will be found running forward above the pudic nerve, upon the inner surface of the obturator internus muscle, and above the attachment of the great sacrosciatic ligament.

SURGICAL ANATOMY OF GLUTEAL BRANCH OF POSTERIOR DIVISION OF INTERNAL ILIAC.

Description and Relations.—Largest branch of posterior division, of which it is the continuation. Passes backward and downward between first sacral nerve and lumbosacral cord—leaving pelvis through upper part of sacrosciatic notch, above pyriformis, in osseotendinous groove formed by margin of bone and pelvic fascia, accompanied by gluteal vein and superior gluteal nerve,—emerging from the pelvis under the gluteus maximus, where it divides into its branches just above the upper border of the pyriformis muscle.

Line of Artery.—Having rotated inward and slightly flexed the thigh, draw a line from the posterior superior iliac spine to the top of the great trochanter. A point on this line at the junction of the upper and middle thirds will correspond with the emergence of the gluteal artery from the sciatic notch (Fig. 32, A, B, D).

Indications for Ligation.—Wounds; aneurism.

Site for Ligation.—At emergence from sciatic notch, at upper border of pyriformis muscle (Fig. 32).

LIGATION OF GLUTEAL BRANCH OF INTERNAL ILIAC ARTERY ON THE BUTTOCK.

Position.—Patient on involved side, rolled nearly onto chest; knee flexed; thigh rotated inward. Surgeon on side of operation.

Landmarks.—Posterior superior iliac spine; top of great trochanter.

Incision.—Having drawn the line given under Surgical Anatomy, an incision about 10 cm. (4 inches) in length is drawn along this line, with its center corresponding with the junction of its upper and middle thirds, which will be over the site at which the gluteal artery leaves the sciatic notch (Fig. 32, D).

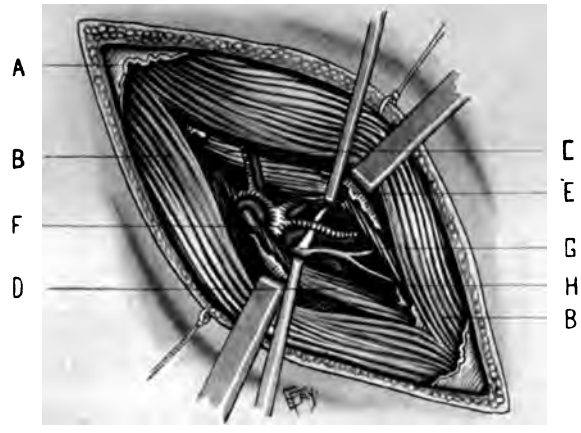

Fig. 34.—Ligation of Right Gluteal Artery upon the Buttock, above the Pyriformis:—A, Deep fascia over gluteus maximus; B, B, Gluteus maximus, incised and retracted; C, Gluteus medius (retracted upward); D, Pyriformis (retracted downward); E, Fascia between gluteus maximus and gluteus medius and pyriformis; F, Gluteal artery and venæ comites; G, Superior gluteal nerve and branches; H, Gluteus minimus.

Operation.—After dividing skin, superficial fascia, some superficial nerves, and the fascia of the gluteus maximus, the muscle itself is met, its fibers running parallel with the skin incision (Fig. 34). Incise the muscle-fibers of the gluteus maximus along their cleavage line. Having passed through the thickness of the gluteus maximus, a branch of the gluteal artery will generally lead to the interval between the gluteus medius and pyriformis (which otherwise is sought without this guide). Having divided the fascia over the lower border of the gluteus medius, separate these muscles by retractors and expose the upper margin of the sciatic notch by passing the

finger under the lower border of the gluteus medius—and through the upper portion of the sciatic notch, between the lower border of the gluteus medius and upper border of the pyriformis, emerge the gluteal artery, vein, and superior gluteal nerve.

SURGICAL ANATOMY OF EXTERNAL ILIAC ARTERY.

Description.—The larger (in the adult) branch of common iliac. About 9 to 10 cm. (3½ to 4 inches) in length. Arises at bifurcation of common iliac at sacro-iliac synchondrosis—running thence obliquely downward and outward along brim of pelvis, upon inner border of psoas muscle—passing under lower border of Poupart's ligament, midway between anterior superior iliac spine and symphysis pubis, to become femoral. The external iliac vein lies to inner side of artery below, and to inner and posterior aspect above. The deep epigastric artery arises about 6 mm. (¼ inch) above Poupart's ligament, and runs between transversalis fascia and peritoneum toward the umbilicus. The deep circumflex iliac arises below the deep epigastric, and passes behind Poupart's ligament upon the iliacus muscle. The internal abdominal ring is situated about 1.3 cm. (½ inch) above Poupart's ligament, and midway between anterior superior iliac spine and spine of os pubis, and hence just external to course of artery.

Relations.—Anteriorly: Parietal peritoneum; subperitoneal fascia; end of ileum, on right; sigmoid flexure of colon, on left; genital branch of genito-crural nerve (over its lower third); circumflex iliac vein; spermatic artery and vein; ovarian vessels (in female); vas deferens; ureter (sometimes); external iliac lymphatic vessels and glands. **Posteriorly:** External iliac vein; inner border of psoas magnus and its tendon; iliac fascia. **Internally:** External iliac vein; peritoneum; vas deferens; ovarian vessels, in female. **Externally:** Psoas magnus; iliac fascia.

Branches.—Deep epigastric; deep circumflex iliac; several branches to psoas magnus and lymphatic glands.

Line of Artery.—See Surgical Anatomy of Common Iliac.

Indications for Ligation.—Wounds; secondary hemorrhage; femoral or iliofemoral aneurisms; to arrest malignant growths; in elephantiasis arabum; as a distal ligation in aneurism of common iliac.

Sites of Ligation.—Proximal to deep epigastric and deep circumflex iliac branches (Fig. 30, D).

LIGATION OF EXTERNAL ILIAC

BY RETROPERITONEAL ROUTE.

Position.—Patient supine, near edge of table. Surgeon on side of operation.

Landmarks.—Poupart's ligament; anterior superior iliac spine; line of artery.

Incision.—Begins over external iliac artery, about 1.3 cm. (½ inch) above Poupart's ligament, and passes upward and outward parallel with the ligament, to the anterior superior iliac spine—and is prolonged upward as far as necessary, in the cleavage line of the external oblique (Fig. 30, D).

Operation.—(1) Having incised skin, superficial fascia—together with, possibly, the superficial epigastric, branches of superficial circumflex iliac,

with their veins, ligating where necessary, expose the aponeurosis of the external oblique (Fig. 35). (2) Divide this aponeurosis in its cleavage line, without cutting its fibers—and continue this division, or separation, in the cleavage line as far toward or beyond the anterior superior iliac spine as indicated to give free room for manipulation. (3) Having retracted the cut edges of the external oblique well apart, separate from the outer half of Poupart's ligament the attachment of the internal oblique. Carefully retract the cut edges of the internal oblique, being on the watch for branches of the iliohypogastric and ilio-inguinal nerves between the internal oblique and transversalis, and, if encountered, carefully displace them above or below, but avoid cutting them. If necessary to gain more room, the internal oblique is to be incised in the line of the separation of the external oblique as far as

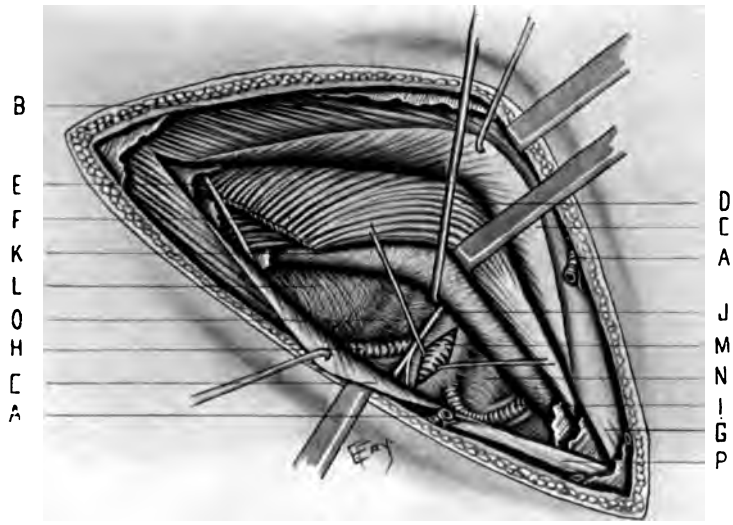

Fig. 35.—Ligation of Right External Iliac, Retroperitoneally—through Oblique Incision Parallel with Poupart's Ligament:—A, A, Superficial epigastric artery; B, External oblique muscle; C, C, G, External oblique aponeurosis; D, Internal oblique; E, Ilio-inguinal nerve; F, Transversalis muscle; H, Deep circumflex iliac artery and accompanying vein; I, Deep epigastric artery and venæ comites; J, Genitocrural nerve; K, Peritoneum (peeled back and retracted upward); L, Iliac fascia; M, External iliac artery (its sheath incised); N, External iliac vein; O, Anterior crural nerve (seen through fascia); P, Poupart's ligament.

the upper limit of the separation of the fibers of the latter muscle. (4) Having incised the internal oblique and protected the nerves encountered, detach the transversalis from the outer third of Poupart's ligament, and as far beyond as necessary, incising its fibers transversely to their direction, but in the direction of the division of the internal oblique. After dividing the transversalis, guard the deep circumflex iliac artery and vein and the genitocrural nerve, both lying between the transversalis fascia and peritoneum. (5) Having now separated the fibers of the aponeurosis of the external oblique, and divided the fibers of the internal oblique and transversalis in the same line as the separation of the external oblique aponeurosis, and having safeguarded the important nerves encountered, the fascia transversalis is then exposed and is divided over the artery in a transverse direction, corresponding

with the preceding separation and incision lines. The artery is here clearly defined, and the deep epigastric, the main source of collateral circulation, is carefully guarded. (6) As soon as the artery is clearly located, the subperitoneal tissue about the vessel is carefully opened up and the artery well exposed—as well as the deep epigastric, for the purpose of guarding it. The peritoneum is then pushed and rolled backward and upward from the vessel with the fingers and held out of the way by retractors. (7) When sufficiently exposed, the sheath of the artery is opened and the needle passed from the vein on its inner side guarding the anterior crural nerve on its outer side. The ligature should be about 3 cm. (1¼ inches) above Poupart's ligament. (8) In concluding the operation, the cut edges of the transversalis are united by buried catgut sutures to their line of severance from Poupart's ligament, and as far beyond as they may have been divided. The cut edges of the internal oblique are similarly sutured to their former attachment to Poupart's ligament, and to their opposite cut margin as far beyond as divided. And, finally, the separated margins of the external oblique are united by a buried gut suture. The skin wound is then closed.

Comment.—The incision for exposure may, if thought necessary, begin about 3 cm. (1¼ inches) to the outer side of the spine of the os pubis—being thus begun well to the inner side of the artery, as in the modified Astley Cooper operation.

Collateral Circulation.—Internal mammary, lumbar, lower intercostals, above; with deep epigastric, below. Iliolumbar, lumbar, gluteal, above; with deep circumflex iliac, below. Obturator and sciatic, above; with internal circumflex below. Sciatic, above; with superior perforating, below. Gluteal, above; with external and internal circumflex and first perforating, below. Internal pudic, above; with external pudic, below.

LIGATION OF EXTERNAL ILIAC

BY TRANSPERITONEAL ROUTE.

Position.—As in the extraperitoneal operation. Or in the Trendelenburg position.

Landmarks.—As for the extraperitoneal exposure.

Incision.—The incision may be in one of three sites: (**a**) As an intramuscular incision, placed over the site of the artery to be tied (Fig. 30, F); (**b**) vertical, in the linea semilunaris (Fig. 30, E); or (**c**) vertical, in the linea alba (Fig. 30, C).

Operation.—The steps of the operation and the manipulation to expose the site of ligation are, practically, similar to those in the transperitoneal exposure of the common iliac, or the internal iliac.

SURGICAL ANATOMY OF DEEP EPIGASTRIC BRANCH OF EXTERNAL ILIAC ARTERY.

Description and Relations.—The deep epigastric generally arises from inner side of external iliac, about 6 mm. (¼ inch) above Poupart's ligament. It descends from its origin to Poupart's ligament (thereby forming a loop over which the vas deferens in male, and round ligament in female, pass on their way to the internal ring)—thence ascends along inner border of internal abdominal ring, lying behind inguinal canal and slightly above and to outer

side of femoral ring—thence it continues upward and inward toward the umbilicus, between fascia transversalis and peritoneum, passing above and to outer side of external abdominal ring to inferior border of posterior layer of rectal sheath (semilunar fold of Douglas). Having passed beneath the fold of Douglas, it runs upward between the rectus muscle and sheath, about midway between its external and internal borders, to enter the muscle and anastomose with the superior epigastric of the internal mammary. Two venæ comites accompany the artery.

Comment.—The position of the artery between the two abdominal rings, and to the upper and outer side of the femoral ring is important.

Line of Artery.—From a point on Poupart's ligament midway between the anterior superior iliac spine and the symphysis pubis toward the umbilicus—but after this line crosses the linea semilunaris it passes upward about midway between the external and internal borders of the rectus.

Sites of Ligation.—Preferably, between 0.6 and 2.5 cm. (½ and 1 inch) from origin. It may also be ligated in the lower abdominal wall.

LIGATION OF DEEP EPIGASTRIC

NEAR ORIGIN.

Position.—As for ligation of external iliac retroperitoneally.

Landmarks.—Poupart's ligament; position of external iliac artery.

Incision—Operation.—As for ligation of external iliac retroperitoneally—that artery being first exposed—and the epigastric branch traced from it (Fig. 30, D, and Fig. 35, I).

SURGICAL ANATOMY OF FEMORAL ARTERY.

Description.—Continuation of external iliac. Begins at lower border of Poupart's ligament, midway between anterior superior iliac spine and symphysis pubis—passes down anterior and inner side of thigh to opening in adductor magnus, at junction of middle and lower thirds of thigh, through which it passes into popliteal space, becoming popliteal artery. Above, the artery lies near the antero-internal aspect of head of femur. Below, it is close to inner side of bone. Between, it is some distance from bone. In its upper third the artery passes from the center of base to apex of Scarpa's triangle. [Scarpa's triangle is bounded, externally, by sartorius; internally, by adductor longus; its base, above, being formed by Poupart's ligament; its apex, below, at junction of sartorius and adductor longus. Its floor (from without inward) is formed by iliacus, psoas, pectineus, small part of adductor brevis, and small part of adductor longus. It contains femoral artery (in its center), with its cutaneous and profunda branches; femoral vein (toward inner side), with deep femoral vein and internal saphenous branches passing from middle of base to apex; anterior crural nerve (to outer side); lymphatic glands.] In its lower third the artery passes through Hunter's canal. [Hunter's canal is an aponeurotic canal extending from apex of Scarpa's triangle to femoral opening in adductor magnus, and formed, externally, by vastus internus; postero-internally, by adductor longus and magnus; antero-internally, by aponeurosis stretching from vastus internus over femoral vessels to adductor longus and magnus, the sartorius passing over top of this aponeurosis. It contains femoral artery, femoral vein (each

in its own sheath, the vein being behind and external to artery), and long saphenous nerve (external to vessels).]

Divisions of Artery.—Common Femoral—first 4 cm. (1½ inches). Superficial Femoral—made up by remainder (about 9 cm.—3½ inches). Deep Femoral—profunda femoris branch.

Relations.—(a) **Common Femoral:**—**Anteriorly**—skin; superficial fascia; superficial inguinal glands; iliac portion of fascia lata; continuation of transversalis fasci into femoral sheath; crural branch of genitocrural nerve; superficial circumflex i iac vein; superficial epigastric vein (sometimes). **Posteriorly**—continuation of iliac fascia into femoral sheath; pubic portion of fascia lata; nerve to pectineus; psoas muscle; pectineus muscle; capsule of hip-joint. **Externally**—anterior crural nerves. **Internally**—femoral vein. (b) **Superficial Femoral Artery in Scarpa's Triangle:**—**Anteriorly**—skin; superficial fascia; crural branch of genitocrural nerve; deep fascia;

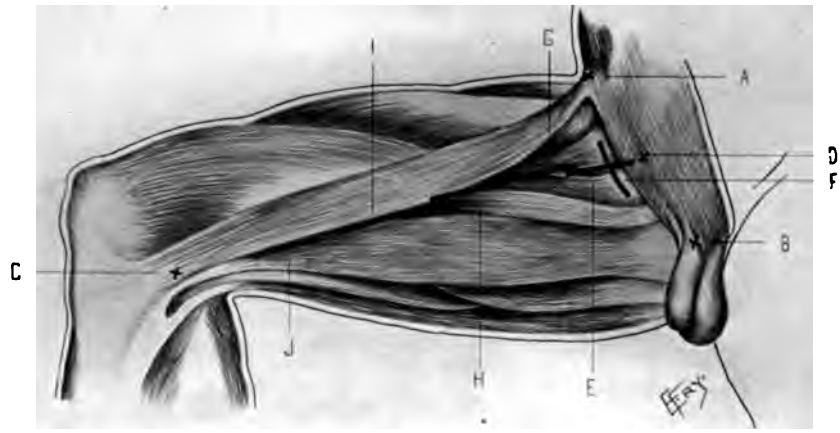

Fig. 36.—Incisions for Ligation of Chief Arteries of Thigh:—A, Anterior superior iliac spine; B, Symphysis pubis; C, Adductor tubercle; D, Mid-point between anterior superior iliac spine and symphysis pubis; E, Ligation of common femoral at base of Scarpa's triangle, by parallel incision over artery; F, Same, by incision parallel with Poupart's ligament and just below; G, Of profunda femoris, near origin; H, Of superficial femoral at apex of Scarpa's triangle; I, Of superficial femoral in Hunter's canal; J, Of popliteal in upper part of popliteal space, from inner side of thigh.

internal cutaneous nerve. **Posteriorly**—femoral vein; profunda vein; profunda artery; pectineus muscle; adductor longus. **Externally**—long saphenous nerve; nerve to vastus internus. **Internally**—femoral vein (getting behind artery at apex of Scarpa's triangle). (c) **Superficial Femoral Artery in Hunter's Canal:**—**Anteriorly**—skin; superficial fascia; deep fascia; sartorius; aponeurotic roof of Hunter's canal; internal saphenous nerve. **Posteriorly**—angle of junction of vastus internus and adductors; femoral vein (lying, in middle of Hunter's canal, behind and becoming slightly external and closely adherent to artery). **Externally**—vastus internus, femoral vein (at lower part of Hunter's canal). **Internally**—adductor longus (above); adductor magnus (below).

Branches.—From Common Femoral—superficial epigastric, superficial circumflex iliac, superficial external pudic, deep external pudic, profunda. From Superficial Femoral in Scarpa's Triangle—muscular, saphenous.

From Superficial Femoral in Hunter's Canal—muscular, anastomotica magna.

Line of Artery.—(With hip slightly flexed, thigh abducted and rotated outward.) From a point midway between anterior superior iliac spine and symphysis pubis, to adductor tubercle of internal femoral condyle (Fig. 36, D, C). (When thigh in normal position and parallel with its fellow—from midway between anterior superior iliac spine and symphysis pubis, to inner border of patella.)

Sites for Ligation.—Common femoral at base of Scarpa's triangle—rare (on account of proximity of large vessels). Superficial femoral at apex of Scarpa's triangle—operation of election. Superficial femoral in Hunter's canal—not common (Fig. 36).

Comment.—(1) A short common femoral is more frequent than a long one. (2) Apex of Scarpa's triangle is from 7.5 to 9 cm. (3 to 3½ inches) below Poupart's ligament. (3) Profunda femoris arises about 4 cm. (1½ inches) below Poupart's ligament. (4) At groin, femoral artery and vein are on same plane—at apex of Scarpa's triangle, vein is posterior—in middle of Hunter's canal, vein is posterior and slightly external—at lower part of Hunter's canal, vein is external. (5) Order of vessels at apex of Scarpa's triangle, from before backward, is femoral artery, femoral vein, profunda vein, profunda artery. (6) Line approximately representing course of long saphenous vein is one running from a point about 2 cm. (¾ inch) internal to mid-point between anterior superior iliac spine and symphysis pubis, to posterior border of sartorius muscle at femoral condyle.

LIGATION OF COMMON FEMORAL

AT BASE OF SCARPA'S TRIANGLE.

Position.—Patient supine; hip slightly flexed; thigh abducted and rotated outward; knee bent and lying upon its outer aspect. Surgeon stands on side of operated limb, cutting from above downward on the right, and vice versa.

Landmarks.—Line of artery.

Incision.—About 5 cm. (2 inches), beginning just a little above Poupart's ligament and extending downward in line of artery (Fig. 36, E).

Operation.—Incise skin and superficial fascia. Avoid lymphatic glands—also the superficial circumflex iliac, superficial epigastric, and superficial external pudic arteries and veins. Divide the iliac portion of the fascia lata (Fig. 37). Avoid the crural branch of the genitocrural nerve on the femoral sheath, a little external to the artery. Expose and open the sheath, guarding the femoral vein, which lies immediately to the inner side of the artery and within the sheath—and the anterior crural nerve lying further to the outer side of the artery and outside of the sheath. Pass the needle from the vein.

Comment.—(1) Ligation at the base of Scarpa's triangle is rarely done, owing to the nearness and number of the branches—except in such cases as wounds, and to control hemorrhage at the hip-joint, or for temporary control in operating about the thigh. Where not otherwise indicated, ligation of the external iliac is the better operation. (2) The artery may also be exposed, at this site, by an incision parallel with and about 6 mm. (½ inch) below the middle third of Poupart's ligament (Fig. 36, F).

Collateral Circulation.—Internal pudic of internal iliac; with pudic

of femoral. Gluteal; with external and internal circumflex and superior perforating. Superficial circumflex iliac; with external circumflex. Obturator; with internal circumflex. Sciatic; with superior perforating and

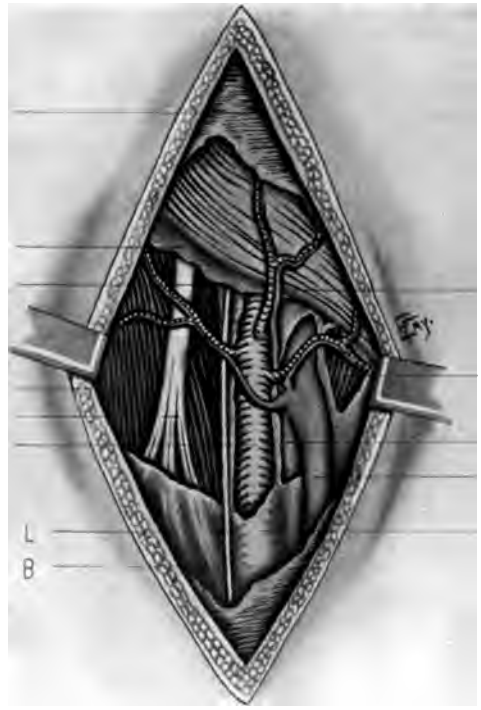

Fig. 37.—Ligation of Right Common Femoral at Base of Scarpa's Triangle :—A, Superficial fascia; B, B, Fascia lata; D, Pectineus; E, Psoas; F, Iliacus; G, Poupart's ligament and external oblique; H, Common femoral artery, with superficial epigastric, external pudic, and circumflex iliac branches; I, Femoral vein; J, Internal saphenous, with superficial epigastric, external pudic, and circumflex iliac veins; K, Anterior crural nerve; L, Crural branch of genitocrural.

internal circumflex. Comes nervi ischiadici; with all the perforating branches of profunda and articular of popliteal.

SURGICAL ANATOMY OF PROFUNDA FEMORIS BRANCH OF COMMON FEMORAL ARTERY.

Description.—Largest branch of femoral, nearly equaling main trunk. Arises from externo-posterior aspect of common femoral, about 4 cm. (1½ inches) below Poupart's ligament—passing down thigh, at first external to superficial femoral—thence posterior to femoral artery and vein to inner side of femur—thence leaves femur and runs beneath adductor longus and adductor magnus.

Relations.--**Anteriorly:** (near origin) skin; superficial fascia; deep fascia; branches of anterior crural nerve; (lower down) femoral vein; profunda vein; (still lower) adductor longus. **Posteriorly:** (in order) iliacus; pectineus; adductor brevis; adductor magnus. **Externally:** vastus internus.

Internally: pectineus; angle of junction of adductor brevis and adductor magnus.

Branches.—External circumflex; internal circumflex; three perforating.

Site of Ligation.—At origin.

LIGATION OF PROFUNDA FEMORIS

NEAR ORIGIN.

Position.—Patient supine; limb extended and parallel with fellow. Surgeon on outer side of operated limb, cutting from above downward on the right, and vice versa.

Landmarks.—Line of artery (with extended limb—see page 95); Poupart's ligament.

Incision.—About 5 or 6 cm. (2 or 2½ inches) in length, in line of artery—calculating to fall over its outer border, with the center of incision over a point in the course of the artery about 4 cm. (1½ inches) below Poupart's ligament (Fig. 36, G).

Operation.—Incise skin, superficial fascia, and fascia lata. Expose the inner edge of the sartorius and retract it outward. Beneath this muscle lies the rectus, with branches of the anterior crural nerve in close relation—these are to be drawn outward. The trunk of the common femoral will then be exposed, with the profunda coming off from its postero-external aspect, and running outward and downward, with the external circumflex arising from it and passing under the rectus. The artery is then freed and the ligature passed.

LIGATION OF SUPERFICIAL FEMORAL

AT APEX OF SCARPA'S TRIANGLE.

Position.—Same as for ligation of common femoral at base of Scarpa's triangle.

Landmarks.—Line of artery.

Incision.—About 7.5 cm. (3 inches) in length, in line of artery—with its center over apex of Scarpa's triangle, that is, about 7.5 cm. (3 inches) below Poupart's ligament (Fig. 36, H).

Operation.—Incise skin and superficial fascia. Draw aside, or ligate, branches of internal saphenous vein (Fig. 38). Divide fascia lata. Identify inner margin of sartorius (fibers running downward and inward) and retract outward. Open up the groove between the sartorius and adductor longus (fibers of latter running directly downward, or downward and outward) and retract the adductor longus internally, if necessary. The internal cutaneous nerve and long saphenous nerve are encountered anterior to the artery, and are to be displaced to one side. Clearly identify the femoral sheath and incise—guarding the femoral vein, which lies posteriorly and internally to the artery. Pass the needle from the vein.

Collateral Circulation.—External circumflex; with lower muscular branches of femoral, anastomotica magna, superior articular of popliteal, and anterior tibial recurrent. Perforating and terminating of profunda, with muscular branches of femoral and muscular and superior articular

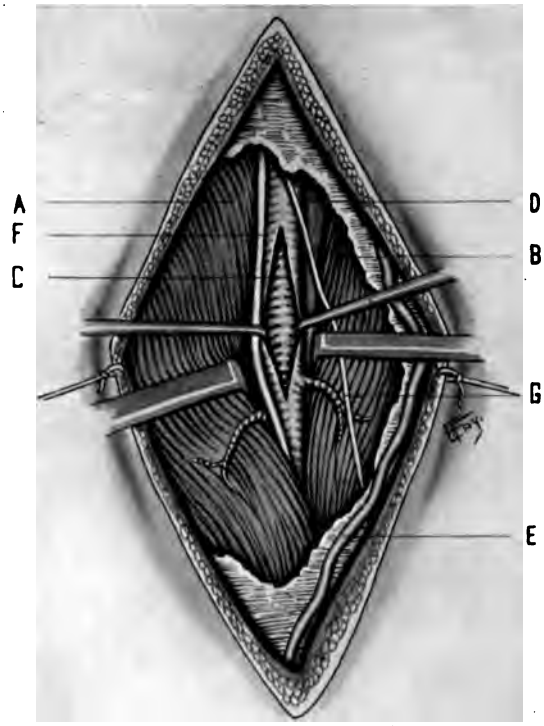

Fig. 38.—LIGATION OF RIGHT FEMORAL AT APEX OF SCARPA'S TRIANGLE:—A, Sartorius; B, Adductor longus; C, Femoral artery and muscular branches, with its sheath incised and retracted; D, Femoral vein; E, Branch of internal saphenous vein; F, Long saphenous nerve; G, Internal cutaneous nerve.

branches of popliteal. Comes nervi ischiadici; with perforating of profunda and art cular of popliteal.

LIGATION OF SUPERFICIAL FEMORAL

IN HUNTER'S CANAL.

Position.—Same as for common femoral at base of triangle.

Landmarks.—Line of artery.

Incision.—From 7.5 to 9 cm. (3 to 3½ inches), in line of artery—over middle third of thigh (Fig. 36, I).

Operation.—Incise skin and superficial fascia. The anterior branch of the internal cutaneous nerve, to the outer side, and the long saphenous vein, to the inner side, are likely to be encountered. Divide the fascia lata. Expose the outer edge of the sartorius (its fibers running downward and inward) and retract inward from its position over the roof of Hunter's canal. Hunter's canal is thereby exposed in the interval between the vastus internus and the adductor magnus (the fibers of the latter running obliquely downward and outward). The nerve to the vastus internus may be here exposed. Incise the roof of the canal, when the internal saphenous nerve is found between the aponeurotic roof and the sheath of the vessels, running from without inward. Open the sheath and pass the needle from the vein.

Comment.— Guard against taking the vastus internus for the sartorius—the fibers of the former running downward and outward.

Collateral Circulation.—Same as for the superficial femoral at the apex of Scarpa's triangle.

SURGICAL ANATOMY OF POPLITEAL ARTERY.

Description.—Continuation of femoral. Extends from aponeurotic opening in adductor magnus, at junction of middle and lower thirds of thigh, downward and outward through the popliteal space to its center behind the knee-joint —thence vertically downward to the inferior border of the popliteus muscle, opposite the lower border of the tubercle of the tibia, where it divides into anterior and posterior tibial arteries.

Relations.—Anteriorly: (from above downward) popliteal surface of femur; posterior ligament of knee; posterior articular surface of tibia; popliteus muscle. **Posteriorly:** (above) semimembranosus; (center) skin, superficial fascia, deep fascia; (below) internal head of gastrocnemius, aponeurotic arch of soleus. Popliteal vein lies behind artery throughout its course, crossing obliquely from outer to inner side, and may be double below. Internal popliteal nerve lies behind artery and vein (immediately posterior to latter), crossing the vessels obliquely at their center, from outer to inner side. **Externally:** (above) external condyle, biceps, internal popliteal nerve; (below) outer head of gastrocnemius, plantaris. **Internally:** (above) semimembranosus; (below) inner head of gastrocnemius, internal popliteal nerve.

Branches. — Cutaneous; muscular (superior muscular, inferior muscular or sural); articular (superior external articular, superior internal articular, inferior external articular, inferior internal articular, azygos articular); terminal (posterior tibial, anterior tibial).

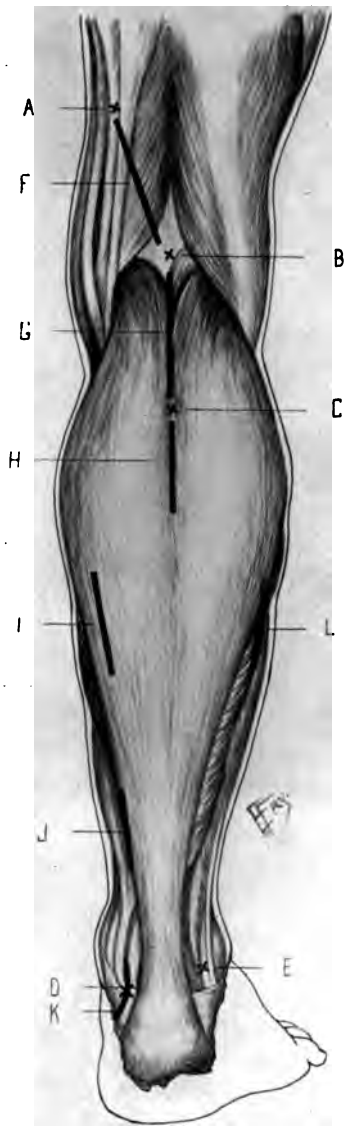

Fig. 39.—Ligation of Popliteal, Posterior Tibial, and Peroneal Arteries:—A, Outer border of semimembranosus (at junction of middle and lower thirds of thigh); B, Middle of popliteal space; C, Center of posterior aspect of leg on level with tibial tubercle; D, Point midway between convexity of heel and tip of internal malleolus; E, Mid-point between outer border of tendo Achillis and tip of external malleolus; F, Incision for popliteal artery in upper part of popliteal space, from behind; G, Same, in lower part of popliteal space; H, Of posterior tibial in its upper third; I, Same, in its middle third; J, Same, in its lower third; K, Same, behind internal malleolus; L, Incision for peroneal in middle of leg.

Line of Artery.—From outer border of semimembranosus (at junction of middle and lower thirds of thigh) obliquely down to middle of popliteal space, directly posterior to the knee-joint (for upper part of artery); and from mid-point of popliteal space vertically down to level of lower border of tubercle of tibia (for lower part of artery). (Fig. 39, A, B, C.)

Sites of Ligation.—May be ligated either in its upper part or lower part—the artery being tied with difficulty in its middle, owing to its depth and relations (Figs. 36 and 39).

Indications for Ligation.—Rare, other than wounds and aneurism—the superficial femoral usually being ligated instead.

LIGATION OF POPLITEAL ARTERY IN UPPER PART OF POPLITEAL SPACE

FROM BEHIND.

Position.—Patient as nearly prone as feasible, resting on side of shoulder and chest, with limb extended. Surgeon to outer side of left limb, cutting downward; and to outer side of right limb, cutting upward (or inside of right limb, cutting downward).

Landmarks.—Line of artery and upper boundaries of popliteal space.

Incision.—About 9 cm. (3½ inches) in length, in line of artery, beginning at outer border of semimembranosus, at junction of middle and lower thirds of thigh, and passing obliquely downward to the middle of the popliteal space (Fig. 39, F).

Operation.—Incise skin and superficial fascia. Avoid the small sciatic nerve. Open up the deep fascia. Retract the hamstring muscles to the outer and inner sides. The popliteal nerve is first encountered crossing from the outer to the inner side—the popliteal vein crossing similarly. Displace these structures laterally—when the artery is found, generally lying in fatty areolar tissue.

Collateral Circulation.—Where the ligation is between the superior and inferior articular arteries;—anastomotica magna, superior external and internal articular, descending branch of external circumflex, above; with inferior external and internal articular and anterior tibial recurrent (also, possibly, posterior tibial recurrent and superior fibular of anterior recurrent), below.

LIGATION OF POPLITEAL ARTERY IN UPPER PART OF POPLITEAL SPACE

FROM INNER SIDE OF THIGH—JOBERT'S OPERATION.

Position.—Patient supine; thigh slightly flexed; fully abducted and rotated outward; knee at a right angle and resting on external aspect. Surgeon on outside, cutting downward on right, upward on left (or may stand on inner side of right and cut downward).

Landmarks.—Tendon of adductor magnus.

Incision.—About 7.5 cm. (3 inches) in length, beginning opposite the junction of middle and lower thirds of thigh, and running parallel with and immediately posterior to the tendon of the adductor magnus (which is inserted into the adductor tubercle on the internal condyle of the femur). (Fig. 36, J.)

Operation.—Incise skin and superficial fascia. Avoid anterior branch of internal cutaneous nerve (Fig. 40). Divide deep fascia. Expose the

anterior edge of the sartorius and retract it backward, together with the internal saphenous vein, if in view (the internal saphenous nerve being beneath the sartorius, out of view). Having thoroughly divided the deep fascia, the adductor magnus tendon is identified and drawn forward—then the semi-

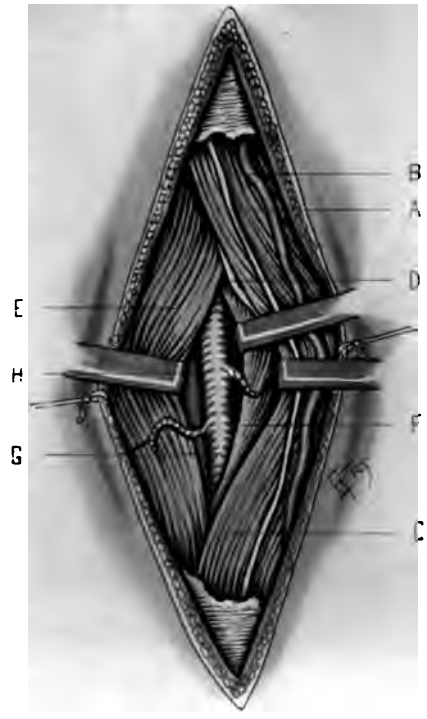

Fig. 40.—Ligation of Upper Part of Right Popliteal from Inner Side of Thigh:—A, Anterior branch of internal cutaneous nerve; B, Internal saphenous vein; C, Sartorius (its anterior border retracted posteriorly); D, Internal saphenous nerve (mainly under sartorius, out of sight); E, Adductor magnus (drawn anteriorly); F, Semimembranosus (drawn posteriorly); G, Popliteal artery; H, Popliteal vein (below and external to artery).

membranosus is identified and drawn backward—and the artery is then sought between these two structures, near the bone and in considerable fatty areolar tissue. Both popliteal vein and nerve lie on a plane posterior to the artery, and are generally not brought to view.

LIGATION OF POPLITEAL ARTERY IN LOWER PART OF POPLITEAL SPACE

BY POSTERIOR MEDIAN INCISION.

Position.—As for ligation in the upper part of the space.

Landmarks.—Boundaries of the popliteal space (the biceps above, and the plantaris and outer head of gastrocnemius below, forming the outer boundary;—and the semimembranosus and semitendinosus above, and the inner head of the gastrocnemius below, forming the inner boundary).

Incision.—About 9 cm. (3½ inches) in length, beginning at the middle of the popliteal space (on a level with the knee-joint) and passing downward between the two heads of the gastrocnemius (Fig. 39, G).

Operation.—Incise skin and superficial fascia. Avoid the external saphenous vein and external saphenous nerve in the outer aspect of the wound, or the communicans poplitei nerve which helps form the external saphenous nerve (Fig. 41). Divide the deep fascia. Expose the inner and outer heads of the gastrocnemius, with the sural arteries going to them—and retract these and the plantaris muscle to their respective sides. Muscular branches of the internal popliteal nerve may be met with here, and maybe

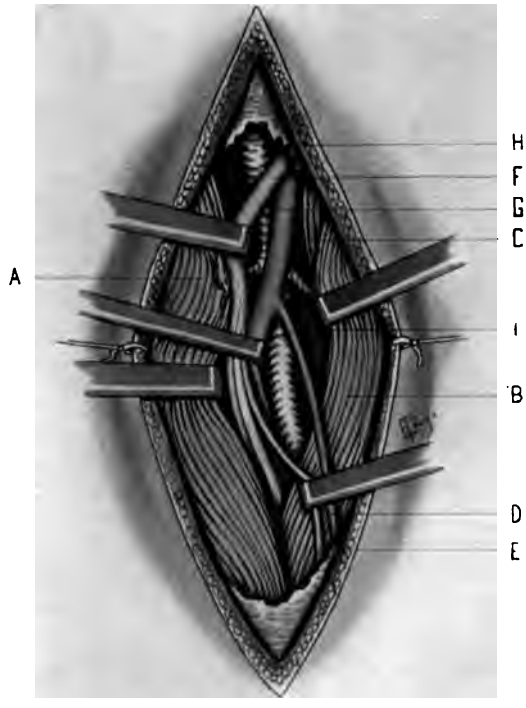

Fig. 41.—Ligation of Right Popliteal at Lower Part of Popliteal Space:—A, Inner head of gastrocnemius (retracted inward); B, Outer head of gastrocnemius (drawn outward); C, Plantaris; D, External saphenous vein; E, Communicans poplitei nerve; F, Internal popliteal nerve (drawn inward); G, Popliteal vein (drawn inward); H, Popliteal artery and muscular branches; I, Popliteus muscle

the posterior tibial nerve. The external saphenous vein is the guide to the popliteal vessels. The internal popliteal nerve is found most superficial of the three important structures—the popliteal vein next (both crossing to the inner side, toward which side they are further retracted)—and the artery deepest of all, near the bone and in much fatty areolar tissue. The needle is passed from the side of the vein, flexure of the knee aiding during this stage.

Comment.—A continuation upward of the above incision would amount to ligation of the popliteal artery in the middle of the popliteal space.

Collateral Circulation.—If the artery be ligated between the superior and inferior articular branches, the collateral anastomosis would be the same as after the above operation.

SURGICAL ANATOMY OF ANTERIOR TIBIAL ARTERY.

Description.—The smaller bifurcation of popliteal artery, at lower border of popliteus muscle, passing thence forward between the two heads of tibialis posticus, through aperture in upper part of interosseous membrane, between tibia and fibula, to deep part of front of leg—descending, at first, on anterior surface of interosseous membrane, then on the tibia, and finally onto front of ankle-joint, beneath anterior annular ligament, where it becomes dorsalis pedis. It is accompanied by two venæ comites. The anterior tibial nerve accompanies its lower three-fourths, lying upon its fibular side, though partly overlapping it in middle of leg.

Relations. — Anteriorly: skin, superficial fascia; deep fascia; anterior tibial nerve (at middle); tibialis anticus (above); extensor longus digitorum (above); extensor proprius pollicis (below); anterior annular ligament (below). **Posteriorly:** interosseous membrane (upper two-thirds); tibia and ankle-joint (lower one-third). **Externally:** anterior tibial nerve (above and below); extensor longus digitorum (upper third); extensor proprius pollicis (middle third). **Internally:** tibialis anticus (upper two-thirds); extensor proprius pollicis (crosses lower part of artery).

Branches.—Posterior tibial recurrent, superior fibular (sometimes), anterior tibial recurrent, muscular, internal malleolar, external malleolar.

Line of Artery.—From inner side of head of fibula, to center of line between the malleoli—(according to Kocher, from midway between external surface of head of fibula and center of tubercle of tibia, to the same point below). The artery passes

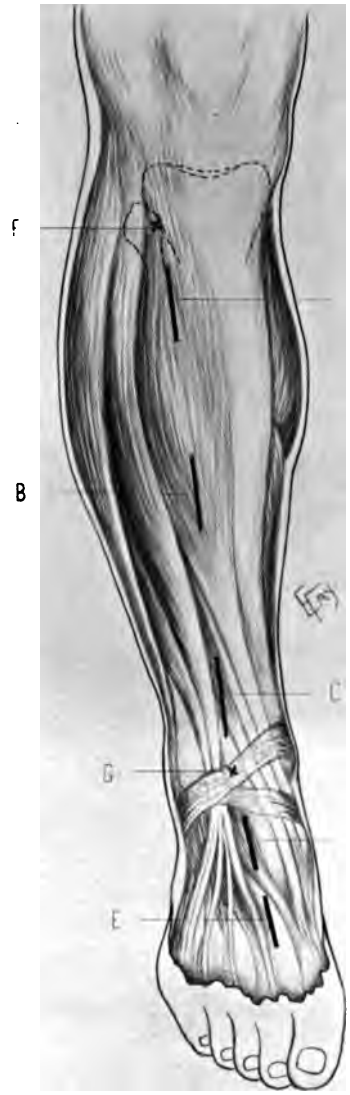

Fig. 42.—Incisions for Ligation of Anterior Tibial and Dorsalis Pedis Arteries:—A, Incision for upper third of anterior tibial; B, For middle third of anterior tibial; C, For lower third of anterior tibial; D, For dorsalis pedis just below ankle-joint; E, For dorsalis pedis in first interosseous space; F, Inner side of head of fibula; G, Mid-point between two malleoli.

through the interosseous membrane about 3 cm. (1¼ inches) below the level of the head of the fibula.

Indications for Ligation.—Wounds (of anterior tibial or in foot); aneurism.

Sites of Ligation.—Upper and middle thirds—rarely, except in wounds. Lower third—most frequent site (Fig. 42).

LIGATION OF ANTERIOR TIBIAL

IN ITS UPPER THIRD.

Position.—Patient supine; leg extended and rotated inward. Surgeon on outer side (cutting from above downward, on the right—and vice versa).

Landmarks.—Line of artery.

Incision.—About 7.5 cm. (3 inches) in length, in line of artery—beginning about 2.5 cm. (1 inch) below head of fibula (Fig. 42, A).

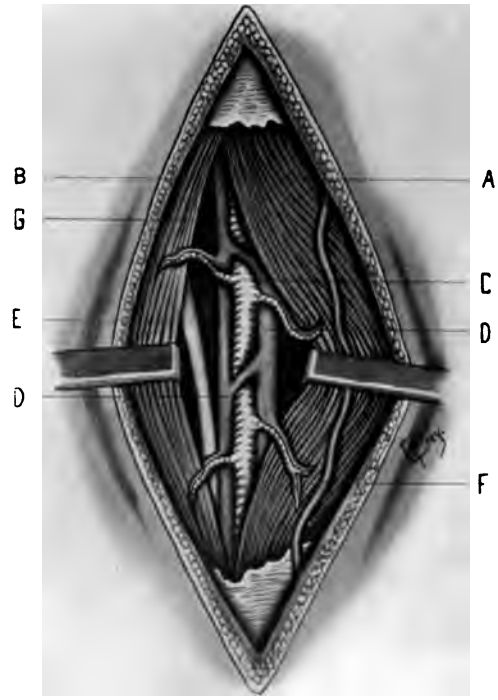

Fig. 43.—Ligation of Upper Third of Right Anterior Tibial:—A, Tibialis anticus muscle; B, Extensor communis digitorum; C, Anterior tibial artery and branches. D, D, Anterior tibial venæ comites; E, Anterior tibial nerve; F, Branch of internal saphenous vein; G, Interosseous membrane.

Operation.—Incise skin, superficial fascia, and deep fascia. Define the gap between tibialis anticus, internally, and extensor longus digitorum, externally, and retract these structures to their respective sides (Fig. 43). Open up this interval—flexing the foot to relax the parts. Aim to reach the external aspect of the tibia, covered by the tibialis anticus, and, when reached,

follow down to the interosseous membrane, upon which the artery will be found. Two venæ comites lie in very close contact, in front of and behind the artery. The anterior tibial nerve may not yet have reached the outer side of the artery. If the venæ comites be not separable, include them in the ligature.

Comment.—The interval between the tibialis anticus and extensor longus digitorum is the key to the situation, and is rather hard to find. The outer edge of the tibialis anticus often overlaps the extensor longus digitorum. And also one may get into the septum between the extensor longus digitorum and peroneus longus and work down toward the fibula. Guides to the proper intermuscular gap, accessory to the sensation of touch, are the "white line" (sometimes visible) and a small artery leading to the anterior tibial.

LIGATION OF ANTERIOR TIBIAL

IN ITS MIDDLE THIRD.

Position—Landmarks.—As for ligation of the upper third.

Incision.—About 7.5 cm. (3 inches) in length, in line of artery, with its center over the center of the leg (Fig. 42, B).

Operation.—Incise skin, superficial and deep fascia. Recognize the interval between the tibialis anticus (its outer edge still muscular) internally—and the extensor longus digitorum (its inner edge tendinous) externally. A yellow fatty line may sometimes indicate the interval. Open up this interval, flexing the foot. Retract these muscles to their own sides—and, deeper in the wound, a'so retract the extensor proprius pollicis to the outer side. Follow down the gap toward the tibia (and not the gap between the extensor longus digitorum and extensor proprius pollicis). The anterior tibial nerve will be found slightly overlapping the artery—draw it outward. The artery will be found on the interosseous membrane, under cover of the muscular fibers of the tibialis anticus, with the extensor proprius pollicis on its outer side. The venæ comites are separated with difficulty, and, if so, may be included in the ligature.

LIGATION OF ANTERIOR TIBIAL

IN ITS LOWER THIRD.

Position.—As for ligation of the upper third—without the inward rotation of the foot.

Landmarks.—Line of artery.

Incision.—From 5 to 7.5 cm. (2 to 3 inches) in length, with center over center of lower third of leg (Fig. 42, C).

Operation.—Incise skin and fascia. Clearly identify tendon of tibialis anticus. Divide the upper part of the superior band of the anterior annular ligament in the line of the wound (Fig. 44). Demonstrate the interval between the tendon of the tibialis anticus and tendon of the extensor proprius pollicis—flexing the foot and retracting these tendons to their own sides. The anterior tibial artery will be found between them, lying upon the anterior aspect of the tibia and held down by fatty areolar tissue—accompanied by two venæ comites, and with the anterior tibial nerve on the outer side. Pass the needle from the nerve. In closing the wound, suture the anterior annular ligament.

Comment.—If the artery were ligated after passing beneath the obliquely crossing extensor proprius pollicis, it would then have the tendon of the extensor proprius pollicis to its inner side and the innermost tendon of the extensor longus digitorum to its outer side.

Collateral Circulation.—(When ligated below the malleolar branches.) External malleolar of anterior tibial, with anterior peroneal of peroneal and

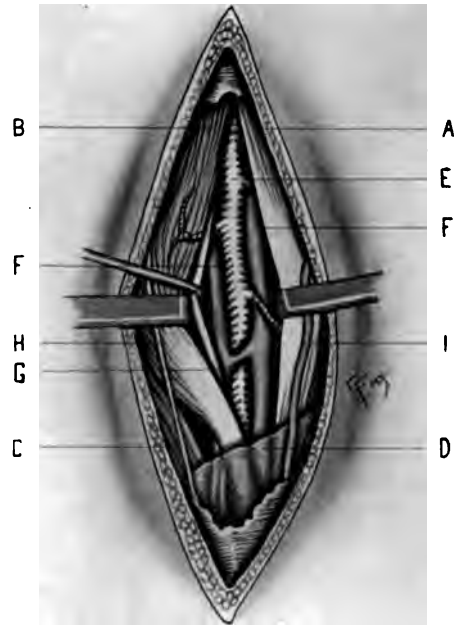

Fig. 44.—Ligation of Lower Third of Right Anterior Tibial:—A, Tendon of tibialis anticus, retracted inward; B, Extensor proprius hallucis, retracted outward; C, Extensor longus digitorum; D, Annular ligament; E, Anterior tibial artery and branches; F, F, Anterior tibial venæ comites; G, Anterior tibial nerve; H, Branch of musculocutaneous nerve (inner branch); I, Branch of internal saphenous vein.

with calcaneal of posterior peroneal. Internal malleolar of anterior tibial, with internal malleolar of posterior tibial. Dorsalis pedis and branches, with internal plantar of posterior tibial, with external plantar of posterior tibial, with anterior peroneal of peroneal, and with calcaneal of posterior peroneal. Muscular branches of anterior tibial anastomosing through the interosseous membrane with muscular branches of posterior tibial.

SURGICAL ANATOMY OF DORSALIS PEDIS (OF ANTERIOR TIBIAL).

Description.—Continuation of anterior tibial—extending from bend of ankle along tibial side of foot to apex of first intermetatarsal space—passing into sole (as communicating artery) between two heads of first dorsal interosseous. The anterior tibial nerve lies upon its outer side. The artery is accompanied by two venæ comites.

Relations.—Anteriorly: Skin, superficial fascia; deep fascia; anterior

annular ligament; extensor longus pollicis; innermost tendon of extensor brevis digitorum. **Posteriorly:** (from above downward) Astragalus; scaphoid; internal cuneiform; ligament of first and second metacarpals. **Externally:** Innermost tendon of extensor longus digitorum (above); innermost tendon of extensor brevis digitorum (below); anterior tibial nerve. **Internally:** Extensor longus pollicis.

Branches.—Tarsal; metatarsal; dorsalis hallucis; communicating (plantar digital).

Line of Artery.—From center of line connecting two malleoli, to proximal end of first metatarsal space.

Indications for Ligation.—Rare—wounds, aneurism.

Sites of Ligation.—At ankle-joint (involves cutting anterior annular ligament); below ankle-joint (general site); at first interosseous space (Fig. 42).

LIGATION OF DORSALIS PEDIS

JUST BELOW ANKLE-JOINT.

Position.—Patient supine; foot resting on heel and extended. Surgeon below foot, on either side (or on outer side of both limbs, cutting downward on right, and upward on left). Assistant steadies foot.

Landmarks.—Line of artery.

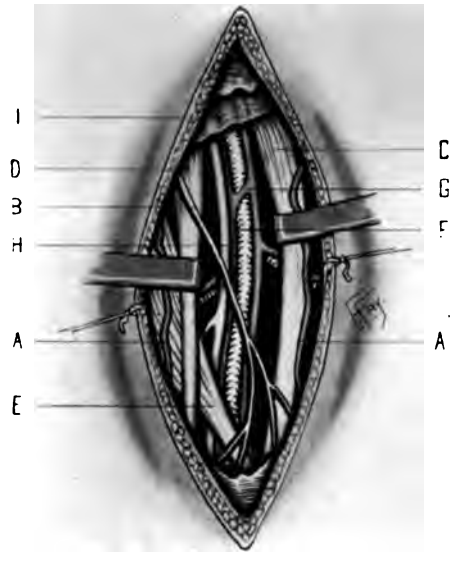

Fig. 45.—Ligation of Right Dorsalis Pedis Just below Ankle-joint:—A, A, Branches of internal saphenous vein; B, Internal branch of musculocutaneous nerve and its divisions; C, Tendon of extensor proprius hallucis; D, Inner tendon of flexor longus digitorum; E, Inner tendon of extensor brevis digitorum; F, Dorsalis pedis artery; G, Venæ comites of dorsalis pedis artery; H, Anterior tibial nerve; I, Annular ligament.

Incision.—From 2.5 to 5 cm. (1 to 2 in.), in line of artery, passing from lower border of anterior annular ligament—between tendon of extensor pollicis and inner tendon of extensor longus digitorum (Fig. 42, D).

Operation.—Incise skin and superficial fascia. Tributaries of internal saphenous vein and the internal branch of the musculocutaneous nerve lie in the line of incision (Fig. 45). Open up the deep fascia between the tendon of the extensor proprius pollicis and innermost tendon of flexor longus digitorum —when the artery will be found upon the tarsal ligaments. The anterior tibial nerve lies upon its fibular side—two venæ comites accompanying the artery. Avoid opening the tendon sheaths.

Comment.—When the artery is tied at the base of the first interosseous space, an incision is made from the apex of the first interosseous space, passing down between the first and second metatarsals. The artery is found emerging from under the innermost tendon of the extensor brevis digitorum, which is retracted inward.

SURGICAL ANATOMY OF POSTERIOR TIBIAL ARTERY.

Description.—Larger and more direct division of popliteal artery—extending from lower border of popliteus muscle (on level with lower border of tubercle of tibia), down tibial side of back of leg, between superficial and deep muscles, to middle of fossa between tip of internal malleolus and os calcis—and dividing, under abductor hallucis, into internal and external plantar branches. It arises midway between tibia and fibula, covered by the superficial muscles—lower down it lies behind the tibia—and at its lower third it is covered by only skin and fascia, and then passes beneath the internal annular ligament. It is accompanied by two venæ comites. The posterior tibial nerve crosses the artery, from the inner to outer side, about 2.5 to 4 cm. (1 to 1½ inches) below inferior border of popliteus, and runs thence along its fibular aspect.

Relations.—**Anteriorly:** (From above downward) tibialis posticus; flexor longus digitorum; tibia; internal lateral ligament of ankle-joint. **Posteriorly:** Skin; superficial fascia; gastrocnemius; soleus; deep intermuscular (transverse) fascia binding artery to underlying muscles; posterior tibial nerve (crossing from inner to outer side above, and then running along fibular side). In lower third, covered only by skin and fascia. **Externally:** Posterior tibial nerve (lower three-fourths); vena comes. **Internally:** Posterior tibial nerve (upper one-fourth); vena comes. **At Ankle-joint:** Posterior tibial artery lies under internal annular ligament and abductor hallucis—resting upon internal lateral ligament of ankle—having tibialis posticus and flexor longus digitorum in front—and posterior tibial nerve and flexor longus hallucis behind and externally.

Branches.—Peroneal, muscular, medullary, cutaneous, communicating, internal malleolar, internal calcaneal, external plantar, internal plantar.

Line of Artery.—Lower half—line from a point 5 cm. (2 inches) below center of popliteal space, to midway between tip of internal malleolus and center of convexity of heel. Upper half—forms a slight curve inward from this line.

Indications for Ligation.—Wounds; aneurisms.

Sites of Ligation.—Upper third—not infrequent—difficult because of depth. Middle third—same. Lower third—most usual site. Behind ankle—also common (Fig. 39, K).

LIGATION OF POSTERIOR TIBIAL

IN ITS UPPER THIRD—ABOVE ORIGIN OF PERONEAL BRANCH.

Position.—As for ligation of lower part of popliteal artery (page 101).

Landmarks.—Popliteal boundaries (page 101); head of fibula.

Incision.—Begins in popliteal space, on level with head of fibula, and passes directly down the middle line for about 7.5 cm. (3 inches) (Fig. 39, H).

Operation.—Incise skin, superficial fascia, avoiding external saphenous vein and nerve. Divide deep fascia, exposing two heads of gastrocnemius. Incise their connecting raphé freely and separate them fully, avoiding their nerves and vessels as much as possible. Expose the upper border of the soleus beneath the external head of the gastrocnemius. Retract the plantaris (found between the outer head of the gastrocnemius and soleus). The lower border of the popliteus, opposite which the posterior tibial nerve begins, about corresponds with the upper border of the soleus—so that after retracting the internal popliteal nerve and vein to the inner side, draw the upper border of the soleus downward (or nick its upper border) and thus expose the bifurcation of the popliteal artery into anterior tibial (passing through the interosseous membrane) and posterior tibial (descending on the deep muscles). Pass the needle between the anterior tibial and peroneal branches.

Collateral Circulation.—(When ligated between the bifurcation and origin of the peroneal.) Peroneal of posterior tibial, with communicating and muscular branches of the posterior tibial; external calcaneal of peroneal, with internal calcaneal of external plantar; external malleolar of anterior tibial, with external plantar; internal malleolar of anterior tibial, with internal malleolar of posterior tibial; dorsalis pedis and branches, with internal and external plantar.

LIGATION OF POSTERIOR TIBIAL

IN ITS MIDDLE THIRD.

Position.—Patient supine; knee flexed; leg on outer side. Surgeon to outer side, cutting downward on right, and upward on left.

Landmarks.—Inner margin of tibia.

Incision.—From 7.5 cm. to 10 cm. (3 to 4 inches) in length, placed parallel with and 2 cm. (¾ inch) behind the inner margin of the tibia, along its middle third (Fig. 39, I).

Operation.—Incise skin and superficial fascia. Avoid internal saphenous vein and internal saphenous nerve (Fig. 46). Divide the deep fascia. The inner edge of the gastrocnemius should be identified here—and retracted outward. Having gone through the deep fascia, the soleus is exposed, and is to be divided along its attachment to the tibia, and its outer part retracted. The transverse intermuscular fascia (between superficial and deep muscles of back of leg) is now in view, and is incised in the axis of the limb, whereby the flexor longus digitorum is reached—and, by following along the surface of this muscle until nearly opposite the outer border of the tibia, the vena comes interna, posterior tibial artery, vena comes externa, and posterior tibial nerve are met in order, lying upon the tibialis posticus, or between it and the flexor longus digitorum. Pass the needle from the nerve, including the venæ comites if unavoidable—flexing the knee and foot to relax the structures.

Comment.—The knife should be held at a right angle to the surface of the muscle, in cutting through the soleus, pointing toward the tibia until the transverse fascia is reached—and thereby wandering too deeply, or in the wrong direction, is less likely. If one incise too near the tibia, the flexor

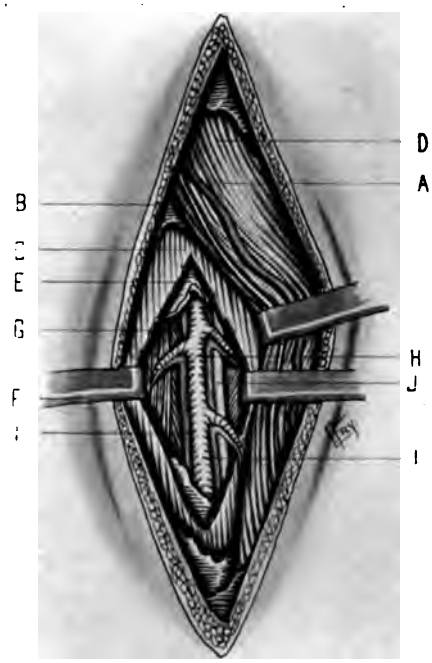

Fig. 46.—LIGATION OF MIDDLE THIRD OF RIGHT POSTERIOR TIBIAL:—A, Internal saphenous vein; B, Internal saphenous nerve; C, Soleus, incised vertically, and margins of incision well retracted; D, Inner head of gastrocnemius strongly retracted outward; E, Transverse intermuscular fascia; F, Flexor longus digitorum; G, Tibialis posticus; H, Posterior tibial artery; I, I, Posterior tibial venæ comites; J, Posterior tibial nerve.

longus digitorum may be divided and the interosseous membrane reached. While incising the soleus, do not mistake its central membranous tendon for the transverse intermuscular fascia. The artery lies about 3 cm. (1¼ inches) external to the inner border of the tibia.

LIGATION OF POSTERIOR TIBIAL

IN ITS LOWER THIRD.

Position.—As for the middle third.

Landmarks.—Line of artery.

Incision.—About 5 cm. (2 inches) in length, in line of artery, with its center over the lower third of the leg—which should fall midway between the inner border of the tendo Achillis and the inner border of the tibia (Fig. 39, J).

Operation.—Incise skin and superficial fascia. Divide the deep fascia binding down the flexor tendons—when the artery will be found lying between the flexor longus digitorum and flexor longus pollicis—the posterior

tibial nerve lying to its fibular side, with the venæ comites surrounding the artery.

Comment.—If the incision be at the upper part of the lower third of the artery, the vessel will be found upon the flexor longus digitorum. If the incision be at the lower part of the lower third, the upper part of the internal annular ligament must be cut.

LIGATION OF POSTERIOR TIBIAL

BEHIND INTERNAL MALLEOLUS.

Position.—As for ligation of the lower third.

Landmarks.—Internal malleolus.

Incision.—About 5 cm. (2 inches) in length, placed about 1.3 cm. (½ inch) posterior to and parallel with the inner malleolus (Fig. 39, K).

Operation.—Incise skin and superficial fascia—during which branches of the internal saphenous vein are encountered (Fig. 47). Expose the internal annular ligament and divide it over the vessels—the artery being found

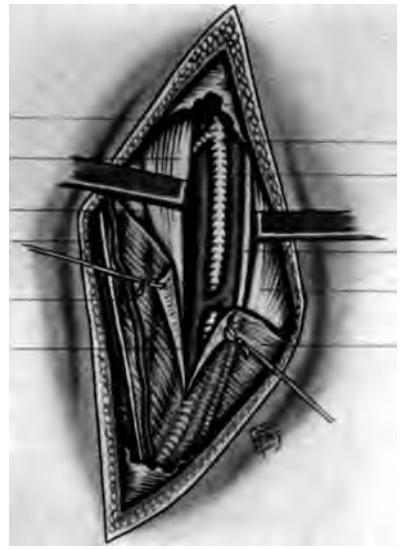

Fig. 47.—Ligation of Right Posterior Tibial behind Internal Malleolus:—A, Branch of internal saphenous vein; B, Branch of internal saphenous nerve; C, Internal annular ligament (incised); D, Tendon of flexor longus hallucis; E, Tendon of flexor longus digitorum; F, Tendon of tibialis posticus; G, Posterior tibial artery; H, H, Posterior tibial venæ comites; I, Posterior tibial nerve.

in the interval between the flexor longus digitorum and flexor longus hallucis, surrounded by its venæ comites and with the nerve upon its fibular side.

Comment.—Keep the knife pointed toward the tibia, in making the incision. Avoid opening the sheaths of the tendons. Behind the internal malleolus and posterior surface of the tibia are four compartments, which, passing from tip of malleolus toward heel, are—first, a canal in the annular

ligament for the posterior tibial muscle tendon—a second canal for the flexor longus digitorum tendon—a third space occupied by the posterior tibial artery, its venæ comites, and the posterior tibial nerve—and a fourth canal for the flexor longus hallucis.

SURGICAL ANATOMY OF PERONEAL BRANCH OF POSTERIOR TIBIAL ARTERY.

Description.—Arises from posterior tibial about 2.5 cm. (1 inch) below inferior border of popliteus—and curves (with convexity outward and upward) obliquely outward and downward to fibula—descending thence close to inner border of fibula, to lower third of leg, where the anterior peroneal is given off (which pierces the interosseous membrane to front of leg)—thence passes, as posterior peroneal, to inferior tibiofibular joint and external malleolus. It is accompanied by two venæ comites.

Relations.—(From origin to bifurcation.) **Anteriorly:** (from above downward) Tibialis posticus; fibrous bed between origins of tibialis posticus and flexor longus hallucis. **Posteriorly:** (from above downward) Soleus; flexor longus hallucis (completing fibrous canal of artery).

Branches.—Muscular, nutrient, anterior peroneal, communicating, posterior peroneal, external calcanean.

Line of Artery.—From middle of popliteal space, on level of lower border of tubercle of tibia, arching slightly outward and then downward along inner border of posterior surface of fibula. For purposes of ligation, the artery is represented by a line from posterior border of head of fibula to point midway between external malleolus and outer margin of tendo Achillis.

Indications for Ligation.—Rare—except for wounds, when the vessel is cut down upon at the point wounded.

Sites of Ligation.—Upper part—rare, owing to depth. Middle—usual site (Fig. 39).

LIGATION OF PERONEAL BRANCH OF POSTERIOR TIBIAL

IN MIDDLE OF LEG.

Position.—Patient rests on shoulder and chest of opposite side; knee flexed; leg on antero-internal surface. Surgeon on outer side, cutting from below on right, and from above on left.

Landmarks.—External border of fibula.

Incision.—About 7.5 cm. (3 inches) in length—parallel with and just behind external border of fibula, with its center over the middle of the leg—which falls behind the peronei muscles (Fig. 39, L).

Operation.—Incise skin and superficial fascia. Branches of the external saphenous nerve and external saphenous vein are apt to be encountered here (Fig. 48). Expose the soleus (which, at this site, no longer arises from the fibula) and retract it upward and inward (incising its lower fibers if any be found attached to the fibula at this height). Divide the deep fascia behind the peronei. Expose the flexor longus hallucis and incise through its thickness, close to the fibula—until the fibrous canal of which it forms the roof

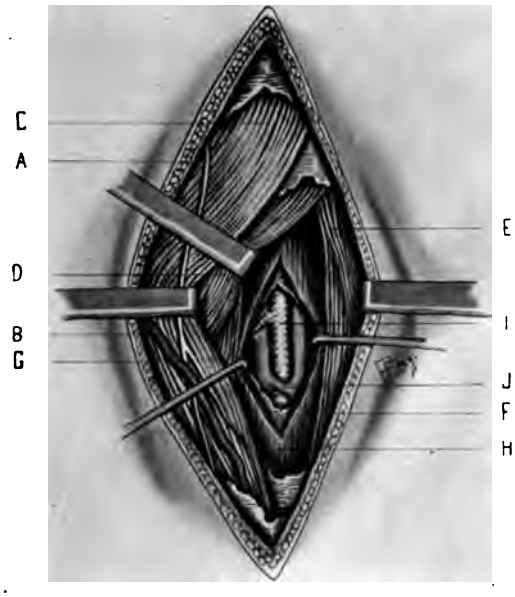

Fig. 48.—Ligation of Right Peroneal in Middle of Leg:—A, Branch of external saphenous nerve; B, Branch of external saphenous vein; C, Gastrocnemius, retracted inward; D, Soleus, retracted upward and inward; E, Peroneus longus; F, Peroneus brevis; G, Tibialis posticus; H, Flexor longus hallucis, incised, showing roof of aponeurotic canal enclosing vessels; I, Peroneal artery; J, Peroneal venæ comites.

is reached. Divide the aponeurotic canal and expose the artery lying near the fibula, with its venæ comites

SURGICAL ANATOMY OF EXTERNAL PLANTAR BRANCH OF POSTERIOR TIBIAL.

Description.—Larger of two terminal branches given off by posterior tibial at inner ankle. Passes from beneath internal annular ligament, obliquely forward and outward across sole of foot to base of fifth metatarsal—thence curves forward and inward to base of first interosseous space—where it anastomoses with communicating branch of dorsalis pedis, to form plantar arch. Two venæ comites accompany the artery.

Relations.—First part (from inner ankle-joint to base of fifth metatarsal): Rests on os calcis; flexor accessorius; flexor minimi digiti. Covered by—skin; superficial fascia; plantar fascia; abductor hallucis; flexor brevis digitorum and abductor minimi digiti. Lies between—flexor brevis digitorum and abductor minimi digiti. Accompanied by—external plantar nerve and two venæ comites. **Second part:** (Plantar arch; from base of fifth metatarsal to proximal end of first interosseous space.) Rests on—proximal ends, and corresponding interosseous muscles, of second, third, and fourth metatarsals. Covered by—skin; superficial fascia; plantar fascia; flexor brevis digitorum; tendon of flexor longus digitorum; lumbricales; branches of internal plantar nerve; adductor hallucis.

Branches.—Muscular, calcaneal, cutaneous, anastomotic, articular, posterior perforating, digital.

Line of Artery.—First Part: from point midway between tip of internal malleolus and great tubercle of os calcis, to base of fifth metatarsal. Second Part:—from base of fifth metatarsal, to posterior part of ball of great toe.

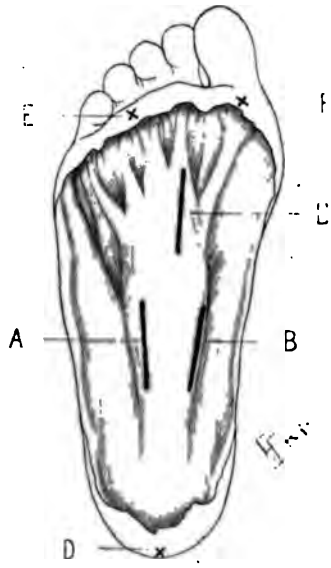

Fig. 49.—Incisions for Ligation of Plantar Arteries:—A, Incision for external plantar in sole of foot; B, For internal plantar in sole of foot; C, For external plantar arch at base of first interosseous space; D, Ball of heel; E, Base of fourth toe; F, Base of first toe.

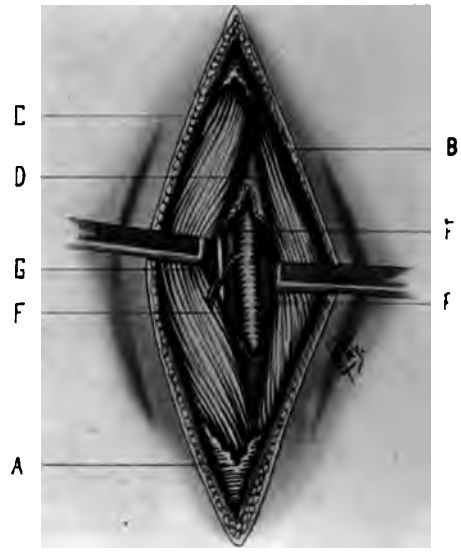

Fig. 50.—Ligation of Right External Plantar in Sole of Foot:—A, Superficial fascia; B, Abductor minimi digiti; C, Flexor brevis digitorum; D, Deep plantar fascia; E, External plantar artery; F, F, External plantar venæ comites; G, External plantar nerve. (The foot here rests upon the toes, the reverse of the position in Fig. 49, where it rests upon the heel.)

Indications for Ligation.—Wounds and aneurisms.

Sites of Ligation.—At origin—more frequent site. In the sole. Plantar arch—rare. (Fig. 49, A, C.)

LIGATION OF EXTERNAL PLANTAR

AT ORIGIN.

Position.—As for the posterior tibial at the ankle.

Landmarks.—Sustentaculum tali.

Incision.—Begins 2 cm. (¾ inch) below and in front of sustentaculum tali and passes backward along inner border of foot, above the abductor hallucis prominence.

Operation.—Incise skin, superficial fascia, exposing the abductor hallucis. Draw this muscle downward. Divide the deep fascia lying beneath the abductor hallucis—and the bifurcation of the artery will be found just in front of a line let fall from the posterior margin of the internal malleolus—accompanied by veins and the posterior tibial nerve.

LIGATION OF EXTERNAL PLANTAR

IN SOLE OF FOOT.

Position.—Patient supine; foot resting upon heel, steadied upon a support. Surgeon at foot of table.

Landmarks.—Ball of heel; fourth toe.

Incision.—Along arch of foot, in a line from ball of heel to fourth toe—about 6 cm. (2½ inches) in length (Fig. 49, A).

Operation.—Divide skin, superficial fascia, fatty areolar tissue, and plantar fascia. Expose the gap between the flexor brevis digitorum and abductor minimi digiti—in which the artery is found, with accompanying nerve and veins (Fig. 50).

SURGICAL ANATOMY OF INTERNAL PLANTAR BRANCH OF POSTERIOR TIBIAL.

Description.—Smaller of two terminal branches given off by posterior tibial at inner ankle—passing forward along inner side of sole, generally to first interosseous space, to anastomose with fifth plantar digital of communicating branch of dorsalis pedis.

Relations.—First covered by abductor hallucis—then lies between abductor hallucis and flexor brevis digitorum—and, toward distal end, is covered by skin and fascia.

Branches.—Muscular, cutaneous, articular, anastomotica, superficial digital.

Sites of Ligation.—At origin—more frequent. In sole. (Fig. 49, B.)

LIGATION OF INTERNAL PLANTAR

AT ORIGIN.

Position—Landmarks—Incision—Operation.—As for ligation of external plantar at origin.

LIGATION OF INTERNAL PLANTAR

IN SOLE OF FOOT.

Position.—As for external plantar.

Landmarks.—Heel; great toe.

Incision.—Along arch of foot, in line from point of heel to great toe—about 6 cm. (2½ inches) in length (Fig. 49, B).

Operation.—Divide skin, superficial fascia, and fatty areolar tissue. Expose the gap between the abductor hallucis and flexor brevis digitorum—in which interval the artery is found (Fig. 51).

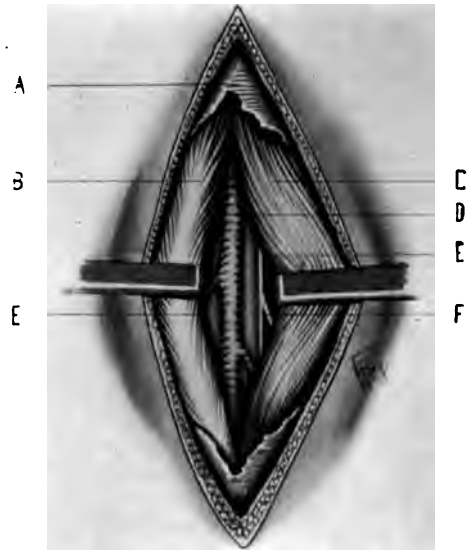

Fig. 51.—Ligation of Right Internal Plantar Artery in Sole of Foot:—A, Superficial fascia; B, Abductor hallucis; C, Flexor brevis digitorum; D, Internal plantar artery; E, E, Internal plantar venæ comites; F, Internal plantar nerve. (The foot here rests upon the toes, the reverse of the position in Fig. 49, where it rests upon the heel.)

TEMPORARY LIGATION OF ARTERIES.

Definition.—The temporary arrest of circulation in an artery by means of a ligature carried beneath the vessel—whereby the artery is drawn upon until the flow ceases, but is not tied.

Indications.—Where it is desired to control for a time the arterial circulation during the steps of an operation—or where a ligature is placed about an artery in advance of, or preparatory for, any emergency which may arise —(*e. g.*, temporary ligature of common carotid in the removal of a tumor of the neck, or of the femoral in popliteal aneurism).

Operation.—All the steps, up to the exposure of the sheath of the artery, are similar to those for an ordinary ligation. At this point, instead of opening the sheath, the sheath itself is isolated (unless a common sheath contain other important structures). A stout ligature (preferably broad) that will not cut is passed beneath the sheath. The two ends of the ligature are not tied upon the artery, but are simply grasped by clamp-forceps in the hands of an assistant (or knotted into a loop). When it is desired to control all flow through the vessel, the assistant simply lifts the artery slightly from its position—the under wall of the artery is thereby pressed into contact with the upper wall by the loop of the ligature, over which the artery makes an angle, and the flow ceases. On relaxing tension, the artery falls back into its normal position and the flow continues. Where no further need exists for this control, one end of the loop is drawn upon and the ligature slips out from under the artery. Where the temporary is converted into a permanent ligature, the ligature is tightened in the ordinary manner—although, were this likelihood foreseen, it would be better to open the sheath of the

artery at first and place the temporary ligature directly around the artery proper.

Comment.—As this secondary operation is generally resorted to in the course, and in the site, of some more major and primary operation, the steps of the temporary ligature are modified by those of the main operation.

INTERMEDIATE LIGATION, OR LIGATURE EN MASSE.

Definition.—Ligature *en masse* for parenchymatous hemorrhage is a method of controlling hemorrhage which comes from no definite vessels, or from inaccessible sources, or as a capillary oozing.

Description.—A fully curved needle, armed with catgut, is made to enter the tissue to one side of the site from which the flow comes—passes deeply into the parts, and, in emerging, more or less completely surrounds the area of hemorrhage—which is controlled by the tightening of the ligature. Or, in hemorrhage from a larger area, a curved needle, held in a holder, may be made to surround the area from which parenchymatous bleeding comes by circumventing that area with a purse-string ligature introduced by several consecutive insertions of the needle—at, for instance, four points of a circle. The ends of beginning and ending of this catgut ligature are then drawn and knotted—only tightly enough to control hemorrhage, and not tightly enough to strangulate the parts.

ARTERIORRHAPHY.

Definition.—Suture of an artery.

Indications.—Arteriorrhaphy may be required in longitudinal wounds of an artery; in limited transverse wounds; in transverse wounds of more than half the circumference; and in complete division, or in division with partial resection (the resected portion not exceeding more than about 2 cm. —$\frac{3}{4}$ inch).

Operation.—(a) **In wounds of artery:** (1) With aseptic precautions, the sheath of the artery is exposed and opened with minimum injury to vessel and surroundings. If the circulation have not been controlled by a constrictor, or some form of pressure, the artery is clamped above and below the injury with special forceps (*e. g.*, Billroth's, with broad blades protected by pieces of rubber drainage-tubes drawn over them; or by means of floss silk lightly tied, or looped). (2) Seize, in turn, the lips of the wounded artery with a pair of oculist's rat-tooth fixation-forceps. Using a fully curved and round conjunctival needle (or straight floss-needle, or cambric needle) threaded with twisted silk of exact size as eye of needle (that hemorrhage may not occur through the needle-hole which the silk has not fully filled), penetrate the tunica adventitia and muscularis, down to (but not through) the intima. The lips of the wound are pierced immediately opposite each other. The knots are interrupted—are from 1 to 2 mm. (about $\frac{1}{20}$ to $\frac{1}{10}$ inch) apart—enter artery about 1.5 mm. ($\frac{1}{16}$ inch) from edge of wound—and are lightly tied with a reef-knot, avoiding inversion of the lips of the artery. The sheath of the artery is separately sutured over the vessel, if possible. The skin wound is closed as usual. A wound in the long axis of the artery tends to gape least, and a transverse wound most. If the artery be divided through one-half of its circumference, it should be entirely divided

and re-united by some method of suture, preferably by invagination. **(b) In complete division of artery:** The artery should be united end-to-end

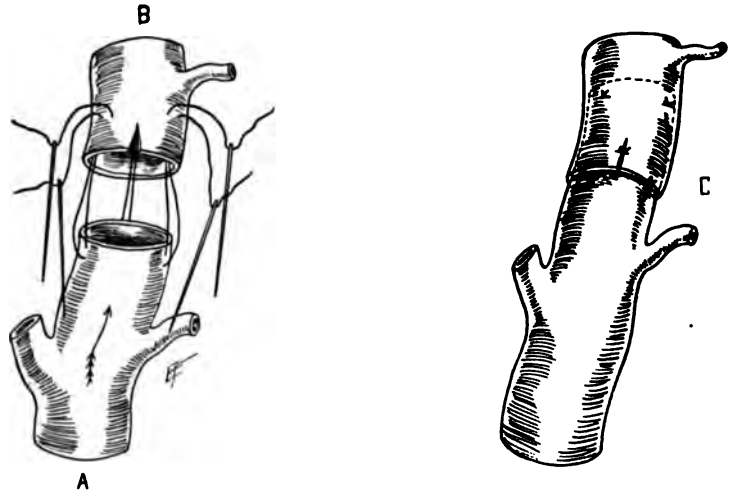

Fig. 52.—ARTERIORRHAPHY IN COMPLETE CIRCULAR DIVISION OF AN ARTERY (MURPHY'S METHOD):—A, Intussusceptum, with sutures passing through outer and middle coats; B, Intussuscipiens (split to aid invagination) with sutures passing through all coats.
Fig. 53.—C, Same, showing all sutures tied.

by invagination. A piece of finely twisted silk is threaded upon two needles —one of which is passed through the outer and middle coats of the proximal

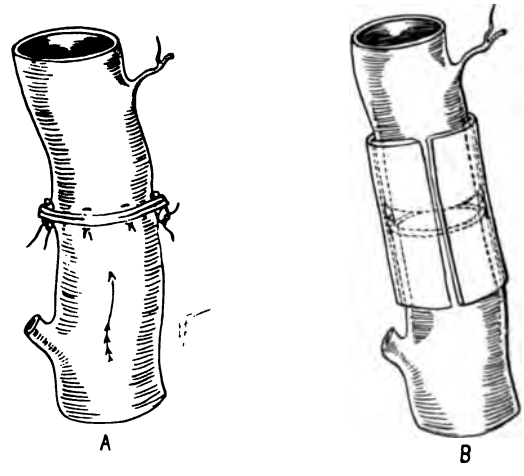

Fig. 54.—CIRCULAR ARTERIORRHAPHY IN COMPLETE DIVISION OF AN ARTERY:—A, Method of Salomoni and Tomaselli - interrupted sutures through all coats.
Fig. 55.—B, Same, method of Glück—interrupted sutures through outer coats, protected by cylinder of decalcified bone, ivory, or rubber.

end, in the long axis—then both needles, held side by side, are simultaneously

passed through all coats of the distal end (intussuscipiens) about 7 to 12 mm. ($\frac{1}{3}$ to $\frac{1}{2}$ inch) from its free end, passing from within outward. Two or three of these sutures are applied equidistantly. The distal end is then slit a short distance (the slit not extending as low as the sutures) to aid in invagination—which is then accomplished by traction upon the sutures—which are, after invagination is complete, tied lightly with reef-knot. Reinforcing

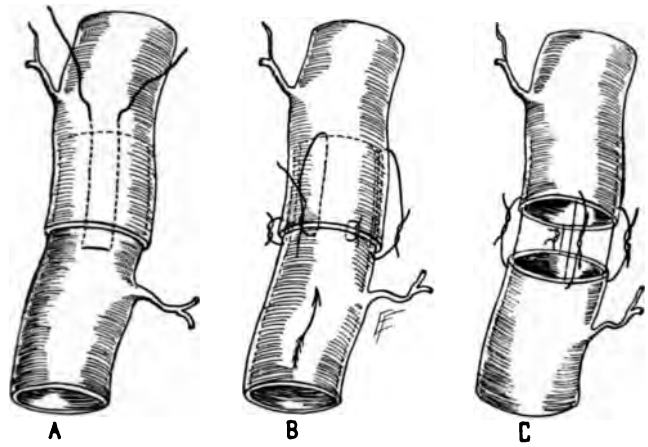

Figs. 56-58.—CIRCULAR ARTERIORRHAPHY, AFTER COMPLETE DIVISION OF AN ARTERY:—The methods of Bouglé.

sutures are placed at the line of junction, and uniting the lips of the slit—but do not pass through the intima of the intussceptum. (See Figs. 52 and 53.)

Comment.—Besides the method of Murphy, above described, end-to-end union may also be accomplished by suturing through all the coats, of both ends, as in Salomoni's and Tomaselli's method (Fig. 54). Or one of Bouglé's methods may be used (Figs. 56, 57, and 58)—or Glück's method (Fig. 55).

ARTERIAL FORCIPRESSURE.

Definition.—Pressure of artery by artery-clamp forceps.

Description.—This is the ordinary method of controlling hemorrhage by seizing arteries in a wound, upon an amputation stump or in the course of any operation—by means of clamp, or hemostatic forceps. The forceps are allowed to remain *in situ* for a period of time after their application, but are not twisted upon their axis (as in the following operation). The hemostat should grasp the bleeding end of the artery, and as little else as possible. Where circumstances allow, the artery to be subjected to forcipressure should be cleared of surrounding connective tissue by a stroke or two of the knife, especially in the case of the larger vessels. In the case of the smaller arteries, the forceps may be removed and nothing further done, with fair certainty that no further bleeding will occur from the crushed vessels. In the case of the larger arteries, a catgut ligature should be applied over the point of the forceps, just prior to their removal.

Comment.—In some operations, as in vaginal hysterectomy by the clamp method, the forceps are left in the wound for twenty-four or forty-eight hours.

ARTERIOSTREPSIS.

Definition.—Torsion of an artery by means of artery-clamp forceps.

Description.—The operation consists in the seizing of the divided end of an artery with forceps and twisting it through two or three revolutions, in the direction of its long axis—causing a rupture and retraction of its inner and middle coats within the outer coat. A clot forms and organizes upon and in the roughened inner coats and is protected by the outer coat. The twisting should cease short of causing a complete severance of the end of the artery. This is the common method of arresting hemorrhage from the smaller vessels bleeding in a wound or upon the surface of an amputation stump, and its use should be confined to such vessels, although the femoral artery has been successfully controlled by torsion (occurring in accidents). The technic differs slightly in the application of arteriostrepsis to small and medium vessels: (a) Upon Smaller Arteries:—seize the extremity of the bleeding vessel with catch-forceps, including as little tissue, other than the sheath of the artery, as possible—draw it out from its connections and twist it around two or three times and release the hold. (b) Upon Medium Arteries:—seize the extremity of the severed artery, in its long axis, with catch-forceps, and draw the vessel out of its sheath for about 1.3 to 2 cm. (½ to ¾ inch). With a second pair of catch-forceps, grasp the bared artery about 1.3 cm. (½ inch) from its extremity, at a right angle to its long axis, and hold steadily. Then rotate the vessel two or three times by means of the terminal forceps, and let go. Thus the proximal forceps prevent the artery from being twisted in its sheath, which would sever its vasa vasorum in their passage from the sheath to the artery. Only that portion of the artery, therefore, between the clamps is twisted.

LIGATION FOR RADICAL CURE OF ANEURISM.

Description.—Several methods of applying ligatures for the radical cure of aneurism have been adopted—either as a means alone, or in conjunction with other steps.

Methods.—(1) Antyllus's Method ("Old Method"):—The sac is incised—the clots are turned out—and the involved artery ligated above and below the sac. (2) Anel's Method:—Ligature of the involved artery just above (proximal to) the sac. (3) Hunter's Method:—Ligature of the main vessel involved at some distance above (proximal to) the sac, so that one branch, at least, intervenes between sac and ligature, thereby only partly cutting off the circulation through the sac. (4) Brasdor's Method:—Ligature of the main artery involved beyond (distal to) the sac, entirely cutting off the circulation through the sac. (5) Wardrop's Method:—Ligature of one or more of the distal branches. (6) Extirpation:—Ligature of the main vessel (and collateral branches) above and below the sac, with extirpation of the aneurism—with or without opening the sac.

OPERATION FOR RADICAL CURE OF ANEURISM, BASED UPON ARTERIORRHAPHY.

MATAS'S METHOD.

Description.—The aneurismal sac is laid open—the openings of the main and collateral vessels are closed by suture—and the cavity of the sac obliterated by suturing its walls, and overlying integumentary parts, to its floor. Four cases thus far operated in the above manner by the author of the method have been uncomplicated and have resulted in complete cure. Matas now further proposes to restore the circulation through the part, by forming a new blood-channel by suturing the lower part of the sac over a temporarily placed rubber tube—which is withdrawn just before the remainder of the sac is obliterated.

Indications.—The method is applicable to all cases where (**a**) a distinct

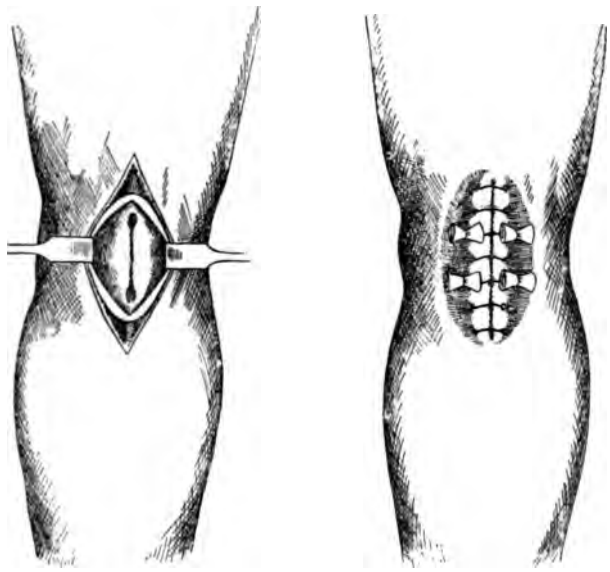

Fig. 59.—OPERATION FOR RADICAL CURE OF ANEURISM (MATAS'S METHOD):—A, First stage of operation—fusiform aneurism laid open, showing two openings and intervening groove. (Modified from Matas.)

Fig. 60.—B, Final stage—showing walls of aneurism-sac and integuments sutured to floor of sac over gauze rollers. (Modified from Matas.)

sac exists (whether fusiform or saccular), and (**b**) where the proximal circulation can be controlled. In the fusiform type of aneurism two openings of the main vessel exist, one at either end, generally with a groove connecting them. Here both openings are obliterated by suture, as well as the floor of the aneurism. It is now proposed to restore the circulation through these two openings and groove in the manner above described. In the saccular type a single opening of the main vessel exists. Here the margin of the opening is obliterated by suture, leaving the artery intact and capable of carrying on circulation.

Operation.—(1) Control of circulation through sac by digital or con-

strictor compression, traction-loop around vessel, or by special artery-clamps. (**2**) Free median incision of the overlying parts and of the aneurismal sac, from end to end. All clots are turned out. All laminated fibrin is rubbed

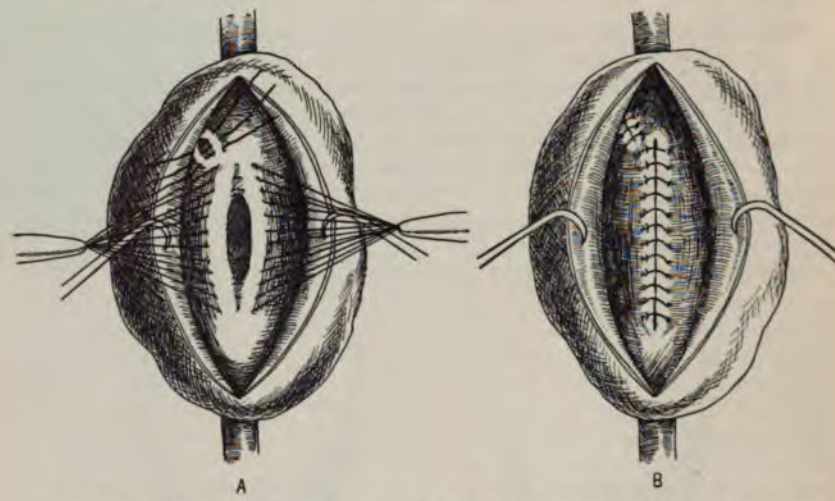

Fig. 61.—Operation for Radical Cure of Aneurism (Matas's Method):—A, Suturing together borders of openings in main and collateral arteries, in case of saccular aneurism, leaving channel of main artery intact. (Modified from Matas.)

Fig. 62.—B, Same, showing openings completely closed. (Modified from Matas.)

off with gauze mops from the walls of the sac. All openings into the sac are thus exposed (Fig. 59). (**3**) Obliteration of all vascular openings by inter-

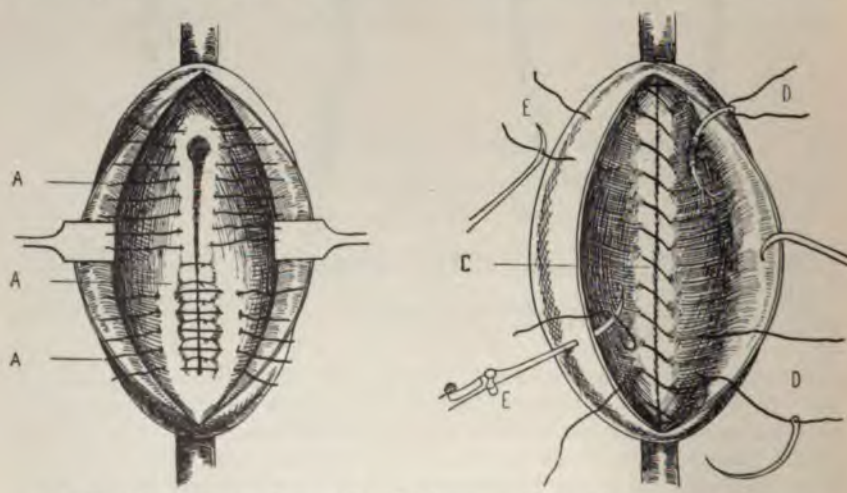

Fig. 63.—Operation for Radical Cure of Aneurism (Matas's Method):—A, A (two upper A's), First tier of sutures all placed and partly tied, in a fusiform aneurism; A (lower A), Second tier partly placed. (Modified from Matas.)

Fig. 64.—Same:—C, Second tier (here shown continuous), placed and tied, obliterating openings and groove; D, D, Placing sutures with curved needle, to approximate aneurism-wall to floor of aneurism; E, E, Reverdin needle in act of drawing sutures through aneurism wall. (Final tying of these four sutures is shown in Figs. 60 and 66.) (Modified from Matas.)

rupted or continuous Lembert sutures of chromic gut introduced by curved needle in holder, and taking firm and deep hold of the lips to be approximated (Figs. 61 and 62). (4) Reinforcement of first tier of sutures, especially in large aneurisms, by a second tier of Lemberts, preferably continuous. Object

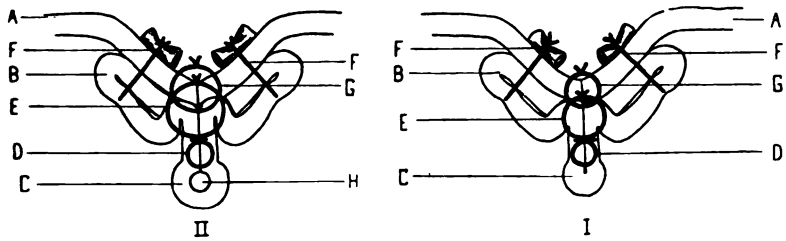

Fig. 65.—Operation for Radical Cure of Aneurism (Matas's Method):—I, Diagram of cross-section of parts in complete obliteration of sac and blood-channel; A, Integuments; B, Aneurismal sac; C, Walls of blood-channel; D, First tier of sutures, approximating borders of blood-channel; E, Second tier of sutures, approximating floor of sac over first tier; F, F, Sutures through walls and into floor of aneurism, approximating former to latter; G, Suture through margin of integuments and into floor of sac, over second tier. (Modified from Matas.)

Fig. 66.—II, Diagram of cross-section of parts in complete obliteration of aneurism-sac, but with restoration of blood-channel; parts are same as in above, except that D represents suture approximating walls of sac over a temporary rubber tube; H, Restored blood-channel. (Modified from Matas.)

of second tier is to protect against leakage and for the purpose of reducing the size of the sac and building it up from the bottom toward the surface, in the middle line (Figs. 63 and 64). (5) In-folding of the walls of the aneu-

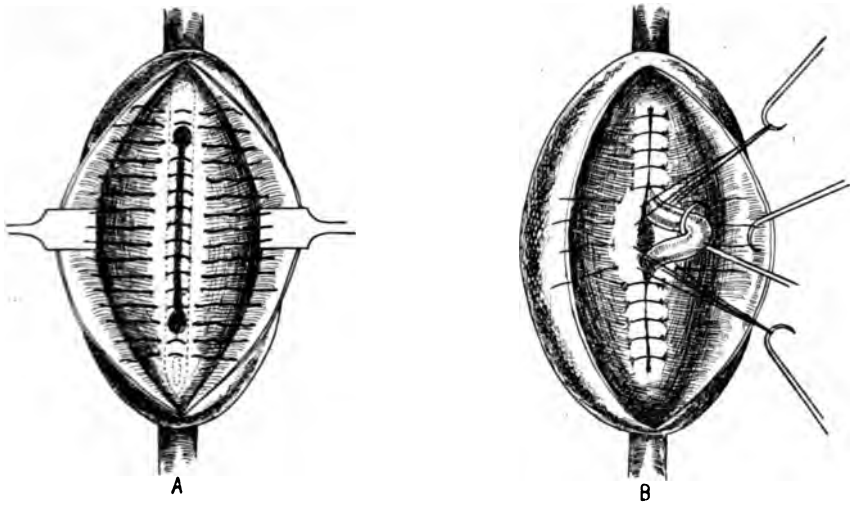

Fig. 67.—Operation for Radical Cure of Aneurism (Matas's Method):—A, Suturing borders of openings and connecting groove over temporary rubber tube, in case of fusiform aneurism. (Modified from Matas.)

Fig. 68.—B, Same, withdrawing tube through temporarily displaced sutures. (Modified from Matas.)

rismal sac, together with the overlying integumentary tissues—and the obliteration, thereby, of the sac by complete approximation of these tissues to the floor of the sac and to the central elevation formed by the one or two tiers

of sutures just described. The two flaps thus in-turned consist of aneurismal wall and integumentary coverings. These relaxed flaps are sutured to the bottom of the aneurism by interrupted sutures deeply placed (Fig. 64)—and, especially in large aneurisms, the approximation is made more complete, and dead spaces between the wall of sac and integuments, on the one hand, and the floor of the sac, on the other, rendered less likely by the passage of deep chromic gut, or silkworm-gut, sutures—passing through all the walls of the sac and into the floor of the aneurism, and tied over rollers of gauze on the skin surface (Fig. 60). A hollow ovoid is thus left on the skin surface where formerly a convexity existed (Fig. 66). (6) Where a new blood-channel is to be formed, a rubber tube is carried through both openings and made to occupy the groove which usually exists between the two openings (Fig. 67). Over this tube the sac is sutured, as in Witzel's gastrostomy (page 769). All sutures are placed before any are tied. The end sutures are then tied over the tube—when the tube is withdrawn through the separated middle sutures, which are then tied (Figs. 68 and 65). The operation is then completed as in cases where the circulation is entirely obliterated.

Comment.—(1) Union takes place between the serous surfaces lining the sac (the arteries being mesoblastic). (2) The sutures take good and strong hold in the walls of the sac. (3) Advantage of this method of operating are the following: simpler technic; less traumatism; elimination of any ligaturing; no disturbance of structures in vicinity of aneurismal sac; collateral circulation preserved; circulation of main artery preserved, in favorable cases; usually prompt healing by approximation of skin to floor of aneurismal sac.

OTHER OPERATIONS FOR RADICAL CURE OF ANEURISM.

Acupuncture.—A method of treating aneurisms by the introduction of long needles into their sacs. Several long, fine needles are simultaneously introduced, by the safest route, through overlying integuments, into and through the wall of the aneurism—and on beyond, until in contact with the opposite wall. Here they are allowed to quietly rest for several hours, and are then withdrawn. Repetition of this process may be resorted to upon successive occasions. Coagulation is thus favored.

Needling (Macewen's Operation).—The introduction of one or two long needles into the sac, with irritation of its wall. A long, fine needle is introduced, by the safest route, through skin and connective tissue, into and through the wall of the aneurism—and is pushed on until in contact with the inner surface of the opposite wall. The wall of the aneurism is then gently irritated by a process of scratching, by means of the point of the needle —which is then withdrawn. The interior of the sac should be evenly irritated throughout, or at different sites consecutively. This direct irritation of the wall should be only great enough to produce a reparative exudation together with a deposit of fibrin—and thus white thrombi are formed upon the surface of the sac. Two or more needles may be used simultaneously in a large sac, and several hours may be consumed in the process—and their use repeated upon successive occasions.

Introduction of Wire.—A fine cannula is introduced, by the safest route, through skin, fascia, and wall of aneurism, into the cavity of the sac. Through this cannula several yards of fine wire (according to size of aneurism) are introduced and left, the cannula being withdrawn. Cure is effected by the clotting of blood upon this wire meshwork. Catgut, silk, horsehair, and the

like have been used—but silvered copper wire has proved the most satisfactory.

THE TREATMENT OF VASCULAR NEOPLASMS BY INJECTION OF WATER AT HIGH TEMPERATURE.

WYETH'S OPERATION.

Description.—This method of treatment consists in the injection into the substance of vascular neoplasms (angeiomata) of water at a temperature of from 190° to 212° F. and over—the object being immediately to coagulate the blood and albuminoids of the tissues. The vascular tumors thus far treated by the author of the operation have been arterial angeiomata (cirsoid aneurisms), capillary angeiomata ("mother's marks"), and venous angeiomata (cavernous nævi).

Instruments.—Syringe with metallic cylinder and an adjustable piston, and needles of various sizes. The water is usually gotten from some immediately adjacent vessel in which it has come to a boil, and under all aseptic precautions. In cirsoid aneurisms and in the larger cavernous nævi, where the water should be kept at the boiling-point during the use of the needle and syringe, the author of the operation has devised a long metallic instrument under the cylinder of which a Bunsen burner is held during operation.

Operation.—(1) The region of the injection is rendered aseptic in the usual manner. The operation is done under complete narcosis. The quantity and temperature of the water will vary according to the size and nature of the growth. (2) In arterial and venous angeiomata the needle is carried deeply into the substance of the growth and from 30 to 60 minims of water are thrown out in one site—the needle is then withdrawn from 1.3 to 2.5 cm. (½ to 1 inch) and about the same amount injected—and the same steps repeated in different sites until the whole tumor is solidified. While using water of a temperature sufficiently high to coagulate the blood and albuminoids of the neighboring tissues, it should not be delivered into the part so exceedingly hot nor with such pressure as to cause subsequent sloughing of the overlying parts. Evidence of sufficient distention of the part to discontinue the injection in that particular site is given by slight bleaching of the skin. (3) In capillary angeiomata, especially upon delicate parts, water a little below boiling (about 190° F.) should be used—and only about two to six minims thrown in at a single puncture—beginning at the periphery of the growth. Sloughing is more apt to occur in the capillary angeiomata. The injection may be repeated in from seven to ten days, if necessary. (4) A surgical dressing is then applied and the part kept at rest.

Comment.—(1) No painful symptom nor septic infection has followed any of the cases except in one instance where the patient passed out from under the observation of the author of the operation. (2) Especial care is advised in the cases of angeiomata of the neck and scalp, because of œdema. (3) No more than from five to six ounces should be injected at one sitting.

CHAPTER II.

OPERATIONS UPON THE VEINS.

PHLEBOTOMY.

Definition.—Incision of a vein, or venesection. A method, now rarely practised, of depletion by bleeding, for its effect upon the system. One of the veins of the elbow is usually selected.

Indications.—Pulmonary engorgement; engorgement of the right heart; many inflammatory states in sthenic persons.

Preparation.—Bend of elbow shaved.

Position.—Patient, holding arm extended and abducted, sits upright, that warning by approaching syncope may be given. Surgeon stands in front and to right of either arm.

Instruments and Accessories.—Lancet or bistoury; fillet or constrictor; round object to grasp (roller bandage); a graduated "bleeding-bowl" or measure; gauze compress; bandage.

Operation.—Apply the constrictor around the lower third of the arm, that the return venous flow may be obstructed and veins about the elbow made prominent, while not firmly enough to obstruct the arterial flow. The grasping and manipulating of the fingers about some object will aid the distention of the veins. The most prominent vein at the bend of the elbow is now selected. The median basilic vein (which is crossed by the internal cutaneous nerve and is parallel with and separated from the brachial artery by the bicipital fascia) is generally chosen—because of its greater prominence, and because of being steadied by the underlying bicipital fascia. The median cephalic vein (which is covered by skin and fascia alone and rests upon the external cutaneous nerve) is often chosen—and is also sometimes the more prominent. The vein is steadied by pressure of the left thumb just below the intended incision. The lancet or bistoury, with its back to the arm, is thrust through the skin over the vessel, and into the distended vein beneath —and is made to cut its way upward and outward at a single stroke—calculating to sever, in an oblique direction, about two-thirds of the vein. Upon removing the thumb, the bleeding is allowed to continue until approaching faintness indicates a sufficient loss—when the constrictor is removed, the gauze pad placed over the wound, and a figure-of-eight bandage applied to the elbow.

Comment.—(1) If bleeding continue, the vein is to be entirely severed —and the wound may even be enlarged and the vessel doubly ligated. (2) The internal saphenous vein may also be used.

PHLEBORRHAPHY.

Definition.—The suture of a wound in a vein, without occluding the caliber of the vessel.

Indications.—Where, in the case of a limited wound to one of the larger veins, it is desired to control hemorrhage without permanently destroying the function of the vein by transverse ligation—and where the wound is too long for lateral ligation.

Operation.—Having well exposed the vein and controlled the hemorrhage from the vessel by distal compression (by constrictor, digital compression, or temporary ligature), one of the lips of the wounded vein is steadied with fine forceps, while a fine needle, armed with finest catgut, pierces this lip, including, if possible, only the external and part of the middle coat. The opposite lip is similarly steadied and similarly pierced, in the opposite direction

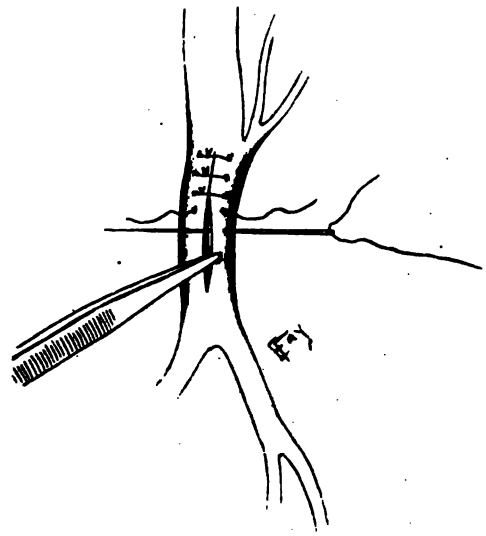

Fig. 68.—PHLEBORRHAPHY:—Forceps are seen everting lip of wound for passage of needle and interrupted sutures.

(penetrating part of the middle and the entire thickness of the outer coat). By tying the ligatures carefully, the two lips are brought into even apposition. Interrupted sutures, closely applied, will more safely repair the wound than continuous suture (Fig. 69).

Comment.—This method is especially applicable where (**a**) the wound is longitudinal (and therefore the lips tend to lie parallel), and (**b**) where the wound extends in any one direction a distance greater than equivalent to the diameter of the lumen. Sometimes instead of approximating lip to lip, the edges of the wound are sutured upon themselves.

LATERAL LIGATION OF VEINS.

Description.—The application of a ligature to the wall of a vein for the purpose of closing a wound in the vein without obliterating its lumen.

Indications.—Wound of one of the larger veins, where it is desired to

control hemorrhage without destroying the function of the vein by transverse ligation.

Operation.—Having controlled hemorrhage and brought the vein well into the field of operation, seize the two lips of the wounded vein in a single bite of a pair of dissecting forceps—draw them outward from the wall of the vein in the form of a small cone (whose apex is formed by the forceps)—and, around the base of the cone, tie, with a reef-knot, a ligature of fine chromicized catgut, relaxing the tension upon the cone at the moment of tightening the

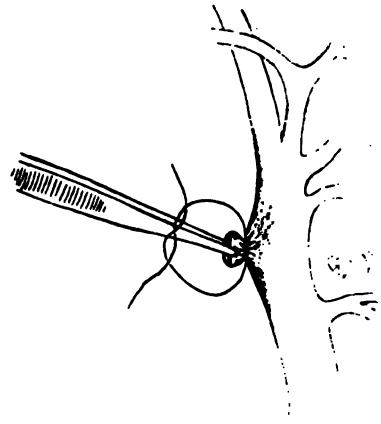

Fig. 70.—LATERAL LIGATION OF A VEIN:—Forceps are shown drawing outward and puckering together the wounded lateral wall of a vein, around which a ligature is being tied.

knot—and thus throwing into folds the walls of the rent in the vessel very much as one puckers together the mouth of a sac with a draw-string. The ligature is cut short and the temporary compression relaxed—and the wound closed as in an ordinary ligation (Fig. 70).

Comment.—This method is applicable where the wound does not extend in any one direction a distance equivalent to the diameter of the lumen. Transverse wounds gape more than longitudinal ones and are thus especially suitable for this form of ligature.

TRANSVERSE LIGATION OF VEINS.

Description.—The ordinary ligation of a vein (in contradistinction to lateral ligation).

Indications.—Wounds; arteriovenous aneurism; simple and suppurative phlebitis; thrombosis; angeiomata.

Operation.—As for ligation of arteries, in general principle.

TEMPORARY LIGATION OF VEINS.

Description.—As for same operation upon arteries (page 116).

Indications.—As in temporary ligation of an artery (*e. g.*, temporary

ligation of internal jugular vein in removal of tumor of neck—or while ligating or suturing a wound of the vein).

Operation.—Same, practically, as for the corresponding operation upon the arteries (page 116).

VENOUS LIGATION EN MASSE.

Description.—For parenchymatous hemorrhage.

Operation.—Practically identical with intermediate ligation, or ligation *en masse*, described under Arteries (page 117).

VENOUS FORCIPRESSURE.

Description.—A method of control of venous hemorrhage, corresponding with arterial forcipressure (page 119)—though of more limited application.

PHLEBOSTREPSIS.

Description.—Corresponding with arteriostrepsis (page 120).

ACUPRESSURE OF VEINS.

Description.—Pressure of vein by needle—the pressure being applied directly or indirectly. Rarely resorted to at present. Formerly much used for varicose veins, nævi, and venous hemorrhage.

Operation.—Several methods of acupressure exist, differing in but minor details. The following is the most generally applicable method: The needle (or pin) enters the skin near the involved vein—passes under the vein as closely as possible—and emerges from the skin on the opposite side. Over this needle, in a figure-of-eight fashion, a silk ligature is wound—thus compressing the vein between needle and ligature.

PHLEBECTOMY.

Description.—Excision of a vein, in whole or in part.

Indications.—The usual causes for which veins are removed are varicosity (*e. g.*, excision of varicosed veins of leg, or of a varicocele) and thrombosis, especially suppurative (*e. g.*, excision of internal jugular for suppurative thrombosis following middle-ear disease).

Operation.—As illustrative of the technic of phlebectomy in general, partial excision of the internal saphenous will be described for varicosity of that vein and its branches—the operation consisting in the total removal of sections of the vein and its branches at intervals along its course. (1) The site and course of the varicose veins are previously marked with nitrate of silver stain (on the preceding day, to allow of darkening), that the landmarks may not be lost during operation. The limb is shaved. An Esmarch is generally used to control hemorrhage. (2) Over the course of the vein (or slightly to one side, or obliquely crossing it) incisions of from 8 to 15 cm.

(3 to 6 inches) are made at intervals—extending, if necessary, from the inner side of the foot to the saphenous opening in the thigh. These incisions are especially placed over the most marked groups of veins—and those nearer the saphenous opening are usually the first attacked. The skin and bands of fibrous tissue binding down the vein are divided and the involved veins exposed. The vein and its branches are entirely isolated to the extent of the incision, by blunt and sharp dissection. The vein is then gently drawn upon, so as to bring into the open wound as much of itself and branches as possible—when it is gut-ligatured at both ends, each branch being also ligatured—after which the main vein and its branches are cut away. This site of operation is then packed with gauze, until removal at all indicated sites is accomplished—to allow of cessation of all bleeding before suturing. (3) The edges of the skin wound are then sutured with silk, or silkworm-gut—after which the limb is dressed, immobilized, and slightly elevated.

Comment.—(1) The removal of the vein in sections appears to give as good, or better, results as the attempt to remove the entire vein. (2) Avoid wounding the veins in operation, which increases the difficulties. (3) Avoid including a nerve filament in the ligature, which has caused much subsequent pain.

INTRAVENOUS INFUSION OF NORMAL SALT SOLUTION.

Description.—Injection of normal salt solution into the venous circulation.

Indications.—Hemorrhage; shock; sepsis; suppression of urine; and other conditions.

Preparation of Normal Salt Solution.—The physiological salt solution for man is a mixture of 0.6 of 1 per cent. of sodium chlorid in water (approximately, one dram of sodium chlorid to one pint of water). This mixture is to be sterilized and used at a temperature of 100° F.—being allowed to pass from an elevated funnel, or jar, through a rubber tube and special cannula into the vein. The salt may be sterilized first—or the solution may be sterilized after preparation. The operation is conducted aseptically throughout.

Preparation.—Patient's elbow is shaved and protected by aseptic dressing (if occasion allow).

Position.—Patient recumbent; arm extended, abducted and supine. Surgeon on right side of both arms—or on right side of right, cutting from above; and on left side of left, cutting from below.

Instruments and Accessories.—Scalpel; dissecting forceps; artery-clamp forceps; funnel; rubber tube; bulbous-pointed cannula; aneurism-needle; ligature; suture; needle and holder; constrictor for arm; gauze compress, cotton and bandage.

Operation.—The most prominent vein at the bend of the elbow is chosen (see Phlebotomy, page 126). If the vein be prominently marked, incise directly over and parallel with it. If not marked, incise obliquely across the known course of the median basilic vein, the incision running parallel with the direction of the bicipital fascia. Proceed carefully until the vein is located. Expose from 2.5 to 4 cm. (1 to 1½ inches) of the vein. Pass two catgut ligatures beneath the vein, about 2.5 cm. (1 inch) apart—and tie the distal one permanently (Fig. 71). With a pair of sharp-pointed scissors, curved on the flat, an oblique incision is made through one-half of the vein, between the two ligatures, the apex of the "V" pointing distally. Into this

oblique opening into the vein, the cannula (after seeing that no air is in the instrument) is introduced—and the proximal ligature is tightened about it with a friction-knot. Through this is allowed to flow, by static pressure, as much fluid as is indicated (generally from one to six pints). The cannula is then withdrawn—the proximal ligature is tightened and tied permanently

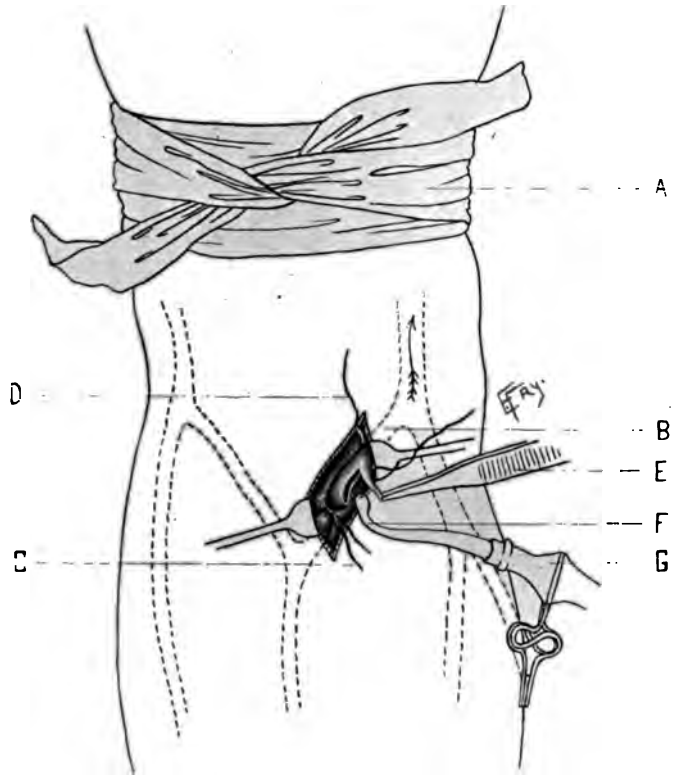

Fig. 71.—INTRAVENOUS INFUSION OF NORMAL SALT SOLUTION:—A, Bandage tourniquet; B, Median basilic vein; C, Distal (to heart) ligature tied about vein; D, Proximal (to heart) ligature loosely placed and ready to be tied about vein; E, Forceps grasping tongue of wound in vein just made by curved scissors; F, tip of cannula about to enter vein and around which ligature will be tied; G, Stopcock.

—and the vein completely severed. The wound is sutured and the dressing applied.

Comment.—The fluid may be thrown into an open vein in a stump—or any convenient vein in a wound may be opened. The basilic vein itself may be used—or the internal saphenous.

CHAPTER III.

OPERATIONS UPON THE LYMPHATIC GLANDS AND VESSELS.

SURGICAL ANATOMY OF THORACIC DUCT.

Course and Relations.—(1) **Abdominal portion:**—(from origin to diaphragm);—Begins in abdomen at receptaculum chyli, on anterior surface of second lumbar vertebra, lying behind and to right side of aorta and between aorta and right crus of diaphragm. At aortic opening in diaphragm (in front of twelfth dorsal vertebra) it still lies to right of aorta and has vena azygos major to its right. (2) **Thoracic portion:**—(from diaphragm to superior thoracic opening);—Runs up posterior mediastinum between aorta and vena azygos major, in front of sixth to twelfth dorsal vertebræ. Opposite to fifth dorsal vertebra it passes to left behind esophagus and aortic arch to enter superior mediastinum, whence it emerges through superior thoracic opening into root of neck. (a) In Posterior Mediastinum (from below upward)—**Anteriorly;** pericardium; esophagus; arch of aorta. **Posteriorly;** sixth to twelfth dorsal vertebræ; anterior common ligament; right inferior intercostal arteries; vena azygos minor (sometimes one of left middle intercostal veins and vena azygos tertia). **Left;** thoracic aorta. **Right;** vena azygos major; right pleura. (b) In Superior Mediastinum;—**anteriorly;** first part of left subclavian artery. **Posteriorly;** upper dorsal vertebræ (first to fifth.) **Left;** left pleura. **Right;** esophagus. (3) **Cervical portion:**—(from superior thoracic opening to termination);—From superior thoracic opening it ascends on left side of neck to level of seventh cervical vertebra—curves thence downward, forward, and outward, arching over apex of left pleura—passing in front of subclavian artery, scalenus anticus muscle, vertebral vein—and behind left internal jugular vein, and behind and then externally to left common carotid artery—and, receiving left jugular lymphatic trunk, empties into left innominate vein at junction of left internal jugular and left subclavian veins.

Course and Relations of Right Lymphatic Duct.—About 1.3 to 2 cm. ($\frac{1}{2}$ to $\frac{3}{4}$ inch) in length—formed by union of subclavian and jugular lymphatic ducts—passes downward and inward—and empties into venous circulation at junction of right internal jugular and subclavian veins.

SUTURE OF THORACIC DUCT.

Description.—Suture of the thoracic duct is indicated in wounds of the duct occurring from external injury, or in the course of an operation.

Operation.—The method of suturing the thoracic duct is similar to that employed in suturing a vein (see Phleborrhaphy, page 126). Having completed the technic of suturing the duct itself, the neighboring tissues should be drawn over and sutured about the wound in the duct, to aid in closing and reinforcing the sutured site—and the overlying skin should be

sutured throughout and pressure applied. Minimum nourishment should be administered to the patient, to keep the duct as empty as possible until union of the wound has occurred.

Comment.—If possible, the right duct should be similarly dealt with.

LIGATION OF THORACIC DUCT.

Description.—The thoracic duct, where completely severed by accident, has been ligated, and recovery has followed—although there has been a question as to whether, in such cases, a branch of the main duct has not existed and maintained the circulation. Suturing, however, is always preferable to ligation, where possible. Where ligation is performed, the technic is the same as that for ligating a vein (pages 127 and 128).

Comment.—The right lymphatic duct may also require ligation if its divided ends be discovered in a wound.

SURGICAL ANATOMY OF ANTERO-LATERAL ASPECT OF NECK.

Boundaries of Antero-lateral Aspect of Neck.—Superiorly: lower border of body of inferior maxilla, and imaginary line from angle of inferior maxilla to mastoid process. **Inferiorly:** upper border of clavicle. **Anteriorly:** median line of neck. **Posteriorly:** anterior border of trapezius.

Subdivisions of Quadrilateral Surface of Neck.—(a) Anterior Triangle —divided, by digastric muscle above and anterior belly of omohyoid below, into submaxillary, superior carotid, and inferior carotid triangles. **(b)** Posterior Triangle—divided, by posterior belly of omohyoid, into occipital and subclavian triangles.

Anterior Triangle.—Boundaries, anteriorly: median line of neck, from chin to sternum. **Posteriorly:** anterior margin of sternomastoid muscle. **Superiorly:** lower border of body of inferior maxilla, and line from angle of inferior maxilla to mastoid process (base). **Inferiorly:** at sternum (apex). This triangle is subdivided into submaxillary, superior carotid, and inferior carotid triangles.

Submaxillary Triangle.—Boundaries: Superiorly—lower border of inferior maxilla, and line from angle of inferior maxilla to mastoid process. Inferiorly—posterior belly of digastric and stylohyoid. Anteriorly—anterior belly of digastric (or middle line of neck). **Coverings:** integument; superficial fascia; platysma; deep fascia; branches of facial nerve; branches of superficialis colli nerve. **Floor:** anterior belly of digastric; mylohyoid; hyoglossus. **Contents:** Muscles—styloglossus, stylopharyngeus. Ligaments —stylomaxillary (separating anterior from posterior part of triangle). Arteries—external carotid, posterior auricular, temporal, internal maxillary, mylohyoid branch of inferior dental, facial with submaxillary and submental branches, internal carotid. Veins—internal jugular, facial, submaxillary. Nerves—facial, pneumogastric, glossopharyngeal, mylohyoid branch of inferior dental. Other Structures—parotid gland, submaxillary gland, lymphatic glands.

Superior Carotid Triangle.—Boundaries: Superiorly—posterior belly of digastric. Inferiorly—anterior belly of omohyoid. Posteriorly—anterior border of sternomastoid. **Coverings:** integument; superficial fascia; platysma; deep fascia; branches of facial nerve; branches of superficialis colli

nerve. **Floor:** parts of thyrohyoid; hyoglossus; inferior constrictor of pharynx; middle constrictor of pharynx. **Contents:** Arteries—common carotid; internal carotid; external carotid; superior thyroid; lingual; facial; occipital; ascending pharyngeal. Veins—internal jugular; superior thyroid; lingual; facial; occipital (sometimes); ascending pharyngeal. Nerves—descendens hypoglossi; hypoglossal; pneumogastric; sympathetic; spinal accessory; superior laryngeal; external laryngeal. Other Structures—larynx; pharynx; lymphatic glands.

Inferior Carotid Triangle.—Boundaries: Superiorly—anterior belly of omohyoid. Anteriorly—middle line of neck. Posteriorly—anterior margin of sternomastoid. **Coverings:** integument; superficial fascia; platysma; deep fascia; descending branch of superficialis colli nerve. **Floor:** scalenus anticus (superiorly and externally); longus colli (inferiorly and internally); rectus capitis anticus major (between and superiorly); vertebral artery and vein (between and inferiorly). **Contents:** Muscles—sternohyoid; sternothyroid. Arteries—common carotid (not strictly); inferior thyroid; vertebral. Veins—internal jugular. Nerves—pneumogastric; descending filaments from loop between descendens and communicans hypoglossi; recurrent laryngeal; sympathetic. Other Structures—larynx; trachea; thyroid gland; lymphatic glands.

Posterior Triangle.—Boundaries: Anteriorly—posterior border of sternomastoid. Posteriorly—anterior border of trapezius. Superiorly—occiput (apex). Inferiorly—superior border of clavicle (base). This triangle is subdivided into the occipital and subclavian triangles.

Occipital Triangle.—Boundaries: Anteriorly—posterior border of sternomastoid. Posteriorly—anterior border of trapezius. Inferiorly—posterior belly of omohyoid. **Coverings:** integument; superficial fascia; platysma; deep fascia. **Floor:** splenius capitis; levator anguli scapulæ; middle scalenus; posterior scalenus. **Contents:** Arteries—transversalis colli. Veins—transversalis colli. Nerves—spinal accessory; descending branches of cervical plexus. Other Structures—lymphatic glands.

Subclavian Triangle.—Boundaries:—Posteriorly—posterior belly of omohyoid. Inferiorly—upper border of clavicle. Anteriorly—posterior border of sternomastoid (base). **Coverings:**—integument; superficial fascia; platysma; deep fascia; descending branches of cervical plexus. **Floor:**—first rib, first serration of serratus magnus. **Contents:**—Arteries—subclavian (third part); suprascapular; transversalis colli. Veins—subclavian (sometimes); suprascapular; transversalis colli; external jugular; small vein from cephalic to external jugular. Nerves—brachial plexus, small nerve to subclavius. Other Structures—lymphatic glands.

Lymphatic Glands of Head and Neck.—Consist of superficial and deep glands. (A) **Superficial glands of head and neck:**—Consist of transverse and vertical sets. (1) **Transverse set of superficial glands:**—Extend transversely from occiput along mastoid process, zygoma, and lower border of jaw, to symphysis menti, and comprise following groups;—(a) Occipital or Suboccipital—below superior curved line of occipital bone, between skin and insertion of complexus muscle. (b) Posterior Auricular, or Sternomastoid—behind ear, between skin and insertion of sternomastoid. (c) Parotid—in front of ear, between skin and parotid gland, some being embedded within parotid gland. (d) Buccal—on surface of buccinator, between it and skin. (e) Submaxillary—in digastric triangle, between skin and mylohyoid and hyoglossus. (f) Suprahyoid—in middle line, between anterior bellies of digastric, between skin and mylohyoid. (2) **Vertical set of super-**

ficial glands (superficial cervical chain):—(**a**) Anterior—in front of neck, between hyoid bone and sternum, and between skin and superficial muscles. (**b**) Middle (superficial cervical chain)—chiefly along external jugular vein, mainly in posterior triangle of neck, between platysma and deep cervical fascia. (**c**) Posterior—over trapezius, between it and skin. (**B**) **Deep glands of head and neck**:—Comprising those of head and neck. (**1**) **Those of head**:—Consisting of following groups:—(**a**) Lingual—on external surface of hyoglossus and geniohyoglossus. (**b**) Internal Maxillary—on lateral aspect of pharynx, behind buccinator muscle. (**c**) Posterior Pharyngeal—between posterior surface of pharynx and rectus capitis anticus major, near base of skull. (**2**) **Those of neck**:—Consisting of following sets;—(**a**) Superior set—along internal jugular vein, from base of skull to level of thyroid cartilage. (**b**) Inferior set—along internal jugular vein, from thyroid cartilage to near clavicle.

REMOVAL OF LYMPHATIC GLANDS OF NECK.

General Considerations.—In the case of diseased cervical glands, an operation may be undertaken—(**1**) for the removal of one or a few defined glands, in one or more of the regions of the neck, in which case a single or several incisions, more or less limited, are so placed as most readily and safely to expose the involved glands;—or (**2**) for the removal of glands widely, deeply, and indistinctly disseminated throughout the antero-lateral aspect of the neck, in which case one or more extensive incisions are necessary, both for the removal of the glands and in order to give room in which to safeguard important structures during their removal. Removal of disseminated cervical glands will be first described—and removal of isolated glands will be referred to under Comment.

Indications for Removal of Cervical Lymphatic Glands.—Chronic tubercular adenitis (most frequently); acute non-tubercular suppurative adenitis; enlargement secondarily from neighboring malignant growths.

Preparation.—Shaving of all hairy parts at site of and bordering upon field of operation.

Position.—Patient supine; shoulders raised; neck resting over a support, to render it prominent; head so turned as to increase prominence, length, and width of neck, and in order to drag glands out from under protecting tissues. Surgeon on side of operation; assistant opposite.

Landmarks.—The triangles of the neck.

Instruments.—Scalpels; scissors, straight, curved, blunt and sharp; dissecting forceps; toothed forceps; artery-clamp forceps; blunt dissector; retractors; tenacula; grooved director; aneurism-needle; needles; needle-holder; sutures; ligatures; sterilized water on hand to flood neck in case of opening large vein in an inaccessible locality.

Incision.—Various forms of incision have been used, singly or combined. Where the entire antero-lateral aspect of the neck is to be exposed, a $\sum$-shaped incision (Fig. 72) may be used—BC extending from over the mastoid process to the interval between the sternal and clavicular attachment of the sternomastoid, passing down the middle of the sternomastoid or along its anterior border—BA extending transversely forward from the upper end of the oblique incision to the angle of the jaw, and thence along the lower border of the jaw to the symphysis—CD extending transversely outward along the upper border of the clavicle, as far toward the acromioclavicular articulation as necessary. If only the anterior triangle of the neck be involved, the por-

tion ABC of the incision is alone used—if the posterior triangle, the portion BCD.

Operation.—(1) Incise directly through skin, superficial fascia, platysma, and deep fascia—the diagonal portion of the Σ-shaped incision being first made; that is, the portion over the anterior border of the sternomastoid. Sever the external jugular vein between two ligatures. Branches of the superficialis colli nerve will be cut, but the auricularis magnus and occipitalis minor should be retracted backward, if exposed. This incision is carried down to and exposes the whole length of the sternomastoid muscle. (2) Carry the upper incision transversely downward to the angle of the jaw,

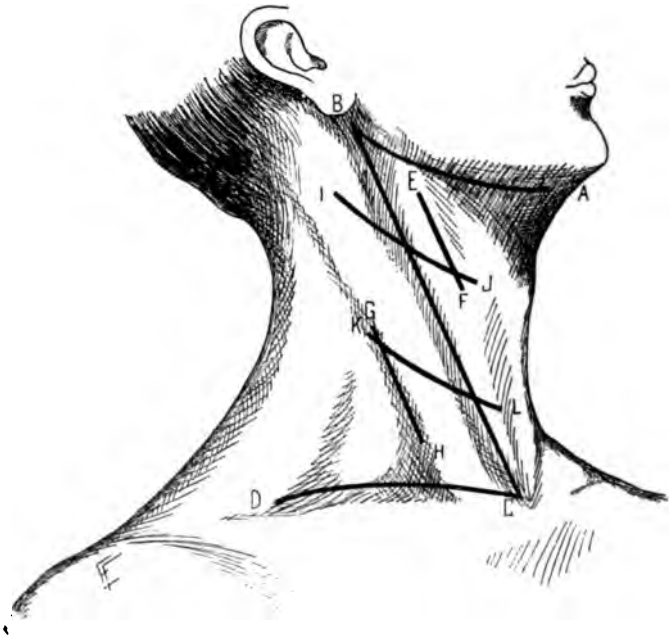

Fig. 72.—Incisions for Exposing Lymphatic Glands of Cervical Region:—BC, Line over anterior border of sternomastoid, from mastoid process to interval between sternal and clavicular origins of sternomastoid; BA, Line from mastoid process to angle of jaw, and thence forward along its lower border; CD, Line from sternoclavicular articulation outward along upper border of clavicle. Anterior triangle of neck is exposed by raising flap ABC; Posterior triangle, by raising flap BCD; Entire antero-lateral aspect of neck, by raising both flaps. Following incisions may be used for removing isolated groups of glands; EF, Incision parallel with anterior border of sternomastoid; GH, parallel with posterior border; IJ, Transverse oblique in upper part of neck; KL, Transverse oblique in lower part of neck.

and then forward along the lower border of the inferior maxilla toward the symphysis, passing through the skin, superficial fascia, platysma, and deep fascia—and exposing, without injury, the parotid gland, facial nerve, tributaries of temporomaxillary vein, facial artery and vein, submaxillary and submental glands. The facial artery and vein may be divided between two ligatures, if necessary. (3) The lower incision is now carried transversely along the upper border of the clavicle, as far toward its outer end as necessary—passing through skin, superficial fascia, platysma, and deep fascia—dividing some of the descending superficial branches of the cervical plexus and a few minor vessels. (4) Having now completed these three incisions,

two triangular flaps are carefully dissected up and turned aside—an anterior flap (ABC), having the same boundaries as the anterior triangle of the neck, is turned forward, hinging on the anterior median line of the neck—and a posterior flap (BCD), having the same boundaries as the posterior triangle of the neck, is turned backward, hinging on the anterior margin of the trapezius (or on a line posterior to that, if the lower transverse incision have been extended posteriorly to the acromioclavicular articulation). Thus, the superficial parts having been turned aside, the entire antero-lateral quadrilateral surface of the neck is exposed on a plane with the important structures and in easy access to those structures. (**5**) All glands are now dissected out, together with their surrounding connective tissue—being sought in the localities indicated in the above summary (see Lymphatic Glands of Head and Neck, page 134)—guarding, at the same time, the important anatomical structures enumerated under Surgical Anatomy of the Triangles of the Neck. (**6**) If avoidable, the sternomastoid should not be cut—it generally being possible, in such a free exposure, to retract it alternately well forward and backward in order to remove the glands partly or entirely covered by it, slightly flexing the chin on the sternum to lessen tension. Where, however, it proves a barrier to thorough and safe work, it should be unhesitatingly severed—the emergence of the spinal accessory nerve from its posterior border being exposed, and the muscle divided transversely below the nerve The upper end of the muscle is then turned upward and backward with the uninjured nerve, and the lower end downward and forward—and the important structures beneath it thus easily brought to view. (**7**) In completing the operation, the cut ends of the sternomastoid should be carefully sutured with interrupted buried catgut sutures. The flaps are now turned back into place and sutured throughout—the flaps being sutured to each other first, then along the superior transverse line, and, last, along the inferior transverse line—the wound being closed throughout with silkworm-gut or silk—and firm pressure, to occlude dead spaces, made in the dressing. The neck and head are steadied in some form of retentive apparatus until union has occurred.

Removal of Isolated Lymphatic Glands of the Neck.—These isolated glands will belong to one of the groups of superficial or deep glands given, with their relations, upon a preceding page. The position, direction, and extent of the incision for their exposure will be determined by the special group of glands involved and the extent of the involvement—the general rule being that the incision is so placed as to reach the site most readily and with greatest safety to neighboring structures—and may be a single vertical, transverse, or oblique straight incision, making an opening whose lips have to be retracted to expose the parts;—or a combination of these;—or a curved incision, thereby forming a flap, which is temporarily turned back. The two most generally used forms of incision, however, are those which are more or less parallel with one of the borders of the sternomastoid (Fig. 72, EF or GH)—or more or less parallel with the natural obliquely transverse crease crossing the neck about on a level with the hyoid bone, in the cleavage line of the skin (Fig. 72, IJ or KL). The incision may be placed over the submaxillary, superior carotid, or inferior carotid triangle, of the anterior triangle of the neck, or over the occipital or subclavian triangle, of the posterior triangle—or over the posterior aspect of the neck, between the anterior border of the trapezius and the posterior median line, and between the superior border of the scapula—or may involve several triangles.

Comment.—(**1**) Great care is necessary in removing glands from thin-

walled veins. Should a vein be wounded, the opening should be caught up instantly and laterally ligated, if the wound be appropriate, or sutured, or even transversely ligated. If so situated that closure cannot be immediately made, the part should be flooded with water, so that water stands over the open vein, to prevent the drawing-in of air until the vein can be secured. (2) The important nerves are to be particularly guarded. (3) The arteries and arterial hemorrhage give far less concern than the veins and venous hemorrhage. (4) It is better to dissect the glands out in masses or chains, together with their adherent connective tissue—invisible, impalpable glands being thus more thoroughly removed. (5) Glands should be removed with their capsules intact. (6) The sternohyoid and omohyoid may also be divided and subsequently sutured. (7) All bleeding should be immediately controlled as encountered, and ligated as soon as convenient.

SURGICAL ANATOMY OF AXILLARY REGION.

Description.—The axilla is a pyramidal space between the upper lateral wall of thorax and inner wall of arm—its apex corresponding with interval between first rib on inner side, clavicle in front, and upper edge of scapula behind;—its base, broad at chest and narrow at arm, is composed of skin and dense fascia, extending between inferior border of pectoralis major in front, and inferior border of latissimus dorsi behind.

Boundaries.—Anteriorly—pectoralis major (throughout); pectoralis minor (its center). **Posteriorly**—subscapularis (above); teres major and latissimus dorsi (below). **Internally**—first to fourth ribs; first to third intercostal muscles; serratus magnus. **Externally**—humerus; coracobrachialis; biceps.

Contents.—Arteries:—axillary (along external wall, nearer anterior than posterior boundary); superior thoracic; acromial thoracic; long thoracic; alar thoracic; subscapular; anterior circumflex; posterior circumflex. **Veins**:—axillary (to inner side of axillary artery); receiving venæ comites of brachial artery and tributaries of branches of axillary artery. **Nerves**:—brachial plexus lies to outer side of first part of axillary artery;—the second part of axillary artery has the outer, inner, and posterior cords of plexus in the relations expressed by their names;—the third part of the artery has, anteriorly, inner head of median nerve; posteriorly, musculospiral and circumflex; externally, median, musculo-cutaneous; internally, ulnar, internal cutaneous, lesser internal cutaneous. Posterior thoracic (on serratus magnus). Intercosto-humeral. External and internal anterior thoracic, crossing in front and behind axillary artery respectively. **Glands**:—see below.

Axillary Lymphatic Glands.—Are arranged in four groups: (a) Axillary glands proper—median set; three or four in number; along axillary artery and vein. (b) Pectoral glands; inner or anterior set; four or five in number; along long thoracic artery, below great pectoral muscles and on serratus magnus. (c) Subscapular glands—external or posterior set; two in number; along subscapular artery, under latissimus dorsi. (d) Subclavian or infraclavicular—superior set; two in number; near cephalic vein; just below clavicle in fossa under pectoralis major and deltoid, upon costocoracoid membrane.

Axillary Lymphatic Trunk.—Efferent trunk from above sets of glands—runs upward along subclavian vein—emptying into thoracic duct on left, and into right lymphatic duct on right.

REMOVAL OF AXILLARY LYMPHATIC GLANDS.

Description.—The removal of the axillary glands is done, in the majority of cases, in connection with the removal of neighboring malignant growths, especially those involving the breast—and, in such cases, the incision for exposing the axillary region is merely a prolongation into the axilla of the incision for the original operation. The steps, therefore, of the operation for the removal of these glands will be found sufficiently described under the operations for the radical removal of the breast (pages 582 to 585). Where it is planned to remove enlarged axillary glands alone and as a distinct operation, the incision is placed over the involved glands (Fig. 73).

Fig. 73.—Incision for Exposing Axillary Lymphatic Glands:—Passing between biceps and pectoral muscles, in front, and the scapular muscles, posteriorly, to which may be added one or more incisions at right angle, extending either in front of or behind the main incision.

SURGICAL ANATOMY OF SCARPA'S TRIANGLE.

Description.—A triangular area just below fold of groin.

Boundaries.— Base (above); Poupart's ligament. Externally; sartorius. Internally; adductor longus. Apex (below); junction of sartorius and adductor longus.

Roof.—Skin; superficial fascia; fascia lata.

Floor.— (From without inward.) Iliacus; psoas; pectineus; adductor brevis; adductor longus.

Contents.— Arteries; common femoral (from middle of base to apex); superior epigastric; superficial circumflex iliac; superficial external pudic; deep external pudic; profunda femoris. Veins; femoral (to inner side of artery); profunda femoris; tributaries of branches of femoral; internal saphenous. Nerves; anterior crural (to outer side of artery); crural branch of genitocrural; external cutaneous. Lymphatics; superficial and deep glands.

Inguinal Lymphatic Glands.—Consist of two following sets; (1) **Superficial Glands;** Oblique or Inguinal Set—along Poupart's ligament, upon fascia lata. Vertical or Saphenous Set—around saphenous opening and upon fascia lata. (2) **Deep Glands;** along upper part of femoral vessels, one or more being within femoral canal.

REMOVAL OF INGUINAL LYMPHATIC GLANDS.

Description.—The operation will differ according to site and amount of glandular involvement—and the lines of incision are given accordingly.

Indications.—Glands enlarged or broken down as a result of venereal disease; tubercular glands; simple, chronic, and suppurative adenitis; malignant involvement.

Preparation.—Groin shaved.

Position.—As for ligation of femoral artery at base of Scarpa's triangle (page 95).

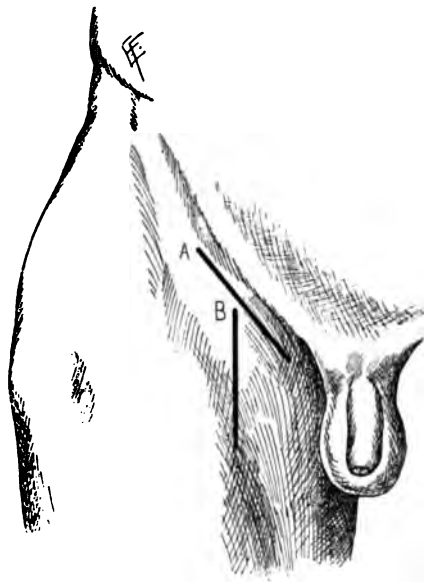

Fig. 74.—Incisions for Exposing Inguinal Lymphatic Glands:—A, Oblique incision just below and parallel with Poupart's ligament, for oblique superficial set of glands; B, Vertical incision over femoral artery, for vertical superficial and deep sets. A T-shaped incision may be made by uniting these, where all three sets are involved.

Landmarks.—Given under Surgical Anatomy of Scarpa's Triangle.

Instruments.—As for removal of cervical glands (page 135).

Incisions.—(1) Where the oblique (superficial) set of glands are involved—an incision may be made parallel with and just below Poupart's ligament, with its center over the enlarged glands (Fig. 74, A). (2) Where the vertical (superficial and deep) sets are involved—the incision is made along the course of the femoral artery, with its center over the enlarged glands (Fig. 74, B). (See ligation of common femoral at base of Scarpa's triangle, page 95.) (3) Where all three sets are involved—the incision may be a combination of the above two, being somewhat T-shaped.

Operation.—Divide skin and superficial fascia in the direction or directions indicated above. The superficial vessels encountered are ligated. The superficial glands (oblique and vertical sets) will be found upon the fascia lata, in the positions indicated. To reach the deep glands (lying along the great vessels) the fascia lata is incised in the line of the femoral artery (as for ligation of that artery). Important structures are to be avoided and the glands sought along the course of the artery and vein. The general principles mentioned under the removal of cervical lymphatic glands are applicable here—and elsewhere, wherever glandular tissue is removed.

THE NEW YORK LIBRARY. ACADEMY OF MEDICINE.

CHAPTER IV.

OPERATIONS UPON THE NERVES, PLEXUSES, AND GANGLIA.

Note.—The operations which may be performed upon Nerves, Plexuses, and Ganglia will be first described—and then the operations for the exposure of the more important nerves, plexuses, and ganglia will be given. Having exposed a nerve, any of the operations about to be described may be applied to it, as indicated.

NEUROTOMY.

Description.—Section of a nerve. Neurotomy may be transverse (*e. g.*, as when performed for neuralgia of a sensory nerve, or spasm of a motor nerve);—or longitudinal (*e. g.*, as done in some cases of neurorrhaphy and neuroplasty).

Indications.—Neuralgia of sensory nerves; spasm of motor nerves; preliminary to neurorrhaphy or neuroplasty.

Preparation—Position—Landmarks—Surgical Anatomy—Incision.—Determined by the special nerve involved.

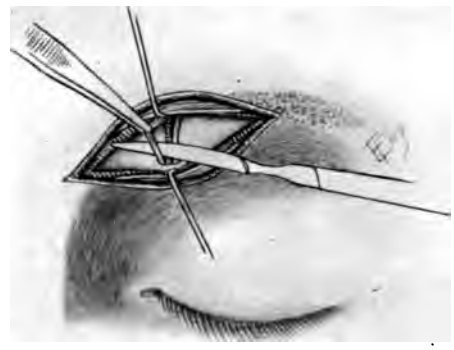

Fig. 75.—Neurotomy of Supraorbital Nerve.

Operation.—Having exposed and isolated the individual nerve, it is lifted from its bed by forceps and divided with a scalpel or scissors. The cut ends are allowed to fall back into place—or, better, should be so dropped back into the wound as to make re-union unlikely. The wound is closed as usual. No special after-treatment is carried out (Fig. 75).

Comment.—Chiefly applicable to smaller sensory nerves—and, rarely, smaller motor nerves. Not generally successful in neuralgias.

NEURECTOMY.

Description.—Excision of a nerve. Neurectomy may be partial or complete. As ordinarily performed, only a small part of the length of the nerve is removed.

Preparation—Position—Landmarks—Surgical Anatomy—Incision.—Determined by the special nerve.

Indications.—Neuralgia of sensory nerves; spasm of motor nerves.

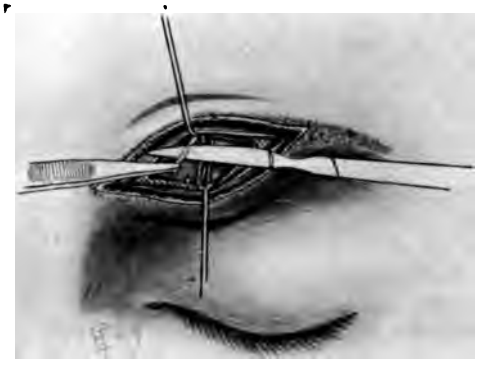

Fig. 76.—Neurectomy of Supraorbital Nerve.

Operation.—The nerve having been exposed and brought well into the field, is lifted out of its bed with forceps—and from 2 to 3 cm. (1 to 1¼ inches) of its trunk is excised with scalpel (preferable to scissors, which partly crush). The ends are then allowed to drop back into position—and the wound is closed (Fig. 76).

Comment.—Total excision is most frequently done by avulsion (page 143).

NEURECTASY.

Description.—Nerve-stretching.

Indications.—Neuralgia of sensory and spasm of motor nerves.

Preparation—Position—Landmarks—Surgical Anatomy—Incision.—Determined by the nerve operated upon.

Operation.—The nerve is freely exposed and separated by blunt dissection sufficiently for manipulation. Small nerves are stretched by means of a nerve-hook inserted beneath them. Large nerves are stretched by being grasped between thumb and finger—the nerve is steadily and evenly pulled from its center for about five minutes—then from its periphery for about five minutes. The extremes of force employed may be represented by a pull of a half-pound for the supraorbital—and from thirty to sixty pounds (according to the judgment of the operator) for the sciatic. The manipulation is done with as limited disturbance to the surrounding structures as possible. After the stretching, the nerve is dropped back into place and the incision closed. In the after-treatment, the part should be immobilized until union of the wound occurs. Temporary paralyses of motion and sensation are to be expected (Fig. 77).

Fig. 77.—Neurectasy of Infraorbital Nerve.

Comment.—Sensory nerves seem more dulled by traction in a direction away from the cord—motor nerves more dulled by traction toward the cord.

NERVE-AVULSION.

Description.—The tearing away of a nerve from its central and peripheral connections.

Indications.—Neuralgia. Chiefly used upon branches of the fifth nerve.

Preparation—Position—Landmarks—Surgical Anatomy—Incision.—Determined by the special nerve.



Fig. 78.—Nerve-avulsion of Infraorbital.

Operation.—Having exposed the nerve involved, it is grasped by catch-forceps (firmly, but not strongly enough to crush and break it)—and then slowly wound around the forceps (by twisting the latter between the fingers)—until the nerve is torn away from its connections, both proximally and distally. Branches of the nerve are also sometimes avulsed, to a greater or

less extent along with the main trunk—as well as a part or the whole of a ganglion. The nerve may, also, be partly cut—either distally (generally) or peripherally. The wound is closed throughout, in the usual manner (Fig. 78).

NEURORRHAPHY.

Description.—Suturing of nerve which has been partially or entirely divided. Neurorrhaphy may be primary, or immediate, where the nerve is sutured at once,—or secondary, where the suturing is done subsequent to repair of injury.

Indications.—Repair of injury to nerve. Neuroplasty.

Preparation—Position—Landmarks—Surgical Anatomy—Incision.—Determined by the nerve involved.

Operation of Primary, or Immediate, Neurorrhaphy.—The severed nerve-ends are exposed in the wound and brought well within reach. See if they be cleanly cut. If not, gently grasp them with forceps and cut them cleanly, and preferably transversely, with a sharp knife, with a minimum sacrifice of nerve-tissue. The ends are brought and held in apposition, in their normal relations, anterior aspect to anterior aspect, and the like. If

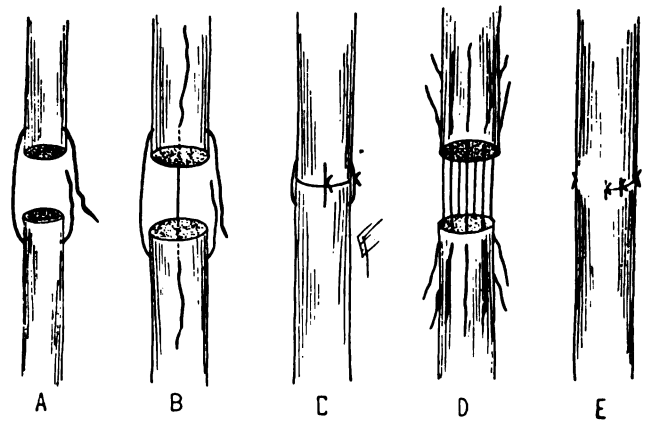

Figs. 79–83.—Methods of Nerve Suturing:—I.—A, B, C, Sutures passing through entire thickness of nerve and sheath; D, E, Sutures passing through nerve-sheath only.

the ends cannot be approximated, flex or extend the limb to increase the length, or stretch both ends gently (preferably grasping them with the fingers). It is desirable that there should be no tension upon the sutures. The junction is made with a fine cambric needle threaded with fine chromic catgut and held in a needle-holder. One of several methods of suturing may be adopted;—(a) The sutures may be passed entirely through the sheath and nerve, in two or more directions, and about 5 mm. (⅕ inch) from the ends. The needle passes from before backward through the entire thickness of the proximal end—then similarly through the distal end, from behind forward—and the suture is tied lightly, so as not to have tension. A second suture may be applied antero-posteriorly, or laterally—and as many as seem needed accurately to coapt the ends. This is the most general method of nerve-suturing (Figs. 79–81, A, B, C). (b) Sutures may be passed through the

nerve-sheath alone, encircling the nerve proper. This is the preferable operation—but is possible only in large nerves (Figs. 82-83, D, E). (c) Part of the sutures may pass through the nerve and sheath (as in a)—and part through the sheath only (as in b) (Figs. 84-86, A, B, C). (d) After

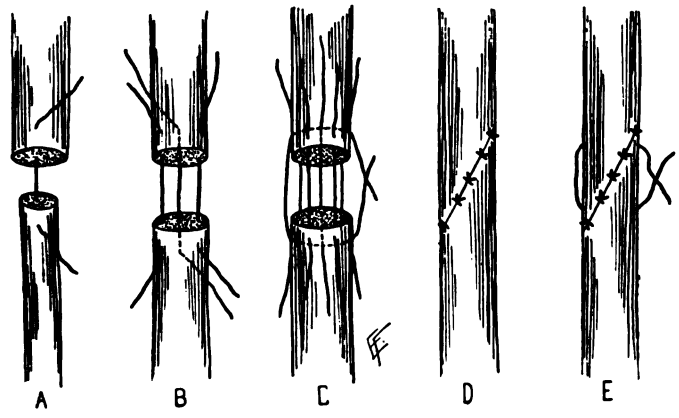

Figs. 84-88.—METHODS OF NERVE SUTURING:—II.—A, B, Sutures passing through sheath and part of nerve; C, Sutures through sheath, reinforced by relaxation-suture through entire nerve; D, Nerve cut obliquely and united by suture through sheath and part of nerve; E, Same with relaxation-suture.

paring the larger end, it may be split down its center for about 1.3 cm. (½ inch)—the smaller end may be beveled on two sides and sutured between the lips of the split end (Fig. 93, A). (e) One end may be beveled on its

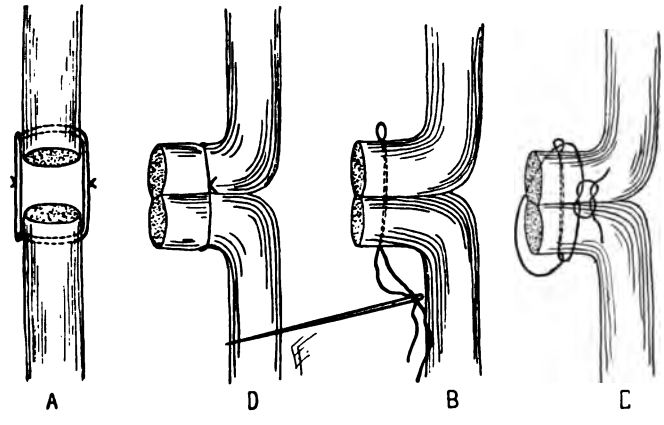

Figs. 89-92.—METHODS OF NERVE-SUTURING:—III.—A, Reinforcing through-and-through suture by lateral suture through loops of first suture; B, C, D, Union by approximation of lateral aspects of nerve, after freshening.

upper surface, the other on its lower surface—the two freshened surfaces are then placed in contact and sutured through and through (Figs. 87 and 88, D, E). This requires a greater length of nerve than some of the other methods. Other methods are shown in Figs. 89 to 92, and 94 and 95.

Having completed the union of the nerve-ends, the wound is sutured and the limb immobilized so as to minimize tension for about ten days—the part is then gently massaged daily and the splint reapplied between times and not removed for about six weeks. Primary union is particularly to be sought. The restraining splint should be such as will hold the part so that the nerve will be relaxed.

Operation of Secondary Neurorrhaphy.—Having applied Esmarch's bandage, one may cut directly down upon the supposed site of the nerve-ends. It is better, however, deliberately to incise for and expose both proximal and distal nerve-trunks, above and below the involvement, on anatomical grounds. Much difficulty may be experienced in finding the nerve-ends, unless traced down and upward, as the case may be, from the nerve-trunks. The proximal end is easier to find, and apt to be bulbous and sensitive. The distal end is apt to be atrophied. Sufficient freeing of the nerve-ends to enable them to meet is necessary. While in primary suturing the severed ends may or may not require trimming before suturing, in secondary suturing they are, in addition to being freed from connective tissue, always to be excised. Having identified the nerve-ends, dissect away all intervening fibrous tissue. With a sharp knife cut away transversely the proximal end until healthy nerve tissue is reached. In the case of the distal end, simply cut away enough of the upper end to afford good approximation (for degenerative processes will have extended far down this end under any circumstances). If the ends can now be made to meet without too much tension, they are sutured together by one of the methods described under primary neurorrhaphy. If greater length be necessary, as is almost invariably the case, it may generally be gotten by first carefully stretching the ends—after which they are united by suture. If sufficient length cannot be thus secured, neuroplasty must be done (page 147). Following secondary neurorrhaphy the wound is closed, the limb splinted, and the same after-treatment carried on as after the primary operation—although results are not to be expected so soon. Restoration of function may require from one to two years.

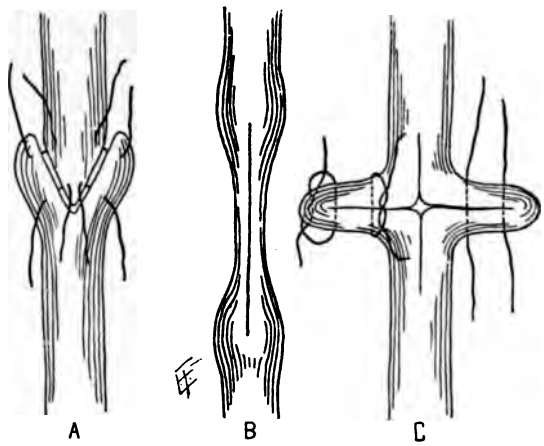

Figs. 93–95.—METHODS OF NERVE-SUTURING:—IV.—A, Suturing of beveled end between lips of split end; B, C, Method of uniting sound upper and lower portions of nerve by splitting and suturing contracted portion.

Comment.—Where stretching is resorted to to gain length in secondary suturing, it should be applied before excising the nerve-ends—traction being made upon the nerve-ends themselves, which are afterward removed. And if tension be too great upon the sutured ends, relaxation-sutures may be applied above and below the line of finer approximation sutures.

NEUROPLASTY.

Description.—The union of severed nerve-ends by processes of plastic elongation of the nerve itself,—or by the interposition of nerve or other

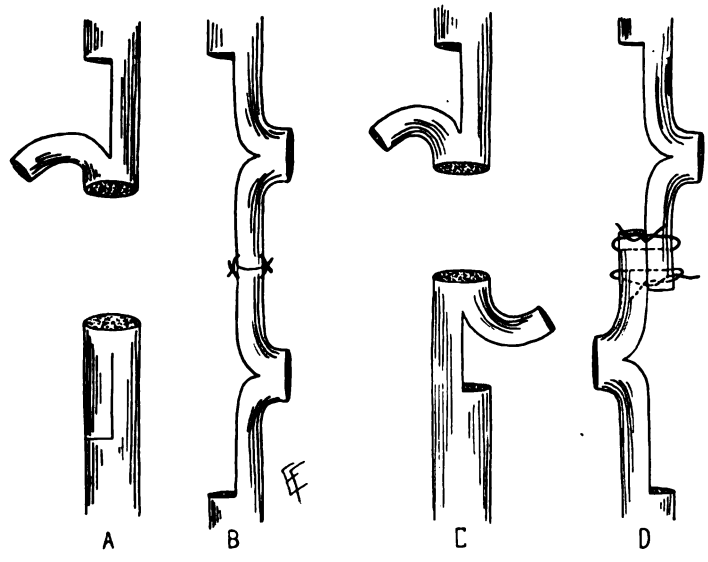

Figs. 96–99.—NEUROPLASTY:—I.—A, B, Union by splitting both ends of nerve and uniting split ends end-to-end; C, D, Same, with split ends united laterally.

material—in cases where the loss of nerve-substance is so great that the severed ends cannot be brought and held together by the ordinary methods

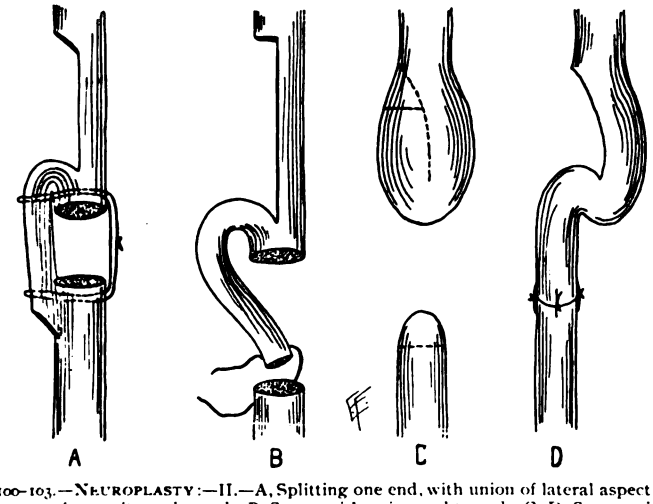

Figs. 100–103.—NEUROPLASTY:—II.—A, Splitting one end, with union of lateral aspect of split end to lateral aspect of opposite entire end; B, Same, with union end-to-end; C, D, Same as in B, in case of bulbous ends.

of suturing. The object sought is the supplying of a substance between the cut ends along which the nerve-fibers may grow from the proximal to the distal end (as the tendrils of a vine grow along a trellis).

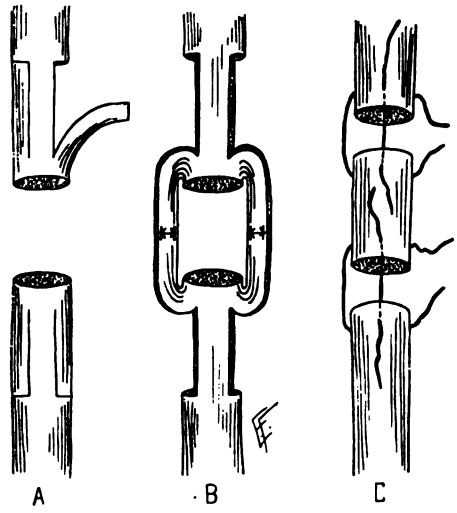

Figs. 104-106.—NEUROPLASTY:—III.—A, B, Doubly splitting both ends, with union of split ends end-to-end; C, Interpolation of section of nerve.

Indications. — Where, in primary operations, considerable nerve-substance has been destroyed by the cause of the injury,—or, in secondary operations, the retraction of the severed ends has been very great—so that by no other means can the ends of the nerves be brought and kept together.

Preparation — Position — Landmarks—Surgical Anatomy — Incision. — Determined by the special operation.

Operation. — Having exposed and isolated the severed ends, and, in the case of secondary operations, freed them from connective tissue and freshened them by partial excision, one of the following means of bringing and holding the ends in contact is resorted to:—(a) At points as far from the ends of the nerves as indicated by the length of the intervening space to be filled, divide each nerve half-way, transversely—split each end back to within about 6 mm. (¼ inch) of its end—bend the two cut portions toward each other—and suture them end to end, or laterally (Figs. 96–99, A, B, C, D). In filling smaller gaps, one trunk only may be split—bent back to the other end—and both freshened and sutured (Figs. 100 and 101, A, B). (b) Sections of nerves from a freshly amputated human limb, or from the lower animals, may be interposed in the gap and sutured at both ends by one of the methods given under neurorrhaphy. This interposed part does not grow, but only serves the rôle of a trellis (Fig. 106, C). (c) A solid cylinder of decalcified bone may be interposed and sutured to the ends of the nerves. (d) Strands of fine catgut may be made to bridge the interval, as a guide to the new nerve-fibers (Fig. 107, A). (e) The proximal and distal ends of the nerve may be enclosed in a hollow cylinder of decalcified bone (Figs. 108 and 109, B, C). (f) Proceed as in Fig. 104, A—then shift the

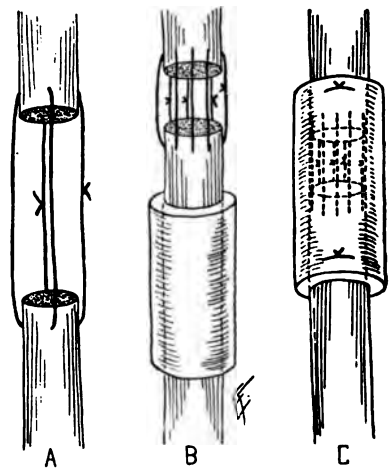

Figs. 107-109.— NEUROPLASTY:— IV.— A, Union by strands of gut alone; B, C, Same, reinforced with decalcified bone cylinder.

cut ends laterally, and approximate as shown in Fig. 105, B. (g) Combine methods (d) and (e)—the combined method of bridging with catgut and enclosure in decalcified bone tube. One end of the catgut bridge is slipped through the tube, sutured to the other end, and drawn back within the tube (Figs. 108 and 109, B, C). (h) Shortening of the limb, by resection of its bone or bones, to allow of approximation of the ends of the nerve. (The musculospiral has been thus successfully treated.) Of the above methods, method (a) is the one most generally used. Having completed the neuroplastic operation, the wound is closed and the part immobilized in a position to relax the nerve.

NERVE-GRAFTING; NERVE-IMPLANTATION.

Description.—The grafting of the ends of an injured nerve into the trunk of a neighboring nerve—the severed upper end being grafted into the intact nerve at a point opposite its level, above—and the severed lower end grafted into the intact trunk opposite its level, below—that is, at points where they can be conveniently brought into contact with the sound nerve. The object sought is to switch the interrupted nerve-stream, or nerve-impulse, from the proximal end of the cut nerve into the neighboring sound nerve—thence to have it conveyed along this used nerve down to the point where

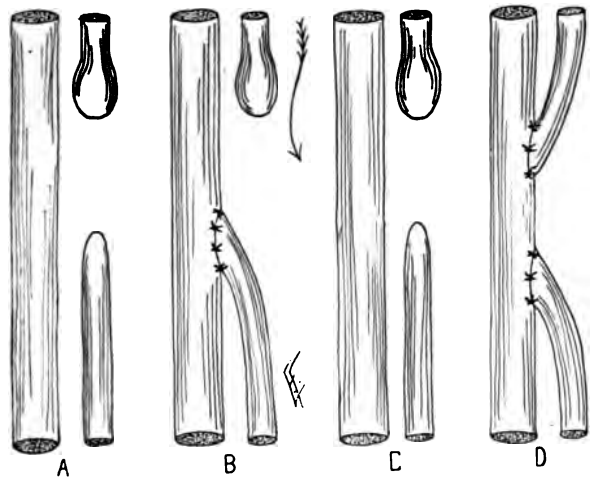

Figs. 110–113.—NERVE-GRAFTING:—I.—A, B, Engrafting of freshened lower end of divided median nerve (for instance) upon intact ulnar nerve; C, D, Engrafting of freshened upper and lower ends of divided median nerve upon intact ulnar nerve.

the distal end of the cut nerve is sutured to the utilized nerve—and thence returned to the original nerve and transmitted along the distal portion of the cut nerve to its final distribution, as though no interruption to its normal course and transmission had occurred. An illustration would be a divided median nerve and an intact ulnar nerve—where the upper end of the median nerve is sutured to the upper part of the ulnar—and the lower end of the median to the lower part of the ulnar (Figs. 112 and 113, C, D). The object finally sought is to have nerve-fibrils grow down this nerve from the proximal

cut end to the distal cut end. The method is of limited application, because of the necessity of finding large nerves in close proximity—the upper extremity being about the only locality in which the method can be utilized (Figs. 114 and 115).

Preparation—Position—Landmarks—Surgical Anatomy—Incision.—Determined by the individual operation.

Operation.—Expose, isolate, and excise the proximal and distal ends of the severed nerve, supposing it to be a secondary case. Also through

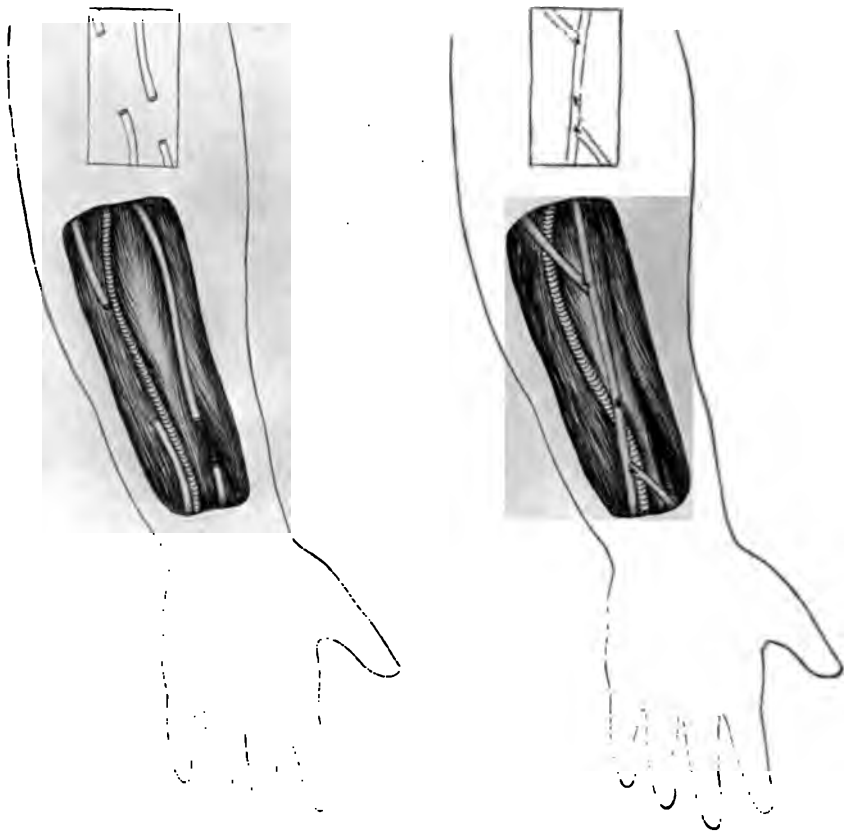

Figs. 114 and 115.—NERVE GRAFTING:—II. A (to left), Showing ulnar and median nerves divided at different heights. B (to right), Union of upper end of median to lower end of ulnar;—followed by engrafting of upper end of ulnar and lower end of median into this new trunk.

the original incision, expose the neighboring nerve upon which the grafting or implantation is to be made. By means of curved scissors, remove a limited portion of its sheath, on the lateral aspect of the nerve, at the sites where the upper and lower severed nerve ends are to be grafted. The obliquely or transversely divided ends of the involved nerve are to be sutured to the denuded lateral aspect of the intact nerve, above and below, by fine chromic sutures passing through the sheath of the nerve ends, on the one hand, and through the sheath and part of the thickness of the intact nerve at the

bared sites, on the other hand. Having completed the nerve-suturing, if the neighboring parts have been disarranged, these should be rearranged—by buried catgut sutures, if necessary. The wound is then closed throughout. The part should be immobilized in a position of relaxation of nerve-tension until union has occurred—and subsequently treated as described under neurorrhaphy.

Comment.—The intact nerve may be split at the two places to receive the freshened severed ends. It seems to make no difference whether a sensory nerve be grafted to a motor or to a mixed nerve—or vice versa.

OPERATION FOR RELIEF OF NERVE COMPRESSED BY BONY OR FIBROUS CICATRICIAL TISSUE.

Description.—Nerves are sometimes involved and pressed upon in the processes of repair following injury of bones and soft parts, or in the processes of disease, and eventually become so firmly compressed as to have their function impaired—in which case an operation to free them for pressure is indicated.

Position—Landmarks—Incision.—Dependent upon nerve involved.

Operation.—The steps of the operation will be determined by the position and nature of the compression. Where fibrous cicatricial tissue surrounds the nerve, the mass is to be exposed by dissection—the nerve is to be isolated either above or below the mass and is to be followed through it and dissected out from it. The cause of compression, as far as possible, is to be removed, so as to avoid a recurrence. Where a bony callus surrounds the nerve, this is to be reached by the safest route through the muscular planes—the nerve being similarly isolated above and below the mass—and freed through it. It is often necessary to chisel away as much of the callus as imprisons the nerve—and in order to render a recurrence of compression unlikely. The wound is closed as usual.

Comment.—Nerves may be compressed by growing tumors—their relief being determined by the treatment adopted for the tumor.

INTRANEURAL INFILTRATION FOR REGIONAL ANESTHESIA.

Description.—The injection of a sterilized anesthetic solution into a nerve-trunk. The injection may be made at the site of the proposed operation, or above the site.

Indications.—To produce anesthesia in the region supplied by the nerve, for the purpose of operating at any magnitude. Especially indicated in those portions of the body which may be more or less isolated,—and in those cases in which general anesthesia is contraindicated.

Position—Landmarks—Incision.—Determined by the special operation.

Operation.—The anesthetic fluid may be injected at the site of operation or above it;—(**a**) Where the Injection is made into the Nerve-trunk above the site of Operation—the anesthesia being produced in the region supplied by the nerve:—(Suppose the injection be made into the sciatic nerve, for amputation of the leg); To prepare the way for the incision, anesthetize the skin by intradermal infiltration—and the connective tissue by subdermal (subcutaneous) infiltration. Expose the sciatic nerve above the bifurcation

into internal and external popliteal and isolate it sufficiently for manipulation. Insert the needle of the syringe through the sheath of the nerve and into and among its fibers—and slowly inject the anesthetizing fluid (the amount determined by the nature of the solution and size of the nerve) until the entire extent of a transverse section of the nerve has been infiltrated or "blocked"

Fig. 116.—INTRANEURAL INFILTRATION FOR REGIONAL ANESTHESIA:—The great sciatic nerve being here infiltrated.

(Fig. 116). If this single injection be considered sufficient to last throughout the operation, the wound may be at once closed—otherwise it is temporarily packed with gauze. The limb is elevated and exsanguinated by gravity. A circular constrictor is applied above the site at which the nerve was infiltrated. Within a few minutes of the infiltration, the distal regions supplied by the

nerve will be completely anesthetic, and any operation may be performed thereon, as long as the constrictor remains *in situ*. (b) Where Infiltration is made into Nerve-trunks as exposed in the course of an Operation:—Anesthetize the skin by intradermal infiltration, and the connective tissue by subdermal infiltration. As each nerve is exposed, it is isolated, taken up, and infiltrated as in the above method. Where the case is a limb, a circular constrictor is used as above. Where the region is such an one as is involved in the radical operation for inguinal hernia, no arrest of circulation is attempted. In this method the anesthesia is complete not only at the site infiltrated, but in the regions supplied by the infiltrated nerves—but lasts a shorter time, unless the infiltration be repeated, than where a constrictor can be applied.

Nature of the Anesthetic Solutions.—These have been of various constitutions and percentages—there being no recognized standard solution universally employed in this comparatively new field of surgery. Sterilized

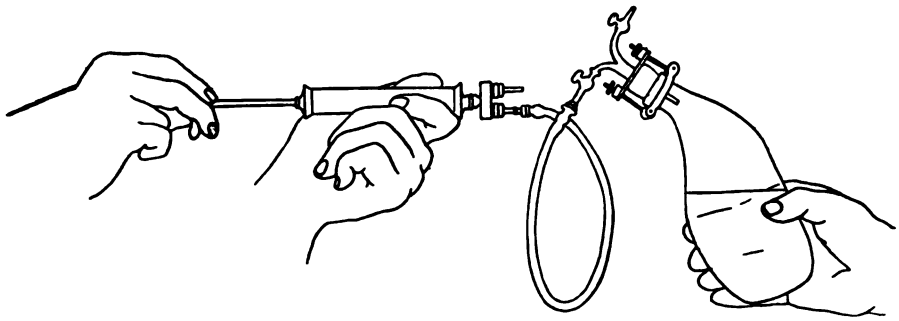

Fig. 117.—MATAS'S APPARATUS FOR PARANEURAL INFILTRATION OR ŒDEMATIZATION:—Air for pressure is here being pumped into the bottle containing the anesthetic solution. (Modified from Matas.)

solutions of cocain, of eucain B, of nirvanin, of Schleich's solution, and others, have been used. Almost any suitable syringe may be used, though a special instrument is more appropriate. Matas (whose writing upon local anesthesia this article largely follows) has devised a special form of injecting apparatus for infiltration in the paraneural method (Fig. 117).

Comment.—If the site of operation be supplied entirely by one nerve, that nerve alone need be infiltrated, at some convenient point proximal to the site of intended operation. If the site of operation, however, be supplied by several nerves, each has to be separately infiltrated;—for example, in the operation of amputation of the leg described above, if the operation is to be above the level of the tuberosity of the tibia, the anterior crural nerve is to be also injected,—if below that level, the long saphenous nerve is to be injected instead of the anterior crural—the sciatic being, of course, infiltrated in both instances. The entire upper limb can be anesthetized by infiltrating the brachial plexus above the clavicle.

PARANEURAL INFILTRATION FOR REGIONAL ANESTHESIA.

Description.—The injection of a sterilized anesthetic solution into the tissues immediately surrounding a nerve-trunk.

Indications.—To produce anesthesia in the region of the infiltration and as far beyond as the solution is diffused.

Position—Landmarks.—Determined by the special operation.

Operation.—Without making any incision for the exposure of the nerve, the anesthetic solution is injected first intradermally, to deaden the site superficially, and then into the tissues immediately in the neighborhood of the nerve, and as near to the nerve as possible. This infiltration of the tissues alongside of the nerve is done upon a knowledge of the anatomy of the nerve and its relation—and is meant to "envelope the nerve in an anesthetic atmosphere." In the case of dealing with an extremity, a few minutes after the infiltration the part is elevated, exsanguinated by gravity, and a circular constrictor applied above the region of infiltration—subsequently

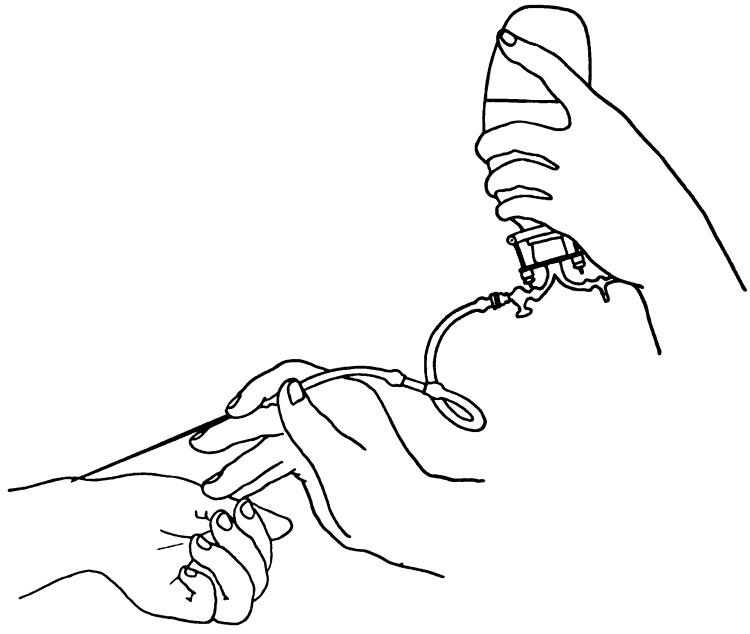

Fig. 118.—Paraneural Infiltration in the Course of the Radial Nerve. (Modified from Matas.)

to which the parts below the infiltration will be anesthetized by the diffusion of the anesthetic solution (Fig. 118). In other localities no attempt to control the circulation is made. The anesthetic solutions and the special syringe for injection are mentioned under Intraneural Infiltration.

Comment.—This method is more applicable to smaller extremities and parts—while the intraneural method to the larger. The paraneural infiltration for regional anesthesia differs from local infiltration for regional anesthesia (which may be represented by the common use of cocain hypodermatically) in that in the latter no attempt is made to infiltrate along the anatomical course of the nerves, but the injection is made almost at random into the cutaneous and subcutaneous tissue.

SURGICAL ANATOMY OF GASSERIAN GANGLION OF TRIFACIAL NERVE.

Description and Relations.—(**a**) Both sensory and motor root of the trifacial pass downward and forward through an aperture in dura mater, which lies under cover of tentorium cerebelli and a little to outer side of apex of petrous portion of temporal bone, to enter Meckel's space, between the supporting and periosteal layers of dura mater, in which space the sensory portion enlarges into the gasserian ganglion. (**b**) The gasserian ganglion, of somewhat semilunar form, with convexity forward, rests in depression upon upper surface of petrous portion of temporal bone, near its apex—and also to a slight extent upon cartilage which occupies foramen lacerum medium. Its upper surface is firmly attached to dura mater (roof of Meckel's space)—its lower surface, less firmly (to floor of Meckel's space). Its inner part lies near posterior extremity of cavernous sinus and internal carotid artery. The motor root and the large superficial petrosal nerve lie beneath the ganglion. From its convex antero-external border are given off the following main divisions;—Ophthalmic, passing out through sphenoidal fissure; Superior Maxillary, passing through foramen rotundum; Inferior Maxillary, passing through foramen ovale and being joined immediately after its exit by the motor root, which also passes through foramen ovale separately.

INTRACRANIAL EXPOSURE OF GASSERIAN GANGLION AND THREE DIVISIONS OF FIFTH NERVE.

HARTLEY-KRAUSE OPERATION.

Description.—Osteoplastic resection of temporal region with temporary turning down of flap of bone and soft parts and separation of dura mater from middle fossa of skull—the ganglion and three divisions of the fifth nerve being exposed without opening dura.

Preparation.—Head shaved.

Position.—Patient on back; head to one side and supported by firm pillow. Surgeon at side of head, either in front of or behind patient. Assistant opposite.

Landmarks.—External angular process of frontal; tragus of ear; supratemporal ridge.

Incision.—A horseshoe-shaped incision is made over the temporal region, its anterior extremity being near the external angular process of the frontal bone, its posterior extremity near the tragus of the ear, and the highest part of the curve reaching the supratemporal ridge (Fig. 119).

Operation.—(**1**) The above incision passes through all the soft tissues and periosteum directly to the bone, along the entire line. (**2**) With periosteal elevator, the soft parts of the flap are freed from the bone to a slight extent only, around the entire incision line—the freeing at the two ends of the base-line being a little more extensive. Throughout the rest of its extent, the flap remains adherent to the underlying bone. (**3**) With a trephine of about 1.3 cm. (½ inch) diameter, two discs of bone are removed, the anterior with its center over the tip of the sphenoid wing, the posterior having its center over a point 2.5 cm. (1 inch) vertically above the external auditory meatus. From these trephine-openings the dura is separated as far as possible, both along the straight basal line connecting the two openings, and in the direction in which the convex bone-section is to be made. (**4**) A section of bone similar

in shape to the skin incision, but smaller in size, is now made. This section is made from the squamous portion of the temporal and greater wing of the sphenoid—the basal attachment being somewhat narrower than the greatest transverse measurement of the convex portion. This bone-section was formerly made by a special chisel cutting a triangular groove—but is now made by a motor or other saw—the section beginning at one trephine-opening

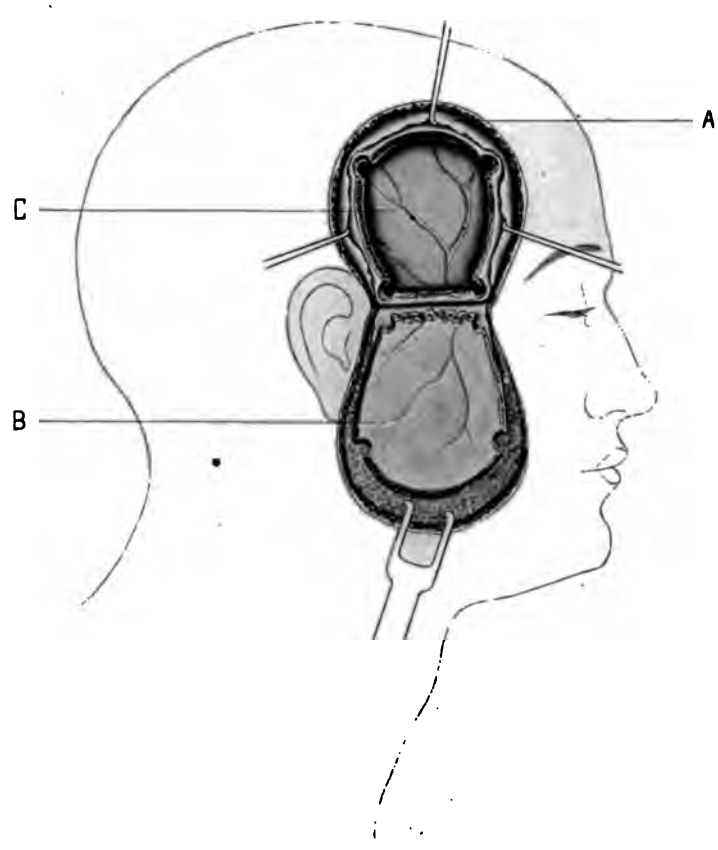

FIG. 114.—EXPOSURE OF GASSERIAN GANGLION BY OSTEOPLASTIC FLAP—PREPARATORY TO THE HARTLEY-KRAUSE OPERATION: 1.—A, Periosteum; B, Horseshoe flap broken back and turned down; C, Dura mater, with anterior and posterior branches of middle meningeal artery.

and ending at the other, care being taken to do no damage to the dura. (5) The bone being thus cut through everywhere except across its basal line, some stout instrument (such as an osteotome or elevator) is inserted into the groove at its greatest convexity, resting against the parietal bone as a fulcrum —then, with a sharp, sudden movement, this flap of skin, muscle, periosteum,

and bone is prized outward and downward, generally snapping directly and evenly across the basal line just above the zygomatic arch, and remaining hinged by the soft parts—and exposing an area of brain (covered by dura mater) of about 5 to 7.5 cm. (2 to 3 inches) in diameter (Fig. 120). (6) If the middle meningeal artery is found injured, it is tied as near the foramen spinosum as possible. (7) The dura mater and temporosphenoidal lobe of

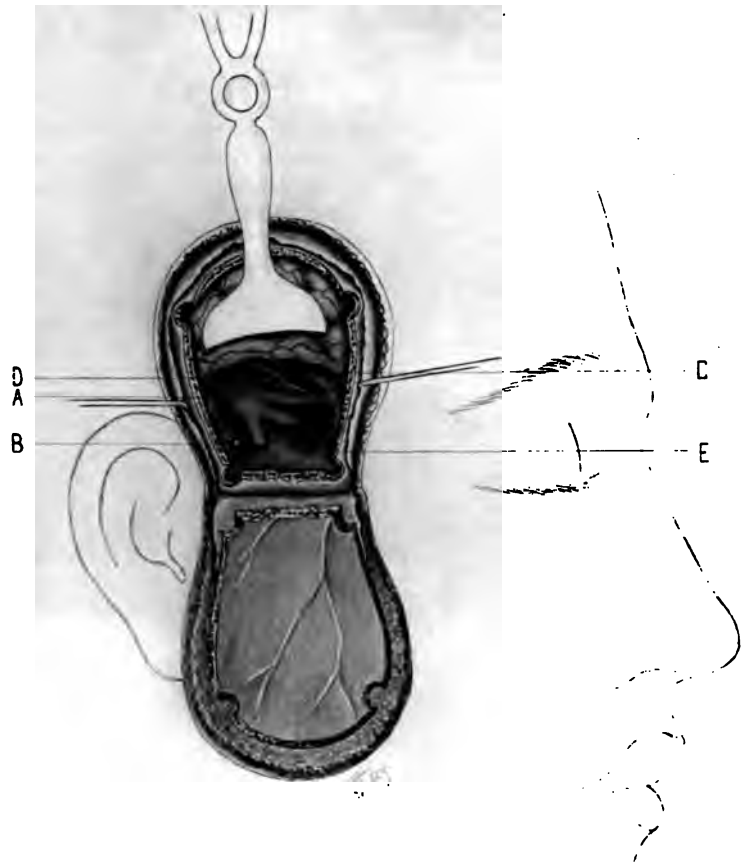

Fig. 120.—Exposure of Gasserian Ganglion by Osteoplastic Flap, by the Hartley-Krause Method:—II.—The brain elevated and structures in middle fossa shown. A, Gasserian ganglion, with first division passing through sphenoidal fissure; second, through foramen rotundum; third, through foramen ovale; B, Middle meningeal artery passing through foramen spinosum; C, Position of cavernous sinus; D, Position of common carotid. The third nerve (above) and fourth nerve (below) are seen passing between the first division of the fifth nerve and the cavernous sinus. The dura mater forming Meckel's space is not here shown. E, Floor of middle fossa.

the brain are now separated from the middle fossa of the skull. This is done in the direction toward the apex of the petrous portion of the temporal bone, and is accomplished by the fingers or a piece of gauze, or by a curved, blunt elevator. Sometimes the dura is considerably torn, and sometimes the artery is torn whether the dura is or not, requiring temporary packing of the bony groove to control the hemorrhage, where ligature is impossible.

Injured dura should be sutured wherever possible. (8) The three divisions of the nerve are now seen and are traced back from their foramina. The positions of the carotid artery and cavernous sinus are located as nearly as possible, for the purpose of guarding them. (9) Isolate and cut the first, second, and third divisions close to the sphenoidal fissure, foramen rotundum, and foramen ovale, respectively. Secure the proximal ends of the severed nerves with forceps or silk, and, practising traction upon them, trace them back to the gasserian ganglion—after incising the dura mater over them. Then, raising the ganglion from its bed, sever its connections with the brain close to the dura mater, and, if possible, without including or injuring the motor root. (10) At the end of the operation the dura and cerebral convolutions are allowed to fall into place—the flap of bone and soft parts is turned up—and sutures applied to skin and muscles.

Comment.—(1) The width of the basal line of bone may be decreased by rongeur forceps, thus increasing the likelihood of a clean, transverse breakage—or a Gigli saw may be conducted under the bone at its base and made partly to divide it. (2) In the use of either chisel or saw, the inner tablet of the skull may be left uncut in two or three places, over a limited extent, so that when the flap is broken back, these parts of the vitreous are left as shelves for the flap to rest upon when turned back into place. (3) Bleeding may be so great as compel one to pack and finish the operation in two stages. (4) The advisability of removing the first division is doubtful, because of the trophic changes which follow in the eye. The first division is never involved alone. (5) The motor root should always be left undisturbed, if possible—to avoid paralysis of the muscles of mastication. It is more apt to be injured if the dura be opened over the ganglion and the sensory root be cut between the ganglion and the pons. When possible it is best to cut the second and third divisions close to the foramen rotundum and foramen ovale respectively—dissect them back to the ganglion, and remove the parts of the ganglion corresponding to these divisions, leaving untouched the first division, with its corresponding ganglion and the motor root. (6) If the first division be removed, with the corresponding part of the ganglion, especial care is needed not to harm the cavernous sinus and the nerves to the eye—to aid in avoiding which, the second and third divisions should be removed first to give more room. If the first division be accidentally severed, leave the lacerated end as near the remains of the ganglion as possible. (7) If much oozing follows packing, wick or gauze drainage is indicated for twenty-four or forty-eight hours. (8) The chief dangers of the operations are—injury to internal carotid and cavernous sinus; laceration of brain; injury to nerves of eye (third, fourth, and ophthalmic division); hemorrhage from middle meningeal artery. (9) In Horsley's method of intracranial exposure of the gasserian ganglion a large soft flap is turned down from the temporal region, the underlying bone is removed by trephine and bone forceps (not to be returned), the temporosphenoidal lobe exposed, the dura incised, the ganglion exposed, and the root cut on the proximal side of the ganglion.

EXTRACRANIAL EXPOSURE OF GASSERIAN GANGLION AND THREE DIVISIONS OF FIFTH NERVE.

ROSE'S METHOD.

Description.—The ganglion is approached through the pterygomaxillary fossa, the zygoma being temporarily and the coronoid process of the inferior

maxilla permanently resected, and the trephine applied to include the anterior and outer portion of the foramen ovale.

Preparation.—Head shaved; eyelids stitched together with horsehair or other sutures.

Position.—As in preceding operation.

Landmarks.—Outer canthus of eye; zygomatic arch; meatus auditorius externus; angle and horizontal ramus of lower jaw.

Incision.—Begins near outer canthus of eye, about 1.3 cm. (½ inch) below the external angular process of the frontal—passes backward along the upper border of the zygoma to its posterior extremity—thence downward just in front of ear to the angle of the jaw—thence forward along the horizontal ramus of the jaw to the facial vessels.

Operation.—(1) Reflection of the Skin Flap;—Incise through skin and fascia only, along the above line. Raise this semicircular skin flap without harming the facial nerve or Stenson's duct. (2) Exposure of the Pterygoid Space;—Incise down through the periosteum for the entire length of the zygoma, and detach the periosteum. Drill (for later wiring of the bones) two holes through the zygomatic process of the malar, and two through the root of the zygoma. Divide the bone (downward and forward) between the two anterior holes—and also between the two posterior holes. Displace the zygoma downward and backward, bringing the masseter with it (dividing the necessary muscle-fibers). The coronoid process is exposed and cut obliquely downward and forward, as low as possible, then turned upward, and, together with tendon, cut away (there being no object in retaining it, as it would waste with the other muscles of mastication supplied by the motor fibers of the third division). (3) Exposure of the Foramen Ovale;—Expose the internal pterygoid by removing the overlying fat and connective tissue. The internal maxillary artery, which is generally found upon the muscle, is divided between two ligatures. The inferior dental and lingual gustatory nerves are sought at the lower border of the external pterygoid, cut, and their proximal ends tied with silk, to serve as guides. Expose the foramen ovale on the under surface of the great wing of the sphenoid, by partly cutting away and partly retracting away (by scraping) the external pterygoid—thus exposing both the great wing of the sphenoid and the external pterygoid plate. The foramen ovale is sought by following up the silk ligature, drawing the nerves of the third division taut, and also by the finger feeling in its known position, a little behind and external to the external pterygoid plate, remembering that just to the inner side and behind the foramen ovale lie the eustachian tube and the middle meningeal artery about to enter the foramen ovale. Bleeding is apt to be considerable here, especially from the veins of the pterygoid plexus and from veins passing through the foramen ovale between the pterygoid plexus and the cavernous sinus. This hemorrhage is controlled by gauze packing. (4) Opening the Base of the Skull;—A small, long-handled trephine is placed just in front and to the outer side of the foramen ovale, so that the margin of the foramen is included in the disc of the bone to be removed. (5) Division of Nerve-trunks and Partial Removal of the Ganglion;—The trephine-opening having been cleared and sufficiently enlarged by chisel or forceps, the surgeon follows, by means of the silk ligature, the third division up to the ganglion, which is loosened from its bed and the second and third divisions freely resected—the first being left undisturbed. (6) Closure of the Wound;—The wound having been irrigated with 1 : 4000 bichlorid, dried and dusted with iodoform, the previously drilled zygoma is wired, the temporal fascia sutured to the

cut margin of the fascia over the zygoma, and the wound closed without drainage. The eyelid stitches are removed in three or four days.

Comment.—(1) The operation may be performed in two stages. (2) The coronoid process may be drilled (for wiring) before cutting. (3) The extracranial method of exposing the ganglion is preferable.

SURGICAL ANATOMY OF SUPRAORBITAL BRANCH OF FRONTAL NERVE.

Description.—Passes forward from bifurcation of frontal nerve and leaves orbit through supraorbital notch (or foramen)—and, giving off palpebral branches, ascends vertically upward close to bone, beneath orbicularis palpebrarum and occipitofrontalis to forehead, where it divides into cutaneous and pericranial branches. The supraorbital vessels lie on its outer side.

EXPOSURE OF SUPRAORBITAL BRANCH OF FRONTAL AT SUPRAORBITAL FORAMEN.

Position.—Patient supine; head slightly elevated. Surgeon on side of operation, or above head.

Landmarks.—Supraorbital notch (or foramen)—which, if not easily felt, lies at junction of inner and middle thirds of supraorbital margin.

Incision.—Transverse, about 2.5 cm. (1 inch) in length, along supraorbital margin, with center over position of supraorbital notch (or foramen)—the eyebrow having been previously shaved.

Operation.—Having steadied the brow by the first finger of left hand (which also draws up the soft parts so as to hide subsequent scar) and depressed lid with left thumb, carry the above incision through skin, fascia, and orbicularis palpebrarum—when the nerve will be found upon the periosteum, accompanied by its vessels.

SURGICAL ANATOMY OF SUPERIOR MAXILLARY BRANCH OF TRIFACIAL AND MECKEL'S GANGLION.

Description.—Arises from center of gasserian ganglion—runs forward through foramen rotundum—traverses upper part of sphenomaxillary fossa—enters orbit through sphenomaxillary fissure—thence courses forward along infraorbital groove, accompanied by infraorbital artery, to infraorbital canal—along which it passes to emerge upon face through infraorbital foramen, as the infraorbital nerve, terminating beneath levator labii superioris muscle in a leash of branches. The distance of infraorbital foramen from foramen rotundum is about 5 cm. (2 inches).

Sphenopalatine or Meckel's Ganglion.—Placed deeply in sphenomaxillary fossa, beneath superior maxillary nerve, near sphenopalatine foramen. Its relations are:—Superiorly, superior maxillary nerve; Posteriorly, sphenoid bone and vidian canal; Externally, internal maxillary artery and external pterygoid muscle; Internally, vertical plate of palate and sphenopalatine foramen.

Comment.—The posterior superior dental is given off from the superior maxillary just before the nerve enters the infraorbital canal—the middle

superior dental, at the back part of the canal—and the anterior superior dental just before its exit upon the face. To insure, therefore, the removal of the origin of the posterior superior dental nerve, the trunk has to be removed as far back as Meckel's ganglion.

EXPOSURE OF SUPERIOR MAXILLARY NERVE AND MECKEL'S GANGLION BY THE ANTRAL ROUTE.

CARNOCHAN'S OPERATION.

Description.—The superior maxillary nerve is removed from the infraorbital foramen to the foramen rotundum, together with Meckel's ganglion—by following the course of the infraorbital canal, and removing parts of the anterior wall, roof, and posterior wall of the antrum of Highmore.

Position.—Patient supine; head elevated and turned slightly to one side. Surgeon on side of operation.

Landmarks.—Infraorbital foramen (which is about 8 mm.—⅓ inch—below the infraorbital margin, and on a line drawn from the supraorbital foramen to a point between the two bicuspids of both jaws).

Incision.—V-shaped (two sides of an equilateral triangle, each side being about 2.5 cm.—1 inch—long), placed with its center over the infraorbital foramen and its two limbs upward.

Operation.—(1) This incision is carried to the bone. The flap is then turned up over the closed eye and its apex stitched to the forehead. (2) The infraorbital nerve is isolated at the foramen, cut as long as possible, and tied with silk—to serve as a guide and means of traction. (3) A trephine of about 1.3 to 2 cm. (½ to ¾ inch) in diameter, or a chisel, is now applied to the cleared bone, and a portion of bone removed including the foramen in its upper half—and the mucous membrane of the antrum is incised. (4) The upper portion of the posterior wall of the antrum is similarly removed over an area of about 6 mm. (¼ inch), either by trephine or chisel. (5) The mucous membrane covering the roof of the antrum is now divided in the direction of the infraorbital canal, followed by breaking away the bony floor of the canal, which may be done by chisel or stout scissors, while practising traction upon the nerve as a guide. (6) By this means, and by the use of long slender scissors and dissecting forceps, the nerve is freed back across the sphenomaxillary fossa to the foramen rotundum, until it hangs freely exposed. (7) Effort should be made to recognize Meckel's ganglion at this stage, locating it as definitely as possible. Considerable bleeding may be expected at this period of the operation—hemorrhage being controlled chiefly by pressure. Artificial illumination should be used. The nerve, while slight traction is being applied, should be divided at the foramen rotundum and from its sphenopalatine branches. The nerve and ganglion are then withdrawn. (8) The soft parts are now sutured—and, if much oozing occur, temporary drainage is to be provided for through the lower angle of the wound, or temporary packing may be necessary, with subsequent suturing of the lower part of the wound.

Comment.—(1) A T-shaped incision may be used—the horizontal portion being placed under the lower margin of the orbit, and the vertical portion running down on the cheek to near the mouth. Or a ⌐-shaped incision may be used—the horizontal portion along the orbit, and the vertical portion in the nasolabial groove. Probably the best incision is a long transverse one below the orbital margin, with strong retraction. (2) When

Meckel's ganglion is removed, the vidian nerve is paralyzed and therefore the motor branches to the palate muscles.

EXPOSURE OF SUPERIOR MAXILLARY NERVE AND MECKEL'S GANGLION BY THE ORBITAL ROUTE.

Description.—After subperiosteally displacing the contents of the orbit from the infraorbital canal and removing the roof of the canal, the nerve is followed back to and beyond Meckel's ganglion and cut at the foramen rotundum.

Position.—As in the above operation.

Landmarks.—Infraorbital margin and infraorbital foramen.

Incision.—Curved incision along lower margin of orbit over infraorbital foramen—extending from near internal angular process to external angular process of frontal.

Operation.—Carry the incision to the bone throughout. Isolate the nerve—cut as long as possible—and attach a stout piece of silk to the proximal end as a guide and means of traction. The bone between the infraorbital foramen and infraorbital margin is removed by trephine or chisel, exposing the anterior portion of the infraorbital canal. The periosteum of the floor of the orbit is raised along the orbital margin with a periosteal elevator—a spatula or retractor is placed beneath this and the tissues of the orbit are held out of the way. The roof of the canal is next broken down with a fine chisel, or other instrument—bleeding being controlled by pressure—and the nerve lifted out of its bed by traction on the ligature—and is then traced back with delicate instruments to the foramen rotundum and removed, together with Meckel's ganglion and its terminal filaments. The orbital contents are then allowed to fall back into place and the skin incision sutured.

Comment.—It is exceedingly difficult, and probably impossible, actually to reach the ganglion by this method, especially without wounding the eye-structures. It is also difficult to make the section far enough back to include all the dental nerves.

EXPOSURE OF SUPERIOR MAXILLARY NERVE AND MECKEL'S GANGLION BY THE PTERYGOMAXILLARY ROUTE.

BRAUN-LOESSEN OPERATION.

Description.—The nerve and ganglion are reached in the pterygomaxillary fossa by temporarily resecting the zygoma, turning it and the masseter muscle downward, firmly retracting the temporal muscle backward, and following the posterior surface of the superior maxillary bone into the pterygomaxillary fossa.

Position.—Patient supine; head on one side and elevated; surgeon to right for both sides.

Landmarks.—External angular process of frontal; zygoma; posterior border of ascending ramus of lower jaw.

Incision.—Begins at external angular process of frontal, passes downward and backward along upper border of zygoma to tragus of ear, thence downward in front of ear along posterior margin of inferior maxilla to angle of lower jaw.

Operation.—(1) This incision (the region having been shaved) passes

only through skin and superficial fascia—and the flap of integumentary tissues thus raised by dissection is turned forward and temporarily attached to the nose by suture. (2) An incision is made along the zygoma, passing to the bone, which is then exposed subperiosteally. Two holes are drilled (for wiring the bone later) through the malar bone on a line with a continuation of the upper part of its posterior border, and two through the zygoma near its root. The zygomatic arch is then sawed through between the two anterior drill-holes and between the two posterior drill-holes, directing the saw from without inward at the two ends (forming a beveled shelf for the arch to rest upon when replaced). The temporal fascia has been freed along its upper border in exposing the arch—and now the entire arch is turned down, with its attached masseter, cutting whatever fibers of that muscle are still holding the arch in place. (3) At this stage the mouth is opened with a gag and the lower jaw depressed, to carry downward and backward the coronoid process, with its temporal attachment—at the same time drawing backward with retractors the temporal muscle and tendon from the anterior portion of the temporal fossa. If this do not give sufficient exposure, the anterior part of the muscle and tendon is divided transversely. (4) The pterygomaxillary fissure is thereby exposed—and the internal maxillary artery and vein are seen entering and leaving the pterygomaxillary fossa through this fissure and are both ligated. The superior maxillary nerve is found leaving the foramen rotundum and is brought forward by means of a nerve-hook. The nerve and Meckel's ganglion can be more thoroughly exposed, at this stage of the operation, by chiseling away the spur of bone at the base of the external pterygoid plate, projecting outward and forward across the pterygomaxillary fissure and partially blocking the entrance to the pterygomaxillary fossa—and then both nerve and ganglion can be hooked forward. (5) In concluding the operation, the temporarily removed zygomatic arch is wired at both ends where previously drilled. If the temporal muscle have been partly severed, this is sutured. The temporal fascia is sutured to the cut margin of fascia over the zygoma. The skin incision is closed as usual.

Comment.—(1) If the infraorbital nerve be exposed at its emergence upon the face from the infraorbital foramen and be severed, then by traction upon the nerve hooked up in the sphenomaxillary fossa the entire length of the infraorbital nerve may be drawn out of the canal backward and all its dental branches torn across in their bony canals. (2) This operation is similar, in principle, to Rose's method of exposing the gasserian ganglion—and the chief indication for its use is where it is found desirable to expose the inferior maxillary at the foramen ovale, as well as the superior maxillary, with Meckel's ganglion, at the foramen rotundum. To expose the superior maxillary and Meckel's ganglion alone, the antral or the orbital route would be preferable;—and to expose all three roots, or the second and third, the Hartley-Krause or the Rose operation, especially the former, would be better.

EXPOSURE OF INFRAORBITAL NERVE AT INFRAORBITAL FORAMEN.

Position.—Patient's head slightly elevated. Surgeon to side of operation.

Landmarks.—Infraorbital foramen—which, if not palpable, lies about 8 mm. (⅓ inch) below infraorbital margin, and on line from supraorbital foramen to a point between the two bicuspids in both jaws.

Incision.—About 2 cm. ($\frac{3}{4}$ inch) in length, over the infraorbital foramen, parallel with the margin of the orbit.

Operation.—Skin, fat, and orbicularis palpebrarum are incised. The levator labii superioris is exposed and also incised. The nerve is found at its emergence from the foramen.

Comment.—The infraorbital nerve may be exposed through the mouth, without scarring. Having made the gingivolabial fold tense, an incision is made through the mucous membrane and periosteum along the line of reflection from the upper lip to the superior maxilla. The soft parts are then dissected away from the bone along the canine fossa, subperiosteally, and firmly retracted upward—until the infraorbital foramen is reached.

Note.—For the Anatomy of the Infraorbital, see the Superior Maxillary nerve.

SURGICAL ANATOMY OF INFERIOR MAXILLARY BRANCH OF TRIFACIAL AND THE OTIC AND SUBMAXILLARY GANGLIA.

Description of Inferior Maxillary.—Formed of two roots—a large sensory root from the inferior angle of gasserian ganglion—and a small motor root which passes under the ganglion and unites with the sensory root just after it has passed through the foramen ovale—both roots passing through the foramen separately. The nerve divides into anterior and posterior divisions 3 to 4 mm. ($\frac{1}{8}$ inch, about) beneath the base of skull and under cover of the external pterygoid—the former receiving the greater part of the motor root and the latter the greater part of the sensory root.

Ganglia.—(1) Otic (Arnold's) Ganglion;—situated immediately beneath foramen ovale, having inferior maxillary nerve on its outer side, the eustachian tube on its inner side, and the middle meningeal artery on its posterior side. (2) Submaxillary Ganglion;—placed between mylohyoid and hyoglossus muscles, above deep portion of submaxillary gland, and at outer side of Wharton's duct.

Note.—Foramen ovale lies on a line connecting the eminentia articularis, at root of zygoma, of one side, with that of the other, and about 3 cm. ($1\frac{1}{4}$ inches) from the eminentia—and is directly posterior and a little external to the external pterygoid plate. The middle meningeal artery enters the foramen spinosum just behind the foramen ovale. (3) The internal maxillary artery, in its second part, runs forward and upward on outer surface of external pterygoid muscle. (4) The pterygoid plexus of veins lies on the external pterygoid muscle.

EXPOSURE OF INFERIOR MAXILLARY NERVE AT FORAMEN OVALE —OR OF SUPERIOR MAXILLARY NERVE AT FORAMEN ROTUNDUM.

MIXTER'S OPERATION.

Description.—Mixter's operation consists in a temporary excision and downward displacement of the zygomatic arch, with the attached masseter —followed by a backward displacement of the temporal muscle, to reach the superior maxillary nerve and foramen rotundum—and a forward displacement of the muscle to reach the inferior maxillary and foramen ovale. The inferior maxillary nerve may be exposed at its origin by any of the operations exposing the gasserian ganglion, either intracranially or extracranially.

Position.—Patient on back; head elevated and turned to one side. Surgeon on side of operation, or to right for both operations.

Landmarks.—Zygoma; temporal ridge.

Incision.—Curved, with convexity upward—beginning about 1.3 cm. (½ inch) below malar portion of zygomatic arch and passing upward along posterior margin of malar bone and external angular process of frontal bone, to commencement of temporal ridge—thence follows lower temporal ridge to opposite anterior margin of ear—and then curves downward to pass in front of ear and ends about 1.3 cm. (½ inch) below root of zygoma.

Operation.—The above incision is made through the shaved skin and through the fascia—and this flap is turned downward, guarding Steno's duct. The temporal artery is ligated, unless it can be displaced backward. The zygomatic arch is exposed subperiosteally and sawed through in front and behind, beveling from without inward—and guarding against opening the inferior maxillary articulation behind. The zygoma, attached masseter, and fatty connective tissue are now well retracted downward. The temporal muscle and its attachment to the coronoid process become thereby well exposed—and are manipulated in accordance with the structure sought:—(**a**) To Expose the Superior Maxillary Nerve and the Foramen Rotundum:—The temporal muscle and tendon are firmly retracted posteriorly, by a broad, smooth retractor, aided by an assistant's depressing the jaw—the surgeon being guided by the posterior wall of the superior maxillary bone and the spur of bone projecting forward and outward from the base of the external pterygoid plate. This spur is chiseled away to better expose the foramen rotundum, if necessary—the chiseling being done in a forward and slightly inward direction, to avoid going into the middle fossa of the skull. Having removed this spur, the superior maxillary nerve is to be found crossing the pterygomaxillary fossa from the foramen rotundum to the infraorbital foramen, with Meckel's ganglion beneath it, and near the sphenopalatine foramen. (**b**) To Expose the Inferior Maxillary Nerve and Foramen Ovale:—The temporal muscle and tendon are now firmly retracted forward (the jaw being now closed to carry the coronoid process forward)—the surgeon being guided to the foramen ovale by its position just posterior and external to the base of the external pterygoid plate, at a distance of about 3 cm. (1¼ inches) internal to the anterior margin of the posterior attachment of the zygoma and slightly posterior to this line drawn directly inward. On the way inward the internal maxillary artery is met on the external pterygoid muscle and ligated. The pterygoid plexus of veins also lies upon this muscle. The external and internal pterygoid muscles can generally be displaced by retraction without necessitating their incision. The foramen ovale is usually recognized by the tip of the finger and the nerve is exposed emerging from it and drawn forward by a hook. Free hemorrhage may necessitate packing one part of the wound while working in another. In concluding the operation for exposure of either structure, the zygoma is replaced and the flap turned back into position.

Comment.—(**1**) If the zygoma be drilled anteriorly and posteriorly and then sawed between each pair of drill-holes, it may be subsequently wired. (**2**) If sufficient room cannot be gotten by retraction of the temporal muscle and tendon, it may be divided in part, transversely—the anterior portion being cut to reach the foramen rotundum—and the posterior portion in order to reach the foramen ovale. The muscle should be sutured on completing the operation. (**3**) The coronoid process could be drilled, sawed between the drill-holes, and the coronoid tip and temporal attachment turned

EXPOSURE OF INFERIOR DENTAL NERVE AT MENTAL FORAMEN, FROM WITHIN MOUTH.

Description.—The lower lip is everted and an incision made over the site of the mental foramen.

Position.—Patient supine; head supported and to one side. Surgeon on side of operation, or on right for both operations. Assistant draws lower lip well downward.

Landmarks.—A line drawn over the supraorbital foramen and between the two bicuspids of both jaws will cross the infraorbital and mental foramina—the mental foramen, in the adult, generally lying midway between the upper and lower borders of the jaw proper (exclusive of teeth).

Incision.—Transverse, through mucous membrane along line of its reflection from lower lip to inferior maxilla, with its center between the two bicuspids, the lower lip being firmly drawn downward. A vertical incision may be made instead of the transverse.

Operation.—This incision passes through periosteum to bone, upon slight downward freeing of which the nerve is found emerging from the mental foramen.

Comment.—An incision could be made from without, through the tissues of the chin, over the position of the foramen, in the direction of the fibers of the facial nerve, if the matter of scarring be not taken into account.

SURGICAL ANATOMY OF LINGUAL (GUSTATORY) NERVE.

Description and Relations.—A nerve of common sensation—branch of posterior division of inferior maxillary nerve. Descends under external pterygoid, to inner side and anterior to dental nerve, a cord generally connecting the two, and being joined near origin by chorda tympani. The nerve then passes between internal pterygoid muscle and ramus of lower jaw—inclining inward to side of tongue, and, passing over attachment of superior constrictor of pharynx to the lower jaw and the styloglossus muscle, above the deep part of submaxillary gland, is continued forward between mucous membrane of mouth and mylohyoid muscle and lies on its origin close to bone—then runs between mylohyoid and hyoglossus—crosses below Wharton's duct, and passes along side of tongue, under mucous membrane, to apex.

Comment.—On widely opening the mouth, one can feel the pterygomaxillary ligament, as a prominent ridge behind the last molar. The nerve is generally to be felt behind the pterygomaxillary ligament, about 1.3 cm. (½ inch) posterior and inferior to the last molar, lying just beneath the mucous membrane.

EXPOSURE OF LINGUAL (GUSTATORY) NERVE IN THE MOUTH.

Position.—Patient on back; head slightly raised; gag in opposite side of mouth; cheek of operated side held open by retractors; tongue of patient drawn out and to opposite side by assistant. Surgeon stands on patient's right for both operations, and uses a head-mirror.

Landmarks.—Ramus of jaw; pterygomaxillary ligament; last molar tooth.

Incision.—Vertical, about 2.5 cm. (1 inch) in length, placed in fold of mucous membrane midway between tongue and gum, with center on level with last molar. The nerve lies about at the junction of the upper and middle thirds of a line from the crown of the last molar to the angle of the jaw.

Operation.—Having incised in the above line, the nerve is found just beneath the mucous membrane, prior to dipping under the mylohyoid muscle —and is isolated and drawn forward by a hook.

Comment.—The lingual nerve may be reached from outside the mouth by excising a part of the inferior maxilla, at the junction of the alveolar process and the ascending ramus (Loebker). Or it may be reached by dissecting up under the internal surface of the inferior maxilla, displacing the submaxillary gland, dividing the posterior portion of the mylohyoid and finding the nerve under the posterior portion of the sublingual gland (Luschka).

SURGICAL ANATOMY OF FACIAL NERVE.

Description.—Arises, superficially, at upper end of medulla oblongata, in groove between olivary and restiform bodies—passes, in company with auditory nerve, forward and outward to internal auditory meatus, which it enters with auditory nerve, the pars intermedia intervening between the nerves. At the bottom of meatus, the facial nerve enters aqueductus Fallopii, which it follows to its emergence at the stylomastoid foramen—thence passes downward and forward through substance of parotid gland—crosses external carotid artery and divides behind ramus of inferior maxilla, opposite upper margin of digastric muscle, into two chief branches:—(1) Temporofacial, running upward and forward through parotid gland, crossing external carotid artery and temporomaxillary vein and passing over neck of condyle of jaw, and dividing into temporal, malar, and infraorbital branches,—and (2) Cervicofacial, running downward and forward, through parotid gland, crossing external carotid artery, and dividing, opposite angle of jaw, into buccal, supramaxillary, and inframaxillary branches.

EXPOSURE OF FACIAL NERVE IN FRONT OF MASTOID PROCESS.

BAUM'S OPERATION.

Position.—Patient supine; head elevated and to one side. Surgeon to right for both operations.

Landmarks.—Anterior border of mastoid process; posterior border of ascending ramus of inferior maxilla. The point at which the nerve is sought being from 6 mm. to 1.3 cm. ($\frac{1}{4}$ to $\frac{1}{2}$ inch) in front of center of anterior border of mastoid process.

Incision.—Begins close behind pinna of ear, opposite meatus—passes downward to opposite lobule of ear, and then downward and forward almost to angle of inferior maxilla.

Operation.—This incision is deepened through skin and fascia, with care. The parotid fascia is incised and the parotid gland is retracted forward. The anterior edge of the sternomastoid is exposed and drawn backward. The posterior belly of the digastric is exposed and the nerve is sought on a line with the upper border of the posterior belly of this muscle and at the point above mentioned—coming from the stylomastoid foramen toward the

surface of transverse process of atlas to occipital bone, between curved lines, and external to complexus),—below and externally, by obliquus capitis inferior (from apex of spinous process of axis to lower and back part of transverse process of atlas). Within this triangle lies the suboccipital nerve (posterior division of first cervical nerve), which does not divide into internal and external branches—lying close to the occiput and behind the vertebral artery. Trace it as near to the spine as possible. Thus the first cervical nerve is exposed. (3) The external branch of the posterior division of the third cervical nerve is found about 2.5 cm. (1 inch) lower down than the occipitalis major (page 171) and under the complexus. It is to be followed to the common trunk of the posterior division. And thus the third cervical nerve is exposed.

Comment.—This operation has been modified by making a vertical incision from the occiput downward, about 4 cm. (1½ inches) outside of the median line—passing through the trapezius, edge of the splenius, and then through the complexus. Also, the second and third divisions may be divided without the first.

SURGICAL ANATOMY OF BRACHIAL PLEXUS OF NERVES.

Formed by.—Fasciculus from anterior branch of fourth cervical, anterior branches of fifth, sixth, seventh, and eighth cervical, and greater part of anterior branch of first dorsal.

Extent and Position.—From lower part of side of neck to lower part of axillary space, dividing, opposite the coracoid process, into numerous trunks, and giving off its terminal nerves at the lower axillary boundary.

Relations.—(1) **In neck**:—First, lies between anterior and middle scaleni and at outer border of former muscle;—then partly behind and partly above and external to third part of subclavian artery, in the posterior triangle of neck, crossed by posterior belly of omohyoid;—then behind clavicle and subclavius muscle, upon first serration of serratus magnus and subscapularis muscles. (2) **In axilla**:—Lies to outer side of first portion of axillary artery, being covered by pectoralis major—then surrounds second portion of artery, covered by the pectoralis minor and resting upon subscapularis muscle, one cord lying to inner side, one behind, and one to outer side of vessel. The third part of the artery has the internal cutaneous and inner head of median nerve in front; circumflex and musculospiral behind; ulnar and lesser internal cutaneous on inner side; and trunk of median and musculocutaneous on outer side.

EXPOSURE OF BRACHIAL PLEXUS IN NECK.

Position.—Patient upon back, near edge of table; thorax raised; head extended and turned to opposite side; arm drawn downward and behind back. Surgeon stands in front of right shoulder, in operating upon either side.

Landmarks.—Sternomastoid; trapezius.

Incision.—Vertical, in posterior triangle of neck—beginning about 9 cm. (3½ inches) above clavicle and passing downward to within about 1.3 cm. (½ inch) of middle of clavicle, parallel with anterior border of trapezius, but nearer posterior border of sternomastoid.

Operation.—Having divided skin and platysma, the external jugular

vein is either ligated and cut between two ligatures, or retracted. Some of the descend ng branches of the cervical plexus are apt to be incised, generally the supraclavicular. Incise the deep cervical fascia. Recognize the outer border of the anterior scalenus and retract inward. Retract the posterior belly of the omohyoid downward and expose the brachial plexus by dissection. Avoid the transversalis colli artery and vein crossing the middle of the plexus. Identify the cords of the plexus by following with finger to the interval between the anterior and middle scalenus muscles.

SURGICAL ANATOMY OF CIRCUMFLEX NERVE.

Description.—One of terminal branches of posterior cord of brachial plexus, lying, at first, between axillary artery and subscapularis muscle, it passes downward and outward to lower border of that muscle, accompanied by posterior circumflex artery—it then winds backward and outward around the surgical neck of humerus, through the quadrilateral space bounded by teres minor above; teres major below; long head of triceps internally; and neck of humerus externally—and divides into upper and lower branches.

EXPOSURE OF CIRCUMFLEX NERVE ON BACK OF ARM.

Position.—As for exposure of ulnar nerve just above inner condyle of humerus (page 175).

Landmarks.—Angle made between posterior scapular muscles and posterior border of deltoid—by pressing latter muscle toward neck of humerus.

Incision.—Made in long axis of limb and placed over above interval.

Operation.—Expose and draw forward the posterior border of the delto'd, exposing the teres m'nor above and long head of triceps internally. In the angle formed by the last two muscles the circumflex nerve, accompanied by the posterior circumflex artery (lying below), is seen coming out from before backward through the quadrilateral space and curving around the surgical neck of the humerus to enter the under surface of the deltoid.

SURGICAL ANATOMY OF MUSCULOCUTANEOUS NERVE.

Description.—Arising from outer cord of brachial plexus opposite lower border of pectoralis minor, it runs downward and outward, perforating the coracobrachialis and passing obliquely across the arm between the biceps and brachialis anticus to outer side of biceps a little above the elbow, where it perforates the deep fascia, passing behind the median cephalic vein, and divides into anterior and posterior cutaneous branches.

EXPOSURE OF MUSCULOCUTANEOUS NERVE IN UPPER PART OF ARM.

Position.—As for exposure of ulnar nerve just above inner condyle of humerus (page 175).

Landmarks.—Upper internal bicipital sulcus.

Incision.—Along inner margin of biceps, beginning at prominence of coracobrachialis and passing downward.

surface. The posterior auricular artery and vein will probably need ligating, and some fibers of the great auricular nerve will be cut. The internal jugular vein is near the deep part of the wound, but there are no other important vessels anterior to the plane of the digastric (behind which is the external carotid). If necessary, especially in stout subjects, a small transverse incision, passing forward from below the pinna, may be added.

SURGICAL ANATOMY OF SPINAL ACCESSORY NERVE.

Description and Relations.—(1) Accessory portion passes outward to jugular foramen, where it unites with spinal portion, and is joined to upper ganglion of the vagus and sends fibers into its pharyngeal and superior laryngeal branches and into the trunk of that nerve below the ganglion. (2) Spinal portion, after issuing from jugular foramen (where it unites with accessory portion), passes backward, crossing in front of (sometimes behind) the internal jugular vein, descends obliquely behind digastric and stylohyoid muscles and occipital artery to enter upper third of sternomastoid about 5 cm. (2 inches) below tip of mastoid process—perforates this muscle in its second fourth and emerges on level with center of its posterior border —and runs thence obliquely across the occipital triangle, and, entering upper part of lower third of its anterior border, terminates in the deep surface of the trapezius.

EXPOSURE OF SPINAL ACCESSORY NERVE AT ANTERIOR BORDER OF STERNOMASTOID MUSCLE.

Position.—Patient supine; shoulders slightly elevated; head to opposite side; neck supported. Surgeon on right, for either operation.

Landmarks.—Anterior border of upper portion of sternomastoid.

Incision.—About 7.5 cm. (3 inches) in length, following the anterior border of the sternomastoid, with its center opposite a point about 5 cm. (2 inches) below the tip of the mastoid process.

Operation.—Having cut through skin and superficial fascia, and opened up the cervical fascia, avoiding the external jugular vein and great auricular nerve, expose the anterior border of the sternomastoid and draw the muscle firmly backward. Recognize the inferior border of the posterior belly of the digastric—the nerve will be found passing from beneath it to the sternomastoid, crossing the transverse process of the atlas. Avoid branches of the facial nerve (at the upper edge of the wound) and the occipital artery (lying over the nerve).

Comment.—If only that portion of the spinal accessory be involved which is distal to the sternomastoid, the nerve may be exposed by an incision placed along the posterior border of the sternomastoid, with its center opposite the center of the posterior border of the muscle.

SURGICAL ANATOMY OF OCCIPITALIS MAJOR BRANCH OF POSTERIOR DIVISION OF SECOND CERVICAL NERVE.

Description and Relations.—Internal branch of posterior division of second cervical nerve—passes upward across (not contained within) sub-

vein is either ligated and cut between two ligatures, or retracted. Some of the descend ng branches of the cervical plexus are apt to be incised, generally the supraclavicular. Incise the deep cervical fascia. Recognize the outer border of the anterior scalenus and retract inward. Retract the posterior belly of the omohyoid downward and expose the brachial plexus by dissection. Avoid the transversalis colli artery and vein crossing the middle of the plexus. Identify the cords of the plexus by following with finger to the interval between the anterior and middle scalenus muscles.

SURGICAL ANATOMY OF CIRCUMFLEX NERVE.

Description.—One of terminal branches of posterior cord of brachial plexus, lying, at first, between axillary artery and subscapularis muscle, it passes downward and outward to lower border of that muscle, accompanied by posterior circumflex artery—it then winds backward and outward around the surgical neck of humerus, through the quadrilateral space bounded by teres minor above; teres major below; long head of triceps internally; and neck of humerus externally—and divides into upper and lower branches.

EXPOSURE OF CIRCUMFLEX NERVE ON BACK OF ARM.

Position.—As for exposure of ulnar nerve just above inner condyle of humerus (page 175).

Landmarks.—Angle made between posterior scapular muscles and posterior border of deltoid—by pressing latter muscle toward neck of humerus.

Incision.—Made in long axis of limb and placed over above interval.

Operation.—Expose and draw forward the posterior border of the delto d, exposing the teres m nor above and long head of triceps internally. In the angle formed by the last two muscles the circumflex nerve, accompanied by the posterior circumflex artery (lying below), is seen coming out from before backward through the quadrilateral space and curving around the surgical neck of the humerus to enter the under surface of the deltoid.

SURGICAL ANATOMY OF MUSCULOCUTANEOUS NERVE.

Description.—Arising from outer cord of brachial plexus opposite lower border of pectoralis minor, it runs downward and outward, perforating the coracobrachialis and passing obliquely across the arm between the biceps and brachialis anticus to outer side of biceps a little above the elbow, where it perforates the deep fascia, passing behind the median cephalic vein, and divides into anterior and posterior cutaneous branches.

EXPOSURE OF MUSCULOCUTANEOUS NERVE IN UPPER PART OF ARM.

Position.—As for exposure of ulnar nerve just above inner condyle of humerus (page 175).

Landmarks.—Upper internal bicipital sulcus.

Incision.—Along inner margin of biceps, beginning at prominence of coracobrachialis and passing downward.

surface of transverse process of atlas to occipital bone, between curved lines, and external to complexus),—below and externally, by obliquus capitis inferior (from apex of spinous process of axis to lower and back part of transverse process of atlas). Within this triangle lies the suboccipital nerve (posterior division of first cervical nerve), which does not divide into internal and external branches—lying close to the occiput and behind the vertebral artery. Trace it as near to the spine as possible. Thus the first cervical nerve is exposed. (3) The external branch of the posterior division of the third cervical nerve is found about 2.5 cm. (1 inch) lower down than the occipitalis major (page 171) and under the complexus. It is to be followed to the common trunk of the posterior division. And thus the third cervical nerve is exposed.

Comment.—This operation has been modified by making a vertical incision from the occiput downward, about 4 cm. (1½ inches) outside of the median line—passing through the trapezius, edge of the splenius, and then through the complexus. Also, the second and third divisions may be divided without the first.

SURGICAL ANATOMY OF BRACHIAL PLEXUS OF NERVES.

Formed by.—Fasciculus from anterior branch of fourth cervical, anterior branches of fifth, sixth, seventh, and eighth cervical, and greater part of anterior branch of first dorsal.

Extent and Position.—From lower part of side of neck to lower part of axillary space, dividing, opposite the. coracoid process, into numerous trunks, and giving off its terminal nerves at the lower axillary boundary,

Relations.—(1) **In neck**:—First, lies between anterior and middle scaleni and at outer border of former muscle;—then partly behind and partly above and external to third part of subclavian artery, in the posterior triangle of neck, crossed by posterior belly of omohyoid;—then behind clavicle and subclavius muscle, upon first serration of serratus magnus and subscapularis muscles. (2) **In axilla**:—Lies to outer side of first portion of axillary artery, being covered by pectoralis major—then surrounds second portion of artery, covered by the pectoralis minor and resting upon subscapularis muscle, one cord lying to inner side, one behind, and one to outer side of vessel. The third part of the artery has the internal cutaneous and inner head of median nerve in front; circumflex and musculospiral behind; ulnar and lesser internal cutaneous on inner side; and trunk of median and musculocutaneous on outer side.

EXPOSURE OF BRACHIAL PLEXUS IN NECK.

Position.—Patient upon back, near edge of table; thorax raised; head extended and turned to opposite side; arm drawn downward and behind back. Surgeon stands in front of right shoulder, in operating upon either side.

Landmarks.—Sternomastoid; trapezius.

Incision.—Vertical, in posterior triangle of neck—beginning about 9 cm. (3½ inches) above clavicle and passing downward to within about 1.3 cm. (½ inch) of middle of clavicle, parallel with anterior border of trapezius, but nearer posterior border of sternomastoid.

Operation.—Having divided skin and platysma, the external jugular

vein is either ligated and cut between two ligatures, or retracted. Some of the descend ng branches of the cervical plexus are apt to be incised, generally the supraclavicular. Incise the deep cervical fascia. Recognize the outer border of the anterior scalenus and retract inward. Retract the posterior belly of the omohyoid downward and expose the brachial plexus by dissection. Avoid the transversalis colli artery and vein crossing the middle of the plexus. Identify the cords of the plexus by following with finger to the interval between the anterior and middle scalenus muscles.

SURGICAL ANATOMY OF CIRCUMFLEX NERVE.

Description.—One of terminal branches of posterior cord of brachial plexus, lying, at first, between axillary artery and subscapularis muscle, it passes downward and outward to lower border of that muscle, accompanied by posterior circumflex artery—it then winds backward and outward around the surgical neck of humerus, through the quadrilateral space bounded by teres minor above; teres major below; long head of triceps internally; and neck of humerus externally—and divides into upper and lower branches.

EXPOSURE OF CIRCUMFLEX NERVE ON BACK OF ARM.

Position.—As for exposure of ulnar nerve just above inner condyle of humerus (page 175).

Landmarks.—Angle made between posterior scapular muscles and posterior border of deltoid—by pressing latter muscle toward neck of humerus.

Incision.—Made in long axis of limb and placed over above interval.

Operation.—Expose and draw forward the posterior border of the delto'd, exposing the teres m'nor above and long head of triceps internally. In the angle formed by the last two muscles the circumflex nerve, accompanied by the posterior circumflex artery (lying below), is seen coming out from before backward through the quadrilateral space and curving around the surgical neck of the humerus to enter the under surface of the deltoid.

SURGICAL ANATOMY OF MUSCULOCUTANEOUS NERVE.

Description.—Arising from outer cord of brachial plexus opposite lower border of pectoralis minor, it runs downward and outward, perforating the coracobrachialis and passing obliquely across the arm between the biceps and brachialis anticus to outer side of biceps a little above the elbow, where it perforates the deep fascia, passing behind the median cephalic vein, and divides into anterior and posterior cutaneous branches.

EXPOSURE OF MUSCULOCUTANEOUS NERVE IN UPPER PART OF ARM.

Position.—As for exposure of ulnar nerve just above inner condyle of humerus (page 175).

Landmarks.—Upper internal bicipital sulcus.

Incision.—Along inner margin of biceps, beginning at prominence of coracobrachialis and passing downward.

Operation.—Having incised the superficial structures, the biceps muscle is exposed and drawn outward. The nerve is found penetrating the outer border of the coracobrachialis, covered by the biceps.

SURGICAL ANATOMY OF MEDIAN NERVE.

Description.—(a) In Arm; Arises by a root from inner and one from outer cords of brachial plexus, which embrace axillary artery, uniting either in front or to outer side of the vessel. Descends arm on outer side of brachial artery at first—then crosses in front of the middle of artery (though sometimes passing behind)—thence downward on inner side of artery to elbow—where it is separated from elbow-joint by brachialis anticus muscle and is covered by bicipital fascia. (b) In Forearm; Passes between two heads of pronator radii teres and descends between flexor sublimis and profundus digitorum to about 5 cm. (2 inches) above the annular ligament of wrist, where it lies beneath the fascia, between the tendons of the flexor sublimis digitorum below, the palmaris longus internally, and the flexor carpi radialis externally (or rather more under the palmaris longus). (c) In Hand; It enters palm beneath the annular ligament and rests upon flexor tendons, covered by fascia and superficial palmar arch.

EXPOSURE OF MEDIAN NERVE IN MIDDLE OF ARM.

Position.—Patient's arm is extended and abducted, with hand supine. Surgeon stands on outer side of right limb, cutting from above downward; and between body and left limb, cutting from above downward (or on outside of left limb, cutting from below upward).

Landmarks.—Inner edge of bicipital muscle.

Incision.—Along inner edge of biceps, in middle of arm—about 4 cm. (2½ inches) in length.

Operation.—Divide skin and connective tissue. Avoid internal cutaneous nerve and basilic vein. Clearly expose inner edge of biceps muscle and draw the muscle to the outer side, when the median nerve is found crossing the brachial artery from the outer toward the inner side (or sometimes passing beneath the artery).

EXPOSURE OF MEDIAN NERVE AT BEND OF ELBOW.

Position.—As above.

Landmarks.—Groove between biceps and pronator radii teres muscles.

Incision.—Between inner margin of biceps and outer margin of pronator radii teres, somewhat nearer the former, with center of incision opposite the fold of the elbow, and being about 5 cm. (2 inches) in length.

Operation.—This incision will, in the usual disposition of the veins at the elbow, pass to the outer side and nearly parallel with the median basilic vein, which should be retracted inward. Incise the bicipital fascia in a line with the skin-cut. The median nerve lies just to the inner side of the brachial artery and its venæ comites—all lying upon the brachialis anticus. Gut-suture the bicipital fascia in closing the wound.

SURGICAL ANATOMY OF ULNAR NERVE.

Description.—(a) In Arm; Arises from inner cord of brachial plexus, between axillary artery and vein, and passes down arm on inner side of axillary and brachial arteries to middle of arm, covered only by skin and fascia—thence diverges to cross inner head of triceps obliquely—pierces internal intermuscular septum and descends posterior to that structure, together with inferior profunda artery, which is upon its outer side. (b) At Elbow; Occupies groove between olecranon and internal condyle, resting upon posterior surface of latter (rarely upon anterior surface), and enters forearm between two heads of flexor carpi ulnaris. (c) In Forearm; Passes vertically down ulnar side, upon flexor profundus digitorum, its upper half covered by flexor carpi ulnaris, its lower half by skin and fascia (the nerve here lying external to flexor carpi ulnaris). The ulnar nerve lies, throughout, to the ulnar side of the ulnar artery—the upper third lying considerably to the inner side, and the lower two-thirds near to the inner side. The dorsal cutaneous branch passes posteriorly between 5 and 7.5 cm. (2 and 3 inches) above the wrist. (d) At Wrist; Crosses front of annular ligament between ulnar artery and pisiform bone, a little internal and posterior to the artery, and immediately divides into superficial and deep palmar branches.

EXPOSURE OF ULNAR NERVE ABOVE MIDDLE OF ARM.

Position.—As for median nerve in middle of arm (page 174).

Landmarks.—Brachial artery, which is parallel with and to outer side of the nerve for the upper half of the arm.

Incision.—From 5 to 7.5 cm. (2 to 3 inches) in length, with its center just above the middle of the arm—running parallel with and about 1.3 cm. (½ inch) to inner side of line of brachial artery (the line for the ligation of the middle third of the brachial artery passing along the inner margin of the biceps muscle).

Operation.—Incise skin and fascia, which here alone cover the nerve. Avoid the basilic vein and the venæ comites of the brachial artery—also the internal cutaneous nerve to the outer, and the lesser internal cutaneous nerve to the inner side. The ulnar nerve is found diverging from its course parallel with the inner side of the brachial artery to pass obliquely across the inner head of the triceps to pierce the internal intermuscular septum.

EXPOSURE OF ULNAR NERVE JUST ABOVE INTERNAL CONDYLE OF HUMERUS.

Position.—Patient upon back at edge of table. Assistant stands on side opposite one to be operated, and, grasping patient's wrist, with patient's hand prone, draws his (patient's) arm and forearm across the chest, thus exposing its posterior surface to the operator—who stands upon the side to be operated, cutting from elbow toward shoulder on both sides.

Landmarks.—Olecranon; internal condyle of humerus.

Incision.—About 5 cm. (2 inches) in length, extending from a point about 1.3 cm. (½ inch) above (to proximal side of) internal condyle and midway between internal condyle and olecranon, upward toward a point at inner

side of brachial artery opposite the insertion of the coracobrachialis muscle (about center of arm).

Operation.—Incise skin and fascia in above line—when the nerve will be found upon the posterior surface of the internal intermuscular septum, with the inferior profunda artery upon its outer side.

Comment.—If the incision were to extend over the internal condyle, the nerve would be found lying upon the posterior surface of the base of the inner condyle of the humerus, close to the bone and along the inner edge of the triceps.

SURGICAL ANATOMY OF MUSCULOSPIRAL NERVE.

Description.—Arises, in common with circumflex nerve, from posterior cord of brachial plexus—descends arm behind axillary and brachial arteries and in front of tendons of latissimus dorsi and teres major, and winds around humerus in musculospiral groove, from inner to outer side, with superior profunda artery, lying between the internal and external heads of the triceps. Arriving at outer side of arm, it pierces the external intermuscular septum about midway between insertion of deltoid and tip of external condyle (namely, at lower third) and descends between supinator longus and brachialis anticus to front of external condyle, where it divides into radial and posterior interosseous nerves.

EXPOSURE OF MUSCULOSPIRAL NERVE BELOW MIDDLE OF ARM.

Description.—The exposure is here made upon the external aspect of the arm and the nerve is reached anterior to the external intermuscular septum.

Position.—Same as for ulnar nerve just above internal condyle (page 175). The surgeon may also stand so as to cut from shoulder toward elbow.

Landmarks.—Insertion of deltoid (about middle of arm); external condyle of humerus; upper border of supinator longus.

Incision.—About 6 to 7.5 cm. (2½ to 3 inches) in length—crossing obliquely the outer surface of the lower third of the arm—so placed that its center will be midway between the deltoid and the external condyle—and so that its obliquity will follow the line of the upper border of the supinator longus.

Operation.—Having incised skin and fascia, avoiding cephalic and median cephalic veins, identify the internal border of the supinator longus. Draw this muscle to the outer side, so as to expose the interval between it and the brachialis anticus—where the nerve will be found close to the bone, accompanied by a branch of the superior profunda artery.

Comment.—Exposure of the nerve at its bifurcation into radial and posterior interosseous may be accomplished (if not performed as a separate operation) by continuing the above incision downward.

SURGICAL ANATOMY OF RADIAL BRANCH OF MUSCULOSPIRAL NERVE.

Description.—Anterior subdivision of musculospiral. At first lies a short distance to radial side of radial artery, but gradually approaches it

closely and runs parallel with it, on its outer side, covered by supinator longus —running along anterior border of extensor carpi radialis brevior and resting on supinator brevis, insertion of pronator radii teres, and radius. About 7.5 cm. (3 inches) above the wrist the nerve quits the artery, passes backward beneath the tendon of supinator longus, and, piercing the deep fascia, divides into external and internal branches.

SURGICAL ANATOMY OF POSTERIOR INTEROSSEOUS BRANCH OF MUSCULOSPIRAL.

Description.—Posterior subdivision of musculospiral. Passing downward in interval between brachialis anticus and extensor carpi radialis longior, winds around outer side of radius to back of forearm, passing between superficial and deep layers of supinator brevis muscle. Thence it enters the cellular interval between the superficial and deep layers of the muscles at back of forearm, passing onto the interosseous membrane at lower third of forearm—and thence under cover of tendons of extensor communis digitorum to back of wrist, where it swells into a gangliform enlargement.

EXPOSURE OF RADIAL OR POSTERIOR INTEREOSSEOUS BRANCH OF MUSCULOSPIRAL, AT THEIR COMMENCEMENT.

Position.—As for the median nerve in middle of arm (page 174).

Landmarks.—External bicipital sulcus.

Incision.—Along anterior margin of supinator longus muscle, in external bicipital sulcus—center of incision corresponding with external condyle.

Operation.—Incise skin and fascia. Avoid median cephalic vein and musculocutaneous nerve. Retract supinator longus to outer and brachialis anticus to inner side—between which two structures the beginning of the radial and of the posterior interosseous will be found, accompanied by a branch of the superior profunda artery.

Comment.—This is, practically, a continuation of the operation for the exposure of the musculospiral below the middle of the arm.

SURGICAL ANATOMY OF THE INTERCOSTAL NERVES.

Description.—(a) Pectoral Intercostal Nerves:—Pass outward, as the anterior divisions of the dorsal nerves, in front of superior costotransverse ligaments, levatores costarum, external intercostal muscles, covered (to angle of ribs) by pleura and endothoracic fascia. They then approach upper part of each intercostal space to accompany intercostal vessels, in groove of rib above, to front of chest—the nerve lying below the vessels. Between angle of rib and middle of rib they lie between internal and external intercostal muscles, giving off, a little posterior to middle of the ribs, the lateral cutaneous branches—which latter branches pass through external intercostal and serratus magnus muscles about center of ribs and divide into anterior and posterior branches. The main trunk of the intercostal nerve continues forward among fibers of internal intercostal muscles to costal cartilages—thence passes between internal intercostal muscles and pleura, crossing in front of internal mammary artery and triangularis sterni muscle—to pierce

internal intercostal muscles and pectoralis major and end in the anterior cutaneous branches. **(b) Abdominal Intercostal Nerves:**—Take the same course (as the anterior divisions of the dorsal nerves) as the pectoral intercostals, from their origin to ends of intercostal spaces in which they lie—thence they run between the slips of origin of diaphragm to enter the abdominal wall, each nerve (from seventh to ninth, inclusive) crossing behind cartilage of rib below. In the abdominal wall they pass between internal oblique and transversalis, diverging from each other as they go forward, to outer edge of the rectus—and, piercing posterior layer of rectal sheath, rectus itself, and anterior layer of sheath, they supply rectus and sheath and end in the anterior cutaneous nerves near the linea alba.

Comment.—(1) The exceptions in the distribution of the anterior divisions of the first, second, and twelfth nerves are not mentioned in the above descriptions. (2) The upper six dorsal nerves form the pectoral intercostal nerves—the lower six, the abdominal intercostals. (3) The final distribution of the lower dorsal nerves is as follows;—sixth, to pit of stomach; seventh, to lower end of ensiform cartilage; eighth, over the middle linea transversa; tenth, to the umbilicus; twelfth, midway between umbilicus and pubis.

EXPOSURE OF INTERCOSTAL NERVE BETWEEN ANGLE AND MIDDLE OF RIB.

Position.—Patient on side. Surgeon either in front or at back of patient.

Landmarks.—Angle and lower border of rib.

Incision.—Parallel with and just below lower border of rib, and lying between the angle and middle of rib.

Operation.—Having incised skin, fascia, and external intercostal muscle, separate the cut edges of the external intercostal muscle and seek for nerve in the intermuscular plane between external and internal intercostals, near the lower border of the rib above. The nerve may be drawn down into view from the groove in the lower border of the rib by means of a nerve-hook. If necessary, bite out a half-button of rib subperiosteally with rongeur forceps, fully exposing the nerve and intercostal vessels, when the latter may be divided between ligatures, if necessary.

SURGICAL ANATOMY OF ANTERIOR CRURAL NERVE.

Arises from second, third, and fourth lumbar nerves and descends through fibers of psoas muscle—emerging from lower part of its outer border, and descending beneath Poupart's ligament into thigh, beneath the iliac fascia, in groove between psoas and iliacus, being separated from femoral artery on its inner side by the psoas. It divides below Poupart's ligament into an anterior division, passing in front of the external circumflex vessels—and a posterior division, passing behind these vessels.

EXPOSURE OF ANTERIOR CRURAL NERVE, BELOW POUPART'S LIGAMENT.

Position.—Patient on back; limb extended and rotated slightly outward. Surgeon to outer side of right limb, and to inner side of left or on right,

eaning over body; or on outer side of left limb, cutting from below upward).

Landmarks.—Middle of Poupart's ligament.

Incision.—Vertical, about 5 cm. (2 inches) in length, carried downward from a point about 1.3 cm. (½ inch) external to center of Poupart's ligament.

Operation.—Incise skin and superficial fascia. Crural branch of genitocrural nerve may be met running down the thigh. The superficial circumflex iliac vessels will lie across the incision. Flex the thigh to relax the muscles. The nerve will be found lying to the outer side of the femoral artery, in the groove between the iliacus and psoas muscles.

EXPOSURE OF OBTURATOR, SUPERIOR GLUTEAL, AND PUDIC NERVES.

The operations for the exposure of the obturator nerve at the thyroid foramen, the superior gluteal nerve upon the buttock, the pudic nerve upon the buttock, and the pudic nerve in the perineum, are, practically, the same as the operations for the ligation of the obturator artery at the thyroid foramen (page 85), the gluteal artery upon the buttock (page 89), the internal pudic artery upon the buttock (page 88), and the internal pudic artery in the perineum (page 88), respectively.

SURGICAL ANATOMY OF GREAT SCIATIC NERVE.

Description.—Continuation of lower cord of sacral plexus—leaves pelvis by great sacrosciatic foramen, below pyriformis—descends from hollow between great trochanter and tuberosity of ischium down back of thigh, to about its lower third, where it divides into external and internal popliteal nerves (the division often occurring higher). The great sciatic nerve rests, from above downward, upon the ischium, gemellus superior, obturator internus, gemellus inferior, quadratus femoris and adductor magnus,—and is covered by, from above downward, the skin, fascia, gluteus maximus, biceps, and small sciatic nerve. It has the sciatic artery to its inner side, and small sciatic nerve superficial to it above, and to its inner side as it (the small sciatic nerve) descends the thigh.

EXPOSURE OF GREAT SCIATIC NERVE AT LOWER BORDER OF GLUTEUS MAXIMUS.

Position.—Patient turned upon side sufficiently to expose field of operation. Surgeon on side of operation, cutting downward on left side, and upward on right.

Landmarks.—Lower margin of gluteus, which is below fold of buttock; tuberosity of ischium; great trochanter.

Incision.—Begins over gluteal fold and passes vertically downward for a distance of 7.5 to 10 cm. (3 to 4 inches), with center of incision over lower margin of gluteus maximus and placed midway between tuberosity of ischium and great trochanter—although the nerve lies a little nearer the former than the latter, for by this incision the hamstring muscles are more easily retracted.

Operation.—Having incised skin and fatty areolar tissue, the small sciatic nerve and cutaneous vessels are encountered. Expose the lower edge

of the gluteus maximus, running downward and outward, and retract upward. Find and retract the hamstring muscles inward, bending the knee to aid the retraction. The nerve is found a little nearer the tuberosity of the ischium than the great trochanter and under the outer edge of the biceps muscle.

SURGICAL ANATOMY OF INTERNAL POPLITEAL BRANCH OF GREAT SCIATIC NERVE.

Description.—The larger branch of the great sciatic. Extends from bifurcation, at lower third of thigh, through middle of popliteal space to lower border of popliteus muscle, where it becomes the posterior tibial nerve. It is covered, above, by hamstring muscles; in the middle, by skin and fascia; and below, by heads of gastrocnemii. The popliteal vein intervenes between the nerve superficially, and the artery deeply. In the upper popliteal space the nerve lies external to the popliteal artery and vein; at the level of the knee, the nerve crosses these vessels; and in the lower popliteal space the nerve lies to the inner side of the vessels.

EXPOSURE OF INTERNAL POPLITEAL NERVE AT LOWER PART OF POPLITEAL SPACE.

Position.—Patient rests on shoulder and side of chest, as nearly prone as anesthesia will allow; limb extended. Surgeon to outer side of left, cutting downward; and to inner side of right, cutting downward (or to outer side, cutting upward).

Landmarks.—Heads of gastrocnemii muscles.

Incision.—Begins opposite the center of the popliteal space and passes vertically downward for about 9 cm. (3½ inches), between the two heads of the gastrocnemii.

Operation.—Having divided skin and superficial fascia, avoid external saphenous vein and nerve at the outer and lower part of the wound. Expose the heads of the gastrocnemii and open up, by blunt dissection, the interval between them, retracting the heads of the muscle to their respective sides. The nerve will be found the most superficial of the important structures in the popliteal space.

SURGICAL ANATOMY OF POSTERIOR TIBIAL NERVE.

Description.—The direct continuation of internal popliteal nerve. Extends from lower border of popliteus muscle to interval between internal malleolus and heel, where it divides into internal and external plantar nerves. It is covered, above, by gastrocnemius, plantaris, soleus, and intermuscular deep fascia; and, below, by only skin and fascia. It rests upon (its anterior relations are), above, tibialis posticus; and, below, flexor longus digitorum. It lies to inner side of posterior tibial artery above, but soon crosses it and runs on its fibular side to ankle.

EXPOSURE OF POSTERIOR TIBIAL BETWEEN ORIGIN AND ANKLE.

The operation for the exposure of the posterior tibial nerve at its origin is, practically, the same as that for the exposure of the internal popliteal at

the lower part of the popliteal space (page 180). The posterior tibial nerve in the leg may be exposed by the same operation as would expose the posterior tibial artery at the same level (page 112).

EXPOSURE OF POSTERIOR TIBIAL NERVE BEHIND INTERNAL MALLEOLUS.

Position.—Patient on back; knee flexed; leg resting on outer side. Surgeon stands facing either foot, cutting from above downward.

Landmarks.—Internal malleolus; tendo Achillis.

Incision.—Curved, about 5 cm. (2 inches) in length, made about 1.3 cm. (½ inch) behind and parallel with the internal malleolus, beginning just in front of tip of malleolus and extending upward in a line midway between internal malleolus and tendo Achillis.

Operation.—Directing the knife toward the tibia, divide skin, superficial fascia, and annular ligament. The order of the structures met behind the internal malleolus, from within outward, is, tibialis posticus; flexor longus digitorum; posterior tibial artery, vein and nerve; flexor longus hallucis. The nerve is therefore sought between the tendons of the flexor longus digitorum and flexor longus hallucis.

SURGICAL ANATOMY OF EXTERNAL POPLITEAL (PERONEAL) BRANCH OF GREAT SCIATIC.

Description.—Smaller branch of great sciatic. Enters superior angle of popliteal space and passes obliquely along outer side of this space to head of fibula, lying near inner border of biceps (lying beneath skin and fascia, behind head of fibula, to inner side of biceps tendon). The nerve leaves the popliteal space in interval between biceps tendon and outer head of gastrocnemius—winds around neck of fibula between bone and peroneus longus muscle—and, piercing origin of latter muscle, divides into anterior tibial, musculocutaneous, and recurrent articular nerves.

EXPOSURE OF EXTERNAL POPLITEAL BEHIND TENDON OF BICEPS.

Position.—Patient on uninvolved side, rolled into slightly prone position; leg extended. Surgeon stands facing back of patient's knee.

Landmarks.—Tendon of biceps; head of fibula.

Incision.—About 4 to 5 cm. (1½ to 2 inches), along posterior edge of tendon of biceps, extending from over the prominence of the external condyle of the femur toward the posterior border of the head of the fibula.

Operation.—Divide skin and deep fascia. Expose the biceps tendon. Flex the knee to relax the tendon and search for the nerve near the attachment of the biceps tendon to the head of the fibula, near the outer edge of the gastrocnemius.

SURGICAL ANATOMY OF ANTERIOR TIBIAL BRANCH OF EXTERNAL POPLITEAL.

Description.—One of the terminal branches of the external popliteal. Commences between fibula and peroneus longus—pierces septum between peronei and extensors—passing obliquely beneath extensor longus digitorum to forepart of interosseous membrane. Runs forward on interosseous membrane between extensor longus digitorum and tibialis anticus, in upper part of leg—and between tibialis anticus and extensor longus hallucis, lower down. Passes under anterior annular ligament and ends in front of bend of ankle in external and internal branches. The anterior tibial nerve reaches the fibular side of the tibial artery at the junction of the upper and second fourths of the leg, thence lies in front of the artery to the ankle, and thence generally lies to its outer side.

EXPOSURE OF ANTERIOR TIBIAL NERVE NEAR ORIGIN.

Position.—Patient supine and inclined to uninvolved side; hip slightly flexed and rotated inward, so that knee rests upon inner aspect. Surgeon stands behind either limb, cutting from above on the right, and from below on the left.

Landmarks.—Outer tuberosity of tibia; head of fibula.

Incision.—Begins opposite the most external part of the tibial tuberosity, and about 1.3 cm. (½ inch) anterior to the head of the fibula, and passes downward for 5 to 7.5 cm. (2 to 3 inches).

Operation.—Having incised skin and fascia, the intermuscular septum between peroneus longus and extensor longus digitorum is sought, running obliquely downward and forward, and is opened up by blunt dissection. The anterior tibial nerve (and also the musculocutaneous nerve) is found deep in this intermuscular interval, running downward and inward, below the fibular head and covered by the extensor longus digitorum (the musculocutaneous running vertically downward).

Comment.—The anterior tibial nerve may be exposed at any point on the leg below its upper fourth, by the same operation as would expose the anterior tibial artery at the corresponding level (page 105).

SURGICAL ANATOMY OF THE CERVICAL SYMPATHETIC GANGLIA AND CORD.

Description.—The cervical portion of the gangliated cord lies deeply in the neck, embedded in the fascia between the muscles covering the front of the vertebral column behind, and the carotid sheath in front—and consists of three ganglia, together with the connecting cord:—(a) Superior Cervical Ganglion (largest)—lies opposite second and third cervical vertebræ (sometimes, fourth and fifth)—rests upon rectus capitis anticus major, posteriorly, —has internal carotid artery and internal jugular vein, anteriorly,—and pneumogastric nerve, externally. (b) Middle Cervical Ganglion (sometimes wanting) —opposite sixth (or seventh) cervical vertebra—upon, or close to, where the cord crosses the inferior thyroid artery. (c) Inferior Cervical Ganglion—between base of transverse process of seventh cervical vertebra and neck of first rib, lying between subclavian and vertebral arteries.

TOTAL EXCISION OF CERVICAL SYMPATHETIC GANGLIA AND CORD.

JONNESCO'S OPERATION.

Description.—The cervical sympathetic ganglia and cord have been incised, partially excised, and totally excised—chiefly for exophthalmic goiter and epilepsy—and also in hysteria, chorea, tumors of the brain, and glaucoma. The cord and one or both upper ganglia of one or both sides have been removed,—or both upper ganglia of both sides, with intervening cords, —or both cords with all the ganglia of one or both sides. The removal of the cord and ganglia of one side will be described below.

Position.—Patient supine; shoulders and head raised and latter turned to opposite side; neck, shaved, rests upon a narrow support (to render prominent). Surgeon to right, for both sides.

Landmarks.—Mastoid process; posterior border of sternomastoid; clavicle.

Incision.—Beginning opposite the posterior margin of the mastoid process, passes downward along the posterior border of the sternomastoid to just below the clavicle.

Operation.—Incise skin, superficial fascia, and platysma. Divide the external jugular vein between two ligatures. Displace the sternomastoid inward (or it may be split longitudinally near its posterior border and the parts retracted laterally). Expose the common sheath of the vessels by blunt dissection. Lift the carotid sheath, unopened, upward and retract it inward —when the cervical cord and superior and middle cervical ganglia will be exposed, lying upon the prevertebral muscles. Having well retracted the structures to that side toward which most easily displaced, isolate the trunk of the cervical sympathetic near the center of the incision. Follow it up to the superior ganglion, divide the communicating branches of the ganglion with delicate scissors, and remove the ganglion with fine forceps. Practising slight traction upon the distal end of the trunk, trace the cord down to the middle ganglion, which is similarly removed—carefully guarding, throughout, all important adjacent structures. Continuing gentle traction upon the cord, just sufficient to follow it, trace the main trunk down behind the clavicle to the inferior ganglion. Guard the spinal accessory nerve in the upper part of the neck—the nerves of the cervical plexus in the middle of the neck—the thyroid and vertebral vessels, recurrent laryngeal and phrenic nerves and pleura in the lower part of the neck—and the thoracic duct on the lower left side. In closing the operation, approximate the separated muscles with buried gut sutures—and close the superficial wound in the usual manner, unless temporary drainage be indicated.

CHAPTER V.

OPERATIONS UPON THE BONES.

OSTEOTOMY IN GENERAL.

Definition.—Any division of bone by cutting instrument.

Indications.—Deformities of bones and joints (such as result from congenital conditions); diseases of bones and joints, followed by weakening of bone and subsequent curvature or angularity; malunion following fracture; ankylosis.

Varieties.—(**a**) Linear Osteotomy; Simple division of bone in its continuity, by simple transverse, oblique or vertical section-line (*e. g.*, linear osteotomy of neck or shaft of femur for faulty ankylosis). (**b**) Cuneiform Osteotomy; Removal of a wedge-shaped piece of bone in its continuity (*e. g.*, cuneiform osteotomy for bent tibia),—or from, or including, one of its ends (*e. g.*, cuneiform osteotomy of a joint for ankylosis). (**c**) Osteo-arthrotomy; Though not a distinct variety of osteotomy, may be considered as an inter-articular osteotomy, linear or cuneiform.

General Manner of Performing Osteotomy as to the Instrument.—Osteotomy, in general, may be performed with an osteotome, an instrument ground evenly from both sides, and graded upon the handle to indicate depth of section,—with a chisel, an instrument beveled from one side only, and similarly graded upon handle,—or with a special saw.

General Manner of Performing Osteotomy as to Method of Operation.—(**a**) Open Method; in which the site of the bone-section is exposed to view by a preliminary operation. (**b**) Subcutaneous or Submuscular Method; in which the site of bone-section is reached through the smallest, simplest incision and the bone divided out of sight and by the sense of touch. Cuneiform osteotomy is nearly always done by the open method. Linear osteotomy may be done by the subcutaneous or by the open method—the former being more frequently done—the latter being preferable where the safety of the parts can be better preserved by first exposing them. Cuneiform osteotomy should be done subperiosteally where possible, and when not contraindicated (as by disease). Linear osteotomy should be done subperiosteally when performed by the open method, if possible and not contraindicated. Linear osteotomy is usually performed with an osteotome or a saw. Cuneiform osteotomy is generally done with a chisel (sometimes with a saw).

Instruments Used in Osteotomy.—Rubber tourniquet; scalpels; tenotomy knives; hemostatic forceps; dissecting and toothed forceps; scissors, curved and straight, sharp and blunt; retractors; chisels, various sizes and widths; osteotomes, various sizes and widths; mallets, preferably of wood; saws, especially of the osteotomy type (with narrow blade and with cutting part only at end, and with blunt point and large handle), and also chain-saws, Gigli saws, and butcher saw; periosteal elevators, curved and straight; rugines; raspatories; blunt dissector; bone-holding forceps; bone-cutting forceps; needles, straight and curved; needle-holder; chromic and plain

gut; silkworm-gut and kangaroo tendon; bone-drills; silver wire; pegs and nails, ivory and metallic; sand-bag (for part to rest upon and dissipate the jar).

Preparation of Patient.—The part shaved.

Position.—The position of patient, surgeon, and assistant will be determined by the special operation.

LINEAR OSTEOTOMY BY THE SUBCUTANEOUS METHOD.

Steps of Operation Preparatory to Division of Bone.—Having exsanguinated the limb by elevation, followed by the application of a rubber tourniquet (which may generally be dispensed with), the portion of the limb involved is placed upon a sand-bag (previously dampened and covered with several layers of wet, sterilized towels, to prevent the flying of dust), which forms a yielding bed into which the part may be moulded and in which it may receive the jar of the blows from the mallet. An incision, just long enough to admit the osteotome or saw, is made over the site of the bone-section. The incision is as limited as possible, and so placed as to reach the bone by the most direct and safest route, and with the least danger to important structures. It should be, where possible, in a line with the overlying muscle-fibers—should avoid vessels and nerves—and is generally parallel with the bone. This incision is usually made directly to the bone with one stroke—it being impossible, from the small size of the wound, to recognize the intermuscular planes, or the bone's exact level, if at any depth from the surface. Having made a path to the bone, the remaining steps of the operation will depend upon the instrument with which the division of the bone is to be made.

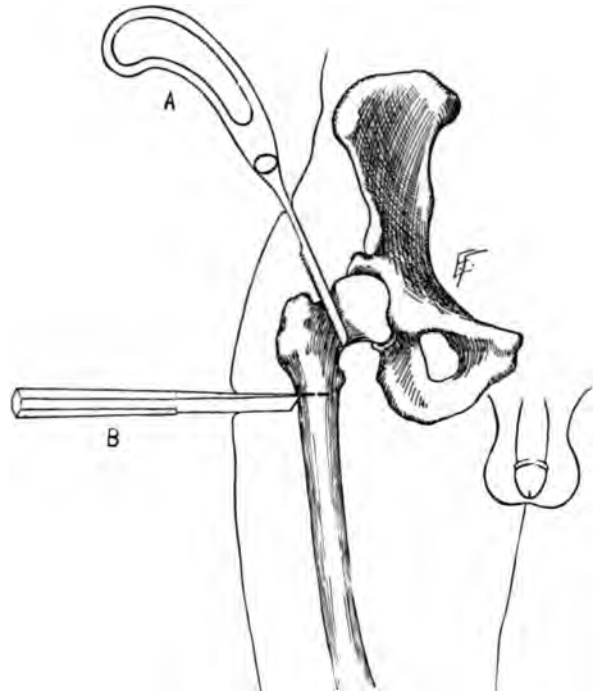

Fig. 121.—LINEAR OSTEOTOMY BY THE SUBCUTANEOUS METHOD: —A, Linear osteotomy of anatomical neck of femur with saw; B, Linear osteotomy of surgical neck of femur with osteotome.

Division of Bone with Osteotome.—Having made the incision through the soft parts with a knife, the knife is not withdrawn but allowed to remain *in situ* as a guide—upon this an osteotome (somewhat narrower than the

bone to be divided) is introduced, entering the wound with the length of its cutting-edge corresponding to the length of the wound. It is carefully passed down, in contact with the knife, to the bone, and the knife withdrawn. The osteotome, constantly held in contact with the bone, is now turned with its cutting-edge in the direction of the desired bone-section (which is generally at a right angle to the incision of the soft parts). In the act of turning the osteotome into position, the soft parts are levered away by the blunt sides of the instrument, and the bone is hugged, but care is used not to detach the periosteum (which the knife-incision may have cut) (Fig. 121, B). The osteotome is held in the surgeon's left hand near its cutting end—being grasped in his full hand, the ulnar margin of his hand resting on the patient's limb to steady the instrument. The instrument should cut away from important structures, and preferably toward the surgeon. After each stroke of the mallet, the osteotome should be shifted, traveling back and forth in the line of section, that it may not bind in any one place. In section of thick bones, if the instrument bind, it is withdrawn and a thinner (not narrower) one is introduced—and subsequently a still thinner, if necessary. Progress through the bone is determined by the skilled sense of touch. The section should be evenly made, as to depth, completely across the width of bone, traveling back and forth, no two blows being made in one site. Never remove the instrument from the groove in the bone when once the section has been commenced (unless a larger instrument catches in the section and has to be replaced by a thinner one), for it is often hard to regain the groove. The last portion of bone on the far side of the section, when important structures are just beyond, need not be cut with the osteotome, but may be bent or broken subsequently by manipulation of the limb.

Division of Bone with Saw.—A special osteotomy saw, generally of the Adams type, is used. The operation is very similar to that just described, except in the substitution of the saw for the osteotome. The skin incision is placed as in the above operation, but is made with a tenotome instead of an ordinary knife—usually cutting in the line of the muscle-fibers and in the axis of the limb. When the bone is reached, the blade of the tenotome is turned so as to cross the bone transversely and is made to cut a path for the saw across the bone—the non-cutting part of the handle of the tenotome doing no harm to the soft parts between the bone and wound of entrance. When the way for the saw has been prepared, the tenotome is left *in situ* as a guide. Upon this the blade of the saw is introduced down to the bone and its cutting part pushed on across the portion of bone to be divided (Fig. 121, A). The bone is to be sawed with short strokes, guarding against thrusting the point of the saw into the soft parts, especially at the beginning and ending of the section. The section may be nearly made with the saw and completed by manual bending or breaking.

After-treatment.—Following osteotomy, the limb, or part, is in a condition of compound fracture made under the most favorable circumstances. Some form of splint, or a plaster-dressing, must immobilize the limb and keep the ends of the bones in apposition. The wound is closed by suture—no drainage being used in clean cases.

Comment.—(1) In division by an osteotome, the osteotome itself is sometimes used to cut its way through the soft parts, instead of knife. (2) When the bone-section is nearly complete, bending is especially applicable in young, tender bones. (3) The section of the bone should generally be completed by instrument, and not by breaking, as a splinter of bone may do damage to adjacent parts.

LINEAR OSTEOTOMY BY THE OPEN METHOD.

Steps of Operation Preparatory to Division of Bone.—The site of the bone-section is exposed by an incision so placed as to reach the bone most readily and safely, seeking an intermuscular plane where possible. Having passed through skin, fascia—and through or between muscles—the soft parts are opened up and retracted to either side—and the region of bone fully exposed to view. Where it is possible to do so, and where it is not contraindicated, the periosteum is incised in the long axis of the bone, freed from its circumference, and retracted with the soft parts. The bone-section may then be made with an osteotome or with a saw:—

Division of Bone with Osteotome.—The osteotome is introduced at once upon the bone, in the direction the section is to be made—after which it is manipulated as in the subcutaneous method—much greater control of the instrument being possible.

Division of Bone with Saw.—The saw is similarly introduced at once upon the bone, in the direction the section is to be made. The section is then made by short strokes, while the parts are well retracted and the entire operation exposed to view.

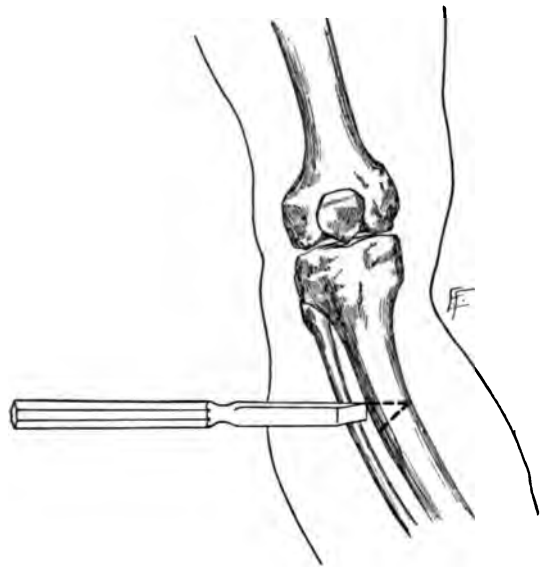

Fig. 122.—CUNEIFORM OSTEOTOMY:—Chisel is shown removing wedge-shaped piece of bone from bent tibia.

After - treatment.—Unless contraindicated, the periosteum should be sutured with gut—the sutures at the same time passing through the muscles and quilting them together. The wound is then closed in the usual way—and a retentive apparatus applied, as described in the last operation.

Comparison.—In subcutaneous osteotomy the use of the osteotome is safer, less damaging, and the section is cleaner than by the saw. In open osteotomy the saw is preferable, especially the chain or Gigli saw. In the open method, while a larger wound of entrance is made, the bone-section is more accurately made and less damage is done to the neighboring tissues.

CUNEIFORM OSTEOTOMY.

Description.—A wedge-shaped piece of bone is removed, the size of which is determined by the needs of the case—the general rule being that the sides of the wedge should be at right angles to the axis of the bone just

above and below the section—ordinarily, however, a smaller wedge suffices. The wedge usually extends entirely through the bone, its base being upon one surface and the apex upon the opposite—but it may extend only two-thirds or three-fourths of the way through, the balance being bent or broken. The operation is nearly always done by the open method.

Operation.—Having exsanguinated the limb by elevation, followed by the application of a rubber tourniquet (which is much more frequently used than in the linear form of osteotomy) the limb is placed upon a sand-bag. The incision is placed over the site of the base of the wedge to be removed and is considerably longer than the base of the wedge—and is so planned as to enable the bone to be reached through the most direct and safest route, and to enable the muscles to be separated rather than cut. The skin and fascia are first incised—the muscles separated in their intermuscular cleavage line and retracted—and the periosteum incised in the axis of the bone, down to the bone, and retracted with, and adherent to, the soft parts. This clearing of the bone subperiosteally is accomplished with a curved periosteal elevator, the clearing being done more extensively at the site corresponding with the base of the wedge. The chisel is the best instrument with which to perform cuneiform osteotomy—though a chain or Gigli saw may sometimes be used advantageously, and even an ordinary saw may be conveniently used in some cases of angular ankylosis (Fig. 122). The chisel is held like an osteotome, for the sake of steadiness. The beveled edge of the chisel is directed toward the wedge of bone to be removed. If the wedge be of considerable size, it cannot be removed with accuracy in one piece—a small wedge, narrow at its base, must be first removed—and then slices may be chiseled from the sides of this until a cuneiform space representing a wedge of the requisite size is removed. Having removed the wedge of bone, the ends of the bone are put into position—the periosteum is sutured with gut—the wound closed—and the limb put up in an immovable splint.

Comment.—In this, as in the other forms of osteotomy, additional means may be used for holding the divided ends of the bone in place, besides the special form of splint—such as wiring, pegging, suturing, and other devices mentioned under operations for ununited fractures.

OPERATIONS FOR RECENT OR UNUNITED FRACTURES IN GENERAL.

Operations for ununited fractures resolve themselves, as far as the forms of the bones are concerned, into three classes—those for fractures of the long bones—of the short bones—and of the mixed bones. The general principles involved are the same in all classes. Fractures of the patella and olecranon require special mention.

The principles involved:—the placing of freshened ends of bones in good position, without too great tension, and without intervening soft parts—and the maintaining of these ends strictly in position by competent immobilizing splint.

Following is a brief summary of the technic employed in the majority of cases;—Exposure of ends of bones as nearly subperiosteally as possible—resection of the ends as nearly transversely as the nature of the fracture will permit—if the ends of the bones can be easily approximated and easily retained in position, place them in apposition, suture the periosteum, approximate the muscles by buried sutures, close the wound, and apply an immobilizing splint. If the ends are not likely to be easily kept in ap-

proximation (especially as the result of an oblique section), one of the methods of holding them in apposition (to be described below) may be resorted to —in addition to placing the ends in contact and applying a retentive form of apparatus.

In operating, some form of tourniquet is usually applied. The site of operation is to be shaved. The position of patient, surgeon, and assistant will be determined by the special operation.

The instruments used are those employed for Osteotomy (page 184).

OPERATION FOR RECENT OR UNUNITED FRACTURE BY RESECTION OF ENDS OF BONES, WITH RETENTION OF COAPTATED ENDS BY IMMOBILIZING SPLINTS.

Description.—The ends of the bones are exposed and excised, and the freshened ends are then brought into contact and held in apposition by a splint or a plaster cast.

Operation.—Having exsanguinated the limb and applied a tourniquet, an incision, sufficiently free to allow of protrusion of the ends of the bones, is made in the long axis of the limb, directly over the ends of the bones — and placed so as to give free access by the most direct and safest route to the involved site. The skin and fascia are divided—the muscles are separated in their intermuscular planes and retracted —or, if separation of the muscles in their planes be impossible, they are divided in the direction of their fibers. Important vessels and nerves are carefully avoided, being retracted to one side. The wound is made fully large and the lateral retraction of the soft parts sufficient to make the necessary manipulations possible without adding to the traumatism. The ends of the bones are fully exposed and entirely freed of all tissue which may intervene between the fragments, whether normal or cicatricial. As the ends of the bones are approached, care is taken to avoid injuring the periosteum—which should be split longitudinally and freed circumferentially from the ends of the bones, without otherwise severing its connection, and should be raised without separation of overlying muscle, that is, as a musculo-periosteal covering. The end of each bone is dealt with in turn, and, after being thoroughly freed, is, where possible, protruded through the wound, the limb being bent at an angle for this purpose

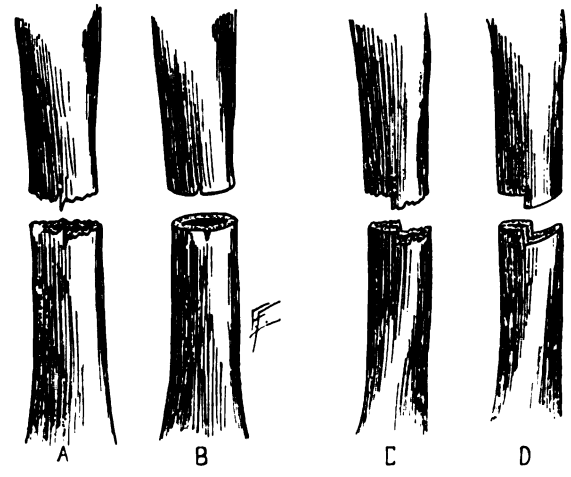

Figs. 123-126.—I—Operations for Ununited Fractures by Simple Section:—A, B, Simple transverse fracture, followed by transverse section of bones; C, D, Irregularly transverse fracture, followed by section of bone parallel with fractures.

and the soft parts well retracted, the periosteum being carefully peeled back during this step. A minimum slice of bone is now removed from the end of each bone, simply enough to insure a fresh, raw surface upon each. If the bones have been protruded, this section is generally best made with a butcher's saw. If the ends have not been protruded through the wound, after they have been well freed, it is best to slip a chain or Gigli saw between the bone and the periosteum and thus make the section. The section may also be made, though generally less satisfactorily, with a chisel. The direction of the section will depend largely upon the nature of the ends of the bone;—if a rather transverse fracture, the section is made transversely;—if a very oblique fracture, the section is made obliquely (Figs. 123–126, A, B, C, D; and Figs. 127–130, A, B, C, D). Whether the section be made transversely or obliquely, the section is so planned as to leave a limb in correct position, as to its axis and as to its rotation, and is so made as to secure two parallel surfaces for contact. An exception to this is where some special form of section is made, as when the bones are so sawed as to have an angularity of one fit into a depression of another, producing the mortising effect — the great principle being that the ends of the bones should be cut so as to fit each other. A transverse section of the bones is always preferable, unless involving too great a sacrifice of length. The ends are now approximated in the position in which the bones will remain, and are held in this position during the remainder of the operation and until the permanent splint be applied. The periosteum is sutured with gut. The muscles are brought together with buried gut sutures. The outer wound is closed in the usual way. The limb is then placed in a permanent splint, or in a plaster cast, with extreme care, so steadying the parts during the dressing that the ends of the bones remain undisturbed.

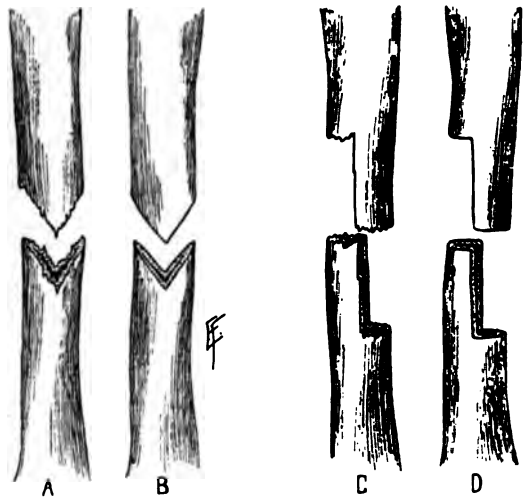

Figs. 127–130.—II.—Operations for Ununited Fractures by Simple Section:—A, B, Wedge-shaped, and C, D, rectangular fracture, followed by section of bone parallel with fracture.

Comment.—(1) The operation is, practically, that of osteotomy by the open method. (2) In a recent case, the after-treatment is that of a compound fracture, with the limb put up in a position to relax the pull on the fractured ends. (3) In old cases where bands of fascia, or tendons, are apt to draw the ends out of place, these should be divided. (4) Where it seems likely that the ends of the bones will tend to displacement, especially in such cases as the femur, a process of mortising may be carried out in fashioning the ends of the bones for approximation.

OPERATION FOR RECENT OR UNUNITED FRACTURE BY WIRING OF ENDS OF BONES, WITH OR WITHOUT RESECTION.

Description.—In addition to the retention of the coaptated ends of the bones by splints, the ends are previously drilled and wired into contact. In the case of new fractures, where the ends are left so shaped as likely to remain in position when wired, resection of the ends of the bones need not be done —otherwise the ends should be resected. In all cases of old fracture the ends of the bones are always resected, so as to present freshened surfaces.

Operation.—The steps of the operation are the same, in all respects, as for resection with retention by splints—up to the exposure and clearing of the ends of the bones—after which the technic will differ, dependent upon whether the bones are resected or not;—(a) Wiring of the bones without resection:—The ends of the bones are grasped and steadied by some special form of bone-holding forceps, while holes for the passage of wire are drilled

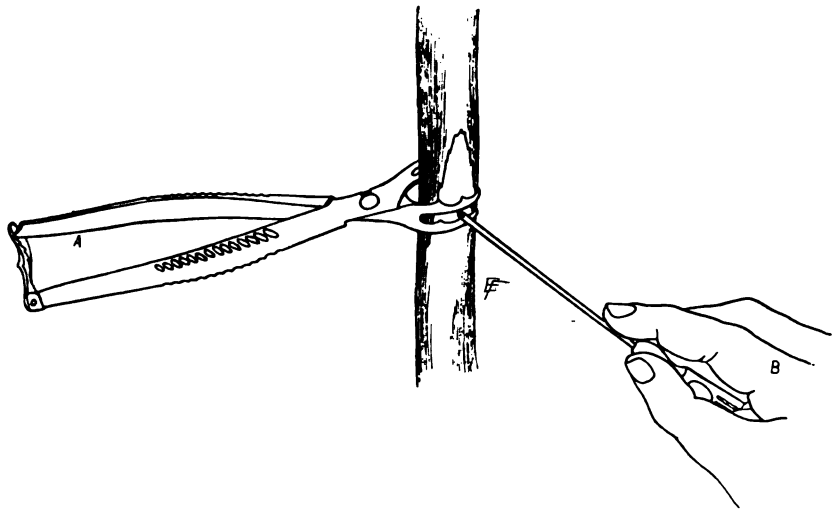

Fig. 131.—METHOD OF DRILLING BONE FOR WIRING:—A, Bone holding forceps; B, Hand-drill.

—sufficient in number to furnish the desired strength and so planned in position as to retain the normal axis of the bone (Fig. 131). The holes may be drilled and the silver wire passed in several ways. Where the fracture is practically a transverse division of the bone, the drill-holes are usually made to pass through one wall of the upper and the corresponding wall of the lower fragment, the wire thus passing through but a small portion of the medulla of the bone (Figs. 132–134, A, B, C, D). In the case of an oblique fracture, the holes may be drilled and the wire passed in the same way—or the fragments may be held in position and the holes drilled through opposite walls and the intervening medullary substance (Figs, 135, 136, and 137, and Figs. 138–140). The ends of the wire, in either of the methods above mentioned, may then be twisted, cut short and pressed into the periosteum and bone—or may be twisted long and brought out of the wound (Figs. 141–143). In both methods the periosteum is pierced by wire, though elsewhere it is preserved as intact as possible upon the bones. (b) Wiring of the bones

after resection:—The resection of the ends of the bones is accomplished just as in the operation for ununited fracture by resection of the ends of the

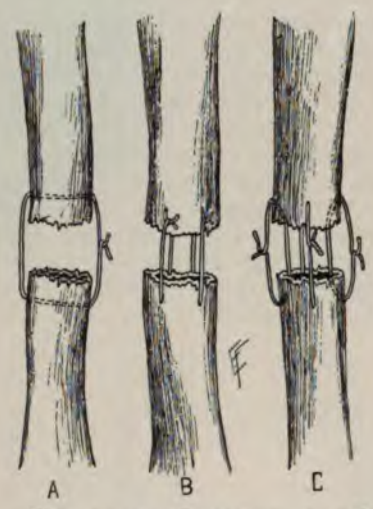

Figs. 132-134.—Operations for Ununited Fractures by Section and Wiring:—I—In transverse fractures;—A, Single wire through both walls of each bone; B, Double wire through both walls of each bone; C, Wires passed through single wall of each end. These forms may be used without section of bone.

Figs. 135-137.—Operations for Ununited Fractures by Section and Wiring:—II—In oblique fractures;—A, Double wires through both walls of each end, in axis of bone; B, Same, crossing fracture at right angle; C, Loop of wire carried through drill-hole, and free ends brought around bone and through loop and twisted. These forms may be used without section of bone.

Figs. 138-140.—Operations for Ununited Fractures by Section and Wiring:—III—By simple loop-ligatures;—A, By double loops around bone at right angle to axis of bone; B, Double loops at right angle to line of oblique fracture; C, Double loops, as in A, reinforced by lateral wire-loops. These forms may be adopted without section of bone.

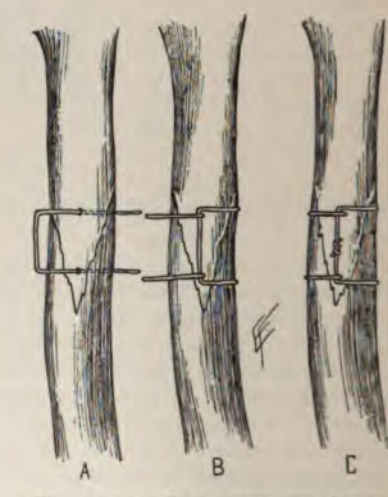

Figs. 141-143.—Operations for Ununited Fractures by Section and Wiring:—IV—By frame-ligature;—A, B, C, First, second, and third stages of the frame-ligature.

bones, with retention of the coaptated ends by immobilizing splints (page 189). The ends of the bones are then drawn back into their musculo-periosteal sheaths—and the ends are then wired as in (a) above. Following the approximation of the ends of the bones, the periosteum is sutured with gut—the muscles are brought together with buried gut sutures—the outside wound closed as usual—and an immobilizing splint applied. The wire is not expected to be removed when buried,—when left long, it is subsequently (after firm union) untwisted and drawn out, to accomplish which, it is sometimes necessary to expose the parts by incision down to the bone.

Comment.—The drill-holes should be a little larger than the silver wire used. The wire should be fairly heavy. The holes are drilled from 8 mm. to 1.3 cm. ($\frac{1}{3}$ to $\frac{1}{2}$ inch) from the ends of the bones, penetrating obliquely if but one wall of the upper and one wall of the lower fragment be drilled—and penetrating at a right angle to the surface, if the drilling pass transversely through opposite walls. In drilling for oblique fracture, the suture should pass at a right angle to the line of fracture.

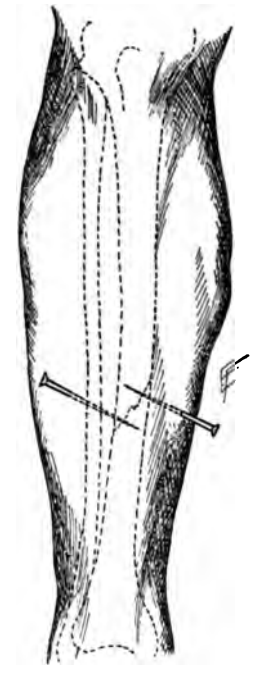

Fig. 144. — Uniting Fractured or Resected Bone by Nailing.

OPERATION FOR RECENT OR UNUNITED FRACTURE BY SUTURING, WITH OR WITHOUT RESECTION.

Description.—The operation is here practically the same as that for ununited fracture by wiring—except that heavy chromic gut, kangaroo tendon, or silk (preferably one of the first two) is used to approximate the ends of the bones.

Comment.—As the chief dependence is in the ultimate bony union between the fractured or resected ends, and as the chief function of wire, gut, tendon, or silk suture is temporarily to hold the ends in position until union is sufficiently advanced to fix the ends of the bones firmly and permanently, it is unquestionably best to use a material which, while fulfilling that temporary office, will then disappear of its own accord and give no future trouble—and, therefore, heavy chromic gut or kangaroo tendon is the ideal material for this purpose, if the conditions of the case permit.

OPERATION FOR RECENT OR UNUNITED FRACTURE BY NAILING, PEGGING OR SCREWING ENDS OF BONES, WITH OR WITHOUT RESECTION.

Description.—The ends of the fractured bones, with or without resection, are brought and held together by means of plated nails or screws, ivory pegs, or by means of metallic plates held in place by nails or screws, or by metallic bands.

Operation.—The ends of the bones are exposed, freed, and, if necessary, resected, as in the above operations. If the fracture, or section be trans-

verse, the nails, pegs, or screws are put in obliquely, passing from without through the proximal wall of the upper fragment, through the medullary substance, and into the wall of the lower fragment, from within outward. Two or more nails or pegs are generally inserted, passing in different directions (Figs. 144 and 145). If the section, or fracture, be oblique, the nails are put in at a right angle to the surface of bone and pass transversely through. Where plates are used, they are placed over the line of fracture or resection—some of the screws passing into the upper fragment, and some into the lower

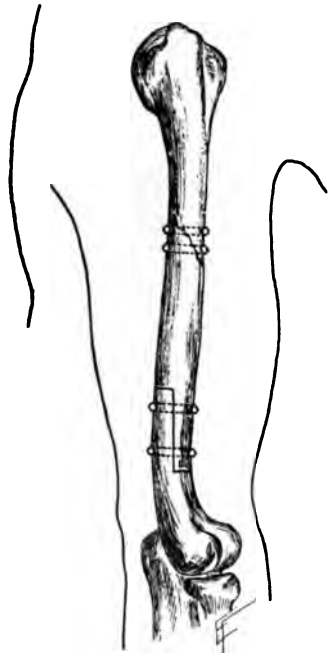

Fig. 145.—Uniting Fractured or Resected Bone by Pegging.

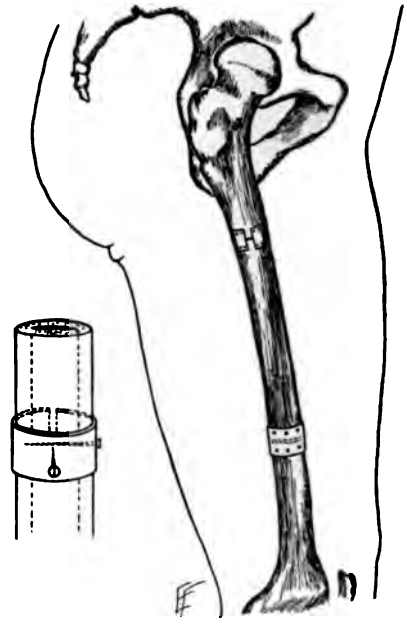

Figs. 146 and 147.—Uniting Fractured or Resected Bone by Screwing. Screws may be used alone—or in metallic plates, as shown in diagram to left.

(Figs. 146 and 147). As little damage as possible is done to the periosteum. The muscles are brought together by buried gut sutures—the wound closed—and the limb immobilized.

Comment.—The nails and screws generally protrude through the skin and are removed in about two weeks, or remain longer. Ivory pegs are similarly treated, or, if very short, may be left *in situ*. Metallic plates and bands are expected to be left *in situ*.

OPERATION FOR RECENT OR UNUNITED FRACTURE BY PARKHILL'S CLAMP.

Description.—The fragments of bone are here held together by means of a special form of clamp consisting of four long steel screw-pins and an interlocking mechanism.

Operation.—The ends of the bones are exposed and freed in the ordinary

manner—and resected, if necessary. Two holes are drilled in the long axis of each fragment, in direct line with each other. Four long steel screw-pins are then screwed into these holes by means of a clock-key attachment—after which the "wings" of the instrument are adjusted. While the ends of the bones are held in accurate apposition and care taken that the proper

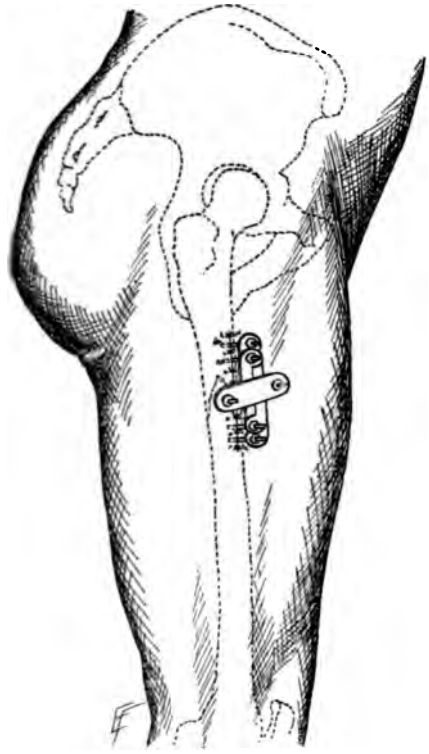

Fig. 148.—Operation for Fractured or Resected Bone by Parkhill's Bone-clamp: —Surface view of clamp in position.

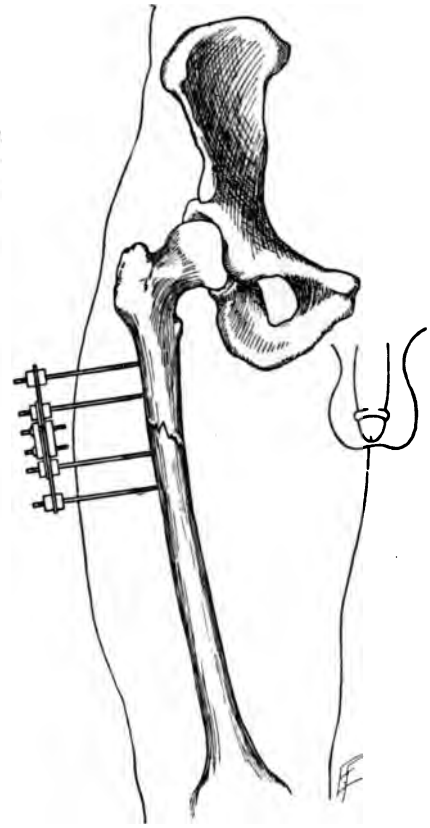

Fig. 149.—Operation for Fractured or Resected Bone by Parkhill's Bone-clamp: —Side view of clamp in position.

axis of the bone is secured, the two fragments are clamped together in the special manner of the instrument. The muscles and other soft parts are then adjusted about the screws of the clamp, which projects without the wound. The dressing is then applied—and the pins of the clamp not removed for from four to six weeks (Figs. 148 and 149).

OTHER OPERATIONS FOR RECENT OR UNUNITED FRACTURES.

(1) **Ligation of Bone.**—One or more pieces of wire are passed around the fractured portion of bone, either at a right angle to the axis of the bone, or at a right angle to the line of fracture. These are twisted, cut short, and

buried. The bone may be notched to aid in holding the wire in place. Longitudinal loops may unite the circumferential wire bands (Figs. 138–140).

(2) **Combined Ligature and Suture.**—A hole is drilled through the fragments at a right angle to their line of fracture—a loop of wire is passed through, given a half-turn in the center, and the two ends passed around the sides of the bone and through the loop and twisted (Fig. 137, C).

(3) **Frame Ligature of Bone.**—Drill two holes through the fragments, in the long axis of the bone—pass the free ends of a wire loop through the holes—pass the loop over the free ends and draw tight—then bring the free ends around to the holes through which the looped end originally passed and

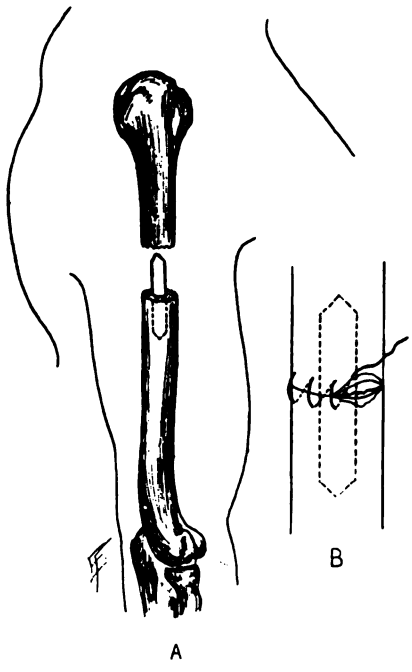

Figs. 150 and 151.—Operation for Fractured or Resected Bone by Intramedullary Pegging:—A, Peg is seen in medullary cavity of lower bone, and about to be introduced into that of upper; B, Periosteum is being sutured along margins of bone.

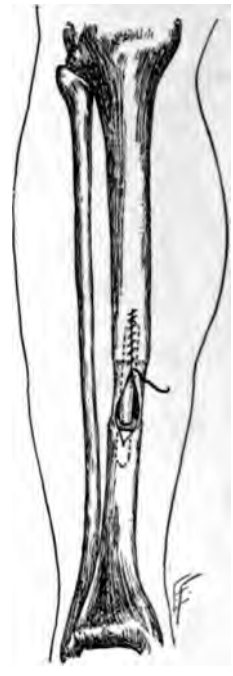

Fig. 152.—Operation for Fractured or Resected Bone by Intramedullary Pegging:—Where part of one bone has been excised and periosteum is being sutured around peg.

carry them under the wires emerging from those holes and twist them together in the long axis of the bone (Figs. 141–143).

(4) **Intramedullary Pegging.**—Pegs of ivory, or of fresh, or decalcified bone, are lightly driven into the medullary canal of one bone, and the ends of the fractured bone so displaced, temporarily, as to enable the medullary cavity of the opposite fragment to be slipped over the opposite end of the peg (Figs. 150 and 151). Where there has been a loss of substance of bone and the periosteum corresponding to the absent bone is preserved, this has been sutured over the bone peg with success, especially in the young (Fig. 152).

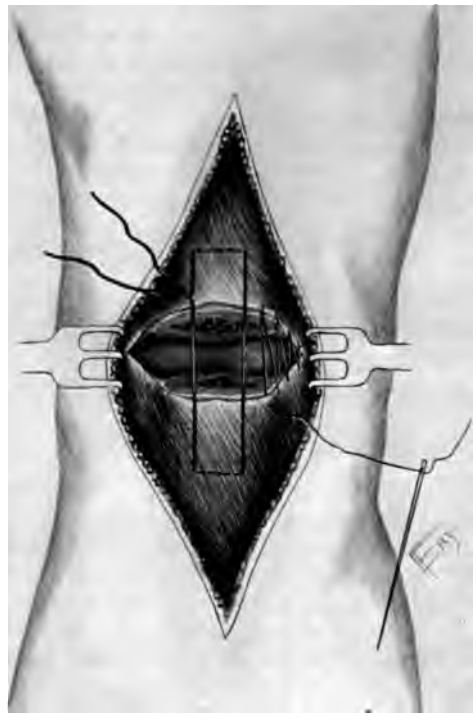

Fig. 153.—OPERATION FOR FRACTURED PATELLA BY STIMSON'S METHOD OF MEDIATE SUTURE: —A, Heavy silk suture (of mattress variety) passing through greater thickness of quadriceps extensor tendon, above, and ligamentum patellæ, below; B, Chromic gut suture of torn capsule and fibro-periosteum.

OPERATION FOR RECENT OR UNUNITED FRACTURE OF PATELLA

BY STIMSON'S METHOD OF MEDIATE SUTURE.

Description.—The margins of bone, after being cleared, and, if necessary, freshened, are held in position by a heavy silk suture-loop passed transversely through the quadriceps extensor tendon above, and the ligamentum patellæ below.

Position.—Patient supine; limb fully extended. Surgeon on side of operation. Assistant opposite.

Landmarks.—Contour of patella.

Incision.—Median, in long axis of limb, with its center over center of patella and extending considerably above and below the patella but not passing into muscular tissue.

Operation.—The incision extends through skin, fascia, prepatellar bursa, expansion of quadriceps extensor tendon, and periosteum directly to the patella bone. The soft parts are well retracted, so as to expose the entire extent of the transverse fracture (which is possible because of the length of the incision) (Fig. 153). The joint is irrigated to remove the clots. If the fracture be recent, no removal of fibrous tissue or bone is necessary. If old, each fragment is carefully seized with bone-holding forceps and steadied

in such a position as to render it accessible to the saw, and a thin slice of bone is then removed. A heavy silk ligature, threaded upon a curved needle, is now carried transversely through the ligamentum patellæ near its apex, passing through about two-thirds of its width and thickness—then transversely through the quadriceps extensor tendon, near the upper border of the patella, also passing through about two-thirds of its width and thickness. While the fragments are held in close contact this ligature is tightly tied. The torn capsule on either side of the patella and the fibro-periosteum are sutured with chromic gut. The fibrous tissues overlying the patella, and divided in the median incision, may then be sutured with buried gut suture. The skin wound is closed. No drainage is used. The limb is put up in full extension.

Comment.—In some old cases the quadriceps extensor tendon has contracted to such an extent that it is necessary to lengthen the common quadriceps extensor (see operation for muscle-lengthening, page 208).

OPERATION FOR RECENT OR UNUNITED FRACTURE OF PATELLA

BY WIRING OR SUTURING.

Description.—The ends of the bones, after being cleared, and, if necessary, freshened, are drilled and wired together, the wire being buried and left—or they may be sutured with an absorbable material. The joint may be exposed by a median vertical, transverse, or by Cheyne's oval incision—the last being here described.

Position—Landmarks.—As in the above operation.

Incision.—Oval, outlining a flap with upward convexity, which is raised from over the patella and temporarily turned downward. The incision begins 2.5 cm. (1 inch) to one side of the patella, on a level a little below the fracture—extends vertically upward and then curves across the front of the thigh about 2.5 cm. (1 inch) above the upper border of the patella, and descends on the opposite side to a point corresponding with its commencement. This flap-incision gives a full field and places the scar above the patella.

Operation.—The fractured ends of the bones are exposed, the joint irrigated, and the fragments slightly everted and examined. All interposed periosteum, fibrous and other tissue is removed. In recent cases no removal of bone is ordinarily indicated. In old cases a thin slice of bone is removed from each fragment. Each fragment is now grasped in turn by means of stout bone-forceps, injuring the bone as little as possible while firmly steadying it (Fig. 154). One, two, or three wire sutures, as seem indicated, are now introduced in the following manner;—Two holes are drilled directly opposite each other in a vertical line, in the upper and lower fragments, a short incision being made for the drill through the fibrous covering of the patella, within 8 mm. to 1.3 cm. ($\frac{1}{3}$ to $\frac{1}{2}$ inch) of the fractured edges—the margins of the incision through the fibrous tissue being drawn aside and the drill (hand or motor) directed obliquely, so as to come out at the fractured margin after having passed through about two-thirds of the thickness of the bone. All the drill-holes are first made, and are made from without inward. Care is taken that each pair of holes is drilled immediately opposite and that their points of emergence on the fractured surfaces are on the same level. The wires are now passed, are grasped with strong forceps, and, while an assistant firmly approximates the margins of the fragments, these wires are tightly

twisted for three or four turns, cut off about 6 mm. (¼ inch) long, bent upon the bone, and slightly buried by one or two blows of the mallet. The periosteum which has been drawn out from between the fragments of bones is stitched together with chromic gut to the opposite lip of the torn periosteum.

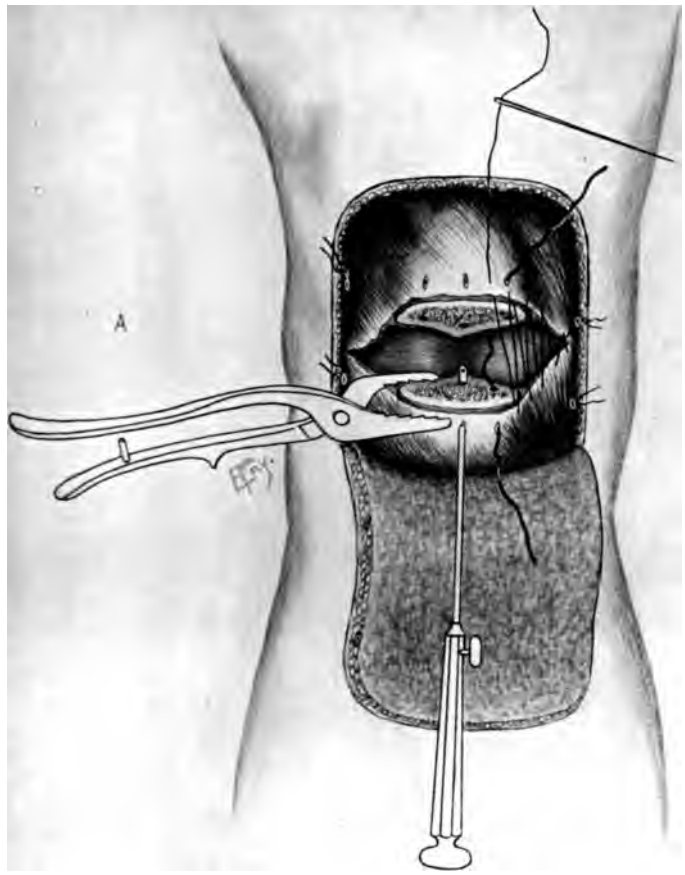

Fig. 154.—Operation for Fractured Patella by Wiring:—A, Lower fragment of patella steadied with bone-holding forceps; B, Drill in act of making holes for passage of silver wire, one piece of which is seen in position; C, Chromic gut suture of torn capsule and fibro-periosteum.

The rent in the capsule generally found on each side of the fractured patella is similarly sutured with gut. The fibrous covering of the patella, incised in raising the oval flap, is sutured with buried gut. The wound is closed throughout—no drainage being used. The limb is put up in full extension.

Comment.—Chromic gut, kangaroo tendon, and silk are also used in the same manner as wire.

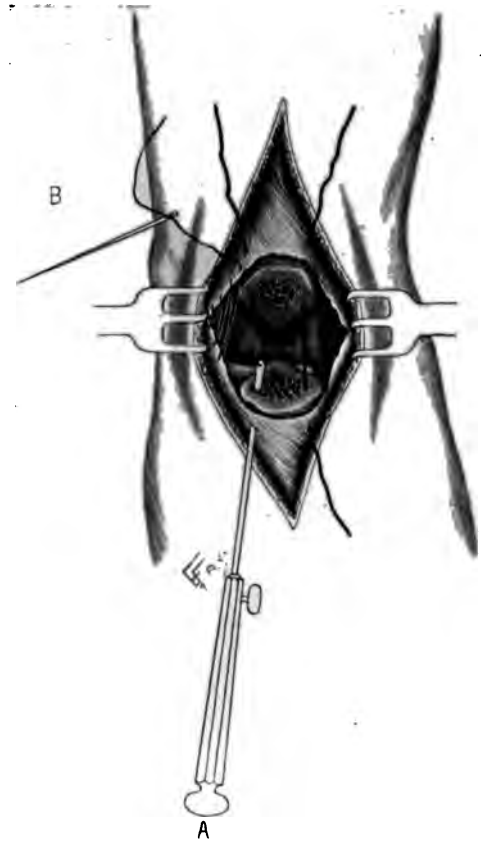

Fig. 155.—Operation for Fractured Olecranon by Wiring:—A, Drilling holes for passage of silver wire, one suture being seen in position, and one being drawn through; B, Chromic gut suturing of torn capsule and fibro-periosteum.

OPERATION FOR RECENT OR UNUNITED FRACTURE OF OLECRANON

BY WIRING OR SUTURING.

Description.—The olecranon is quite frequently fractured at its junction with the shaft of the ulna—and is repaired by wiring or suturing in the same general manner as in the case of fracture of the patella.

Position.—Patient supine; forearm drawn across chest, by an assistant on the opposite side, presenting to the surgeon the semiflexed elbow, while exposing the fragments; and fully extended by the side while suturing. Surgeon stands opposite the elbow.

Landmarks.—Contour of olecranon; shaft of ulna; condyles of humerus.

Incision.—The site of fracture may be exposed—(1) By an oval incision;—beginning to one side of lateral border of olecranon, just below the fracture—passes upward in axis of limb for about 2.5 cm. (1 inch) above the olecranon—thence curves across arm and descends to a corresponding point on the opposite side—thus furnishing a free exposure of the fracture and providing a scar which falls out of the way of pressure. (2) By a median longitudinal

incision;—beginning and ending considerably above and below the line of fracture, but not involving the muscles above or below—and having its center over the fracture. The length of this incision allows of sufficient lateral retraction to well expose the parts (though less perfectly than the incision just described).

Operation.—The incision passes through skin, fascia, bursa, fibrous expansion of the triceps tendon, and periosteum directly onto the bone (Fig. 155). The manner of exposing the fractured ends, irrigating the joint, removing a slice of bone from each fragment in old cases, drilling the fragments, passing and tightening the wire, suturing the torn periosteum and fascia, and closure of wound are similar, in all practical essentials, to the corresponding steps in the operations just described upon the patella (page 198). The limb is put up in full extension.

Comment.—(1) Chromic gut, kangaroo tendon, and silk may be used instead of wire. (2) In some old cases, where much retraction of the triceps has occurred, that muscle should be lengthened, as described under muscle-lengthening (page 208).

SEQUESTROTOMY.

Description.—An operation for the removal or excision of a sequestrum (dead bone) *en masse*. The operation might be more properly termed sequestrectomy. The site of the sequestrum is generally determined by the presence of one or more sinuses, together with the history of the case.

Position and Preparation.—Patient is so placed as to expose the in-

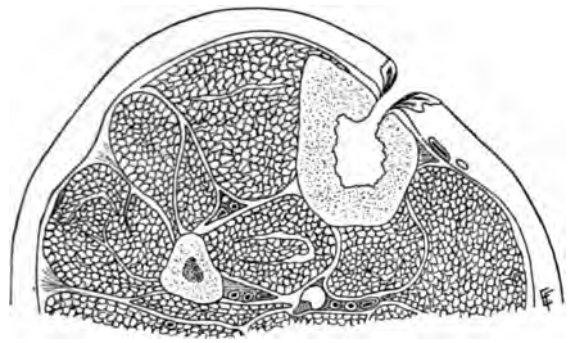

Fig. 156.—Cross-section of Leg, Showing a Sequestrum-cavity.

volved site most conveniently. A constrictor is usually applied, where possible, to control hemorrhage.

Landmarks.—Generally the existence of one or more sinuses; the known anatomy of the part.

Incision.—Generally placed in the long axis of the limb, or in such a position as to fall in with the intermuscular cleavage line and so as to lead to the site by the safest route—with its center over the sinus, or extending between the two chief sinuses (Fig. 156).

Operation.—The incision passes down to and through the periosteum. The soft parts, including periosteum, are then retracted laterally, fully exposing the bone in the neighborhood of the sinus, or between two or more sinuses. It may be at once possible to grasp the sequestrum with strong forceps

introduced through the sinus-opening and draw it out—or the sinus-opening may be sufficiently enlarged for this purpose by rongeur forceps. If neither of these can be done, the sinus may be enlarged with the curved chisel—or the bone between two sinuses may be chiseled away—or the bone may be chiseled away in the long axis of the sequestrum, even where but one opening exists—or a trephine-opening (one or more) may be made instead of using the chisel. Following the removal of the sequestrum, the cavity of the bone should be well scraped. The periosteum and muscles are then united by buried gut sutures, and the skin closed with sutures of silkworm-gut or silk—drainage being established to the bottom of the bone cavity in the most favorable position. If the limb be weakened by the operation, it should be put up in a splint.

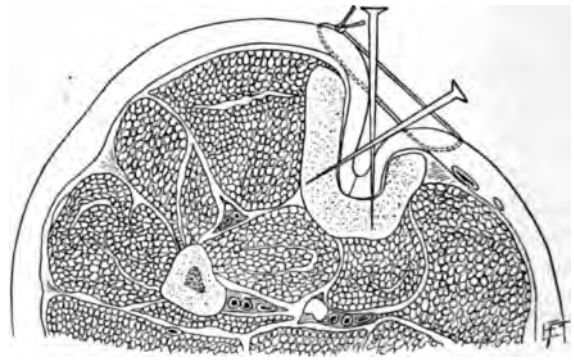

Fig. 157.—SEQUESTROTOMY:—Neuber's Operation. The antero-internal aspect of the tibia is removed—sequestrum cavity scraped—the integumentary tissues nailed to its floor—and relaxation sutures placed.

Comment.—Bone-chips may be used in the cavity—or the entire thickness of the soft parts, including periosteum, may be inverted into the bottom of the bone cavity from each side and held in place by a nail or peg (Fig. 157). Or the cavity may be packed throughout with gauze.

OSTEOPLASTY.

Description.—Transplantation of bone—in the form of bone-chips or decalcified bone-fragments—which are placed in the desired site and among which organization of the blood-clot takes place. The transplantation of a larger section of bone, entirely detached, has not yet been commonly done—though the success of reinserting the trephine-buttons suggests the practicability of such a course. This principle will be further mentioned under osteoplastic amputations.

Operation.—The site of operation having been rendered bloodless by a proximal constrictor, and having provided the bone-chips in advance (which come specially prepared by decalcification), the locality is exposed. If the chips are to be used within a bone cavity, such as a scraped medullary cavity, it is seen that this is thoroughly aseptic before their introduction. If they are to be used within a periosteal cavity (as after the partial resection of a bone), this periosteal cavity should be kept as nearly like the special form of the original bone as possible. In the case of the bone cavity, the bone-chips are dropped into the cavity and the soft parts sutured as just described in the above operation. In the case of a periosteal cavity, sutures

of gut are made to approximate the periosteal margins over the included bone-chips—and the muscles over the periosteum—and finally the skin, in the usual manner. The tourniquet is then removed and the blood allowed to flow into the part and fill the interstices between the bone-chips. The part is usually put up in an immobilizing splint.

Comment.—If the neighboring parts do not cover the site in which the bone-chips have been deposited, they may be covered by sterilized rubber tissue.

EXCISION.

Excision of the bones is described under the general head of Excisions, including both joints and bones (pages 397 to 457).

THE NEW YORK ACADEMY OF MEDICINE LIBRARY.

CHAPTER VI.

OPERATIONS UPON THE JOINTS.

ARTHROTOMY.

Description.—A simple incision into a joint.

Indications.—Exploration; removal of foreign body; evacuation of pus, or other fluid; irrigation; drainage.

Preparation.—As for a major operation of the same joint.

Position.—Determined by the special operation—and such as to render the site of incision prominent and convenient.

Special Instruments.—Scalpel; dissecting forceps; artery-clamp forceps; retractors; tourniquet (sometimes).

Operation.—The patient having been placed in a position to render the joint most accessible—and the overlying tissues in the best position with reference to the joint—an incision, of the simplest form and shortest extent compatible with the object in view, is made over that aspect of the joint which will lead into the interior of the joint-structures by the route which is shortest and safest, both in regard to the joint-structures and the tissues intervening between skin and joint. Having opened up the joint, the subsequent steps will depend upon the special object of the operation;—(a) Where exploration is the object; its interior is examined by some form of probe or sound, or, preferably, by the gloved finger-tip;—(b) Where the removal of a foreign body is sought; suitable forceps are introduced, with which it is grasped and withdrawn;—(c) Where drainage is indicated; a tube, or other drain, is inserted through the incision, with or without a counter-opening. In the first two cases, the wound is entirely closed. In all cases the joint is immobilized.

PUNCTURE OF JOINTS.

Description.—The exploration of the fluid contents of a joint by means of the needle of a suction-syringe—for the purpose of ascertaining the nature of those contents—or for the evacuation of the fluid found.

Indications.—Collection of pus, or other fluid, within a joint.

Preparation—Position.—As for arthrotomy.

Special Instruments.—Exploratory or aspirating syringe.

Operation.—The same preliminaries having been observed as in arthrotomy, the needle of the exploratory syringe is thrust, by the safest and shortest route, into the joint—the cylinder withdrawn and the contents aspirated. Following the withdrawal of the needle, the punctured wound is hermetically closed with sterilized collodion.

ERASION OR ARTHRECTOMY.

Description.—Etymologically, erasion signifies the scraping or curetting of a joint—and arthrectomy, the cutting out of a joint. Practically, both expressions are used synonymously—and are taken to signify the exposure of a joint with the removal of the diseased tissue alone. While arthrectomy

signifies, literally, the cutting out of a joint, it is not here used as the word excision commonly signifies. In excision, the articular ends of the bones are invariably removed—in erasion or arthrectomy, while a certain amount of bone may be incidentally removed (and always as much as is diseased is removed) in the gouging, only the articular cartilages and synovial membrane are supposed to be scraped or curetted. When bone is removed at all, the least possible is removed, and that is generally done with a gouge—and the whole operation conducted with as little injury as possible to the neighboring structures. In extreme cases all the articular cartilage is gouged away, all the synovial membrane is dissected out, and some of the bone is removed. An erasion or arthrectomy is, therefore, commonly understood as the application of scraping to the interior of a joint—the laying open of a joint and the removal of as many and as much of the tissues forming the joint as are diseased—synovial membrane, capsular ligaments, cartilage, and bone—the removal generally being accomplished by some form of gouge for cartilage and bone, and scissors and knife for soft parts. An arthrectomy, finally, may be regarded as a procedure the same in general purpose, though less

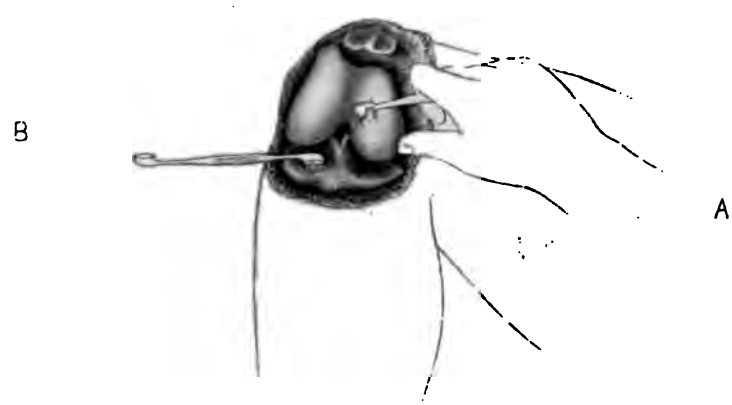

Fig. 158.—Erasion of the Knee-joint:—A, Removal of cartilage of condyle of femur with raspatory; B, Removal of cartilage of tibia with curette. The joint is exposed by a transversely curved incision and the patella turned backward.

severe in degree, as an excision—and is distinctly a conservative measure especially applicable to early cases. An arthrectomy is a part of every excision. Arthrectomy has its greatest application in joints of simple structure and easy approach—the knee being its most frequent site of application. A movable joint is always to be sought after erasion, even in the case of the knee (although in the latter case some surgeons prefer to secure ankylosis in preference to a probable weak joint). Arthrectomy is always preferable to excision in children, owing to its non-interference with the growth of bone.

Indications.—Disease of the articular structures, especially tubercular.

Preparation—Position.—As for excisions (page 397).

Special Instruments.—Besides those used for excisions, the following are specially required;—Gouges, curettes; spoons—of many sizes and shapes, dull and sharp. Flushing-gouges.

Operation.—No form of constrictor is ordinarily used—though may be used, as in excisions. The incision is generally the same as that for the

excision of the corresponding joint. Having exposed the interior of the joint, the following structures are closely examined, and, if necessary, removed —the guide being that all diseased tissue should be removed;—(a) Synovial membrane; where but slightly involved, is curetted,—where extensively, it is grasped with toothed forceps and dissected out, in as continuous a layer as possible, with scissors or scalpel. Every recess is sought and, if diseased, thoroughly curetted or removed. (b) Bursæ communicating with joint; are subjected to the same treatment as the synovial membrane—opened up and followed to their furthest extent. (c) Ligamentous tissue; to be scraped and cut away. (d) Articular cartilage; all involved or suspicious areas are gouged out with a sharp spoon. (e) Articular ends of bones; if actually diseased, or suspicious, to be removed with gouge. (f) Extra-synovial and extra-articular tissues; to be dissected out and removed, if involved. Finally, where much debris results, it is well to use a flushing-gouge and clean out the area of operation. Drainage is usually not necessary—but may be temporarily used where thought best. The capsular ligament, if not dissected away in removing disease, is closed by buried gut sutures. Muscles separated in reaching the joint are similarly brought together with buried gut sutures. The limb is put up upon an immobilizing splint. The after-treatment is practically the same as after excisions—and a more satisfactorily functioning joint is to be expected (Fig. 158).

EXCISION.

Excision of the joints is described under the general head of Excisions, including both bones and joints (pages 397 to 457).

THE NEW YORK ACADEMY OF MEDICINE
LIBRARY.

CHAPTER VII.

OPERATIONS UPON THE MUSCLES.

MYOTOMY.

Description.—Division of muscle—generally done as a preliminary to muscle-lengthening, or in the exposure of underlying parts, or in deformities.

Operation.—The muscle is fully exposed by an appropriate incision—or is exposed in the course of some operation. Having been isolated from neighboring structures, the muscle is cleanly divided with a scalpel, cutting transversely, or very slightly obliquely, to the direction of its fibers. A grooved director may first be passed beneath the muscle, but is rarely necessary. Myotomy should be done by the open method. Muscles are sometimes divided subcutaneously (as the sternomastoid, for torticollis), but this is even less advisable (owing to their greater size and less accurately defined contour) than the subcutaneous division of tendons.

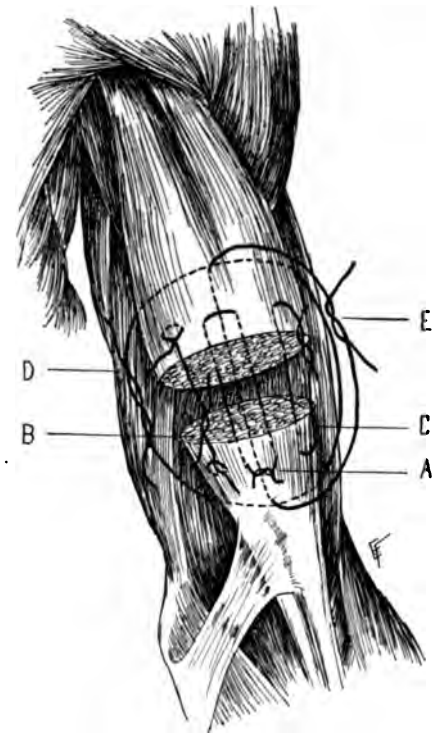

Fig. 159.—MYORRHAPHY:—The divided biceps is here shown sutured in several ways; A, Mattress suture; B, Lateral knotted suture; C, Peripheral suture; D, Lateral through-and-through suture; E, Antero-posterior through-and-through suture. The last two are here shown as relaxation—or reinforcing—sutures.

MYORRHAPHY.

Description. — Suturing of muscle which has been either purposely and cleanly divided (as in an operation)—or accidentally and unevenly divided or ruptured (as from injury or from excessive action).

Operation.—(a) Where muscle has been deliberately cut in the course of an operation, to expose underlying parts (as in dividing the sternomastoid in removing the cervical glands);—The muscle is here cleanly and evenly divided, preferably in a transverse or very slightly oblique direction. At the time of suturing, the parts are put into a position to relax the muscle as much as possible. While the two opposing ends of the muscle are carefully held in easy contact, as many muscle-sutures are inserted and tied as the

size and form of the muscle require. Chromic gut or kangaroo tendon is used for suturing—and the sutures are all buried. One of several forms of stitch may be applied. As the muscle-sutures are practically the same as tendon-sutures, and applied in the same manner, they will only be briefly mentioned here and their fuller description given under tendons. (1) Interrupted mattress sutures (Fig. 159, A). This is probably the best form of muscle-suturing. (The manner of its insertion is given at page 214.) (2) Interrupted sutures passing transversely through the upper and lower ends of the cut muscle (page 214). (3) Lateral knotted sutures (Fig. 159, B) (page 215). (4) Simple, peripheral longitudinal coaptation sutures (Fig. 159, C) (page 214). (5) Relaxation sutures for reinforcement;—In any of the above forms of primary or coaptation sutures, one or more relaxation sutures of heavy catgut may be applied passing transversely through the entire thickness of the muscle considerably above and below the primary sutures, and tied tightly enough to take the chief tension—and thus free the primary sutures from strain (Fig. 159, D, E). (b) Where the muscle has been accidentally and unevenly ruptured:—The ruptured muscle is exposed by the safest, most direct, and least damaging route—remembering that the ends of the muscles may have retracted far away from their normal position. If the ends of the muscle have been left very irregular, they are carefully trimmed, and are then sutured in one of the above manners. If they be torn almost transversely, they are approximated and sutured without trimming. If much muscle tissue have been lost, or be sacrificed in trimming, some process of lengthening may have to be resorted to before the ends can be made to meet without too great tension (see muscle-lengthening, page 208). In order that the skin-incision, used in reaching the part, may not lie over the muscle wound, bringing two cicatrices directly opposite, a curved incision may be used—or an oval flap of overlying parts may be raised. In completing the operation, the part should be so immobilized in the dressing as to relax the muscle as completely as possible.

MUSCLE-LENGTHENING.

Description.—In old cases in which muscle tissue has contracted considerably (as in long-standing cases of fractured patella or olecranon)—or in cases in which much muscle tissue has been lost in injury, or has been sacrificed in trimming muscles for suturing—it is impossible to approximate the separated ends without too great tension, unless the muscle be lengthened. Muscle-lengthening, therefore, is resorted to in two sets of cases,—those in which muscle must be lengthened to enable parts below, other than the muscle, to be approximated without too great tension (as in the case of the triceps or the common quadriceps extensor, in fractures of olecranon and patella),—and those in which lengthening is necessary after an old transverse rupture of a muscle in which the ends are separated too far to allow of approximation without too great tension (as in transverse rupture of the biceps muscle). In either category of cases the operation is the same.

Operation.—The patient having been placed so as to relax the part completely, the site of lengthening is exposed by a longitudinal incision of about 7.5 to 10 cm. (3 to 4 inches) in length, placed over the involved muscle. The incision should be sufficiently long to afford free access and manipulation and planned to reach the parts by the safest, most direct, and least damaging route. Retract the overlying soft parts and isolate the muscle. Divide the

muscle in a zig-zag line running transversely, and about 7.5 to 10 cm. (3 to 4 inches) above the ruptured part. This is a series of bluntly rounded serrations or V's—the incision passing upward about 5 cm. (2 inches) and downward the same distance, until the width and entire thickness of the muscle is traversed (Fig. 160, A). The muscle on either side of the zig-zag incision is now drawn apart until the apices of the V's touch. If the teeth or serrations are 5 cm. (2 inches) in length, when the suturing is done, nearly 5 cm. (2 inches) in length will be gained. The adjacent lateral margins of the two muscle-ends are now sutured by the knotted sutures described above (Fig. 161, E, E) (pages 214 and 215). A V from above is now sutured, by the same knotted suture, or other form of suture, to

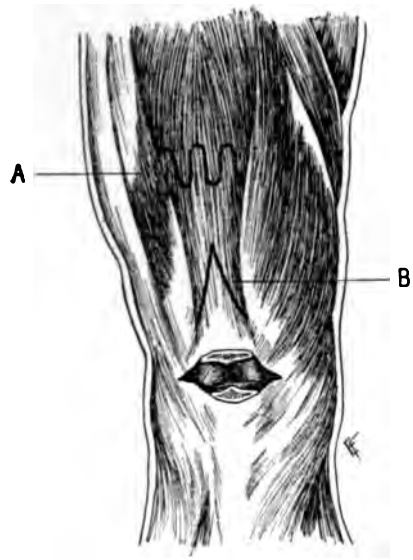

Fig. 160.—MUSCLE-LENGTHENING:—I—A, By means of a series of U-shaped incisions; B, by a single long V-shaped incision. (The manner of uniting these sections is shown in the following diagram.)

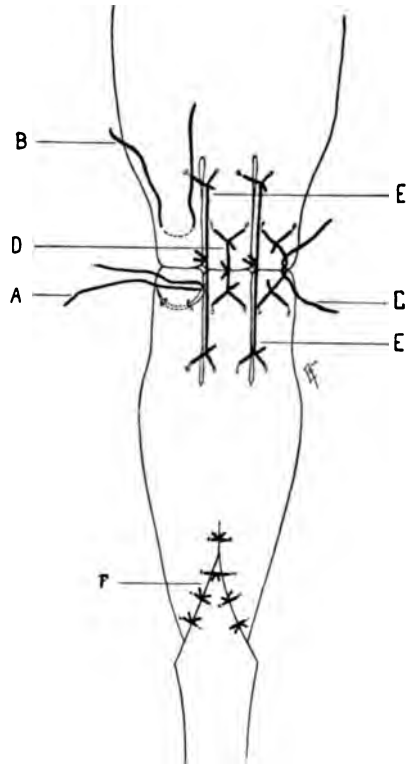

Fig. 161. — MUSCLE-LENGTHENING:— II — Manner of suturing the muscle-sections shown in the last illustration; A, Needle carrying one part of a lateral knotted suture through one of the tongues of the split muscle; B, Opposite part placed; C, Each half tied and the free ends being knotted; D, A completed lateral knotted suture; E, E, Lateral knotted sutures approximating the bases of the tongues and also serving as relaxation-sutures; F, Suture of the tongue-and-groove suture.

the Λ below, so that their blunted tips are held in contact by the sutures passed through above and below their tips (unless some such form of suture be used, as shown in Fig. 159, A, B, C, D). Theoretically, the apex of a V above will correspond with the base of a V below, but, practically, the apices are so disposed in the suturing as to bring them in contact. Sufficient length having been gained, the lower operation, for which the lengthening was primarily done, is now performed (an ununited fracture of patella or

olecranon, or ruptured biceps)—and unless this site has been exposed in the original incision, a separate incision is made for that purpose. Both wounds are then closed and the limb placed in a splint that will cause full relaxation of the parts during healing. Lengthening may also be accomplished by a long V-shaped incision, as in Fig. 160, B, which is then sutured as shown in Fig. 161, F.

CHAPTER VIII.

OPERATIONS UPON THE TENDONS AND TENDON-SHEATHS.

TENOTOMY.

Description.—Division of tendons.

Varieties.—Open Tenotomy, where the tendon is freely exposed before

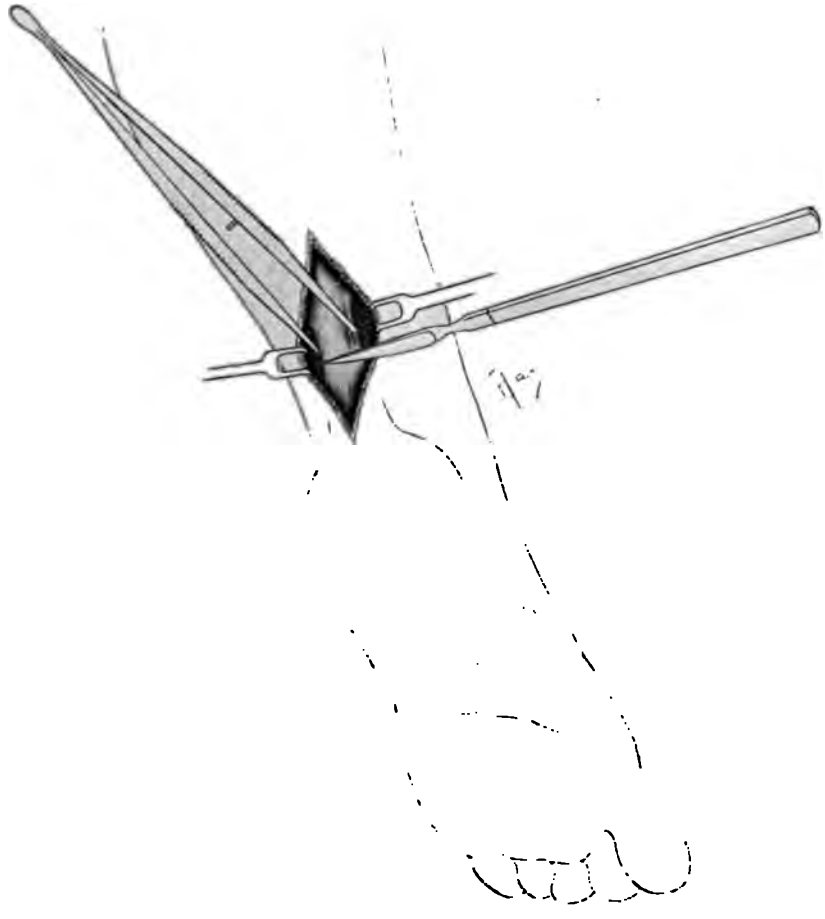

Fig. 102.—Open Tenotomy. Of the tendo Achillis.

being cut. Subcutaneous Tenotomy, where the division is made beneath the skin, by the sense of touch. Complete Tenotomy, where the entire thick-

ness of the tendon is divided. Partial Tenotomy, where a part only of the thickness of the tendon is divided, the remaining fibers being stretched.

Indications.—Shortening of tendons. To prevent action of muscles.

Special Instruments.—For open tenotomy;—scalpel; artery-clamps; dissecting forceps; retractors. For subcutaneous tenotomy;—tenotomes, straight, curved, sharp and blunt.

Open Tenotomy.—The tendon is here divided in an open wound. The incision for its exposure is generally made parallel with and directly over the tendon. The overlying soft parts are retracted—the tendon is exposed and isolated—and its sheath, if any, is opened. The tendon is then grasped with forceps and divided with a scalpel. The ends retract in both directions.

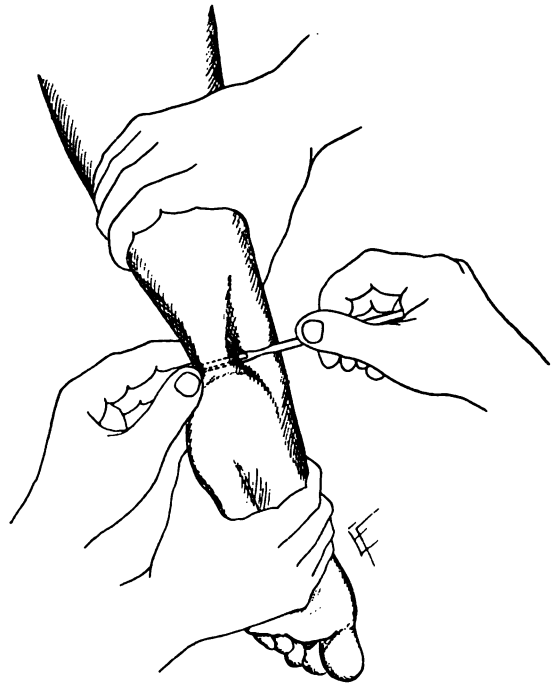

Fig. 163.—Subcutaneous Tenotomy:—Of the tendo Achillis.

The wound is entirely closed and the limb dressed upon a splint, or the part immobilized (Fig. 162).

Subcutaneous Tenotomy.—The tendon is here divided subcutaneously, through the smallest possible wound. Having put the tendon upon the stretch, to render prominent, an incision is made parallel with and just to one side of the tendon to be cut, and so placed as to do the least damage to other structures in the neighborhood. The incision is first made with a sharp tenotome, through skin and fascia down to the tendon—upon this as a guide the blunt tenotome is passed sidewise (the sharp one being withdrawn). The tenotome is then insinuated beneath the tendon, which it closely hugs throughout. Sometimes temporary relaxation of the tendon will aid the passage of the knife beneath it. The cutting-edge of the tenotome is then turned outward—the tendon put upon the stretch—the forefinger of the

left hand being placed over the site of section as a guard and guide—and the tendon cut by a short sawing movement, the last fibers being cut carefully as the tendon is felt to yield. The knife is finally withdrawn upon its side. The wound is sutured and the limb dressed upon a splint (Fig. 163).

Comment.—(1) In simple sections where the tendons are easily accessible and the neighboring parts are not important, subcutaneous tenotomy may be done. Where the opposite conditions exist, open tenotomy should always be practised. (2) In doing subcutaneous tenotomy, the tenotome is sometimes inserted between skin and tendon and the section made inward upon the tendon—which is more dangerous than cutting from beneath the tendon outward.

TENORRHAPHY.

Description.—Suturing of tendon. In recent cases the ends of the tendons can ordinarily be approximated without great difficulty. In old cases if the ends cannot be approximated and sutured after freshening them by

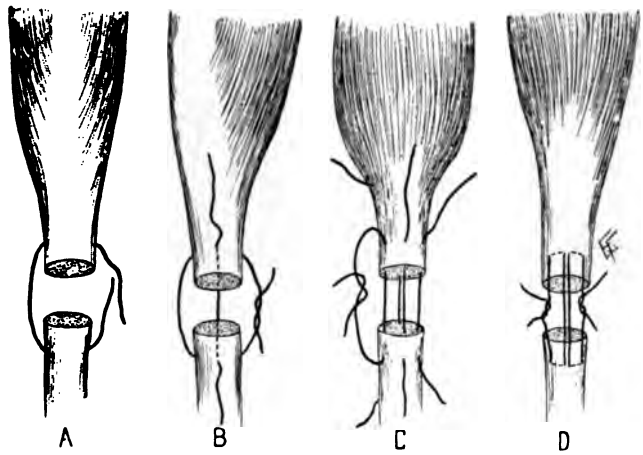

Figs. 164-167.—TENORRHAPHY:—A, Single suture through entire thickness of tendon; B, Two sutures entirely through tendon, in opposite directions; C, Peripheral sutures; D, Woelfler's quilt sutures.

trimming, some method of lengthening must be used—and if their union cannot be accomplished by lengthening, transplantation to adjacent tendons may be resorted to.

Varieties.—Primary, when the tenorrhaphy is done near the time of injury. Secondary, when done after healing.

Operation.—In recent cases an already existing wound may be present (except in such cases as subcutaneous rupture of a tendon)—and where a wound is present, this is simply enlarged and the tendon more fully exposed and the ends isolated. Where no wound exists at the time of the tenorrhaphy, the main tendon and its ends are exposed by an incision which reaches the site by the safest and simplest route. In primary tenorrhaphy the ends may require no trimming, especially in clean cuts,—or but slight trimming. In secondary tenorrhaphy, a transverse or oblique section of the tendon ends is always necessary, prior to suturing. In either case, the opposite ends of

the tendons are brought well into the wound and approximated. Chromic catgut and kangaroo tendon are the best materials for uniting the ends. Several methods of suturing are used—the chief of which will be here described: (**a**) Interrupted sutures passing transversely through upper and lower ends of divided tendon (Figs. 164 and 165, letters A, B);—A straight needle enters the proximal surface of the upper portion and passes transversely through its thickness, about 8 mm. or 1.3 cm. (from ⅓ to ½ inch) from the cut margin—emerges at same level upon distal surface—crosses the gap—enters the distal surface of the lower portion, from 8 mm. to 1.3 cm. (⅓ to ½ inch) from the cut end—passes transversely through—emerges at same level on proximal surface. The two ends of the suture are drawn upon until the tendon ends are approximated, and are then tied. When the tendon-ends have been cut obliquely, the sutures are so passed as to cross the line of division at a right angle (Fig. 173, B). (**b**) Interrupted mattress sutures;—A curved needle enters the proximal surface of the lower portion, about 8 mm. (⅓ inch) from its end—passes axially through two-thirds of the thickness

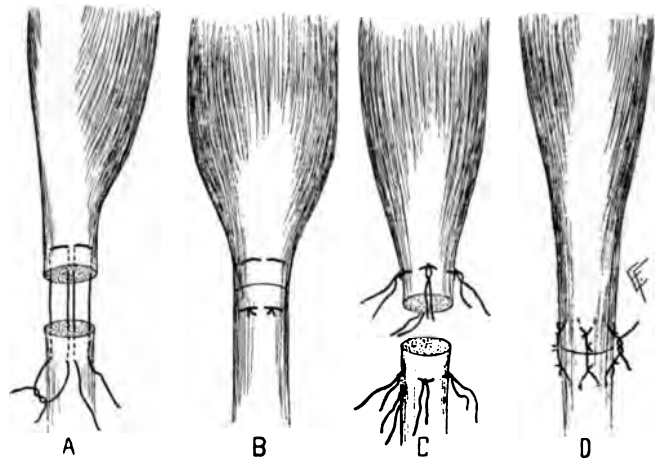

Figs. 168–171.—TENORRHAPHY:—A, Mattress sutures; B, Same, tied; C, Lateral; knotted sutures; D, Same, tied.

of the tendon—emerges on the cut margin—crosses the gap to the upper portion—enters the cut margin about two-thirds its thickness from the proximal surface—emerges about 8 mm. (⅓ inch) above the end—passes over the outer surface of the upper portion of the tendon for from 8 mm. to 1.3 cm. (⅓ to ½ inch)—again enters the upper portion on a level with the point at which it has just emerged from the upper portion—passes through about two-thirds its thickness—emerges on the cut margin—crosses the gap to the lower portion—enters its cut margin about two-thirds its thickness from the proximal surface—and emerges on the proximal surface on a level with the original entrance—when the two ends of the tendon are drawn upon until the cut surfaces come well into contact and are then tied (Figs. 168 and 169, A and B; and Fig. 167, D). (**c**) Peripheral longitudinal coaptation sutures;—A curved needle enters the lateral surface of the upper portion, about 8 mm. or 1.3 cm. (⅓ to ½ inch) from the cut edge—passes longitudinally through the tendon and emerges on the cut margin about 6 to 8 mm. (¼ to ⅓

inch) from the lateral surface—crosses the gap—enters the cut margin of the lower portion, from 6 to 8 mm. ($\frac{1}{4}$ to $\frac{1}{3}$ inch) from the lateral surface—passes longitudinally through the muscle and emerges on the lateral surface, about 8 mm. to 1.3 cm. ($\frac{1}{3}$ to $\frac{1}{2}$ inch) from the cut margin. The upper and lower ends of the sutures are now tied, approximating the tendons. These sutures are repeated at intervals of about 8 mm. to 1.3 cm. ($\frac{1}{3}$ to $\frac{1}{2}$ inch) around the entire circumference of the tendon (Fig. 166, C). (**d**) Lateral knotted sutures;—A curved needle enters the lateral surface of the upper portion about 8 mm. to 1.3 cm. ($\frac{1}{3}$ to $\frac{1}{2}$ inch) from the cut margin—passes transversely through the tendon tissue for about 8 mm. to 1.3 cm. ($\frac{1}{3}$ to $\frac{1}{2}$ inch) in width, and 8 mm. ($\frac{1}{3}$ inch) in depth—and emerges on the level of entrance. The two ends of the suture are now tied, care being taken to but slightly, if at all, pucker the tendon—and one end of the suture is then cut short The same kind of suture is applied immediately below, in the lower portion of the tendon, and one end of the suture similarly cut short. The two long ends of the sutures are then tied together, thus approximating the two ends of the tendon. As

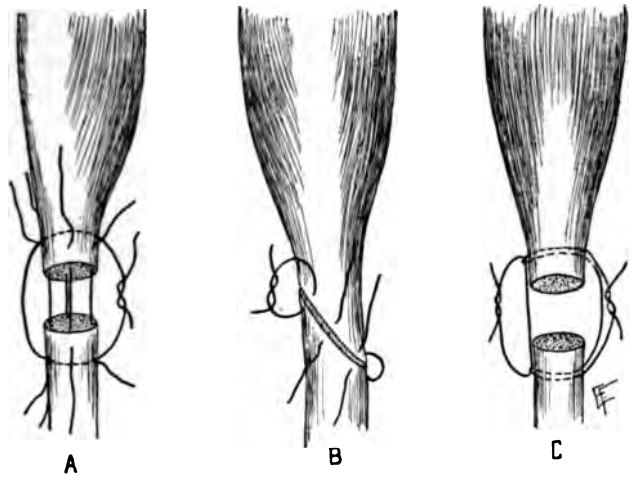

Figs. 172–174.—TENORRHAPHY:—A, Reinforcing or relaxation suture, applicable to any form of suturing (shown with first turn of knot); B, Suturing of obliquely divided ends; C, Reinforcing through-and-through suture by lateral suture through loops of first suture.

many of these pairs of sutures are introduced as necessary (Figs. 170 and 171, C and D). The extreme margins of the tendon-ends may be further sutured, between these sutures, by method **"c."** (**e**) Relaxation sutures;—In any of the above forms of primary or coaptation sutures, one or more relaxation sutures of heavy catgut may be applied, passing transversely through the entire thickness of the tendon considerably above and below the primary sutures—and tied tightly enough to take the chief tension, and thus free the primary sutures from strain (Fig. 172, A). (**f**) Combination of the interrupted mattress (method **"b"**), or lateral knotted sutures (method **"d"**), with relaxation sutures (method **"e"**). Of these various methods, either method **"a"** or **"b"** is probably most generally applicable—the former especially in smaller tendons and the latter in larger. Having united the tendon-ends, the wound is closed and the limb put up upon an immobilizing splint.

Comment.—(1) While a constrictor is not generally necessary, its use is ordinarily advisable. (2) Some surgeons prefer to expose the parts by a curved incision, beginning and ending over the tendon, above and below the rupture, but not over the rupture—so that there may be no possibility of adhesion between the tendon cicatrix and the skin cicatrix. (3) The ends of the tendons often form adhesions to their sheaths, and must be freed before they can be brought together. (4) All tendon-sheaths opened to expose tendons must be repaired with catgut. (5) The upper end of the divided tendon retracts further, and is harder to find, than the lower. The upper end retracts more because of the more active shortening of the proximal end of the muscle. It may be found, in hard cases, by "milking" the tendon-sheath downward—or by incising over the tendon higher up and tracing downward—or by incising the sheath in the lower part of the wound and tracing upward. The upper end of the tendon may sometimes be brought into view by extending the fingers or toes, the fibro-serous vincula pulling down the adjacent tendons. The lower end is generally not hard to be found—when hard, incise over the sheath lower down and trace upward—or pass a probe into its sheath from below and protrude it upward. (6) If the two ends cannot be found, one end must be transplanted into a neighboring tendon of the same group or function (see transplantation and grafting of tendons, pages 221 to 223). (7) The limb is put up so as to relax the tendon and muscle fully, and held so in a splint during union. After union has occurred, passive and active movements are begun early and persisted in—in order to prevent adhesion of tendon to sheath, and to get full range of movement. (8) It will be seen by comparing the illustrations of Neurorrhaphy (pages 144 to 146) that many of the methods used in uniting nerves are applicable to the union of tendons.

TENDON-LENGTHENING.

Description.—Tendon-lengthening, sometimes called tendoplasty, is applied to the lengthening of shortened tendons, or to the union of severed tendons, by processes of plastic elongation.

Varieties.—Tendon-lengthening may be required in two classes of cases; —(1) Where the tendon is intact but shortened;—(2) Where the tendon has been severed and the divided ends have retracted. As to the time of performing the operation, tendon-lengthening may be either primary (done near the time of injury), or secondary (when done after retraction and healing).

Operation.—Much that has been said under Tenorrhaphy, as to the exposure of the tendon, is equally applicable here—(see Operation, page 213, and Comment, page 216). Having exposed the shortened tendon, or the retracted tendon-ends, in the wound, one of several methods of lengthening may be applied—the chief of which will be here described:—(a) **Operations for lengthening shortened intact tendons**:—(1) By long oblique division of tendon, with gliding of beveled ends;—The obliquity of the division will determine the amount of lengthening—the ends being slid past each other far enough to still leave sufficient substance for union—and then the ends are sutured by several transverse sutures of chromic gut or kangaroo tendon. An oblique incision of 5 cm. (2 inches) will furnish a lengthening of from 2.5 to 4 cm. (1 to 1½ inches) (Fig. 176, B). (2) By central longitudinal splitting of tendon with transverse division of the split ends and their approximation, surface to surface;—Having split the shortened tendon

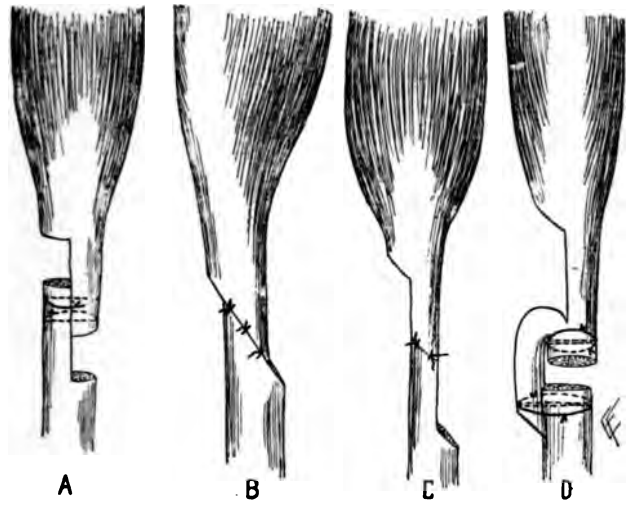

Figs. 175–178.—TENDON-LENGTHENING:—A, Splitting tendon transversely and longitudinally and suturing ends laterally; B, Splitting and suturing tendon obliquely; C, Splitting tendon obliquely and longitudinally and suturing split portions end-to-end; D, Splitting one end obliquely and longitudinally and suturing the split end laterally to opposite unsplit end.

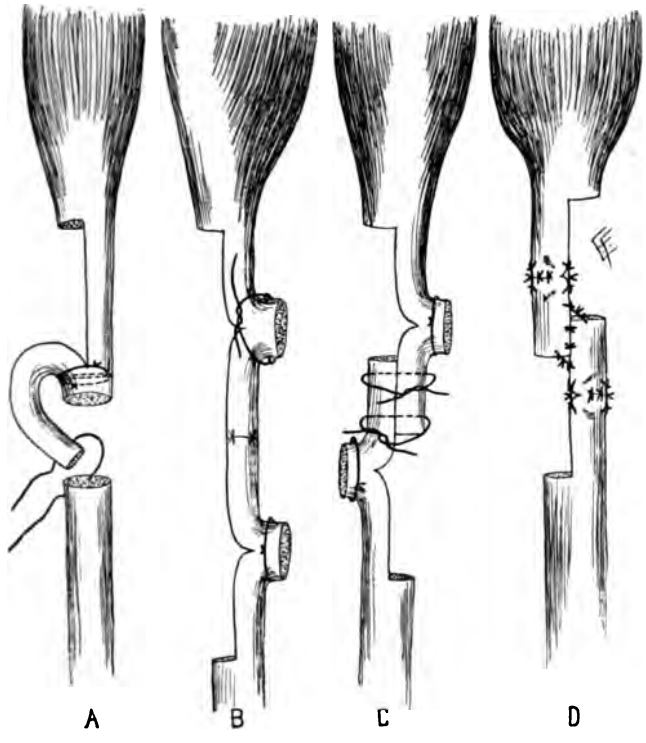

Figs. 179–182.—TENDON-LENGTHENING:—A, Splitting one end longitudinally and transversely, reinforcing where bent, and suturing split end into opposite unsplit end; B, Splitting both ends longitudinally and transversely, reinforcing where bent, and suturing split portions end to end; C, Same, with suturing of split portions laterally; D, Same as last, with different sutures (lateral knotted and ordinary).

down its center, as far as necessary to furnish the needed length, the ends of the split portion are divided transversely, or slightly obliquely, in opposite directions. They are then glided past each other and fastened laterally near their ends by two or more sutures passing through their combined thickness (Fig. 175, A). (3) By central longitudinal splitting of tendon with transverse division of the split ends and their approximation, end to end;—Somewhat similar to the method just described, except that the extreme ends of the split portions are sutured end-to-end, rather than surface-to-surface (Fig. 177, C). (4) By zig-zag incisions;—Incisions, transverse to the length of the tendon, are made on opposite sides of the tendon, passing half-way across, and not placed directly opposite each other. As many as are deemed necessary are thus placed, and the tendon lengthened by traction (Figs. 187 and 188, A, B). (b) **Operations for lengthening shortened severed tendons**:—(1) By partially splitting one end, twisting the split half

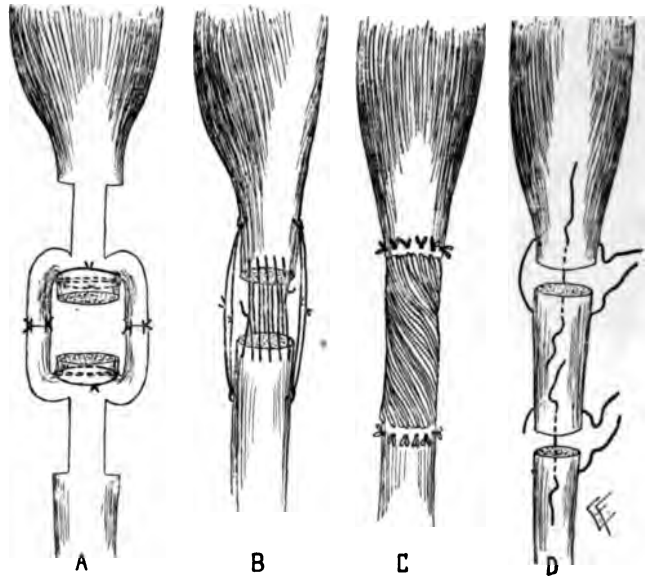

Figs. 183-186.—TENDON-LENGTHENING:—A, Double splitting of both ends, reinforcing where bent, and suturing split portions end-to-end; B, Bridging with gut, or reinforcing or relaxing with lateral knotted sutures; C, Bridging with twisted gut; D, Interpolation with another piece of tendon.

and suturing it to itself and to the end of the opposite end. Calculating the required amount of tendon needed, the upper end of the tendon is partially split, twisted upon itself and sutured to itself—and its free end sutured to the opposite lower end of the unsplit tendon (Fig. 178, D; and Fig. 179, A). (2) By partially splitting both ends, twisting the split portions and suturing them to themselves and to the end of the opposite end. This is the application to both ends of the principle applied in "1" to one end (Fig. 180, B). (3) By partially splitting both ends, twisting the split portions and suturing them to themselves and laterally to the opposite end (Fig. 181, C). (4) By distance suturing, or bridging, with catgut;—The ends are approximated by lateral knotted sutures, as far as possible, then a continuous catgut suture is run back and forth between the ends and between the lateral knotted

sutures, partially filling in the gap by catgut strands, upon which lymph and blood are poured, and, together with the catgut, organized (Figs. 184 and 185, B and C; and Fig. 189, C). Following the union of the tendon-ends, the tendon-sheath, if it have been incised or otherwise injured, is repaired with catgut sutures, as far as possible. In exposing the tendon, the sheath should not have been needlessly freed, for the vessels of the tendon reach it through the sheath. The overlying muscles are brought together with buried catgut sutures. The skin-wound is then closed—and the limb immobilized upon a splint, which will insure relaxation of the part. Passive and active motion should be begun as soon as sound healing has occurred.

Comment.—Many of the methods of nerve-lengthening are equally applicable to tendon-lengthening (pages 147 to 149). Not only may tendon-lengthening be accomplished by processes of plastic elongation in the

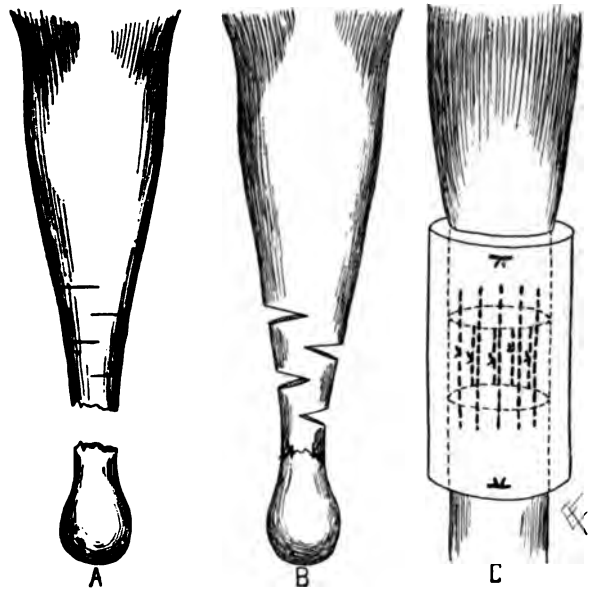

Figs. 187–189.—TENDON-LENGTHENING:—A, Poncet's accordion method (in case of tendo Achillis) —incisions partly across tendon; B, Same, showing amount of lengthening by traction upon tendon; C, Bridging with gut, reinforced with decalcified bone-cylinder.

sense of bringing into position undetached portions of tendon—but elongation may be also accomplished by the interposition of tendon substance, in those cases where the gap is too long to be bridged by other means, as in the similar operation for nerve-lengthening. The two most ordinary ways are the following;—(**a**) A piece of tendon of the required length and as nearly the desired size as possible, taken from a human being just operated upon, or from a lower animal, is inserted into the interval between the severed ends, which have been freshened, and is sutured to both ends of the main tendon by longitudinal peripheral sutures, or other method (Fig. 186, D). (**b**) Half the thickness, and as much of the length as required, of part of the same or of one of the neighboring tendons of the patient is taken, and sutured, as

above, into the gap. The wound is treated as after other forms of tendon-lengthening. The interpolated tendon probably disappears, as such, after serving as a framework.

TENDON-SHORTENING.

Description.—The shortening of a tendon for the purpose of increasing the action of a muscle which has become impaired by the elongation of its tendon,—or for the purpose of improving a deformity (as the shortening of the tendo Achillis for talipes calcaneus).

Operation.—Having exposed the involved tendon, its shortening may be accomplished in one of several ways;—(1) By excision of a piece of the tendon, with the union of the resulting ends by one of the methods of tenorrhaphy. (2) By oblique division of the tendon, followed by gliding of the ends in such a way as to lessen the length of the tendon, and the suturing of the ends as

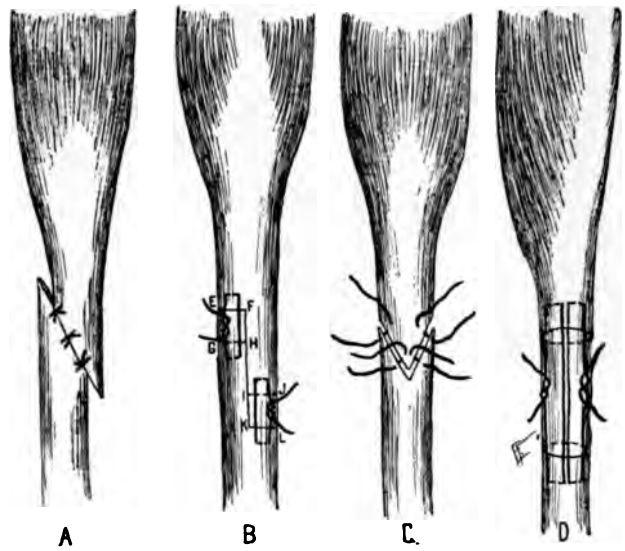

Figs. 190–193.—TENDON-SHORTENING:—A, Portion of tendon excised obliquely and severed portions sutured end-to-end, in direct contact or overlapping (reverse of Fig. 176, B); B, Z-shaped incision is made, followed by excision of E F G H and I J K L, after which E F is sutured to K L: C, Following excision, ends of tendon are sutured in form of mortise; D, Excision of portion of tendon by transverse incision, followed by mattress-suturing of opposite ends (portion between circular transverse incisions is here excised).

in Fig. 190, A. (3) By division and shortening of the tendon, followed by the beveling of one end into a wedge, and the splitting of the other end—and the suturing of the wedge into the split portion, thus using up the excess of length (Fig. 192, C). (4) By the figure of Z method (Fig. 191, B);—make a vertical incision down the center of the tendon from F to K, and transverse ones along E F and K L. Having drawn the cut portions apart, shorten each piece by removing the ends at G H and I J. E F and G H are then sutured together, and I J and K L—as well as the vertical line of division. The wound, following the operations for tendon-shortening, is closed and treated as after tendon-lengthening. Another form of tendon-shortening is shown in Fig. 193, D, where a portion of tendon is removed.

TENDON-GRAFTING.

Description.—Tendon-grafting, tendon-transplantation, or tendon-implantation, as the operation is variously termed, is the attachment of the distal end of a divided tendon into a neighboring sound tendon of the same general group or function. The attachment is sometimes made laterally, without the division of the involved tendon

Indications.—(1) Those cases in which so much of the tendon has been destroyed that its reconstruction is impossible—and the damaged tendon

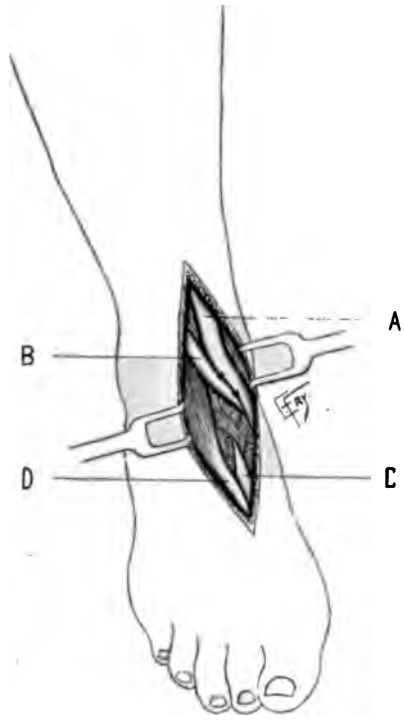

Fig. 194.—TENDON-GRAFTING:—Of sound extensor of great toe into impaired anterior tibial; A, Tendon of tibialis anticus; B, Proximal end of extensor proprius hallucis, which has been severed from lower end, C, and engrafted upon anterior tibial tendon; D, Innermost tendon of extensor brevis digitorum.

is therefore grafted to a neighboring tendon (for instance, should one of the four tendons of the flexor sublimis or profundus digitorum be too extensively damaged for union of the proximal and distal ends, its distal end may be attached to one of the neighboring sound tendons of the same muscle). (2) Those cases in which a group of muscles, or a single muscle, has been paralyzed—and one or more of the tendons of the paralyzed group is therefore grafted to a tendon of an unparalyzed group (for instance, if the tibialis anticus were paralyzed and the extensor proprius hallucis intact, the tendon of the tibialis anticus may be grafted upon the latter) (Fig. 194). Where the tendon of the muscle from which the power is to be derived is of comparatively

little importance functionally, and the paralyzed muscle is of more importance, the entire sound tendon may be diverted into the paralyzed muscle (Figs. 195–198). But where the tendon of the muscle which is to supply the power is more important than the paralyzed tendon, then but a portion of the sound tendon should be diverted into the paralyzed one (Figs. 199–203).

Figs. 195-198.—TENDON-GRAFTING:—I—Where the tendon of the muscle supplying the power is of comparatively little importance (shown on the right, in light), the entire sound tendon is grafted upon the impaired tendon (shown on the left, in dark). (Modified from Vulpius.)

Figs. 199-203.—TENDON-GRAFTING:—II—Where the tendon of the muscle supplying the power is of greater importance (shown on the right, in light), only a portion of the sound tendon is grafted upon the impaired tendon (shown on the left, in dark). (Modified from Vulpius.)

Operation.—Having exposed the field of operation by an incision harming the adjacent structures as little as possible, and having isolated the involved and the sound tendons, the technic of grafting may be accomplished in one of several ways—the chief of which will be here mentioned;—**(a) Tendon-grafting by lateral attachment:**—In the case of a divided tendon, the distal end is freshened by an oblique paring (Fig. 204, A). In the case of a

paralyzed (undivided) tendon, it is divided obliquely (also A, Fig. 204). That portion of the sound tendon to which the involved tendon is to be attached is freshened upon its lateral aspect—to which the obliquely divided distal end of the injured, or paralyzed, tendon is now sutured with gut by peripheral coaptation sutures, or other form of suturing. Sometimes the paralyzed tendon is not divided, but its lateral aspect freshened, just as in the case of the sound tendon—these aspects being then brought together and sutured (Fig. 205, B). Especially would this be indicated where it is possible for the function of the paralyzed muscle eventually to regain its functioning. (b) **Tendon - grafting by implantation:** — The sound tendon is split entirely through its center, over an area sufficiently long to accommodate the tendon to be grafted. Freshen the distal end of the involved tendon (injured or paralyzed) by paring both sides in a beveling or wedge-shaped fashion. The wedge-shaped piece of tendon is then inserted between the lips of the split tendon and held in place by two or more gut sutures passed transversely through both tendons (Fig. 206, C). The wound is finally closed in the usual way—and the limb put up upon a splint in such a position as to secure relaxation of the parts.

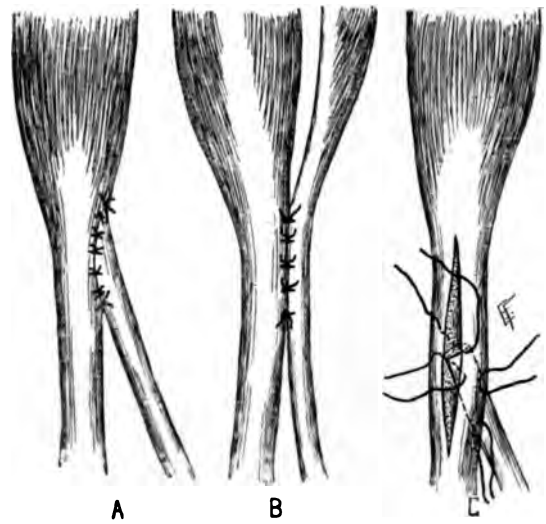

Figs. 204-206.—TENDON-GRAFTING:—A, Grafting end of divided tendon into lateral aspect of undivided tendon; B, Grafting undivided tendons laterally; C, Implantation of beveled end of tendon between the split portions of sound tendon.

REPAIR OF RUPTURED OR DIVIDED TENDON-SHEATHS.

Description.—A tendon-sheath may be accidentally ruptured by violent action or injury, as in the case of the long head of the biceps, or may be purposely divided in an operation temporarily to expose the tendon within, or the underlying parts beyond (as the division of the sheath of the tendo Achillis for tenorrhaphy, or the division of the common sheath of the peroneus longus and brevis tendons temporarily to retract the contained tendons in the excision of the ankle-joint).

Operation.—When the object is to expose the tendon and sheath alone, a slightly curved incision is made, coming over the sheath above and below but somewhat to one side at the site of rupture (so that the cicatrices of skin and sheath will not fall directly over each other). Or a straight incision may be made directly over the tendon-sheath. When the sheath is divided in the course of some other operation, the position of the incision will have been determined by the special operation. The part is then put into that

position which will relax the tendon to the greatest extent—the tendon and sheath are then clearly located, and the former placed within the latter, while the edges of the sheath are held aside. The sheath is then carefully dropped together over the tendon and the sheath-margins sutured with a fine continuous gut suture. The wound is now closed and the limb put up so as completely to relax the tendon. In about ten days the limb is taken out of the splint at intervals and passively moved, to prevent adhesion of tendon to sheath—while the surgeon's left thumb placed over the tendon during manipulation holds it in place within the sheath and relieves part of the strain upon the recently sutured sheath.

Comment.—In cases of paralysis, the peroneus longus has been grafted into the tendo Achillis, into the tibialis posticus, and even into the tibialis anticus;—the tibialis anticus into the extensor proprius hallucis;—the sartorius into the rectus femoris, and the like. Tendons are sometimes approximated by tunneling under other structures.

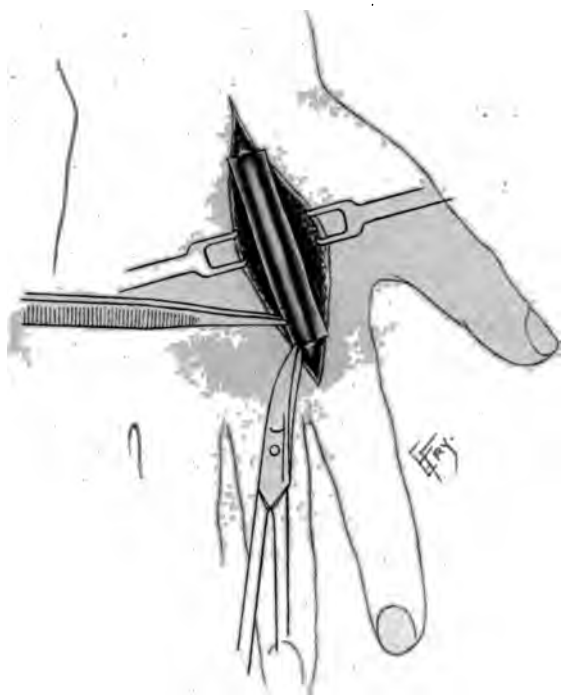

Fig. 207.—Excision of Tendon-sheath:—Sheath is seized with forceps and divided circularly around the tendon at both ends of the involved area.

EXCISION OF TENDON-SHEATHS.

Description.—The removal of more or less of the sheath of a tendon. Generally resorted to in cases of obstinate tenosynovitis.

Operation.—The special tendon-sheath involved is exposed by an incision directly over it,—or by an incision beginning and ending over the sheath but passing to one side of the sheath throughout the rest of its course, thus en-

abling a skin-flap to be turned to one side, so that when replaced its scar will not fall directly over the tendon. Having retracted the soft parts, the tendon-sheath is entirely isolated, with care, from the neighboring structures—especially from those forming its bed. The sheath of the tendon is now divided circularly around the tendon, above and below the diseased portion—but without cutting the tendon itself. Having completed the two circular incisions at either end, the sheath is split in the long axis of the tendon—and thus laid completely open—and may be removed in one piece (Fig. 207). Any diseased portions of the contained tendon found, should be scraped. The skin-flap is then united—and the limb put up so as to immobilize the tendon.

CHAPTER IX.

OPERATIONS UPON THE LIGAMENTS.

SYNDESMOTOMY.

Description.—Division of ligaments. Generally performed for the contraction of ligaments occurring as the cause, in whole or in part, of some of the deformities.

Operations.—The ligament, or ligaments, at fault may be divided by the subcutaneous or open method—the latter being preferable. In the open method the involved ligaments are exposed by the simplest and safest route —and divided in the same general manner as the division of tendons by the open method—and the wound similarly treated.

SUTURING OF LIGAMENTS.

The suturing of ligaments is performed upon the same general principles as is tendon-suturing (see page 213).

LENGTHENING OF LIGAMENTS.

Description.—Lengthening of ligaments which have become shortened through disease or injury—especially in cases of deformity.

Operation.—Many of the same methods involved in tendon-lengthening are applicable to the lengthening of ligaments. Where a ligament is attached to a bony prominence, this has been chiseled off and displaced to a neighboring site and there nailed (as in the case of the ligamentum patellæ, where the tubercle of the tibia has been displaced to the upper portion of the tibia —but with uncertain success). (See Tendon-lengthening, page 216.)

SHORTENING OF LIGAMENTS.

Description.—Shortening of ligaments which may have become lengthened through disease or injury.

Operation.—Many of the tendon-shortening methods may also be applied to elongated ligaments. As in the above operation, where a ligament is attached to a prominence of bone, this may be chiseled from its normal site and nailed to an adjacent site (as in the case of the ligamentum patellæ, where the tibial tubercle has been displaced lower down the tibia).

Note.—Most of the work done upon Ligaments will be found described in special writings upon orthopedic surgery. (Also see Tendon-shortening, page 220.)

THE NEW YORK ACADEMY OF MEDICINE LIBRARY.

CHAPTER X.

OPERATIONS UPON THE FASCIA.

FASCIOTOMY.

Description.—Fasciotomy or aponeurotomy signifies the division of bands or planes of contracted fascia. The term is used with especial reference to operations upon contracted palmar and plantar fascia, in the deformities of those parts—and in connection with the contracted fascia lata, and the contracted fascia following burns, and the like.

Operation.—The division is usually accomplished by the subcutaneous or open method. The general principles of the operations will be here described—the steps of the special operation will be determined by the anatomy and contraction of the part involved. (a) **Fasciotomy by the Subcutaneous Method**:—Where the contracted fascia is in the form of narrow bands, a sharp-pointed tenotome with a narrow cutting-edge (of about 6 mm., or ¼ inch) is best. Where the fascia is contracted in the form of planes, a sharp-pointed tenotome with a longer cutting-edge is to be preferred. The short-bladed fasciatome, however, is the safer form of tenotome, as far as damaging the neighboring structures is concerned. The instrument is inserted flatwise beneath the fascia—the cutting-edge is then turned toward the contracted fascia, which is rendered further prominent by extending the part, and the special band of fascia is divided against which the knife-edge presses—then another band is sought—new bands appearing to spring into existence as others are cut—the tenotome being carefully pushed in different directions until all the bands are cut. Just before each band is cut, the tip of the surgeon's left forefinger should be placed over the tense band of fascia and make counter-pressure, and thereby serve as a guide of the progress of the knife toward the skin. Sometimes all the bands can be divided through one introduction of the tenotome—in other cases the tenotome is introduced at several sites. The tenotome is sometimes introduced between the skin and the fascia and divides the latter by cutting downward, which is somewhat more risky. When all or nearly all of the ligaments have been divided which the tenotome can detect and reach, the part is fully extended, breaking down the remaining ones if any. The tenotome wound or wounds are then closed by a suture or two and the limb immobilized in a splint, which is worn for a long period. (b) **Fasciotomy by the Open Method**:—A number of limited incisions may be made from without inward, through the skin and fascial bands,—or the involved fascial bands may be exposed through a skin-flap which is raised and retracted to one side, or through a long straight incision whose margins are retracted laterally. Following the thorough exposure of the parts, in the last method, the contracted fascia is dissected out wherever present. In either one of the open methods, the part is fully extended after the operation, the skin-wound closed and the part immobilized.

Note.—Much of the work done upon the Fascia will be found described in special writings upon orthopedic surgery.

CHAPTER XI.

OPERATIONS UPON THE BURSAE.

PUNCTURE OF BURSAE.

Description.—Generally resorted to for exploring the nature of the bursal contents, or for injecting fluid for destroying its secreting surface, or simply for the evacuation of its contents.

Operation.—The needle of the syringe is introduced, with the usual precautions, into the interior of the enlarged bursa—piercing the skin as directly over the cyst as possible and passing by the safest route through, cr preferably between, the overlying tissues. The site of the introduction will depend upon the special bursa.

INCISION OF BURSAE.

Description.—Usually resorted to for the evacuation of pus, or other fluid; or to expose the interior for curettage.

Operation.—An incision is made down to the bursal sac—selecting a site where the least important structures will be encountered and the sac most readily reached. The intervening parts having been retracted to one or both sides and the bursa steadied by the surgeon's left forefinger and thumb, its wall is incised with a scalpel—after which the special object of the operation is accomplished. The steps of the operation will depend upon the special bursa. In some cases the incision will pass from the skin directly into the bursal cavity, without any intervening dissection.

EXCISION OF BURSAE.

Description.—Generally done for the removal of chronically inflamed or diseased bursæ—the majority of the latter cases being tubercular.

Operation.—The exposure of the enlarged bursa is accomplished as described under the operation for incision. The surrounding parts having been then drawn well aside, the entire bursal sac is dissected from its bed, partly by blunt and partly by sharp dissection—carefully guarding the neighboring structures, and especially those joints with which the bursa may communicate. Whenever possible, the communication with a joint should be closed by suturing together the edges of the neck of the excised bursa. The wound is then closed, or drained, as indicated.

LIBRARY.

CHAPTER XII.

AMPUTATIONS.

GENERAL CONSIDERATIONS.

Definition.—Amputation—the removal of a limb through its continuity. Disarticulation—the removal of a limb at a joint.

Indications.—Any injury, disease, or malformation rendering retention of the limb incompatible with life or comfort;—avulsion of limb; compound fracture; compound dislocation; fracture with great comminution of bone; laceration of important vessels; extensive contusion; extensive laceration; gunshot injuries; aneurism; effects of heat and cold; gangrene; extensive bone disease; tumors; elephantiasis; tetanus; snake-bite; deformities. Amputations are far less frequent in modern conservative surgery than formerly—limbs now being often saved by excision, and other operations, which were at one time sacrificed.

Preparation of Patient.—The constitutional preparation of the patient—and the previous and immediate local antiseptic preparation of the part—are the same as for any major operation. The part should be shaved, where its condition admits of this preparation—and should come to the table with the preliminary dressing in position.

Position of Patient, Surgeon, and Assistant.—(1) **Patient** rests upon back, lying near side of table, and nearer the upper end for amputations of the upper extremity, that the limb may be held out from the table at a right angle;—and nearer the lower end for amputations of the lower extremity, that the limb may be held both out from the table, and also over the end of the table. (2) **Surgeon** so places himself as to enable him to grasp with his left hand the patient's limb between the saw-line and the trunk—which will place him upon the outer side of the right limbs, and on the inner side of the left limbs (between the table and the left limbs) (Fig. 208). This is the general rule, of almost universal application (and will not be repeated with each operation)—where exceptions occur they will be mentioned with the special amputations. In amputations of the upper part of the left arm and upper part of the left thigh, especially the latter, it may be more convenient to stand to the outer side of the limb, in which case the left hand grasps the limb below the saw-line. This avoids wedging one's self between the table and the upper part of the limb, which, in the case of the lower limb particularly, cannot be stretched out at a right angle from the table. (3) **Assistant**:—grasps the part of the limb, wrapped in an aseptic towel, that is to be removed, standing facing the surgeon, so that he can better steady the limb against the movements of the saw than if he stood at the end of the limb—his arms being thus parallel rather than at a right angle to the working of the saw.

Instruments.—Esmarch's rubber bandage and tourniquet; amputating knives, long and short; scalpels, various; cartilage knives; Catlin knives; saws, ordinary amputating, bow, and butcher; small thin saw, for spiculæ of bones; periosteal elevators; metallic retractors (for flaps); linen retractors

(for flaps); broad metallic or ivory spatulæ and retractors to hold soft parts out of way; dissecting and toothed forceps; artery-clamp forceps, numerous; rongeur forceps; scissors, straight and curved, sharp and blunt; tenacula; probes; grooved directors; ligatures and sutures, silk, catgut, plain, chromic and silkworm-gut; tendon; needles, straight and curved; needle-holder;

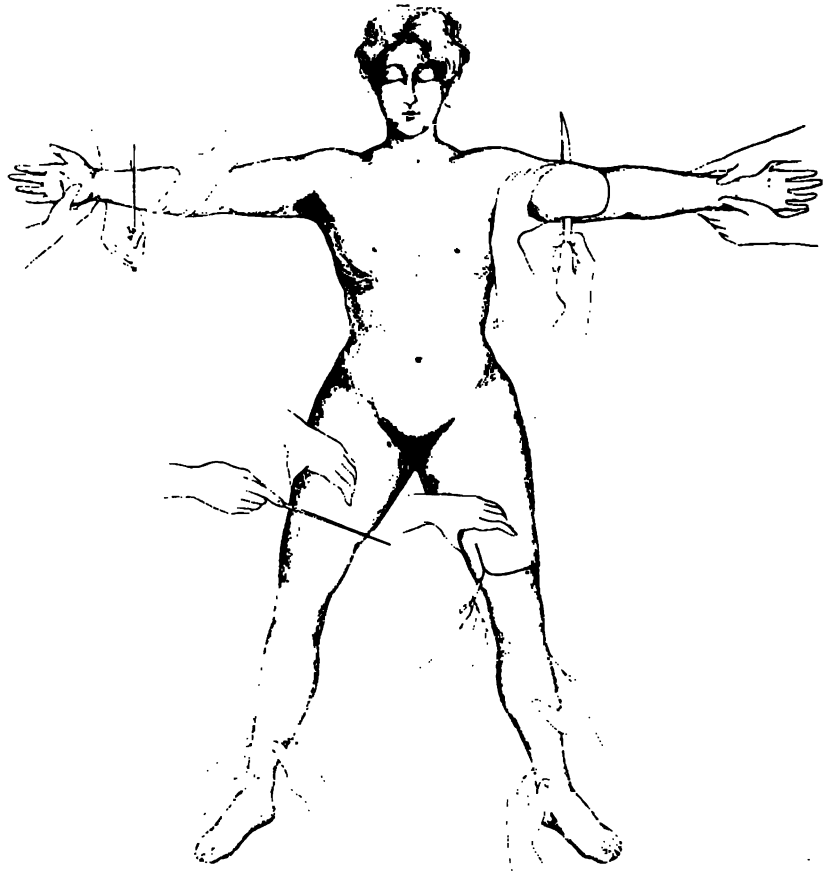

Fig. 208.—Illustrating Position of Surgeon in Amputating:—Standing to outer side of right, and to inner side of left limb; manipulating knife with right hand, and steadying limb; also retracting soft parts with left hand placed between saw-line and trunk.—Hands of assistant are shown in various positions grasping and supporting part to come away.

drainage tubes; irrigator and irrigation fluid; normal salt solution and instruments for intravenous infusion; dressings for stump; splint. Special instruments will be mentioned under special amputations.

Control of Hemorrhage in Amputations.—Hemorrhage may be controlled in one of two general ways: by some form of tourniquet or constrictor, or by digital compression. (A) **Control of hemorrhage by tourniquet or constrictor:** Several forms of tourniquet control are in use;—(1) Esmarch's Broad Rubber Bandage, and Tourniquet of Rubber Tubing or Narrow Band; These constrictors may be used in two ways;—(a) Use of

Bandage and Tourniquet (Esmarch Method);—The bandage is applied from the fingers or toes upward, for example, nearly to the shoulder or hip —the tourniquet is then applied above the bandage—and the bandage removed. This saving to the patient of the blood in the limb is more particularly indicated when the limb is healthy and the patient anemic—otherwise a patient who loses a limb can also generally afford to lose its proportional amount

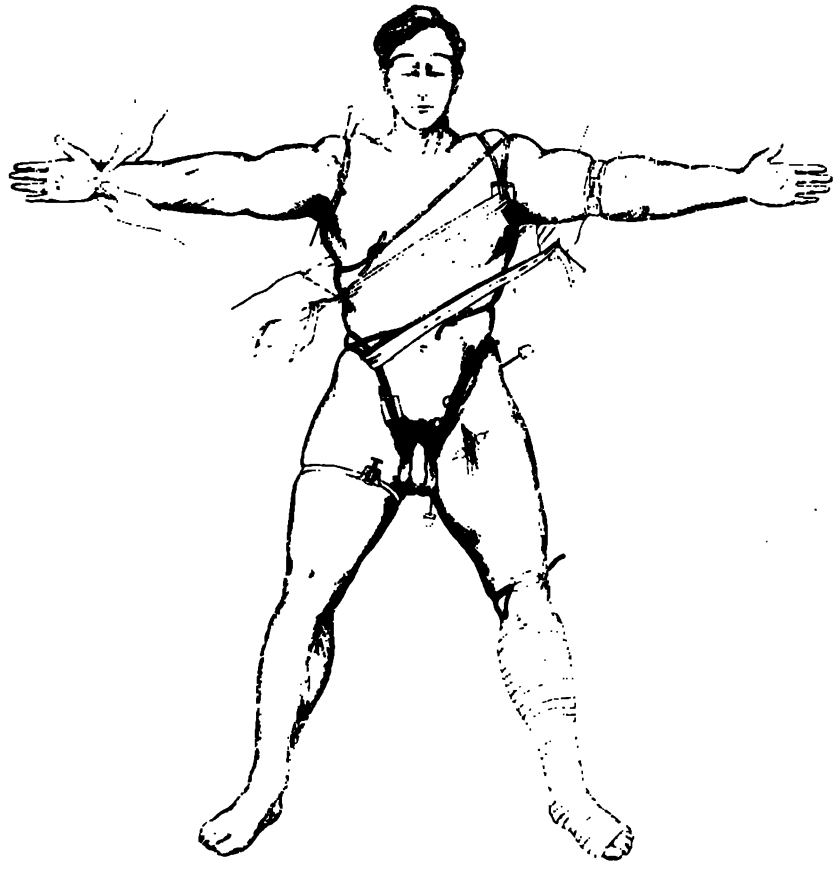

Fig. 209. Illustrating Methods of Hemorrhage Control.—Wyeth's method by rubber tourniquet and needles, at right shoulder-joint.—Same at left hip-joint.—Ordinary rubber tourniquet and pad at left shoulder joint, reinforced (kept from slipping) by strips of roller-bandage. Same, at right hip-joint.—Use of Esmarch rubber tourniquet above left elbow. Exsanguination of limb by Esmarch rubber bandage, followed by application of rubber tubing (or Esmarch rubber tourniquet) above left knee.—Compression of right femoral by Petit type of tourniquet.—Preliminary ligation of left femoral.—Digital compression of main arteries at right wrist.

of blood (Fig. 209, left leg). (**b**) Use of Esmarch's Tourniquet Alone; The limb is held elevated for about three minutes (this empties the veins mechanically and causes the arteries to contract reflexly, thus lessening the blood to the limb; but if the elevation be too long, the arteries recover, dilate, and let in more blood) - and, during the time of this elevation, a healthy limb may be massaged downward to aid exsanguination - the tourniquet alone is then

applied as high up the limb as indicated for the special operation, no form of bandage having been previously applied (Fig. 209, left arm). In operating anywhere below the elbow or knee, the constriction should be applied just above the elbow or knee,—and in amputating anywhere above the elbow or knee, the constriction should be applied as near the trunk as possible. This is the general method of hemorrhage control in the majority of cases. The objections which have been urged against the Esmarch bandage and tourniquet, or tourniquet alone, are—the increased bleeding following the operation, from temporary vasomotor paralysis; the possible lowered vitality of the compressed parts; occasional temporary paralysis of nerve-trunks from pressure; and the possibility of forcing pathological products into the body. The great advantage over these disadvantages, however, is that it controls all bleeding—and its use, therefore, is advisable in spite of the disadvantages. (2) Tourniquet of the Petit Type;—The entire limb is compressed, with special pressure over the main artery (Fig. 209, right thigh). (3) Tourniquet of the Signorini Type;—No circular constriction is used—a pad on one arm of the tourniquet compresses the artery against a counter-pad on the other arm of the tourniquet opposite or beneath the limb or body. **(B) Digital compression of the main artery**:—Compression is generally made through the skin—but may be made directly upon the main vessel through an incision made immediately over it (Fig. 209, right hand). The office of hemorrhage-control by digital compression is sometimes delegated to a single individual in a hospital. **Note**:—Special methods of controlling the circulation will be mentioned in connection with special amputations, especially those about the shoulder- and hip-joints (Fig. 209, shoulders and hips).

THE GENERAL TECHNIC IN AMPUTATING.

LOCATION OF LINE OF BONE-SECTION, OR DISARTICULATION.

The determination of the saw-line in an amputation, or the disarticulation-line in a disarticulation, is the first step—generally marking the upper limit of the operation—and is the necessary guide to the subsequent steps.

Level at Which the Bone, or Bones, are to be Sawed.—Is to be determined by the individual case—and its position should be such that enough healthy tissue will be provided for, between the saw-line and the upper limit of the diseased or injured tissues to be removed, to furnish ample covering of soft parts to protect the stump without undue tension.

Level of Joint-line at which Disarticulation is to be Done.—The position of the articulation-line is, of course, fixed—it is only necessary to recognize it anatomically—and to determine whether sufficient sound tissue intervenes between joint-line and upper limit of the parts to be removed to afford covering satisfactory in quantity and quality to protect the stump. Otherwise the disarticulation will have to be converted into an amputation at a higher level.

Relation of Saw-line to Length of Flap, and Vice Versa.—While the position of the saw-line determines the amount of tissue (and, consequently, length of flap or flaps or of circular covering) which will be required to cover the sawed bone—so also does the choice of the method of amputation to be used largely determine the amount of bone to be sacrificed (and, consequently, the length of the resulting limb)—for (**a**), In circular amputations and amputations by equal flaps, the minimum amount of bone is sacrificed; and (**b**), In amputations by a single flap, the maximum amount of bone is sacrificed.

LOCATION OF LIMITS OF SKIN INCISIONS.

A total covering of soft parts equivalent to 1½ diameters of the limb at the saw-line is the general rule of allowance. It is necessary, therefore, to determine the lower limit of the skin incision, as this forms the lower limit of the total covering. This limit may be determined accurately or approximately.

In Circular Amputations.—(a) Accurately;—Find the circumference of the limb at the saw-line by means of a metallic tape-line (say, 15 cm., or 6 inches)—one-third of the circumference will give the diameter (say, 5 cm., or 2 inches). Therefore, to furnish 1½ diameters (say, 7.5 cm., or 3 inches) the lower limit of the skin incision would have to be 3.8 cm., or 1½ inches, below the saw-line. (b) Approximately;—Place the thumb at the saw-line on the anterior aspect of the limb (the nail facing the junction of the limb with the trunk) and the tip of the index-finger immediately opposite on the posterior aspect of the limb (without compressing the soft parts). Now, keeping the thumb where first placed, and keeping the distance between the tip of the thumb and tip of the index unchanged, rotate the hand around (making these two fingers act as the two arms of callipers) until the tip of

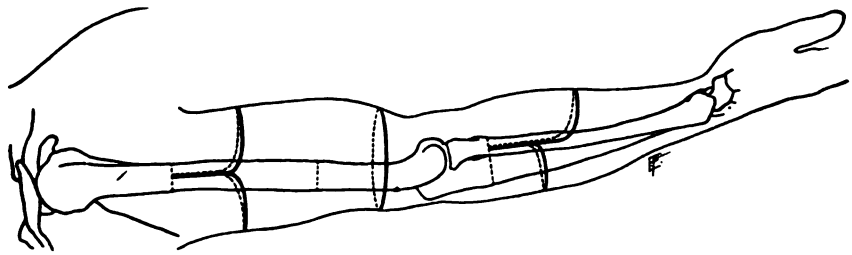

Fig. 210.—Relation of Skin Incision to Saw-line:—Methods of amputation by equal flaps, circular covering, and unequal flaps are shown each to furnish a covering of 1½ diameters of limb at saw-line.

the index rests upon the anterior aspect of the limb in a vertical line below the tip of the thumb. The distance between the thumb-tip and the finger-tip will be the diameter of the limb at the saw-line—and three-fourths of this measurement will insure a covering of the requisite 1½ diameters of the limb. In calculating the covering in the circular method of amputating, it is to be remembered that as the circular covering will be sutured in a straight line, either from before backward or from side to side, practically the covering may be regarded as being furnished by two aspects of the limb, either the front and back or the two sides—that is, as though furnished by two equal flaps (Fig. 210).

In Equal Flap Amputations.—Same as for the circular method, whether calculated accurately or approximately (Fig. 210).

In Unequal Flap Amputations.—(say the anterior twice as long as the posterior flap);—(a) Accurately;—Finding the circumference and diameter in the above manner (the measurements being as there given)—the lower limit of the anterior flap would be 5 cm. (2 inches) below the saw-line, and the lower limit of the posterior, 2.5 cm (1 inch) below. (b) Approximately;—Having gotten the measurement of the full diameter marked out on the anterior aspect, as explained above, this will represent the length of the anterior flap—and one-half of this measurement will give the length of the posterior flap (Fig. 210).

INCISION OF SKIN AND FASCIA.

In general terms, it is considered that the aspects of the limb furnish an average covering of 1½ diameters of the limb at the saw-line—whether this covering consist of skin alone, or of skin and muscle combined—and whether furnished by one or more aspects of the limb. In the circular method of amputating, the covering is furnished equally from all aspects of the limb. In the method by equal flaps, it is furnished equally by two aspects of the limb. And in the method by unequal flaps, the inequality of length may be parceled out in any way indicated, just so the total covering is equivalent to 1½ diameters at the saw-line. If the covering be from one aspect alone, as in the single flap or in the elliptical methods, the total diameter and a half comes from that one aspect. Where the amputation is done through a site of maximum contractility of skin and muscles (as through the lower half of

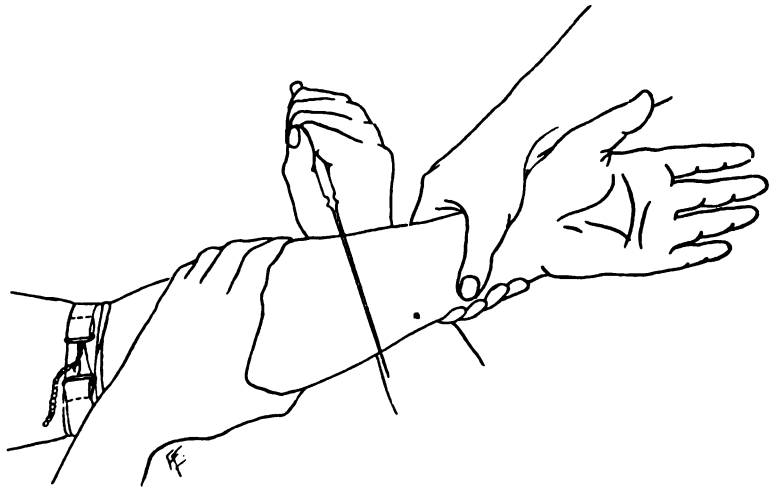

Fig. 211.—Incising Skin and Fascia in Circular Amputation:—1. Position of long knife in incising upper, further and part of lower aspects of limb.

the arm, or the lower half of the thigh), a somewhat greater allowance may become necessary (even to the extent of two diameters). Where the amputation is done through a site of minimum contractility of skin and muscles (as through the dense tissues of the palm of hand and sole of foot), a somewhat less allowance than the average may be provided.

Manner of Incising Skin and Fascia in Circular Amputations.—Whether a stump is going to be covered by skin alone, or by skin and muscle, the skin is invariably cut first and cut separately. Standing to the outer side of the right and inner side of the left limbs, grasp the part above the level of the skin incision with the left hand and retract the skin upward, either entirely alone or aided by an assistant (the assistant's aid being more necessary in large limbs)—the retraction being evenly maintained throughout. This is done to provide as ample a skin covering for the muscles as possible, for, as the average contractility of the skin involved in an amputation is greater than the average contractility of the muscles involved, if the skin and muscles were divided on the same level it would subsequently be found difficult, or

impossible to make the skin meet over the cut muscles. Therefore this circular division of skin, which has been well drawn up under the knife-cut prior to incising, means an actual division of the skin a little lower than the position of the knife on the limb indicates—but insures having a somewhat fuller measure of skin than if it were cut without retraction. Having thus retracted the skin, take a long knife with a blade one-and-a-half times the diameter of the limb to be removed—and, holding it in a full hand, like a pruning-knife, pass the arm under the patient's limb and bring the cutting-edge into contact with the upper surface of the limb, the back of the knife being horizontal and pointing upward, the heel of the knife being over the center of the limb, and the point projecting beyond the limb toward the surgeon. Beginning the incision with the heel of the knife, steadily and evenly draw the knife from heel to point, passing with one sweep of the knife

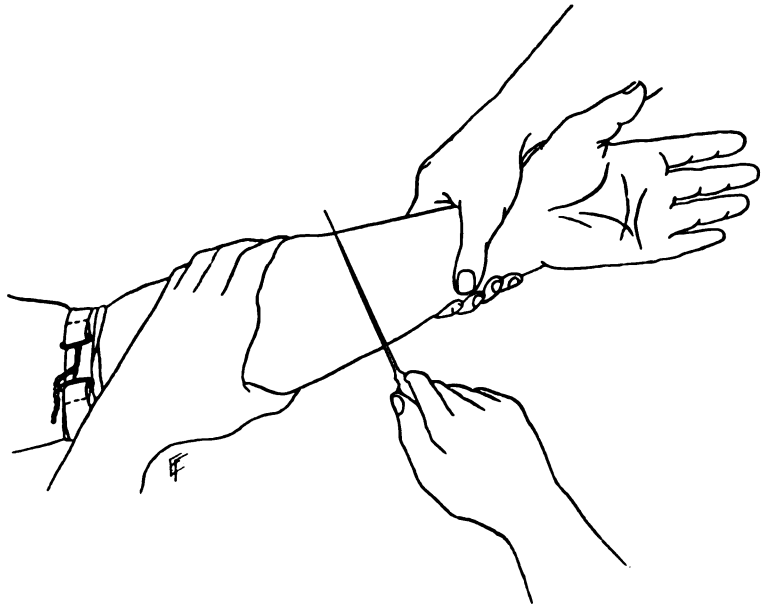

Fig. 212.—Incising Skin and Fascia in Circular Amputation:—II—Position of long knife in incising nearer and remainder of lower aspect of limb.

through three-fourths of the circumference (Fig. 211). The knife is then withdrawn and reinserted with its heel at the place of beginning of the incision on the supero-external surface (in operating on the right limbs), and, with one sweep, passes through the remaining fourth of the circumference (Fig. 212). The attempt to make the complete circuit with one sweep is not to be recommended, as the ends of the resulting wound are not apt to be in line, and the wound, generally, imperfectly made. This circular skin incision is sometimes made with a small knife. The assistant can aid the surgeon by rotating the limb to meet the knife. The blade is held perpendicular to the skin throughout. The incision passes through skin and fascia, but not into muscles. Owing to the unequal retraction which sometimes takes place upon the different aspects of a limb, it may be necessary to plan one portion of the circular incision upon a lower level than the rest

of the incision—this greater allowance of skin at this site will, however, be drawn up on a level with the rest of the circular incision, owing to the greater retraction there. So that what may appear as an oblique incision, will become circular and upon the same level after the division.

Manner of Incising Skin and Fascia in Flap Amputations.—As in

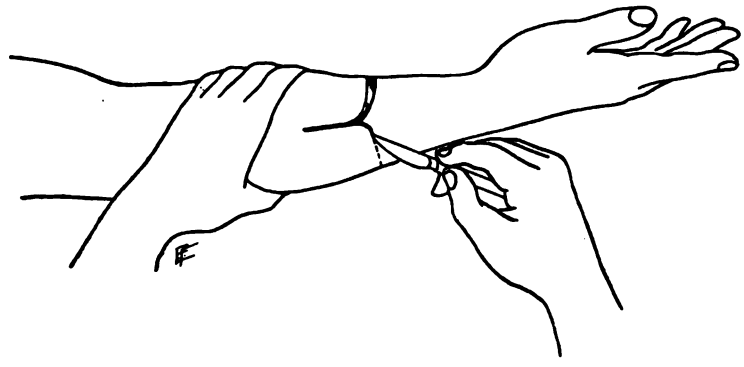

Fig. 213.—INCISING SKIN AND FASCIA IN FLAP AMPUTATION:—I—In cutting rounded flaps.

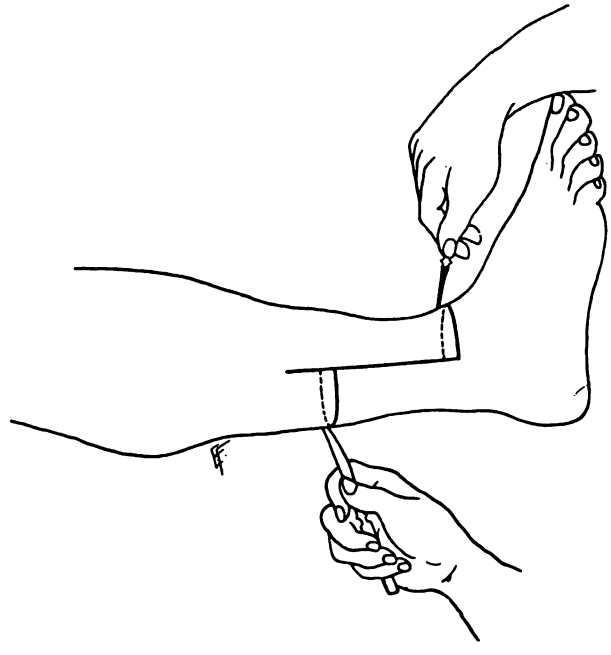

Fig. 214.—INCISING SKIN AND FASCIA IN FLAP AMPUTATION:—II—In cutting rectangular flaps.

the circular method, whether the covering is to be of skin alone, or of skin and muscles, the skin is invariably cut first and separately—and whether the flap be cut from without inward, or from within outward (by transfixion). The preliminary steps, as to position, retraction of skin, and general prin-

ciples involved, are the same as in making the skin incision in the circular amputation. When all is ready, the surgeon takes an ordinary scalpel of medium size, and, holding it as a violin-bow, enters its point into the skin vertically, at the upper limit of the base of the flap. The knife passes through skin and connective tissue, and as it travels vertically down one limb of the flap the cutting-edge is lowered until it forms less than a right angle with the surface being cut—when nearly the lower limit of the flap is reached, the knife rounds the corner of the flap—thence passes transversely across that aspect of the limb from which the flap is being taken—then similarly rounds the opposite corner—and thence travels vertically upward to a point corresponding with the point of beginning (Fig. 213). Care should be exercised that each flap should measure one-half the circumference of the limb at its base, and one-half of the circumference at that part of its free end just above the rounded corners—and that these corners should be very bluntly, and not sharply, rounded (that they should be squarely rounded, as it were), for if they be too much tapered at their free ends, they will cover the stumps with difficulty and unsatisfactorily. Instead of cutting the entire flap with one sweep of the knife, each vertical limb and one corner of the flap should be made with one downward cut of the knife. While all flaps should be practically square, with merely the corners rounded, an exception is made in the method of unequal rectangular flaps of skin and fascia (Teale's method)—the corners of the flaps being here right-angled, instead of rounded (Fig. 214). This is also the case in the conversion of a circular method of amputation into a flap method by two vertical incisions placed laterally—and even here the corners may be rounded.

FREEING SKIN AND FASCIA.

Having incised skin and fascia, for either a circular or a flap amputation, the manner and extent of further freeing skin and fascia will depend upon whether the method is to be one of simply skin and fascial covering, or of skin, fascial, and muscular covering for the stump.

Freeing Skin and Fascia in Simple Skin and Fascial Covering for Stump.—The skin and fascia, after having been divided, are partly retracted and partly dissected back to the line of future division of muscles. The edges of skin and fascia (avoiding the separation of the one from the other, as the vessels reach the skin through the fascia) are grasped by the fingers of the left hand, lifted from the muscles, and drawn upward—and, while held in this position, and while under slight tension, the fascia is touched here and there at points where it especially binds along the line of its junction with the muscles and deep fascial planes, by a scalpel held at a right angle to the surface of the muscles and with its cutting-edge toward the part to be removed—and thus scoring of the skin and consequent damage to its blood-supply are avoided. The skin and fascia are, by this means, raised in one layer from the muscles—and the skin should be raised with all the underlying fascia possible—and the combined skin and fascia should be raised evenly up to the future line of muscle division (Fig. 215).

Freeing Skin and Fascia in Skin, Fascial, and Muscular Covering for Stump.—Special care is here taken not to separate skin and fascia from underlying muscles, any further than simply in the immediate line of original skin incision, and simply for the purpose of allowing of full retraction. The skin and fascia are here not picked up and separated from the muscles—

the only knife-touches necessary being a few where the fascia has not been thoroughly divided and where it is necessary further to divide a fascial attachment here and there in order that the skin and fascia may retract as far as

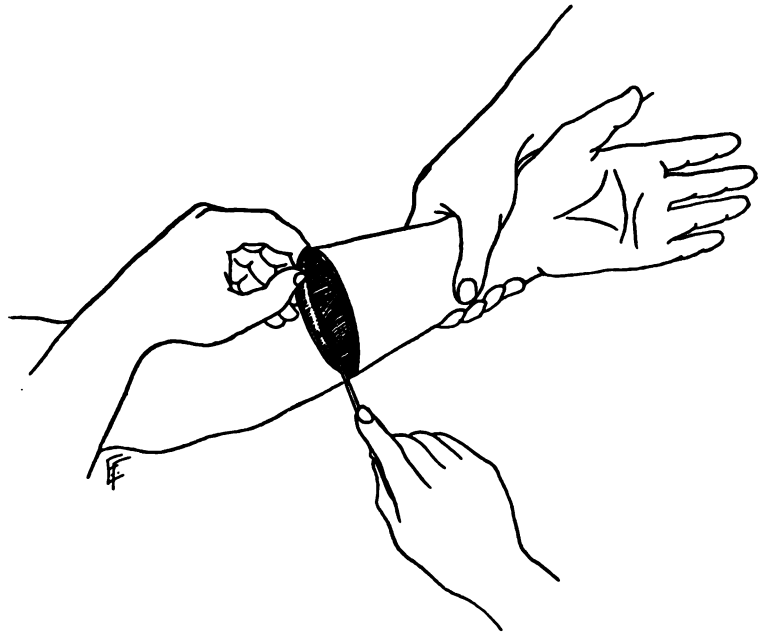

Fig. 215.—Freeing Skin and Fascia from Underlying Muscles.

they naturally will unaided by manual retraction—and this is done by touching the points of binding at the bottom of the original incision, by the point of a knife held vertically.

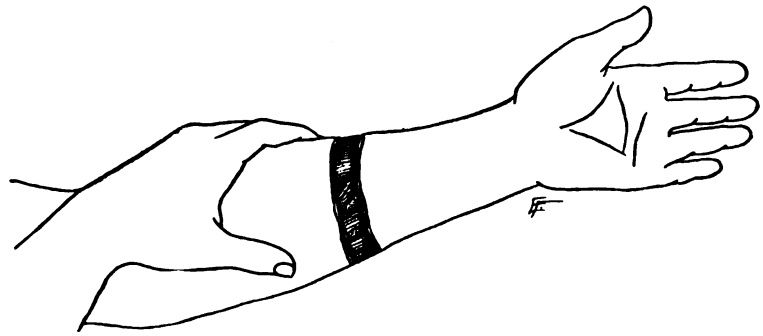

Fig. 216.—Retraction of Skin and Fascia.

RETRACTION OF SKIN AND FASCIA.

Where Stump-coverings are to be of Skin and Fascia Alone.—Having freed skin and fascia from the underlying parts, as above described, partly by retraction and partly by dissection, until the line is reached at which the muscles are to be divided, the skin and fascia are further retracted above

this line and are held out of the way by the hands of an assistant, or by retractors (Fig. 216).

Where the Stump-coverings are to be of Skin, Fascia, and Muscles.—Retraction of skin and fascia from the underlying muscles, other than that which occurs unaided, is not practised. It is sought, on the other hand, to keep in contact, as one layer, skin, fascia, and muscles.

DIVISION OF MUSCLES IN CIRCULAR METHODS OF AMPUTATION.

In the Ordinary, or Infundibuliform, Variety of Circular Amputation.—(For description, see page 261.)—(a) Division of More Superficial Muscles;—The position of surgeon, manner of holding limb, kind of knife and manner of manipulating it, are all the same as in making the skin incision.

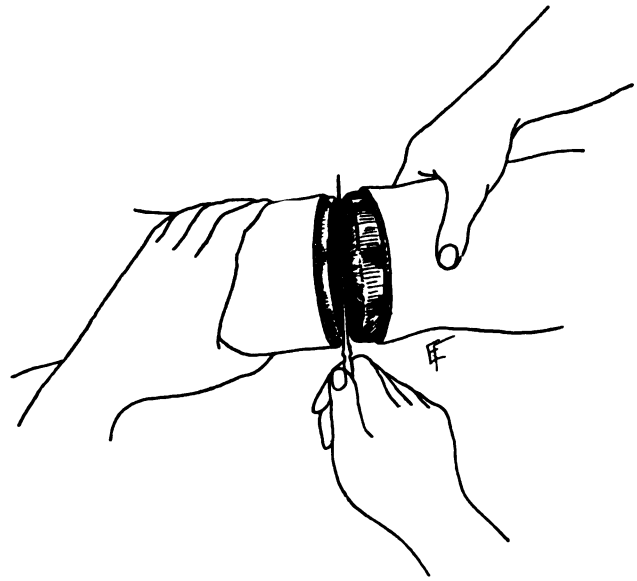

FIG. 217.—DIVISION OF MUSCLES IN INFUNDIBULAR VARIETY OF CIRCULAR AMPUTATION:—I—Dividing more superficial muscles on level with retracted skin and fascia.

The skin and fascia having been circularly incised and allowed to retract, the surgeon grasps the limb above the naturally retracted skin, and further retracts skin and fascia, putting, at the same time, the muscles upon the stretch by this upward retraction of the overlying parts, aided by an assistant in the case of larger limbs. The more superficial muscles are now divided circularly on an exact level with the retracted skin, by one sweep of a long knife passing, first, through three-fourths of a circle, followed by a second sweep through the remaining fourth (Fig. 217). It is not always possible to divide only and wholly what are generally understood as the superficial layers of muscles—it is only meant that one divides, in this first circular division, about one-half of the muscular covering of the limb, the knife sometimes dividing a group of muscles completely and sometimes only partially. To allow for unequal retraction, the muscles may sometimes have to be divided lower on one aspect of the limb than on another. (b) Retraction of More Super-

ficial Muscles;—This layer of muscle tissue is now retracted as the skin was above it. It is not expected that the first muscle layer includes all and only the superficial muscles, and the deep layer all and only the deep muscles—

Fig. 218.—Division of Muscles in Infundibular Variety of Circular Amputation:—II—Dividing deeper muscles on level with retracted superficial muscles.

the former includes simply the more superficially placed, and the latter the more deeply placed muscles. There is no general use made of the scalpel in freeing the superficial muscle layer, as in the case of separating the fascia and skin from the muscles, but, where indicated, a touch of the knife may be used to

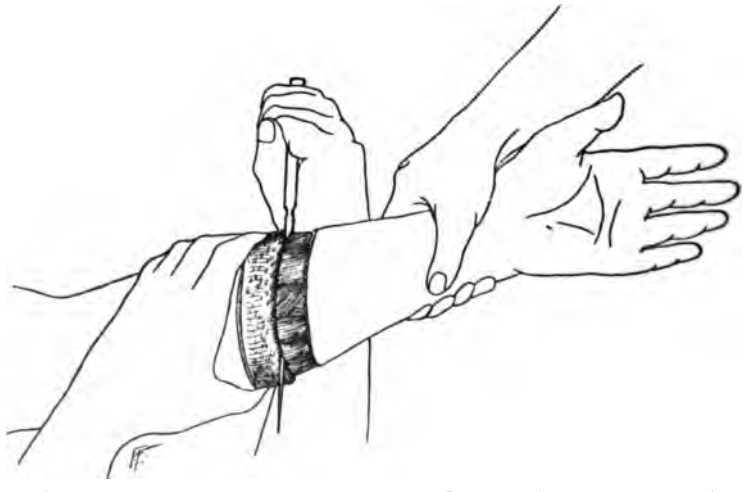

Fig. 219.—Division of Muscles in Cuff Variety of Circular Amputation—on a level with the turned-back cuff and fascia.

enable the more superficial muscles to be evenly retracted. (c) Division of Deeper Muscles;—Having retracted the divided muscles more superficially placed, the more deeply situated muscles are now circularly divided on a

level with the retracted superficial muscles, and in a manner similar to the divi-

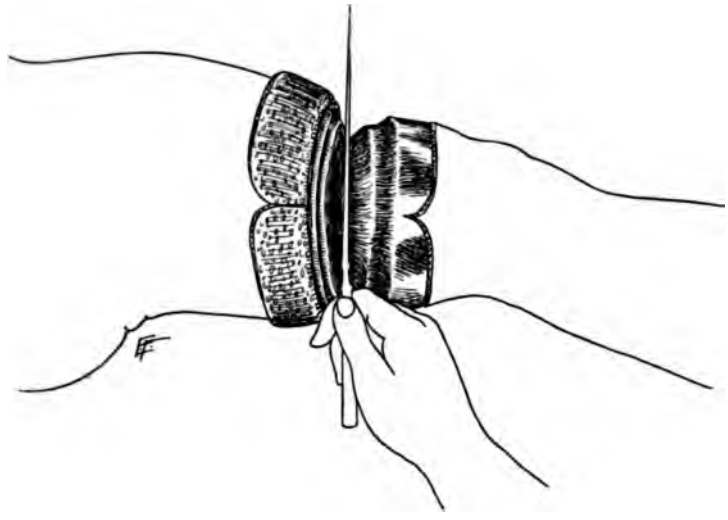

Fig. 220.—DIVISION OF MUSCLES IN MODIFIED CIRCULAR AMPUTATION—showing flaps of skin and fascia turned back, the more superficial muscles divided, and the knife in the act of dividing the deeper muscles in the infundibular fashion.

sion of the first layer (Fig. 218). It is to be planned that this circular division of the deep muscles will come down upon the bone sufficiently far below the saw-line to provide for a periosteal flap. **(d)** Retraction of Deeper Muscles;—This is done preparatory to forming the periosteal covering. Note—it will thus be seen that, having divided skin and fascia lowest of all, the superficial muscles have been divided upon a higher level, and the deep muscles upon a still higher level—forming, thereby, when the bone is sawed, a hollow cone, whose apex will be formed by the sawed bone, whose base will be the margin of skin and fascia, and whose sides will be composed of the cut muscles (Fig. 242).

In the Circular Amputation "à la Manchette," or Cuff Variety of Circular Amputation.—(For description, see page 263.)—In this method, all the muscles are divided circularly down to the bone at one level, which is that of the reflected cuff of skin—calculating to come down upon the bone sufficiently far below the saw-line to form a musculo-periosteal covering (Fig. 219).

Fig. 221. — DIVISION OF MUSCLES IN OVAL METHOD OF AMPUTATION.

In the Modified Circular Amputation.—(For description, see page 264.)—After the flaps of skin and fascia have been retracted, the more superficial muscles are divided on a level with the retracted flaps—this layer of muscle tissue is retracted—and the deeper layer is divided upon a level with the retracted superficial layer—calculating to come down upon the bone far enough below the saw-line to allow for a musculo-periosteal covering (Fig. 220). The division of muscles being, in other words, just as in the ordinary circular amputation. This is the better way of dividing the muscles in the modified circular operation. Where, in the modified circular amputation, the muscles are all divided at one level (that of the retracted flaps), the muscles are divided as in the circular amputation *à la manchette.*

In the Oval Method of Amputating.—(For description, see page 265.)—After having made the oval incision through skin and fascia, the muscles are divided directly to the bone—the knife entering the muscle tissue upon the line of the retracted skin and fascia. Along the queue, or vertical portion of the oval, which begins at, or just above, the saw-line, or disarticulation-line, the two lines of incision will coincide—parting below to follow the outlines of the oval—and meeting at the mid-point behind (Fig. 221).

In the Racket Method of Amputating.—(For description, see page 266).—The principle here is the same as in the oval method.

DIVISION OF MUSCLES IN FLAP METHODS OF AMPUTATION.

In Amputating by Single Flap of Skin and Muscle.—(For description, see page 267.)—The skin-and-fascia flap having been outlined and incised, the muscles are cut, preferably from without inward (or may be cut from within outward, by transfixion), beveling inward, on a line with the retracted skin-and-fascia flap—the incision coming down upon the bone sufficiently far below the saw-line to provide for a musculo-periosteal covering (Fig. 222).

In Amputating by a Single Skin-flap.—(For description, see page 269).—Having retracted skin-and-fascia flap, the muscles are divided circularly at the saw-line, or disarticulation-line.

In Amputating by Equal Flaps of Skin and Muscle.—(For description, see page 269.)—Same as by single flap of skin and muscle (Fig. 223).

In Amputating by Equal Flaps of Skin.—(For description, see page 270.)—Same as by single skin-flap.

In Amputating by Unequal Flaps of Skin and Muscle.—(For description, see page 271.)—Same as by single flap of skin and muscle.

In Amputating by Unequal Flaps of Skin.—(For description, see page 272.)—Same as by single flap of skin.

In Amputating by the Elliptical Method.—(For description, see page 273.)—As this may be considered a variety of single flap amputation (of either skin alone, or of skin and muscle combined), the manner of dealing with the muscle is here the same as in that operation.

In Amputating by Teale's Method of Unequal Rectangular Flaps of Skin and Muscle.—(For description, see page 272.)—Upon the line of the retracted skin and fascia, the muscles are cut through the periosteum along the two vertical lines. The muscles are then cut through the periosteum transversely along the free margin of the retracted skin and fascia representing the end of the longer flap—all of the soft parts are then dissected up above the lower limit of the shorter flap, when the muscles opposite its lower limit are transversely divided through periosteum to bone.

Method of Cutting Flaps from Without Inward.—In this method the flaps are cut by dissection, as it is sometimes called. The incision outlining the flap having been made through skin and fascia, the surgeon, standing to the outer side of right limbs and inner side of left limbs, and grasping the limbs between saw-line and trunk, proceeds to cut the muscle portion of the flap. A scalpel is made to cut the muscles along the line of retracted skin-and-fascia flap, the point of the knife entering the muscles at the upper limit of one of the limbs of the skin-and-fascia flaps—follows this margin vertically downward, passing deeply through the muscles—as the free border is approached, the knife is given a direction obliquely inward, so as to broadly and thickly bevel the muscles here, leaving them thinnest (though not thin) along this aspect of the flap—continuing the beveling process across the entire transverse width of the free end of the flap and well around its bluntly rounded corner — thence the knife passes vertically up the opposite limb of the flap, sinking deeply into the muscles, though the bone need not be fully reached in the vertical cuts at the first stroke (Fig. 224). As in cutting skin-flaps, the entire incision need not be made at one stroke of the knife—but is better made in two strokes from above downward. The surgeon now grasps the partly cut flap with the fingers of his left hand, and, while drawing it away from the bone, proceeds to fashion the rest of it along the same lines upon which it was begun, beveling it toward the bone by successive cuts of the knife—planning that the base of the flap will contain the full thickness of the soft parts covering the bone—and calculating that the knife will come down upon the bone (or bones) far enough below the saw-line (or disarticulation-line) to provide a musculo-periosteal (or capsulo-periosteal) covering. Where two flaps are cut, the second is cut in the same general manner. Care should be taken that the muscles are thickly and bluntly beveled, else a thin, ill-nourished ending to the flap is apt to be left. No attempt is made to bevel the upper part of the sides of the flap (the vertical portions)—the beveling beginning only just above the rounded corners. By cutting on a line with

Fig. 222.—Division of Muscles in Amputation by Single Flap Method.

the retracted skin, ample covering of the muscle-portion of the flap by the skin-and-fascia portion is provided (Fig. 223).

Method of Cutting Flaps from Within Outward.—In this method the flaps are cut by transfixion. The skin and fascia should always be cut first and from without inward, as the first step of every flap (as well as of every other kind of) amputation—no matter what the method of doing the

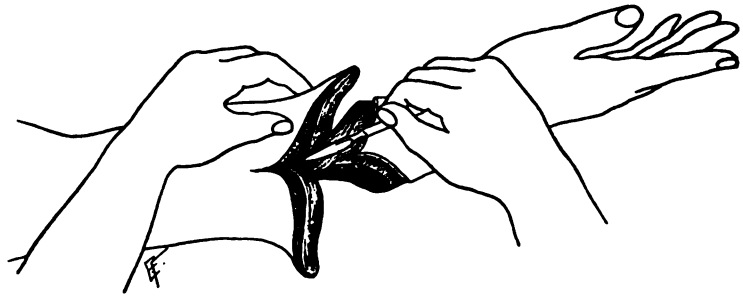

Fig. 223.—Division of Muscles in Amputation by Double Flap Method.

other steps of the operation. If this be not done, the muscles and skin will necessarily be cut upon the same, or nearly the same, level—with the inevitable result that there will be a deficiency of skin to cover the muscles, owing to the greater retraction of the former. Having, therefore, cut the skin and fascia flap from without, the surgeon proceeds to cut the muscles by transfixion. A long knife is taken, having a length equal to at least one-and-a-half diameters of the limb at the site in question. Marking the saw-line with

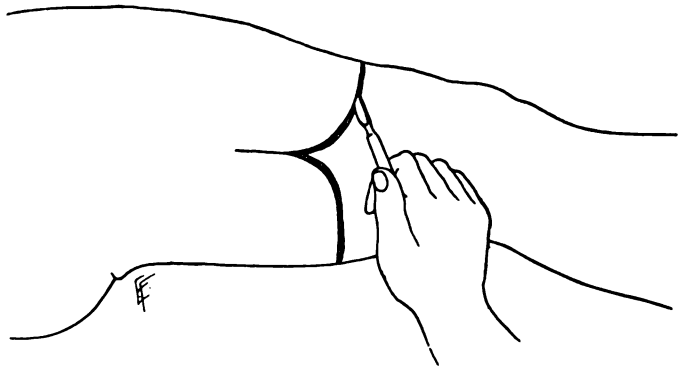

Fig. 224.—Method of Raising Flaps of Skin and Muscle by Cutting from Without Inward.

the thumb of the left hand, the point of the long knife (whose sides look upward and downward and whose edge points toward the extremity to be removed) is entered directly in the center of the lateral aspect of the limb (where the flaps are to be taken from the anterior and posterior aspects of the limb) and opposite the saw-line. The knife-point should be so placed and pointed as to avoid important vessels. The knife is then carefully pushed directly forward, until its point strikes the center of the lateral aspect of the bone (or, if two bones, of that one nearer the operator)—the handle is

then lowered while the forward progress of the knife continues, so that its point is made to hug the bone closely until its upper margin is reached—the handle is then raised so as to cause the point to sink and follow, as nearly as possible, the surface of the bone (or bones) on the opposite side (which, naturally, can be less closely followed than the nearer quadrant of the bone's circumference). When the knife's point is felt to have reached a point on the far side of the limb corresponding with the center of the bone, the handle is then lowered to a horizontal position and the knife thrust on forward until it protrudes through the skin on the far side of the limb. The surgeon stops here a moment to calculate the line along which the cutting-edge of the knife is to emerge—the guide to which being the line of the retracted skin flap. With a slow back-and-forth sawing movement, the knife is made to cut its way forward—hugging the bone (or bones) closely throughout the greater portion of its way—until near the free end of the flap, when it is made to round its way out in such a manner as to cut a thickly beveled edge of muscle on

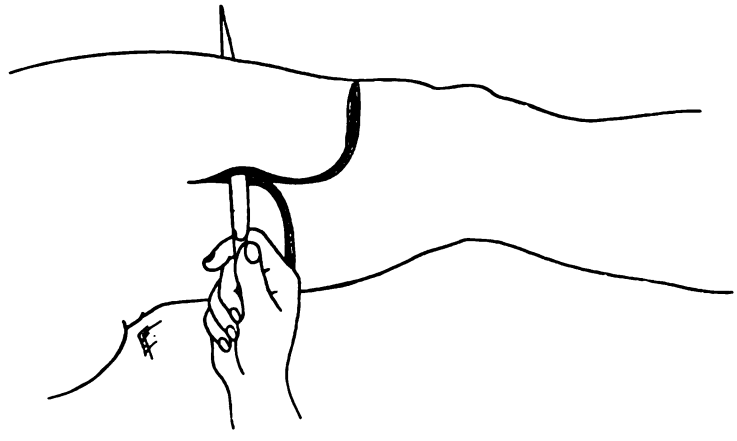

Fig. 225.—METHOD OF RAISING FLAPS OF SKIN AND MUSCLE BY CUTTING FROM WITHIN OUTWARD (BY TRANSFIXION)—cutting upon the line of retracted skin and fascia, which have been previously divided.

a line with the retracted free edge of skin (Fig. 225). In cutting a second flap from the opposite aspect of the limb, the first flap is retracted out of the way—the knife then passes over the cut surface of the muscle along exactly the same course as in beginning the transfixion of the first flap—until its point strikes the center of the lateral aspect nearer the surgeon (at exactly the same point as in the first manœuvre). The handle is now raised, to cause the point to follow down the lower quarter of the circumference of bone nearer the operator—when its lower margin is reached, the handle of the knife is lowered and the knife pushed forward, until the inferior surface of the bone (or bones) is passed. The handle is now still further lowered and the knife pushed forward, so as to cause the point to follow the further inferior quarter of the bone and emerge opposite the center of its lateral aspect. But as this manœuvre is difficult to accomplish, the surgeon generally aids the knife with his left hand, by partly guiding it and partly depressing the remaining soft parts on far side below the point of the knife so that its edge escapes them. Then with a similar back-and-forth movement, at first hugging the bone, the knife is made to cut its way out on a line with the retracted skin-flap. In order to

avoid cutting the muscle-flaps too narrow and too thin, it is necessary to hug the bone (or bones) until about three-fourths of the flap is cut and then abruptly round out to the line of the retracted skin-flap. Great care is also necessary to avoid piercing the main vessels in making the transfixion—and to avoid splitting them (whether at first transfixed or not) in cutting forward to form the flap. Therefore, it is sometimes necessary, when forming flaps by transfixion, to so plan them that they will not be precisely antero-posterior, or lateral—but will be so formed as to be least likely to contain split vessels. Considerable tissue at the base of the flap often escapes division in cutting by transfixion and has to be cut subsequently. The method of transfixion may be varied by not passing the knife so closely to the bone—that is, by transfixing the more superficial muscles only, retracting these, and then cutting the deeper muscles circularly at the saw-line. A further modification of the transfixion method consists in cutting through skin-and-fascia flap from without—then transfixing the apex of the muscle-flap—and dissecting up the remaining soft parts.

Comparison of Methods of Cutting Flaps.—(a) The method of cutting from without inward enables a flap to be cut with greater precision—makes the wounding and splitting of the main vessels unlikely—and provides for a more accurate calculation of covering for the stump, especially as to the relation between the amount of skin and muscle covering. It is the method to be chosen in the great majority of cases. (b) The method of cutting flaps from within outward (transfixion) is a convenient method in very large limbs, and in some special amputations, and where speed is necessary. Flaps thus cut are apt to have their arteries injured—are apt to be too thinly beveled at their free ends—are apt to be too narrow throughout, and too pointed at their ends—and, generally, less judgment can be exercised in their fashioning. Even in the larger limbs a flap can be more satisfactorily cut from without inward than by transfixion. Even where transfixion is used, however, the skin and fascia should invariably be cut from without—and the knife should come out on a line with this retracted skin.

FREEING AND RETRACTING OF MUSCLES.

In Ordinary Circular Method.—After the division of the more superficial muscles by the circular sweep of the knife, it may be found that here and there these muscles are not divided to an equal depth. Such unequal division, wherever found, is completed by a few strokes of the edge of a small knife. This layer of muscles is then retracted upward until the level is reached for the circular division of the deeper muscles.

In Circular Amputation à la Manchette.—Here the muscles are divided directly to the bone, on the line of the reflected cuff, and no special freeing or retraction of the muscles is done, until ready to make the musculo-periosteal covering.

In Modified Circular Amputation.—The muscles are here freed and retracted as in the ordinary circular amputation.

In Oval Method of Amputation.—Here the muscles are divided on the line of the oval—no freeing or retraction being necessary until ready to make the musculo-periosteal flap.

In Racket Method of Amputation.—Same as in the oval method.

In Single, or Equal, or Unequal Flaps of Skin and Muscle.—(A) When Cut from Without;—The fingers of the left hand raise the flap away

from the bone, while the surgeon cuts the vertical limbs of the flap to the bone, and gradually bevels the terminal portion of the flap obliquely upward toward the bone. (B) When Cut from Within by Transfixion;—No freeing or retraction necessary, until ready to make the musculo-periosteal covering. (The fingers of the left hand may grasp up the soft parts of the limb and lift them away from the bone as the knife cuts its way out.)

In Single, or Equal, or Unequal Flaps of Skin.—The muscles are here divided on one level—no freeing or retraction being necessary, until ready to make the musculo-periosteal covering.

In Elliptical Method.—The muscles are handled as in an amputation by a single flap of skin and muscles.

In Unequal Rectangular Flaps of Skin and Muscle (Teale's Method).—The muscles are here handled as in amputation by unequal flaps of skin and muscle.

MAKING MUSCULO-PERIOSTEAL, OR PERIOSTEO-CAPSULAR, COVERING FOR END OF BONE.

Description.—A covering should be provided for the end of the amputated or disarticulated bone, or bones, which will consist of periosteum and overlying muscle, raised as a single musculo-periosteal or periosteo-capsular flap or covering. Care should be exercised in raising this covering, that muscle is not first raised from periosteum and periosteum from bone, but that muscle and periosteum should be raised in one adherent layer. Periosteum is absent over cartilaginous surfaces, hence a pure musculo-periosteal covering is not to be gotten in a disarticulation—but as much of the capsule of the joint, which is practically a continuation of the periosteum, should be preserved as possible, and treated in the same way as the periosteum, that the articular end of the proximal bone may be covered. The distinct advantages of a musculo-periosteal covering for the end of the bone are the following;—(1) The muscles being adherent to the periosteum, when a covering of the latter is stitched over the bone, a thicker and more fixed covering to the end of the bone is secured than could be otherwise attained:—(2) The end of the bone being covered by periosteum, adhesion of the soft parts to the end of the bone is far less likely, the parts covering the bone generally remaining freely movable, and are, therefore, both better nourished and are less likely to become painful;—(3) The medullary cavity of the bone being shut off by the musculo-periosteal covering, is much less apt to become involved in any septic process which may arise in the stump. The only objections which can be raised to a musculo-periosteal covering are the time and trouble involved—which should not be allowed to weigh against the practical advantages—nor should the possible formation of osteophytes and proliferation of bone from the turned-over periosteum be seriously regarded.

Manner of Providing Musculo-periosteal Covering in all Forms of Circular Amputation, and in all Double-flap Amputations Cut from Without Inward.—The surgeon should plan to have his knife pass through the deep layer of muscles surrounding the bone in such a way as to come down through these muscles and upon the periosteum without separating muscles from periosteum (which would also detach the vascular supply of the periosteum), and at such a level on the bone below the saw-line as to equal a full half-diameter of the bone at the saw-line. In circular amputations this final cut will pass transversely through the muscles,—in flap ampu-

tations, obliquely through, in the process of beveling. As soon as the periosteum is reached in this final incision, all the soft parts are carefully retracted around the whole circumference of bone at this level, especial care being taken not to use force in the retraction, thereby separating muscle from periosteum by dragging the former off of the latter. A circular incision is now made through the periosteum around the entire circumference of bone, at the level of the lightly retracted muscles—cutting the periosteum with especial firmness where closely bound to the lineæ asperæ. The periosteum is then detached back to the line of the future saw-cut, by means of a periosteal elevator—care being exercised not to push the muscles off the periosteum, but to push the periosteum back from the bone with the muscles attached (Fig. 226).

In Flap Amputations by Transfixion.—The knife should be entered just far enough below the saw-line to equal a full half-diameter, or more, of bone at the saw-line. When the flaps are cut, the periosteum is divided circularly at this level—and then the periosteum and muscles are detached back to

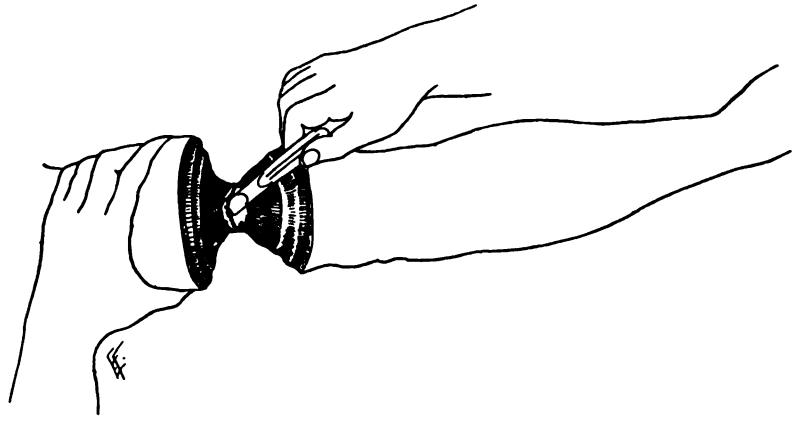

Fig. 226.—Raising a Musculo-periosteal Covering—in the circular method of amputation.

the saw-line—or the periosteum may be raised as two small flaps, their incision beginning at the saw-line (Fig. 227).

In Oval and Racket Modifications of the Circular Amputation.—The freeing back of the muscles should be stopped at a level equal to a full half-diameter, or more, of the bone below the saw-line—the periosteum is here circularly divided—and the periosteum and muscles detached thence back to the saw-line.

In Single-flap Amputations of Skin and Muscle.—The knife comes down upon the bone one full diameter, or more, of bone below the saw-line. As the two vertical limbs of the flap have been cut down to the periosteum in the earlier part of the operation, a musculo-periosteal flap is now marked out, having a base equal to half the circumference of the bone at the saw-line and a length equal to one full diameter, or more, of the bone at the saw-line. The periosteum and muscles are now detached back to the line of bone-section —all the hitherto undisturbed parts on the opposite side of the limb are now divided transversely to the bone- and the bone sawed.

In Flap Amputations of Skin Only. -As the muscles are here divided

circularly, the musculo-periosteal flap is provided for just as in the ordinary circular amputation.

In the Elliptical Modification of the Single-flap Method.—The musculo-periosteal covering is handled as in the single flap of skin and muscle.

In Unequal Rectangular Flaps of Skin and Muscle (Teale's Method).—The musculo-periosteal covering is secured as in amputation by unequal flaps of skin and muscle.

In Amputating Limbs with Two Bones.—The musculo-periosteal covering for the larger bone is provided as described in the single bone limbs. The musculo-periosteal covering for the smaller bone is provided in the same manner, but will be cut at a higher level (as it is circularly divided, or a flap is cut, which will be equivalent to the smaller diameter of the smaller bone). Where the bones are of the same size, the periosteum is divided at the same level in each case—which may also be done when the bones are of unequal size, the redundancy of periosteum in the case of the smaller bone being subsequently removed with scissors.

Fig. 227.—Raising a Musculo-periosteal Covering—in the flap method of amputating.

Note.—The final treatment of the periosteal covering cannot be carried out until after the division of bone.

Comment.—(1) It will be seen that in circular amputations and in amputations by double flaps, the musculo-periosteal covering is furnished from the entire circumference of the bone—while in amputations by single flaps, a single flap of musculo-periosteal tissue is raised, the width of which is equal to a half-circumference of bone and a length equal to a diameter of bone. (2) As there is comparatively little retraction of fibrous periosteal tissue, the chief retraction taking place in the attached and overlying muscles, a length for the musculo-periosteal covering of one full diameter of the bone (each side of the bone hereby furnishing one-half diameter) will, therefore, cover the end of the bone, but none too fully—so that this measurement should be made very full. (3) Where it is difficult to detach the musculo-periosteal covering backward after simply a circular division of the periosteum, two vertical incisions may be made upon the lateral aspects of the bone, from the site of the saw-line to join the circular cut—which will make the detachment easier. These vertical incisions may, indeed, be made in all cases. Even where the vertical incisions are not made in detaching the periosteum, they may be subsequently made before adjusting the periosteal flaps or covering. In the pure flap amputations the muscles have already

been divided to the periosteum, so that the knife easily makes the two vertical incisions in the periosteum. In the circular amputation where it is necessary to add the vertical cuts before sawing the bone (that is, in order to reach the saw-line), the point of the knife may be pushed into the transversely divided muscles, in the long axis of the limb, up to the saw-line (which will lie only a half-diameter of the bone above) and cut downward thence to join the circular cut. (4) In the case of the two-bone limbs, the interosseous membrane is also freed back in the act of detaching the periosteum. (5) Some hold that the periosteal covering is without value in the adult and actually harmful in the young, owing to the possibility of reproduction of bone rendering the stump conical. The former is an error of observation. The latter must be very rare, the epiphysis being responsible for the chief increase of length of bone.

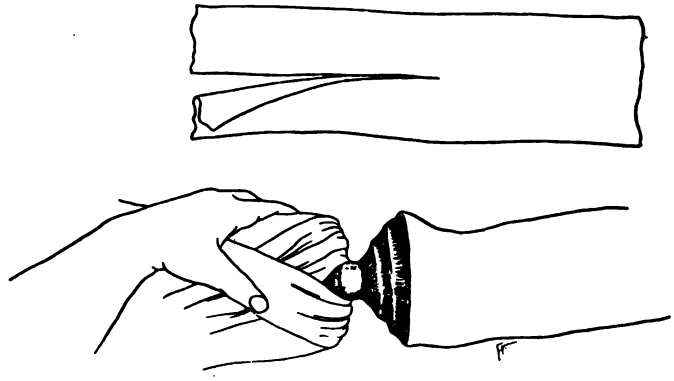

Fig. 228.—Retraction of Soft Parts Preparatory to Sawing of Bone—in the case of a single-bone limb. A single-tail retractor is shown above.

RETRACTION OF SOFT PARTS PREPARATORY TO SAWING THE BONE.

All the soft parts overlying the bone having now been divided, from skin to periosteum, these soft parts are to be retracted above and out of the way of the saw-line, which should be seen to be clear in its entire circumference before making the bone-section.

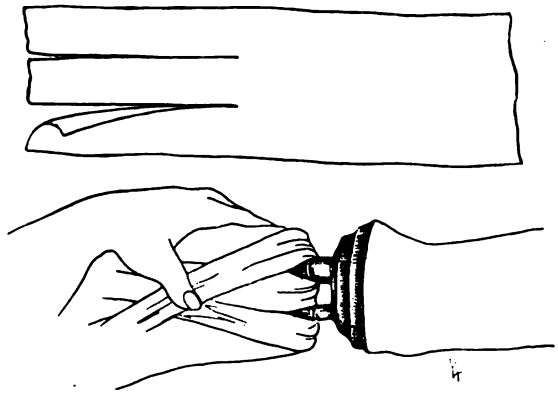

Fig. 229.—Retraction of Soft Parts Preparatory to Sawing of Bone—in the case of a double-bone limb. A double-tail retractor is shown above.

In Single-bone Limbs. — A double-tailed linen retractor is generally used to hold the soft parts back — the two tails of the retractor passing around the bone, thus supporting the soft parts and drawing them upward and out of the way (Fig. 228).

In Double-bone Limbs.—A three-tailed linen retractor is usually used—the central tail passing between the bones—the outer of the other two tails on the outer side of the outer bone, and the inner on the inner side of the inner bone (Fig. 229).

Comment.—The parts may also be retracted by the hands, or by various forms of metallic or other retractors.

SAWING THE BONE, OR BONES.

General Considerations.—The surgeon, standing to the outer side of right limbs and to the inner side of left limbs, grasps the limb firmly with his left hand just above the saw-line. An assistant supports the distal portion of the limb, holding it out over the side of the table, and on an exact line with the level at which the limb leaves the trunk, in the case of the arm and thigh; and on a level with the surgeon's left hand in the case of the forearm

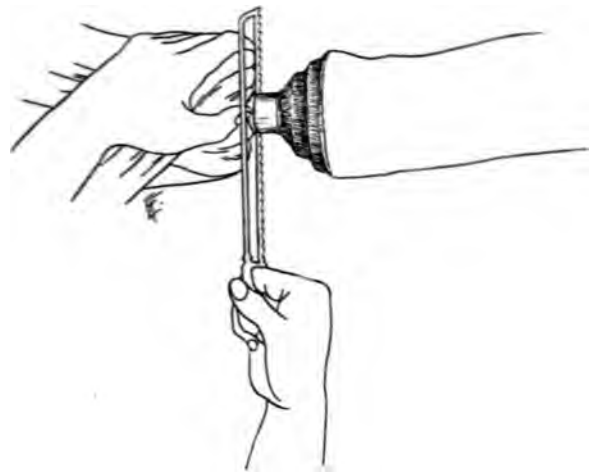

Fig. 230.—MANNER OF SAWING THE BONE—in the case of a single-bone limb.

and leg. If he elevates it above the common level, he will bind the surgeon's saw throughout the entire transverse section (because the parallel walls of the section will tend to approximate),—and if he depresses it below the common level, while he makes it easier for the surgeon to saw, he is apt to splinter the bone just before the section is completed (because the parallel walls of the section will tend to diverge).

In Single-bone Limbs.—The surgeon places the edge of his thumb-nail down upon the bone immediately above the saw-line, as a guide to the saw, temporarily loosening but not entirely relaxing his steadying hold with the other fingers and palm upon the limb. Holding an ordinary amputating saw in his right hand, he deliberately places its heel against his thumb and knuckles, and directly over the saw-line—and, with a fairly slow but firm and steady movement, he draws the saw backward from heel to point, thus grooving the bone transversely. If this groove be not distinct or deep enough, the first movement (from heel to point) may be repeated. The surgeon now resumes his steadying grasp of the limb with his left hand and proceeds to saw the bone by slow, even, steady, back-and-forth strokes of the saw,

traveling the entire length of the saw-blade at each stroke—and avoiding uneven and too rapid sawing, the latter sometimes generating a harmful degree of heat. It is during the section of the latter part of the bone that the assistant is most careful in his manner of holding the limb and the surgeon in his use of the saw. Toward the last the strokes of the saw should be slower, shorter, and lighter, and the limb so balanced that there will be no cross-strain anywhere throughout its length—and thus are the chances of splintering minimized. If indicated, the larger saw may be removed toward the last and the section be completed with a lighter, finer saw, but this is ordinarily unnecessary. As the bones of both single-bone limbs are nearly circular, no beveling of the edges is needed (Fig. 230).

In Double-bone Limbs.—The general manipulative method is here the same as in the single-bone limbs. The saw first engages the heavier bone, and, having passed partly through this, is dropped upon the lighter or more movable bone—the section of which latter bone should be first completed, the saw all the while cutting the heavier bone also, which it finally completes alone. Where both bones are of the same size (as the middle of the forearm), the saw grooves the one nearer the operator and is then dropped upon the farther one. Where a bone presents a prominent ridge, almost or quite subcutaneous (as the anterior border of the tibia), this would become an angular projection after section of the bone and would be apt to become a prominent point of pressure. To avoid this, this edge of bone should be beveled—which is best done by making an oblique saw-cut from above downward, beginning about 1.3 cm. (½ inch) above the saw-line and passing obliquely into the bone at such an angle as to be about 6 or 8 mm. (¼ or ⅓ inch) below the level of the bone by the time it has reached the saw-line. Having made this 1.3 cm. (½ inch) oblique saw-cut into the bone, the saw is then withdrawn and is made to traverse the bone transversely along the line of bone-section in the ordinary manner. When the saw, traveling transversely, reaches the short oblique section, the small triangle of bone will drop out—and when the section is completed, the prominent edge of the bone will be found beveled (Fig. 231).

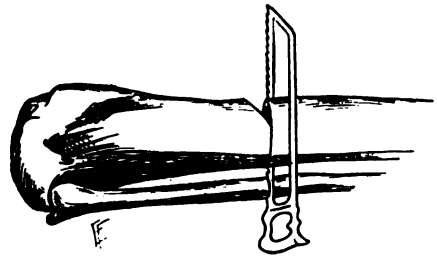

Fig. 231.—Manner of Sawing the Bones—in the case of a double-bone limb. The method of beveling a prominent margin of bone is also here shown.

Comment.—In the very young, and especially in amputating those bones which grow chiefly from an upper epiphysis, it is well to saw the bone as high as possible—as subsequent growth from such bones may require reamputation.

REMOVING SPLINTERED BONE.

If, in the final saw-section, whether by splintering or a transverse snapping of the frail bridge of bone, a fragment of bone is left projecting from the stump, or any other projecting irregularity should appear upon the transversely divided bone, this should be removed down to a level with the face of the bone. This is accomplished by grasping the spicula of bone with bone-holding forceps (such as the lion-jaw type) and steadying it, while the surgeon removes the spicula with a small, fine saw (Fig. 232).

Comment.—(1) Bony projections are often crudely crushed off with bone-cutting forceps—this is quickly done and is a temptation—but is not to be recommended, as necrosis of the margin of the bone is more apt to follow crushing than sawing. (2) The splinter of bone may be upon the

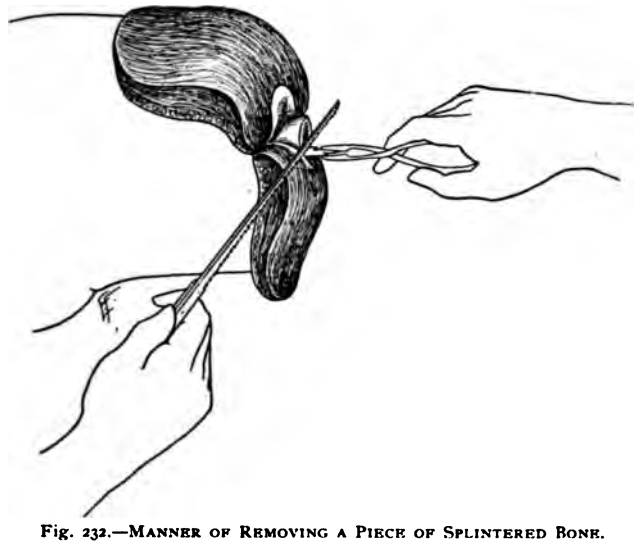

Fig. 232.—Manner of Removing a Piece of Splintered Bone.

portion of bone removed—there will then be a corresponding depression, with probably a tearing of periosteum and muscles, upon the bone in the stump—which may require to be evened off.

LIGATING ARTERIES AND VEINS.

As soon as the bone has been sawed, all the chief arteries and the larger veins should be tied. The arteries are tied in the order of their importance and are sought in their known positions. They have frequently retracted somewhat, so as to be out of sight, and are to be traced by their known relations. The stump should be held in a good position and light—and, if necessary, dried of blood. The cut ends of the arteries are caught by catch-forceps and drawn out of their beds by the surgeon—while an assistant ligates the larger vessels with chromic catgut, tying them with a surgeon's knot. The larger arteries may be tied with the stay-knot of Edmunds and Ballance (page 24). All the vessels should be clamped before any are tied. The larger arteries should be drawn out of their sheath before being tied. The smaller arteries with their sheaths may be included in the ligature. Arteries which are caught with difficulty with catch-forceps may be taken up with a tenaculum. Very small vessels may be compressed or twisted without ligaturing. The chief veins should be tied—as well as any others which are seen gaping. All vessels should be tied as long as possible—and should be disturbed in their sheath as little as possible. Arteries bleeding from their osseous canals in the end of the bone cannot be tied, but may be controlled by plugging the vascular canal with a piece of catgut, a piece of sterilized wood, or with Horsley's antiseptic wax, or Halsted's gut-wool—

or a limited portion of the canal may be crushed in upon itself. After all known vessels are tied, the Esmarch, or other constrictor, should be relaxed and all hitherto untied vessels which now bleed are to be ligated (Fig. 233, A, B, and C).

Comment.—(1) See that the first knot (friction-knot) does not loosen before the second knot (surgeon's knot) is complete—and that the knot is far enough from the end of the vessel not to slip off. (2) Where hemorrhage

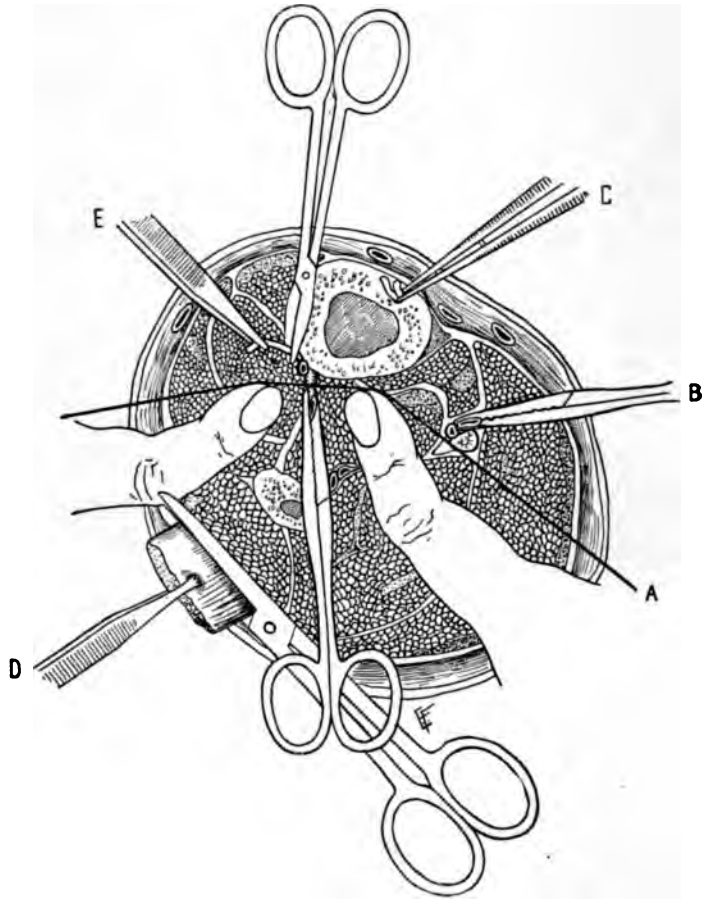

Fig. 233.—STUMP AFTER AMPUTATING THROUGH LOWER PART OF RIGHT LEG:—A, Ligation of anterior tibial artery; B, Clamping of posterior tibial artery; C, Plugging vascular canal of bone with piece of catgut; D, Cutting off tag of peroneus longus; E, Cutting anterior tibial nerve short.

is apprehended, vessels may be taken up immediately after dividing the soft parts, and before even severing the bone. Instead of taking up and tying the vessels seriatim, they may be immediately clamped, one after another, and, if not tied at once, the catch-forceps may be retracted with the flaps, or with the circular division of soft parts, and the bone sawed, after which the vessels are tied—relaxing the original hold where vessel and sheath are included and taking up vessel alone. (3) Obstinate oozing may generally be

controlled by ligating *en masse*—or by douching with hot saline solution, or by pressure. This is the form of hemorrhage which is more apt to occur after the removal of the constrictor.

TREATMENT OF NERVES, TENDONS, AND TAGS OF MUSCLE, FASCIA, AND SKIN.

(1) All nerves should be cut as short as possible, to avoid entanglement and pressure in the process of cicatrization—to accomplish which they should be caught by forceps and drawn well out and then cut with scissors and allowed to retract out of sight. Where the flap method has been done and it is likely that an important nerve may be subjected to pressure when the flaps are bent and sutured over the end of the bone, the nerve should be dissected out. This is especially the case in the method of single-flap amputation. Nerve ends are apt to become bulbous in any event, but will not be troublesome unless subjected to pressure. (2) All tendons should be caught with forceps, steadied, and cut short under slight tension. They are difficult to cut unless steadily held and slightly stretched—when they may be cut with scissors or a very sharp knife. Tendon-ends possess low vitality, are apt to slough, fulfil no useful purpose in the stump, and make but poor covering. (3) All tags and irregularities of muscle, fascia, and skin should be evenly trimmed, so as to conform with the general contour. (Fig. 233, E and D.)

TRIMMING OF FLAPS.

It is undesirable, and somewhat unsurgical, to make a miscalculation in the length or contour of a flap, which will require any subsequent trimming—but where a flap is distinctly too long, or too large, or misshapen, it is better to do the trimming necessary to make a good fit than to suture it in place as it is. It is held in the left hand and trimmed as one would trim a piece of paper. A flap may be trimmed as a whole—or some individual tissue composing it may be trimmed.

RE-AMPUTATION FOR IMPROPERLY MADE FLAPS.

It is even more unsurgical, and much more difficult to rectify, to find that so little allowance of covering has been made that the end of the bone either cannot be covered at all, or cannot be covered without a degree of tension calculated to endanger the flaps. In such a case all that one can do is to amputate at a higher level. If only a slight deficiency of covering exist, the end of the bone may be freed of its soft parts by retraction and made to project and then be removed by the saw. Where the deficiency is greater, from one to several inches of the soft parts may also have to be removed, as well as the bone. In such a case one proceeds very much as in the original operation, modified by the needs.

ADJUSTMENT AND SUTURING OF MUSCULO-PERIOSTEAL OR PERIOSTEO-CAPSULAR COVERING.

The first step in the closure of the stump-tissues is the adjustment of the musculo-periosteal covering. It will be remembered that in all circular amputations, and in all double-flap amputations of skin and muscle, the

musculo-periosteal covering was made by a circular division of the periosteum around the bone one-half of a full diameter of the bone below the saw-line (thus furnishing a full diameter), and that the periosteum, with adherent muscles, was then detached in one layer up to the saw-line. Therefore, after the bone is sawed and the soft parts drop down around its cut end, the musculo-periosteal covering will form a hollow cylinder projecting from the lower surface of the transversely sawed bone—the periosteum hanging down around the bone for a depth, approximately, of a half diameter of the bone, the muscles being adherent to its outer side. This cuff of musculo-periosteal covering may be converted into two small flaps by cutting along its lateral aspects with straight-pointed scissors, from its lower free margins up to the bone. The corners of these little flaps may then be slightly rounded, though this is not necessary. These two flaps are then dropped over the end of the bone and their edges are sutured together with catgut, the sutures passing through periosteum and muscles. While the above method makes a neater fit, it is not really necessary that the musculo-periosteal covering should be slit up at all on the sides—it suffices simply to approximate the edges over the bone by a suture running either antero-posteriorly or transversely. Where the musculo-periosteal covering has been raised in the form of a single flap (as in the amputation by a single flap), this single flap of musculo-periosteal covering is dropped over the end of the bone and its margins sutured to the cut margins of the periosteum around the rest of the circumference of bone, including the muscle overlying the periosteum. Where the bone-section is very small, it is often difficult to adopt any definite plan of making and suturing a musculo-periosteal flap, the periosteum being torn in shreds in the process of detachment. In such cases the mass of musculo-periosteal tissue is simply gathered together and sutured over the end of the bone. (Figs. 234 and 242.)

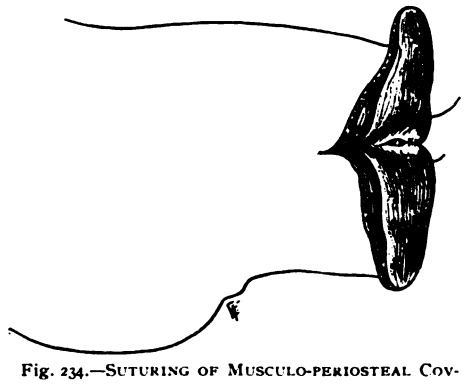

Fig. 234.—Suturing of Musculo-periosteal Covering.

QUILTING OF MUSCLES.

The muscle tissue which enters into the covering of the bone should, where possible, be approximated and sutured into apposition by buried chromic gut sutures, placed in one or more tiers, by means of either buried simple sutures, or buried quilt- or mattress-sutures. Thus the cut aspects of the muscles are brought into contact,—less tendency for them to retract away from the end of the bone occurs,—in the process of cicatrization they become incorporated in the general pad of covering which forms the stump (even though the muscle tissue itself may be subsequently replaced by fibrous tissue),—there is less chance of adhesions forming between bone and skin,—and, altogether, a fuller, softer, better-formed pad of covering is provided. These advantages more than counterbalance the only two disadvantages—namely, of time and trouble involved. By the process of quilting, muscles

are brought and held in contact until united, which, in the ordinary method of simply dropping muscles over the ends of the bones and depending upon the single line of marginal skin-sutures to approximate, either could not be made to come into contact even temporarily, or, if so, would generally retract apart before union.

In Circular (Infundibuliform Variety), Modified Circular, Oval, and Racket Methods.—After suturing the musculo-periosteal covering the muscle surfaces are brought into contact immediately over the musculo-periosteally covered end of bone. The approximation of muscle tissue over the bone may be made in the way in which the muscles most naturally fall. Other things being equal, the approximation should be made so as to cause the suture line to be parallel with the future suture line of the integumentary coverings. The first tier of sutures is placed nearer the bone, entering and leaving the muscle tissue at such a distance from the bone as to secure an easy approximation of the muscle substance over the end of bone. This first row of sutures, which, if of the simple form, may be either interrupted or continuous, will conceal the end of the bone. A second tier, especially in heavily muscled limbs, or in thin limbs with large muscle flaps, should be applied—being inserted nearer the edge of the muscle tissue than the first—and, when tied, will hide the first row (Fig. 235).



Fig. 235.—QUILTING OF MUSCLES IN CIRCULAR METHOD OF AMPUTATION:—First tier of sutures has been placed—and is being buried by the second tier.

In Circular Method à La Manchette.—As the muscles are here all divided on one level, and that level is that of the retracted skin, skin and fascia alone cover the end of the bone, and no approximation and quilting of the muscles are possible.

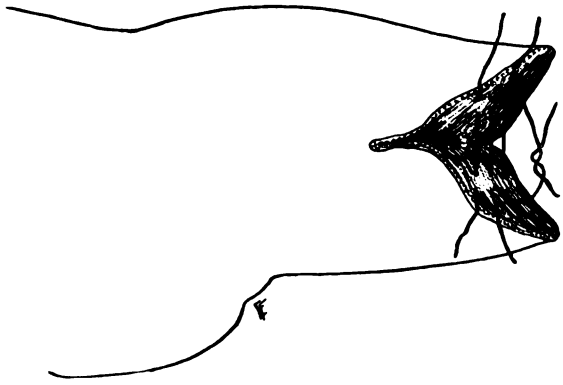

Fig. 236.—QUILTING OF MUSCLES IN FLAP METHOD OF AMPUTATION:—First tier of buried sutures has been placed and tied—and second tier is being placed.

In All Double-flap Amputations of Skin and Muscle.—The muscles are quilted in the same manner as in the ordinary circular (infundibuliform), the process of muscle-quilting being easier in the double-flap method than in the ordinary circular, as the muscles are adherent to the flaps on either side and are more readily held in approximation while being quilted (Fig. 236).

In All Double Flaps of Skin.—No quilting of muscles is here possible—as the muscles are transversely divided on a level with the retracted skin-flaps.

In All Single Flaps of Skin and Muscle, Including the Elliptical Method.—As the muscles are here divided obliquely on the side of the flap, and transversely on the opposite side, the quilting of muscles is not done as in the above-described methods (where the lateral aspects of the muscles are sutured to lateral aspect, or ends to ends). The lateral aspect of the muscles in the present instance, some of which aspect is made up by the obliquely beveled muscles, is sutured to the transversely divided muscles on the side of the limb opposite to the flap—and the ends of the muscles in the flap are sutured to the circumferential margin of the transversely divided muscles in the stump. As the base of the flap comes from a full half-circumference of the limb, the bent-over flap is only approximated to the opposite half of the face of the stump. Where this method is used in the neighborhood of an articulation (that is, in a disarticulation) where only tendons pass over and cover the joint, no quilting is possible. It is, therefore, applicable only where muscles cover bones, which, in the case of the joints, is only at the shoulder and hip.

DRAINAGE.

No drainage is necessary in amputating through sound tissue in the continuity of a limb. Temporary drainage (for two or three days) may be instituted in disarticulating through the larger joints—to provide for the escape of the synovial fluid which the remaining synovial surfaces will go on secreting for a time. Where drainage is indicated, it is sometimes better to make a counter-opening than to attempt to drain through a non-dependent suture-line. Drainage may be temporarily used where bleeding in the stump-tissues is feared after prolonged use of an Esmarch, or for other reason. Drains of rubber-tubing, glass, gauze, or bone-tube may be used.

SUTURING OF THE STUMP.

The suturing of the edges of the wound should be done with silk and by means of interrupted sutures. Where no great tension is likely to occur, silkworm-gut may be used. Catgut is also employed. The parts should come together without tension. The interrupted is to be preferred to the continuous form of suturing, for the parts may be thereby more accurately adjusted—and if it become necessary to open any part of the wound for drainage, or other cause, only the few indicated sutures need be cut.

In Circular Amputations.—It is optional with the operator as to whether the soft parts are so approximated as to result in a line of sutures running from before backward, or from side to side. The former is to be preferred, as the lower end of the suture-line (in the recumbent position of the patient) drains the wound by gravity, in case drainage be necessary. Where skin and muscle come evenly to the edge of the wound, both are included in the sutures. Where skin is longer than muscle, the sutures which close the wound pass through skin only—the muscles having been approximated by their own buried sutures.

In Flap Amputations.—Here the direction of the line of sutures will be determined by the position of the flaps. Where double flaps are taken from the anterior and posterior aspects of a limb, the suture-line will run

from side to side. Where double flaps are taken from the lateral aspects the suture-line will be antero-posterior. Where a single flap is approximated to the opposite side of the limb, its margin is sutured to the opposite half-circumference. Where the margin of the flaps is composed of skin and muscle, both are included in the sutures. Where the skin is longer than the muscle, the skin alone is included in the suturing. In all cases the muscle surfaces are supposed to have been quilted together prior to the final closure of the wound.

Comment.—(1) Owing to the difficulty of equally dividing out the positions for sutures where a large wound is to be brought together, it is well to begin by putting in a central suture and then divide each remaining half of the space into quarters by two other sutures—then these smaller lengths can be sutured with interrupted or continuous suture—the former being better, as, in case it be necessary to loosen any suture for suppuration, or otherwise, the entire line need not be loosened. (2) If tension upon the edges be great, a few tension-sutures may be used.

DRESSING OF THE WOUND.

The wound and stump should be covered with absorbent gauze—the entire stump enveloped in absorbent cotton—which should be snugly bandaged to the end of the stump and the circumference of the limb. A padded posterior splint should be incorporated in the outer layers of the dressing, projecting beyond the stump slightly—both to support the part; protect it from injury; and control, or lessen, the muscular startings which are apt to occur. The stump should rest upon an inclined plane, outside of bed-covering.

REMOVAL OF DRESSINGS.

If all goes well, the dressings are not removed until about the tenth day (or from the tenth to the fourteenth). If a drainage-tube be used, the dressings are often changed when that is withdrawn—although it is sometimes withdrawn at the end of the second or third day--and the dressings not removed until the usual time.

THE METHODS OF AMPUTATION.

THE EVOLUTION OF AMPUTATION METHODS.

The methods of amputation have undergone a slow process of evolution —which may be briefly stated in the following tabular form (modified from Kocher).

Circular Incision.—The fundamental type of amputation. Of which there are two varieties, and from which all other methods of amputation may be derived;—(a) Transverse circular incision (Fig. 237, A); (b) Oblique circular incision (Fig. 237, B).

Racket Incision.—Formed by the addition of a longitudinal incision to the circular incision. (a) If the longitudinal incision be added to the transverse circular incision, the transverse racket incision results (Fig. 237, C); (b) If the longitudinal incision be added to the oblique circular incision, the oblique racket incision results (Fig. 237, D). *Note*—The corners of the

racket incision are now generally rounded off, as in the oval method, the

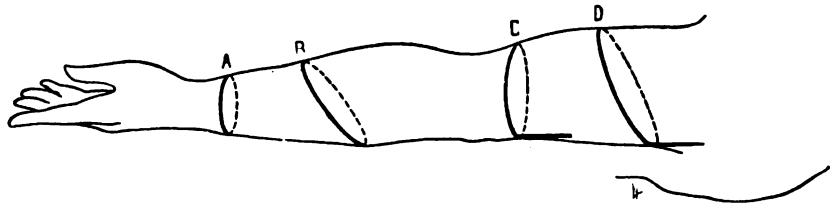

Fig. 237.—THE EVOLUTION OF AMPUTATION METHODS:—I—A, Transverse circular incision; B, Oblique circular incision; C, Transverse racket incision; D, Oblique racket incision. (Modified from Kocher.)

only practical difference between the two, as now usually employed, being that the queue is made longer in the racket method.

Oval Incision.—Formed by the shortening of the queue and the rounding-

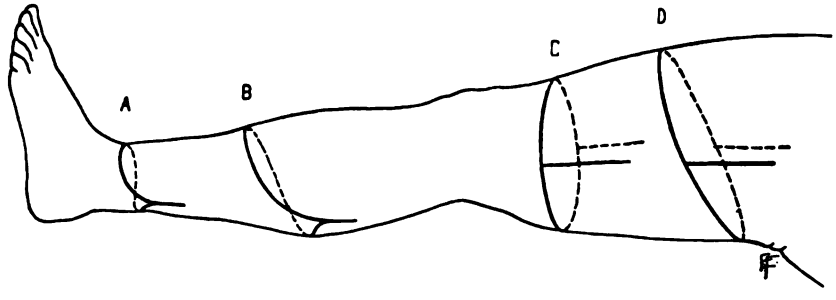

Fig. 238.—THE EVOLUTION OF AMPUTATION METHODS:—II—A, Transverse oval incision; B, Oblique oval incision; C, Equal rectangular flaps; D, Unequal rectangular flaps. (Modified from Kocher.)

off of the angles of the racket incision. (a) If the angles of the transverse racket incision be rounded, the transverse oval incision results (Fig. 238, A);

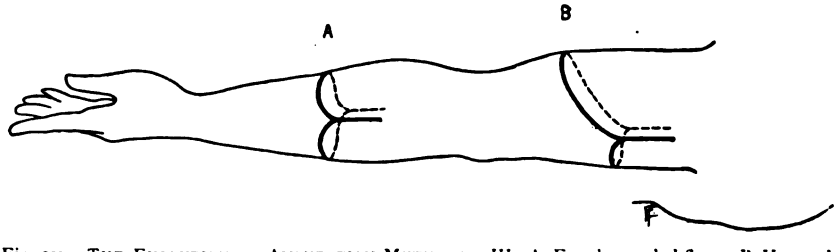

Fig. 239.—THE EVOLUTION OF AMPUTATION METHODS:—III—A, Equal rounded flaps; B, Unequal rounded flaps. (Modified from Kocher.)

(b) If the angles of the oblique racket incision be rounded off, the oblique oval incision results (Fig. 238, B).

Rectangular Flaps.—Formed by two longitudinal incisions. (a) If the two longitudinal incisions be added to the circular incision, equal rectangular flaps result (Fig. 238, C); (b) If they be added to the oblique circular incision, unequal rectangular flaps result (Fig. 238, D).

Rounded Flaps.—Formed by rounding the angles of the rectangular flaps. (a) If the angles of equal rectangular flaps be rounded, equal rounded flaps result (Fig. 239, A); (b) If the angles of unequal rectangular flaps be rounded, unequal rounded flaps result (Fig. 239, B).

Elliptical Method.—The position of this method, in the process of evolution, will be described further on (page 273).

SUMMARY OF AMPUTATION METHODS.

Fundamental Types.—Circular Method; Flap Method.

Modern Types.—(a) Circular and its modifications; (b) Flap and its modifications; (c) Irregular methods of amputation.

As to Nature of Covering of Stump.—All methods of amputation are either—(a) Skin Coverings—that is, skin and fascia alone cover the divided muscles and bone, as in the cuff method of the circular amputation, and in the simple skin-flap in the flap method of amputation;—or (b) Skin-and-muscle Coverings—where skin, fascia, and muscles, combined and unseparated, including the periosteum, cover the end of the bone, as in the ordinary (infundibuliform) circular amputation, and in flaps of skin and muscle in the flap method of amputation.

CIRCULAR METHODS OF AMPUTATING.

(a) Ordinary Circular Method—(amputation circulaire infundibuliforme);—(b) Cuff Method of Circular Amputation—(amputation *à la manchette*);—(c) Modified Circular Method of Amputation—(mixed method);—(d) Oval (or Lanceolate) Method;—(e) Racket Method.

ORDINARY CIRCULAR AMPUTATION.

(AMPUTATION CIRCULAIRE INFUNDIBULIFORME).

General Description.—The soft parts are divided by a series of circular cuts, retraction of the parts taking place between each circular sweep of the knife, so that they are cut partly through at different levels—the sawed bone forming the apex of the funnel left upon the proximal end of the bone, and the skin margin the base—the distal part removed being cone-shaped.

Technic.—Stand to outer side of right and inner side of left limbs, so as to grasp limb between trunk and amputation-site. Determine the saw-line. Fix the skin incision at a level below the saw-line equal to ½ of 1½ times the diameter of the limb (or three-fourths of that diameter) at the saw-line (that is, at 11.5 cm., or 4½ inches, below the saw-line, if the diameter of the limb at the saw-line be 15.3 cm., or 6 inches) (Fig. 240, A). Grasp the limb just above the line of the skin incision with the left hand and retract the skin upward, aided, if the limb be large, by an assistant. With a long knife, make a circular incision, at the skin-incision line, through skin and superficial fascia, entirely around the limb. Free skin with its superficial fascia from the muscles with their deep fascia, aiding

the separation in the interfascial line by touches with a scalpel, where necessary. Retract the skin and fascia evenly around the circumference of the limb. Divide the more superficial layer of muscles circularly, on a level with the retracted skin. Retract this more superficial layer of muscles. Divide the remaining deeper muscles circularly on a level with the retracted outer layer of muscles—and planning to come down upon the bone, or bones, far enough below the saw-line to allow of making a musculo-periosteal covering for the bone or bones. Retract the deeper muscles thus cut. Divide with a stout knife, the periosteum circularly around the bone, or bones, at a distance below the saw-line equal to a good one-half diameter of the bone

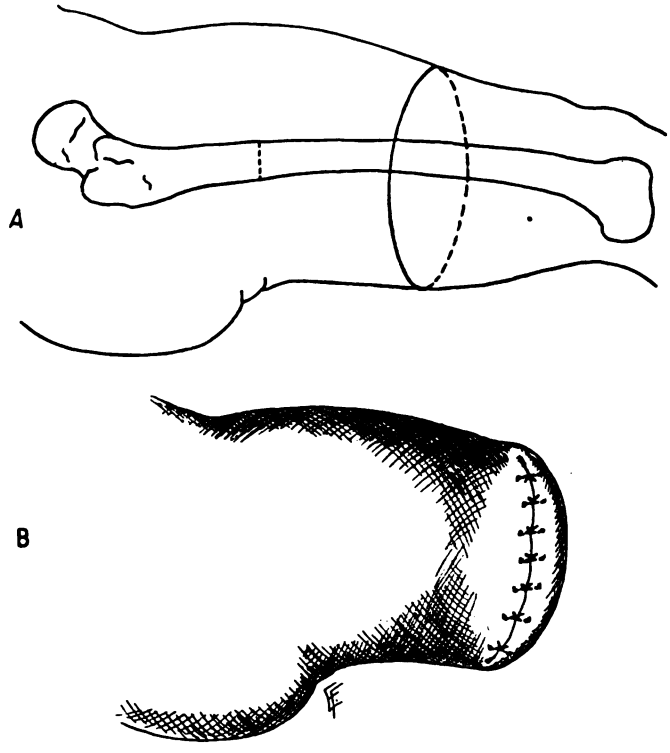

Figs. 240 and 241.—ORDINARY (INFUNDIBULAR) FORM OF CIRCULAR AMPUTATION:—A, Position of incision and bone-section; B, Resulting suture-line. The skin-incision and suture-line here are also applicable to the cuff variety of the circular method.

at the saw-line. Push up the periosteum from the bone with periosteal elevator—keeping the muscles adherent to the periosteum. Apply linen (or other) retractors to the soft parts and draw them above the saw-line. Saw the bone, or bones. If splintering occur, grasp the spicula with forceps and remove with finer saw. Allow the soft parts to drop over the end of bone, or bones, the sawed ends of which will form the apex of a funnel—the bone being covered by periosteum—periosteum by muscle—and muscle by fascia and skin (Fig. 242). Tie the vessels—cut the nerves and tendons short—and remove any tags of connective tissue or skin. Suture the musculo-periosteal covering over the end of bone, or bones. Quilt the

muscles together in one or two layers. Suture the skin and fascia antero-posteriorly (Fig. 241, B)—and apply the dressing and supporting splint.

Resulting Stump.—Evenly covered on all sides by muscle and skin —the bone being particularly well protected and on a higher level above the surface of the stump than in any other form of amputation. The scar is terminal—antero-posterior, if the wound be sutured from before backward,—lateral, if sutured from side to side (Fig. 241, B).

Indications.—In limbs more or less evenly surrounded by muscles:—lower part of forearm (sometimes), arm, and thigh.

Comment.—(1) Owing to unequal skin retraction in some localities (as the antero-internal aspect of the arm and thigh) the circular incision may have to be planned obliquely and only become circular after the incision —and may also have to be planned lower. (2) A pure ordinary circular (infundibuliform) amputation is impossible in a limb of rapidly increasing girth, as it is impossible to retract the soft parts. A single lateral vertical incision through skin and fascia, or double lateral incisions, may become necessary in order to free the parts—when it ceases to be a typical infundibuliform amputation.

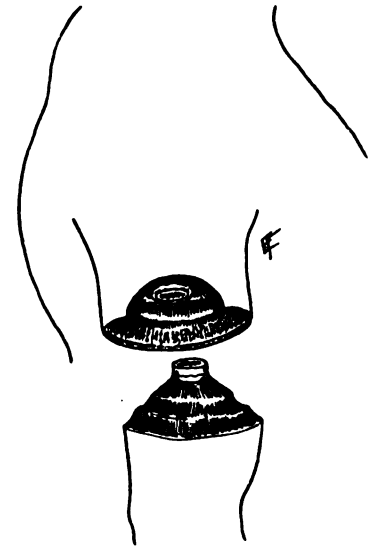

Fig. 242.—APPEARANCE OF THE PARTS FOLLOWING THE INFUNDIBULAR FORM OF CIRCULAR AMPUTATION:—A funnel-shaped cavity left proximally, and a cone-shaped mass distally.

CUFF METHOD OF CIRCULAR AMPUTATION

(CIRCULAR AMPUTATION À LA MANCHETTE).

General Description.—A circular division of the skin is made, which is turned over and upward upon itself as a cuff—and, upon a level with this retracted cuff of skin and fascia, the muscles are divided to the bone, generally with one circular sweep of a long knife.

Technic.—The steps of the operation are similar to those of the ordinary circular amputation (page 261) up to the completion of the circular incision through the skin and superficial fascia. The skin and subcutaneous tissue are then turned back upon themselves as a cuff—the freeing being done by means of the fingers of the left hand, aided by touches of a scalpel, until evenly retracted all around. On a level with the retracted cuff, the muscles are circularly divided down to the bone—the site at which this division takes place being such as will allow of ample and easy covering of the transversely divided muscle by the skin and fascia—an average calculation being that about one-third of the total distance from saw-line to line of skin incision should be given to skin and fascia alone. The subsequent steps of the operation, including the musculo-periosteal covering for the bone, being the same as for the ordinary, or infundibuliform, circular amputation.

Resulting Stump.—Apt to be more or less irregular in contour and not so well padded, owing to the nature of the parts used for covering. The scar lies as in the ordinary circular amputation (page 262).

Indications.—Most frequently used where the soft coverings are more tendinous than muscular:—wrist, lower part of forearm, ankle, and lower part of leg (in thin subjects).

Comment.—(1) and (2) The same comments made under (1) and (2) of the last operation apply equally here (page 263). (3) Owing to the greater proportion of skin in this covering and the division of muscles in one layer, as well as the number of tendons present in the sites where this method is generally used, the covering of the bones is not so satisfactory as in the ordinary circular method.

MODIFIED CIRCULAR AMPUTATION

(MIXED METHOD).

General Description.—Two equal flaps, composed of skin and fascia,

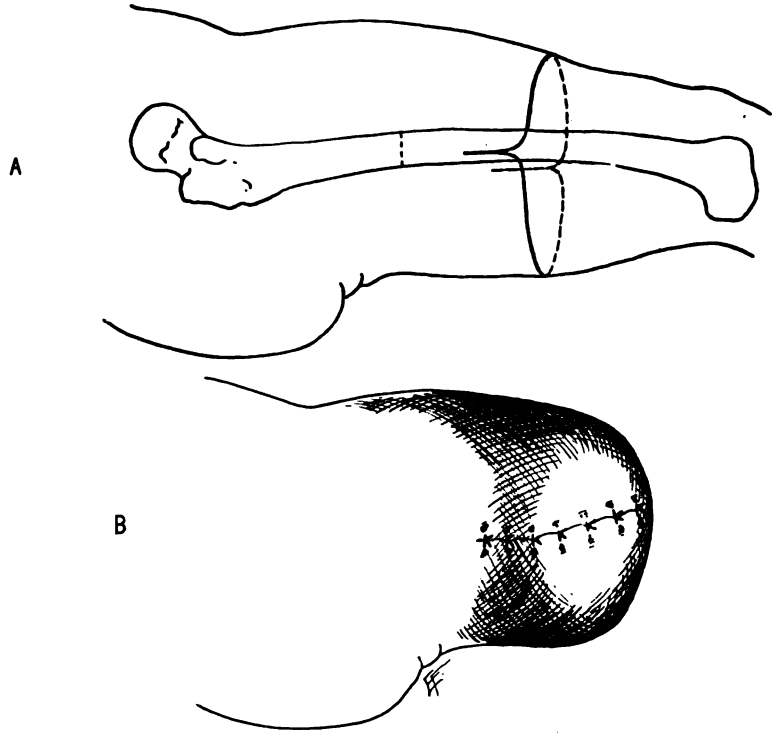

Figs. 243 and 244.—Modified Circular Method of Amputation (Applicable to Both) :—A, Position of incision and bone-section; B, Resulting suture-line.

of varying length, and having bases equal to one-half of the circumference of the limb at their upper ends, are cut and dissected up a short distance—followed by a circular sweep of the knife through the retracted superficial muscles—and by a second circular sweep at a higher level, through the retracted deeper muscles—and completion of the operation as in the ordinary circular amputation.

Technic.—Having fixed upon the saw-line, and having marked a point below the saw-line equal to ½ of 1½ diameters of the limb at the saw-line (that

is, three-fourths of the diameter at the saw-line), two equal flaps of skin and fascia (of this length) are planned. These flaps have bases equal to one-half the circumference of the limb at the level of their upper limit —and their length will be equal to one-third or one-half of the total distance between saw-line and lowest limit of skin-covering (generally one-third in slender, ill-formed limbs, and often one-half in large, tapering limbs). The flaps are usually lateral ones, but may be anterior or posterior (Fig. 243, A). Retracting the skin with the left hand, begin the incision at one mid-lateral aspect of the limb, at a level above the lowest limit of the skin incision equal to one-third or one-half (as the case may be) of the distance between the saw-line and the lowest limit of the skin incision—pass vertically downward, through skin and fascia, until nearly at the level of the lowest skin incision—thence round forward into the line of lowest skin incision, in a bluntly rounding manner—and complete the opposite end of the same flap in the same manner. Then make the opposite flap in the same way as the first one, corresponding in shape and size. Dissect these flaps of skin and fascia back to just beyond their bases. While the flaps, and the muscles also, are retracted, divide the more superficial muscles circularly—retract these, and divide the deeper muscles similarly—making the usual provision for the musculo-periosteal covering. The operation is completed as in the ordinary circular amputation—the skin and fascial flaps being sewed over the quilted muscles—the bone being at the apex of a funnel which is somewhat shallower than in the infundibuliform variety of circular amputation (owing to the muscles having been divided at a higher level).

Resulting Stump.—While not covering the end of the bone with quite as thick a padding of soft parts, its general features are the same as those following the ordinary circular method. The main part of the scar is terminal, but its ends are apt to be partly lateral (Fig. 244, B).

Indications.—This is the form of circular amputation most generally used and is adapted to a greater number of sites than the ordinary circular, or the cuff modification of the ordinary method.

Comment.—(1) The skin-flaps may be cut of unequal lengths. (2) The muscles may be divided at one level. (3) This form of circular amputation has largely replaced either of the other forms.

OVAL METHOD OF AMPUTATION.

General Description.—A modification of the circular method. The skin incision is in the form of an oval, with one of its ends more prolonged and pointed—the soft parts between skin and bone being divided by cutting from without inward—and the lips of the wound being sutured in a single line parallel with the long axis of the wound.

Technic.—This amputation being generally used in disarticulations, the upper or pointed end of the oval usually begins just above a joint-line and upon its outer or anterior aspect—the limbs of the oval parting at an angle sufficient to include the head of the distal bone—and sweeping thence in a curve down the lateral aspects of the limb—passing, finally, transversely toward each other—to meet upon the inner or under surface of the distal limb and at a distance beneath the line of articulation calculated to furnish sufficient covering for the head of the proximal one of the bones making up the joint (Fig. 245, A). Having completed the incision through skin and fascia, one of two courses may then be adopted;—(a) The incision may then be deepened

throughout direct to the bone, by cutting from without—the deep incision, from the point where the arms or limbs of the oval begin to diverge, following the line of the retracted skin. This is the general method in all of the smaller disarticulations and in most of the larger. (**b**) Or the joint may be opened by the more vertical part of the incision and, after disarticulation, the muscles may be cut from within outward, on a line with the retracted skin. Having tied the vessels, cut the nerves and tendons short, the wound is sutured in its long axis (Fig. 245, B)

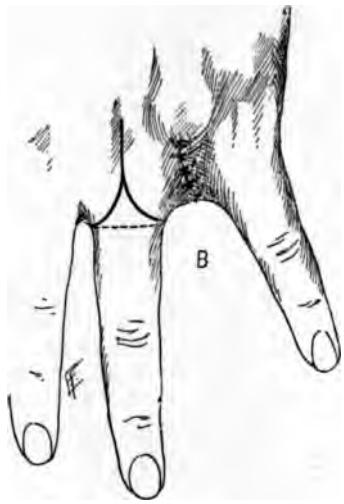

Fig. 245.—Oval Method of Amputation:—A, Form and position of oval; B, Resulting suture-line.

Resulting Stump.—The end of the bone is very fully covered except where the head or articular end of the proximal bone is disproportionately large. The scar is termino-lateral (Fig. 245, B).

Indications.—A form of amputation generally used for disarticulating a limb from the trunk, or a smaller limb from a larger limb. The method admits of first opening the joint for investigation before finally deciding upon amputation—and it also admits of securing the vessels before removing the limb.

Comment.—The suture-line may run antero-posteriorly in one straight line—or the free, lower convex border of the flap may be turned over and sutured to the upper angular concavity of the wound.

RACKET METHOD OF AMPUTATION.

General Description.—A modification of the circular method. The same, in principle, as the oval amputation—with the addition of a longitudinal vertical cut prolonged from the apex of the oval forming the "handle of a racket" — thus giving a better exposure of joints without sacrifice of tissue and securing a better covering for the bone in the upper part of the wound.

Technic. — Practically similar to the oval amputation, except that the queue of the racket begins considerably farther back over

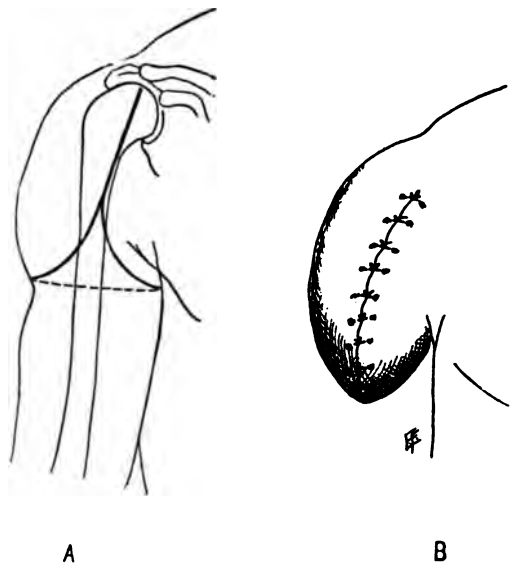

Figs. 246 and 247.—Racket Method of Amputation:—A, Form and position of incision; B, Resulting suture-line.

the head of the proximal bone forming the joint—and along this single straight line the knife travels some distance before the arms of the racket begin to diverge. After the beginning of the divergence of the limbs of the racket, the operation is completed as in the oval operation (Fig. 246, A).

Resulting Stump.—More satisfactory covering is secured by the racket than by the oval method of amputating. The scar is termino-lateral (Fig. 247, B).

Indications.—Disarticulations of the shoulder- and hip-joints, and of the digits from the hand and foot (especially, in the latter instances, where a metatarsal or metacarpal bone is removed with the digit). As in the oval method, but to a much greater extent, does the racket method admit of a preliminary examination of the joint through the vertical portion of the incision, before deciding upon amputation. The vessels may also be secured before entirely separating the limb. The muscles in the stump are better preserved.

Comment.—(1) The queue of the racket should be placed, if possible, over an intermuscular septum and be deepened in the septum. (2) Amputation by a T-shaped incision is, practically, a form of racket incision. (3) The suture line may run antero-posteriorly (or from the outer to the inner aspect of the part), which is to be preferred. Or the upper portion of the queue may be sutured in this manner and the lower convex portion of the flap brought up and sutured to the angular concavity formed by the divergence of the lateral limbs of the racket.

FLAP METHODS OF AMPUTATING.

(a) Single Flap of Skin and Muscles;—**(b)** Single Flap of Skin;—**(c)** Equal Flaps of Skin and Muscles;—**(d)** Equal Flaps of Skin;—**(e)** Unequal Flaps of Skin and Muscles;—**(f)** Unequal Flaps of Skin;—**(g)** Elliptical Method;—**(h)** Unequal Rectangular Flaps of Skin and Muscle.

AMPUTATION BY SINGLE FLAP OF SKIN AND MUSCLES.

General Description.—A method of amputating whereby the stump is covered with a single flap derived from one aspect of a limb—and consists of skin, fascia, and muscles. Such an amputation involves the maximum sacrifice of bone.

Technic.—Having fixed upon the saw-line (or line of disarticulation), a point is determined upon below this line, and on that aspect of the limb which is to furnish the flap, which will represent a distance below the saw-line equivalent to 1½ diameters of the limb at the saw-line. A flap is then marked out with a base equal in width to a half-circumference of the limb at the saw-line, and a length equal to 1½ diameters of the limb at that line. (Fig. 248, A). Grasping the limb as in the ordinary circular amputation, the knife is entered at the far upper end of the base of the flap, at a right angle to the skin—and passes vertically down the mid-axis of the limb to near the lower limit of the flap—where it forms a squarely or bluntly rounded corner to the flap—thence passes transversely along the lower limit of the flap—and completes the opposite limb of the flap symmetrically with the first limb. This incision passes through skin and fascia. When this integumentary flap has retracted, the muscles are cut obliquely on a line with its retracted edges, so directing the knife as to bluntly bevel the muscular portion as the knife cuts its way

from without inward and upward. This incision passes obliquely through all the muscles and is planned to come down upon the bone at a distance beneath the saw-line equivalent to a good diameter of the bone at the saw-line, thus providing for a musculo-periosteal covering. The knife is then carried through the periosteum so as to form a musculo-periosteal flap with a base of half the bone at the saw-line and once the diameter. The musculo-periosteal covering is then detached back to the saw-line. Divide the hitherto undisturbed soft parts on the opposite side of the limb by a circular sweep of the knife—passing through the skin and fascia of the half-circumference

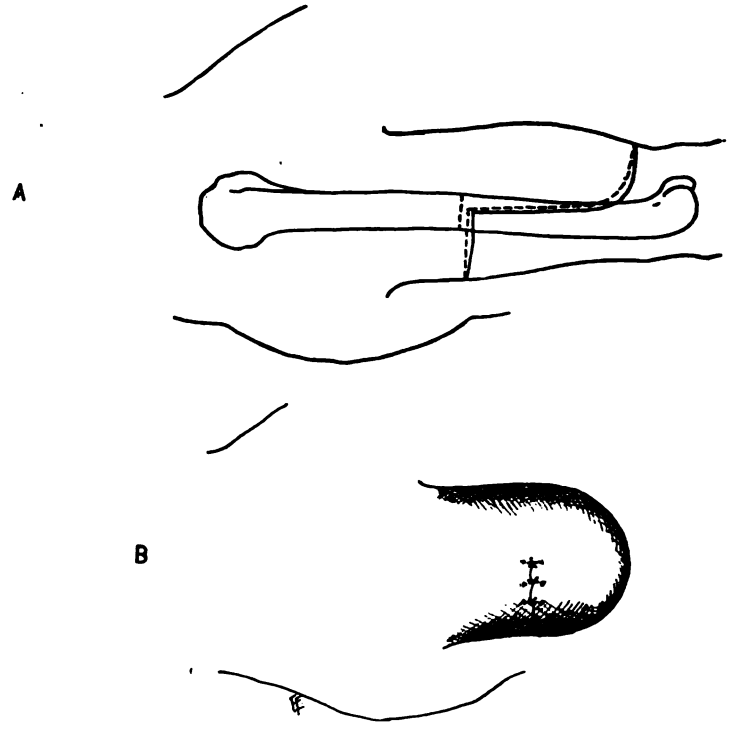

Figs. 248 and 249.—AMPUTATION BY SINGLE FLAP OF SKIN AND MUSCLE:—A, Form and position of incisions; B, Resulting suture-line.

a little below the level of the base of the single flap—and through the muscles on a level with the base of that flap, including the periosteum. Retract all the soft parts on the proximal side of the saw-line and divide the bone. Suture the musculo-periosteal flap over the bone, the free edge of the periosteal flap being sutured to the half-circumference of the opposite aspect of the bone. Quilt the lateral and terminal aspects of the cut muscles in the flap with the transversely cut ends of the muscles on the opposite side of the limb. Suture the terminal and lateral aspects of the skin of the flap to the transversely divided skin of the opposite side.

Resulting Stump.—The stump is at first well covered with muscle—and, when this atrophies, by the replacing fibrous tissue. The scar is lateral (Fig. 249, B).

Indications.—Cases of injury so destroying the soft parts as to leave those of but one aspect available. Also in such cases as Farabeuf's amputation of the upper third of the leg by a single external flap of skin and muscles, or Dubreuil's disarticulation at the wrist by a single external flap of skin and muscles.

Comment.—(1) In all flaps, skin must be longer than muscle. (2) There is sometimes an excess of muscle in a flap, part of which should be removed in the process of beveling—but a fully muscled flap is generally desirable. (3) A flap of skin and muscle is more apt to live and makes a better covering than one of skin alone. (4) While the muscle tissue as such may not remain in the tissues of a stump, the muscle-fibers undergoing atrophy, yet the fibrous tissue matting and padding together of the parts is left in its place. (5) A single flap requires the maximum sacrifice of limb, one side of the limb furnishing the entire covering and the bone being consequently divided at a higher level.

AMPUTATION BY SINGLE FLAP OF SKIN.

General Description.—The features of this operation are practically the same as those of the amputation by a single flap of skin and muscles, except that the covering here consists entirely of skin.

Technic.—Having incised through skin and fascia, this integumentary flap is dissected up from the muscles throughout, including all overlying fascia, and is retracted above the saw-line (or disarticulation-line)—when the bone is sawed or disarticulated, and the flap dropped over the end of the limb—its terminal aspect being sutured to the transversely divided skin of the opposite side.

Resulting Stump.—Very thinly covered, but as the skin so utilized is generally accustomed to pressure, the result is usually satisfactory.

Indications.—Such localities as the knee-joint (disarticulation by a single anterior flap), or the elbow-joint (disarticulation by a single posterior flap).

Comment.—(1) As this method is generally used in a disarticulation, a capsulo-periosteal rather than a musculo-periosteal covering is provided. (2) Nutrition of a single flap of skin and muscle is more difficult to maintain than in the more ordinary methods—and the nutrition of a flap of skin alone is even harder. (3) Skin-flaps are more used now than formerly because, owing to rarer suppuration, their vitality can be more counted upon.

AMPUTATION BY EQUAL FLAPS OF SKIN AND MUSCLE.

General Description.—Coverings for the stump are gotten from two opposite aspects of the limb in the form of two flaps composed of all the soft parts covering the limb—having equal bases and lengths—and the allowance of skin being sufficiently in excess to well cover the muscles.

Technic.—The preliminaries being the same as in the ordinary circular amputation, two flaps are marked out, each having a width of base equal to the half-circumference at the saw-line and a length equal to three-fourths of the diameter of the limb at that same line (Fig. 250, A). With a large scalpel, incise along the outlined flaps, passing through skin and connective tissue. When these integumentary flaps have retracted, proceed to form the remainder of the flaps—cutting obliquely along the margin of the retracted skin, in such

a manner that the flaps will be bluntly (not thinly) beveled, directing the knife so that the beveling will be greatest (though not thin even here) at the tip, and thickest toward the base—and coming down upon the bone, or bones, a distance below the saw-line equal to a full diameter of the bone (or of the bigger bone) to allow for musculo-periosteal covering. At this level make a circular cut around the bone through the periosteum with a heavy knife —detach the musculo-periosteal covering of the bone upward to the saw-line —retract the soft parts—divide the bone—suture the musculo-periosteal covering—quilt the muscles—and suture the skin.

Resulting Stump.—As a rule, excellently covered by substantial tissues. The scar is termino-lateral (Fig. 251, B).

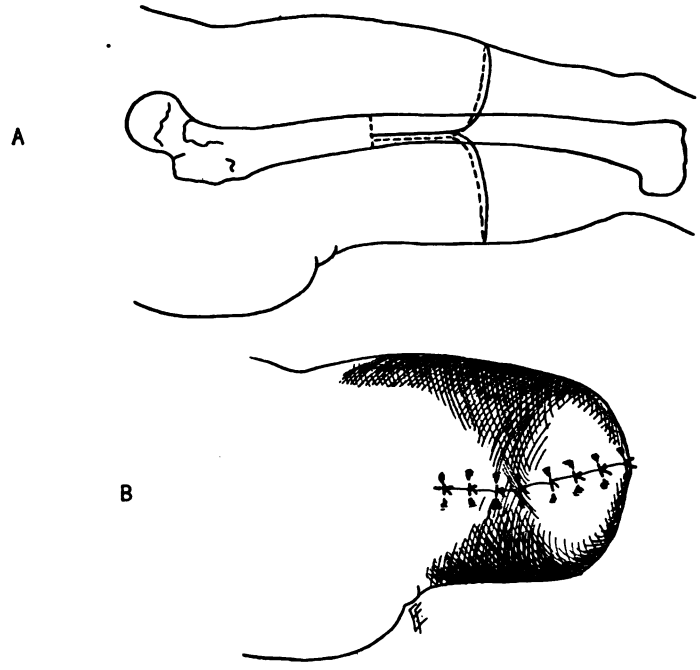

Figs. 250 and 251.—AMPUTATION BY EQUAL MIXED FLAPS:—A, Form and position of incisions; B Resulting suture-line.

Indications.—In the continuity of limbs (between joints) where the bone or bones are equally covered with soft parts.

Comment.—(1) The simplest form of making double flaps is by two vertical incisions down the opposite sides of what has been begun as a circular method. (2) One flap may be cut from without inward, and the other by transfixion. (3) In very muscular limbs it makes the meeting of skin over muscles easier if about 2.5 cm. (1 inch) of skin and fascia are dissected up from the muscle, after marking out and dividing the skin and fascia, and then cutting the muscles to the bone in a beveling fashion.

AMPUTATION BY EQUAL FLAPS OF SKIN.

This operation is the same, in general contour and dimensions of the flaps, as the last—except that the covering here consists of skin only.

Technic.—Having incised through skin and fascia, upon the same lines as in the last form of amputation, the two equal flaps of integumentary tissues are dissected up to a level below the saw-line which will allow of providing a musculo-periosteal covering—at this level the muscles, after retracting the skin, are circularly divided down to the bone—this circular incision is continued, on the same level (one-half diameter of the bone below the saw-line) around and through the periosteum—the periosteum is then retracted, with the overlying muscles, to the saw-line—and the bone divided. The musculo-periosteal covering is then sutured over the bone—and the skin margins sutured together.

Resulting Stump.—Thinly covered, no muscle being present—but is generally satisfactory in the localities where adopted. The scar is terminolateral.

Indications.—Where a satisfactory muscle covering is hard to secure—as in the lower third of the forearm and leg and in the fingers—the tendons predominating in these localities.

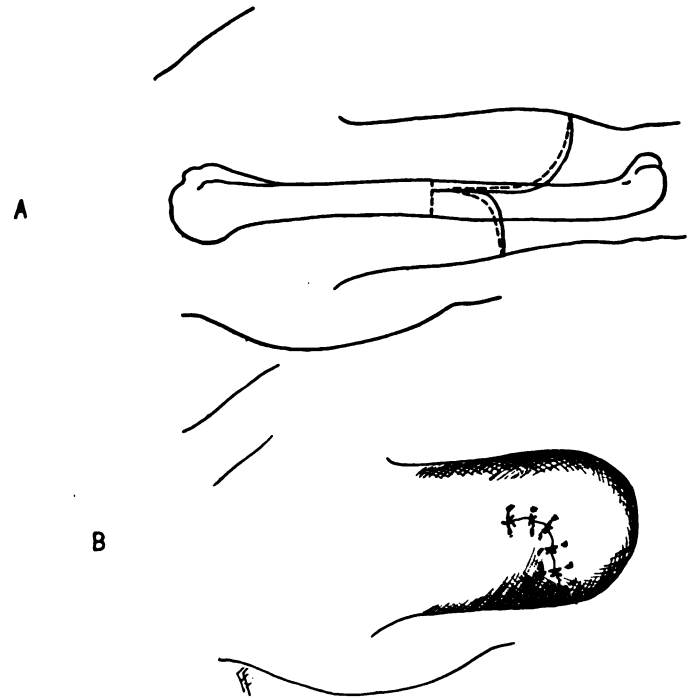

Figs. 252 and 253.—AMPUTATION BY UNEQUAL MIXED FLAPS:—A, Form and position of incisions, and line of bone-section; B, Resulting suture-line.

AMPUTATION BY UNEQUAL FLAPS OF SKIN AND MUSCLES.

General Description.—Coverings are furnished by two flaps taken from opposite aspects of the limb—each flap having a base equal to one-half circumference of the limb at the saw-line—and one flap having a length greater than the other. One flap usually furnishes one-third or two-thirds of the covering, and the opposite flap two-thirds or one-third—the longer

flap generally coming from that aspect of the limb most thickly muscled. The flaps may bear any relation to each other in relative length—but the two flaps combined furnish a covering equivalent to 1½ diameters of the limb at the saw-line.

Technic.—This amputation is identical, except as to the length of the flaps, with the amputation by equal flaps of skin and muscle (Fig. 252, A).

Resulting Stump.—Generally well covered. With scar either entirely lateral or partly lateral and partly terminal, dependent upon the preponderance of one flap over the other (Fig. 253 ,B).

Indications.—Thigh and arm throughout, and upper parts of forearm and leg.

AMPUTATION BY UNEQUAL FLAPS OF SKIN.

General Description.—Coverings are of skin and fascia alone and are furnished by the two opposite aspects of the limb, in the form of two flaps having equal bases and unequal lengths. This amputation is identical throughout with the amputation by equal flaps of skin, except as to the length of the flaps.

AMPUTATION BY UNEQUAL RECTANGULAR FLAPS OF SKIN AND MUSCLES.

TEALE'S METHOD.

General Description.—The general method of performing this operation is similar, in principle, to that for amputation by unequal flaps of skin and muscles—with the exception that the flaps are rectangular (instead of rounded) and of special dimensions.

Technic.—Having fixed upon the saw-line, two flaps are marked out, having their bases at that line and extending downward as described below. Find the circumference of the limb at the saw-line. The longer flap is to have its length and its breadth equal to a half-circumference at the saw-line. The shorter flap is to be one-fourth of the length of the longer, and its breadth equal to the remaining half-circumference at the saw-line. The longer flap should be of the same width all the way down. The shorter flap will have a width at its free end equal to very nearly a half-circumference of the limb at the level where it terminates (as that level, in the case of the shorter flap, is so short a distance beneath the saw-line) (Fig. 254, A). Having marked out these flaps, which should be accurately measured, the vertical parts of the incision should be made from above downward, connected at their lower ends by the transverse incision which marks the limit of the longer flap, and by another transverse incision across the opposite half-circumference of the limb, at the proper level, marking off the lower limit of the shorter flap. These incisions at first involve skin and fascia only. When retraction has occurred (making a difference in the transverse incisions only), they are deepened throughout to the periosteum. The vertical limbs of the flaps are first cut to the periosteum—then the lower transverse limit of the longer flap, which is dissected up above the lower limit of the shorter flap—which in turn is cut transversely to the periosteum and dissected up. When a level below the saw-line is reached equal to a half-diameter of the bone at the saw-line, a circular incision is made through the periosteum and a musculo-periosteal covering raised. All the soft parts are now retracted above the saw-line and the bone divided. The musculo-periosteal covering is sutured. The longer flap is bent over

the end of the bone—its end being sutured to the end of the shorter flap—the lateral aspects of the shorter flap are sutured to the lateral aspects of the longer—and the lateral aspects of the bent-over portion of the long flap are sutured to the contiguous lateral aspects of the unbent portion of the long flap. The muscles are quilted prior to suturing the skin. The part is well supported by splint, with only light pressure over the bent longer flap.

Resulting Stump.—An H-shaped cicatrix is formed upon the aspect of the limb furnishing the shorter flap. The end of the bone is well covered when the long flap contains a preponderance of muscle—less well covered when containing a preponderance of tendons (Fig. 255, B).

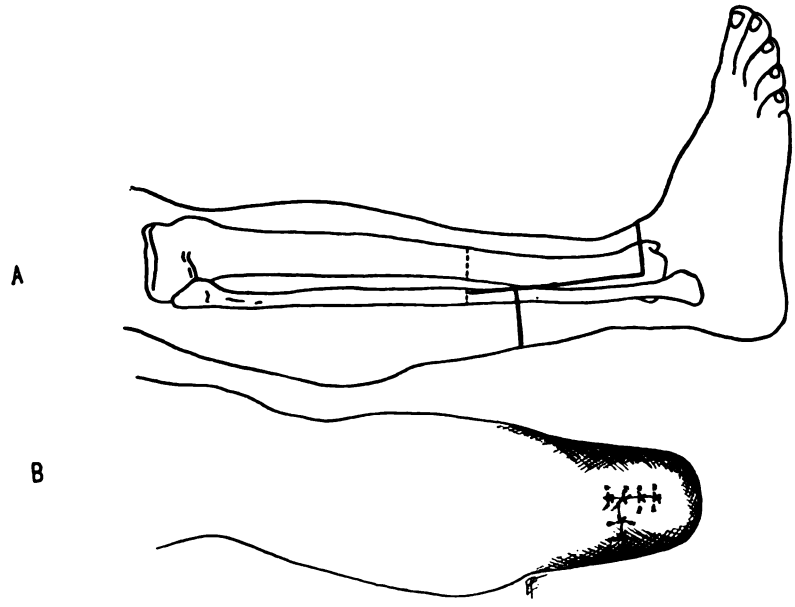

Figs. 254 and 255.—AMPUTATION BY UNEQUAL MIXED RECTANGULAR FLAPS:—A, Form and position of incisions, and line of bone-section; B, Resulting suture-line.

Indications.—In the lower part of the leg (where the longer flap is taken from the anterior aspect)—and sometimes in the lower forearm (where the longer flap comes from the posterior aspect).

ELLIPTICAL METHOD OF AMPUTATION.

General Description.—This is not a distinct form of amputation. It may be considered a variety of the circular method (an oblique circular), or, equally, a variety of single-flap amputation—and may be held in an intermediate position. It is circular, as to skin incision; and flap, as to its manner of covering the stump and in the suturing. The skin incision is in the form of an ellipse, or a lozenge, the upper part of the ellipse being upon one aspect of the limb and the lower part upon the opposite—the lateral limbs of the figure crossing the lateral aspects of the limb to be amputated.

The idea of the ellipse is brought out by imagining the outline projected upon a flat surface.

Technic.—Having fixed upon the saw-line (or line of disarticulation), a point is determined above this, on, say, the posterior aspect of the limb, which is just above the saw-line—this becomes the highest point of the ellipse. The point marking the lowest point of the ellipse is placed upon the opposite side of the limb, at a distance below the saw-line equal, approximately, to 1½ diameters of the limb at the saw-line (as there is but this one source of covering). Between these two points the lateral limbs of the ellipse pass, crossing the lateral aspects of the limb to be operated obliquely, from above downward, and so planned as to give a well-rounded convex termination of the ellipse below to be brought up and fitted into a corresponding concavity above (Fig. 256, A). The incision first passes around the outline of the ellipse, through skin and fascia only. Around the lower three-fourths of the line of this retracted skin and fascia a second incision passes through the muscles to the bone. The soft parts (skin and muscles) forming the lower part of the ellipse (the part that is to remain attached to the limb which is to be retained) are now dissected up from the bone to a point sufficiently below the upper limit of the ellipse to allow a musculo-periosteal or capsulo-periosteal covering to be raised, and then on up to just below the upper limit of the ellipse (that is, to the saw-line or line of disarticulation). This large single mass of soft parts is well retracted—and the muscles on that aspect of the limb opposite to the one furnishing the muscles in the elliptical covering are circularly divided—and the limb sawed, or disarticulated, preserving the periosteum in the usual way. The lower convexity of the elliptical flap is now sutured into the upper concavity left by the part of the limb removed—the musculo-periosteal, or capsulo-periosteal, covering and the muscles being treated in the general manner by buried gut sutures—and the skin wound closed.

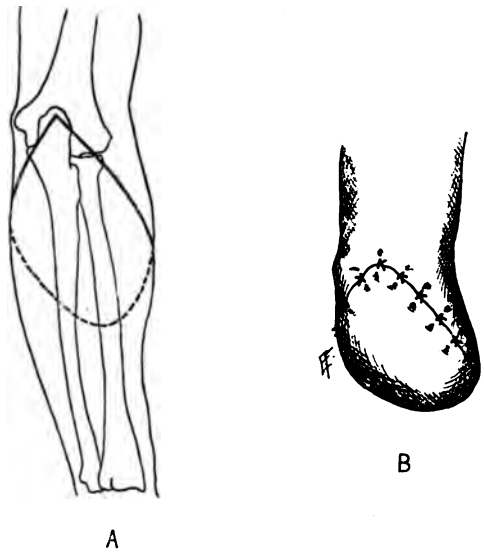

Figs. 256 and 257.—AMPUTATION BY THE ELLIPTICAL METHOD:—A, Form and position of incision; B, Resulting suture-line.

Resulting Stump.—The ellipse is generally taken from a locality which affords a plentiful covering for the extremity, which is thus well provided for. The scar is lateral (Fig. 257, B).

Indications.—Chiefly used for disarticulations—especially at the elbow and wrist, and in the supramalleolar amputation.

Comment.—The muscle-portion of the ellipse may be cut also by transfixion, though, as usual, less satisfactorily.

IRREGULAR METHODS OF AMPUTATION.

This is a special feature of modern-day surgery. Formerly amputations were done upon hard and fast lines. Now there is a marked tendency to allow the method of amputation to be determined by the special features and need of the individual case—and, as a result, irregular amputations are more commonly done, which, while accomplishing the general indications, are not bound by any set rule, shape, or measurement. The practical surgeon, therefore, should, on common-sense ground, adapt his method of amputation to the case in point, rather than be bound by any fixed form of amputation. The greatest field for irregular forms of amputation is in cases of injury and deformity, rather than in disease.

SELECTION OF AMPUTATION METHOD.

Many considerations enter into the determination of the best method of amputation in a particular case—and the choice should be given to that method which promises to fulfil the greatest number of the following features;—

Characteristics of Good Amputation Methods.—(1) Minimum sacrifice of healthy tissue—(2) Best permanent bone-covering—(3) Small wound area—(4) Good blood-supply to stump—(5) Favorably placed cicatrix—(6) Efficient drainage—(7) Simplicity of method—(8) Vessels and muscles cut transversely—(9) Possibility of getting satisfactory musculo-periosteal covering —(10) Ease of exposing bone at saw-line—(11) Ease of bringing soft parts together over bone without tension—(12) Adjustability of artificial limb—(13) Largest range of adaptability—(14) Shapeliness of resulting stump—(15) Rapidity of method.

Comment.—Circumstances may determine the selection of an amputation method known in advance not to be the best—for instance, owing to the increased mortality in approaching the trunk, a limb may be removed, in a case where the vitality of the patient demands that every chance be given him, at a level which, while increasing his chances for life, may not furnish the best covering. Again, in amputating about the hand, it may conserve the interest of the patient better to be satisfied with even a partial flap and allow the remainder to heal by granulation, rather than remove an additional ½ cm. (¼ inch) of an important finger. Rapidity of method used to be the chief consideration, but is now the last in importance, except in special instances—other considerations taking precedence—the operation being done with deliberation and precision.

Features of the Circular Method of Amputating.—(1) Minimum sacrifice of bone and soft parts of any method.—(2) Bone especially well covered in the infundibuliform variety. Conical stump sometimes follows retraction, especially in the cuff and modified varieties of the circular.—(3) Smallest wound area of any method.—(4) Tissues of stump well supplied with blood.—(5) Cicatrix terminal.—(6) Efficient drainage when sutured antero-posteriorly.—(7) Most simple of any method.—(8) Main vessels and muscles cut transversely.—(9) Musculo-periosteal covering well provided. —(10) Exposure of bone at saw-line not always easy.—(11) Not always easy to bring soft parts together over bone.—(12) Terminal cicatrix favorable for hollow artificial limbs; unfavorable for solid limbs of lower extremity.—(13) Unfavorable for amputation following injury involving the aspects of

the limb to unequal heights.—(14) Somewhat greater tendency to become conical.—(15) Most rapid of any method.

Features of the Flap Method of Amputating.—(1) Greater sacrifice of bone and soft tissues (especially in unequal flaps).—(2) Coverings of bone can be more largely regulated to suit demand. Conical stumps less apt to follow than after the cuff and modified forms of the circular.—(3) Greater wound area.—(4) In long flaps the blood-supply may not be so satisfactory.—(5) Terminal or termino-lateral cicatrix—can be planned as desired.—(6) Drainage as efficient as in the circular if the flaps be lateral. Not so efficient if the flaps be antero-posterior.—(7) Not so simple as the circular.—(8) Muscles divided obliquely; vessels also, and latter may be split up.—(9) Musculo-periosteal covering well provided.—(10) Bone easily exposed at the saw-line.—(11) Flaps easily brought together over bone.—(12) Terminal cicatrix favorable for any hollow artificial limb. Terminal portion of termino-lateral cicatrix pressed upon by solid lower limb, and lateral portion pressed upon by any hollow artificial limb.—(13) Favorable for amputations following injury involving the aspects of the limbs unequally. Adaptable to any part of any limb.—(14) Stump apt to be more shapely than that of the circular.—(15) Less rapid than the circular.

Circumstances Influencing Death-rate After Amputation.—The death-rate is greater;—(1) The nearer the amputation is to the trunk—(2) In the lower than in the upper limbs—(3) For injury than for disease—(4) In men than in women—(5) Between the ages of five to fifteen than before or after.

THE AMPUTATION STUMP.

QUALITIES OF A GOOD STUMP.

Firm in consistency—well covered—insensitive—of regular and symmetrical contour. The death-rate and the quality of the stump determine the success of any form of amputation. The following features are characteristic of a good stump—and also indicate the changes which follow successful amputation:—

Skin.—Not adherent, except at cicatrix. Capable of withstanding (and, preferably, accustomed to withstand) pressure. Plentifully supplied with blood.

Muscles.—The muscles of a stump are not retained as such—the muscle tissue disappears in greater part and is replaced by fibrous tissue. Exceptionally some muscle tissue remains and continues to function. The mass of fibrous tissue which replaces it, however, serves a useful purpose in padding over the end of the bone. In brief, muscle tissue tends to decrease—and fibrous tissue to increase. Muscles and tendons either become incorporated in the cicatrix, form new attachments to bone, or retract out of the way.

Bone.—The ends of the bones become rounded and the medullary canals closed by fibrous tissue. The end of the bone may either dwindle and atrophy, or the periosteum may, exceptionally, deposit an excess of bone. The shaft of the bone in an amputated limb also atrophies somewhat.

Cartilage.—Following a disarticulation, the articular cartilage left atrophies and sometimes entirely disappears.

Nerves.—Also atrophy to a greater or less extent. The ends generally become bulbous, but give no trouble unless they become adherent to bone or cicatrix.

Vessels.—Share in the general atrophy, and dwindle to a size commensurate with the parts to be supplied. Ligated trunks become obliterated to their nearest branch. Collateral circulation is established.

CHARACTERISTICS OF A BAD STUMP.

In contradistinction to the general qualities of a good stump, a bad stump may be flaccid, scantily covered, sensitive, of irregular contour—and may be further characterized by the following conditions:—

Skin.—Thin, scanty, tightly drawn, adherent, puckered—cold or purple from improper circulation—ulcerated from the same cause, or from trophic changes—involved with corns—and may become malignant.

Muscles.—See the changes mentioned in the last section.

Connective Tissue.—Bursæ may form.

Bone.—Osteitis, periosteitis, and necrosis may occur.

Two special forms of bad stump are met:—

Painful Stump.—May be due to osteitis or periosteitis—but is generally due to compression of the nerve. The nerve may be directly pressed upon by new bone or fibrous tissue—may be stretched over the stump—or may be the seat of neuritis. The end of a painful nerve is generally bulbous—but not necessarily—for often normal-looking nerve-ends are sensitive, and bulbous ones non-sensitive.

Conical Stump.—The end of the bone forms the apex of a cone which may be the result of one or more of the following causes—(1) Flaps cut too short—or bone too long.—(2) Sloughing or suppuration of the soft parts.—(3) Post-operative contraction of muscles.—(4) Growth of the bone from an active epiphysis in the young.

Comment.—Unfavorable changes are less apt to occur in case of primary union than in the reverse.

CONDITIONS INFLUENCING VITALITY OF STUMP.

(1) Blood-supply—full or scant, impeded or unobstructed by position of stump-covering.—(2) Compression by bandage, dressing or splint.—(3) Tightness and unnatural position of flaps, as compared with easy and natural position.—(4) Full allowance of skin and non-separation of skin from muscle, as compared with the reverse.—(5) Long and loose tendons and aponeuroses. (6) Too rapid sawing of bone.—(7) Finally, site of amputation, manner of performing the operation, prior local condition, prior constitutional condition, and after-treatment—all influence the vitality of the stump.

Comment.—The chief dangers to be avoided, are—over-tension in the skin and muscle covering—insufficient blood-supply—rough projections of bone and laceration of the parts—and inclusion of nerves in the cicatrization.

CONTRACTILITY OF THE TISSUES OF THE STUMP.

Skin.—The average contractility of the skin is equivalent to about one-third of its length. It is most contractile where thinnest—where the subcutaneous tissue is least—where its attachment to underlying parts is least—where it is least stretched by movements—and where the process of healing has been longest. It is least contractile where the opposite conditions exist.

Muscles.—The extremes of muscular contractility vary from a sligh separation of divided parts up to a retraction of four-fifths of their lengt Contractility is primary, where it occurs at the time of the operation—an secondary, where it occurs subsequent to the operation. Muscles contrac most—which are freest between origin and insertion—which have lon fibers—and where the process of healing has been longest. The larger th muscle, the greater the amount left in the flap, and the younger and healthie the subject, the greater the contraction. Muscles contract least where th conditions are the reverse of those just mentioned.

Skin, Fascia, and Muscles.—The average contractility of the mixe tissues of a flap, or covering, is generally equivalent to about one-third o the length of the flap, or covering. Additional length, however, should b allowed, in calculating the length of coverings—(1) When the transverse section of the bone is large as compared with the transverse section of th soft parts—(2) When the amputation is considerably below the origin of th muscle involved—(3) When secondary retraction is expected.

POSITION OF STUMP-CICATRICES.

The cicatrix should be so placed as to be the least exposed to pressure after the healing of the wound.

With Reference to Their Position.—Scars may be Terminal—at th end of the stump;—Lateral—on one or more sides of the stump;—Termino lateral—occupying the end and side of the stump.

With Reference to Their Production.—The following methods of amputation produce the following kinds of scars;—Circular is followed by terminal scar;—Elliptical, by lateral scar, if the ellipse be oblique, and terminal if the ellipse be nearly horizontal;—Oval, by termino-lateral;—Racket, by termino-lateral;—Single flap, by lateral scar;—Double flap, by terminal scar, if the flaps be equal, and lateral if the flaps be unequal.

Comment.—(1) Other things being equal, that method of amputation should be chosen which will bring the scar in the most favorable position for that particular case—and especially with reference to the subsequent functioning of the stump and its adaptability to an artificial limb. (2) In amputating in some situations the muscles of one group being so much stronger than those of another, will often draw a scar, terminal at the time of operation, much higher up upon one aspect than it will be drawn on the opposite aspect. Calculations for such an occurrence have, therefore, to be made.

FUNCTION OF AMPUTATION STUMPS.

In the Upper Extremity.—The chief function of the stump in the upper extremity is range of movement and power to wield an artificial limb, rather than to bear pressure and weight. As the chief pressure of an artificial limb comes upon the lateral aspects of the stump, the scar of the stump in the upper extremity is best when terminally placed.

In the Lower Extremity.—The chief function of the stump in the lower extemity is to bear pressure and weight. As the chief pressure of a solid artificial limb comes upon the end of the stump, the scar of the stump in the lower extremity is best when laterally placed—in those cases in which a solid artificial limb is to be worn. As, however, most modern artificial

limbs for the lower extremity, for the better classes, are hollow, there is not now made the same difference as formerly.

The Modern Type of Artificial Limb.—While the above was particularly true of the older, cruder forms of artificial limbs (and is still true of the peg-leg), the modern forms of artificial limbs are nearly always made upon the basis of a light, hollow cone, and are so adjusted as to largely adapt themselves to the conditions found—and, generally speaking, most of the pressure is of the lateral aspects of the stump and living limb against the sides of the hollow cone of the artificial limb—so that pressure is exercised upon the lateral aspects of the living stump and limb rather than upon the end—and in the lower as well as in the upper extremity.

Comment.—A function of the stump of the upper extremity, especially about the hand, and more particularly of a woman, is to be as symmetrical and shapely as possible, in the case of partial sacrifice of that member. While in the case of a laborer it would certainly be better to sacrifice appearance to strength and utility, one might be urged to sacrifice strength for appearance in the case of a woman of the non-working class.

AMPUTATIONS AND DISARTICULATIONS OF THE UPPER EXTREMITY.

SURGICAL ANATOMY OF THE FINGERS.

Bones.—Third, second, and first phalanges of the fingers;—and second and first phalanges of the thumb.

Articulations and Ligaments.—(a) Second Interphalangeal Articulations; anterior; two lateral; capsule. Posterior ligament not present—place supplied by united tendons of extensor communis digitorum and extensor indicis, for index;—extensor communis digitorum for middle and ring;—united tendons of extensor communis digitorum and extensor minimi digiti, for little finger. (b) First Interphalangeal Articulations;—anterior (glenoid); two lateral; capsule. Posterior ligament not present—place supplied by extensor longus pollicis (extensor secundi internodii pollicis) for thumb;—united tendons of extensor communis digitorum and extensor indicis, for index;—extensor communis digitorum, for middle and ring;—united tendons of extensor communis digitorum and extensor minimi digiti, for little finger. (c) Metacarpo-phalangeal Articulations;—anterior; two lateral; capsule. Posterior ligament—not present as distinct ligament—place supplied by scattered fibers from one lateral ligament to opposite lateral ligament; extensor brevis pollicis (extensor primi internodii pollicis); extensor longus pollicis (extensor secundi internodii pollicis), for thumb;—and the same ligaments for the other fingers as those for the first interphalangeal joints.

Sesamoid Bones.—Two on palmar surface of metacarpo-phalangeal joint of thumb, developed in inner and outer heads of flexor brevis pollicis, which here replace the anterior ligament. One or two on palmar surface of metacarpo-phalangeal joint of index and little fingers. Rarely one on palmar surface of metacarpo-phalangeal of middle and ring fingers. Rarely one on palmar surface of interphalangeal joint of thumb.

Muscles and Tendons.—(A) Of Fingers in General;—(a) On palmar aspect;—flexor sublimis digitorum; flexor profundis digitorum. (b) On dorsal aspect of index;—united tendons of extensor communis digitorum and extensor indicis; first dorsal interosseous (abductor indicis). On dorsal aspect of middle finger;—extensor communis digitorum; second dorsal

interosseous; third dorsal interosseous. On dorsal aspect of ring finger;—extensor communis digitorum; fourth dorsal interosseous; second palmar interosseous. On dorsal aspect of little finger;—united tendons of extensor communis digitorum and extensor minimi digiti; fourth lumbrical; third palmar interosseous. (c) On ulnar aspect of little finger;—abductor minimi digiti; flexor brevis minimi digiti. (B) Of Thumb;—(a) On palmar aspect;—flexor longus pollicis. (b) On dorsal aspect;—extensor brevis pollicis (extensor primi internodii pollicis); extensor longus pollicis (extensor secundi internodii pollicis). (c) On radial aspect;—abductor pollicis; outer head of flexor brevis pollicis. (d) On ulnar aspect;—inner head of flexor brevis pollicis; adductor obliquus pollicis; adductor transversus pollicis.

Sheaths (Thecæ).—Processes of palmar fascia extending down fingers from palm of hand to bases of last phalanges, being attached to lateral margins of first phalanges, and forming sheaths for flexor tendons.

Synovial Membranes.—(a) Of index, middle, and ring fingers;—extend from base of last phalanges up to bifurcation of palmar fascia, namely, about opposite necks of metacarpals (corresponding, approximately, to middle crease on palm of hand, for index, and to lowest crease for middle and ring). (b) Of thumb and little finger;—extend from base of last phalanges to and into great synovial sac of hand.

Nails.—Overlie the soft parts covering the distal two-thirds of the last phalanges on their dorsal aspect.

Arteries.—(a) Palmar Supply;—Four palmar digital branches of superficial arch; radialis indicis of deep arch; princeps pollicis of deep arch. (b) Dorsal Supply;—Second and third dorsal interosseous branches of posterior radial carpal branch of radial; first dorsal interosseous (metacarpal) branch of radial; dorsalis indicis branch of radial; dorsalis pollicis branch of radial.

Veins.—(a) Superficial;—digital (one on each side). (b) Deep;—venæ comites.

Lymphatics.—One lymphatic vessel on dorsal and one on palmar aspect of each side of each finger.

Nerves.—(a) Median supplies—thumb, index, middle, and ring fingers. (b) Ulnar supplies—ring, little, and middle (sometimes). (c) Radial supplies—thumb, index, middle, and ring.

SURFACE FORM AND LANDMARKS OF THE FINGERS.

The proximal ends of the phalanges form the knuckles—and therefore the joint-line is beyond the knuckle. The interphalangeal joint-lines are found, with approximate accuracy, by flexing the distal phalanges at a right angle with the proximal phalanges (or metacarpals)—and then prolonging the mid-lateral axis of the proximal bone forward—this line will pass through the center of the joints. More accurately, the last interphalangeal joint is 2 mm. ($\frac{1}{12}$ inch), the first interphalangeal joint 4 mm. ($\frac{1}{6}$ inch), and the metacarpo-phalangeal joint 8 mm. ($\frac{1}{3}$ inch) beyond the prominence of the knuckle.

The sesamoid bones can be felt in front of the metacarpo-phalangeal joint of the thumb.

The palmar aspects of the fingers are crossed by three series of transverse folds;—the highest are single for the index and little fingers, double for the middle and ring—and are nearly 2 cm. ($\frac{3}{4}$ inch) below the metacarpo-phalangeal joints;—the middle are double for all the fingers—and are directly opposite the first interphalangeal joints;—the lowest are single for all the

fingers—and are a little above the second interphalangeal joints. The thumb has two folds—the higher, single, crosses the metacarpo-phalangeal joint obliquely;—the lower, single, directly opposite the first interphalangeal joint.

The free margin of the webs of the fingers is about 2 cm. ($\frac{3}{4}$ inch) below the metacarpo-phalangeal joints.

The lateral ligaments of the joints are nearer the palm than the dorsum.

The sheaths of the flexor tendons extend from the metacarpo-phalangeal joints to the proximal ends of the third phalanges—are least distinct opposite the joints—gape when cut—and lead into the palm of the hand.

The digital arteries bifurcate about 8 mm. ($\frac{1}{3}$ inch) above the free margin of the webs of the fingers.

The epiphyses form the heads of the four inner metacarpals, the base of the first, and the bases of all the phalanges—all joining the shaft about the twentieth year.

The skin of the palm is thick, dense, and adherent—that of the dorsum, thin and loosely connected to the fascia.

GENERAL SURGICAL CONSIDERATIONS IN AMPUTATIONS OF THE FINGERS.

Minimum sacrifice of tissue is the rule in all amputations about the fingers—especially in thumb, index, and little fingers—so that there may be left some length of digit, no matter how short, to approximate to other digits and objects grasped. The basal principle here is—(a) Save a stump, no matter how imperfect—(b) provided tendons remain connected to it, or can be sutured to it—(c) and sound skin can be found to cover it. Indeed, the last may be dispensed with, if there seem fair chance that granulation will cover over the part. Amputations here, especially in cases of injury, are often irregular operations, and amount to little more than trimming of mangled parts—as a bony stump of irregular form, provided flexion and extension exist, is better than a shorter stump of more symmetrical contour.

Since the bones of the fingers are large, as compared with the surrounding soft parts, an ample allowance of covering should be made.

In the interphalangeal region the joints are concave from side to side, with the concavity toward the finger-tips. In the metacarpo-phalangeal region the convexity is toward the tips.

Owing to the function of the fingers, cicatrices should be planned to fall out of the way of pressure—should not be terminal or palmar—and are best placed on the dorsum.

The stump of a phalanx is often considerably in the way unless the flexor and extensor tendons can act upon it. Formerly all of a finger below the center of the middle phalanx (where the superficial flexor is attached) was sacrificed. Now, however, the flexor tendon is sutured into the mouth of the cut theca and periosteum, or even the flap, thereby securing control of the phalangeal stump

The fibrous sheaths of the flexor tendons gape open when cut across and their channels lead directly into the palm of the hand, and those of the thumb and little finger into the great synovial sac beneath the annular ligament of the wrist, furnishing a ready avenue for possible infection. They should, therefore, be closed by two or three catgut sutures, passed from the palmar to the dorsal aspect of the sheath with a curved needle, whenever cut in the

course of an amputation about the fingers. But when cut, especially when the finger is extended, the flexor tendons draw up into the sheath out of sight, and if the sheaths were then sutured the action of the flexor tendons upon the phalangeal stump would be lost. Therefore, to give the flexor tendons a firm hold upon the part, the sutures should include flexor tendon, theca, and periosteum—passing, in order, from before backward, through anterior wall of theca, flexor tendon (if distal to center of middle phalanx), or tendons (if proximal to center of middle phalanx), and posterior wall of theca, which is blended with the periosteum. Where the theca is imperfect, the tendons should be sutured to neighboring periosteum, glenoid ligament, adjacent fibrous tissue, or into the tissues of the flap. Thus the mouth of the sheath is closed by the tendon while anchoring the latter to the part. This sheath is absent over the terminal phalanx and over the distal interphalangeal joint—and is indistinct over the metacarpo-phalangeal joint. Where absent, the flexor tendons should be sutured into the neighboring structures, as just described. Where the periosteum is to be included in the suture, it should be stripped back before dividing the bone.

If the base of the terminal phalanx be saved, the attachment of the deep flexor is preserved. If the upper third of the second phalanx be saved, the attachment of the superficial flexor is preserved. If the amputation be through the first interphalangeal joint, or proximal to it, both flexor tendons will be lost—unless they are sutured into the neighboring structures as just described (into theca, periosteum, or flaps).

The best form of amputation for all parts below the metacarpo-phalangeal joint is one in which a palmar flap predominates—furnishing a covering of thick, sensitive skin accustomed to pressure—and a cicatrix on the dorsum.

In disarticulations by the palmar flap method, a slight downward convexity given to the transverse dorsal incision gives a better apposition with the palmar flap than would a straight transverse incision over the dorsum of the joint.

Disarticulation is best accomplished from the dorsum, after flexing the joint—cutting, in order, through the following structures—skin; fascia; extensor tendons (attached to the bases in the interphalangeal joints, and forming the posterior ligaments of the joints); dorsal portion of the capsule, the knife passing thence behind the base of the distal bone and cutting the lateral ligaments from within outward; anterior portion of capsule, from within; and anterior ligament, also from within.

The glenoid ligament, the fibro-cartilaginous plate which is mainly attached to the base of the distal bone, should be left in the stump.

A longitudinal cut made in the mid-lateral aspect of the finger will have the digital arteries on the palmar side.

All flaps should be cut from without inward—none by transfixion.

The heads of the metacarpals should be preserved, especially in those who require strength in their hands. Their removal weakens the hand. If left in, they and their soft overlying parts eventually atrophy to some extent and the gap is not so apparent. If removed, somewhat greater symmetry is acquired at the cost of strength.

Musculo periosteal coverings in these small amputations through the phalanges are often difficult to provide, but should be provided where possible—even a periosteo capsular covering in disarticulating.

In making all palmar incisions, the part should be extended—and flexed while making dorsal incisions. The fullest coverings will be thus secured.

Guard against making flaps too narrow and pointed—the heads of the bones to be covered are all large, following disarticulation.

incisions outlining the different amputations pass through only skin
cia at first.
igatures should be catgut—and the skin sutures either silk or silkworm-

ll amputations about the fingers the stump should be snugly dressed
ıdaged, and an anterior splint should be included in the dressing.

ATION THROUGH LAST PHALANX OF FINGERS, IN GENERAL.

t **Form.**—Palmar Flap.
ıment.—The palmar flap method furnishes the best form of covering
owing to the presence of the nail, is about the only available form
utation in this locality.

AMPUTATION THROUGH LAST PHALANX OF FINGERS

BY PALMAR FLAP.

cription.—Single palmar flap of all tissues down to bone.

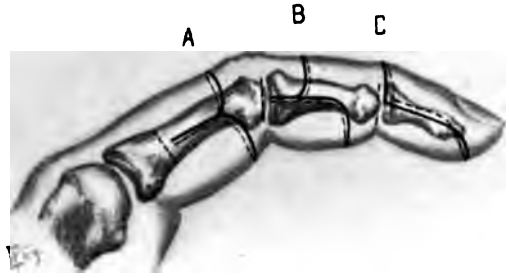

59.—AMPUTATIONS ABOUT THE FINGER:—A, Through first phalanx, by equal palmar and
os; B, At first interphalangeal joint, by long palmar and short dorsal flaps; C, At second
ngeal joint, by palmar flap.

ition (for all Amputations about the Fingers).—Patient on back;
xtremity held out from body, or, better, supported on a small table;
ronated and fingers flexed while dorsal incisions are made, and hand
ed and fingers extended during palmar incisions. Assistant stands
of surgeon, between him and shoulder of patient—steadying the hand
th of his own and holding the adjacent fingers out of the way. Surgeon
igit to be removed with thumb and forefinger of left hand—with
thumb downward and his hand pronated during palmar incisions—
h his thumb upward and his hand supinated during dorsal incisions.
dmarks.—The space is so limited that the saw-line can only be
between the matrix of nail and proximal end of second phalanx.
sion.—(1) Palmar incision—from saw-line downward along lateral
of phalanx, midway between dorsal and palmar surfaces, around the
f the pulp, and back to the saw-line on the opposite side. (2) Dorsal
—connects upper ends of palmar incision, passing transversely over
um with slight downward convexity. (For principle, see Fig. 258, C,
lisarticulation at the last interphalangeal joint is shown.)

course of an amputation about the fingers. But when cut, especially when the finger is extended, the flexor tendons draw up into the sheath out of sight, and if the sheaths were then sutured the action of the flexor tendons upon the phalangeal stump would be lost. Therefore, to give the flexor tendons a firm hold upon the part, the sutures should include flexor tendon, theca, and periosteum—passing, in order, from before backward, through anterior wall of theca, flexor tendon (if distal to center of middle phalanx), or tendons (if proximal to center of middle phalanx), and posterior wall of theca, which is blended with the periosteum. Where the theca is imperfect, the tendons should be sutured to neighboring periosteum, glenoid ligament, adjacent fibrous tissue, or into the tissues of the flap. Thus the mouth of the sheath is closed by the tendon while anchoring the latter to the part. This sheath is absent over the terminal phalanx and over the distal interphalangeal joint—and is indistinct over the metacarpo-phalangeal joint. Where absent, the flexor tendons should be sutured into the neighboring structures, as just described. Where the periosteum is to be included in the suture, it should be stripped back before dividing the bone.

If the base of the terminal phalanx be saved, the attachment of the deep flexor is preserved. If the upper third of the second phalanx be saved, the attachment of the superficial flexor is preserved. If the amputation be through the first interphalangeal joint, or proximal to it, both flexor tendons will be lost—unless they are sutured into the neighboring structures as just described (into theca, periosteum, or flaps).

The best form of amputation for all parts below the metacarpo-phalangeal joint is one in which a palmar flap predominates—furnishing a covering of thick, sensitive skin accustomed to pressure—and a cicatrix on the dorsum.

In disarticulations by the palmar flap method, a slight downward convexity given to the transverse dorsal incision gives a better apposition with the palmar flap than would a straight transverse incision over the dorsum of the joint.

Disarticulation is best accomplished from the dorsum, after flexing the joint—cutting, in order, through the following structures—skin; fascia; extensor tendons (attached to the bases in the interphalangeal joints, and forming the posterior ligaments of the joints); dorsal portion of the capsule; the knife passing thence behind the base of the distal bone and cutting the lateral ligaments from within outward; anterior portion of capsule, from within; and anterior ligament, also from within.

The glenoid ligament, the fibro-cartilaginous plate which is mainly attached to the base of the distal bone, should be left in the stump.

A longitudinal cut made in the mid-lateral aspect of the finger will have the digital arteries on the palmar side.

All flaps should be cut from without inward—none by transfixion.

The heads of the metacarpals should be preserved, especially in those who require strength in their hands. Their removal weakens the hand. If left in, they and their soft overlying parts eventually atrophy to some extent and the gap is not so apparent. If removed, somewhat greater symmetry is acquired at the cost of strength.

Musculo-periosteal coverings in these small amputations through the phalanges are often difficult to provide, but should be provided where possible —even a periosteo-capsular covering in disarticulating.

In making all palmar incisions, the part should be extended—and flexed while making dorsal incisions. The fullest coverings will be thus secured.

Guard against making flaps too narrow and pointed—the heads of the bones to be covered are all large, following disarticulation.

All incisions outlining the different amputations pass through only skin and fascia at first.

All ligatures should be catgut—and the skin sutures either silk or silkworm-gut.

In all amputations about the fingers the stump should be snugly dressed and bandaged, and an anterior splint should be included in the dressing.

AMPUTATION THROUGH LAST PHALANX OF FINGERS, IN GENERAL.

Best Form.—Palmar Flap.

Comment.—The palmar flap method furnishes the best form of covering—and, owing to the presence of the nail, is about the only available form of amputation in this locality.

AMPUTATION THROUGH LAST PHALANX OF FINGERS

BY PALMAR FLAP.

Description.—Single palmar flap of all tissues down to bone.

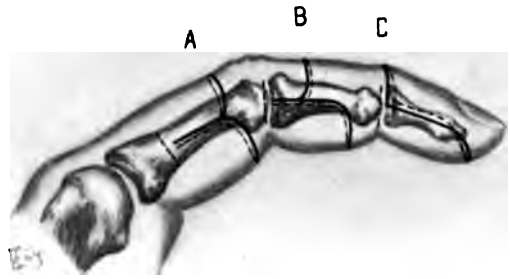

Fig. 258.—AMPUTATIONS ABOUT THE FINGER:—A, Through first phalanx, by equal palmar and dorsal flaps; B, At first interphalangeal joint, by long palmar and short dorsal flaps; C, At second interphalangeal joint, by palmar flap.

Position (for all Amputations about the Fingers).—Patient on back; upper extremity held out from body, or, better, supported on a small table; hand pronated and fingers flexed while dorsal incisions are made, and hand supinated and fingers extended during palmar incisions. Assistant stands in front of surgeon, between him and shoulder of patient—steadying the hand with both of his own and holding the adjacent fingers out of the way. Surgeon holds digit to be removed with thumb and forefinger of left hand—with back of thumb downward and his hand pronated during palmar incisions—and with his thumb upward and his hand supinated during dorsal incisions.

Landmarks.—The space is so limited that the saw-line can only be placed between the matrix of nail and proximal end of second phalanx.

Incision.—(1) Palmar incision—from saw-line downward along lateral aspect of phalanx, midway between dorsal and palmar surfaces, around the center of the pulp, and back to the saw-line on the opposite side. (2) Dorsal incision—connects upper ends of palmar incision, passing transversely over the dorsum with slight downward convexity. (For principle, see Fig. 258, C, where disarticulation at the last interphalangeal joint is shown.)

Operation.—Having outlined these incisions, carry the palmar incision to the bone—dissect up all palmar tissues down to the bone—deepen the dorsal incision to the bone—retract the soft parts, in the entire circumference —and saw the phalanx with a light saw, while holding the tip of the phalanx with bone-holding forceps (as there is generally too little room for the fingers of the operator to grasp). Ligate the palmar digital artery on each side. Suture the deep flexor tendon to the periosteum or flap. Suture the palmar flap to the transverse dorsal line.

DISARTICULATION AT SECOND INTERPHALANGEAL JOINT OF FINGERS, IN GENERAL.

Best Method.—Palmar Flap.

Other Methods.—Short Dorsal and Long Palmar Flaps.

Comment.—Even where the double flap method is adopted, the covering must be almost entirely palmar, owing to the position of the nail.

DISARTICULATION THROUGH SECOND INTERPHALANGEAL JOINT OF FINGERS

BY PALMAR FLAP

Position.—As for amputation through last phalanx (page 283).

Landmarks.—Second interphalangeal joint-line.

Incisions.—(1) Palmar incision—begins opposite the joint-line, midway between dorsal and palmar surfaces—passes down lateral aspect for a distance equal to 1½ diameters of the finger at the disarticulation-line—crosses palmar aspect with bluntly rounded corners—and passes upward to the corresponding point on the opposite side of the finger. (2) Dorsal incision—connects upper end of palmar incision by a transverse incision made over dorsum of joint, with slight downward convexity (Fig. 258, C).

Operation.—Having outlined these incisions through skin and fascia, carry the palmar incision to the bone on a line with the retracted skin—and dissect the soft parts up from the bone. Deepen the dorsal incision to the bone, along the line of retracted skin—open the joint from the dorsum and disarticulate from within outward. There is no theca here to close. Suture the deep flexor tendons into the neighboring tissues. Ligate the two digital arteries. Suture the palmar flap to the dorsal line.

Comment.—The joint is sometimes first disarticulated by a transverse dorsal incision—and the palmar flap then cut from within outward—but with less satisfactory result.

DISARTICULATION THROUGH SECOND INTERPHALANGEAL JOINT OF FINGERS

BY SHORT DORSAL AND LONG PALMAR FLAPS.

Position—Landmarks.—As in the last operation.

Incisions.—(1) Palmar flap—little more than length of diameter of finger at disarticulation-line—begins at disarticulation-line, in mid-lateral aspect of finger—passes directly down the finger for the above distance—crosses the palm with bluntly rounded corners—and passes up the finger to

the corresponding site upon the opposite side. (2) Dorsal flap—one-third the length of the palmar—beginning and ending at the same points as the palmar—and crossing the dorsum with bluntly rounded corners at the above distance below the upper limit. (For principle, see Fig. 258, B.)

Operation.—Carry these incisions to the bone on the lines of retracted skin, completing the palmar incision first—dissect the soft parts from the bone up to the joint-line—open the dorsal aspect of the joint and disarticulate —completing the operation as in the above method.

AMPUTATION THROUGH SECOND PHALANX OF FINGERS, IN GENERAL.

Best Methods.—Palmar Flap; Short Dorsal and Long Palmar Flaps.

Other Methods.—Equal Dorsal and Palmar Flaps; Equal Lateral Flaps; Single External Flap (for index); Single Internal Flap (for little finger); Circular; Oblique Circular; Dorsal Flap.

Comment.—Any single flap, unless taken from the palm, brings part of the scar into the palm. A dorsal flap gives a palmar scar. All equal flap methods and circular methods give terminal scars.

AMPUTATION THROUGH SECOND PHALANX OF FINGERS

BY PALMAR FLAP.

Position.—As for amputation through last phalanx (page 283).

Landmarks.—Lines of proximal and distal joints.

Incisions.—(1) Palmar incision—begins opposite saw-line in mid-lateral aspect of finger—passes vertically downward a distance equivalent to 1½ diameters of the finger at the saw-line—crosses the palmar aspect with bluntly rounded corners—passes vertically upward in the mid-lateral aspect of the opposite side to a point corresponding with the one of beginning. (2) Dorsal incision—connects the upper limits of the limbs of the palmar incision, passing transversely across the dorsum with slight downward convexity. (For principle, see Fig. 258, C.)

Operation.—The above incisions are now deepened to the bone, the palmar first and then the dorsal, on a line with the retracted skin. The soft parts are dissected off the bone back to the saw-line and are retracted while the bone is being sawed. Ligate the digital arteries. In amputating distally to the upper third of the second phalanx, the superficial flexor tendon will retain its attachment. The deep flexor tendon will, however, be severed and should be sutured into the mouth of the fibrous sheath (which ends at the middle of the second phalanx) and into neighboring periosteum and soft parts, if necessary—the closure of the sheath being accomplished in the process of anchoring the deep flexor tendon. The flap is then sutured in the usual way.

AMPUTATION THROUGH SECOND PHALANX OF FINGERS

BY SHORT DORSAL AND LONG PALMAR FLAPS.

Position—Landmarks.—As in the last operation.

Incisions.—(1) Palmar Flap—(2) Dorsal Flap—both outlined exactly as in the disarticulation through the second interphalangeal joint by short

dorsal and long palmar flaps—with the necessary calculations for the change in position (page 284). (For principle, see Fig. 258, B.)

Operation.—For the technic of the operation, see the disarticulation just mentioned. For the manner of dealing with the structures encountered, see the operation last described.

DISARTICULATION AT FIRST INTERPHALANGEAL JOINT OF FINGERS, IN GENERAL.

Best Methods.—Same as mentioned under amputation through second phalanx (page 285).

Other Methods.—Same (page 285).

Comment.—Same (page 285).

DISARTICULATION AT FIRST INTERPHALANGEAL JOINT OF FINGERS

BY PALMAR FLAPS.

Position.—As in amputation through last phalanx (page 283).

Landmarks.—First interphalangeal joint-line.

Incisions.—As for disarticulation at second interphalangeal joint by palmar flap (page 284). (For principle, see Fig. 258, C.)

Operation.—Same, in principle, as the disarticulation at the second joint of the fingers. Both flexor tendons are here severed below their insertions, and the use of the proximal phalanx would be much interfered with unless these tendons were securely attached to the sheath, periosteum, or glenoid ligament of the stump.

DISARTICULATION AT FIRST INTERPHALANGEAL JOINT OF FINGERS

BY SHORT DORSAL AND LONG PALMAR FLAPS.

Position—Landmarks.—As in the last operation.

Incision.—Same as in disarticulation at the second interphalangeal joint (page 285). (For principle, see Fig. 258, B.)

Operation.—Same as in the operation just referred to (page 285). For treatment of the flexor tendons, see disarticulation at first interphalangeal joint by a palmar flap (page 286).

AMPUTATION THROUGH FIRST PHALANX OF FINGERS, IN GENERAL.

Best Methods.—Palmar Flap; Short Dorsal and Long Palmar Flaps.

Other Methods.—Same as mentioned under amputation through second phalanx (page 285). To which list may be added the oval method.

Comment.—Same as made under the operation just referred to (page 285).

AMPUTATION THROUGH FIRST PHALANX OF FINGERS

BY PALMAR FLAP.

Position.—As for amputation through last phalanx (page 283).

Landmarks.—Lines of metacarpo-phalangeal and first interphalangeal joints.

Incisions—Operation.—Same as for amputation through second phalanx (page 285). For reference to flexor tendons, see under disarticulation at first interphalangeal joint by palmar flap (page 286).

AMPUTATION THROUGH FIRST PHALANX OF FINGERS

BY SHORT DORSAL AND PALMAR FLAPS.

Position—Landmarks.—As in the above operation.

Incision—Operation.—As for amputation through the second phalanx by the same method (page 285). For reference to treatment of the flexor tendons and sheaths, see under disarticulation at first interphalangeal joint by palmar flap (page 286).

DISARTICULATION OF FINGERS AT METACARPO-PHALANGEAL JOINTS, IN GENERAL.

Best Methods.—Oval Method (for fingers in general and for thumb); Externo-palmar Flap of Farabeuf (for index); Interno-palmar Flap of Farabeuf (for little finger); Oblique Palmar Flap (for thumb).

Other Methods.—Equal Lateral Flaps; Circular Incision, joined by vertical dorsal queue; Palmar Plap; Large External and Small Internal Flaps (for index); Large Internal and Small External Flaps (for little finger).

Comment.—The first four are the best in the sites indicated and are superior to the others mentioned. The oblique palmar flap for the thumb gives the best covering where sufficient tissue exists.

DISARTICULATION OF FINGERS, IN GENERAL, AT METACARPO-PHALANGEAL JOINT.

BY OVAL METHOD.

Description.—The queue is placed over the dorsum of the joint and the center of the oval passes across the palmar aspect at the web-line.

Position.—As for amputation through the last phalanx (page 283).

Landmarks.—Head of metacarpal; metacarpo-phalangeal joint-line; web of finger.

Incision.—Begins just above head of metacarpal, on its dorsal aspect (in the position corresponding with its neck)—passes down the median dorsal aspect over the prominence of the knuckle, to just beyond the base of the first phalanx (which is about midway between the metacarpo-phalangeal joint-line and the free edge of the web)—at this point the hitherto median incision diverges into two symmetrical limbs—each sweeping across the dorso-lateral aspect of the finger to just below the junction of the finger with the web—and thence transversely across the palmar surface in the line of the crease, on a level with the free border of the web, coming to the opposite side just below the junction of the web with the finger. This rather extensive incision is best made with three strokes—from commencement to web of one side—from point of divergence of median line to web of opposite side—and across palmar surface connecting the two limbs (Fig. 259, H).

Operation.—The above incision through skin and fascia is now deepened. The palmar portion is cut to the bone while the finger is forcibly extended.

The lateral portions are carried to the bone, cutting the lumbricales and

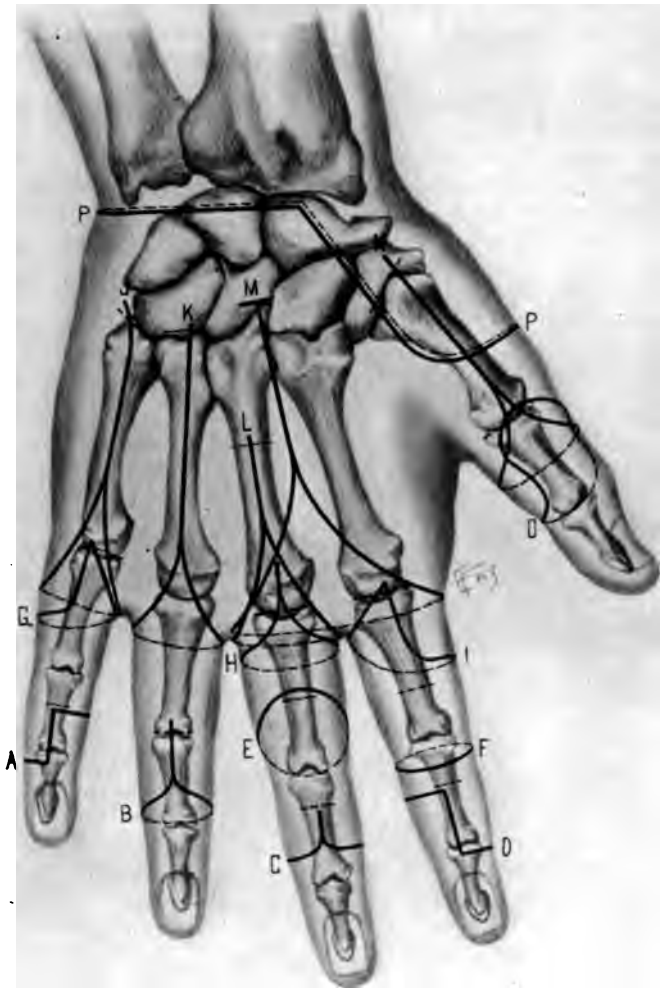

Fig. 259.—AMPUTATIONS ABOUT THE FINGERS, HAND, AND WRIST :—A, Through second phalanx of little finger, by single internal flap ; B, At first interphalangeal joint, by oval method ; C, Through second phalanx, by equal lateral flaps ; D, Through second phalanx of index, by single external flap ; E, Through first phalanx, by oblique circular ; F, Through first phalanx, by ordinary circular ; G, At metacarpo-phalangeal joint of little finger, by interno-palmar flap ; H, At metacarpo-phalangeal joint, by oval method ; I, At metacarpo-phalangeal joint of index, by externo-palmar flap ; J, Of little finger at carpo-metacarpal joint, by racket method ; K, Same of ring finger ; L, Of middle finger and part of metacarpal, by racket method ; M, Of two inner fingers at carpo-metacarpal joints, by racket method ; N, Of thumb at carpo-metacarpal joint, by racket method ; O, Through metacarpo-phalangeal joint of thumb, by oblique palmar flap ; P, P, At wrist-joint, by external flap.

interossei. The soft parts are retracted to the joint-line. The extensor tendons are then cut and the joint thus entered from the dorsum—the lateral

ligaments and glenoid ligament being cut from within and the disarticulation completed. The two digital arteries are tied and the synovial sheath closed. The edges of the sides of the oval are sutured in one vertical, antero-posterior line, in continuation with the queue of the incision. The splint applied should include the wrist-joint.

Comment.—(1) The joint may be opened from the palmar surface, by cutting the glenoid ligament transversely against the base of the metacarpal. In either case, the glenoid ligament is retained. (2) No attempt is made to attach the flexor tendons, as the entire finger is removed and there would be nothing for them to flex. (3) The lower end of the vertical cicatrix is eventually drawn up out of the way of palmar pressure. (4) If it be desired to remove the head of the metacarpal, prolong the queue of the incision upward—free the neck of the bone of soft parts, hugging the bone in the process—retract the soft parts—and, while partly lifting the metacarpal from its bed by traction upon the finger, if still attached, or by grasping the head of the bone with bone-forceps, if disarticulation have occurred, pass a chain or Gigli saw beneath the bone and make a section, so as to bevel the bone obliquely from behind downward and forward, and from the inner- or outer aspect toward the median aspect. (5) Where the skin of the palm is very dense and hard, as in laborers, an awkward projection of skin may be left on the palmar surface of the convexity of the oval, which can be removed and make the suturing more satisfactory by cutting out a V-shaped portion from the palmar aspect. This, however, amounts, practically, to lateral flaps, and brings part of the scar into the palm. (6) Avoid cutting into the web.

DISARTICULATION OF THUMB AT METACARPO-PHALANGEAL JOINT

BY OVAL METHOD.

Position.—As in amputation through last phalanx (page 283).

Landmarks.—Neck of first metacarpal; metacarpo-phalangeal joint.

Incision.—Begins on dorsal aspect of neck of metacarpal, to ulnar side of median line—passes directly down over head of bone and along median aspect of extensor tendons, or slightly to ulnar side, to just beyond the base of the metacarpal—thence the median incision diverges—each limb passing obliquely across the dorso-lateral borders of the thumb, so as to cross and meet upon the palmar aspect opposite the center of the first phalanx. (Similar to H, Fig. 259.)

Operation.—Deepen this incision to the bone along the line of the retracted skin—dividing the extensor brevis pollicis and extensor longus pollicis opposite the metacarpo-phalangeal joint, and the flexor longus pollicis opposite the middle of the first phalanx. The sesamoid bones are to be detached from the base of the first phalanx and left in the stump. As far as possible the muscles which are attached to the base of the first phalanx (extensor brevis pollicis, adductor obliquus pollicis, adductor transversus pollicis, abductor pollicis, flexor brevis pollicis), as well as the long flexors and extensors, should be sutured into the tissues of the stump—as considerable range of movement is thereby secured for the metacarpal bone, whereby it may offer counterpressure to the fingers. Close the synovial sheath. Tie the dorsalis pollicis and two branches of the princeps pollicis. Suture the oval in a single straight line in continuation of the queue.

Comment.—The head of the metacarpal is large and requires ample covering.

DISARTICULATION OF THUMB AT METACARPO-PHALANGEAL JOINT

BY OBLIQUE PALMAR FLAP—(FARABEUF).

Description.—This method consists of two U-shaped incisions, the dorsal having its convexity upward, the palmar having its convexity downward—the limbs of each U passing, and obliquely meeting, on the lateral aspects of the thumb.

Position.—As for amputation through the last phalanx (page 283).

Landmarks.—Lines of the metacarpo-phalangeal and interphalangeal joints.

Incision.—The convexity of the dorsal U is upward and corresponds with the dorsal aspect of the metacarpo-phalangeal joint. The convexity of the palmar U is downward and is placed just above the interphalangeal joint-line. Between these two rounded extremities the lateral limbs pass in an oblique direction along the lateral borders of the thumb, becoming continuous with each other (Fig. 259, O).

Operation.—This incision is deepened throughout to the bone, along the line of the retracted skin—the extensor brevis pollicis and extensor longus pollicis are divided over the metacarpo-phalangeal joint, and the flexor longus pollicis about the center of the first phalanx—the soft parts are freed back to the joint-line—the sesamoid bones are detached from the base of the first phalanx and left in the flap—the joint is entered from above and disarticulation completed. The dorsalis pollicis and the two branches of the princeps pollicis are to be tied. The synovial sheath is closed. The convexity of the palmar flap is sutured into the concavity of the dorsal wound —bringing the cicatrix well on to the dorsum and out of the way of pressure

Comment.—As the head of the metacarpal is disproportionately large, an additional allowance of covering must be made.

DISARTICULATION OF INDEX-FINGER AT METACARPO-PHALANGEAL JOINT

BY EXTERNO-PALMAR FLAP—(FARABEUF).

Description.—This is really an oval method, so modified as to bring the cicatrix upon the interno-dorsal aspect of the metacarpo-phalangeal region—so that fingers and objects opposed to that aspect may not come into contact with the scar.

Position.—As for amputation through last phalanx of finger (page 283).

Landmarks.—Metacarpo-phalangeal joint-line; middle of first phalanx; web.

Incision.—Begins at metacarpo-phalangeal joint-line, immediately over the median aspect of the extensor tendon—passes vertically down the median dorsal aspect of the finger, in the above relation to the extensor tendon, to the center of the first phalanx—thence sweeps across the lateral and palmar aspects to the web—and thence passes in a straight line, by the shortest route, up the inner side of the finger to the place of beginning (Fig. 259, I).

Operation.—This superficial incision is deepened to the bone—the soft parts retracted to the joint-line—disarticulation effected—and the operation completed as in the simple oval method. The digital, dorsalis indicis, and radialis indicis arteries are to be tied. The flexor sheath is to be closed—and the parts so sutured as to cause the cicatrix to occupy the position of the straight portion of the incision, upon the interno-dorsal aspect.

Comment.—(1) The placing of the incision over the median, or even slightly to the ulnar, rather than the radial aspect of the extensor tendon (as recommended by Farabeuf), gives ampler covering, and a greater certainty of the scar falling well to the ulnar side. (2) If the head of the metacarpal be removed, it is exposed as mentioned under the oval method (page 289, Comment).

DISARTICULATION OF LITTLE FINGER AT METACARPO-PHALANGEAL JOINT

BY INTERNO-PALMAR FLAP—(FARABEUF).

Description.—This, also, is a modification of the oval method, so calculated as to bring the cicatrix upon the externo-dorsal aspect of the metacarpo-phalangeal region—that non-scar tissue may come into contact with objects which press the stump.

Position—Landmarks.—As in the last operation.

Incision.—Begins at the metacarpo-phalangeal joint-line, immediately over the median aspect of the extensor tendon—passes vertically down the dorsal aspect of the finger, in the above relation to the extensor tendon, to the center of the first phalanx—thence sweeps across the lateral and palmar aspects of the finger to the web—and thence passes in a straight line, by the shortest route. up the radial side of the finger to place of beginning (Fig. 259, G).

Operation.—The steps of the disarticulation are completed as in the corresponding operation just described upon the thumb, the reverse of which this is, in every respect. Two digital arteries are to be tied. The parts are to be so sutured as to cause the cicatrix to occupy the position of the straight portion of the incision, upon the externo-dorsal aspect of the region, buried in the groove formed by the adjacent finger.

Comment.—(1) Carrying the incision over the median aspect of the extensor tendon insures more covering than if the incision passed down the ulnar aspect, as recommended by Farabeuf—and also makes it more certain that the scar will fall well to the radial side of the stump, out of the way of pressure. (2) If it be desired to remove the head of the metacarpal, it is exposed as described under the oval method of disarticulating the fingers in general—the bone being here beveled from ulnar to radial aspect, and from dorsum to palm.

SURGICAL ANATOMY OF THE HAND.

Bones.—(a) Metacarpals, of thumb and fingers;—(b) Carpals;—First Row; scaphoid, semilunar, cuneiform, pisiform;—Second Row; trapezium, trapezoid, os magnum, cuneiform.

Articulations and Ligaments.—(A) Metacarpo-Phalangeal Articulations;—See description under Surgical Anatomy of Fingers. (B) Metacarpals with each other (Intermetacarpal);—(a) Carpal ends of four inner metacarpals;—dorsal, palmar, and interosseous ligaments, and synovial membrane;—(b) Digital ends of four inner metacarpals;—transverse metacarpal ligaments (on palmar aspect). (C) Inner Metacarpals with the carpus;—dorsal, palmar, and interosseous ligaments, and synovial membrane. (D) Metacarpal of thumb with trapezium;—capsular ligament. (E) Articulations of second row of carpals with each other;—three dorsal, three palmar, and three interosseous ligaments, between trapezium and trapezoid, between

trapezoid and os magnum, and between os magnum and unciform; and synovial membrane between each. (**F**) Articulations of carpals of first row with each other;—two dorsal ligaments between scaphoid and semilunar, and between semilunar and cuneiform; two palmar ligaments between scaphoid and semilunar, and between semilunar and cuneiform; two interosseous ligaments between scaphoid and semilunar, and between semilunar and cuneiform; capsular ligament between cuneiform and pisiform; two palmar ligaments between pisiform and unciform process of unciform, and between pisiform and fifth metacarpal; and synovial membrane between each bone. (**G**) Articulations of two rows of carpals with each other (medio-carpal);—palmar, dorsal, external lateral and internal lateral ligaments, and synovial membrane (between each row).

Anterior Annular Ligament.—(**a**) Attachments;—Internally; pisiform and unciform process of unciform bone. Externally; tuberosity of scaphoid, inner part of anterior surface, and ridge on trapezium. Superiorly; continuous with deep fascia of forearm. Inferiorly; continuous with palmar fascia, and furnishing attachment to some of muscles of thumb and little finger. (**b**) Structures passing superficial to anterior annular ligament (from without inward); radial vessels and nerve, flexor carpi radialis, palmaris longus, ulnar vessels and nerve, flexor carpi ulnaris. (**c**) Structures passing beneath anterior annular ligament (from above downward); flexor sublimis digitorum, median nerve, flexor profundus digitorum, flexor longus pollicis.

Posterior Annular Ligament.—(**a**) Attachments;—Internally; styloid process of ulna, cuneiform and pisiform bones. Externally; outer margin of radius and elevated ridge on its posterior surface. Superiorly; continuous with deep fascia of forearm. (**b**) Tendons passing beneath posterior annular ligament (in six compartments, from without inward);—(**1**) extensor ossis metacarpi pollicis and extensor brevis pollicis; (**2**) extensor carpi radialis longior and brevior; (**3**) extensor longus pollicis; (**4**) extensor communis digitorum and extensor indicis; (**5**) extensor minimi digiti; (**6**) extensor carpi ulnaris.

Synovial Sacs.—Two synovial sacs lie beneath the anterior annular ligament, one for the flexor sublimis digitorum and flexor profundus digitorum, and one for the flexor longus pollicis. Both extend upward for 3 to 4 cm. ($1\frac{1}{4}$ to $1\frac{1}{2}$ inches) above the anterior annular ligament. That for the flexor longus pollicis extends downward to last phalanx of thumb. That for the flexor tendons of fingers divides into four processes; the one for the little finger generally extending to base of last phalanx;—those for index, middle, and ring fingers ending about middle of the metacarpals—and are thus separated by about 1.3 cm. ($\frac{1}{2}$ inch) from the great synovial sac. Thus there is an open channel from the ends of the thumb and little fingers to a point 3 or 4 cm. ($1\frac{1}{4}$ to $1\frac{1}{2}$ inches) above the anterior annular ligament.

Muscles and Tendons.—(**1**) **Of palmar aspect:**—(**a**) Superficial Muscles from Forearm;—Flexor carpi radialis; palmaris longus; flexor carpi ulnaris; flexor sublimis digitorum. (**b**) Deep Muscles from Forearm;—Flexor profundus digitorum; flexor longus pollicis. (**c**) Short, small Muscles of Thumb;—Abductor pollicis; opponens pollicis (flexor ossis metacarpi pollicis); flexor brevis pollicis; adductor obliquus pollicis; adductor transversus pollicis. (**d**) Short, small Muscles of Little Finger;—palmar brevis; abductor minimi digiti; flexor brevis minimi digiti; opponens minimi digiti (flexor ossis metacarpi minimi digiti). (**e**) Short Central Muscles of Hand;—four lumbricals; three palmar interossei. (**2**) **Of dorsal aspect:**—(**a**) Superficial Muscles from Forearm;—Extensor communis digitorum; extensor

minimi digiti; extensor carpi ulnaris. (b) Deep Muscles from Forearm;—Extensor ossis metacarpi pollicis; extensor brevis pollicis (extensor primi internodii pollicis); extensor longus pollicis (extensor secundi internodii pollicis); extensor indicis; extensor carpi radialis longior; extensor carpi radialis brevior. (c) Small Muscles of Dorsal Aspect of Hand;—four dorsal interossei.

Attachment of Muscles to Bases of Metacarpals.—To first; extensor ossis metacarpi pollicis. To second; extensor carpi radialis longior; flexor carpi radialis. To third; extensor carpi radialis brevior. To fifth; extensor carpi ulnaris; some fibers of flexor carpi ulnaris.

Arteries.—(a) **Palmar supply**:—(1) From Radial;—anterior radial carpal; superficialis volæ; deep arch; princeps pollicis; radialis indicis; three palmar interossei; three superior (posterior) communicating (perforating); three inferior (anterior) communicating (perforating); palmar carpal recurrent. (2) From Ulnar;—anterior interosseous; anterior ulnar carpal; superficial palmar arch; four palmar digital; deep palmar (communicating); three palmar interossei (from deep arch, common to radial and ulnar); three superior (posterior) communicating (perforating) (also common to radial); three inferior (anterior) communicating (perforating) (also common to radial); palmar carpal recurrent (also common to radial). (b) **Dorsal supply**:—(1) From Radial;—radial; posterior radial carpal; dorsalis pollicis; dorsalis indicis; metacarpal (first dorsal interosseous); second and third dorsal interosseous; three superior (posterior) communicating (perforating); three inferior (anterior) communicating (perforating). (2) From Ulnar;—posterior ulnar carpal; metacarpal.

Veins.—(a) Superficial;—Dorsal Venous Plexus—from which arise superficial radial vein, and anterior and posterior superficial ulnar veins;—Anterior Median Plexus—from which arise superficial median vein. (b) Deep; Two venæ comites for each artery.

Lymphatics.—Pass up the forearm from the lymphatic palmar arch, and from the dorsal plexus of lymphatics.

Nerves.—(a) From Median;—Median and following branches; outer and inner palmar cutaneous; muscular branches; five digital branches; (b) From Ulnar;—Ulnar and following branches; palmar cutaneous; dorsal cutaneous; superficial palmar branch; deep palmar branch. (c) From Radial;—external branch; internal branch.

SURFACE FORM AND LANDMARKS OF THE HAND.

Carpal bones—two subcutaneous eminences may be felt upon the palmar aspect of the hand just below the wrist—the outer (just beneath the radial styloid process) due to the tuberosity of the scaphoid and ridge on the trapezium (the ridge being just beneath the former)—the inner, due to the pisiform bone The unciform process of the unciform lies below and slightly internal to the pisiform. No other carpal bones are recognizable on the palmar surface—and only the cuneiform on the dorsum.

Metacarpal bones—The heads of the metacarpals form the knuckles. The dorsal surface of the fifth, and the heads of all, are subcutaneous—all the other aspects of the remainder are covered by muscles or tendons. The base of the metacarpal of the thumb can be felt—and the sesamoid bones opposite the metacarpo-phalangeal joint

Skin-folds (creases) of the hand—(a) Superior fold—begins at wrist, between thenar and hypothenar eminences, and runs to the outer border

of the hand at the base of the index-finger—and is formed by the adduction of the thumb. (b) Middle fold—begins at outer border of hand where superior fold ends, and runs inward and slightly upward and ends at outer limit of hypothenar eminence—and is formed by the simultaneous flexion of the metacarpo-phalangeal joints of the first and second fingers—and about corresponds, opposite the third metacarpal, to the lower portion of the superficial palmar arch. (c) Inferior fold—begins opposite the cleft between the index and middle fingers and runs almost transversely to the ulnar margin of the hand, crossing the lower part of the hypothenar eminence—and is formed by the flexion of the middle, ring, and little fingers. It crosses the necks of the three inner metacarpals, and approximately indicates the upper limit of the synovial sheaths of the flexor tendons of the three outer fingers. Midway between this fold and the free margins of the webs are the metacarpo-phalangeal joints.

Line of carpo-metacarpal joints—from base of fifth metacarpal, to carpo-metacarpal joint-line of thumb (both of which may be recognized). The inner portion of this line is regular, the outer portion irregular.

Line of metacarpo-phalangeal joint-line—found by flexing the first phalanges at a right angle with the metacarpals—and then prolonging the mid-lateral axis of the metacarpals forward—which lines will pass through the center of the joints.

Free edges of webs of fingers, on palmar aspect, are about 2 cm. (¾ inch) below the metacarpo-phalangeal joints.

Muscles—The muscles of the thenar (thumb) eminence—and those of the hypothenar (little finger) eminence are recognizable, and also the adductor transversus pollicis. The lumbricals form soft eminences behind the clefts of the fingers—and the dorsal interossei form similar soft eminences between the metacarpals. The position of many of the extensor tendons can be recognized by both sight and touch—and some of the flexor tendons can be detected by touch while in the act of movement.

Vessels—the superficial palmar arch is on a level with the lower border of the outstretched thumb, passing down from the wrist on the outer side of the pisiform. The deep palmar arch lies about 1.3 cm. (½ inch) nearer the wrist, crossing the shafts of the second, third, and fourth metacarpals near their bases.

GENERAL SURGICAL CONSIDERATIONS IN AMPUTATIONS ABOUT THE HANDS.

A finger may be removed with a part, or the whole, of its metacarpal. In the middle metacarpals, the removal of a part, where possible, is better than a disarticulation at the carpo-metacarpal joint—as the end of the bone is not apt to get into the way, and the strength of the hand is greater. In the case of the thumb and little finger, however (which are the fingers most frequently removed, because most exposed to injury), it is best to remove the entire metacarpal—the retention of a part of the outer metacarpals being of little value, and often in the way—and its removal not weakening the hand as much as the loss of an inner one.

If but a part of the metacarpal of the thumb or little finger be removed, however, the remaining portion should be beveled obliquely away from the position of most pressure.

The metacarpals should be divided in their continuity by a Gigli saw. It is easier, but less surgical, to divide them with bone-cutting pliers.

Additional advantages in amputating a finger and part of its metacarpal, over disarticulating a finger and all of its metacarpal, are the following;—deep palmar arch is not exposed; synovial sacs of flexor tendons may escape, if the bone be divided above its center; carpo-metacarpal synovial sacs are not opened; and tendons attached to bases of metacarpals are not lost.

Where, in disarticulating at the carpo-metacarpal articulation, the joint-line is not easily located before incising, begin the incision as high as thought to be the articular line, and then verify the line by inserting the tip of the index-finger into the wound, while the opposite hand manipulates the special finger whose metacarpal forms part of the articulation.

As the metacarpal of the thumb and, according to some, of the little finger do not communicate with the large synovial sac of the carpal bones, they can be removed in their entirety with little danger of infection—but, in unclean cases, the removal of the second, third, and fourth metacarpals in their continuity is preferable to a disarticulation at the carpo-metacarpal line, with the likelihood of general infection.

The synovial sheaths should be closed with gut-suture when cut. But where large synovial sheaths and extensive articular surfaces are opened up, drainage for twenty-four or forty-eight hours is indicated.

In partial amputations of the hand, the flexor and extensor tendons should be cut long enough to be sutured into the wound, so as to retain flexion and extension of the stump.

The main dangers in amputating and disarticulating about the hand are wounding of the deep palmar arch or termination of the radial, and in opening the synovial sheath of the palm or fingers.

The stump should be dressed upon a splint which will immobilize the wrist.

AMPUTATION OF FINGERS, IN GENERAL, WITH PARTS OF THEIR METACARPALS.

Methods.—Racket Method—best for single fingers, in general, as well as for thumb and little finger; and also for two or three continguous inside fingers. Equal Dorsal and Palmar Flaps—best for the three inner fingers. Anterior Ellipse (sometimes called a Short Palmar Flap)—best for all the fingers, not including the thumb.

AMPUTATION OF A FINGER, IN GENERAL, WITH PART OF ITS METACARPAL,

BY RACKET METHOD.

Description.—The finger is removed as one continuous whole at the line of section of the metacarpal.

Position.—Same as for amputation through last phalanx (page 283).

Landmarks.—Outline of dorsal aspect of metacarpal; carpo-metacarpal joint; webs of fingers.

Incision.—Begins over dorsum of metacarpal, a short distance above the point at which the bone is to be sawed—passes thence downward over the middle of the dorsal aspect until the neck of the metacarpal is reached —whence the median line diverges into two limbs, each limb passing down the dorso-lateral aspect of the finger to just below the junction of the web and finger—whence each limb crosses immediately in front of the digito-palmar crease to meet in the center of the palmar aspect of the finger (Fig. 259, L).

Operation.—This incision is deepened to the bone on the line of the retracted skin. The extensor tendons are divided near the upper end of the vertical incision. The sides of the shaft of the metacarpal are carefully cleared, hugging the bone in the process. The region of the metacarpo-phalangeal joint is also freed and the flexor tendons divided near the neck of the metacarpal, while the finger is forcibly extended. The shaft of the metacarpal is further cleared up to the saw-line, the finger being held in extreme extension. The Gigli or chain saw is now passed beneath the metacarpal, while the soft parts are held out of the way, and the bone sawed so as to bevel it from below upward and toward the dorsum. The digital arteries are divided and are to be tied. The synovial sheath of the flexor tendons should be closed with gut sutures. The wound is sutured in a single median line upon the dorsal aspect.

AMPUTATION OF THUMB WITH PART OF ITS METACARPAL

BY RACKET METHOD.

Description—Position—Landmarks.—As for amputation of a finger with part of its metacarpal (page 295).

Incision.—As in disarticulation of thumb with its entire metacarpal, by the racket method (page 298)—except that the queue of the incision only extends up to a little above the saw-line.

Operation.—As for amputation of a finger with part of its metacarpal (page 295). The metacarpal should be beveled from above downward and inward.

AMPUTATION OF LITTLE FINGER WITH PART OF ITS METACARPAL

BY RACKET METHOD.

Description—Position—Landmarks.—As for amputation of a finger with part of its metacarpal (page 295).

Incision.—As in disarticulation of little finger with its entire metacarpal, by the racket method (page 298)—except that the queue of incision begins just above section-line of bone.

Operation.—As for amputation of a finger with part of its metacarpal, by the racket method. The metacarpal should be beveled from above downward and toward the radial side.

AMPUTATION OF TWO CONTIGUOUS INSIDE FINGERS WITH PART OF THEIR METACARPALS

BY RACKET METHOD.

Similar, practically, to the disarticulation of two contiguous inside fingers with their entire metacarpals, by the racket method (page 299).

AMPUTATION OF THREE INSIDE FINGERS WITH PARTS OF THEIR METACARPALS

BY RACKET METHOD.

See the disarticulation of the three innermost fingers with their entire metacarpals (page 299), or by the racket method.

AMPUTATION OF THREE INNERMOST FINGERS WITH PARTS OF THEIR METACARPALS

BY EQUAL DORSAL AND PALMAR FLAPS.

See the disarticulation of the three innermost fingers with their entire metacarpals, by the method of equal dorsal and palmar flaps (page 300).

AMPUTATION OF ALL THE FINGERS (EXCLUDING THE THUMB), WITH PARTS OF THEIR METACARPALS,

BY ANTERIOR ELLIPSE.

See the corresponding disarticulation of all the fingers, exclusive of the thumb, with their entire metacarpals, by an anterior ellipse (or short palmar flap, as it is sometimes called) (page 301).

DISARTICULATION OF FINGERS, IN GENERAL, WITH THEIR ENTIRE METACARPALS.

Methods.—Racket Method—best for the fingers in general, including thumb, index, and little fingers—and also used for the two or three inside fingers. Equal Dorsal and Palmar Flaps—best for three innermost fingers. Anterior Ellipse (Short Palmar Flap)—best for all the fingers, exclusive of thumb—and also best for all the fingers including thumb. Palmar Flaps—sometimes used for the thumb, but inferior to the racket. Circular Method—sometimes used for all the fingers, with or without the thumb.

Comment.—Preservation of the carpus is desirable, especially if the flexor and extensor tendons are so sutured into the wound that considerable range of movement may be secured for the stump wielding the artificial limb.

DISARTICULATION OF AN INNER FINGER WITH ITS METACARPAL

BY RACKET INCISION.

Description.—The finger is removed as one continuous whole at the carpo-metacarpal articulation.

Position.—As for amputation through the last phalanx (page 283).

Landmarks.—Outline of dorsal aspect of carpo-metacarpal articulation, and metacarpal bone.

Incision —Begins just above the carpo-metacarpal joint—passes down the median dorsal aspect of the metacarpal until its neck is reached—thence diverges into two limbs, each limb running over the dorso-lateral aspect of the finger to just below the junction of the web and finger—whence each limb crosses the digito-palmar crease to meet in the center of the palmar aspect of the finger. If necessary for the purpose of aiding disarticulation at the carpo-metacarpal joint, a short transverse incision may be made at a right angle to the upper end of the queue (Fig. 259, K).

Operation.—This incision is now deepened on a line of the retracted skin and fascia. The shaft of the metacarpal and the metacarpo-phalangeal joint are carefully cleared, hugging the bones as closely as possible, while an assistant keeps the finger in the position of extreme extension. The extensor tendons are divided as near the upper limit of the queue as possible—the flexor tendons near the neck of the metacarpal. The sides of the metacarpal are now bared up toward the carpo-metacarpal articulation, using especial

care in the palmar region. The ligaments of the intermetacarpal joints and carpo-metacarpal joints are divided by carefully thrusting a knife between the sides of the bases of the metacarpals and between the metacarpals and the carpal bones, working from the dorsum of the hand. The disarticulation is completed by forcibly turning back the finger upon the dorsum of the hand, completing, with the knife, the division of any undivided ligaments, insertions of tendons, or palmar structures. The synovial sheaths of the flexor tendons should be sutured with catgut, if possible. Tie the two digital arteries—and suture the wound in a single median line upon its dorsal aspect.

DISARTICULATION OF INDEX-FINGER WITH ITS METACARPAL

BY RACKET INCISION.

Description.—The steps of this operation are practically the same as for the corresponding operation upon an inner finger. The incision is in the mid-dorsal line. The addition of a short transverse incision at a right angle to the upper end of the queue is especially advisable here, owing to the width of the base of the second metacarpal. The outer (radial) of the diverging limbs below should follow the dorsal aspect a little further down before sweeping over the lateral aspect than does the inner (ulnar) limb, in order to bring the scar more out of the way of pressure. The index should be extended and abducted in clearing and disarticulating. Tie the digital, radialis indicis, and dorsalis indicis arteries—and suture the wound in a vertical dorsal line.

DISARTICULATION OF LITTLE FINGER WITH ITS METACARPAL

BY RACKET INCISION.

Description.—The steps of the operation are essentially similar to those for the removal of an inner finger with its metacarpal by the racket incision. It is better to place the incision in the mid-dorsal aspect than toward the inner (ulnar) side of the metacarpal, as objects less easily press such a scar. At the upper extremity of the queue a short transverse incision may be added, not crossing the upper end of the queue (as in the case of the inner fingers), but running from the upper end of the queue at a right angle toward the ulnar aspect of the hand, over the carpo-metacarpal joint—to allow of readier disarticulation. The inner (ulnar) of the diverging limbs below should follow the dorsal aspect a little further down before sweeping over the lateral border than does the outer (radial) limb—in order to bring the scar more out of the way of pressure. The little finger should be extended and abducted (from the median line of the hand) in clearing and disarticulation. Carefully close the large synovial sac of the little finger, if opened. Preserve the hypothenar muscles as far as possible and suture into the wound. Suture the wound in a single dorsal line (Fig. 259, J).

DISARTICULATION OF THUMB WITH ITS METACARPAL

BY RACKET INCISION.

Description.—Removal of the thumb, together with its metacarpal, at the carpo-metacarpal joint.

Position.—Same as for the fingers, except that the hand is held midway between pronation and supination.

Landmarks.—Outline of the dorsal aspect of the metacarpal, and the carpo-metacarpal joint.

Incision.—Begins just above the carpo-metacarpal joint-line, in the mid-dorsal aspect of the metacarpal—passing into the "snuff-box," if at all, with great care and, at first, very superficially, on account of the radial artery. The incision then passes down the center of the dorsum of the thumb to the neck of the metacarpal—and here divides into the two limbs of an oval, which part to encircle the head of the metacarpal, crossing the palmar aspect of the thumb on a level with the free edge of the web—the outer (radial) of the diverging limbs following the dorsal aspect a little further down before sweeping over the lateral aspect than does the inner (ulnar) limb (Fig. 259, N).

Operation.—This incision is deepened on the line of the retracted skin and fascia. The extensor tendons of the first and second phalanges are cut as long as possible, so as to be sutured into the wound. The dorsum and sides of the metacarpal are cleared of soft parts, hugging the bone. The thumb is extended and abducted and the muscles attached to the base of the first phalanx are divided near the sesamoid bones, preserving the thenar muscles as far as possible. The palmar aspect of the metacarpal is cleared while an assistant rotates the thumb from side to side, working as near the bone as possible. The flexor longus pollicis tendon is divided low down, so that it may be sutured into the wound. Disarticulation is accomplished by severing the binding ligaments and the extensor ossis metacarpi pollicis, while the thumb is flexed into the palm—opening the joint from the dorsum, the thumb being then rotated in different directions to complete the disarticulation. Suture the sheath of the flexor tendon. Tie the arteria princeps pollicis, or its two branches, and the dorsalis pollicis. Quilt the muscles, suturing the flexor, extensor, and thenar tendons and muscles into the wound. The cicatrix will run in a dorsal median line.

DISARTICULATION OF TWO CONTIGUOUS INSIDE FINGERS WITH THEIR METACARPALS

BY RACKET INCISION.

Description.—The operation is the same, in principle, as that for the removal of a single finger and its metacarpal. A vertical incision begins just above the carpo-metacarpal joint-line and between the bases of the two contiguous metacarpals—passes down the back of the hand midway between the two metacarpals for about one-half of their length—then divides into the two limbs of an oval, or racket—the radial limb passing to the radial side of the outer of the two fingers to be removed—the ulnar limb to the ulnar side of the inner of the two fingers to be removed—to the junction of the fingers and webs—thence both limbs cross and meet beneath the fingers in the digito-palmar crease. The incision is deepened—the metacarpals cleared—the tendons cut long—disarticulation accomplished—and the operation completed just as in the disarticulation of a single finger and its metacarpal. The flexor and extensor tendons are to be sutured into the wound (Fig. 259, M).

DISARTICULATION OF THREE INSIDE FINGERS WITH THEIR METACARPALS

BY RACKET INCISION.

Description.—Same, in the main, as the disarticulation of any two

contiguous inside fingers with their metacarpals—except that the vertical incision begins just above the carpo-metacarpal joint line, over the center of the base of the central one of the three metacarpals—passes down this metacarpal for about one-third of its length—and thence diverges, the radial limb to the radial side of the outer finger, and the ulnar limb to the ulnar side of the inner finger—both limbs passing to the junction of the fingers with the webs—and thence crossing and meeting in the digito-palmar crease beneath the central finger. The operation is completed as in the last—three fingers and their metacarpals being removed instead of two.

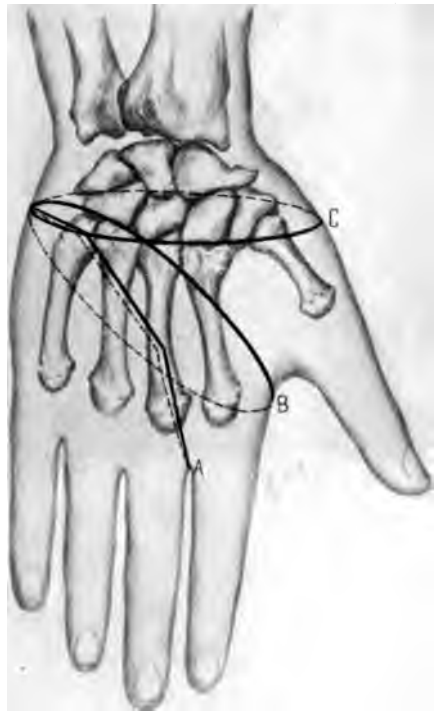

Fig. 260.—AMPUTATIONS ABOUT THE HAND:—A, Disarticulation of three inner fingers, with their metacarpals, by equal dorsal and palmar flaps; B, Disarticulation of all the fingers, except thumb, with their metacarpals, by anterior ellipse; C, Disarticulation at wrist-joint, by circular method. (Dorsal view.)

DISARTICULATION OF THREE INNERMOST FINGERS WITH THEIR METACARPALS

BY EQUAL DORSAL AND PALMAR FLAPS.

Description.—Corresponding incisions are made upon palmar and dorsal aspects of the hand, furnishing symmetrical flaps.

Position.—As in operations upon the fingers (page 283).

Landmarks.—Carpo-metacarpal articulations of third, fourth, and fifth metacarpals; middle palmar crease.

Incision.—(1) Palmar incision—begins just below the base of the fifth metacarpal—passes downward and outward across the palm, parallel with but just below the middle palmar crease, until opposite the center of the ring-finger or just beyond—and is thence directed to the junction of the outer side of the middle finger and web. (2) Dorsal incision—corresponds with the palmar incision (Fig. 260, A).

Operation.—The above incisions are deepened on the line of the retracted skin and fascia. The metacarpal bones are bared to their joint-lines, which is more easily done in the case of the fourth and fifth, the third being exposed by upward and outward retraction of the soft parts. The nerves are cut as near the line of disarticulation as possible. The flexor and extensor tendons are cut long, so as to be sutured into the wound. Care is taken not to wound the deep arch. Tie the interosseous branches of the deep arch, and the palmar digital branches of the superficial arch, or the arch itself, if wounded. Suture the synovial sheaths where opened. The muscles of the hypothenar eminence are left in the palmar flap as far as possible and are quilted to the fascia of the dorsal region, where there are no muscles. The flexor and extensor tendons are also sutured into the wound. The dorsal and palmar flaps are united by suture extending along the ulnar side of the hand.

Comment.—In the unusual cases where this operation is done, injury has generally been the cause, and its extent upon the dorsum and palm will determine the outline of the coverings. Where both are equally involved the above coverings will have to be taken—but if the predominant covering could be gotten from the palm, so as to make a larger palmar and smaller dorsal flap, the scar would lie on the dorsal aspect and be out of the way of pressure, which would be preferable.

DISARTICULATION OF ALL FINGERS, EXCLUDING THUMB, WITH THEIR METACARPALS

BY ANTERIOR ELLIPSE.

Description.—This is, practically, a palmar covering, whose convex anterior border fits into the concave wound on the dorsum of the hand. It is sometimes called the short palmar flap method.

Position.—As in the amputations upon the fingers in general (page 283).

Landmarks.—Base of fifth metacarpal (marking the point at which the ellipse crosses the ulnar border of the hand); point midway between the central crease of the hand and the level of the outstretched thumb (marking the point at which the ellipse crosses the radial border of the hand); the carpo metacarpal joint-line.

Incisions.—Palmar incision—passes between the two above points, with a downward convexity, whose lowest part reaches below the middle of the metacarpals. Dorsal incision—also passes between the same two points, with an upward convexity, whose highest part corresponds with the bases of the two inner metacarpals (Fig. 260, B).

Operation.—These incisions are deepened to the bone. The flexor and extensor tendons are cut long. The soft parts are cleared up to the carpo-metacarpal joint-line—the metacarpals are disarticulated from the carpals, and the second metacarpal from the first metacarpal, cutting the dorsal ligaments by flexing and the palmar ligaments by extending the hand. Tie the palmar digital, palmar interosseous, dorsalis indicis, radialis indicis, and palmar arches, if severed. Close the flexor sheaths—suture the flexor

and extensor tendons into the wound—and suture the convex palmar flap to the concave dorsal wound.

DISARTICULATION OF FINGERS AND THUMB AT CARPO-METACARPAL ARTICULATION

BY PALMAR FLAP.

Description.—Same, in principle, as the disarticulation of the hand at the wrist-joint (page 305)—except that the upper limits of the flap extend only to the ulnar margin of the unciform-metacarpal articulation, on the one side, and the radial margin of the trapezio-metacarpal articulation, on the other side—the lower limit crossing the necks of the metacarpals.

SURGICAL ANATOMY OF THE WRIST-JOINT.

Bones.—Radius; ulna; first row of carpal bones (scaphoid, semilunar, cuneiform, pisiform).

Ligaments.—Anterior radio-carpal; posterior radio-carpal; external lateral; internal lateral; and synovial membrane.

Movements.—Flexion;—accomplished by flexor carpi radialis; flexor carpi ulnaris; palmaris longus. Extension;—by extensor carpi radialis longior; extensor carpi radialis brevior; extensor carpi ulnaris. Adduction;—by flexor carpi ulnaris; extensor carpi ulnaris. Abduction;—by extensor ossis metacarpi pollicis; extensores brevior et longior pollicis; extensores carpi radialis longior et brevior; flexor carpi radialis.

Muscles and Tendons in Neighborhood of Wrist-joint.—**(a)** Anteriorly;—flexor carpi radialis; palmaris longus; flexor carpi ulnaris; flexor subl mis digitorum; flexor profundus digitorum; flexor longus pollicis. **(b)** Posteriorly;—extensores carpi radialis longior et brevior; extensor communis digitorum; extensor indicis; extensor minimi digiti; extensor carpi ulnaris. **(c)** Radial Aspect;—supinator longus; extensor ossis metacarpi pollicis; extensor brevis (primi internodii) pollicis; extensor longus (secundi internodii) pollicis.

Arteries in Neighborhood of Wrist-joint.—Radial, with its anterior carpal, superficialis volæ, posterior carpal and metacarpal (first dorsal interosseous). Ulnar, with its anterior carpal, posterior carpal, carpal branch of anterior interosseous, posterior termination of anterior interosseous. Carpal recurrent branch from deep arch.

Veins in Neighborhood of Wrist-joint.—Superficial—anterior ulnar; posterior ulnar; radial; median. Deep—two venæ comites accompany each of the above arteries.

Nerves in Neighborhood of Wrist-joint.—Superficial—anterior and posterior branches of musculocutaneous; anterior and posterior branches of internal cutaneous; palmar cutaneous branch of median; palmar cutaneous branch of ulnar; cutaneous branch of ulnar communicating with anterior branch of internal cutaneous (frequently absent); dorsal cutaneous branch of ulnar; palmar cutaneous branch of radial; dorsal division of radial. Deep;—median; ulnar; termination of interosseous.

SURFACE FORM AND LANDMARKS OF THE WRIST-JOINT.

Articulation of the wrist-joint is on a level with the apex of the styloid process of the ulna, which is the key to the joint. The ulnar styloid process

is more distinct in pronation and the radial styloid in supination. To find the joint-line of the wrist, draw a straight line connecting the radial and ulnar styloid processes—then draw a curved line between the same points, with the highest part of the convexity 1.3 cm. (½ inch) above the straight line—this curved line will represent the dome-shaped articular line. The ulnar styloid process is more distinct in pronation—that of radial in supination.

Two or three skin-folds generally cross the palmar surface of the wrist transversely—the lowest fairly represents the upper border of the anterior annular ligament—and is about 1.3 to 2 cm. (½ to ¾ inch) below the arch of the wrist-joint.

All the muscles mentioned above under Surgical Anatomy can generally be felt and recognized about the wrist-joint—except the flexor profundus digitorum and flexor longus pollicis, of the anterior group; the extensor carpi ulnaris, of the posterior group; and the supinator longus, of the radial group.

Bony prominences of the tubercle of the scaphoid and ridge of the trapezium are generally to be felt on the anterior aspect of the radial side of the wrist—and those of the pisiform and unciform process of the unciform, on the ulnar side.

The lower end of the diaphysis of the ulna just comes to the radio-ulnar joint. The lower end of the diaphysis of the radius comes within the synovial membrane.

The tendon of the extensor longus (secundi internodii) pollicis marks the center of the lower end of the radius—and indicates the interval between the scaphoid and semilunar.

The ulnar artery, with the ulnar nerve to the ulnar side, lies on the anterior annular ligament, to the radial side of the pisiform and to the ulnar side of the hook of the unciform (in the groove between them). The deep branch of the ulnar artery arises directly below the pisiform.

The radial artery passes under the extensor tendons of the thumb, upon the external lateral ligament, winding over the outer side of the carpus from a point just below and internal to the styloid process of the radius to the base of the first interosseous space.

The superficial palmar arch is on a line with the lower border of the outstretched thumb—and the deep arch is 1.3 cm. (½ inch) higher.

GENERAL SURGICAL CONSIDERATIONS IN DISARTICULATING AT THE WRIST-JOINT.

Disarticulation at the wrist-joint is preferable to amputation through the forearm, as pronation and supination are usually retained, and the stump is better adapted to an artificial limb.

Avoid injuring the radio-ulnar articulation—which is adjacent to, but not a part of, the wrist-joint.

The styloid processes of the radius and ulna should not be removed, especially that of the radius, owing to the attachment of the supinator longus.

Disarticulation of the joint is more easily done from the dorsum.

The pisiform bone is often unconsciously removed with the flap, and it is convenient to so remove it and subsequently to dissect it out.

The best covering for the joint is from the palm, but the nature of the condition for which the operation is done will generally determine from

which aspect the covering can be gotten. Care must be exercised to cover the prominent radial styloid process. In approximating the thick palmar to the thin dorsal skin, the sutures are to be securely tied and left amply long. Drainage is indicated for twenty-four or thirty-six hours. The stump should be placed upon a splint which will steady the part and prevent pronation and supination, in a position midway between pronation and supination.

The lower epiphyses of the radius and ulna join the bones about the twentieth year.

DISARTICULATION AT THE WRIST-JOINT, IN GENERAL.

Best Methods.—Anterior Ellipse; Palmar Flap; External lateral, or radial, Flap (Dubrueil's Method).

Other Methods.—Modified Circular; Circular; Equal Palmar and Dorsal Flaps; Dorsal Flap.

Comment.—Anterior ellipse method forms the best covering, and amounts to a palmar flap. Palmar flap—rather bulky and unyielding and less adjustable. External flap—a good substantial covering, and especially adapted to cases in which the palmar covering is not available. Circular method—forms a scanty covering. Dorsal flap—warrantable when the palmar and external coverings are unavailable, but consists only of skin and tendons.

DISARTICULATION AT THE WRIST-JOINT

BY ANTERIOR ELLIPSE.

Description.—The covering raised is, practically, an anterior flap. The idea of the ellipse is appreciated after marking the outline, as given below, and then viewing it from the radial or ulnar aspect of the hand.

Position.—Patient on back, forearm abducted horizontally; hand pronated or supinated, as indicated by the stage of the operation. Surgeon sits or stands, facing the patient's hand. An assistant steadies the limb from above, and holds the parts out of the way.

Landmarks.—Line of the wrist-joint; pisiform; base of fifth metacarpal; carpo-metacarpal joint of the thumb.

Incision.—Highest point of the ellipse is upon the dorsum, 1.3 cm. (½ inch) below the line of the wrist-joint, and on a line with the middle finger. Lowest point of the ellipse is upon the palm, 6.3 cm. (2½ inches) below the line of the wrist-joint, and on a line with the middle finger. The inner portion of the ellipse crosses the ulnar border of the hand between the pisiform bone and base of the fifth metacarpal. The outer portion of the ellipse crosses the radial border of the hand at the carpo-metacarpal joint-line of the thumb. The entire incision has, therefore, a downward convexity upon the palm and an upward convexity upon the dorsum, and passes through the four above-mentioned points (Fig. 261, A).

Operation.—Supinating the hand while incising the palm, and pronating it while making the dorsal incisions, this entire ellipse, which has been made through the skin and fascia at first, is now deepened throughout. The dorsal integuments are first dissected to the joint-line. The hand is flexed and the extensor tendons, posterior ligament, and lateral ligaments are cut and the joint opened—and then the anterior ligaments. First one and then the other lateral border of the hand is made to present and the lateral parts of the ellipse carried to the bones. The knife is then carried between the

flexor tendons and the carpus, from above and within, and made to clear out the hollow of the carpus in the act of cutting its way obliquely from within downward and outward, to the margin of the palmar incision through the skin—and the hand thus severed from the arm. All loose tendons and nerves are to be cut. The following arteries are to be tied; radial, ulnar (below the deep branch), deep branch of the ulnar, superficialis volæ. The deep palmar arch and part of the superficial palmar arch are removed with

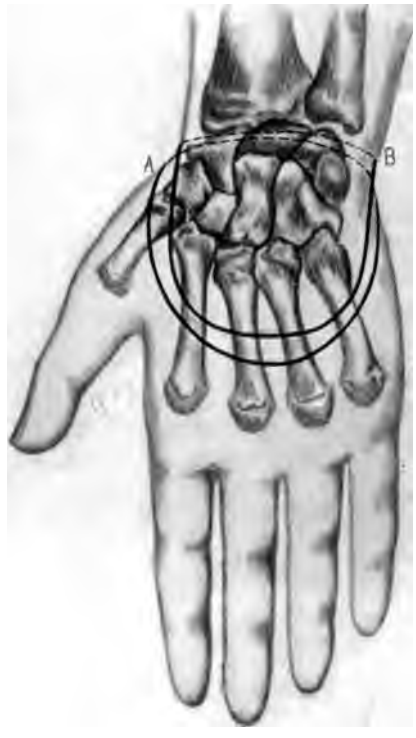

Fig. 261.—DISARTICULATIONS AT THE WRIST-JOINT:—A, By anterior ellipse; B, By palmar flap. (Palmar view.)

the hand. The convex palmar flap is sutured into the concave wound at the back of the wrist.

Comment.—The palmar covering can be entirely freed up to the joint-line before disarticulating.

DISARTICULATION AT THE WRIST

BY PALMAR FLAP.

Description.—The flap is U-shaped, and raised entirely from the palm.

Position.—As in the disarticulation by an anterior ellipse (page 304).

Landmarks.—Styloid process of radius; styloid process of ulna; middle of metacarpus.

Incision.—Palmar incision—radial limb of the U begins 1.3 cm. (½ inch)

below the radial styloid process and is directed downward along the radial border of the index. Ulnar limb of the U begins 1.3 cm. (½ inch) below the ulnar styloid process and is directed downward along the ulnar border of the little finger. These limbs are bluntly rounded at their lower ends and pass transversely toward each other so as to meet just above the center of the metacarpus. Dorsal incision—crosses the carpus in a straight line, or, better, with slightly downward convexity, between the two upper ends of the palmar incision (Fig. 261, B).

Operation.—With the hand in supination and extension, the palmar incision is deepened to the flexor tendons, the thenar and hypothenar muscles being cut through to that extent—and the palmar flap then dissected up to the joint-line, raising the flap from the bony prominences in the palm. With the hand now in pronation and the skin of the wrist drawn upward, the dorsal incision is deepened and the integuments dissected up to the joint-line, when the extensor tendons, posterior ligament, and lateral ligaments are severed and disarticulation accomplished. The flexor tendons and surrounding tissues on the palmar surface are now severed, while on the stretch, by dividing the anterior ligament from within the disarticulated joint and then cutting the flexor tendons from the dorsal toward the palmar aspect, on a line with the retracted palmar flap. The same arteries are to be tied as in the elliptical method, the deep arch and loops of the superficial arch coming away with the hand.

DISARTICULATION AT THE WRIST-JOINT

BY EXTERNAL LATERAL, OR RADIAL FLAP – DUBRUEIL'S METHOD.

Description.—A saddle-shaped flap of skin and muscles is raised from the metacarpal region of the thumb, and approximated to the disarticulated ends of the radius and ulna.

Position.—As in disarticulation by the elliptical method (page 304).

Landmarks.—Wrist-joint; first metacarpal.

Incision.—Flap-incision—begins on back of wrist, about 6 mm. (¼ inch) below the wrist-joint line, and at the junction of the outer and middle thirds of that line—passes thence downward upon the dorsal aspect of the thumb—thence rounds outward to cross the first metacarpal transversely about its middle (remaining, up to the point of rounding outward, as far from the outer border of the hand as at the beginning). The incision now passes upward correspondingly on the inner aspect of the thumb, following the inner part of the thenar eminence to a point about 6 mm. (¼ inch) below the wrist-joint line, at the junction of the outer and middle thirds of that line on the palmar surface. Disarticulating-incision—the two upper ends of this flap are connected by a transverse incision passing directly around the inner aspect of the wrist-joint (Fig. 259, P, P).

Operation.—The thenar incision, forming the flap, is deepened—the soft parts are dissected from the metacarpal, and as much of the thenar muscles as possible are taken. The soft parts upon the inner aspect of the wrist are divided to the bone by the circular incision on a level with the base of the flap. Disarticulation is accomplished from the dorsal and inner aspect, toward the palmar and outer. The following arteries are to be tied: superficial and deep palmar arches, dorsalis and radialis indicis and ulnar. The tendons and nerves are treated as in the preceding operations upon the wrist. The external or thenar flap is now brought transversely across the

articular ends of the radius and ulna, and sutured to the circularly divided parts.

SURGICAL ANATOMY OF THE FOREARM.

Bones.—Radius; ulna.

Articulations and Ligaments.—(**a**) Superior Radio-ulnar Articulation; —orbicular ligament; synovial membrane. (**b**) Middle Radio-ulnar Articulation;—oblique (round) ligament; interosseous membrane. (**c**) Inferior Radio-ulnar Articulation;—anterior radio-ulnar ligament; posterior radio-ulnar ligament; interarticular (triangular) fibro-cartilage; synovial membrane. (**d**) Elbow-joint (page 312). (**e**) Wrist-joint (page 302).

Muscles of the Forearm.—(**a**) **Anterior radio-ulnar region**:—(**1**) More Superficial Muscles;—pronator radii teres; flexor carpi radialis; palmaris longus; flexor carpi ulnaris; flexor sublimis digitorum. (**2**) Deeper Muscles; —flexor profundus digitorum; flexor longus pollicis; pronator quadratus. (**b**) **Radial region**:—supinator longus; extensor carpi radialis longior; extensor carpi radialis brevior. (**c**) **Posterior radio-ulnar region**:—(**1**) More Superficial Muscles;—extensor communis digitorum; extensor minimi digiti; extensor carpi ulnaris; anconeus. (**2**) Deeper Muscles;—supinator brevis; extensor ossis metacarpi pollicis; extensor brevis (primi internodii) pollicis; extensor longus (secundi internodii) pollicis; extensor indicis.

Arteries of the Forearm.—Radial, with radial recurrent; muscular; anterior carpal; superficialis volæ; posterior carpal branches. Ulnar, with anterior ulnar recurrent; posterior ulnar recurrent; common interosseous; anterior interosseous; posterior interosseous; muscular; anterior carpal; posterior carpal branches.

Veins of Forearm.—Superficial—median; median cephalic; median basilic; deep median; radial cephalic; cephalic; anterior ulnar; posterior ulnar; common ulnar; basilic. Deep—two venæ comites accompanying each of above arteries.

Nerves of Forearm.—Superficial;—musculocutaneous; internal cutaneous; external cutaneous branch of musculospiral; cutaneous branch of ulnar; dorsal cutaneous branch of ulnar; cutaneous branches of radial. Deep;—ulnar and its muscular branches; median and its muscular branches; muscular branches of musculospiral; radial branch of musculospiral; posterior interosseous branch of musculospiral.

SURFACE FORM AND LANDMARKS OF THE FOREARM.

Olecranon and posterior border of upper part of ulna are subcutaneous —and the entire shaft is to be felt down to the styloid process, passing from the center of the forearm above to the ulnar side of the wrist below, and lying between the flexor and extensor carpi ulnaris. The ulnar styloid process is best felt with the forearm midway between flexion and extension, being continuous with the posterior subcutaneous border of the bone.

Head of the radius is felt just below and a little in front of the posterior surface of the external condyle, revolving in the orbicular ligament and lesser sigmoid cavity—marked by a dimple in the skin posteriorly, best seen when the arm is extended. The lower half of the radius can be outlined, though not subcutaneous—the outer aspect of the lower part alone being subcutaneous, and ending in the radial styloid process. The radius is deeply covered above

and superficially covered below. Opposite a point in the forearm where one bone is most slender, the opposite bone is most substantial—both being about equal in the middle. The radius and ulna are everywhere nearer the posterior than anterior aspect of the forearm, and increasingly so above. They are nearest each other in complete pronation and furthest in complete supination.

Flexor and pronator muscles form the muscular elevation upon the inner side of the elbow and forearm—the extensor and supinator muscles forming a corresponding elevation upon the outer and posterior side of the elbow and forearm. These two groups diverge above toward the condyles of the humerus and converge below toward the center of the forearm—the supinator longus forming the outer boundary and the pronator radii teres the inner boundary of the triangular space at the bend of the elbow. Of the muscles of the internal group, the pronator radii teres, flexor carpi radialis, palmaris longus, flexor carpi ulnaris, alone influence surface form, the remainder being unrecognizable. The external group of muscles divides into two longitudinal eminences, diverging from each other, with a triangular interval between them:—the outer, consisting of the supinator longus, extensor carpi radialis longior and brevis, descending from the outer condyloid ridge toward the radial styloid process;—the other, more posterior, consisting of the extensor communis digitorum, extensor minimi digiti, extensor carpi ulnaris, descending from the external condyle, separated above from the anconeus by a furrow, and below from the pronator-flexor mass by the ulnar furrow. In the triangular interval between these two groups the extensor ossis metacarpi pollicis, extensor brevis pollicis, extensor longus pollicis, and extensor indicis pass downward. The anconeus forms a slight prominence external to the subcutaneous posterior surface of the olecranon.

In the muscular, the transverse is much greater than the antero-posterior diameter of the forearm—and the downward tapering is marked. In the non-muscular, the forearm is more rounded and the tapering is less. Above, the muscles are found chiefly at the sides and in front;—below, more equally along the anterior and posterior aspects—hence flap amputations are more adapted to the upper and circular amputations to the lower part of the forearm.

The three chief pronators of the forearm are, the pronator radii teres, pronator quadratus, and flexor carpi radialis. The three chief supinators are, the supinator longus, supinator brevis, and biceps.

GENERAL SURGICAL CONSIDERATIONS IN AMPUTATIONS ABOUT THE FOREARM.

For the purposes of amputation, the forearm may be divided into two natural regions, a lower one-third and an upper two-thirds—the former being characterized by an almost even contour of similar dimensions throughout—the latter, especially in the muscular, by its rapidly increasing measurements up to from 2.5 to 5 cm. (1 to 2 inches) below the elbow, and with a slight decrease thence to the elbow-joint. Therefore, on this account, and because of the grouping of the muscles, amputation-methods are described as applicable to "the lower third" and "the upper two-thirds." (In this connection, see the last paragraph from the bottom, in the above section.)

The general type of amputation most suitable for the lower third of the

forearm is the circular method—and the general type most suitable for the upper two-thirds is the flap method.

Saving of the smallest part of the forearm, with its movement, is preferable to disarticulation at the elbow.

If possible, the bones should be sawed below the insertion of the pronator radii teres, otherwise the radius will become supinated and rotatory movements lost.

Owing to the tendency of the bones to project through the angles of the flaps, the flaps at their bases and their lower ends should be made fully long.

In cutting by transfixion the interosseous membrane is apt to be pierced.

A terminal cicatrix is here desirable, as best adapted to an artificial limb.

The stump should be dressed with the forearm midway between pronation and supination, and the elbow steadied by a right-angled splint.

AMPUTATION OF THE FOREARM, IN GENERAL.

Best Methods.—Modified Circular—for the lower third. Equal Anterior and Posterior Flaps—for the upper two-thirds.

Other Methods.—Long Anterior Flap—where the posterior tissues are deficient. Long Posterior Flap—where the anterior tissues are deficient. Long Anterior and Short Posterior Flap. Rectangular Flaps (Teale s method). External Lateral Flap—where the internal tissues are deficient. Equilateral Skin-flaps. Circular Skin-flap. Circular.

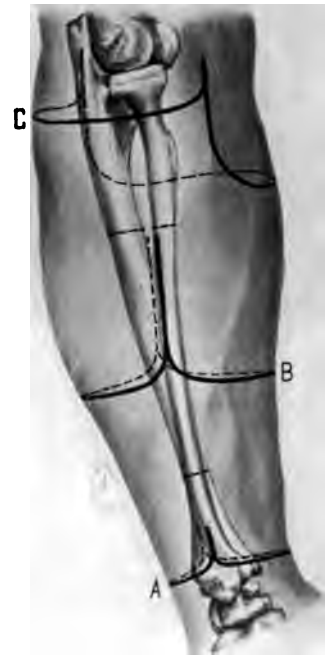

Fig. 262.—AMPUTATIONS THROUGH FOREARM AND AT ELBOW:—A, Through lower part of forearm, by modified circular; B, Through upper forearm, by equal anterior and posterior flaps; C, At elbow-joint, by long antero-internal and short postero-external flaps.

AMPUTATION OF LOWER THIRD OF FOREARM

BY MODIFIED CIRCULAR METHOD.

Description.—Two short flaps of skin and fascia are turned back and the muscles are then circularly divided at the level of the retracted skin-and-fascia flaps.

Position.—Patient supine, near edge of table, with upper limb abducted to a right angle—and held by an assistant in supination during anterior incisions, and in pronation, or vertically, during posterior incisions. Surgeon to outer side of right limbs and inner side of left.

Landmarks.—Saw-line.

Incision.—The total covering is to be 1½ diameters of the forearm at the saw-line. The anterior and posterior aspects will each furnish three-fourths of a diameter. One-half of this three-fourths diameter length will be of skin and fascia alone, on each side—the remaining half of skin, fascia,

and muscle. Therefore a point below the saw-line equal to three-fourths of a diameter at the saw-line will mark the lowest limit from which the covering is to be provided. Two small flaps are incised, each having a base equal to a half-circumference, and a length equal to half (the lower half) of the distance between the saw-line and the lowest limit of the skin incision. These flaps will be bluntly rounded at their lower ends (Fig. 262, A).

Operation.—Dissect up the integumentary flaps half-way to the saw-line—retract them, and, on a level with the retracted flaps, circularly divide the muscles to the bone. This circular incision also divides the periosteum and interosseous membrane. The muscles and periosteum are then retracted to the saw-line—and the bones divided, completing the section of the more movable radius first. Tie the radial, ulnar, anterior and posterior interosseous arteries. Stitch the musculo-periosteal covering over the bones. Quilt the muscles or tendons of the anterior to those of the posterior aspect of the forearm if possible. Suture the integumentary coverings in a straight line antero-posteriorly.

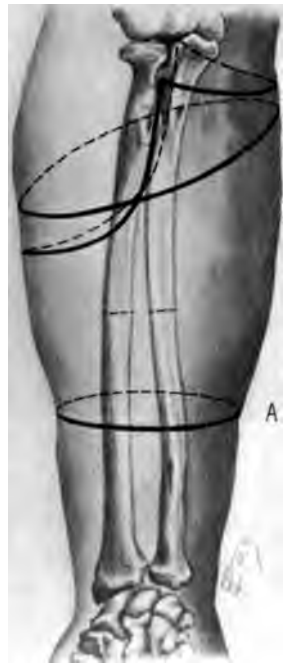

Fig. 263.—AMPUTATIONS ABOUT FOREARM AND ELBOW:—A, Through middle of forearm, by circular method; B, At elbow-joint, by single external flap; C, At elbow, by oblique circular method.

Comment. — The preponderance of tendinous over muscular tissues here makes the infundibular variety of the modified circular difficult or impossible.

AMPUTATION OF LOWER THIRD OF FOREARM

BY CIRCULAR METHOD (CUFF VARIETY).

Description.—The cuff variety of the circular amputation is here done (see under Comment). A cuff of skin, circularly cut, is turned back—and the muscles circularly divided on a level with the reflected skin—the ends of the bones being covered by skin and fascia alone.

Position.—As in the last operation.

Landmarks.—Saw-line.

Incision.—Circular cut, placed three-fourths of a diameter (at the saw-line) below the line of bone-section—thus making a total covering of 1½ diameters, as each side may be regarded as furnishing one-half of the covering. (For principle, see Fig. 263, A.)

Operation.—This circular incision divides the skin and fascia, which are then dissected up, the forearm being vertical while the posterior dissection is done. This dissection and turning back of the flap is continued up to a distance below the saw-line which will leave space to provide a musculo-periosteal covering. Here, after well retracting the integumentary coverings, the muscles are divided circularly to the bone,—extending the hand while the flexors are cut and flexing it while the extensors are being severed. A circular cut is made through the periosteum, around each bone, on a level with the cut muscles—the interosseous membrane is divided transversely—

and a musculo-periosteal covering is freed up to the saw-line, with a periosteal elevator, from each bone. All soft parts are now retracted and the bones sawed, completing the section of the more movable radius first. Tie the radial, ulnar, anterior and posterior interosseous arteries. Cut the tendons (which are here especially numerous) and the nerves short. Suture the musculo-periosteal covering over the bones—and stitch the skin and fascia in a vertical antero-posterior or lateral direction.

Comment.—(1) Owing to the predominance of tendons in this locality, the infundibuliform variety of the circular method is impracticable. (2) The above operation is very similar to the modified circular method just described, which is generally considered better than the present form, in this locality. The cuff method, indeed, is not possible if the limb tapers very decidedly at the site involved. (3) A musculo-periosteal covering is specially indicated here, as being the best means of guarding against a fusion of the cut edges of the bones and consequent loss of pronation and supination. (4) As the large mass of tendons is difficult to cut squarely by a circular incision, a long, narrow knife may be slipped under them, and they may then be cut directly upward from within—or they may be divided with strong, sharp scissors.

AMPUTATION OF UPPER TWO-THIRDS OF FOREARM

BY EQUAL ANTERIOR AND POSTERIOR FLAPS.

Description.—The anterior and posterior aspects of the forearm furnish equal U-shaped flaps of skin and muscle—the anteriorly largely composed of supinator longus and flexors,—the posterior largely made up of extensors.

Position.—As in the modified circular method (page 309).

Landmarks.—Saw-line.

Incisions.—An anterior and a posterior U-shaped flap are incised on the respective aspects of the forearm, the base of each flap at the saw-line being equal to a half-circumference of the limb at that line, and the length of each equal to three-fourths of the diameter—the hand being supinated in making the anterior flap, and the forearm vertical in making the posterior flap (Fig. 262, B).

Operation.—Having cut through skin and fascia in outlining the flaps, these incisions are now deepened upon the line of the retracted skin, beginning at the ulnar side of the anterior flap, in case of the right arm (and on the radial side upon the opposite arm). The vertical ulnar incision will involve the flexor carpi ulnaris and flexor profundus—the vertical radial incision will involve the two radial carpal extensors—both vertical incisions passing directly to the bones. The muscles on the anterior and posterior aspects of the forearm, at the lower rounded extremities of the flaps, are cut from without inward in such a manner as to bevel them slightly. The entire flaps are now raised from the bones up to a point sufficiently below the saw-line to furnish a musculo-periosteal covering—at which level the periosteum is circularly divided around the bones—the interosseous membrane cut transversely—and the musculo-periosteal covering freed to the saw-line. The soft parts are then retracted and the bones sawed. The radial, ulnar, anterior and posterior interosseous arteries are tied. The median, radial, and ulnar nerves should be cut short, or even dissected from the flap. The musculo-periosteal covering is sutured and the muscles quilted—and the integuments sutured in a lateral line.

Comment.—These flaps may be less satisfactorily cut by transfixion—in which method, also, the interosseous membrane is apt to be pierced.

SURGICAL ANATOMY OF THE ELBOW-JOINT.

Bones.—Humerus, radius, and ulna.

Articulations and Ligaments.—(a) Of the Elbow-joint;—anterior, posterior, internal lateral and external lateral ligaments, and synovial membrane. (b) Of the Superior Radio-ulnar Joint;—orbicular ligament, and synovial membrane.

Muscles in Neighborhood of Elbow.—(A) Muscles arising a greater or lesser distance above elbow and inserted below elbow:—(a) On anterior aspect;—biceps and brachialis anticus. (b) On posterior aspect;—triceps and subanconeus. (c) On radial aspect;—supinator longus and extensor carpi radialis longior. (B) Muscles arising from inner condyle of humerus and inserted into forearm and hand;—pronator radii teres, flexor carpi radialis, palmaris longus, flexor carpi ulnaris, flexor sublimis digitorum. (C) Muscles arising from outer condyle of humerus and inserted into forearm and hand;—extensor carpi radialis brevior, extensor communis digitorum, extensor minimi digiti, extensor carpi ulnaris, anconeus and supinator brevis.

Muscles in Direct Relation with Elbow-joint.—Anteriorly; brachialis anticus. Posteriorly; triceps and anconeus. Externally; supinator brevis and common tendon of origin of extensor muscles. Internally; common tendon of origin of flexor muscles.

Arteries in Neighborhood of Elbow.—Brachial, with superior profunda, inferior profunda, and anastomotica magna branches. Radial, with radial recurrent branch. Ulnar, with anterior ulnar recurrent and posterior ulnar recurrent branches.

Veins in Neighborhood of Elbow.—Superficial;—median, median basilic, median cephalic, deep median, radial, cephalic, anterior ulnar, posterior ulnar, and common ulnar. Deep;—Two venæ comites accompanying each of above arteries.

Nerves in Neighborhood of Elbow.—Superficial;—musculocutaneous, internal cutaneous, lesser internal cutaneous, external cutaneous, and branches of musculospiral. Deep;—ulnar, median, radial and posterior interosseous branches of musculospiral.

Bicipital Fascia.—A broad aponeurosis given off from inner side of tendon of biceps, opposite bend of elbow—and passing between the brachial artery and superficial veins and nerves of elbow obliquely downward and inward to become continuous with the deep fascia of forearm, fastening down the flexor muscles.

Bursæ in Neighborhood of Elbow.—Between olecranon and skin, and between olecranon and triceps.

Epiphyses.—Portion of epiphysis forming radial condyle and trochlea is within the capsule of the joint—that forming the two condyles is without. The epiphyses for the trochlea and external condyle blend and join shaft about sixteenth or seventeenth year—that for internal condyle, about eighteenth year. The upper epiphysis of radius forms the head—is within the joint—and joins shaft about sixteenth or seventeenth year. The olecranon is chiefly formed by diaphysis—an epiphysis occurs in its summit from the tenth to twelfth year—joins shaft about sixteenth or seventeenth year—anteriorly the epiphysis being intersynovial, and posteriorly subperiosteal.

Movements of Elbow-joint.—(1) Flexion—by biceps, brachialis anticus, aided by muscles having origin from internal condyle of humerus and by supinator longus. (2) Extension—by triceps, anconeus, aided by extensors of wrist and by extensor communis digitorum and extensor minimi digiti.

SURFACE FORM AND LANDMARKS OF THE ELBOW.

Position of radio-humeral line, and hence the joint-line of the elbow, may be found by feeling for the depression between the head of the radius and capitellum of the humerus at the back of the elbow, marked by a dimple in the integument in the interval between the anconeus to the ulnar side, and the muscular mass of supinator longus and two carpal radial extensors to the radial side.

The humero-radial articulation is horizontal—the humero-ulnar articulation slopes slightly downward.

The fold of the elbow, more prominent when the forearm is semi-flexed, is a little above the level of the joint, and forms the base of the triangular fossa below the elbow, whose sides are formed by the supinator longus and pronator radii teres.

The inner condyle of the humerus is the more prominent and is a little more than 2.5 cm. (1 inch) above the elbow-joint. The outer condyle is 2 cm. (¾ inch) above.

When the forearm is fully extended, the inner condyle, tip of olecranon, and external condyle are all on the same transverse line (in extreme extension, the tip of the olecranon is slightly above);—when the forearm is flexed to a right angle, the tip of the olecranon is directly below the condyles;—when the forearm is completely flexed, the tip of the olecranon is below and in front of the condyles.

A line connecting the two condyles forms a right angle with the axis of the arm—and an angle with that of the forearm.

The upper part of the olecranon is covered by the triceps—the lower part is subcutaneous, and separated from the skin by a bursa.

Three eminences are present upon the anterior aspect of the elbow region; —the biceps above and in the center—the supinator longus and common extensor group on the outer—and the pronator radii teres and common flexor group upon the inner side.

The ulnar nerve and posterior ulnar recurrent artery lie in a deep groove between the olecranon and inner condyle of the humerus.

The anterior integument of the elbow is thin and retractile—the posterior integument loose and but little retractile.

GENERAL SURGICAL CONSIDERATIONS IN DISARTICULATING AT THE ELBOW-JOINT.

The stump after disarticulating at the elbow-joint is better for the adaptation of an artificial limb than after amputation through the arm.

To find the elbow-joint—place the thumb just beneath the external condyle of the humerus and, grasping the wrist with the right hand, pronate and supinate the forearm—when the upper limit of the radial head will be found about 1.3 cm. (½ inch) below the external condyle.

The joint is entered and disarticulated more easily from the outer side.

The muscles on the outer side of the elbow retract more powerfully than those upon the inner side, chiefly owing to the presence of the supinator longus.

The lower end of the humerus is so large that a liberal allowance of covering is necessary. And a more liberal covering has to be provided for the inner than for the outer condyle of the humerus—incisions, therefore, are longer on the inner aspect.

The skin posteriorly is used to pressure—but the muscles here are not so available for padding as in front.

Temporary drainage should be used after disarticulation. The stump should be elevated upon a splint.

DISARTICULATIONS AT THE ELBOW, IN GENERAL.

Best Methods.—Anterior Ellipse—best, where ample sound tissue exists; well nourished and thick enough to cover bones well; cicatrix well placed; but requires considerable tissue; skin-pouch over the olecranon is apt to be left. Posterior Ellipse—best where anterior tissue is unavailable; covering thin and uneven, though used to pressure. Long Antero-internal and Short Postero-external Flaps—cover disarticulated end of humerus well; especially indicated where both lateral aspects of forearm can furnish covering and neither anterior nor posterior can supply the large amounts of tissue necessary for the elliptical methods.

Other Methods.—Circular. Modified Circular. Anterior Flap. Posterior Flap. Long Anterior and Short Posterior Flaps. Short Anterior and Long Posterior Flaps. Single External Flap. Equal Lateral Flaps. Unequal Lateral Flaps. Lateral Skin Flap. Racket Method. Of these methods, the circular requires the least sacrifice of parts, but the resulting covering is not so satisfactory.

DISARTICULATION OF ELBOW-JOINT

BY ANTERIOR ELLIPSE—FARABEUF.

Description.—The covering is, essentially, an anterior flap—the idea of the ellipse being gotten in viewing the outlined incision laterally. The lower anterior convexity of the covering is sutured into the upper posterior concavity.

Position.—Given in the course of the operation.

Landmarks.—Joint-line; prominence of olecranon; eminence of supinator longus on anterior aspect of forearm.

Incision.—The highest point of the ellipse is posterior, over the prominence of the olecranon. The lowest point of the ellipse is anterior, over the eminence of the supinator longus, just above the middle of the forearm. Midway between the upper and lower rounded ends of the ellipse the lateral borders of the ellipse pass along the mid-lateral aspects of the forearm (Fig. 264).

Operation.—The surgeon stands on the left of either right or left elbow (which will place the patient's elbow on his right)—grasping his wrist with his left hand, and flexing the elbow, so rotates the limb as to make the entire elliptical incision without relaxing his hold of the wrist, or removing the knife, which passes from olecranon to olecranon. Taking the right limb, for instance, turn the slightly flexed elbow so as to present the radial aspect—

enter the knife at the apex of the olecranon—pass down the radial lateral aspect—across the lower end of the ellipse, on the anterior aspect of the forearm (with the forearm extended and supine)—then along the inner aspect (with elbow again flexed and the inner aspect of the forearm thereby made to present) and upward to the olecranon. The skin and fascia upon the proximal side of the lower end of this incision are now further retracted by hand. On the line of the retracted integuments the muscles are then cut obliquely from without inward and upward toward the joint, in such a manner as to bevel the anterior covering which is being raised—and, at the same time, raise as much of a capsulo-periosteal covering as possible. This anterior flap is dissected and retracted upward to the joint-line. The anterior lateral and posterior ligaments of the joint are now cut in order. The triceps and any remaining posterior tissues are severed. The radial, ulnar, interosseous, muscular branches, and, possibly, the posterior ulnar recurrent and terminations of the superior and inferior profunda are ligated. Quilt the muscles in the anterior flap to the fascia along the margins of the upper half of the ellipse. Suture the integumentary tissues of the convex lower end of the flap into those of the upper concavity. Temporary drainage is indicated.

Comment. — After the integuments are incised, the muscles are sometimes, though less satisfactorily, cut by thrusting a long knife through the limb opposite the anterior aspect of the joint and cutting from within outward on a line with the retracted skin.

Fig. 264. — DISARTICULATION AT ELBOW-JOINT :—By anterior ellipse.

DISARTICULATION OF ELBOW-JOINT

BY POSTERIOR ELLIPSE.

Description. — The covering is, practically, a posterior flap—the idea of the ellipse being seen in a lateral view of the incision.

Position. — Given in the course of the operation.

Landmarks.—Joint-line; tip of olecranon.

Incision.—The highest point of the ellipse is anterior, opposite the lower margin of the joint-line. The lowest part is posterior, between 8 and 10 cm. (3 and 4 inches) below the joint-line. Midway between the upper and lower rounded ends of the ellipse, the lateral borders of the ellipse pass along the mid-lateral aspects of the forearm. With the elbow flexed to an angle of 135 degrees, the lateral parts of the incision will be parallel with the prolonged anterior aspect of the arm (Fig. 265).

Operation.—The surgeon stands on the right of either elbow, grasping the patient's wrist with his left hand (the back of his hand uppermost and his thumb toward the patient's fingers), and manipulates the elbow so as to complete the incision at one sweep—beginning the incision at the anterior joint-line with the elbow flexed at the above angle—passing down the inner aspect (while that part is manipulated so as to render it prominent)—crossing

the dorsal aspect (while the forearm is held vertical)—ascending the outer aspect (while that aspect is made prominent)—to the place of beginning. Upon the line of the retracted integuments, the deeper parts are now cut. Those along the posterior aspect of the ellipse are divided, together with the periosteum, and including the anconeus, and insertion of the triceps when reached, and are dissected up to just above the tip of the olecranon. The deeper parts along the anterior portion of the ellipse are then divided, corresponding with the joint-line, and the capsule of the joint divided transversely, followed by division of the lateral ligaments and posterior portion of the capsule (unless a capsulo-periosteal covering can be raised). Tie the brachial, posterior interosseous, muscular branches and terminations of the superior and inferior profunda. Cut the ulnar nerve especially short. Quilt the muscles in the posterior flap to the fascia along the margins of the upper half of the ellipse. Drain temporarily. Suture the integuments of the lower portion of the ellipse (the convexity) of the posterior flap, to the upper concavity of the incision.

Fig. 265. — Disarticulation at Elbow:—By posterior ellipse.

Comment. — Transfixion of the lower part of the posterior flap is even less advisable than transfixion in the anterior ellipse—as, in the former case, the bone is almost subcutaneous.

DISARTICULATION OF ELBOW-JOINT

BY LONG ANTERO-INTERNAL AND SHORT POSTERO-EXTERNAL FLAPS.

Description.—A method of unequal lateral flaps of skin and muscles—the incisions themselves are lateral, the bulk of the muscles being antero-internal and postero-external.

Position.—The forearm is held in supination during anterior incisions—and vertical during posterior incisions, or partly flexed.

Landmarks.—Elbow joint-line; tip and base of olecranon.

Incisions.—Antero-internal incision—begins at center of anterior aspect of the joint-line—passes obliquely downward and inward over the forearm, in such a way as to meet the mid-lateral aspect of the forearm, on the ulnar side, at a distance of about 7.5 cm. (3 inches) below the joint-line—thence passes upward and backward along a corresponding line to the base of the olecranon. Postero-external incision—a shorter incision but very similar to the longer, passes between the same points, crossing the mid-lateral aspect of the forearm, on the radial side, about 2.5 cm. (1 inch) below the joint-line (Fig. 262, C).

Operation.—Along the line of these retracted integuments the muscles are cut obliquely down to the bone—when they, and as much of the periosteum as possible, are dissected up to the joint-line in front, and to the tip of the olecranon behind. The elbow is then flexed—the triceps is divided at its

attachment to the olecranon—and disarticulation completed by dividing the posterior, lateral and anterior ligaments, in order. Tie the brachial, terminations of the superior and inferior profunda, and, possibly, some small muscular and articular branches. The large antero-internal flap folds over the articular end of the humerus—its muscles are to be quilted to those of the smaller flap—and the integuments of the two flaps sutured—placing the cicatrix upon the externo-terminal aspect of the joint.

Fig. 266. — DISARTICULATION AT ELBOW:—By long anterior and short posterior flaps.

Fig. 267. — DISARTICULATION AT ELBOW:—By long posterior and short anterior flaps.

SURGICAL ANATOMY OF THE ARM.

Bones.—Humerus.

Muscles of the Arm.—(**A**) Anterior Humeral Region:—coracobrachialis, biceps, brachialis anticus. (**B**) Posterior Humeral Region:—triceps, subanconeus. (**C**) Muscles having their insertions in upper portion of humerus:—supraspinatus, infraspinatus, teres minor, subscapularis, pectoralis major, latissimus dorsi, deltoid, teres major. (**D**) Muscles having their origin from lower portion of humerus:—(**a**) From internal condyle and ridge:—pronator radii teres, flexor carpi radialis, palmaris longus, flexor carpi ulnaris, flexor sublimis digitorum—(**b**) From external condyle and ridge:—supinator longus, extensor carpi radialis longior, extensor carpi radialis brevior, extensor communis digitorum, extensor minimi digiti, extensor carpi ulnaris, anconeus, supinator brevis.

Arteries of Humeral Region.—From Axillary:—acromial and humeral branches of acromial thoracic, subscapular, anterior circumflex, posterior circumflex, and axillary itself. From Brachial:—superior profunda, nutrient,

inferior profunda, anastomotica magna, muscular, and brachial itself. From Radial:—radial recurrent. From Ulnar:—anterior ulnar recurrent, posterior ulnar recurrent.

Veins of Humeral Region.—Superficial:—cephalic, basilic, Deep:—two venæ comites accompany each of above branches of main arteries, and also brachial artery. Axillary vein is formed by two brachial venæ comites and basilic vein.

Nerves of Humeral Region.—Anteriorly:—musculocutaneous, median, internal cutaneous, ulnar, lesser internal cutaneous, intercosto-humeral. Posteriorly:—circumflex, musculospiral.

SURFACE FORM AND LANDMARKS OF THE ARM.

The humerus is almost entirely covered by muscles, being subcutaneous only at the internal and external condyles. The greater and lesser tuberosities and the head may be defined. The greater tuberosity lies just below the antero-external aspect of the acromion. The lesser tuberosity lies to the inner side of and below the greater, the bicipital groove intervening. To feel the head of the bone, abduct the arm, when the head will project prominently into the axilla.

The internal condyle and internal condyloid ridge, and external condyle and external condyloid ridge, can be felt just above the elbow-joint. The latter are more easily felt during semiflexion, as a depression between adjacent muscles.

The greater tuberosity and external condyle are in the same straight line and face in the same direction. The head of the humerus and the internal condyle are also in the same straight line and likewise face in the same direction.

When the arm hangs by the side, the bicipital groove looks directly forward.

The rough prominence upon the outer aspect of the middle of the humerus, into which the deltoid is inserted, also marks the level of the insertion of the coracobrachialis and the origin of the brachialis anticus—and also the entrance of the nutrient artery into the bone, and the level at which the musculospiral nerve and superior profunda artery cross the back of the bone.

The upper epiphysis is horizontal and placed just above the surgical neck, joining the shaft at the twentieth year.

The coracobrachialis and biceps above, and the biceps below, form the prominent muscular mass of the front of the arm. The brachialis anticus is discernible at the lower part of the arm, on each side of the biceps.

The triceps determines the form of the back of the arm. The inner head is least distinct. The outer head forms the large prominence just below the posterior border of the deltoid. The long head emerges from between the teres major and minor and descends along the back of the arm.

The supinator longus and extensor carpi radialis longior form a prominence on the outer side of the lower portion of the arm.

Above the middle of the arm, the biceps, deltoid, coracobrachialis, and long head of triceps are more or less free and capable of retraction. Below the middle of the arm, the biceps is the only free muscle. It is for this reason that the circular method of amputation is suitable only to the lower half of the arm.

In women and in fat persons the contour of the arm is more rounded

and more nearly of one size throughout. In the muscular, it is less regular and more flattened laterally.

On the inner and outer sides of the biceps are found the inner and outer bicipital furrows—the cephalic vein occupying the latter—and the brachial artery and basilic vein the former.

The superior profunda artery arises just below the outlet of the axilla—the inferior profunda opposite the center of the shaft—and the anastomotica magna about 5 cm. (2 inches) above the bend of the elbow.

The skin is most retractile over the inner aspect of the arm.

GENERAL SURGICAL CONSIDERATIONS IN AMPUTATIONS ABOUT THE ARM.

The shortest stump of an arm, even an amputation at the surgical neck, is better than a shoulder-joint disarticulation—as such a stump will ordinarily be able to move an artificial limb. It is, therefore, desirable to retain as much of the humerus as possible, as leverage for the artificial limb.

From the standpoint of the amputator, the arm may be divided into two natural regions—a lower third, more or less cylindrical, and where the muscles are largely attached to bone—and an upper two-thirds, more or less conical, flattened or irregular, and where the muscles are largely free and capable of retraction. Therefore a circular method of amputation is preferable for the lower third, and a flap method for the upper two-thirds.

The surgical neck of the humerus marks the height at which a useful stump can be obtained, as the capsule extends down to its level internally.

In amputating at the surgical neck, the bone is sawed between the tuberosities, and insertions of the pectoralis major and teres major. The supraspinatus, infraspinatus, teres minor, and subscapularis are left attached to the head of the humerus. The bone is sawed below the epiphyseal line. The synovial membrane of the joint (accompanying the biceps tendon) is apt to be opened on the inner aspect, where it is lowest. The bursa under the subscapularis tendon generally communicates with the joint and may be opened during the operation. As much of the attachment of the pectoralis major, teres major, and latissimus dorsi as possible is raised with the periosteum, so as to be included in the musculo-periosteal covering of the end of the bone and in the quilting of the muscles, in order to retain the attachments of these muscles upon the stump and, therefore, their action upon the artificial limb.

In an amputation through the upper two-thirds by an anterior flap twice as long as the posterior, the scar will eventually be terminal, owing to the much greater retraction of the anterior parts—the biceps contracting most of any muscle. A terminal cicatrix is sought in the stumps of the arm.

The stump should be dressed upon a splint.

For control of hemorrhage in amputating at the shoulder joint, see page 325.

AMPUTATION OF THE ARM, IN GENERAL.

Best Methods.—Modified Circular—best for the lower third. Long Anterior and Short Posterior Flaps—best for the upper two-thirds. Single External Flap—best at the surgical neck.

Other Methods.—Simple Circular (infundibular form). Single Anterior

Flap (Malgaigne's method). Anterior Ellipse (practically an anterior flap). Posterior Ellipse (practically a posterior flap). Lateral Flaps (of skin and muscles). Rectangular Flap (Teale's method). Oval Method (at the surgical neck)

AMPUTATION THROUGH THE LOWER THIRD OF THE ARM

BY MODIFIED CIRCULAR METHOD.

Description.—Two short skin-flaps are cut and turned back, and the muscles divided circularly in the infundibular manner.

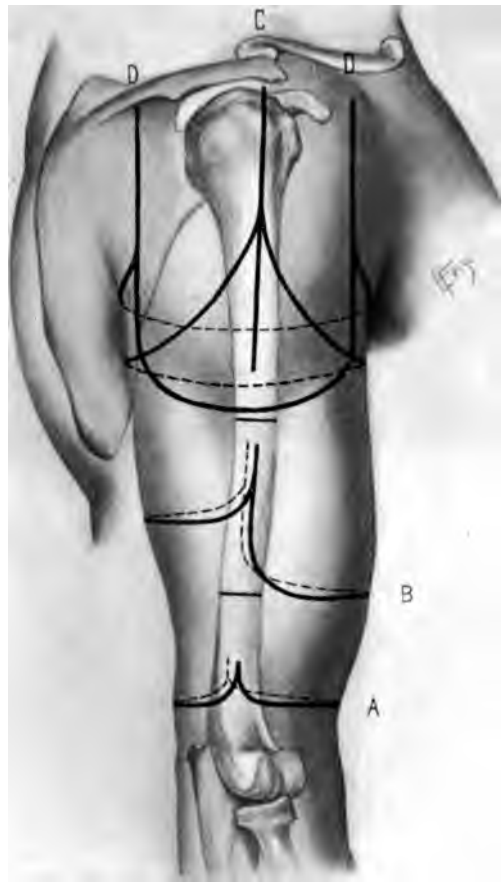

Fig. 268.—Amputations through Arm and at Shoulder:—A, Through lower part of arm, by modified circular; B, Through upper part of arm, by long anterior and short posterior flaps; C, At shoulder-joint, by external racket method (Larrey's operation); D, D, At shoulder, by external, or deltoid, flap (Dupuytren's operation).

Position.—Patient supine, at edge of table; limb horizontally abducted over the edge of table during anterior incisions, and held vertically, with bent elbow, or drawn over the chest, in dorsal incisions. Surgeon on outer

side of origin and inner side of arm bone. Assistant steady the limb above and below the site of amputation.

Landmarks.—Saw-line.

Incision.—The lowest limit of the skin incision is taken at a distance below the saw-line equal to one-fourth of the diameter of the limb at the saw-line, thus securing a covering of its diameter. At this distance the small flaps will occupy approximately the lower one-third. These flaps are generally anterior and posterior, but may be taken at any intermediate position, as the local conditions may demand. They take in one-half the circumference of the limb—they may come in larger extent of the limb to nearly their lower limit when they would come transverse across the limb to a corresponding point on the opposite side. The anterior and posterior flaps are similar (Fig. 268, A).

Operation.—These flaps of skin and fascia are freed up to their base and turned back as cuffs. Then the more superficial muscles are similarly divided, and retracted in turn. Upon the line of these retracted superficial muscles, the deeper muscles are cut to the bone—at a level still nearer the saw-line. This last circular division also divides the periosteum around the entire bone. All the soft parts, including the periosteum, are now freed up to the saw-line and the bone divided. Tie the brachial, superior profunda, inferior profunda, muscular, and possibly the anastomotic main branches. See that the musculospiral nerve is clearly divided and avoid any portion of it apt to be pressed upon in bending the flap over the end of bone. Suture the musculo-periosteal covering. Quilt the muscles. Suture the flaps in a lateral line.

Comment.—(1) The modified circular method makes it easier to free the bone of soft parts up to the saw-line, and also furnishes a more symmetrical terminal covering. If necessary, the skin-flaps may represent one-half of the distance between the saw-line and the lowest limit of the skin-incision. (2) The simple circular method, the mandalinar form may be done here in small limbs with flabby coverings—but would be difficult in large limbs with firm coverings. When the mandalinar circular method is used, it should be an oblique circular, the circle dipping lower on the anterio-internal aspect of the arm, where, owing to greater retraction, it will be subsequently drawn up to the level with the outer part.

AMPUTATION OF THE UPPER TWO-THIRDS OF THE ARM

BY LONG ANTERIOR AND SHORT POSTERIOR FLAPS

Description.—Two U-shaped flaps of skin and muscle are raised, the posterior being one-half the length of the anterior.

Position.—As in the last operation.

Landmarks.—Saw-line.

Incisions.—The base of each flap equals one-half circumference at the saw-line. The length of the anterior flap is equivalent to one diameter at the saw-line. And the length of the posterior flap is one-half the diameter. Both are U-shaped flaps. Care is taken to place these flaps so that the brachial artery will not be apt to be split—the vessel should be in the posterior flap, and the points of junction of the two flaps on the inner and outer aspect of the arm should be so shifted toward the outer side as to make the scars. The arm is raised vertically while the posterior flap is being marked out and incised (Fig. 268, B).

Operation.—Having incised skin and fascia along the above lines, the muscles are divided along the retracted integumentary coverings—cutting to the bone along the vertical limbs of the flaps, and cutting obliquely inward and upward along the rounded transverse endings of the flaps, in a bluntly beveled fashion—coming down upon the bone sufficiently far below the saw-line to provide a periosteal covering, which, with the muscles, is freed up to the saw line—and the bone divided. Care is taken to divide the musculo-spiral nerve evenly and short—as well as the nerves in the anterior flap which bend over the end of the bone, partially excising them if necessary. Tie the brachial, superior profunda, and inferior profunda, and muscular branches. Quilt the muscles of the anterior to those of the posterior flap—the former chiefly covering the end of the bone. Suture the skin margins of the flaps. The limbs should be steadied by a splint which also includes the shoulder.

AMPUTATION OF ARM AT SURGICAL NECK

BY SINGLE EXTERNAL FLAP.

Description.—A U-shaped flap, composed chiefly of deltoid, is raised from the outer aspect of the arm, while the parts on the inner aspect are divided transversely, or with slight downward convexity, on a level with the upper limit of the limbs of the flap.

Position.—As in the above operations—the limb being drawn well away from the body, which will give access to both outer and inner aspects.

Landmarks.—Surgical neck of humerus (just below the tuberosities).

Incisions.—Flap incision—the base of the flap, which is U-shaped, is placed about 2.5 cm. (1 inch) below the saw-line through the surgical neck—its width being equal to half the circumference of the limb at the flap's upper limit—its length being that of the diameter at the saw-line. The anterior limb of the flap passes down the mid-anterior aspect of the arm, and the posterior limb down the mid-posterior aspect. Inner incision—crosses the inner aspect of the arm, with a slight downward convexity, connecting the upper limits of the vertical limbs of the flap (Fig. 269, B).

Operation.—The above incisions pass, at first, through skin and fascia only. After the integuments have retracted, the external flap is cut from without inward, upon the line of the retracted tissues, beveling obliquely upward and inward toward the upper limit of the flap. The bleeding vessels in this external wound are clamped as met. The inner incision is now deepened—and the axillary vessels tied as encountered and before being cut—and the nerves cut short. The tendon of the pectoralis major is preserved, the periosteum being divided below the bicipital groove and stripped up, including this tendon. Avoid opening the synovial sheath of the biceps tendon, dividing it low down, together with the coracobrachialis. Detach the tendons of the latissimus dorsi and teres major as subperiosteally as possible. Retract the outer flap and the parts on the inner aspect of the arm up to the saw-line—and divide the bone through the lowest part of the surgical neck possible. Avoid the circumflex nerve and the posterior circumflex artery. The brachial artery will have been tied in the course of operation—branches of the anterior and posterior circumflex and muscular branches which have not been previously tied are now taken up. Bring the outer flap across the end of the bone—quilt the muscles of the flap to those divided in the inner incision—and suture the integumentary portion of the flap trans-

versely to corresponding tissues of the inner wound. Dress the arm against a full pad in the axilla.

Comment.—(1) The chief advantages of amputation through the surgical neck, over disarticulation at the shoulder, are, that the mortality is less; that a stump for an artificial limb is secured; and that there is not so much muscular atrophy. The chief disadvantages are, that the remaining epiph-

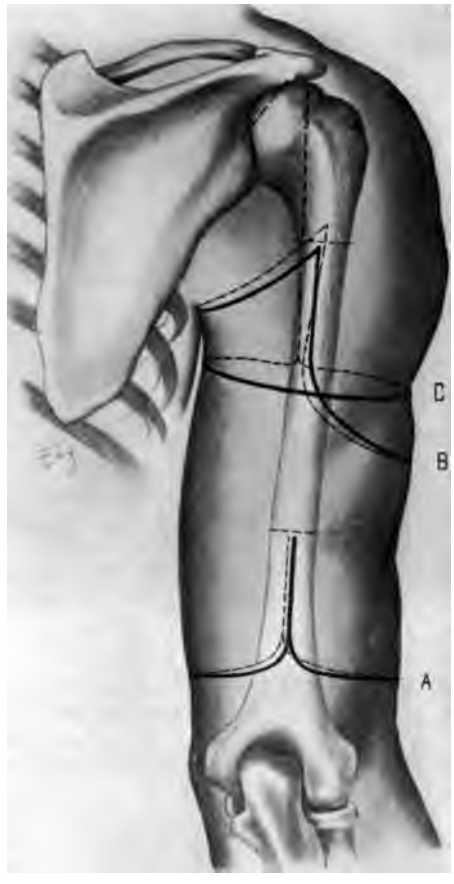

Fig. 260.—Amputations about Arm and at Shoulder:—A, Through lower part of arm, by equal lateral flaps; B, At shoulder-joint, by Furneaux Jordan's method; C, Through surgical neck of humerus, by single external flap.

ysis is apt to produce bone; and that the stump may be strongly abducted. (2) The outer flap may be less satisfactorily cut by transfixion.

SURGICAL ANATOMY OF SHOULDER-JOINT.

Bones.—Scapula; clavicle; humerus.

Articulations and Ligaments.—(a) Acromio-clavicular Articulation:—

superior acromio-clavicular, inferior acromio-clavicular ligaments; inter-articular fibro-cartilage; synovial membrane. (b) Coraco-clavicular Union:—trapezoid and conoid ligaments. (c) Shoulder-joint:—capsular, gleno-humeral bands of capsular, coraco-humeral, glenoid and transverse humeral ligaments, and synovial membrane.

Muscles Reinforcing Shoulder-joint.—Above:—supraspinatus. Below:—long head of triceps; an upward extension of pectoralis major. Internally:—subscapularis. Externally:—infraspinatus; teres minor. Within Joint:—long head of biceps. Surrounding Joint:—deltoid.

Muscles in More or Less Direct Relation with Shoulder-joint.—(a) Anterior Thoracic Region:—pectoralis major, pectoralis minor, subclavius. (b) Lateral Thoracic Region:—serratus magnus. (c) Acromial Region:—deltoid. (d) Anterior Scapular Region:—subscapularis. (e) Posterior Scapular Region:—supraspinatus, infraspinatus, teres minor, teres major. (f) Muscles Passing from Shoulder to Arm Anteriorly:—biceps, coracobrachialis. (g) Muscles Passing from Shoulder to Arm Posteriorly:—triceps.

Movements of Shoulder-joint.—Forward:—pectoralis major, anterior fibers of deltoid, coracobrachialis, biceps (when elbow is flexed). Backward:—latissimus dorsi, teres major, posterior fibers of deltoid, triceps (when elbow is extended). Abduction:—deltoid, supraspinatus. Adduction:—subscapularis, pectoralis major, latissimus dorsi, teres major. Outward Rotation:—infraspinatus, teres minor. Inward Rotation:—subscapularis, latissimus dorsi, teres major, pectoralis major.

Bursæ in Neighborhood of Joint.—Beneath tendon of subscapularis—communicating with joint by opening on anterior side of capsule. Beneath tendon of infraspinatus (sometimes present)—communicating with joint by opening on posterior aspect of capsule. Between under surface of deltoid and outer surface of capsule—not communicating with joint. Biceps tendon passes through the joint and is surrounded by tubular sheath continuous with synovial membrane.

Arteries in Neighborhood of Shoulder-joint.—Suprascapular, transversalis colli, superior thoracic, acromial thoracic, long thoracic, alar thoracic, subscapular, anterior circumflex, posterior circumflex.

Veins in Neighborhood of Shoulder-joint.—Two suprascapular, two transversalis colli, superior thoracic, acromial thoracic, long thoracic, alar thoracic, subscapular, anterior circumflex, posterior circumflex, cephalic

Nerves in Neighborhood of Shoulder-joint.—Acromial branch of cervical plexus, posterior thoracic, suprascapular, external anterior thoracic, internal anterior thoracic, upper subscapular, lower subscapular, middle subscapular, circumflex,—and following passing through axilla to arm and forearm; musculocutaneous, internal cutaneous, lesser internal cutaneous, median, ulnar, musculospiral.

SURFACE FORM AND LANDMARKS OF SHOULDER-JOINT.

To find the direction and position of the shoulder-joint—having fully abducted the arm, draw a slightly curved line from the middle of the coraco-acromial ligament, with convexity inward, to the innermost part of the head of the humerus felt in the axilla.

The coracoid process is not actually within the infraclavicular fossa, but lies near the pectoro-deltoid groove, covered by the anterior fibers of the deltoid, and a little below the clavicle.

The center of the coraco-acromial ligament lies over the superior aspect of the shoulder-joint.

The greater tuberosity of the humerus is felt externally—the lesser anteriorly. To the former are attached the supraspinatus, infraspinatus, and teres minor, in order, from above downward. To the lesser—the subscapularis.

With the arm by the side and the hand supine, the bicipital groove looks directly forward—the head of the humerus lying entirely to the outer side of the vertical line from the coracoid process. The head of the humerus faces, practically, in the direction of the inner condyle—and the greater tuberosity in the direction of the outer condyle.

The upper epiphysis of the humerus unites with the bone about the twentieth year—the inner part of the cartilage is within the capsule of the joint—the outer, anterior and posterior parts are subperiosteal.

The surgical neck lies between the bases of the tuberosities and the insertions of the latissimus dorsi, teres major, and pectoralis major.

The deltoid gives the rounded outline to the shoulder—and its insertion is marked by a depression on the outer aspect of the middle of the arm.

The groove between the pectoralis major and deltoid contains the cephalic vein and the humeral branch of the acromio-thoracic artery.

The acromio-thoracic artery emerges from the upper border of the pectoralis minor in the course of the brachial artery, where a line from near the junction of the third rib and its cartilage to the coracoid process crosses that vessel.

The posterior circumflex artery and circumflex nerve cross the surgical neck of the humerus transversely about 1.3 cm. (½ inch) above the center of the vertical axis of the deltoid.

The skin over the deltoid is thick, adherent, and little retractile—that over the pectoralis major is fine and retractile.

The dorsalis scapulæ artery crosses the axillary border of the scapula opposite the center of the vertical axis of the deltoid.

GENERAL SURGICAL CONSIDERATIONS IN DISARTICULATING AT SHOULDER-JOINT.

Methods of Hemorrhage-control during operations near the Shoulder-joint:—(**a**) Wyeth's Shoulder Transfixion Pins, with tubular rubber Tourniquet placed above them;—The anterior pin enters the middle of the anterior axillary fold, slightly to the inner side of the center of the fold—and emerges 2.5 cm. (1 inch) within the tip of the acromion process. The posterior pin enters the posterior axillary fold, at a point corresponding with the entrance of the anterior pin—and similarly emerges posteriorly 2.5 cm. (1 inch) within the tip of the acromial process. Care is necessary to avoid striking the spine of the scapula with the posterior pin. Rubber tubing of 1.3 cm. (½ inch) diameter is wound several times around the axilla, above the pins, and tied (Fig. 209, right shoulder). (**b**) Preliminary exposure and double ligation of the axillary artery, with division between the two ligatures (as in Larrey's operation, page 329). (**c**) Digital compression of the main artery in the flap by an assistant, who grasps the part just prior to division of the artery (as in Spence's operation, page 327). (**d**) By Tourniquet and Pad;—A firm pad is placed in the axilla—over this are placed several turns of rubber tubing passing around the axilla—the ends are then carried in a single figure-of-eight fashion over the clavicle of the same side, and thence across

the chest and are tied beneath the opposite axilla. Two strips of sterile gauze run beneath the tubing anteriorly and posteriorly (or placed in position prior to applying the tubing) will enable the tubing to be further and more securely drawn inward and thus make less the chances of slipping when the head of the humerus is removed (Fig. 209, left shoulder). (e) Compression (digital or instrumental) of subclavian artery against the first rib, either with or without preliminary incision over the third part of the artery, through the superficial tissues. (f) Securing of the main vessels at the lower end of the incision, as met in the course of the operation —an ordinary tourniquet having been first applied—(as in the Fourneaux Jordan method).

Comparison of methods of hemorrhage-control:—The control of hemorrhage in disarticulating at the shoulder-joint, or in amputating very near the shoulder articulation, is the most serious consideration connected with these operations. Wyeth's method, where the pins do not interfere with the operation as planned, may be regarded as the best means against hemorrhage. Preliminary exposure and ligation of the artery—and compression of the artery in the flap—may be regarded as the next best methods.

The axillary vessels should be as cleanly cut as possible—and so approached as to be secured before being cut, where the method of preliminary ligation is adopted.

The branches of the brachial plexus are to be divided high up.

The acromial process should always be preserved—as it furnishes a support for the artificial limb.

A capsulo-periosteally covered stump should be sought—as furnishing the best support for an artificial limb—therefore one should endeavor to detach the insertions of the pectoralis major, latissimus dorsi, teres major, subscapularis, supraspinatus, infraspinatus, and teres minor along with the periosteum and capsule, in so far as this is possible.

A vertical wound, in closing the site of operation, affords the best drainage. Sometimes drainage is made through a secondary opening. Temporary drainage is always indicated—owing to the extensive synovial surfaces.

The stump should be dressed so as to compress dead spaces—and steadied against the thorax as a splint by the surrounding bandaging.

DISARTICULATION AT SHOULDER-JOINT, IN GENERAL.

Best Methods.—Anterior Racket Method (Spence's operation). External Racket Method (Larrey's operation). External or Deltoid Flap (Dupuytren's operation).

Other Methods.—Anterior and Posterior Flaps. Circular. Elliptical. Lateral Flaps. Fourneaux Jordan's Method.

Comparison of Methods.—The racket methods are the best. The features of the anterior racket method are:—excision of the shoulder-joint may be done, instead of an amputation, through the vertical portion of the incision, which may be alone made at first, until it be found whether amputation be necessary; there is the smallest division of muscle; the posterior circumflex artery and circumflex nerve are not cut; the main vessels are easily controlled. The features of the external racket method are:—the vertical portion of the incision also allows of an excision, the incision at first being exploratory, through which an excision of the joint may be made, or the operation may be converted into an amputation; there is considerable

division of muscle and the joint is more deeply placed than in the anterior racket; the posterior circumflex artery and circumflex nerve are apt to be cut. The disadvantages of the external or deltoid flap, which may be regarded as probably the third best form of disarticulation, are, that the circumflex nerve and posterior circumflex artery are cut—and that preliminary examination of the joint is impossible.

DISARTICULATION AT SHOULDER-JOINT

BY ANTERIOR RACKET METHOD—SPENCE'S OPERATION.

Description.—The queue of the incision is placed over the anterior aspect of the upper end of the humerus—the diverging limbs of the racket, or oval, encircling the inner and outer aspects of the arm and meeting behind.

Position.—Patient near edge of table; shoulders elevated; head to opposite side; limb partly abducted. Surgeon on outer side of both shoulders, or may stand on inner side of left. First assistant stands between shoulder and patient's head, controls hemorrhage and retracts flaps. Second assistant stands near elbow and manipulates limb.

Landmarks.—Coracoid process; pectoro-deltoid groove.

Incision.—Abduct the arm and rotate the head of the humerus outward. Begin the incision just to the outer side of the coracoid process—pass down through the clavicular fibers of the deltoid and pectoralis major, until the humeral attachment of the pectoralis major is reached, which is divided. From this point, the outer limb of the racket curves gently outward through the lowest part of the deltoid to the posterior border of the axilla. From the point of division of the humeral attachment of the pectoralis major, the inner limb of the racket curves downward across the inner aspect of the arm—until it coincides with the opposite limb of the racket (Fig. 270, B).

Operation.—(1) The vertical portion of the incision is carried directly to the bone. The outer limb of the racket at first passes through skin and fascia, and is then deepened to the bone and through the periosteum, along the line of the incised integuments. The inner limb of the racket merely passes through skin and fascia, and especial care is taken that it goes no deeper at this stage. (2) Returning to the outer lip of the wound, the anterior fiber of the deltoid will be found divided, and this lip of the wound is now freed from the bone and joint, as nearly subperiosteally as possible, thereby securing the retention of some of the attachments of the pectoralis major, latissimus dorsi, and teres major to the fibrous tissue—the freeing being accomplished by means of the thumb, periosteal elevator and knife, and continuing up to the great tuberosity—carefully avoiding (by hugging the bone) injury to the circumflex nerve and posterior circumflex artery, which are raised from the bone in this outer flap. (3) The inner lip is similarly, though less extensively, freed up to the lesser tuberosity, carefully guarding the axillary vessels. (4) By manipulating the limb from the elbow, flexed at a right angle, the head of the bone and its tuberosities are made to present themselves in the wound. By rotating inward, the great tuberosity presents, and the supraspinatus, infraspinatus, and teres minor are severed very close to the bone. By rotating outward, the lesser tuberosity presents, and the subscapularis is severed. (5) The long head of the biceps is next cut, and the capsule opened by dividing it transversely against the head of the bone. The capsule being cut and the muscles attached to the tuberosities severed, the head of the bone is now disarticulated and thrust upward above the

glenoid cavity, by abducting and rotating the head of the humerus outward—the connection of the limb being maintained by the still unsevered tissues upon the inner aspect. (6) The surgeon grasps the disarticulated head with

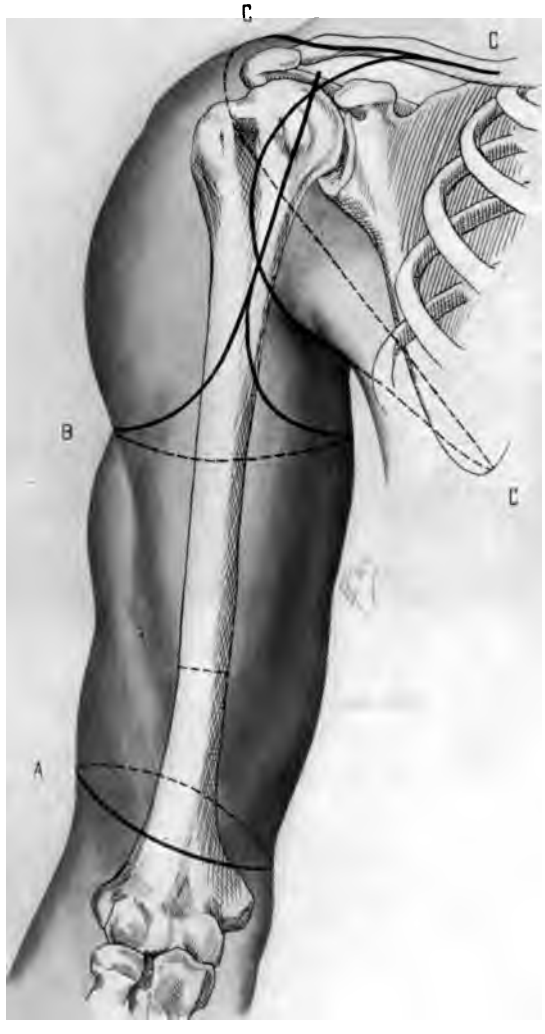

Fig. 270.—Amputations through Arm and at Shoulder:—A, Through lower arm, by oblique circular method; B, At shoulder, by anterior racket method (Spence's operation); C, Of upper limb, together with scapula and part of clavicle, by antero-inferior (pectoro-axillary) and postero-superior (cervico-scapular) flaps (Berger's operation).

the left hand and draws it outward from the trunk. As he does so, the first assistant, standing behind the shoulder, places the palm of the fingers of both hands against the axillary aspect of the still uncut inner tissues, and his thumbs, one from each side, between the neck of the bone and the tissues

of the inner side, compressing the axillary vessels between the thumbs in the wound and the outspread fingers in the axilla—until he feels all circulation controlled. The surgeon now passes a long knife between the neck of the bone and the thumb-nails of his assistant, and, by a steady, sawing movement, cuts his way from within downward and outward, aiming to come out on a line with the retracted integuments along the original incision, along the inner limb of the racket. As the knife cuts its way out, the fingers of the assistant follow the blade closely, with the artery under his grasp. Just prior to the final passage of the knife, the tissues are tightly grasped and steadily held, until the knife emerges—when he presents to the surgeon the cut margin of the inner flap, with the vessels in easy evidence. (7) Tie the brachial artery at once, and the two brachial venæ comites and the basilic vein. In the vertical and external limb of the racket, in incising and deepening the wound, branches of the acromial thoracic, the anterior circumflex, and muscular branches are at first clamped and subsequently tied. (8) The posterior circumflex nerve should not be injured. The nerves which are severed are cut short. (9) The margins of the capsulo-periosteal wound, where any appreciable periosteum has been saved, are sutured. The muscles are quilted by deep and superficial tiers of buried catgut (chromic) sutures. Temporary drainage is provided. The integumentary edges of the wound are sutured in one vertical line. The stump should be snugly compressed against the thorax by the bandage.

Comment.—(1) This operation is an illustration of the control of hemorrhage by digital compression in the flap. (2) By saving as much of the attachment of the pectoralis major, latissimus dorsi and teres major, in the subperiosteal freeing of the humerus, connections in the stump are formed by these tendons and considerable range of movement is thereby added to an artificial limb. (3) The axillary vessels have been exposed where the inner limb of the racket crosses their course and ligated prior to disarticulation. (4) Where the deltoid tissues are very thick, this flap may be advantageously thinned a little by making the incision of the outer limb of the racket in a beveling manner. (5) The more nearly the operation is done subperiosteally, where no contraindication to the preservation of the periosteum exists, the greater the safety to the important tissues, especially the circumflex nerve and posterior circumflex artery.

DISARTICULATION AT SHOULDER-JOINT

BY EXTERNAL RACKET METHOD—LARREY'S OPERATION.

Description.—The queue of the incision is placed over the external aspect of the upper end of the humerus—from the center of this incision (which may first have been made for exploration of the joint alone) the two limbs of the racket diverge—encircling the anterior and posterior aspects of the arm and meeting on the inner side.

Position.—As in Spence's operation (page 327).

Landmarks.—Prominence of acromion.

Incisions.—(1) Vertical incision—(arm being slightly abducted) begins immediately below the anterior aspect of the prominence of the acromion and passes thence vertically down the external aspect of the arm for 10 cm. (4 inches). (2) Oval incision—from the center of the vertical incision the two limbs of the oval, or racket, begin and pass obliquely downward over

the anterior and posterior aspects of the limb, meeting upon its inner border on a level with the lowest part of the vertical incision (Fig. 268, C).

Operation.—(1) The vertical incision passes at once through the deltoid directly to the bone and into the joint. The operation, which may have been begun as an exploratory one, may end with an investigation of the joint —or may proceed to an excision of the joint structures—or may end as an amputation. If the latter, the oval, or racket, incision, as above described, is added to the vertical incision. (2) The limbs of the racket are at first incised through skin and fascia only, and may be made at one stroke, or, better, by two. (3) The anterior limb of the racket is now deepened, while the arm is rotated outward—the incision passing through the anterior portion of the deltoid—the tendon of the pectoralis major is severed as near the bone as possible—the coracobrachialis and biceps are divided—and, next to these, the axillary vessels are encountered, carefully exposed and doubly ligated, beyond the posterior circumflex branch. This flap is then freed up to the joint. For the same reasons mentioned under the last operation, the freeing of these flaps should be done as subperiosteally as possible. (4) The posterior limb of the racket is similarly deepened, the arm being rotated inward—the incision passing through the posterior portion of the deltoid—and meeting the anterior limb upon the inner side of the arm. This flap is then also freed up to the joint as subperiosteally as possible. (5) Disarticulation is accomplished (after severing close to the bone in the above freeing of the anterior and posterior flaps, the attachments of the supraspinatus, infraspinatus, and teres minor to the great tuberosity, and the subscapularis to the lesser) by cutting the capsule and the long head of the biceps against the head of the bone transversely. The head of the bone is now disarticulated and thrust upward. (6) To sever the remaining soft parts, the surgeon grasps the disarticulated head of the humerus with his left hand and draws it outward—then inserts a long knife between the neck of the bone and the remaining undivided parts, and, by a sawing movement, cuts his way downward and outward between the severed axillary vessels and the bone, coming out on a line with the retracted inner limb of the racket incision (just as in the disarticulation by the anterior racket). (7) Besides the above-named vessels, the anterior and posterior circumflex are both apt to be divided, as well as some muscular branches. The circumflex nerve is likely to be severed. All nerves are cut short. (8) The capsule is to be trimmed, if hanging in tags. Temporary drainage is used. The capsulo-periosteal, or capsulo-muscular covering is sutured—the muscles quilted deeply and superficially—and the skin sutured in a vertical line.

Comment.—This operation is an illustration of the control of hemorrhage by the ligation of the main vessels in the line of incision, prior to disarticulation.

DISARTICULATION AT SHOULDER-JOINT

BY EXTERNAL OR DELTOID FLAP.

Description.—A U-shaped flap, consisting practically of the deltoid muscle, is raised from the outer side of the shoulder—its upper limits being connected by a transversely curved incision across the inner aspect of the arm.

Position.—As in Spence's operation (page 327).

Landmarks.—Coracoid process of scapula; spine of scapula.

Incision.—The base of this U-shaped flap extends from the coracoid

process, anteriorly, to the spine of the scapula at the root of the acromion posteriorly. In length, the flap extends nearly to the insertion of the deltoid. The upper extremities of the limbs of the flap are joined by a transversely curved incision (with slight downward convexity) crossing the inner side of the arm about 5 cm. (2 inches) below the lower limit of the axilla. On the right side, the incision begins at the root of the acromion and ends at the coracoid, the arm having been placed across the chest. On the left side, the incision begins at the coracoid, with the arm abducted—and ends at the root of the acromion, with the arm across the chest. In both, the surgeon manipulates the limb with his left hand. This flap consists of the entire thickness of the deltoid at the base, while its margins are beveled (Fig. 268, D, D).

Operation.—The entire length of the superficial incision outlining the flap is now deepened to the bone along the line of the retracted skin—cutting in a beveling fashion obliquely from without inward and from below upward. This mass of soft tissues is then raised from the bone, severing the attachments of the muscles of the great and less tuberosities. The joint is now opened by cutting directly down upon the capsule and long head of the biceps transversely against the head of the bone. The head of the bone is disarticulated and thrust upward, and the operation completed as in Spence's method of disarticulating—that is, the head of the bone is grasped and drawn outward—an assistant guarding the tissues of the inner flap as in the operation just mentioned, a long knife is inserted between the neck of the bone and the still undivided tissues upon the inner aspect and made to cut its way downward and outward on a line with the transversely curved portion of the incision connecting the upper limbs of the flap, thus severing the pectoralis major, latissimus dorsi, and teres major. Having ligated the vessels and cut the nerves short—the muscles are quilted—and the integumentary margin of the deltoid flap is sutured to the border of the short internal flap.

Comment.—(1) This is the least desirable of the three methods of disarticulation described. (2) Hemorrhage may be controlled by some form of tourniquet, or by the early ligation of the artery in the axilla. (3) An attempt may be made to save the circumflex nerve and the posterior circumflex artery—either by isolating and retracting them while incising from the skin downward in the posterior limb of the flap—or by approaching them from the anterior portion of the flap, working under the periosteum and then retracting them.

AMPUTATION OF UPPER LIMB, TOGETHER WITH SCAPULA AND PART OF CLAVICLE,

BY ANTERO-INFERIOR (OR PECTORO-AXILLARY) AND POSTERO-SUPERIOR (OR CERVICO-SCAPULAR) FLAPS—BERGER'S OPERATION.

Description.—Consists in the removal of the upper limb, together with the scapula and the outer two-thirds of the clavicle, *en masse*, without disarticulation at the shoulder-joint.

Position.—Given in the steps of the operation.

Landmarks.—Outline of clavicle; outline of scapula; line of shoulder-joint articulation.

Operation.—(1) Subperiosteal Excision of middle third of Clavicle and double ligature and division of Subclavian Artery and Vein:—Patient on back, at edge of table; shoulders raised; arm by side. Make an incision through the periosteum to bone, over the upper surface of the clavicle, from

outer border of sternomastoid to just beyond the acromioclavicular articulation (Fig. 270, C, C, C). The vein from the cephalic to the external jugular is hereby cut and is doubly ligated. The periosteum is raised, with curved periosteal elevator, from around the entire circumference of the middle third of the clavicle. A chain or Gigli saw is passed between bone and periosteum and the clavicle is divided at the junction of its inner and middle thirds. The outer two-thirds of the clavicle is now grasped with lion-jaw forceps and drawn outward, during which outward traction whatever periosteum may remain is now detached from its middle third. The clavicle is then sawed at the junction of the middle and outer thirds, by a chain, Gigli, or small saw. The middle third of the clavicle is thereby removed. The periosteum over the subclavius muscle and the subclavius muscle are now divided transversely, opposite the inner section of the clavicle, and are dissected up and turned outward, thereby exposing the subclavian vessels, surrounded by more or less fascia. Having divided the overlying fascia, the subclavian vein and then the artery are exposed. Both artery and vein are doubly ligated and divided opposite the lower border of the first rib—the former being secured first (to lessen the amount of blood left in the limb). (2) Formation of Antero-inferior (or Pectoro-axillary) Flap:—Patient on back, with shoulder over edge of table; arm abducted; head to opposite side. Surgeon between arm and trunk. The incision begins at the middle of the clavicular incision—curves downward and outward, passing close to the outer side of the coracoid process—thence along the anterior portion of the deltoid, just external to the pectoro-deltoid groove, to the junction of the anterior axillary wall with the arm—thence across the lower border of the pectoralis major—thence transversely across the inner or axillary surface of the arm—to the lower borders of the tendons of the latissimus dorsi and teres major. Here the limb is elevated—and the incision is carried downward and inward in the groove between the vertical border of the scapula and the muscular elevation formed by the teres major and latissimus dorsi, to end over the posterior surface of the inferior angle of the scapula. This incision passes, at first, through skin and fascia, and is then deepened through the pectoral and axillary tissues—the pectoralis major being cut where its tendinous portion commences—the pectoralis minor near the coracoid process—the brachial plexus near the first rib—the latissimus dorsi in the more posterior part of the line of incision—and whatever remaining axillary tissues bind the limb are cut as encountered. The shoulder is thus freed from the trunk anteriorly—and tends to fall outward and backward. (3) Formation of the Postero-superior (or Cervico-scapular) Flap:—The patient is still supine, with shoulder over edge of table; the arm is now drawn across the chest to emphasize the scapular region. The surgeon stands to the outer side. The incision begins at the outer end of the clavicular incision, just external to the acromio-clavicular joint—passing thence backward over the spine of the scapula by the shortest route, to join the lower end of the antero-inferior flap incision over the inferior angle of the scapula. This incision at first involves only the skin and fascia, which are then well retracted along their upper part, thus exposing the trapezius, which is now divided near its attachment to the clavicle and scapula, and thus severed from the whole limb. (4) Severing of Connections of Scapula to Trunk:—The patient lies as in the last step—and the surgeon stands to the inner side of the right and outer side of left limb. The anterior and posterior flaps are well retracted and the limb permitted to hang away

from the side. The superior and vertical borders of the scapula are rendered prominent and are now freed by cutting the following muscles close to the bone, in order from above downward: omohyoid, levator anguli scapulæ, rhomboideus minor, rhomboideus major, and serratus magnus. The upper extremity is now free from the trunk—the muscles arising from the scapula and inserted into the humerus (teres major and minor, subscapularis, supraspinatus, and infraspinatus) are removed untouched with the limb. (5) Control of Hemorrhage:—Preliminary ligation of the subclavian artery and vein control the chief hemorrhage. In forming the anterior flap, branches of the acromio-thoracic, long thoracic and subscapular are encountered. In forming the posterior flap, the muscular branches in the trapezius are met. In severing the scapula the chief bleeding occurs—the suprascapular artery is to be tied near the omohyoid as it is about to enter the supraspinous fossa —and the posterior scapular is to be tied near the upper angle of the scapula just after dividing the levator anguli scapulæ. (6) Closure of the Wound:—All the nerves are divided short. Generally no sufficient redundancy of muscles is present to admit of quilting, it usually being difficult to approximate the edges of the wound—but, if it be possible, quilting of the muscles together with buried gut sutures should be done—to make a thicker stump-padding and to take the strain off the cutaneous sutures. The anterior and posterior flaps are brought together and sutured in one oblique line, extending from above, downward, outward, and backward. To obliterate the dead spaces which tend to form in so extensive a wound, considerable even pressure is applied in the dressings which bind the parts to the thorax. No drainage is indicated in simple cases.

Comment.—(1) Sometimes the outer two-thirds of the clavicle is drawn outward and disarticulated at the acromion. (2) If the suprascapular and posterior scapular arteries are ligated through such a wound as is made in exposing the clavicle, at this stage, the chief bleeding of the whole operation will be avoided. The former is easily found. (3) One is apt to find too scanty an allowance of flap covering, which is caused by not extending the oval parts of the incisions far enough out over the shoulder.

AMPUTATIONS AND DISARTICULATIONS OF THE LOWER EXTREMITY.

SURGICAL ANATOMY OF THE TOES.

Bones.—Third, second, and first Phalanges.

Articulations and Ligaments.—(a) Second and Third Interphalangeal Joint:—Plantar; dorsal and two lateral ligaments. Extensor tendon reinforces dorsal aspect of joint. (b) First and Second Interphalangeal Joint:—Same as last. (c) Metatarso-phalangeal Joints:—Plantar (glenoid), dorsal, and two lateral ligaments. Extensor tendon reinforces dorsal aspect.

Muscles.—See under Foot.

Sheaths of Flexor Tendons.—Tendons of flexor longus digitorum and flexor brevis digitorum, in their passage along the phalanges, are bound against the bones by fibrous sheaths attached to margins of phalanges and forming osseo-aponeurotic canals lined by synovial membrane. They are strongest opposite the first and second phalanges, and weakest opposite the interphalangeal joints.

Arteries.—Two dorsal digital, from dorsal interosseous and from dorsalis hallucis; two plantar from plantar digital and from princeps hallucis.

Veins.—Superficial:—branches from the superficies of each toe. Deep:—accompany the digital arteries. Note—From the foot to the knee, two veins accompany each artery; from knee upward, one vein accompanies each artery, except at back of thigh and gluteal region, where there are generally two.

Nerves.—External saphenous; internal and external branches of musculocutaneous; internal branch of anterior tibial; digital branches of internal plantar; digital branches of external plantar.

SURFACE FORM AND LANDMARKS OF TOES.

Extensor tendons of four outer toes—the four tendons of the extensor longus digitorum, having been joined by the tendons of the extensor brevis digitorum (except that the latter muscle furnishes no tendon to the little toe) and by fibrous expansions from the interossei and lumbricales—all spread out into a broad aponeurosis, which covers the dorsum of the first phalanx and divides into three slips—the middle slip being inserted into the bases of the second phalanges of the four lesser toes—the two lateral slips, having united on the dorsum of the second phalanx, are inserted into the bases of the third phalanges of the four lesser toes.

Extensor tendon of great toe—the innermost tendon of the extensor brevis digitorum is inserted into the dorsal surface of the base of the first phalanx—blending with the tendon of the extensor proprius hallucis, which is inserted into the dorsal surface of the base of the last phalanx.

Flexor tendons of four outer toes—the four tendons of the flexor brevis digitorum divide opposite the base of the first phalanges (for the passage of the tendon of the flexor longus digitorum) and then unite opposite the first phalanges to form a channel for the flexor longus digitorum—then divide—and are finally inserted into the sides of the middle of the second phalanges. The four tendons of the flexor longus digitorum are inserted into the bases of the plantar surfaces of the last phalanges of the four lesser toes.

Flexor tendons of great toe—the flexor brevis hallucis is inserted into the inner and outer sides of the plantar surface of the base of the first phalanx, a sesamoid bone being present in each of its two heads of insertion. The tendon of the flexor longus hallucis is inserted into the plantar surface of the base of the last phalanx.

The flexor sheaths, which are not so distinct as in the fingers, have been given under Surgical Anatomy (page 333).

The first interphalangeal joint of each toe is about opposite its middle.

The knuckle of each phalangeal joint is formed by the head of the proximal bone—as in the hand.

The joint-line of the interphalangeal and metatarso-phalangeal articulations is found by flexing the distal bone at a right angle to the proximal and extending the mid-lateral axis of the proximal bone—which will pass over the joint-line.

The metatarso-phalangeal joints follow, approximately, the curve of the toes and are about 2.5 cm. (1 inch) behind the webs. The metatarso-phalangeal articulation of the first and fifth toes is detectable by manipulation, and the line of the other joints then found by making a curve between them about parallel with the interdigital webs.

The anterior, or glenoid, ligament occupies the plantar surface of the metatarso-phalangeal and the interphalangeal joints and is more firmly adherent to the base of the distal than to the head of the proximal bone. It is cut against the base of the former.

The nail largely overlies the last phalanx.

Each metatarsal has one epiphysis at its head, uniting from the eighteenth to twentieth year—that of the great toe having it at its base, and uniting at the same time. Each phalanx has one epiphysis at its base—uniting from the seventeenth to eighteenth year.

GENERAL SURGICAL CONSIDERATIONS IN AMPUTATIONS AND DISARTICULATIONS ABOUT THE TOES.

Many of the observations made concerning amputations and disarticulations about the fingers apply to corresponding regions of the toes. But operations here, except about the great toe, are apt to be very irregular proceedings, largely determined by circumstances.

Minimum sacrifice of parts is indicated, often amounting to mere trimmings—but this principle is not as necessary as in the fingers.

Preservation of the heads of the metatarsals increases the strength of the foot.

If the base of the last phalanx be saved, all of the extensor and the deep flexor tendon (flexor longus digitorum) will be preserved. If the proximal half of the second phalanx be saved, part of the extensor and the superficial flexor (flexor brevis digitorum) tendon will be saved.

Preservation of parts of the great toe is much more important than preservation of the four lesser toes.

As the foot rests on the heel, heads of the metatarsals and inner margin of the sole, as much as possible of the anterior part of the foot and phalanges of the great toe is to be saved.

It is important to save the base of the first phalanx of the great toe, owing to the number of muscles which are there inserted. If the base of the first phalanx cannot be saved, its many attached tendons should be removed as nearly subperiosteally as possible and be sutured into the tissues of the stump.

Except in the case of the great toe, a portion of a toe is of little or no use; and, in the case of the four outer toes, a retained portion of a toe may be drawn permanently upward and thus be pressed against. Therefore some surgeons remove the four outer toes at the metatarso-phalangeal joint, if removed at all.

The flexor sheaths should be closed as in the finger operations (page 281).

The flexor tendons should be so sutured as to secure their union to the stump, if it be wished to retain their action. But, except in the case of the great toe, this is much less important than in the fingers.

Musculo-periosteal coverings and capsulo-periosteal coverings in these small amputations and disarticulations are, theoretically, desirable, but, practically, difficult or impossible.

Cicatrices should be planned not to fall in the sole, where they would be constantly exposed to pressure. The plantar flap, therefore, is the best general type of amputation or disarticulation for the toes, bringing, as it does, the cicatrix upon the dorsum.

In amputating by the plantar flap a slight downward convexity given to the transverse dorsal incision makes a better fit.

In making all plantar incisions the part should be extended—and flexed while making dorsal incisions—whereby a fuller covering will be obtained.

Flaps are generally formed (in the palmar flap method) by cutting directly downward in the mid-lateral aspects of the toes, but if the vertical limbs of the incisions be a little nearer the dorsal than the plantar surface, a more liberal covering will be secured.

All flaps should be cut from without inward.

Bones should be divided by a fine, rigid saw, or a chain or Gigli saw—and never by bone-cutting forceps.

Disarticulation of the interphalangeal joints may be made from the dorsal or plantar aspect. In the former, the extensor tendon is cut from without, and then the lateral and glenoid ligaments are cut from within outward. In the latter, the glenoid ligament is cut against the base of the distal bone, and the joint opened, and then the lateral ligaments and the extensor tendon are cut from within outward. The dorsal disarticulation is preferable.

In disarticulating at the metatarso-phalangeal joints, the following points are to be observed:—The joint is to be disarticulated from the dorsum. The sesamoid bones are to be left in with the head of the metatarsal. Ample covering is necessary for the disproportionately large head of the metatarsal. The cicatrix should be away from the plantar surface (where it would be exposed to pressure). Owing to the distance of the joint-line above the web, it would be difficult to disarticulate from the plantar aspect. The heads of the metatarsals should not be removed.

Great care is necessary to hug the bone in freeing up flaps, in order to avoid the digital arteries, which run near the bone and are the sole supply to the coverings. These vessels should run to the end of the flaps.

Ligatures should be catgut—and sutures silk, or silkworm-gut for the skin. Sutures for quilting muscles or tendons, or for closing sheaths, should be of catgut.

Drainage is generally unnecessary.

In all amputations or disarticulations, the stump should be snugly dressed and bandaged against an adjoining toe as a splint.

The stump should be kept out from under the bed-clothes while healing—and the patient frequently lie upon the side to favor drainage, where indicated.

AMPUTATION THROUGH LAST PHALANX OF TOES, IN GENERAL.

Best Method.—Plantar Flap.

Other Method.—Oblique Circular.

AMPUTATION THROUGH LAST PHALANX OF TOES

BY PLANTAR FLAP.

Description.—Hardly feasible as a definite operation—amounting, generally, to trimming of the parts—except in the case of the great toe, which is the operation here described.

Position.—(**For all amputations about the toes**):—Patient supine, with foot beyond end of table; toes extended during plantar incisions, and flexed during dorsal incisions. Assistant stands in front of surgeon, steadying foot with both hands, the fingers of which, at the same time, draw aside

and out of the way, the adjacent toes. Surgeon grasps toe to be removed with thumb and forefinger of left hand—with his thumb on the dorsum of the toe during dorsal incisions; and on the plantar surface of toe during plantar incisions—the index-finger occupying the opposite aspect in each case. His hand will be supinated during dorsal, and pronated during plantar incisions.

Landmarks.—Saw-line, which will lie between base of nail and interphalangeal joint above.

Incision.—The vertical portion begins opposite the saw-line, in the mid-lateral aspect of the toe, or a little nearer the dorsum (which furnishes a fuller plantar flap)—passes straight down that aspect and around the pulp of the toe to the corresponding point on the opposite side. The transverse dorsal incision connects the upper ends of the limbs, with slight downward convexity (Fig. 274, A, for principle).

Operation.—Having incised skin and fascia, these incisions are deepened to the bone—the soft parts are separated up to the saw-line and retracted. The tip of the phalanx is grasped with bone-holding forceps and steadied, while the bone is sawed. If the base of the last phalanges be left, the insertion of the flexor and extensor tendons will be preserved. Arteries rarely have to be tied—except in the case of the great toe.

DISARTICULATION AT SECOND INTERPHALANGEAL JOINT, IN GENERAL.

Best Method.—Plantar Flap.
Other Method.—Oblique Circular.

DISARTICULATION AT SECOND INTERPHALANGEAL JOINT OF TOES

BY PLANTAR FLAP.

Description.—A U-shaped flap is raised from the plantar aspect of the toe and approximated to the dorsal wound.

Position.—As for the last phalanx (page 336).

Landmarks.—Second interphalangeal joint-line.

Incisions.—The vertical portion of the incision begins opposite the joint-line, in the mid-lateral aspect, or a little nearer the dorsum—passes directly down this aspect of the toe a distance sufficient to furnish a covering of 1½ diameters of the toe at the saw-line—then rounds bluntly across the plantar surface and is continued up to a corresponding point on the opposite side. The transverse incision connects the upper limbs of the flap by a slightly rounded convex line (Fig. 274, A).

Operation.—Deepen the vertical portion and the rounded end of the flap to the bone—dissect up the soft parts to the joint-line, cutting the glenoid ligament and flexor tendon against the base of the last phalanx, thus opening the joint. Forcibly flex the joint and deepen the transverse incision to and into the joint, entering from the dorsum and cutting the lateral ligaments from within outward. Two dorsal and two plantar digital arteries may require ligation. Close the flexor sheath with catgut—and, in the great toe, include the flexor tendon. Suture the plantar flap to the transverse dorsal wound.

AMPUTATION THROUGH SECOND PHALANX OF TOES, IN GENERAL.

Best Method.—Plantar Flap.
Other Method.—Oblique Circular.

AMPUTATION THROUGH SECOND PHALANX OF TOES
BY PLANTAR FLAP.

Description.—The manner of performing this operation is sufficiently described in the amputation through the last phalanx (page 336), and the dimensions of the flap, under the disarticulation at the second interphalangeal joint (page 337).

DISARTICULATION AT FIRST INTERPHALANGEAL JOINTS OF TOES, IN GENERAL.

Best Method.—Oval Method.
Other Methods.—Oblique Circular. Plantar Flap.

DISARTICULATION AT FIRST INTERPHALANGEAL JOINTS OF TOES
BY OVAL METHOD.

Description.—Queue of incision over dorsal aspect of joint—the limbs of the oval encircling the toe beyond the first interphalangeal joint-line.

Position.—As in amputating through the last phalanx.

Landmarks.—First Interphalangeal joint.

Incision.—The queue of the oval begins just above the head of the first phalanx, on its mid-dorsal aspect—passes vertically downward over the head of the phalanx, and continues down to near the middle of the first phalanx—where the two corresponding limbs diverge to encircle the second phalanx and meet in the middle of its plantar aspect (Fig. 271, C).

Operation.—Deepen the dorsal incision to the extensor tendon. Extend the toe and deepen the oval to the bone, cutting the flexor tendons transversely. Dissect up the soft parts upon the plantar and lateral aspects. Divide the glenoid (anterior) ligament by cutting against the base of the second phalanx and opening the joint. Divide the lateral ligaments from within outward. Draw upon the toe and cut the extensor tendon high up. Two plantar and two dorsal digital arteries are cut—the former may require ligation. Close the flexor sheath. Suture the wound vertically. The cicatrix will be vertical and dorso-terminal.

Comment.—The head of the first phalanx may be removed, especially of the second and third toes—as it is large and may be in the way.

AMPUTATION THROUGH FIRST PHALANGES OF TOES, IN GENERAL.

Best Methods.—Oval Method. Circular Method.

Other Methods.—Oblique Circular. Equal Lateral. Single External Flap.

Comparison.—The oval method allows readier access to the saw-line and the freeing of the soft parts to that line. The scar is dorso-terminal.

The circular furnishes less easy approach, but leaves a smaller cicatrix, which, however, is terminal.

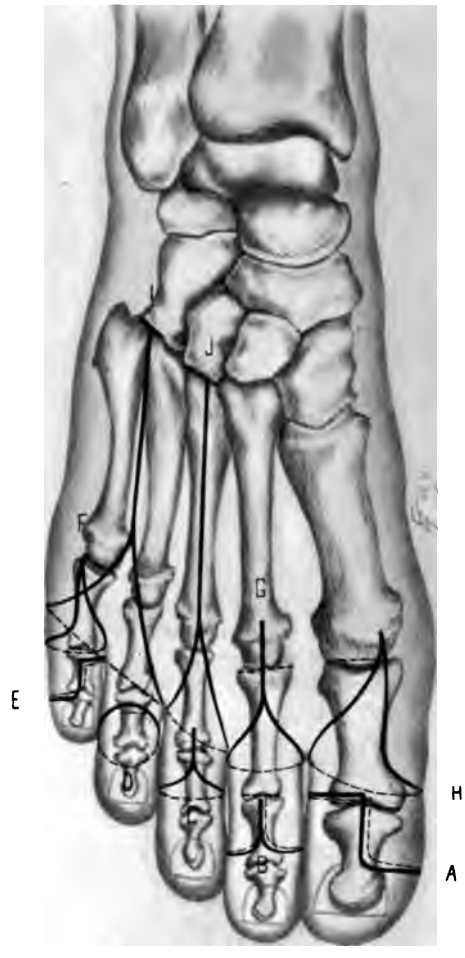

Fig. 271.—AMPUTATIONS ABOUT THE TOES AND FOOT:—A, At interphalangeal joint of great toe, by a single internal flap; B, At first phalangeal joint, by equal lateral flaps; C, At first phalangeal joint, by oval method; D, Through second phalanx, by oblique circular; E, At first phalangeal joint of little toe, by single external flap; F, At metatarso-phalangeal joint of little toe, by externo-dorsal flap; G, At metatarso-phalangeal joint, by oval method; H, At metatarso-phalangeal joint of great toe, by interno-plantar flap; I, Of two inner toes at tarso-metatarsal joints, by racket method; J, Of toe, with its entire metatarsal at tarso-metatarsal joint, by racket method.

AMPUTATION THROUGH FIRST PHALANX OF TOES

BY OVAL METHOD.

Description.—The operation is exactly similar to that for disarticulation at the first interphalangeal joint just described—except that the queue

begins just above the future saw-line, and the oval extends down the toe a distance that will make the covering furnished by the two lateral aspects of the oval about equal to 1½ diameters of the toe at the saw-line.

AMPUTATION THROUGH FIRST PHALANX OF TOES

BY CIRCULAR METHOD.

Description.—The covering is furnished by a circular division of all the soft parts down to the bone, with a vertical suturing of the covering.

Position—Landmarks.—As for the toes in general.

Incision.—A circular incision is made through skin and fascia around the toe at a distance below the saw-line equal to three-fourths of the diameter of the toe at the saw-line (to furnish a covering of 1½ diameters) (Fig. 275, A, for principle, disregarding obliquity of incision).

Operation.—Upon the level of the retracted integuments, the remaining soft parts are circularly divided to the bone—flexing the toe while cutting the dorsal, and extending it while cutting the plantar aspect. These are now retracted to the saw-line and the bone severed. The arteries divided are the same as in the last operation—and the flexor sheath is treated in the same manner. The cicatrix will be vertical and terminal.

DISARTICULATION AT METATARSO-PHALANGEAL JOINTS OF TOES, IN GENERAL.

Best Methods.—Oval Method—best for the inside toes (second, third, and fourth). Interno-Plantar Flap—best for great toe. Externo-Dorsal Flap—best for little toe. Short Dorsal and Plantar Flaps—best for toes *en masse* at the metatarso-phalangeal joints.

Other Methods.—Lateral Flaps. Internal Flap—for great toe. External Flap—for little toe. Oval Flap—for great or little toe. Irregular Circular, with U-shaped flap for Great Toe (Dubrueil's method)—for toes *en masse* at the metatarso-phalangeal joints.

DISARTICULATION OF SECOND, THIRD, OR FOURTH TOES AT METATARSO-PHALANGEAL JOINT

BY OVAL METHOD.

Description.—Same, in principle, as disarticulation at first interphalangeal joint by the oval method.

Position.—As for the toes in general (page 336).

Landmarks.—Metatarso-phalangeal joint.

Incision.—The queue of the incision begins just above the head of the metatarsal, over its mid-dorsal aspect—passes downward in the median line until past the base of the first phalanx—the limbs of the oval now gradually diverge to pass obliquely downward over the lateral aspects of the toes and cross the plantar surface transversely, meeting just in front of the line of the webs (Fig. 271, G).

Operation.—The vertical portion of the incision is deepened to the extensor tendon—the lateral portions are cut to the bone—the toe is extended and the plantar aspect cut transversely to the bone, thereby severing the flexor tendons high up. The soft parts are freed, partly by retraction and

partly by dissection, from the upper portion of the first phalanx to the joint-line, which lies about 2.5 cm. (1 inch) above the web. The glenoid ligament is cut transversely against the base of the first phalanx and the joint opened. Disarticulation may be completed from below, but more conveniently by severing the extensor tendon and disarticulating from the dorsum, cutting the lateral ligaments from within outward, as the toe is rotated from side to side and disarticulation completed. Two dorsal and two plantar digital arteries are cut. The flexor sheath should be closed. The wound is sutured vertically—the scar becoming dorso-terminal.

DISARTICULATION OF GREAT TOE AT METATARSO-PHALANGEAL JOINT

BY INTERNO-PLANTAR FLAP—FARABEUF.

Description.—A modification of the oval method, whereby the covering is gotten from the internal and plantar aspects of the great toe, and the cicatrix is brought well over to lie obliquely from the upper angle of the interdigital web to the head of the metatarsal, and thus well removed from internal and terminal pressure.

Position.—As for the toes in general (page 336).

Landmarks.—Metatarso-phalangeal joint-line; interdigital web.

Incision.—Begins over the metatarso-phalangeal joint, at the junction of the dorsal and internal surfaces—passes vertically down the toe, in the line represented by the junction of these two surfaces (parallel with the extensor tendon), nearly to the head of the first phalanx—curves thence downward over the inner surface to the junction of the internal and plantar surfaces—passes thence obliquely across the plantar surface to the angle of the interdigital web—thence runs directly over the external and dorsal surfaces of the toe to the point of beginning, by the shortest route (Fig. 271, H).

Operation.—This incision is now deepened to the bone in the same order as made, extending the toe while cutting the plantar and flexing while cutting the dorsal tissues. Free the soft parts up to the joint-line. Sever the glenoid ligament against the base of the first phalanx, thus opening the joint, and leaving the glenoid ligament and sesamoid bones in the stump. Divide the lateral ligaments and the extensor tendon. Two plantar and two dorsal digital arteries are cut and will probably require ligation. Close the flexor sheath. Include the cut flexor and extensor tendons in the tissues of the stump. Suture the internal and plantar portions of the oval to the straight incision from the interdigital web to the head of the metatarsal, which will represent the line of the cicatrix.

Comment.—If the vertical portion of the oval be placed directly over the mid-dorsal aspect (as in the corresponding operation upon the index-finger, page 291) a fuller covering will be gotten and the cicatrix will be more certainly protected.

DISARTICULATION OF LITTLE TOE AT METATARSO-PHALANGEAL JOINT

BY EXTERNO-DORSAL FLAP—FARABEUF.

Description.—This is the reverse of the last operation—a modification of the oval method, whereby the covering is gotten from the external and dorsal aspects of the little toe—and the cicatrix brought well over to lie obliquely

from the upper angle of the interdigital web to the head of the metatarsal—and thus well removed from external and terminal pressure.

Position—Landmarks.—As in the last operation.

Incision.—Begins over dorsal aspect of metatarso-phalangeal joint, just to inner side of extensor tendon—passes vertically down the inner margin of the tendon to the end of the first phalanx—curves thence downward and outward over the external aspect of the toe—thence obliquely across the plantar surface to the angle of the interdigital web—thence along the internal aspect of the toe to the point of beginning, by the shortest route (Fig. 271, F).

Operation.—The steps of the operation are exactly similar to those of the disarticulation of the metatarso-phalangeal joint of the great toe. The dorsal, external and part of the plantar portion of the oval are sutured to the straight incision from the metatarso-phalangeal joint to the interdigital web, which will represent the line of cicatrix and be out of the way of pressure.

DISARTICULATION OF TWO ADJOINING TOES AT METATARSO-PHALANGEAL JOINT

BY OVAL METHOD.

Description.—Same as the disarticulation of a single toe at the metatarso-phalangeal joint (page 340)—except that the queue of the oval is placed between the two toes, beginning a little higher above the metatarso-phalangeal joint-line—the two limbs of the oval diverging to encircle the outer and inner toes and meet at the margin of the web between the toes. Each toe is then freed up to the metatarso-phalangeal joint and disarticulated. The wound is sutured as a vertical cicatrix.

DISARTICULATION OF ALL TOES EN MASSE AT METATARSO-PHALANGEAL JOINT

BY EQUAL SHORT DORSAL AND PLANTAR FLAPS.

Description.—The covering is gotten equally from the dorsal and plantar surfaces and the scar is terminal.

Position.—Patient supine; foot over edge of table. Surgeon grasps toes with left hand, with thumb on dorsum and fingers on plantar surface for dorsal incisions—and thumb on plantar and fingers on dorsum for plantar incisions—manipulating the foot as indicated. After the incisions are made, an assistant takes the toes and the surgeon manipulates the flaps. The surgeon stands for the dorsal and sits for the plantar incisions.

Incisions.—(Supposing the left foot to be operated upon)—the dorsal incision (with foot extended and toes flexed) begins at the mid-lateral aspect of the metatarso-phalangeal joint of the great toe—passes vertically down the inner margin of the foot to the middle of the first phalanx—thence rounds broadly on to the dorsum of the foot and follows the line of the web, dipping in between the toes as they are separated, until the little toe is reached, when the incision again rounds broadly into the outer aspect of the foot and passes vertically up in the mid-lateral aspect to the metatarso-phalangeal joint. The plantar incision (with foot flexed and toes extended) passes transversely across the plantar surface of the foot, connecting the distal ends of the vertical limbs of the dorsal incision—beginning at a point where the vertical limb begins to round onto the dorsum, the plantar incision rounds onto the plantar

surface at the middle of the first phalanx of the great toe, and thence follows the line of the web and creases of the toes, dipping in between the toes as they are separated, until the little toe is reached, when the incision rounds into the outer aspect and joins the dorsal incision at a point where the outer vertical limb began to round onto the dorsum (Fig. 272, A, A).

Operation.—The dorsal incision is deepened to the extensor tendons

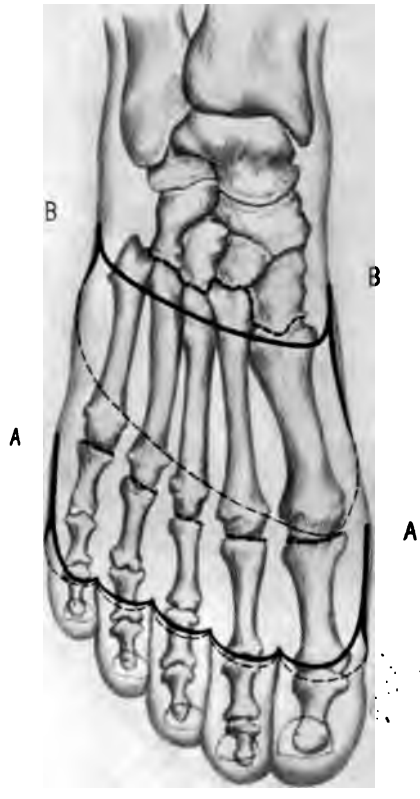

Fig. 272.—Disarticulations about the Foot:—A, A. Of all the toes at metatarso-phalangeal joints, by equal short dorsal and plantar flaps: B, B. Of all the toes at tarso-metatarsal joints, by short dorsal and long plantar flaps (Lisfranc's operation).

and freed half-way back to the joint-line, when the extensor tendons are cut transversely, each toe being previously forcibly flexed in turn. The flap of entire soft parts is then dissected back to the metatarso-phalangeal joint-line. The plantar incision is now deepened to the flexor tendons and freed half-way back to the joint-line, when the flexor tendons are cut transversely, each toe being previously forcibly extended in turn. The flap of entire soft parts is then dissected back to the metatarso-phalangeal joint-line. Both flaps are well retracted to the general joint-line—the toes are flexed and the joints are opened from the dorsum and the lateral ligaments cut from within outward. The toes are then extended and the plantar ligaments are cut from the plantar surface, preserving the glenoid ligaments. The disarticulation

of each toe is thus completed in turn. The flexor sheaths are closed. Two plantar and two dorsal digital arteries for each toe are cut—the latter may not require ligature. The dorsal and plantar flaps are sutured in one lateral, terminal line.

Comment.—It is difficult to get covering for the large head of the first metatarsal—special care is, therefore, given to procuring this covering by keeping well in the mid-lateral aspect of the inner surface of the great toe until quite to, or beyond, the middle of the first phalanx, before rounding into the dorsal and plantar surfaces.

SURGICAL ANATOMY OF THE FOOT.

Bones.—Five metatarsals; seven tarsals (astragalus; os calcis; scaphoid; internal cuneiform; middle cuneiform; external cuneiform; cuboid).

Articulations and Ligaments.—(**A**) Metatarso-Phalangeal Articulations:—See Surgical Anatomy of Toes, page 333. (**B**) Articulation of Metatarsals with each other:—Dorsal, plantar, transverse metatarsal, interosseous ligaments, and synovial membrane. (**C**) Articulations of Metatarsals with Tarsals:—dorsal, plantar, and interosseous ligaments, and synovial membrane. (**D**) Articulation of External Cuneiform and Cuboid:—dorsal, plantar, and interosseous ligaments, and synovial membrane. (**E**) Articulations of Internal, Middle, External Cuneiform bones with each other:—dorsal, plantar, and interosseous ligaments, and synovial membrane. (**F**) Articulation of Scaphoid and Cuboid:—dorsal, plantar, and interosseous ligaments, and synovial membrane. (**G**) Articulation of Scaphoid and three Cuneiform Bones:—dorsal and plantar ligaments, and synovial membrane. (**H**) Articulation of Astragalus and Scaphoid:—Superior astragalo-scaphoid ligament, and synovial membrane. (**I**) Articulation of Os Calcis and Scaphoid:—superior (or external) and inferior (or internal) calcaneo-scaphoid ligaments, and synovial membrane. (**J**) Articulation of Os Calcis and Cuboid:—(**a**) Dorsal—superior and internal (interosseous) ligaments; (**b**) Palmar—long calcaneo-cuboid (long plantar) and short calcaneo-cuboid (short plantar) ligaments. And synovial membrane. (**K**) Articulation of Os Calcis and Astragalus:—external, internal, and posterior calcaneo-astragaloid, and interosseous ligaments, and synovial membrane. (**L**) Articulation of Tarsus with Bones of Leg:—See Surgical Anatomy of the Ankle, page 358.

Anterior Annular Ligament.—Consists of two portions:—(**a**) Vertical (Superior) Portion:—Binds down extensor tendons to tibia and fibula. Continuous with fascia of leg above, and extending from anterior border of tibia to anterior border of subcutaneous surface of fibula. Contains synovial sheath for tendon of tibialis anticus. Following structures pass under it—extensor proprius hallucis, extensor longus digitorum, peroneus tertius, anterior tibial vessels and nerve. (**b**) Horizontal (Inferior, or Y-shaped) Portion:—Binds down extensor tendons to tarsus. Is connected with vertical portion. Attached, externally, to superior surface of os calcis,—anteriorly, to depression for interosseous ligament. It passes upward and inward in a superficial band (which runs in front of the peroneus tertius, extensor longus digitorum, and part of origin of extensor brevis digitorum), and a deep band (which runs behind these muscles). Having formed this loop containing the above muscles, surrounded by synovial membrane, these two bands unite and redivide into two limbs. The Upper Limb passes upward and inward to the internal malleolus—containing tibialis anticus muscle and its

synovial sheath in its structure, but passing over extensor proprius hallucis and anterior tibial vessels and nerve. The Lower Limb passes downward and inward to the scaphoid and internal cuneiform—running over extensor proprius pollicis, tibialis anticus, and anterior tibial vessels and nerve.

Internal Annular Ligament.—Extends from inner malleolus above, to internal border of os calcis below, converting the grooves of this region into four canals, each lined by separated synovial membrane. The canals transmit, from within outward—tibialis posticus—flexor longus digitorum—posterior tibial vessels and nerve—flexor longus hallucis. It is continuous, above, with deep fascia of leg, and, below, with plantar fascia and origin of abductor hallucis.

External Annular Ligament.—Extends from extremity of external malleolus to outer surface of os calcis. Binds down and transmits tendons of peroneus longus and brevis beneath the outer ankle, in one synovial sheath.

Plantar Fascia.—(a) Central Portion:—Arises from internal tubercle of os calcis, posterior to origin of flexor brevis digitorum—divides, near heads of metatarsals, into processes for each of five toes—which again subdivide, opposite metatarso-phalangeal joints, into superficial and deep portions. The superficial part is inserted into the transverse sulcus between sole and toes. The deep part redivides into two slips—which blend with flexor tendons and sheaths and transverse metatarsal ligament. Two vertical intermuscular septa are sent up by central portion—separating middle from external and from internal plantar groups of muscles. (b) Outer Lateral Portion:—From os calcis to base of fifth metatarsal—covering inferior surface of abductor minimi digiti—and continuous with central and dorsal fascia. (c) Inner Lateral Portion:—From internal annular ligament—covering abductor hallucis—and continuous with central and dorsal fascia.

Muscles.—(a) Dorsal Region:—Extensor brevis digitorum; and muscles from leg (page 362). (b) Plantar Region:—First Layer—abductor hallucis, flexor brevis digitorum, abductor minimi digiti;—Second Layer—flexor accessorius, four lumbricales;—Third Layer—flexor brevis hallucis, abductor obliquus hallucis, abductor transversus hallucis, flexor brevis minimi digiti;—Fourth Layer—four dorsal interossei, three plantar interossei. And muscles from leg (page 362).

Synovial Membranes of Tarsal and Metatarsal Joints.—Synovial membranes exist for following joints;—posterior calcaneo-astragaloid joint;—anterior calcaneo-astragaloid and astragalo-navicular joints;—calcaneo-cuboid joint;—articulation of navicular with three cuneiforms, three cuneiforms with each other, external cuneiform with cuboid, middle and external cuneiform with bases of second and third metatarsals, lateral surfaces of second, third, and fourth metatarsals with each other;—internal cuneiform with metatarsal of great toe;—articulation of cuboid with fourth and fifth metatarsals;—(and sometimes the articulation of navicular with cuboid).

Arteries.—Dorsalis pedis branch of anterior tibial, and following branches—external tarsal; internal tarsal; metatarsal and its three dorsal interosseous branches, with the latter's three posterior and three anterior perforating branches; dorsalis hallucis (or first dorsal interosseous); communicating (or plantar digital). Posterior tibial and following branches—anterior peroneal, posterior peroneal and external calcaneal branches of peroneal; internal calcaneal branch of posterior tibial; internal plantar branch of posterior tibial; external plantar branch of posterior tibial and following branches, three posterior perforating (between plantar arch and interosseous), four plantar digital, three anterior perforating (between digital and interosseous), princeps hallucis (fifth plantar digital).

Veins.—Superficial—tributaries of internal (long) saphenous; tributaries of external (short) saphenous. Deep—two venæ comites for each artery.

Nerves.—(a) From Lumbar Plexus—internal saphenous. (b) From Sacral Plexus—following from great sciatic;—external (short) saphenous—posterior tibial and plantar cutaneous branch—internal plantar with cutaneous, muscular, articular, and four digital branches—external plantar, with superficial and deep (or muscular) branches—anterior tibial, with external (or tarsal) branch and its three interosseous; internal branch (continuation of anterior tibial) and its interosseous branch;—and internal and external branches of musculocutaneous.

Bursæ About Foot.—These are variable—the following are generally present—(a) Above, or beneath, tendon of extensor proprius hallucis, over instep,—(b) Between tendon of extensor longus digitorum and projecting end of astragalus (sometimes communicating with joint of head of astragalus), —(c) Between tendo Achillis and calcaneum,—And others may occur over any bony prominence.

SURFACE FORM AND LANDMARKS OF FOOT.

Bony landmarks of dorsum—head of astragalus is felt on extension of foot, in front of ankle-joint.

Bony landmarks of inner aspect of foot—internal tuberosity of os calcis; sustentaculum tali (lesser process of os calcis), 2.5 cm., or 1 inch, below internal malleolus; tuberosity of scaphoid (2.5 to 3 cm., or 1 to 1¼ inches, in front of internal malleolus); internal cuneiform (but slightly); base of first metatarsal (obscurely); shaft of first metatarsal; head of first metatarsal; base of first phalanx of great toe; internal sesamoid bone.

Bony landmarks of outer aspect of foot—outer tuberosity of os calcis; greater part of outer surface and anterior end of os calcis; peroneal tubercle (when present) 2.5 cm., or 1 inch, below external malleolus; base of fifth metatarsal; shaft of fifth metatarsal; head of fifth metatarsal; base of first phalanx of little toe.

Bony landmarks of plantar aspect of foot—inferior surface of os calcis; heads of metatarsals.

Landmarks of medio-tarsal articulation—the joint-line runs transversely across the foot from the astragalo-scaphoid articulation on the inner side, to the calcaneo-cuboid articulation on the outer side. The astragalo-scaphoid joint lies just posterior to the prominent tuberosity of the scaphoid (forcibly extend the foot, when the interval between the tuberosity of the scaphoid and head of the astragalus will be evident). The calcaneo-cuboid joint lies midway between the external malleolus and the prominent base of the fifth metatarsal.

Landmarks of the tarso-metatarsal articulation—the cubo-metatarsal joint (on the outer side) is found on a line with the base of the prominent fifth metatarsal, and this serves as a guide to the remaining joints—the line of which runs obliquely forward toward the inner side of the foot, to a point about 2.5 cm., or 1 inch (extremes 3.8 to 4.5 cm., or 1½ to 1¾ inches), below the posterior margin of the tuberosity of the scaphoid. Practically, the articulations of the fifth, fourth, third, and first metatarsals are in one line, while the line of the articulation of the second metatarsal with the middle cuneiform is from 7 mm. to 1.3 cm. (⅓ to ½ inch) above this oblique line. The tarso-metatarsal articulation of the great toe can sometimes be felt as a

depression 3.8 to 4.5 cm. ($1\frac{1}{2}$ to $1\frac{3}{4}$ inches) anterior to the posterior margin of the tuberosity of the scaphoid, by pressure here while manipulating the toe—which would give an inner landmark to be used with the base of the fifth metatarsal on the outer aspect.

Landmarks of the metatarso-phalangeal articulations—about 2.5 cm. (1 inch) behind the webs of the corresponding toes.

Muscles and tendons more or less influencing surface form upon the dorsum of the foot, from within outward—tibialis anticus, extensor proprius hallucis, extensor longus digitorum, peroneus tertius—and, beneath these, extensor brevis digitorum and dorsal interossei.

Muscles on sole of foot influencing surface form—abductor minimi digiti, abductor hallucis, flexor brevis digitorum.

GENERAL SURGICAL CONSIDERATIONS IN AMPUTATIONS ABOUT THE FOOT.

Remove as little as possible of the metatarsals of the great and little toes as they largely support the weight of the body.

Amputation of the toe, except the great toe, with part or all of its metatarsal, is of very little practical applicability.

Scars should be kept from the plantar, internal, and external aspects of the foot. They should be at the end of the stump or dorsal.

Plantar covering is the best form to provide.

In removing the metatarsal bones entirely, or in part, it is well to adopt the subperiosteal method as far as possible.

There is an increasing tendency to regard the foot as a whole and to amputate regardless of joints.

Sutures should remain in the thick, hard skin of the sole extra long.

Temporary drainage is indicated when large joint-surfaces are opened up.

Stumps should remain out from under the bed-covering when dressed.

Patients should lie part of the time on their side, or flex the knee, to allow of drainage from the angles of wounds, if any fluid accumulate.

If drainage be necessary, drain with two short tubes in either end of the wound.

Amputation through the metatarsus is preferable to tarso-metatarsal disarticulation, for, in the former, attachment of all the important muscles of the foot and all its movements are retained.

Disarticulation at the tarso-metatarsal joints (Lisfranc's operation) gives an excellent stump. Disarticulation at the medio-tarsal joints (Chopart's operation) gives a not altogether satisfactory result.

Subastragaloid disarticulation gives a very good result, furnishing a long limb with ankle-movement.

Syme's amputation (disarticulation at the ankle-joint) is generally considered preferable to either Chopart's or Pirogoff's operation.

In Lisfranc's and Chopart's operations the unopposed action of the calf muscles may permanently raise the heel.

AMPUTATION OF TOES WITH PART OF THEIR METATARSALS.

The amputation of the toes with part of their metatarsals is so similar, in all essential details, to disarticulation of the toes with their entire meta-

tarsals that the former will not be separately given (as was done in the case of the fingers). The best method of removing any of the toes with part of their metatarsal, whether an inside toe or the great or little toe, is by the racket method (see pages 350–352). The best method for the removal of two or three contiguous toes with parts of their metatarsals is by the oval operation (see page 353). The best methods, as well as other methods for these partial operations, are the same as for the entire operations—and will be given at the above references.

The practical differences between the partial and complete operations are—that the incision begins, in the former, just above the saw-line, instead of just above the tarso-metatarsal joint-line—and, instead of disarticulating the proximal end of the bone, it is sawed with a Gigli or chain saw.

The amputation of all the toes with parts of their metatarsals will be given.

AMPUTATION OF ALL THE TOES THROUGH THE METATARSUS

BY SHORT DORSAL AND LONG PLANTAR FLAPS (METATARSAL AMPUTATION).

Description.—The height at which the amputation will be done will depend upon the nature of the cause and condition of the parts. The operation resembles Lisfranc's disarticulation at the tarso-metatarsal joint.

Position.—Patient supine; foot over edge of table. Surgeon opposite foot, standing while operating on dorsum, sitting while working upon plantar aspect—steadying the toes with his left fingers during the incisions, while assistant holds ankle;—and, as soon as incisions are made, assistant takes the toes, while the surgeon grasps the flaps with his left hand.

Landmarks.—Saw-line (which is oblique, to be parallel with the ends of the metatarsals—its inner end being more anteriorly placed than its outer —the line running about parallel with the webs); interdigital webs.

Incisions.—Plantar incision (supposing the metatarsals to be divided at their middle, in the case of the left foot) begins at the mid-lateral aspect of the inner side of the foot and just behind the saw-line—passes vertically down this side of the foot to the level of the crease between the sole and plantar surface of the great toe—thence rounds broadly into the sole and sweeps across the plantar aspect just behind and parallel with the web, to the crease between the sole and little toe—whence it rounds broadly into the mid-lateral aspect of the outer side of the foot and passes straight upward to just beyond the saw-line. Dorsal incision is made parallel with the plantar incision, and joins the vertical portion of that incision about 2.5 cm. (1 inch) from their upper ends, rounding onto the dorsum (that is, the dorsal flap is about 2.5 cm., 1 inch long). The foot is flexed on the leg while the plantar incision is made and extended while the dorsal incision is made (Fig. 273, A, A).

Operation.—The plantar incision is first deepened to the flexor tendons, is then dissected up a short distance and the flexor tendons divided transversely while the foot is forcibly flexed on the leg and toes extended on foot—thence upward to the saw-line, all soft parts down to the bone being raised in the plantar flap. The dorsal incision is now deepened to the extensor tendons, and dissected up a short way, when these tendons are divided transversely while the foot is forcibly extended on the leg and the toes flexed on the foot—thence upward to saw-line, all soft parts down to the bone being raised in the dorsal flap. Both flaps are now retracted—the bones freed

of their interossei muscles—and each bone separately sawed with a fine saw. The following arteries are tied—six plantar digital (upon contiguous sides of the toes, and outer side of the little and inner side of the great toes), second, third, and fourth dorsal interossei, and first dorsal interosseous, or its three dorsal digital branches. The muscles are quilted, those of the dorsal to those of the plantar aspect—and the integumentary margins of the dorsal

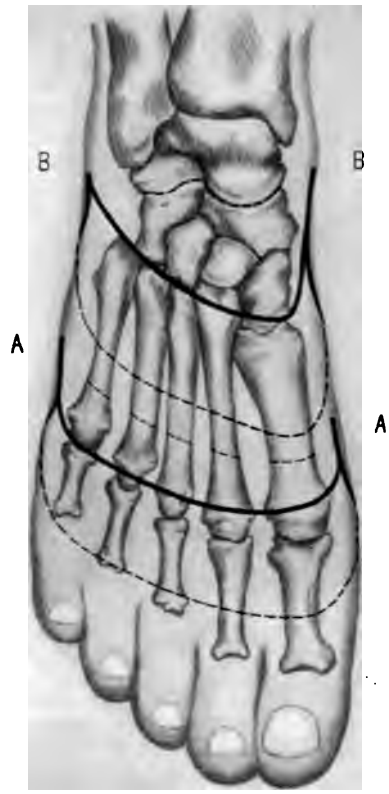

Fig. 273.—AMPUTATIONS ABOUT THE FOOT:—A, A, Amputation of all the toes through the metatarsus, by short dorsal and long plantar flaps (metatarsal amputation); B, B, Disarticulation of anterior part of foot at medio-tarsal joints, by short dorsal and long plantar flaps (Chopart's operation).

and plantar flaps united in a transverse line. The stump is supported upon a splint.

Comment.—If the division of the metatarsus is made nearer its base, the flaps will be proportionately shorter. The flaps may also be made of equal length, or otherwise planned—according to available tissue.

DISARTICULATION OF TOES WITH THEIR ENTIRE METATARSALS.

Best Methods.—Racket—toes in general. Racket, with or without an additional transverse incision at upper end of queue—for great or little toe.

Short Dorsal and Long Plantar Flaps (Lisfranc's Operation)—for the toes *en masse.* Short Dorsal and Long Plantar Flaps, with sawing off the end of the internal cuneiform (Hey's Operation)—for the toes *en masse.*

Other Methods.—Internal Flap—for great toe. External Flap—for little toe. Equal Plantar and Dorsal Flaps—for the toes *en masse.* Long Plantar Flap—for the toes *en masse.*

DISARTICULATION OF TOE WITH ITS ENTIRE METATARSAL

BY RACKET METHOD.

Description.—The coverings are gotten from the lateral and plantar aspects, and the cicatrix is vertical and dorso-terminal.

Position.—As in the metatarsal amputation, page 348.

Landmarks.—Tarso-metatarsal joint; interdigital web.

Incision.—Begins just above the tarso-metatarsal joint, in the mid-dorsal aspect—passes vertically down in the median line to the head of the metatarsal—thence the two limbs of the oval diverge—the outer limb running downward across the outer aspect of the toe to the web—the inner limb across the inner aspect to the web—the two meeting in the digito-plantar crease (which about corresponds to the center of the first phalanx) (Fig. 271, J).

Operation.—Deepen the vertical incision, dividing the extensor tendons as high up as encountered, while the toe is flexed. Deepen the oval incision to the bone, upon the lateral and plantar aspects, extending the toe while severing the flexor tendons transversely. Free the soft parts along the dorsum and lateral surfaces, with a periosteal elevator, hugging the bone closely. Forcibly extend the toe and its metatarsal and free the plantar surface as far as possible. Sever, from the dorsum, the ligaments binding the metatarsal to the tarsus and to the adjacent metatarsals, while the toe is being manipulated and the ligaments are put upon the stretch—thus completing the disarticulation. Divide the flexor tendons high up and close the sheaths. Two dorsal and two plantar digital arteries are cut and are to be tied. Suture the wound in one vertical line.

Comment.—(1) By hugging the bone very closely and guarding the point of the knife while disarticulating, minimum damage is done to the tissues of the sole of the foot. (2) Disarticulation of the second toe from the tarsus and adjacent metatarsals is somewhat difficult (see Lisfranc's operation).

DISARTICULATION OF GREAT TOE WITH ITS ENTIRE METATARSAL

BY RACKET METHOD.

Description—Landmarks.—As in the last operation.

Incision.—Begins just above the tarso-metatarsal joint, at its dorso-internal aspect—passes vertically downward along the outer margin of the extensor tendon to just beyond the center of the metatarsal—thence the two limbs of the oval diverge—the outer limb passing across the dorso-external aspect of the toe to the web—the inner limb passing across the dorso-internal aspect to the plantar surface at a point opposite the web—the two limbs meeting in the digito-plantar crease. If needed for purpose of exposing the joint more readily, an additional transverse incision may be added to the upper end of the vertical incision, running as far as thought necessary directly inward parallel to the tarso-metatarsal joint (Fig. 274, B).

Operation.—Deepen the vertical incision, exposing and dividing the

tendons of the extensor proprius and brevis hallucis near the tarso-metatarsal joint. Deepen the limbs of the oval, cutting to the bone along the lateral and plantar surfaces. Free, up to the tarso-metatarsal joint, the soft parts from the external, internal, and plantar surfaces of the metatarsal and phalanx by closely hugging the bones with periosteal elevator, rotating the toe as indicated. The sesamoid bones are left behind, and the structures about the metatarso-phalangeal joint are removed as nearly subcapsulo-periosteally as possible, in order to retain the attachment of the severed tendons there inserted. Open the tarso-metatarsal joint from the dorsum, completing the disarticulation by severing the remaining ligaments while under tension

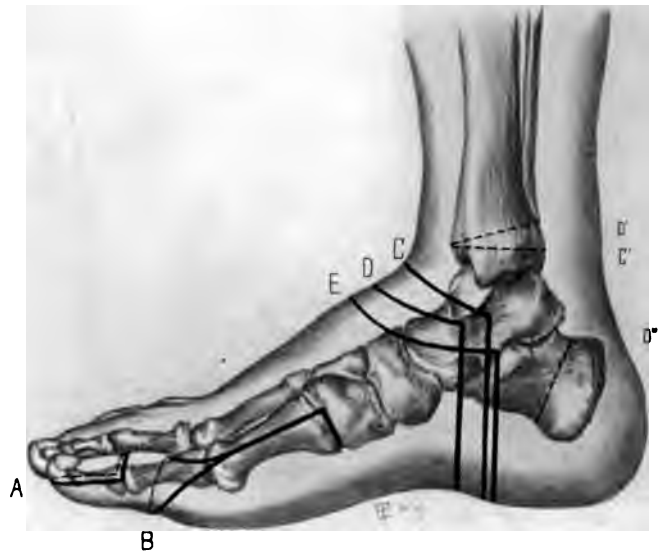

Fig. 274.—AMPUTATIONS ABOUT THE TOES AND FOOT—Inner view :—A, At interphalangeal joint of great toe, by plantar flap; B, Of great toe and its metatarsal, at tarso-metatarsal joint, by racket method, with transverse incision added to upper end; C, Inner aspect of plantar and dorsal incisions in Syme's disarticulation of foot at ankle, by heel-flap; C', Line of tibial and fibular section; D, Inner aspect of plantar and dorsal incisions, in Pirogoff's disarticulation at ankle, by heel-flap; D', Line of section of bones of leg, in same; D'', Line of section of os calcis, in same; E, Inner aspect of plantar and dorsal incisions in subastragaloid disarticulation of foot, by heel-flap.

during the manipulation of the toe. Divide the tendons of the peroneus longus and tibialis anticus. Cut the flexor tendons short and close their sheaths. The following arteries are divided—two dorsal digital, two plantar digital, and termination of internal plantar. Guard against wounding the communicating branch of the dorsalis pedis in the first interosseous space. The suture line will be vertical and fall over the dorso-external aspect of the toe, out of the way of pressure.

Comment.—When the upper transverse incision is added, the vertical incision generally begins just below the tarso-metatarsal joint and the transverse incision is then parallel with the tarso-metatarsal joint. When the vertical incision alone is used, it begins over the internal cuneiform.

DISARTICULATION OF LITTLE TOE WITH ITS ENTIRE METATARSAL

BY RACKET METHOD.

Description—Landmarks.—As in the last operation.

Incision.—Begins just above the tarso-metatarsal joint at its dorso-external aspect—passes vertically downward along the outer margin of the extensor tendon to just beyond the center of the metatarsal—thence the two limbs of the oval diverge—the inner limb passing across the dorso-internal aspect of the toe to the web—the outer limb passing across the dorso-external aspect of the plantar surface at a point opposite the web—the two limbs

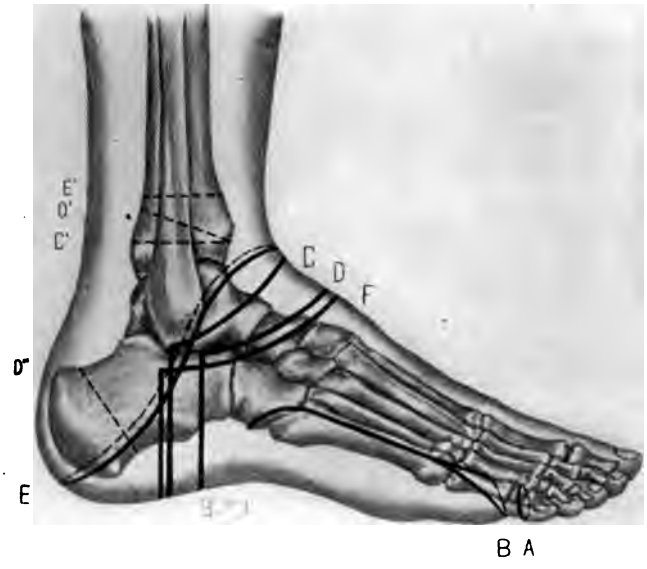

Fig. 275.—AMPUTATIONS ABOUT THE TOES AND FOOT—Outer view:—A, Through first interphalangeal joint of little toe, by oblique circular method; B, Of little toe and its metatarsal, by racket method, with added curved incision at upper end; C, Outer aspect of plantar and dorsal incisions, in Syme's disarticulation of foot at ankle, by a heel-flap; C', Line of section through tibia and fibula, in same; D, Outer aspect of plantar and dorsal incisions, in Pirogoff's disarticulation at ankle; D', Line of section of tibia and fibula in same; D'', Line of section of os calcis, in same; E, Supramalleolar amputation of leg, by oblique elliptical incision; E', Tibial and fibular section in same; F, Outer aspect of dorsal and plantar incisions in Subastragaloid Disarticulation of foot by heel-flap.

meeting in the digito-plantar groove. If needed for purpose of more readily exposing the joint, an additional transverse, or oblique, incision may be added to the upper end of the vertical incision, by prolonging the latter a short way directly outward parallel with the tarso-metatarsal joint (Fig. 275, B).

Operation.—The steps of the operation are practically the same as in the corresponding operation upon the great toe (page 350). The metatarsal is disarticulated from the cuboid and from the fourth metatarsal. Two dorsal and two plantar digital arteries are cut.

DISARTICULATION OF TWO OR THREE CONTIGUOUS TOES WITH THEIR ENTIRE METATARSALS

BY OVAL OR RACKET METHOD.

Description.—Same, in principle, as the operation for the removal of a single toe and its metatarsal (page 350). Where two contiguous toes are removed, the vertical portion of the incision is placed between the two toes, beginning just above the saw-line and diverging to include both toes—meeting on the plantar surface of the web between them. Where three contiguous toes are removed, the vertical portion of the incision is placed over the middle metatarsal, beginning at the saw-line, or just above, and diverging to include all three toes, meeting at the center of the plantar surface of the middle toe, in the digito-plantar crease (Fig. 271, I).

DISARTICULATION OF ALL THE TOES AT TARSO-METATARSAL JOINTS

BY SHORT DORSAL AND LONG PLANTAR FLAPS—LISFRANC'S OPERATION.

Description.—Disarticulation of the anterior portion of the foot at the tarso-metatarsal line—the stump being formed of plantar and dorsal tissues.

Position.—As for the metatarsal amputation (page 348).

Landmarks.—Tarso-metatarsal joint-line; heads of metatarsals.

Incision.—(Supposing the foot of the right side to be operated upon) —(1) Dorsal Flap—The surgeon's left hand grasps the foot with his thumb on the base of the fifth metatarsal and forefinger on the base of the first, his palm to the sole—the foot being extended. The incision begins just behind the base of the fifth metatarsal, nearer the plantar than dorsal surface —passes straight down the outer aspect of the foot for 2.5 cm. (1 inch)— thence rounds onto the dorsum and crosses the foot with slight downward convexity, parallel with and about 1.3 cm. (½ inch) below the tarso-metatarsal joints, reaching the inner border of the foot 1.3 cm. (½ inch) below the tarso-metatarsal joint—thence rounds into the inner aspect of the foot and passes straight upward and ends 2 cm. (¾ inch) above the cuneiform-metatarsal articulation, somewhat nearer the plantar than the dorsal aspect. (2) Plantar Flap—the surgeon holds the toes between the fingers on the dorsum and thumb on the plantar surfaces—the foot being flexed. The incision is continuous with the horizontal portion of the dorsal incision, passing down the outer lateral aspect of the foot along the plantar edge of the fifth metatarsal to just below its middle—then gradually rounds into the sole and sweeps obliquely across the plantar surface in such a way as to cross the fifth metatarsal just above its neck, the fourth metatarsal at its neck, the third and second opposite their heads, and then the first metatarsal at the metatarso-phalangeal joint—thence rounds into the inner mid-lateral aspect of the foot and passes straight up its border, along the plantar edge of the first metatarsal, to become continuous with the vertical portion of the dorsal incision (Fig. 272, B, B).

Operation.—Deepen the dorsal line to the extensor tendons and free back the superficial tissues for about 6 mm. (¼ inch)—and then divide all the soft parts down to the bones, while the foot is fully extended on the leg and the toes flexed on the foot—and free the flap to the joint-line, hugging the bone to save the interosseous vessels and portions of interosseous muscles.

Deepen the plantar incision to the flexor tendons and free back the flap of superficial tissues to the hollow behind the heads of the metatarsals—and then divide all the soft parts down to the bones, while the foot is fully flexed on the leg and the toes extended on the foot—and free the flap to the tarso-metatarsal joint-line. Both flaps contain all the soft parts to the bones. Disarticulation is now accomplished from the dorsum. Retract the flaps—extend the foot—and begin the disarticulation by entering the knife behind the prominent base of the fifth metatarsal, at the outer side of the foot—and then, passing obliquely forward and inward, cut the peroneus brevis and tertius tendons and disarticulate the fifth, fourth, and third metatarsals. Then turn to the inner side of the foot, and sever the ligaments of the first tarso-metatarsal joint, and divide the expansion of the tibialis anticus. There remains the freeing of the second metatarsal, which is somewhat difficult, unless undertaken in a definite manner. Hold the knife like a dagger, with the cutting-edge toward the ankle, the blade pointing forward at an angle with the dorsum of the foot—enter the point deeply between the bases of first and second metatarsals, where they begin to bind—elevate the handle until perpendicular to the dorsum, cutting, at the same time, forward—and thus the ligaments binding the base of the second metatarsal to the base of the first metatarsal and internal cuneiform are severed (the manœuvre being called the "coup de maître"). Repeat this manœuvre between the bases of the second and third metatarsals. Complete the disarticulation of the second metatarsal by severing, from the dorsum, the ligaments between the middle cuneiform and base of the metatarsal. Divide any connecting bands upon the plantar aspect of the joints. The peroneus longus tendon now alone holds the metatarsal—put this upon the stretch, dividing it high up. The following arteries are to be tied—in the dorsal flap; four dorsal interosseous, communicating branch of dorsalis pedis;—in plantar flap; five plantar digital branches of external plantar (and possibly the external plantar itself) and the termination of the internal plantar. Suture any open sheaths. Quilt the muscles. Suture the plantar and dorsal flaps in one transverse line. Support the stump upon a splint.

Comment.—(1) The plantar flap may be cut first. (2) The dorsal flap may be made and disarticulation accomplished, and then the plantar flap cut from within outward—which is not so satisfactory as the above. (3) Freer allowance should be made to cover the thicker inner than the thinner outer side of the foot—which is the reason for cutting the inner aspect of the flap longer. (4) Guard against making the dorsal flap too short and too scant on the dorsal aspects—and also against making either flap too pointed. (5) Guard against mistaking the scapho-cuneiform joint for the metatarso-cuneiform joint. (6) Guard the plantar tissues while disarticulating the second metatarsal. (7) The dorsal flap should include most of the tissues upon the outer and inner aspect of the foot. (8) This method makes an excellent and useful stump.

DISARTICULATION OF ALL THE TOES AT THE TARSO-METATARSAL JOINTS, WITH SAWING OFF OF END OF INTERNAL CUNEIFORM.

BY SHORT DORSAL AND LONG PLANTAR FLAPS—HEY'S OPERATION.

Description.—This operation is similar to Lisfranc's as to incisions, freeing of flaps, ligation of vessels and suturing of wound—differing only in one respect—namely, after disarticulating the four outer metatarsals,

the protruding end of the innermost cuneiform is sawed off on a line with the others, and removed together with the first metatarsal still articulated.

DISARTICULATION OF ANTERIOR PART OF FOOT AT MEDIO-TARSAL JOINT, IN GENERAL.

Best Methods.—Short Dorsal and Long Plantar Flaps—Chopart's Operation.

Other Methods.—Modified Oval (Tripier's Operation)—medio-tarsal disarticulation, with horizontal sawing of os calcis.

DISARTICULATION OF ANTERIOR PART OF FOOT AT MEDIO-TARSAL JOINT

BY SHORT DORSAL AND LONG PLANTAR FLAPS—CHOPART'S OPERATION.

Description.—Disarticulation of anterior portion of foot at astragalo-scaphoid and calcaneo-cuboid joints, by means of a short dorsal and long plantar flap—the operation being somewhat similar to Lisfranc's tarso-metatarsal disarticulation.

Position.—As for Lisfranc's operation.

Landmarks.—Astragalo-scaphoid joint (just behind the tuberosity of the scaphoid); calcaneo-cuboid joint (midway between the external malleolus and tubercle of fifth metatarsal); tarso-metatarsal joint-line; middle of metatarsus.

Incisions.—(Right foot)—Plantar incision—begins on outer aspect of foot, little nearer plantar than dorsal surface, and at a point opposite the calcaneo-cuboid joint (see Landmarks)—passes straight down the outer side of foot to near middle of fifth metatarsal—thence rounds inward and crosses sole of foot, opposite the middle of the metatarsals, to the inner side of the foot—rounds into the inner border of the foot and passes straight up that border, little nearer the plantar than dorsal surface, to a point opposite the astragalo-scaphoid joint (see Landmarks). Dorsal incision—begins by curving from the outer limb of the plantar incision, just posterior to the fifth tarso-metatarsal joint—and ends by curving into the inner limb of the plantar incision just posterior to the first tarso-metatarsal joint—crossing the dorsum opposite the bases of the metatarsals (Fig. 273, B, B).

Operation.—Deepen the plantar incision, the foot flexed on the leg and the toes extended on the foot, to the flexor tendons. Free the skin and fascia a short distance—divide all soft parts to the bones—and dissect up the flap of the entire soft parts to the tarso-metatarsal joint. Deepen the dorsal incision, the foot extended on the leg and the toes flexed on the foot, to the extensor tendons. Free the skin and fascia a short distance—divide all the soft parts to the bones—and dissect up the flap of the entire soft tissues to the tarso-metatarsal joint. Disarticulate from the dorsum while the foot is forcibly extended—rotating the forepart of the foot outward while severing the ligaments of the astragalo-scaphoid joint, and inward while dividing those of the calcaneo-cuboid articulation. The tendons of the tibialis anticus and posticus, and peroneus tertius, brevis, and longus, are cut among the deeper structures. Quilt the muscular and tendinous tissues of the two flaps, especially suturing the extensor tendons and tibialis anticus of the dorsal flap, to the tissues of the plantar flap—in order to counteract the

tendency of the tendo Achillis to permanently extend the foot. In the dorsal flap, the dorsalis pedis and its tarsal and metatarsal branches are cut—and in the plantar flap, the terminations of external and internal plantar arteries, and plantar digital branches.

Comment.—(1) Considerable tendency exists for displacement of the bones of the stump subsequent to healing—either the posterior portion of the os calcis being drawn up by the tendo Achillis, thus throwing the head of the os calcis downward to be pressed upon in walking—or the stump is turned into the varus position and the patient walks upon the outer border of the os calcis. (2) The proportionate lengths of the flaps and the manner of their making may be varied, as described in Lisfranc's operation. The total covering required is about 1½ diameters at the saw-line.

DISARTICULATION OF FOOT AT ASTRAGALO-SCAPHOID AND ASTRAGALO-CALCANEAL ARTICULATIONS—SUBASTRAGALOID DISARTICULATION—IN GENERAL.

Best Methods.—Large Interno-plantar Flap (Farabeuf). Heel-flap.

Other Methods.—Oval, or Racket Method (Maurice Perrin). Oval Method (Verneuil).

Comparison.—The interno-plantar flap furnishes the best blood-supply—the cicatrix is well placed and the stump is broad. But the method requires considerable healthy, available tissue—the operation is somewhat difficult to perform—and the flap is somewhat unwieldy. The heel-flap method is a simpler operation and requires minimum tissue—but gives a narrower stump.

DISARTICULATION OF FOOT AT ASTRAGALO-SCAPHOID AND ASTRAGALO-CALCANEAL JOINTS—SUBASTRAGALOID DISARTICULATION

BY LARGE INTERNO-PLANTAR FLAP—FARABEUF.

Description.—A modified oval method. The structures below the astragalus are removed—the stump being covered by a large flap gotten from the sole and inner border of the foot—the scar being horizontal and upon the outer and anterior aspects of the foot.

Position.—As in the preceding operations, in general—the surgeon so manipulating the foot with his left hand as to turn it from side to side in following the complicated incision.

Landmarks.—Tendo Achillis; external malleolus; base of fifth metatarsal; joint between scaphoid and cuneiforms; joint-line between scaphoid and internal and middle cuneiforms; tendon of extensor longus hallucis, cuneo-metatarsal joint of big toe; external tuberosity of os calcis.

Incision.—Begins at outer margin of insertion of tendo Achillis—curves upward to a point 2.5 cm. (1 inch) below the external malleolus—passes horizontally forward at this level, parallel with the border of the foot, until a point is reached on a line connecting the base of the fifth metatarsal with the joints between the scaphoid and cuneiform bones—thence curves sharply across the dorsum, just anterior to the joint-line between the scaphoid with the internal and middle cuneiforms, until the tendon of the extensor longus hallucis is reached—thence curves slightly forward to cross the inner border of the

foot in the line of the cuneo-metatarsal joint of great toe—thence sweeps across the center of the sole—and, curving into the outer border of the foot, follows that border to the external tuberosity of the os calcis—thence upward to end at the insertion of the tendo Achillis, at the point of beginning (Fig. 276).

Operation.—The above incision is now everywhere deepened to the bone along the line of retracted skin and fascia, using a stout knife and cutting with force as the parts are put upon the stretch—cutting all tendons cleanly —and opening no joints. Now flex the leg upon the thigh, turn the knee inward, and press the inner side of the leg on the table, so that the outer side of the leg presents and the foot is beyond the edge and kept upon the stretch. Dissect up, cleanly from the bones, the outer dorsal portion of the flap, until the head of the astragalus is exposed in front and the tendo Achillis

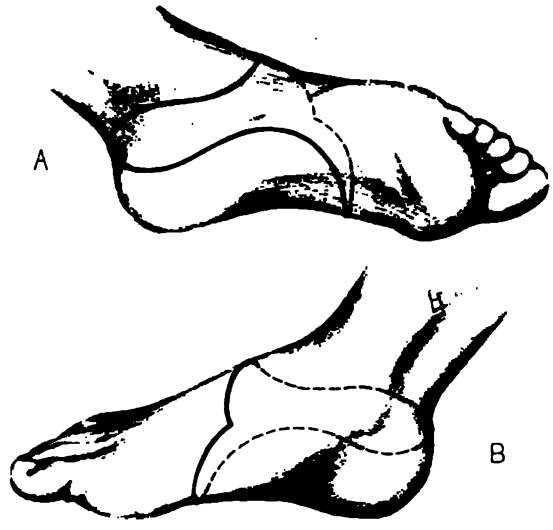

Fig. 276.—Subastragaloid Disarticulation of Foot by Large Interno-plantar Flap (Farabeuf):—A, Outline of incision upon outer aspect of foot; B, Outline of incision upon inner aspect.

behind—divide the tendo Achillis—enter the astragalo-scaphoid joint on its dorsal aspect—keep the knife in the interarticular line and cut backward between the astragalus and os calcis, passing beneath the tip of the external malleolus to the already cut tendo Achillis, severing all ligaments and everting the os calcis as the ligaments are cut—until the under surface of the astragalus is free. The foot is further twisted into extreme varus, and the inner and under surfaces of the os calcis are bared, working from the inner toward the under and outer surfaces of the os calcis, by cutting with short strokes of a strong knife, and closely hugging the bone to avoid damaging important structures on the inner aspect, especially the vessels which supply the flap. By the time the externo-plantar border of the os calcis is reached, the dorsum of the foot will be looking downward. Free the skin from the posterior surface of the os calcis carefully so as not to score the integumentary parts. Sever any emaining connections. Cut the anterior and posterior tibial

nerves high up. The following arteries are encountered, in the direction of the incision, and will require ligation—posterior peroneal, anterior peroneal, dorsalis pedis, internal plantar and external plantar. Provide temporary drainage, by puncturing the heel portion of the flap. Quilt the muscles and tendons. Suture the flap in an external and anterior horizontal line. Dress the stump upon a posterior splint.

DISARTICULATION OF FOOT AT ASTRAGALO-SCAPHOID AND ASTRAGALO-CALCANEAL JOINTS—SUBASTRAGALOID DISARTICULATION

BY HEEL FLAP.

Description.—The structures removed are the same as in the above operation. In the present instance the coverings are furnished from the heel and sole tissues. The steps of the operation are very similar to those of Syme's disarticulation of the foot at the ankle-joint.

Position.—See Syme's operation (page 360).

Landmarks.—External and internal malleoli.

Incisions.—Plantar incision—begins 1.3 cm. (½ inch) below the tip of the external malleolus—passes directly across the sole of the foot—and ends 2.5 cm. (1 inch) below the posterior border of the internal malleolus. Dorsal incision—is U-shaped, connecting the upper ends of the plantar incision—curving across the dorsum on a level with the astragalo-scaphoid joint (Fig. 274, E, and Fig. 275, F).

Operation.—For the general steps of the operation, see Syme's disarticulation at the ankle-joint (page 360), which is similar in general principle, though different in detail. Deepen the incisions to the bones—dissect the heel-flap backward and the dorsal flap upward—open the astragalo-scaphoid joint from the dorsum and cut backward, disarticulating the astragalus from the os calcis. The extreme head of the astragalus may be sawed off. The operation is concluded as in Syme's—the same vessels being also ligated.

Other Amputations About the Foot.—(1) Anterior Intertarsal Disarticulation (Jaeger's Operation)—consists of a disarticulation between the three cuneiforms posteriorly, and the scaphoid anteriorly—the cuboid being sawed across in a line with the disarticulation. This would occupy a position between Lisfranc's tarso-metatarsal disarticulation and Chopart's mediotarsal disarticulation. (2) Amputation Through the Posterior Tarsus—if soft parts cannot be gotten to cover Chopart's stump, the articular surfaces of the astragalus and os calcis are sawed off. (3) Subastragaloid Osteoplastic Amputation (Hancock's Operation)—the tuberosity of the os calcis is sawed off and applied to the lower surface of the astragalus, from which the articular cartilage has been removed.

SURGICAL ANATOMY OF ANKLE-JOINT.

Bones.—Tibia; fibula; astragalus.

Articulations and Ligaments.—Anterior tibio-tarsal, posterior tibio-tarsal, external lateral (consisting of anterior astragalo-fibular, posterior astragalo-fibular, and middle calcaneo-fibular fasciculi), internal lateral (or deltoid) ligaments, and synovial membrane.

Muscles.—See under Foot (page 345) and Leg (page 362).

Movements of Ankle-joint.—Extension—by gastrocnemius, soleus, plantaris, tibialis posticus, peroneus longus, peroneus brevis, flexor longus digitorum, flexor longus hallucis. Flexion—by tibialis anticus, peroneus tertius, extensor longus digitorum, extensor proprius hallucis. Adduction—tibialis anticus, tibialis posticus. Abduction—Peroneus longus, peroneus brevis.

Arteries.—Following branches of anterior tibial—internal and external malleolar and dorsalis pedis. Following branches of posterior tibial—internal calcaneal branch of posterior tibial:—and following branches of peroneal branch of posterior tibial; anterior peroneal, posterior peroneal, and external calcaneal.

Veins.—Superficial—internal saphenous and tributaries; external saphenous and tributaries. Deep—Two venæ comites accompany each artery.

Nerves.—From lumbar plexus—internal saphenous from anterior crural. From sacral plexus—following from great sciatic—external saphenous (from communicans poplitei and communicans peronei); plantar cutaneous, articular, internal plantar and external plantar (from posterior tibial); articular, muscular and external (or tarsal) (from anterior tibial); and internal and external branches of musculocutaneous.

Annular Ligaments.—See under Foot (page 344).

SURFACE FORM AND LANDMARKS OF ANKLE-JOINT.

The general feature of the ankle-joint is that of the prominently rounded superior surface of the astragalus received into the dome of the tibia, and bounded laterally by the descending malleoli.

The line of the joint is transverse—crossing the front of the leg about 1.3 cm. (½ inch) above the tip of the internal malleolus.

The external malleolus extends from 1.3 to 2 cm. (½ to ¾ inch) lower than the internal—and is placed upon a plane about 1.3 cm. (½ inch) posterior to the internal malleolus. The external malleolus is opposite the center of the joint—the internal is in front of the center of the joint. The tip of the external malleolus is nearer the posterior border of the fibula, and the tip of the internal malleolus nearer the anterior border of the tibia.

Chief structures about the ankle-joint—Anteriorly—(from within outward) tibialis anticus, extensor proprius hallucis, anterior tibial artery, anterior tibial nerve, extensor longus digitorum, peroneus tertius. Posteriorly—tendo Achillis. Internally—(from before backward) tibialis posticus, flexor longus digitorum, companion vein, posterior tibial artery, companion vein, posterior tibial nerve, flexor longus hallucis. Externally—(from before backward) peroneus brevis, peroneus longus, external calcaneal and termination of peroneal artery.

The lower epiphysis of the tibia includes the articular surface and internal malleolus, and unites about the eighteenth year. The lower epiphysis of the fibula includes the articular surface and outer malleolus, and unites about the twenty-first year.

GENERAL SURGICAL CONSIDERATIONS IN DISARTICULATIONS AT ANKLE-JOINT.

Great care should be taken of the blood-supply to the heel tissues forming the stump—the chief vessels being the external calcaneal of the posterior

peroneal, externally; and the internal calcaneal of the external plantar, internally.

In section of the lower ends of the tibia and fibula most of the anterior and posterior tibio-fibular and interosseous ligaments are saved.

A posterior splint is used in the dressing following disarticulation.

DISARTICULATION OF FOOT AT ANKLE-JOINT, WITH REMOVAL OF MALLEOLI AND ARTICULAR SURFACE OF TIBIA, IN GENERAL.

Best Method.—Heel-flap—Syme's operation.

Other Methods.—Modified Oval Method—Roux's operation. Large Interno-plantar Flap—Farabeuf's operation. Internal Lateral Flap. Modified External Racket. Dorsal Flap.

DISARTICULATION OF FOOT AT ANKLE-JOINT, WITH REMOVAL OF MALLEOLI AND ARTICULAR SURFACE OF TIBIA,

BY HEEL FLAP—SYME'S OPERATION.

Description.—As described in the title.

Position.—Patient supine; foot elevated and over edge of table. Assistant steadies leg with one hand and holds foot at right angle to leg by grasping toes with other hand. Surgeon sits for plantar and stands for dorsal incisions.

Landmarks.—Outline of ankle-joint; malleoli.

Incisions.—Plantar incision—begins at tip of external malleolus, on the right side (the surgeon's left palm resting on the instep, with forefinger and thumb upon the malleoli)—passes vertically down the outer side of the foot, across the sole and vertically up the inner side of the foot to a point 1.3 cm. (½ inch) below the tip of the internal malleolus. This incision passes exactly at a right angle to the long axis of the foot, in a straight line between these two points—if inclined forward, the flap is very difficult to dissect from the os calcis—if inclined backward, it is easier to separate but apt to form a scanty covering, with imperfect vascular supply. If the inner limb of the vertical incision passes up to the posterior border of the inner malleolus, the posterior tibial artery is more in danger of being divided before its bifurcation and the main branch of the flap, the internal calcaneal of the external plantar, lost. The above incision is made in two cuts, each from a malleolus to the center of the sole. Dorsal incision—(surgeon's left palm to sole, with thumb and first finger grasping the margins of the foot and extending it)—connects the upper ends of the plantar incision by an incision sweeping straight across the front of the ankle. The dorsal and plantar incisions are approximately at a right angle to each other (Fig. 274, C, C′, and Fig. 275, C, C′).

Operation.—The plantar incision, made with a strong knife, passes directly and cleanly to the bone. The large heel-flap is freed from the os calcis as far as its tuberosities, partly by the use of the left thumb, partly by a stout knife cutting close to the bone. It is possible, but difficult and unadvisable, to entirely dissect and retract the heel-flap from the tuberosities and posterior surface of the os calcis, from the plantar wound. With the

foot fully extended the dorsal incision is now made directly to the bone, cutting the tendons and ligaments cleanly. This incision cuts directly through the anterior ligament of the ankle-joint and opens the articulation. The disarticulation is continued by cutting the lateral ligaments from within outward, and completed by similarly cutting the posterior ligament. The tendo Achillis is now cut. The foot is then drawn downward and forward and the posterior and lateral surfaces of the os calcis dissected free of the heel covering by working from behind downward and forward with short, close strokes of the knife while the parts are under tension. The malleoli are now closely cleared of their soft parts, hugging the bones and guarding the flaps. The soft parts are well retracted —and the tibia and fibula are sawed transversely at about 6 mm. (¼ inch) above the inferior border of the tibia (which will remove the articular surface of the dome)—the malleoli being steadied by forceps during the sawing. Ligate the anterior tibial, external and internal plantar, and probably the external and internal malleolar of the anterior tibial, the anterior peroneal, internal malleolar of posterior tibial, and internal and external saphenous veins. Cut all nerves short, especially those of the heel-flap, which is bent over the ends of the sawed bones. Suture the heel-flap to the dorsal incision—using tension-sutures in addition to coaptation-sutures, if there be much strain upon the suture-line. Institute drainage through a counter-opening in the heel-flap, if indicated. So dress the part, with a posterior splint included, as to draw the heel-flap forward and upward.

Comment.—(1) This is probably the best form of disarticulation about the ankle and usually furnishes a very satisfactory result. (2) It is advisable to free the os calcis subperiosteally, if possible—and also to leave the posterior epiphysis, in the young, in the flap.

DISARTICULATION OF FOOT AT ANKLE-JOINT, WITH REMOVAL OF MALLEOLI, ARTICULAR SURFACE OF TIBIA, AND ANTERIOR PART OF OS CALCIS,—IN GENERAL.

Best Method.—Heel-flap—Pirogoff's operation.

Other Methods.—Racket Method (Pasquier-LeFort)—racket from inner side, with horizontal division of calcaneum. Watson's modification of Pirogoff's Heel-flap Method—sawing calcaneum from plantar surface immediately after plantar incision. Sédilot's modification of Pirogoff's operation—middle (internal) oval method, with oblique sawing of calcaneum. Others have sawed the os calcis in angular and curved directions.

DISARTICULATION OF FOOT AT ANKLE-JOINT, WITH REMOVAL OF MALLEOLI, ARTICULAR SURFACE OF TIBIA, AND ANTERIOR PART OF OS CALCIS,

BY HEEL-FLAP—PIROGOFF'S OPERATION.

Description.—An intra-calcaneal osteoplastic amputation of the foot. The operation is very similar to Syme's, except that the anterior and major portion of the os calcis is sawed off and the remaining posterior portion, which is left in the heel-flap, is adjusted to the transversely sawed tibia and fibula.

Position—Landmarks.—As in Syme's operation (page 360).

Incisions.—Plantar incision (right foot)—begins just anterior to the tip of the external malleolus—passes vertically down the outer side of the foot, across the sole, and vertically up the inner side of the foot to a point 1.3 cm. (½ inch) below and a short distance anterior to the tip of the internal malleolus (which points are a little anterior to those of Syme's operation). Dorsal incision—is somewhat more convex; that is, passes further down on the dorsum of the foot than does Syme's (Fig. 274, D, D′, D″, and Fig. 275, D, D′, D″).

Operation.—These incisions are made and deepened in the same manner as in Syme's operation. The heel-flap is not freed back from the plantar surface of the os calcis quite to its tuberosities. The disarticulation is accomplished as in Syme's. The foot is placed in extreme extension and the upper surface of the os calcis exposed, but the tendo Achillis not cut. The whole of the os calcis having been freed except its posterior third, the saw is applied (with the foot in extension) to the upper surface of the os calcis, 1.3 to 2 cm. (½ to ¾ inch) behind the astragalus, and made to saw its way obliquely downward and forward (or more nearly vertically, in the extended position of the foot) in a line about parallel with the now distorted heel incision—all the soft parts being carefully retracted the while, especially the inner arteries. The lower ends of the tibia and fibula are then freed as in Syme's and are sawed off in the same manner, except that, after entering the anterior surface of the bone about 6 mm. (¼ inch) above the inferior border of the tibia, the section is so made that the saw emerges posteriorly about 1.3 cm. (½ inch) higher than on the anterior surface (to be parallel with the section of the calcaneum). Ligate the same vessels as encountered in Syme's operation. Cut the nerves short and the loose tendons. Approximate the sawed calcaneum to the sawed tibia—and suture the plantar flap to the dorsal incision.

Comment.—(1) If the sawed ends of the bone do not lie in good apposition, a thin slice of bone may be further removed with the saw where indicated —or the surfaces of bone may be nailed or pegged together. But when the proper calculations are made the surfaces can generally be held in contact by the suturing together of the fibrous tissues surrounding the sawed ends, with buried chromic gut. (2) The stump thus gained is a little longer than in Syme's operation—the flap is better nourished, is firmer, contains bone and tendo Achillis, and the movement is greater. But the bone is apt to necrose, or become displaced, or may not unite. The operation is more suitable to traumatic cases. An artificial limb is harder to fit. The method is, altogether, not superior to Syme's.

SURGICAL ANATOMY OF LEG.

Bones.—Tibia; fibula.

Articulations and Ligaments.—(a) Superior Tibio-fibular Articulation—anterior and posterior superior tibio-fibular ligaments, and synovial membrane. (b) Middle Tibio-fibular Articulation—interosseous membrane. (c) Inferior Tibio-fibular Articulation—anterior and posterior inferior tibio-fibular and transverse ligaments, inferior interosseous membrane, and synovial membrane.

Muscles.—(a) Anterior Tibio-fibular Region:—tibialis anticus; extensor proprius hallucis; extensor longus digitorum; peroneus tertius. (b) Posterior Tibio-fibular Region:—(1) Superficial Muscles:—gastrocnemius, soleus, plantaris. (2) Deep Muscles:—popliteus, flexor longus hallucis, flexor

longus digitorum, tibialis posticus. (c) Outer, or Fibular, Region:—peroneus longus, peroneus brevis.

Arteries.—Following branches of popliteal—inferior muscular, inferior external articular, inferior internal articular. Anterior tibial and following branches—posterior recurrent tibial, superior fibular, anterior recurrent tibial, muscular, internal malleolar, external malleolar. Posterior tibial and following branches:—peroneal (with its muscular, nutrient, anterior peroneal, and communicating branches), muscular, nutrient, and communicating branches.

Veins.—Superficial—internal saphenous and tributaries—external saphenous and tributaries. Deep—Two venæ comites for each artery.

Nerves.—(a) From lumbar plexus—(1) From anterior crural; posterior branch of internal cutaneous; long saphenous branch and its branches. (b) From sacral plexus—(1) From great sciatic—anterior popliteal and muscular branches; communicans poplitei. Posterior tibial and muscular branches. External popliteal (or peroneal) and cutaneous branches. Anterior tibial and muscular branches. Musculocutaneous and muscular and cutaneous branches.

SURFACE FORM AND LANDMARKS OF LEG.

Following parts of the tibia are palpable—external tuberosity (more prominent); internal tuberosity (broader); tubercle; anterior border, or crest (for upper two-thirds); internal border; internal surface (from tuberosity to malleolus); internal malleolus.

Following parts of fibula are palpable—head; lower part of external surface of shaft (between peroneus tertius, and peronei longus and brevis); external malleolus.

The fibula is on a plane considerably posterior to the tibia.

No muscular fibers are attached to the lower third of the tibia.

The sharp crest of the tibia has become rounded in its lower third.

The interosseous space is widest at the center of the leg, decreasing in width toward both ends.

The tibialis anticus forms a muscular prominence running down the leg external to the tibia. The extensor longus digitorum, a smaller prominence, fills the rest of the interval between the fibula and the tibialis anticus muscle—a groove intervening between these two muscles above, and the extensor proprius hallucis coming to the front between them below.

Externally, the peroneus longus, brevis, and tertius form a muscular prominence.

The internal aspect of the leg is formed—anteriorly, by the subcutaneous tibia—posteriorly, by the projecting border of the soleus and tendon of the tibialis posticus.

The fleshy mass of the calf is formed by the gastrocnemius and soleus, tapering to the tendo Achillis—and beneath them the popliteus, flexor longus hallucis, flexor longus digitorum, and tibialis posticus.

A groove exists between either malleolus and the extended tendo Achillis.

The interosseous membrane separates the anterior from the posterior tibio-fibular muscles.

Tendons predominate over muscles in the lower third of the leg.

The gastrocnemius and soleus have joined by the time the lower third of the leg is reached.

The greatest girth of the leg is at about the junction of the upper and

middle thirds—tapering gradually above to the knee-joint—and rapidly decreasing in size below toward the ankle.

The popliteal artery bifurcates about 5 cm. (2 inches) below the knee-joint—on a level with the lower part of the tubercle of the tibia. In amputating 2.5 cm. (1 inch) below the head of the fibula, one main artery, the popliteal, is cut—at 5 cm. (2 inches), two main arteries, the anterior and posterior tibials—and at 7.5 cm. (3 inches), three main arteries, the anterior and posterior tibials and the peroneal (Holden).

GENERAL SURGICAL CONSIDERATIONS IN AMPUTATIONS ABOUT THE LEG.

In the lower and middle thirds of the leg, the bulk of the muscles are posterior—hence a posterior flap forms the best covering.

In the upper third of the leg the bulk of the muscles are postero-external —hence a flap chiefly external furnishes the best covering.

In all amputations through the upper third of the leg, it is well to cut the fibula at a higher level than the tibia, as it is apt to be drawn out of position and be exposed to pressure.

The "place of election," especially referred to in older writings, was understood to be a hand's-breadth (or an average of 9 cm., or 3½ inches) below the knee-joint.

The termination of the stump, in amputations about the leg, does not directly meet pressure (except in the peg-leg)—the pressure being borne by the lateral aspects of the hollow modern limb—so that a terminal scar (except where a peg-leg is contemplated) is not objectionable.

It is especially necessary, in amputating in the lower extremity, to dissect out all nerves which may be pressed upon—especially in the flap forms of operation.

In sawing the bones of the leg, the prominent border (shin) of the tibia should be beveled, as described in the General Principles (page 252).

The stump should be dressed upon a splint—and be kept out from under the bedclothes.

AMPUTATIONS ABOUT THE LEG, IN GENERAL.

Best Methods.—Oblique Elliptical (Guyon's Supramalleolar Amputation)—for the supramalleolar region. Large Anterior and Small Posterior Flaps (Farabeuf)—for lower third, between supramalleolar region and lower limit of middle third. Large Posterior and Short Anterior Flaps (Hey's Operation)—for middle third. Large External Flap (Farabeuf)—for upper third. Bilateral Hooded Flap (Stephen Smith's Operation)—for "place of election," or upper part of upper third.

Other Methods.—Modified Circular—for supramalleolar region. Oblique Elliptical (Duval)—for lower third. Rectangular Flaps (Teale)—for lower third. Large Posterior and Small Anterior Flaps (Henry Lee)—for middle third. Circular Method. Equal Lateral Flaps. Large Posterior Flap. Large Anterior Flap. Long Anterior and Short Posterior Flaps. Oblique Circular, forming an anterior flap for upper and lower thirds. Oblique Circular, forming an antero-external flap for middle thirds. Oblique Circular—forming a dorsal flap—for supramalleolar region. Long anterior

Curved Flap. Long Anterior Rectangular Flap. Large Anterior Semilunar and Small Posterior Semilunar Flaps.

AMPUTATION OF LEG THROUGH SUPRAMALLEOLAR REGION

BY OBLIQUE ELLIPTICAL INCISION—GUYON'S SUPRAMALLEOLAR OPERATION.

Description.—An operation somewhat resembling Syme's—the tibia and fibula being divided below the medullary canal, and the ends of the bones covered by a heel-flap of skin and muscles.

Position.—In operating upon the leg, in general, the limb projects over the edge of the table—the patient being supine—the surgeon standing to the outer side of the right, and inner side of the left—the assistant steadying the part to come away. In the present operation, the surgeon grasps the foot in his left hand and manipulates it so as to readily expose the line of incision. On the right, the foot is turned inward and the incision begins at the outer side of the heel—crosses the outer aspect of the foot, which is then turned upon its outer side, and the incision carried to the heel along the inner aspect. On the left, the incision may begin in front, with the foot upon its inner side.

Landmarks.—Ankle-joint; malleoli; greatest prominence of the heel.

Incision.—Begins, say, on the anterior aspect of the ankle, opposite the center of the ankle-joint—curves obliquely downward and backward over the lateral aspects of the foot, just skirting the inner malleolus, and passing slightly in front of the external malleolus—ending over the summit of the curve of the heel. The incision may be made from the instep to the heel, or vice versa (Fig. 275, E, E′).

Operation.—The above incision is made through skin and fascia, and is then everywhere deepened to the bone—except that the ankle-joint is not opened, and the peronei tendons behind the external malleolus are not cut, until the soft parts have been cleared above the ankle-joint. The soft tissues are now carefully freed up about 5 cm. (2 inches) above the tips of the malleoli, providing a musculo-periosteal covering—using great care to preserve the vessels on the inner aspect—the surgeon standing for the anterior clearing, and sitting (or elevating the limb) for the posterior clearing. The tendo Achillis is divided. The peronei tendons are cut at about the level of the ankle. The ankle-joint is not opened. The anterior tibial, posterior tibial, termination of the peroneal, and anterior peroneal vessels are ligated. The nerves and tendons are cut especially short. It is probably better to dissect out the posterior tibial nerve. The heel-flap is then sutured to the upper transverse incision, and the stump dressed as in Syme's operation.

AMPUTATION THROUGH LOWER THIRD OF LEG

BY LARGE POSTERIOR AND SMALL ANTERIOR FLAPS—FARABEUF.

Description.—The operation is usually known as a large posterior flap method, the anterior flap supplying so small a part of the covering. Both flaps are of skin and muscle. The posterior flap, which forms the bulk of the covering, is derived really more from the postero-internal aspect, and the anterior or smaller flap, which is about one-fourth the length of the larger, from the antero-external aspect.

Position.—See Guyon's operation (page 365)—and under Incision, below.

Landmarks.—Saw-line.

Incisions.—Posterior flap—begins (on the right side) with the leg turned to present the inner side, at the saw-line, on the inner side of the leg—and passes vertically down in front of the inner border of the tibia for a distance

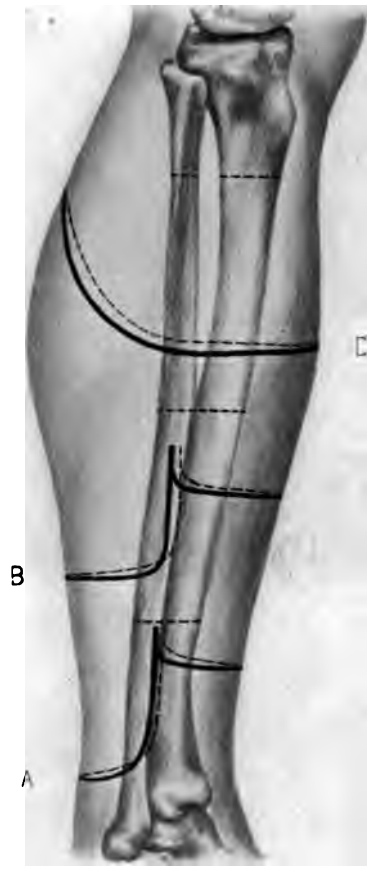

Fig. 277.—AMPUTATIONS ABOUT THE LEG:—A, Through lower third of leg, by large posterior and small anterior flap; B, Through middle third, by long posterior and short anterior (Hey's operation); C, Through upper third, by bilateral hooded flaps (Stephen Smith's operation).

equal to about 1¼ diameters of the limb at the saw-line—then rounds across the posterior aspect of the leg. The outer limb of the incision begins, with the leg turned to present the outer side, at the saw-line, on the outer side of the leg—and passes vertically down just behind the fibula, for a distance equal to about 1¼ diameters of the leg at the saw-line—then rounds across the posterior aspect of the leg to meet the inner incision. The anterior flap is made by a transverse incision, slightly convex downward, passing between the two vertical incisions, at a distance below their upper ends equal to about one-fourth of the length of the posterior flap (Fig. 277, A).

Operation.—These incisions having been made through skin and fascia, the tendo Achillis is divided on a line with the retracted skin and the leg is turned to present its inner side—and the upper part of the inner incision is deepened for a length of about 5 cm. (2 inches), by freeing the muscles from the tibia. The leg is now turned to present the outer side and the upper end of the outer incision is similarly deepened for a distance of about 5 cm. (2 inches), by freeing the muscles from the fibula. The leg is flexed during these incisions. Through these two opposite openings, the left thumb and index are thrust, meeting in the center, and thus the soft parts are picked up and drawn from the bones, the limb still being flexed. A long knife is passed through this opening and made to cut its way out on a line with the retracted skin, bluntly beveling the flap. The anterior incision is now deepened to the bones on a line with the retracted skin. The soft parts are then freed back to the saw-line—the interosseous membrane being divided transversely, and the periosteum having been circularly divided a distance below the saw-line sufficient to furnish a covering of one diameter of each bone at the saw-line. The soft parts are retracted and the bones are sawed—beveling the prominent anterior border of the tibia as described at page 252. Ligate the anterior tibial, posterior tibial, peroneal arteries, and internal and external saphenous veins. Suture the periosteo-muscular coverings over the ends of the bones. Quilting of the muscles is particularly indicated, as the heavy posterior muscles are apt to sag backward. Dissect out the posterior tibial nerve. Dress the stump on a posterior splint.

AMPUTATION THROUGH MIDDLE THIRD OF LEG

BY LONG POSTERIOR AND SHORT ANTERIOR FLAPS—BY HEY'S OPERATION.

Description.—The covering is by skin and muscle flaps, furnished almost entirely from the posterior aspect of the leg. The method is frequently termed simply a long posterior flap operation—and differs but little from the preceding operation.

Position.—As in Guyon's operation (page 365)—and as given under Incision, below.

Landmarks.—Saw-line.

Incisions.—The posterior flap is U-shaped—its breadth is equal to half the circumference of the limb at the saw-line, and its length is equivalent to one diameter of the limb at that line. It begins 2.5 cm. (1 inch) below the saw-line (instead of at that line). The inner limb passes vertically down the leg just behind the internal border of the tibia, rounding broadly into the posterior aspect of the limb—the outer limb passing vertically downward just behind the fibula, posterior to the peronei muscles, and rounding broadly into the posterior aspect of the leg to unite with the opposite limb of the incision. The anterior flap is about one-third the length of the posterior, and is made by joining the vertical limbs of the posterior flap, at their upper thirds, by a transverse incision, with slight downward convexity, across the front of the leg. In these incisions the knee is flexed and the leg is laid on its outer side while the inner incision is being made from above downward, and vice versa (Fig. 277, B).

Operation.—The above incisions pass through the skin and fascia only. With the leg flexed on the thigh and the knee everted, the gastrocnemius is held up by thumb and first finger and cut from without, on a line with the retracted skin and fascia. The upper parts of both vertical incisions are now

deepened—the inner to the tibia, the outer to the fibula, behind the peronei muscles. The left thumb and index are inserted into these slits and the muscles drawn outward. The muscles having been detached from the bones and interosseous membrane above, a long knife is passed between the bones and separated muscles and is made to cut its way outward along the line of the retracted skin. The interosseous membrane is divided transversely and the periosteum of the tibia and fibula circularly—and all the soft parts retracted upward for the 2.5 cm. (1 inch) between the saw-line and the beginning of the flaps. The flaps are now retracted—the bones divided, and the prominent crest of the tibia beveled. The anterior tibial, posterior tibial, and peroneal arteries are ligated. The musculo-periosteal coverings are sutured over the ends of the bones. The muscles are quilted with special care, owing to the tendency of the posterior flap to sag backward. The large posterior and short anterior flaps are then sutured together—and the stump supported upon a posterior splint.

AMPUTATION THROUGH UPPER THIRD OF LEG

BY LARGE EXTERNAL FLAP—FARABEUF.

Description.—The stump is covered by a large U-shaped flap of skin and muscles raised from the external aspect of the leg.

Position.—Patient supine; leg projecting over side of table, with knee flexed and leg lying on inner side for the incision of the external flap, and on the outer side for the transverse incision. Surgeon to outer side of right and inner side of left leg.

Landmarks.—Saw-line.

Incision.—External flap—U-shaped, equivalent in length to one diameter of limb at saw-line—begins opposite the saw-line anteriorly—passes vertically downward parallel with and just internal to the anterior border of the tibia —rounds across the external aspect of the leg and passes vertically upward directly opposite the anterior incision—but ends about 4 cm. (1½ inches) below the saw-line. Transverse incision—passes transversely across the inner aspect of the limb, with slight downward convexity, connecting the upper end of the posterior incision with a point on the anterior incision 4 cm. (1½ inches) below its beginning. The external flap may be cut, or outlined, with one sweep of the knife—but it is better to complete it in two strokes (Fig. 278, C).

Operation.—Beginning with the external flap, the above incision is deepened along the line of the retracted skin—and the large flap, of all the soft parts to the bones, raised. To accomplish this, the incision is first deepened along the anterior limb by cutting down upon the anterior border of the tibia, from above downward. The tibialis anticus is thus freed from the bone. The left fingers of the operator, slipped between muscle and bones, draw it outward, while the short knife continues its downward incisions, beveling obliquely the lower portion of the muscular mass toward the extremity of the flap. Thus the entire muscle-mass is separated from the tibia, interosseous membrane, and fibula, by the use of the knife, fingers, and elevator. Care is taken that the anterior tibial artery is not divided before the free end of the flap is reached, the integrity of which so largely depends upon this vessel. If the parts are freed up too high, especially posteriorly, where the vertical incision is shorter than the anterior, the anterior tibial artery may be severed before traversing the interosseous membrane.

The transverse incision crossing the inner aspect of the limb is now deepened by cutting from without inward on the line of retracted skin and fascia. The interosseous membrane is divided transversely. The periosteum is circularly divided around the tibia and fibula. The periosteum and soft parts are then freed up to the saw-line and retracted while the bones are divided—the prominent margin of the tibia being beveled from above down-

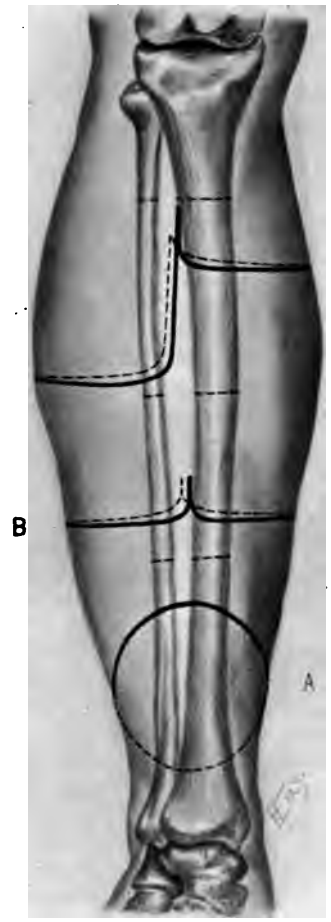

Fig. 278.—Amputations about the Leg:—A, Through lower third of leg, by oblique circular method; B, Through middle third, by modified circular method; C, Through upper third, by large external flap.

ward, and from before backward. The fibula is sawed a little higher than the tibia, and beveled from above downward, and from without inward. The anterior tibial, posterior tibial, peroneal, muscular branches to the gastrocnemius and soleus, and nutrient arteries are ligated. All nerve-trunks which are apt to be pressed upon are dissected out. The muscles are quilted.

The margins of the external flap are sutured to the inner transverse incision —and the limb dressed upon a posterior splint.

AMPUTATION THROUGH UPPER THIRD OF LEG

BY BILATERAL HOODED FLAPS—STEPHEN SMITH.

Description.—Two lateral flaps of skin and fascia are raised from the outer sides of the leg, by an incision extending much higher behind than in front—these are retracted about 2.5 cm. (1 inch)—the muscles circularly divided and retracted to the saw-line and the bones sawed—forming a bilateral hood over the ends of the bones, which is sutured vertically—the scar being eventually drawn up behind the bones.

Position.—Patient supine; leg over edge of table, held horizontal for skin incisions and vertical when freeing back the soft parts. The surgeon, to outer side of right and inner side of left limbs, places the right thumb upon the crest of the tibia, to mark the upper limit of the anterior incision, and the index posteriorly, to mark the upper limit of the posterior incision—leaning over patient and cutting from behind forward on both sides, the incisions meeting at the highest point of the anterior incision.

Landmarks.—Saw-line, marking the upper limit of the posterior incision —and the point on the crest of the tibia marking the upper limit of the anterior incision, and placed about three-fourths of a diameter of the limb at the saw-line below the upper limit of the posterior incision (Fig. 277, C).

Incisions.—The surgeon, having grasped the limb in such a manner as to mark the upper limit of the anterior incision by his left thumb upon the crest of the tibia, and of the posterior incision by his left index in the mid-posterior aspect of the leg at the saw-line—bends over the patient's leg (his arm being above and to the far side of the limb) and inserts the point of a stout knife, held at a right angle to the skin, into the posterior tissues opposite the tip of the index—cuts thence downward, through skin and fascia—vertically downward, at first—and then soon begins gradually to sweep to the side of the limb opposite to that on which he is standing—and continues to pass in this curvilinear manner until a little below the level marked by his left thumb—then curves transversely across the far side of the limb and slightly ascends to the point marked by the tip of the thumb. The knife is now removed and this incision is repeated upon the near side of the limb, the knife entering at the highest point posteriorly, sweeping with the same curve (except that the flap may be advantageously made a little larger on the inner side, to cover the larger tibia) to the highest point anteriorly.

Operation.—Having incised the skin and fascia, these flaps are raised from their lower ends for about 2.5 cm. (1 inch) and are retracted, when the muscles are circularly divided to the bone—and are retracted from the tibia and fibula up to a level far enough below the saw-line to furnish a periosteal covering. Here the interosseous membrane is divided transversely—and the periosteum circularly around the tibia. All the soft parts, including periosteum, are then retracted above the saw line and the bone divided, beveling the tibia and sawing the fibula shorter than the tibia. The short piece of the fibula may then be disarticulated and excised. The anterior and posterior tibial, peroneal, and muscular arteries are tied. The musculo-periosteal covering is sutured over the tibia—the muscles quilted—and the flaps sutured in a vertical line—the redundancy of soft parts being eventually drawn up behind the stump. The hood of skin and muscle falls over the ends of the bones and the stump is freely movable.

SURGICAL ANATOMY OF THE KNEE-JOINT.

Bones.—Condyles of femur; tuberosities of tibia; head of fibula; patella.

Articulations and Ligaments.—(a) External Ligaments—anterior, or ligamentum patellæ; fibrous expansion of extensor tendons (central and two lateral portions); posterior, or ligamentum posticum Winslowii; internal lateral; anterior external lateral; posterior external lateral; capsular. (b) Internal Ligaments—anterior, or external crucial; posterior, or internal crucial; internal semilunar fibro-cartilage; external semilunar fibro-cartilage; transverse; coronary ligaments; and synovial membrane (with the prolongations, ligamentum mucosum and ligamenta alaria).

Muscles.—See under Muscles of Leg (page 362) and those of Thigh (page 376).

Arteries.—Following branches from femoral—anastomotica magna; terminal branch of profunda; descending branch of external circumflex. Popliteal and following branches—superior and inferior muscular; cutaneous; superior external articular; superior internal articular; azygos articular; inferior external articular; inferior internal articular. Following branches from anterior tibial—anterior tibial recurrent.

Veins.—Superficial:—internal saphenous and tributaries; external saphenous and tributaries. Deep:—popliteal; two venæ comites to each artery below the knee; one vena comes to each artery above the knee.

Nerves.—(a) From nerves of lumbar plexus:—From external cutaneous:—anterior branch. From anterior crural:—middle cutaneous; anterior and posterior branches of internal cutaneous branch; internal saphenous; nervus cutaneus patellæ branch of internal saphenous; muscular branches; articular branches. (b) From Sacral Plexus:—Small sciatic branches. From great sciatic;—internal popliteal, and its articular, muscular, and communicans poplitei branches; external popliteal (peroneal) and its articular branches.

Synovial Membrane of Knee-joint.—Beginning at the upper border of the patella and following the capsule of the joint upward, it forms a large cul-de-sac beneath the quadriceps extensor tendon, on the anterior aspect of the thigh, for a distance of 5 to 6.5 cm. (2 to 2½ inches) above the articular surface of the femur, which generally communicates with a synovial bursa between the tendon and front of the femur above the level of the attachment of the capsular ligament. Having invested the circumference of the lower end of the femur, it is reflected upon the fibrous covering of the joint formed by the capsular, posterior, and lateral ligaments, extending on each side of the patella beneath the aponeurosis of the vastus internus and externus (especially the former). Below the patella the synovial membrane is separated from the anterior ligament by the capsular ligament and adipose tissue. From the capsule, the synovial membrane extends down to the semilunar cartilages, covering their upper surface, free border, and inner surface, and forming a cul-de-sac between the groove on the back part of the external semilunar cartilage and the popliteus muscle, extending down to the tibiofibular ligament, constituting a bursa for the play of the popliteus tendon. It is reflected from the under surface of the semilunar cartilages onto the coronary ligaments, thence to the head of the tibia and a short way around its circumference. The inner surface of the ligaments enclosing the joint is covered by synovial membrane, and the crucial ligaments are surrounded by it, except where in contact with other structures (and hence excluded from the synovial cavity). Posteriorly a pouch is prolonged between the

outer head of the gastrocnemius and the external condyle of the femur, and one between the internal head of the gastrocnemius and the internal condyle of the femur. For prolongations of the mucous membrane as ligamentum mucosum and ligamentaria alaria, see under Ligaments.

Bursæ About the Joint.—(a) In Front:—(1) Between patella and skin, (2) Between upper part of tuberosity of tibia and ligamentum patellæ. (3) Between lower part of tuberosity of tibia and skin. (b) On Outer Side:—(1) Beneath outer head of gastrocnemius (sometimes communicating with joint). (2) Above external lateral ligament, between it and tendon of biceps. (3) Beneath external lateral ligament, between it and tendon of popliteus (sometimes only an expansion from following bursa). (4) Beneath tendon of popliteus, between it and condyle of femur (generally an extension from synovial membrane). (c) On Inner Side:—(1) Beneath inner head of gastrocnemius, with prolongations between tendons of gastrocnemius and semimembranosus (often communicating with joint). (2) Above internal lateral ligament, between it and tendons of sartorius, gracilis, and semitendinosus. (3) Beneath internal lateral ligament, between it and tendon of semimembranosus (sometimes only an expansion from following). (4) Beneath the tendon of semimembranosus, between it and head of tibia. (5) Between tendons of semimembranosus and semitendinosus (sometimes).

Structures in Relation with Knee-joint.—(a) Anteriorly:—quadriceps extensor. (b) Posteriorly:—expansion from tendon of semimembranosus; popliteal vessels; internal popliteal nerve; popliteus; plantaris; inner and outer heads of gastrocnemius; lymphatic glands. (c) Externally:—quadriceps extensor; tendon of biceps; tendon of popliteus; external popliteal nerve. (d) Internally:—quadriceps extensor; sartorius; gracilis; semitendinosus; semimembranosus.

Movements of Joint.—Flexion—by biceps, semitendinosus, semimembranosus—assisted by gracilis; sartorius; gastrocnemius; popliteus; plantaris. Extension—by quadriceps extensor. Inward Rotation—by popliteus; semitendinosus—assisted by semimembranosus; sartorius; gracilis. Outward Rotation—by biceps.

SURFACE FORM AND LANDMARKS OF KNEE-JOINT.

Bony landmarks—patella; condyles of femur; tuberosities of tibia; tubercle of tibia; head of fibula.

To find the articular line of the knee-joint—cross the leg on the knee, when the inner tuberosity of the tibia will project beyond the inner condyle of the femur and make the articulation-line evident. The depression between the outer tuberosity of the tibia and outer condyle of the femur may also be made out.

The upper margin of the external tuberosity of the tibia, when the joint is semiflexed, not only represents the articular line—but also the lower limit of the synovial membrane of the knee-joint.

The knee-joint lies about 2 cm. ($\frac{3}{4}$ inch) above the prominence of the tubercle of the tibia—and about opposite the transverse crease of skin in the popliteal space.

When the limb is extended, the joint-line lies slightly above the apex of the patella. When the limb is slightly flexed, an instrument passed horizontally backward just below the apex of the patella will enter the joint.

In full extension the lower third of the patella rests upon the condyles

of the femur;—in full flexion, its upper third is in contact with the condyles; —in semiflexion, the middle third of the patella rests upon the greatest prominence of the femoral condyles. The apex of the patella, in extension, corresponds with the upper margin of the tibia.

The axis of the femur inclines inward from the pelvis. The axis of the tibia is vertical.

The inner aspect of the inner condyle faces, practically, in the same direction as the head of the femur.

Internally, the inner condyle of the femur is more marked, and the inner tuberosity of the tibia less. Externally, the outer tuberosity of the femur is less marked, and the outer tuberosity of the tibia more.

The adductor tubercle of the femur is to be felt at the upper part of the inner condyle—and marks the lower epiphysis.

The upper border of the tubercle of the tibia is on a level with the upper aspect of the head of the fibula.

The head of the fibula may be felt at the outer and back part, in the depression between the tendon of the biceps above, and the peroneus longus below.

The hollow of the popliteal space exists only upon flexion—disappearing upon extension.

The synovial membrane of the knee-joint separates the upper part of the ligamentum patellæ (quadriceps extensor tendon) from the knee-joint—a bursa separates it from the tubercle of the tibia—and another bursa lies between the patella and the skin.

The synovial membrane extends anteriorly for 5 to 6.5 cm. (2 to 2½ inches) above the joint—and, internally, for about 7.5 cm. (3 inches) above the joint (about 2.5 cm., or 1 inch, above the patella).

Popliteal structures detectable by palpation—(*a*) Outer side:—ilio-tibial band, tendon of biceps, external popliteal nerve (close to preceding). (*b*) Inner side:—tendon of semitendinosus (slender), tendon of semimembranosus (thicker), gracilis (appearing as one tendon with preceding, unless manipulated), sartorius (at extreme inner side, detectable by putting into action).

The lower epiphysis of the femur unites about the twentieth year, and the epiphyseal line is intracapsular. The upper epiphysis of the tibia unites about the twentieth year—and the epiphyseal line is extracapsular, and includes the tuberosities and tubercle of the tibia. The epiphysis of the upper end of the fibula unites about the twenty-fifth year.

GENERAL SURGICAL CONSIDERATIONS IN DISARTICULATION AT THE KNEE-JOINT.

Following disarticulation through the knee-joint, a stump usually results which is capable of bearing direct pressure (which, as a rule, stumps of the femur cannot do), and which takes an artificial limb better—the disarticulation being preferable to an amputation through the femoral condyles, or higher.

Instrument-makers generally object to a limb disarticulated at the knee, as the artificial knee then comes in the upper part of the leg. In spite of this, however, and because of the reasons above given, disarticulation should be done in preference to amputation through the thigh.

It is not necessary to remove the remains of the synovial membrane, or the articular cartilages—but the knee-joint should be free of disease.

The semilunar cartilages should not be removed—as they give a square, or flat, surface to rest upon, and help hold down the synovial capsule.

The patella should not be removed—as it affords rotundity and firmness, and the attachment of the quadriceps extensor tendon is thereby retained.

DISARTICULATION AT KNEE-JOINT, IN GENERAL.

Best Methods.—Bilateral Hooded Flaps—Stephen Smith's Method.

Other Methods.—Elliptical Method (Bauden's)—forming an anterior flap. Oblique Circular—forming an anterior flap. Long Anterior Flap. Long Posterior Flap. Bilateral Skin-flaps (Pick's operation). Equal Anterior and Posterior Flaps. Lateral Flaps. Long Anterior and Short Posterior Flaps.

DISARTICULATION AT KNEE-JOINT

BY BILATERAL HOODED FLAPS—STEPHEN SMITH.

Description.—The same, in principle, as the amputation through the upper part of the leg by the same method—except, as originally planned, the present operation furnishes a covering of skin and fascia only. For its modification, see Comment.

Position.—As in the preceding operation (page 370)—with the minor changes suggested by the higher elevation.

Landmarks.—Knee-joint articulation; tubercle of tibia.

Incision.—The highest point of the posterior incision is opposite the joint-line;—and the highest point of the anterior incision is 2.5 cm. (1 inch) below the tuberosity of the tibia. The surgeon's left thumb marks the anterior, and his index the posterior points, as in the last operation. The incision begins posteriorly (the surgeon wielding his knife as in the above operation) in the mid-popliteal space, opposite the interarticular line, as defined by the tip of his left index—passes thence vertically down the mid-posterior aspect for a short distance (about 5 cm., or 2 inches)—thence gradually diverges from the median line as it sweeps downward and outward over that side of the limb further from the surgeon (and over which he is leaning) until about 5 cm. (2 inches) below the tubercle of the tibia, cutting a flap with convexity downward—thence curves forward and slightly upward to a point in the median line 2.5 cm. (1 inch) below the tibial tubercle, thus ending the outline of the further flap. The knife again enters posteriorly at the same point, and makes a similar incision upon that side of the limb nearer the operator—calculating that the internal flap is slightly larger, to cover the larger internal femoral condyle—and meeting the first incision at the median line in front. The limb is rotated outward while the inner incision is being made—and vice versa. The knee is extended throughout (Fig. 279, B).

Operation.—The skin and fascia are now freed all around and dissected up from the muscles and tendons. The ligamentum patellæ is cut transversely against the tuberosity of the tibia as soon as reached. The skin and fascia flaps are retracted up to the joint-line. Incise, transversely, the structures along the upper margin of the tibia, on the anterior and lateral aspects —ilio-tibial band, tendons of sartorius, gracilis, semitendinosus, biceps, the lateral ligaments—and, lastly, cut the coronary ligaments, binding down the semilunar cartilages, attacking them upon the sides of the joint—entering

the joint between the head of the tibia and the semilunar cartilages, thus leaving these cartilages in the stump, and completing their separation by flexing the knee. Flex the knee and cut the crucial ligaments. Extend the knee and divide transversely, with one sweep of a long knife, all the soft parts opposite the posterior aspect of the joint—the gastrocnemius, popliteus, hamstring tendons, popliteal vessels and nerves, and posterior ligament. Ligate the popliteal artery and vein, sural, superior articular, and anastomotica magna branches. Suture the lateral flaps in a vertical line—the scar being eventually drawn into the intercondyloid notch. Drain temporarily through the upper end of the posterior incision.

Comment.—The original technic may be advantageously modified by dissecting up the lower ends of the flaps for about 2.5 cm. (1 inch)—then dividing all the soft parts circularly and retracting these to the joint-line,

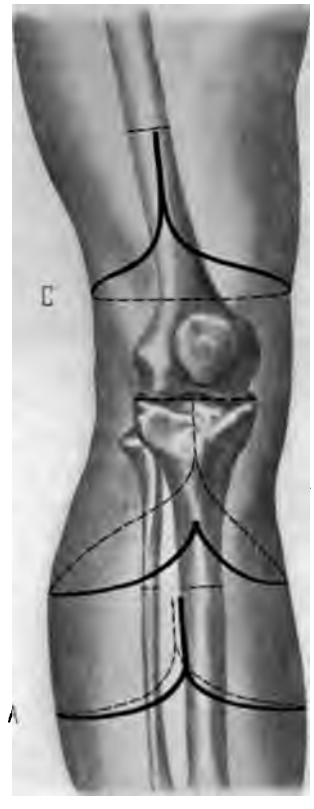

Fig. 279.—AMPUTATIONS ABOUT THE LEG AND THIGH:—A, Through upper third of leg, by equal lateral flaps; B, Disarticulation at knee, by bilateral hooded flaps (Stephen Smith's operation); C, Through lower part of thigh, by oval method.

including their fibrous attachments as far as possible—and then disarticulate. A much more substantial covering is thus gotten for the femoral condyles. Wherever it is possible to quilt muscle tissue into apposition, this should be done.

SURGICAL ANATOMY OF THIGH.

Bones.—Femur.

Muscles of Thigh and Hip-joint.—(a) Muscles of Iliac Region:—psoas magnus; psoas parvus; iliacus. (b) Of Anterior Femoral Region:—tensor vaginæ femoris; sartorius; rectus femoris; vastus externus; vastus internus and crureus; subcrureus. (c) Of Internal Femoral Region:—gracilis; pectineus; adductor longus; adductor brevis; adductor magnus. (d) Of Gluteal Region:—gluteus maximus; gluteus medius; gluteus minimus; pyriformis; obturator internus; gemellus superior; gemellus inferior; quadratus femoris; obturator externus. (e) Of Posterior Femoral Region:—biceps; semitendinosus; semimembranosus.

Arteries of Thigh.—Femoral and following branches:—superficial epigastric; superficial circumflex iliac; superficial external pudic; deep external pudic; profunda (with external circumflex, internal circumflex, and three perforating branches); muscular; anastomotica magna. And also arteries given under the supply to the hip-joint (page 387).

Veins of the Thigh.—Superficial—internal saphenous and tributaries (especially external and internal femoral cutaneous). Deep—one vena comes to each artery on anterior, internal, and external aspect; two venæ comites to each artery on posterior aspect and gluteal region.

Nerves of Thigh.—(a) From Dorsal Nerves:—lateral cutaneous branch of last dorsal. (b) From Posterior Divisions of Lumbar Nerves:—cutaneous nerves from external branches of three upper posterior divisions. (c) From Lumbar Plexus:—ilio-hypogastric; ilio-inguinal; genito-crural; external cutaneous; anterior crural; obturator; accessory obturator. (d) From Sacral Plexus:—muscular; superior gluteal; inferior gluteal; perforating cutaneous; pudic; small sciatic; great sciatic (with internal and external popliteal branches).

SURFACE FORM AND LANDMARKS OF THIGH.

The only portions of the femur which can be felt are the outer surface of the great trochanter; internal and external condyles, with the tuberosities upon each; and the adductor tubercle at the upper part of the inner condyle.

The rami of the pubes and ischia, from the pubic spines to the ischial tuberosities, mark the boundary between the thigh and perineum.

The head of the femur lies close below Poupart's ligament, just to the outer side of its center.

The femur is nearest the external aspect of the thigh in its upper third—about the center in the middle third—and nearest the anterior, or antero-external, aspect in the lower third.

The shaft of the femur is nearest the surface and is most easily reached in its lowest third, in the interval between the vastus externus and biceps.

The articular surface extends higher on the anterior aspect of the external than on the internal condyle of the femur.

A transverse section of the femur at the level of the adductor tubercle touches the upper limit of the articular cartilage and corresponds with the epiphyseal line.

The medullary canal is only present distinctly in the middle two-fourths of the shaft of the femur.

The thigh is separated from the abdomen by the inguinal furrow, the

bottom of which furrow is formed by Poupart's ligament, at the meeting of the aponeurosis of the external oblique and fascia lata.

The skin is coarse and thick on the external aspect of the thigh—fine and thin on the inner aspect—and loosely adherent throughout, though more adherent at the intermuscular septa.

Dense fascia underlies the skin throughout.

The outline of a transverse section of the thigh is irregular in the muscular —and more or less rounded in the stout, non-muscular, and in children.

Most of the muscles of the femoral region are attached to the femur—but the semitendinosus, semimembranosus, sartorius, and gracilis are entirely free, and the biceps nearly so—therefore very unequal retraction follows their section, especially on the posterior and internal aspects.

The rectus femoris forms a prominence below the anterior superior iliac spine, in the angle of divergence between the sartorius and the tensor vaginæ femoris—and largely forms the convex front of the thigh as it descends downward. A furrow on either side separates it from the vasti.

The vastus externus forms a flattened plane on the outer aspect of the thigh, traversed by a vertical groove formed by the ilio-tibial band.

The vastus internus forms an eminence on the inner side of the lower half of the thigh.

When the sartorius is relaxed, a depression exists between the extensor quadriceps and the adductor muscles, running downward and inward, from the apex of Scarpa's triangle to the inner side of the knee—which corresponds with this muscle.

The adductor muscles, together with the gracilis, form the fullness of the inner aspect of the upper part of the thigh and are not to be separately identified—except the upper tendon of the adductor longus (near the pubic spine), and the lower tendon of the adductor magnus (near the adductor tubercle, between the vastus internus and sartorius).

The muscles on the inner aspect of the thigh are not distinctly marked off from those on the posterior femoral aspect. But the muscles on the antero-external aspect are more distinctly marked off from the posterior femoral muscles by the external intermuscular septum.

The tensor vaginæ femoris extends downward and slightly backward from the upper part of the outer side of the thigh—and is continued down the thigh as the ilio-tibial band—which forms a furrow to the outer side of the knee.

The hamstring muscles descend from beneath the fold of the buttock, diverging as they pass downward to form the boundaries of the popliteal space—the biceps forming the outer hamstring—and the semitendinosus, semimembranosus, and gracilis (in order, from without inward) forming the inner hamstring.

For the landmarks of Scarpa's triangle and the femoral artery, see pages 93 and 95, respectively.

The head of the femur joins the shaft at the eighteenth year;—the great trochanter, the same;—the lesser trochanter, at the thirteenth or fourteenth year;—and the lower extremity joins the shaft at the twentieth year.

The growth, in length, of the lower extremity is chiefly from the lower epiphysis of the femur and the upper epiphysis of the tibia and fibula.

GENERAL SURGICAL CONSIDERATIONS IN AMPUTATIONS ABOUT THE THIGH.

The thigh is usually amputated at or below its middle.

In the young, the preservation of whose epiphysis is important, division of the bone should be below the lower epiphyseal line (transcondyloid) if possible—and the covering gotten by a circular method of amputation.

Any length of stump left is better than a hip-joint disarticulation—for the function of the thigh-stump is partly to bear weight, but chiefly to form a lever to move an artificial limb—and the longer the lever, the better.

In amputating through the thigh, the chief weight of the body, as supported by an artificial limb, is borne against the tuberosity of the ischium—and the chief pressure of the artificial apparatus is against the sides of the limb by the sides of the hollow cone of the apparatus. A terminal scar is not contraindicated where a hollow form of artificial limb is intended.

Subtrochanteric amputation is preferable to disarticulation at the hip. If it be found necessary in the course of such an operation, the amputation could be converted into a disarticulation.

In amputating through the condyles (transcondyloid), the section is made through the condyles on a level with the adductor tubercle of the femur.

In amputating just above the condyles (supracondyloid), the section is made from 1.3 to 2 cm. ($\frac{1}{2}$ to $\frac{3}{4}$ inch) above the condyles.

Thigh amputations through the condyles can generally bear the pressure of the body—while one through the shaft usually cannot.

The patella is removed in amputating through the condyles.

The general type of amputation through the thigh is by a longer anterior and shorter posterior flap—at any level, but especially throughout the upper two-thirds.

Greater contraction occurs upon the posterior and inner aspects of the thigh, where additional allowances should be made. The lower the amputation through the thigh, the greater will be the retraction.

In planning a method which will give a terminal scar, dissect out any nerves which might be pressed over the end of the bone.

In antero-posterior flaps cut above the center of the thigh, the femoral and profunda arteries will be cut in the anterior flap;—in similar flaps below the center of the thigh, the femoral artery will be cut in the posterior flap and is in danger of being split;—and in amputations through the middle of the thigh, the antero-posterior flaps should be shifted so as to become antero-external and postero-internal, in order to avoid the risk of splitting the main artery.

In longer anterior and shorter posterior flaps, as compared with equal anterior and posterior flaps, the longer anterior flap drops over the end of the bone, and the shorter posterior flap is not heavy enough to sag backward—as is apt to be the case in equal flaps (and especially in predominating posterior flaps).

Flaps are much more accurately fashioned if cut from without—and the anterior one always should be. If the posterior one must be cut by transfixion, first outline it through skin and fascia with a small knife, and then, transfixing, cut outward on a line with the retracted skin and fascia.

Where speed is requisite (as in the very old, or in emergency), the quickest methods of amputating through the thigh, are, by the circular method through

the lower third; and antero-posterior flap cut by transfixion through the upper two-thirds.

Owing to the extent and inequality of retraction of muscles in amputating through all parts of the thigh, a conical stump is not uncommon.

Hemorrhage is controlled, in operating through the middle and lower thirds, by a rubber tourniquet ordinarily applied, just below the hip-joint. In amputating higher, the tourniquet should be applied as high as possible in the form of a spica, passing around the groin and pelvis. In both cases, especially the latter, the tubing should be held in place by a loop of bandage previously laid under the tubing or tourniquet, anteriorly and posteriorly.

The femur is to be carefully sawed at a right angle to its length—sawing carefully near the lineæ asperæ, to avoid splintering.

The stump should be dressed with a posterior splint included and placed upon an inclined plane, to relax the quadriceps extensor pull.

AMPUTATIONS THROUGH THE THIGH, IN GENERAL.

Best Methods.—Shorter Anterior and Longer Posterior Flaps (Lister's Modification of Carden's operation)—for transcondyloid region. Longer Anterior and Shorter Posterior Flaps (Gritti-Stokes's Method)—for supracondyloid osteoplastic operation. Long Anterior and Short Posterior Flaps—for thigh throughout. Equal Anterior and Posterior Flaps—for thigh throughout, where the tissue is limited. Oblique Circular, or Elliptical, Method—for lower third. External Oval Method—for subtrochanteric region.

Other Methods.—Long Anterior Flap—Carden's transcondyloid operation. Long Anterior and Short Posterior Flaps—Farabeuf's Modification of Carden's transcondyloid operation. Osteoplastic Transcondyloid Method of Sabanajeff. Long Anterior Rectangular Flap—Gritti's osteoplastic supracondyloid operation. Circular. Modified Circular. Long Anterior Flap. Oval Method—throughout. Bilateral Hooded Flaps of Stephen Smith—for lower half. Rectangular Flaps of Teale—for lower half.

AMPUTATION THROUGH CONDYLES OF FEMUR—TRANSCONDYLOID AMPUTATION

BY SHORTER ANTERIOR AND LONGER POSTERIOR FLAPS—LISTER'S MODIFICATION OF CARDEN'S TRANSCONDYLOID OPERATION.

Description.—Carden's operation consists in a division of the femur on a level with the adductor tubercle, together with the removal of the patella—the covering being gotten from a single anterior flap. Lister's modification consists in adding a posterior flap to the anterior flap, and then freeing the soft parts considerably above the base of the flaps.

Position.—Patient on back; drawn down on table so that buttocks are near, or are on, the edge of the table. Surgeon on outer side of right and inner side of left limbs. One assistant steadies and supports the part below the site of operation—and another holds the limb, or retracts the parts, above the site of amputation.

Landmarks.—Adductor magnus tubercle; knee-joint; tubercle of tibia.

Incisions.—Anterior incision—crosses the front of the knee with slight downward convexity—beginning on the horizontal line of the knee-joint and

in a vertical line with the prominences of the tuberosities of the femoral condyles, and crossing the ligamentum patellæ just above its center. The left thumb and index mark the two ends of this incision, and the knee is slightly flexed and rotated from side to side during its making. Posterior incision—joins the posterior extremities of the anterior incision at an angle of 45 degrees to the axis of the leg (Fig. 280, A, A′).

Operation.—These incisions pass through skin and fascia, and the flaps outlined by them are then dissected upward as in a circular amputation. The dissection is carried on close to muscles, tendons, and patella. The hamstring muscles are cut as soon as encountered, dividing them transversely. The quadriceps extensor tendon is similarly cut transversely as soon as the upper border of the patella is reached. The soft parts, including as much of a capsulo-periosteal covering as possible, are then retracted to the level of the adductor tubercle. The condyles of the femur are then sawed through at that level, transversely to the axis of the limb (not of the bone). Ligate the popliteal, or its anterior and posterior tibial divisions, and muscular, articular, and anastomotica magna branches. Suture the capsulo-periosteal covering over the end of the bone. Suture the anterior and posterior flap margins together. Dress the stump upon a posterior splint and place upon an inclined plane.

Comment.—(1) The scar is drawn posteriorly, out of the way of pressure. (2) The patella may be raised in the anterior flap and subsequently dissected out, especially if the parts be thick and unyielding.

AMPUTATION JUST ABOVE CONDYLES OF FEMUR, WITH SPLITTING OF PATELLA,

BY LONGER ANTERIOR AND SHORTER POSTERIOR FLAPS—GRITTI-STOKES'S SUPRA-CONDYLOID OSTEOPLASTIC AMPUTATION.

Description.—Gritti's operation consists in the division of the femoral condyles at the level of the adductor magnus tubercles; the removal of the articular surface from the patella; the application of the sawed patella into contact with the sawed femur; and the covering of the stump with a long rectangular anterior flap. Stokes's modification consists in dividing the femur 2 to 2.5 cm. (¾ to 1 inch) above the adductor tubercle (where the transverse section of the femur more nearly corresponds with the size of the split patella)—the stump being then covered by an anterior longer and posterior shorter flap. The object being, in the latter case, to approximate bone-sections of nearer similar size, and to bring them into contact with less tension.

Position—Landmarks.—As in the above operation.

Incisions.—Anterior longer flap—begins 2.5 cm. (1 inch) directly above the prominence of one condyle and ends the same distance directly above the prominence of the opposite condyle—crossing the front of the knee, with broad curve, just below the tubercle of the tibia. Posterior shorter flap—passes, in a broad curve, between the points of beginning and ending of the anterior flap—being one-third the length of the anterior flap (Fig. 280, B, B′, B″).

Operation.—These flaps, having been outlined through skin and fascia, are now dissected upward. The skin and fascia of the anterior flap is raised from its lower edge until the ligamentum patellæ is reached—which is cut transversely—and the flap further freed and turned up with the patella in it.

The posterior flap of skin and fascia is then freed upward from the muscle structures. These flaps are now retracted to the saw-line (2 to 2.5 cm., or ¾ to 1 inch, above the adductor magnus tubercle) and all the soft parts, including periosteum, are circularly divided to the bone, after which the bone is sawed. The main vessels may be now tied before the section of the patella, which is the most difficult part of the operation, is done. These vessels are

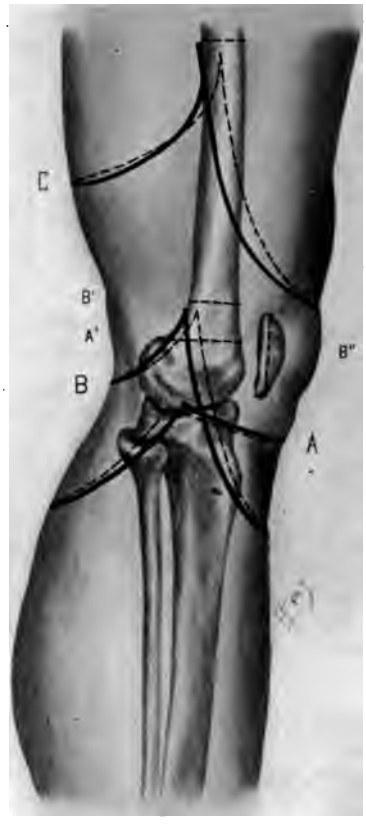

Fig. 280.—AMPUTATIONS ABOUT KNEE AND THIGH :—A, Lister's modification of Carden's transcondyloid amputation of thigh ; A', Division of femur in Lister's operation, on level with adductor tubercle ; B, Gritti-Stokes's supracondyloid amputation of thigh ; with dotted lines, B' and B'', showing division of femur above level of adductor tubercle, and splitting of patella ; C, Through lower part of thigh, by long anterior and short posterior flaps.

the popliteal, muscular, articular, anastomotica magna. The patella is grasped firmly by lion-jaw forceps, and held in such a way as to present its articular surface horizontally. A section of the bone is made in such a manner as to remove the articular surface of the patella. This is best accomplished with a narrow, thin saw. It may also be done with a broad chisel, and, less satisfactorily, with cutting pliers. The cut surface of the patella is then approximated to the sawed end of the femur. It may be held in place by inserting two or three ivory or steel pegs through previously drilled holes in the patella—or by wire or chromic gut suturing through drill-holes

near the margins of patella and femur—or by closely suturing fibrous parts about the patella to the fibrous or periosteal parts about the lower end of the femur. The anterior and posterior flaps are then sutured together. Firm pressure is used against the stump, in the dressing, to aid in steadying the patella against the femur.

Comment.—The scar is drawn up posteriorly out of the way of pressure. This operation is comparable with Pirogoff's osteoplastic amputation of the leg.

AMPUTATION THROUGH LOWER THIRD OF THIGH

BY OBLIQUE CIRCULAR METHOD.

Description.—Owing to greater retraction upon the posterior and inner aspects of the thigh, and in order, therefore, that the incision may eventually occupy the same height around the entire circumference of the limb, the circular incision is placed obliquely—so that it is lowest where the muscular retraction is greatest, namely, at the postero-internal aspect of the thigh.

Position.—As in the transcondyloid operation.

Landmarks.—Saw-line.

Incision.—The highest part of the circular incision is antero-external and is a little more than half the diameter of the limb (at the saw-line) below the bone-section. The lowest part of the circular incision is postero-internal and is little less than one diameter of the limb (at the saw-line) below the bone-section—the two calculations of covering thus providing 1½ diameters of covering in the aggregate. Such an incision is hard to follow unless previously marked (Fig. 281, A).

Operation.—The above incision through skin and fascia is made with two strokes of a long knife—the limb being conveniently rotated during the manœuvre, as described under the "Circular Method of Amputation," page 234. The skin and fascia are then obliquely retracted a short way, parallel with the original incision—and the more superficial muscles circularly divided. These are further retracted and the deeper muscles circularly divided to and including the periosteum, to the bone—cutting each time parallel with the skin incision. The skin, muscles, and periosteum are freed up to just above the saw-line, and retracted—as in the ordinary infundibular form of circular amputation—and the bone sawed. The femoral, anastomotica magna, descending branches of the external circumflex, perforating and muscular branches will be cut and require ligature. The muscles are quilted in two tiers. The skin is sutured so as to make an antero-posterior scar.

Comment.—(1) This may be called an elliptical method, as well as an oblique circular. It is not appropriate except at the lower third of the thigh —where it is excellent. (2) Where great difficulty is experienced in freeing back the soft parts, the circular operation may be modified by adding one or two short lateral vertical incisions, thus forming two antero-posterior integumentary flaps—and dividing the muscles circularly after retracting the skin. This, however, constitutes the modified form of circular amputation.

AMPUTATION THROUGH LOWER, MIDDLE, OR UPPER THIRD OF THIGH

BY LONG ANTERIOR AND SHORT POSTERIOR FLAPS.

Description.—Two U-shaped flaps of skin and muscle are raised, ante-

riorly and posteriorly—the latter being one-fourth the length of the anterior and a little narrower at the base.

Position—Landmarks.—As in the above operation.

Incisions.—Anterior flap—is equal, in length, to 1½ diameters of the

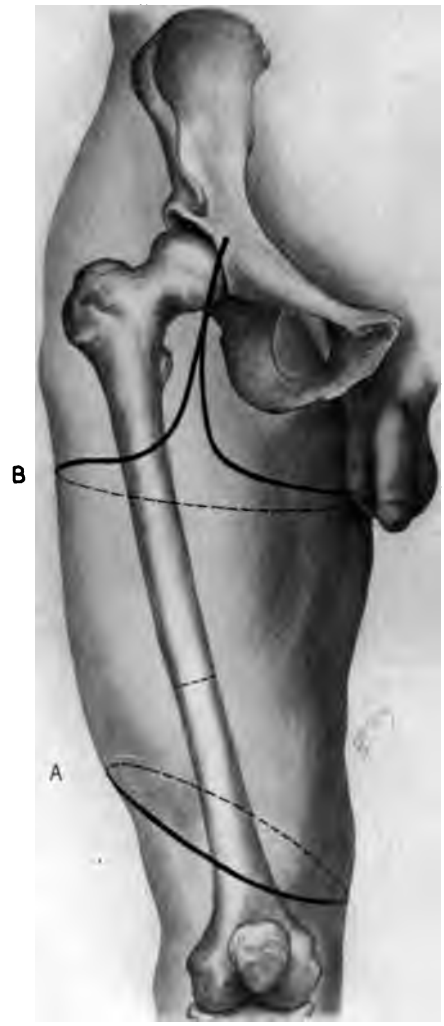

Fig. 281.—AMPUTATIONS ABOUT THIGH AND HIP-JOINT:—A, Through lower part of thigh, by oblique circular method; B, Disarticulation at hip-joint, by anterior racket.

thigh at the saw-line, and, in width, a little more than ½ circumference. It begins (on right side) (with thigh rotated outward) opposite the saw-line, at about the middle of its inner aspect, or a fraction behind—passes vertically down the inner side of thigh—rounds broadly across the anterior surface,

at a distance below the saw-line equal to 1½ diameters, and into the outer aspect—and passes vertically upward (the thigh now rotated inward) to a corresponding point on the opposite side. Posterior flap—begins and ends at the upper limits of the anterior flap—rounding across the posterior surface at a distance below the saw-line equal to a half-diameter—the surgeon's hand passing beneath the thigh. In the above calculations, extra length is allowed, because of the extra retraction (Fig. 280, C).

Operation.—The tissues outlined in the anterior flap are now picked up by the surgeon's left hand, and, along the line of the retracted flap, the muscles are divided obliquely from without inward and upward—so beveling the flap that its extremity will consist of skin and fascia alone. The muscle tissue will begin to enter into the formation of the flap just above the extremity, and increases in thickness to the bone—into contact with which it will come at about one-half to three-fourths the diameter of the femur below the saw-line, at which level the whole thickness of the muscle will be represented. The thigh is then elevated and the posterior flap similarly cut, being obliquely beveled from without inward and from below upward, leaving skin and fascia at the lower end of the flap and full thickness of the muscles at the upper end, where the bone is reached the same distance below the saw-line as in the anterior flap. At the level at which the bone has been reached in the upward cutting of the flaps, a circular sweep of the knife around the femur frees the periosteum. The soft parts, including the periosteum, are then freed upward to just above the saw-line (which is everywhere easily accomplished except at the linea aspera posteriorly) and the bone sawed. If the flaps have been made above the middle of the thigh, the femoral, profunda, descending branches of the external circumflex, and muscular branches will be cut in the anterior flap—and branches of the perforating arteries in the posterior flap. If the flaps have been made below the middle of the thigh, the descending branches of the external circumflex and muscular branches will be cut in the anterior flap—and the femoral, anastomotica magna, and branches of the perforating in the posterior flap. Suture the musculo-periosteal covering over the end of the bone. Quilt the heavy muscles of the flaps in at least two tiers, with buried chromic gut sutures. The anterior flap will drop over the end of the bone and be sutured to the posterior flap. The flaps are well supported by the pressure of the dressing, in which a posterior splint has been included—and the limb placed upon an inclined plane.

Comment.—The flaps may be cut by transfixion, after outlining through skin and fascia—but less satisfactorily.

AMPUTATION THROUGH LOWER, MIDDLE, OR UPPER THIRD OF THIGH

BY EQUAL ANTERIOR AND POSTERIOR FLAPS.

Description.—Same in all essential respects, except as to difference in length of flaps, as amputation by long anterior and short posterior flaps.

Position—Landmarks.—As in the last operation.

Incisions.—Anterior flap—is, in length, three-fourths the diameter of the limb at the saw-line. Posterior flap—is, in length, one diameter of the limb—its greater retraction eventually reducing its length to that of the

anterior flap. The width of both is equivalent to half the circumference of the limb at the saw-line (Fig. 282, A).

Operation.—As in the preceding. The vessels severed are also the same.

Comment.—(1) The method by equal flaps is indicated only where the

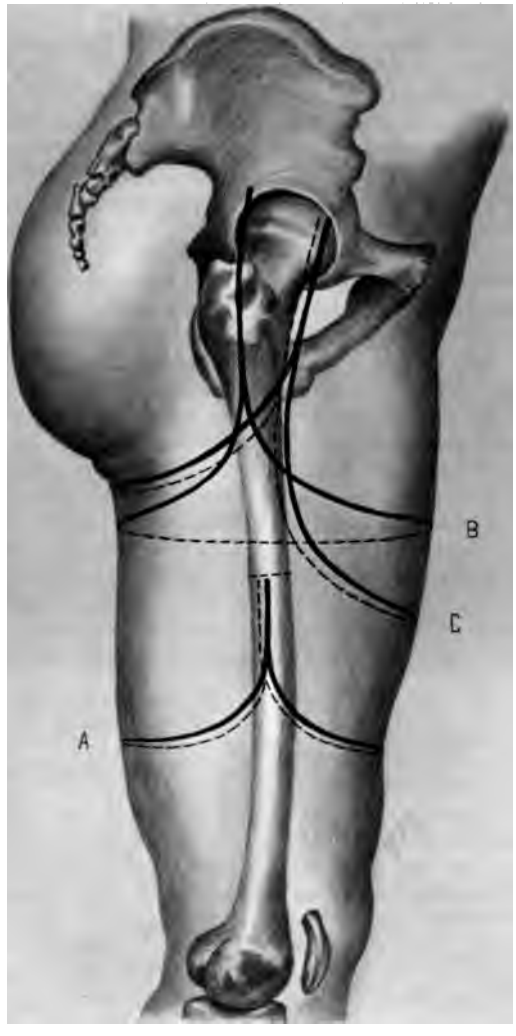

Fig. 282.—AMPUTATIONS ABOUT THIGH AND AT HIP-JOINT:—A, Through middle of thigh, by equal anterior and posterior flaps; B, Disarticulation at hip-joint, by external racket method; C, At hip-joint, by long anterior and short posterior flaps.

anterior tissues are limited. (2) Less sacrifice of length of limb is involved. (3) These flaps are frequently cut by transfixion, without even outlining through the integumentary tissues in advance—but such technic is not advisable.

AMPUTATION OF THIGH JUST BELOW THE TROCHANTERS

BY EXTERNAL OVAL METHOD.

Description.—Similar in principle to disarticulation of the hip-joint by the external racket method (page 392)—except that the vertical incision begins lower, and the bone is divided below the lesser trochanter.

Position.—As in disarticulation of the hip-joint by the external racket method (page 392).

Landmarks.—Great trochanter; lesser trochanter.

Incision.—With the limb adducted, rotated in and slightly flexed, the vertical portion of the incision begins over the prominence of the great trochanter, in the mid-outer aspect of the limb—passes vertically down the outer side of the thigh for about 10 cm. (4 inches)—thence the limbs of the oval diverge to pass over the anterior and posterior aspects of the thigh and meet in the center of its inner side, at a point about 5 cm. (2 inches) lower than the lower end of the vertical incision. Thus an inverted Y is formed upon the outer side of the thigh.

Operation.—The skin and fascia are dissected up along the oval portion of the incision for about 5 cm. (2 inches). The vertical incision is then deepened to the bone. Through the vertical incision the shaft is freed as extensively as possible. The muscles are now circularly divided on a line with the retracted skin and fascia. The soft parts are entirely freed from the bone up to the saw-line—providing a musculo-periosteal covering when near that line. The soft tissues are retracted and the femur sawed. Ligate the femoral artery and vein, profunda artery and vein, internal circumflex, descending (and possibly transverse) branch of external circumflex, comes nervi ischiadici, and many muscular branches. Suture the musculo-periosteal flap. Quilt the muscles with two tiers of gut sutures, along both vertical and oval portions of incision. Suture skin in a horizontal line, forming externo-terminal scar. Include splint in dressing and place on an inclined plane.

SURGICAL ANATOMY OF HIP-JOINT.

Bones.—Os innominatum; femur.

Articulations and Ligaments.—Capsular (with following auxiliary bands—pectineo-capsular, ilio-trochanteric, and ischio-capsular); ilio-femoral (also an auxiliary portion of capsular ligament); ligamentum teres; cotyloid; transverse; and synovial membrane.

Synovial Membrane of Hip-joint.—Beginning at border of cartilaginous surface of head of femur—covers neck of femur within joint—is reflected to inner surface of capsular ligament—covers both surfaces of cotyloid ligament and fat at bottom of acetabulum—and is prolonged around ligamentum teres to head of femur.

Muscles of Region of Hip-joint.—Mentioned in connection with the Thigh (page 376).

Muscles in Relation with Hip-joint.—Anteriorly:—psoas and iliacus. Posteriorly:—pyriformis; gemellus superior; obturator internus; gemellus inferior; obturator externus; quadratus femoris. Superiorly:—straight and reflected tendons of rectus; and gluteus minimus. Internally:—obturator externus and pectineus.

Bursæ in Relation with Hip-joint. Between great trochanter and

gluteus maximus. Between vastus externus and gluteus maximus. Between front of joint, and psoas and iliacus (often communicating with joint).

Movements of Hip-joint.—Flexion:—by psoas, iliacus, rectus, sartorius, pectineus, adductor longus, adductor brevis, anterior fibers of gluteus medius, and minimus. Extension:—by gluteus maximus, biceps, semitendinosus, semimembranosus, gracilis. Adduction:—by adductor magnus, longus and brevis, pectineus, gracilis. Abduction:—by gluteus maximus, medius and minimus. Inward Rotation:—anterior fibers of gluteus medius, gluteus minimus, and tensor vaginæ femoris. Outward Rotation:—posterior fibers of gluteus medius, pyriformis, obturator externus, obturator internus, gemellus superior and inferior, quadratus femoris, psoas, iliacus, gluteus maximus, adductor magnus, longus and brevis, pectineus, sartorius.

Arteries of Region of Hip-joint.—(**a**) From Internal Iliac—obturator; internal pudic; sciatic; ilio-lumbar; lateral sacral; gluteal. (**b**) From External Iliac—deep circumflex iliac. (**c**) From Femoral—see Arteries of Thigh, page 376.

Veins of Region of Hip-joint.—Superficial:—tributaries of internal saphenous. Deep:—accompany corresponding arteries. See Veins of Thigh, page 376.

Nerves of Region of Hip-joint.—(**a**) From Dorsal Nerves:—lateral cutaneous branch of last dorsal. (**b**) From Posterior Divisions of Lumbar Nerves:—cutaneous nerves from external branches of three upper posterior divisions. (**c**) From Lumbar Plexus:—ilio-hypogastric, ilio-inguinal, genito-crural, external cutaneous, anterior crural, obturator, accessory obturator. (**d**) From Posterior Divisions of the Five Sacral and First Coccygeal Nerves:—external branches. (**e**) From the Sacral Plexus:—muscular, superior gluteal, inferior gluteal, perforating cutaneous, pudic, small sciatic, great sciatic.

SURFACE FORM AND LANDMARKS OF HIP-JOINT AND VICINITY.

Spine of the os pubis is palpable, and is nearly on a level with the upper border of the great trochanter—and the upper border of the great trochanter is on a level with the center of the hip-joint.

Top of the great trochanter is about 2 cm. ($\frac{3}{4}$ inch) below the level of the head of the femur.

Great trochanter is from 7.5 to 10 cm. (3 to 4 inches) below the iliac crest, and a little in front of its center.

Head of the femur lies just below Poupart's ligament—and just external to its center.

Nélaton's line runs from the anterior superior iliac spine to the most prominent part of the tuberosity of the ischium. It runs through the center of the acetabulum and indicates the level of the hip-joint.

Bryant's line—(with patient flat on back)—first line is dropped vertically to the table, from the anterior superior iliac spine;—second line passes, in a straight direction, in a line with the long axis of the thigh, from the top of the great trochanter to meet first line;—third line runs from the anterior superior iliac spine to the top of the great trochanter. On the damaged or diseased side, the second line will be shortened.

Anterior superior iliac spine and the crest of the ilium are palpable.

Posterior superior iliac spine is marked by a depression on each side of, and on a level with, the spinous process of the second sacral vertebra—and is just behind the center of the sacro-iliac articulation.

The anterior inferior iliac spine is about 2 cm. ($\frac{3}{4}$ inch) above the upper border of the acetabulum.

Line from the posterior superior iliac spine to the outer part of the tuberosity of the ischium will cross the posterior inferior iliac spine nearly 5 cm. (2 inches) below the posterior superior iliac spine—and the ischial spine about 10 cm. (4 inches) below the posterior superior iliac spine.

Tuberosities of the ischia are palpable on either side of the anus, beneath the lower border of the glutei maximi, especially when the hip is flexed. They are covered, in standing, by the lower margin of the glutei maximi—and, when sitting, by the dense skin and fascia alone.

Third sacral spine is on a level with the lowest limit of the spinal membranes and the cerebrospinal fluid, and is opposite the upper border of the great sacro-sciatic notch.

First piece of the sacrum is on a level with the spine of the ischium.

Apex of the coccyx is just behind the last piece of the rectum.

Gluteus maximus forms the rounded outline of the buttock—its lower border being more oblique and higher than the fold of the buttock. A line from the side of the coccyx to the lower border of the great trochanter corresponds with the lower border of the gluteus maximus.

Fold of the buttock is caused by the creasing of the skin in flexion and extension, and does not correspond with the lower margin of the gluteus maximus but is lower and less oblique.

The antero-internal margin of the acetabulum is about 5 cm. (2 inches) external to the pubic spine.

Edge of the great sacro-sciatic ligament can be felt by pressing deeply under the lower edge of the gluteus maximus.

Femoral artery is separated from the capsule of the hip-joint by the psoas magnus, upon which it rests.

For the landmarks of the gluteal, sciatic, and pudic arteries, see under the Ligations of those arteries (pages 89, 86, and 88).

Ossification in the head of the femur begins at the end of the first year, uniting with the shaft at the eighteenth year;—that in the great trochanter begins in the fourth year, and that in the lesser trochanter at the thirteenth to fourteenth year, uniting, in both cases, about the eighteenth year. The epiphyseal line of the head of the femur is entirely within the capsular ligament.

GENERAL SURGICAL CONSIDERATIONS IN DISARTICULATION AT THE HIP-JOINT.

The question of control of hemorrhage is the most serious problem in hip-joint disarticulations.

The methods of hemorrhage-control are the following;—Wyeth's mattress-needles and tourniquet; elastic tourniquet; preliminary ligation of femoral; Senn's method; ligation of femoral during amputation; digital compression of the femoral, or of the external iliac, above the amputation-site; digital compression of the femoral in the flap, as cut; stout needle beneath the femoral vessels, with rubber tubing wound in figure-of-eight fashion over it (Trendelenburg's method). The first three of the above methods are the best. Such methods as pressure of the abdominal aorta, either extra- or intra-abdominally, or through the rectum, are now not usually resorted to.

Only some form of circularly surrounding tourniquet controls hemorrhage

from branches of the internal iliac, as well as from the femoral. When hemorrhage is once controlled, any form of disarticulation may be adopted.

Manner of applying Wyeth's mattress-needles and tourniquet:—Two steel needles from 3 to 5 mm. ($\frac{2}{16}$ to $\frac{3}{16}$ inch) in diameter and 25.5 cm. (10 inches) in length are inserted and capped with corks (to prevent their points from injuring operator and assistants). The outer needle enters the tissues of the outer aspect of the thigh 6 mm. ($\frac{1}{4}$ inch) below and just to the inner side of the anterior superior iliac spine—traverses the superficial muscles and fascia upon the outer side of the hip, and emerges on a level with, and about 7.5 cm. (3 inches) external to, the entrance. The inner needle enters the tissues of the inner aspect of the thigh internal to the saphenous opening, and about 1.3 cm. ($\frac{1}{2}$ inch) below the crotch—traverses the adductors—and emerges 2.5 cm. (1 inch) below the tuberosity of the ischium. White rubber tubing, about 7 mm. ($\frac{1}{3}$ inch) in diameter, is wound tightly four or five times around the thigh above the fixation-needles, and clamped. This rubber band compresses the common femoral against the rim of the pelvis, anteriorly —and the gluteal, sciatic, and internal pudic against the margin of the great sacro-sciatic notch, posteriorly (Fig. 209, left hip).

Manner of applying the ordinary rubber tourniquet (Jordan Lloyd's method)—First elevate the limb to a vertical position, and hold thus for a few minutes, further aiding the emptying of blood from the limb by downward massage. A strip of sterilized roller bandage is laid down the outer, and one down the inner aspect of the thigh. A sterilized pad is placed over the external iliac artery. Rubber tubing, about 1.8 m. (6 feet) long, is passed around the thigh in several tight turns, over the pad and pieces of roller bandage. The center of these turns is placed between the tuberosity of the ischium and the anus (of the operated side)—the tubing being brought up so as to pass over the center of the iliac crest. The two ends of the tubing are finally grasped firmly in either hand and tightly drawn upward and forward and made to cross each other above the center of the iliac crest. At the point of crossing, an assistant, with the back of the hand (the right hand for the left side, and vice versa) to the patient's body, grasps and holds the crossed rubber band. Or the two ends may be carried around the trunk, brought back again, and make a second similar traversing as the first spica —the two ends being then tied, or clamped, above the center of the iliac crest (of the same or opposite side). The two roller bandages forming the two loops are now drawn upward to hold the tourniquet in place and lift it further from the field of operation—one coming up from in front of the anterior superior iliac spine, and the other from opposite the ischial tuberosity. The anterior part of the tourniquet, running above and parallel with Poupart's ligament, compresses the external iliac under the pad—the posterior part, running across the great sacro-sciatic notch, compresses the gluteal, sciatic, and internal pudic (Fig. 209, right hip).

Manner of preliminary ligation of femoral:—see under Ligations, page 97, and Figs. 209 (left thigh) and 38.

Manner of applying Senn's method of hemorrhage-control in disarticulation at the hip-joint—A straight incision of about 20 cm. (8 inches) is made over the central aspect of the great trochanter, in the long axis of the limb, and commencing about 7.5 cm. (3 inches) above the superior border of the great trochanter. As soon as the femur has been exposed and the head of the bone disarticulated, a pair of hemostatic forceps is introduced closed behind the femur, and on a level which would correspond with that of the trochanter minor when in normal position (that is, prior to disarticulation)—

and is pushed inward and downward below the ramus of the ischium and just posterior to the adductor muscles—until felt through the skin on the inner aspect of the thigh, when an incision is made over its tip and the instrument pressed on through. By opening the blades, the tunnel through the soft parts is enlarged—and the forceps are then made to seize a piece of rubber tubing at its center and draw the doubled portion backward through the wound at the outer aspect of the thigh, leaving the free ends protruding through the inner opening. The portion of the tube grasped by forceps is then cut in two. The limb is now held elevated a few moments, during which the return of blood to the trunk is further aided by downward massage. The anterior half of the tube is then carried firmly around the anterior portion of the soft parts and tied or clamped—and the posterior around the posterior portion, and similarly tied or clamped—thus controlling all circulation proximal to the tubing—the tubing being prevented from slipping by the tunneling of the soft parts. The operation is then completed.

Where the disarticulation has been done by a method allowing of free exposure of the femur in advance of disarticulation, the shaft can be largely freed subperiosteally—with the result that a sufficient growth of bone usually occurs to enable the stump to be freely moved in all directions.

Temporary drainage is indicated—and should be provided through an opening made posteriorly, if no dependent opening exist as a result of the operation.

Sutures are left in an extra length of time—and the flaps are subsequently temporarily supported by strapping.

The stump should be rather firmly bandaged and supported upon a pillow.

DISARTICULATION AT HIP-JOINT, IN GENERAL.

Best Methods.—Wyeth's Method. External Racket Method. Anterior Racket Method.

Other Methods.—Furneaux Jordan's Method (external vertical incision, with circular division of muscles). Long Anterior and Short Posterior Flaps. Equal Anterior and Posterior Flaps. Equal Lateral Flaps. Antero-internal and Postero-external Flaps. Modified Circular Method. Single Internal Flap. Esmarch's Method (circular division of muscles and bone, with dissection out of the bone through an external vertical incision).

DISARTICULATION AT HIP-JOINT

BY WYETH'S METHOD.

Description.—Having controlled hemorrhage by means of rubber-tubing wound around the thigh at its junction with the pelvis, above two large pins introduced in a special manner, a circular incision is made around the thigh, followed by a vertical external incision, and disarticulation at the hip-joint accomplished.

Position.—Patient supine, drawn to foot of table until the sacrum rests upon the corner, with hip projecting beyond, and kept from slipping from table by being steadily held. Surgeon generally stands upon the outer side of both thighs, although it is more convenient to be upon the inner side of the left limb. An assistant holds and manipulates the limb projecting over the

table. Another assistant steadies the pelvis and guards the method of hemorrhage-control.

Control of Hemorrhage.—Special pins are introduced in the manner described under General Surgical Considerations (page 389). Previous to

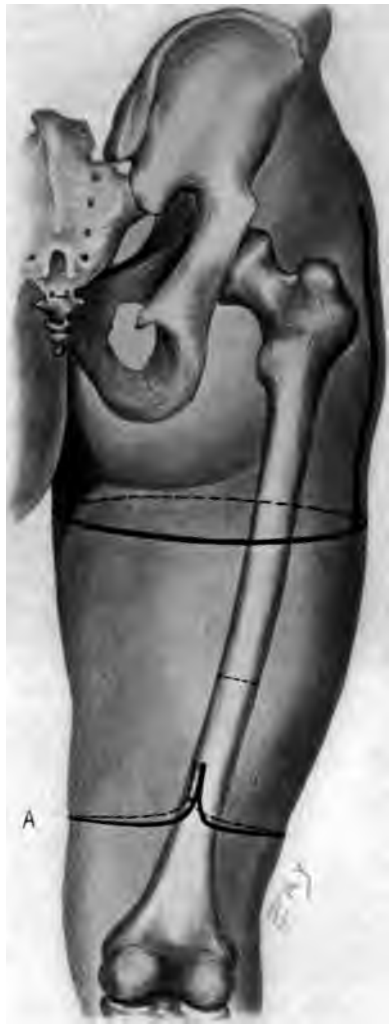

Fig. 283.—AMPUTATIONS THROUGH THIGH AND AT HIP-JOINT:—A, Through lower part of thigh, by modified circular; B, Disarticulation at hip-joint, by Wyeth's method.

the application of the pins, the limb should be constricted by an Esmarch rubber bandage, from the toes to the hip-joint—unless contraindicated.

Landmarks.—Great trochanter; points for the passage of the pins (page 389).

Incisions.—A circular incision is made around the thigh about 15.3 cm.

(6 inches) below the center of the anterior aspect of the rubber tourniquet. The vertical incision passes vertically down the external aspect of the thigh, directly over the great trochanter—passing in a straight line from the tourniquet to the circular incision (Fig. 283, B).

Operation.—The circular incision passes through skin and fascia alone. These are dissected up to the level of the lesser trochanter—that is, for about 5 cm. (2 inches). At this level the muscles are circularly divided to the bone, on a line with the retracted skin and fascia. The vertical incision is now made from the tourniquet down to the circular division, passing directly over the great trochanter. The larger vessels are at once tied—the femoral and profunda arteries and veins, and any other prominent vessel. Through the vertical incision, which has extended, at one sweep, directly through skin, fascia, muscles, and periosteum to the bone, the soft parts are all cleared, as subperiosteally as possible, from the shaft and tuberosities of the femur. Retract the soft parts and divide the capsular ligament transversely over its outer aspect. Manipulate the limb as a lever, nicking the cotyloid ligament to let in air—cut the ligamentum teres—and disarticulate by thrusting the head of the femur upward and outward. If not already severed, divide the posterior aspect of the capsule, and any retaining structures—and remove the limb. If the enucleation be difficult, which is rarely the case in this extensive exposure, the margin of the acetabulum can be chipped away with a chisel sufficiently to let in air—or, if all the vessels be ligatured, the tourniquet may be removed carefully and slowly and the disarticulation completed. The remaining vessels in the posterior aspect of the wound are now ligated—these are chiefly the branches of the sciatic, obturator, external and internal circumflex, and perforating. Having trimmed away all tags of tissue, the heavy muscles are to be quilted together with especial care, by means of two or three tiers of chromic gut sutures. Drainage is to be established—the margins of the wound united in one continuous termino-external suture-line—firm compression made in dressing the wound —and the stump supported upon a pillow.

Comment.—This method probably represents the safest, simplest, and best manner of disarticulating at the hip-joint.

DISARTICULATION AT HIP-JOINT

BY EXTERNAL RACKET METHOD.

Description.—The queue of the incision is placed over the external aspect of the joint—the limbs of the incision encircling the anterior, internal, and posterior aspects of the thigh. Hemorrhage is controlled by an ordinary rubber tourniquet.

Position.—Patient is sufficiently turned to the opposite side to expose the area, and is drawn to the end of the table so that the pelvis rests upon the edge of the table and the hips project beyond—the limb is adducted, rotated inward, and slightly flexed. Surgeon and assistants stand as in the last operation.

Control of Hemorrhage.—For the description of the application of the rubber tourniquet, see General Surgical Considerations, page 389. Also see Hemorrhage control, under the last operation, for reference to the Esmarch bandage.

Landmarks.—Great trochanter.

Incision.—The queue begins about 5 cm. (2 inches) above the upper border of the great trochanter—passes vertically down the limb, along the posterior border of the great trochanter, for about 17 cm. (7 inches)—the two limbs of the racket here diverge to encircle anteriorly and posteriorly, meeting upon the center of the inner aspect of the thigh, about 5 cm. (2 inches) lower down than the termination of the vertical portion of the incision—forming an inverted Y on the outer aspect of the thigh. The limb is rotated as the incision is made (Fig. 282, B).

Operation.—These incisions pass, at first, through skin and fascia only. The skin and fascia of the oval portion of the incision are then dissected up for about 5 cm. (2 inches). The vertical portion of the incision is now deepened to the bone—with the limb in the original position. The anterior, superior, and posterior borders of the great trochanter are cleared of muscles in the order named—as subperiosteally as circumstances allow. The shaft of the femur is cleared, as far as possible, to the extent of the vertical incision. Adduct the limb strongly and divide the superior and posterior parts of the capsule transversely—flex the limb and divide the anterior part of the capsule—rotate outward and cut the round ligament—and then disarticulate. Having ascertained that the tourniquet is compressing the parts well, after the disarticulation of the head of the femur, the muscles are circularly divided on a level with the retracted skin and fascia of the oval incision. The important vessels are at once ligated—consisting of the femoral and profunda arteries and veins, the internal circumflex (and possibly the transverse branch of the external circumflex), comes nervi ischiadici, and muscular branches. The muscles are quilted in two or three tiers, with buried chromic gut sutures, along both the vertical and oval portions of the wound. The suture-line of the skin margins will be termino-external, in one straight line.

Comment.—The approach to the bone is through a region less vascular than by the anterior racket method. The hip-joint can be preliminarily examined, in case disarticulation prove unnecessary. Disarticulation can be effected before severing the vessels. The subperiosteal method can be more easily carried out than by an anterior approach. The branches of the internal pudic are comparatively little involved—there is a low transverse division of the muscles—and good drainage is secured. The method is probably better than disarticulation by the anterior racket method.

DISARTICULATION AT HIP-JOINT

BY ANTERIOR RACKET METHOD.

Description.—The queue of the racket, or oval, is placed anteriorly—the limbs of the oval encircling the external, internal, and posterior surfaces. No tourniquet is used. The femoral is ligated during operation, and the remaining vessels as encountered.

Control of Hemorrhage.—Utilizing the queue of the incision, the common femoral artery and vein are exposed and ligated—during the progress of the operation. Other vessels are secured as exposed.

Position.—Patient supine—otherwise as in the external racket method (page 392).

Landmarks.—Center of Poupart's ligament; course of femoral artery.

Incision.—The queue begins at the center of Poupart's ligament—passes down along the femoral artery for about 7.5 cm. (3 inches)—thence curves inward and crosses the inner aspect of the thigh about 10 cm. (4 inches)

below the genito-crural fold—continues across the posterior aspect of the thigh—crosses the outer side of the limb a short distance below the base of the great trochanter—and thence ascends upward and inward obliquely across the anterior aspect to join the vertical incision about 5 cm. (2 inches) below its commencement at Poupart's ligament (Fig. 281, B).

Operation.—This incision passes well through skin and fascia only, which are allowed to fully retract—and is made with several sweeps of the knife, while the limb is manipulated as indicated. Through the vertical portion of the racket incision, the common femoral artery and vein are early exposed and each ligated in two places and severed between the ligatures. The skin and fascia are fully freed around the entire incision, without any special dissection. The muscles on the outer side (sartorius, rectus, tensor vaginæ femoris) are divided and the external circumflex artery doubly ligated and severed. Passing backward, rotate the thigh inward and cut the insertion of the gluteus maximus. Passing forward, rotate the thigh outward and cut the psoas—and retract the parts and doubly ligate and divide the internal circumflex artery. Divide the muscles of the internal flap on a level with the retracted skin (pectineus, gracilis, and adductors), ligating the muscular branches. Adduct and rotate the thigh inward—severing the muscles attached to the great trochanter. Abduct and rotate the thigh outward—cut the capsule transversely—disarticulate—sever the round ligament—and the obturator externus tendon, if still undivided. The head of the bone is now drawn forward and outward—a long knife is carried behind the bone, passing downward and backward and dividing the remaining parts at the posterior aspect, on a level with the retracted skin (hamstrings, parts of the adductors and sciatic nerve)—ligating the perforating and muscular branches. The muscles are quilted in two or three tiers—after having severed all tags of tissue and instituted drainage. The margins of skin are sutured in a single vertical line. The stump is dressed as in the preceding operations.

Comment.—While possessing many good points in common with the method by external racket incision, the anterior racket method possesses the further advantage that the hip-joint is more easily and directly reached, and disarticulation more readily accomplished. No special form of tourniquet control is necessary. There is, however, not so good an opportunity afforded for a preliminary examination of the hip-joint, with possible excision substituted for amputation. The operation is longer, owing to the slower hemorrhage-control.

OSTEOPLASTIC AMPUTATIONS.

Description.—An osteoplastic operation, in general, consists in the approximation of fresh sections of bone to each other, for the purpose of bringing about union between their opposed surfaces. In an osteoplastic amputation, some portion of a distal bone is raised in the form of an osseo-periosteal flap, adherent to its neighboring soft parts, and applied to the sawed aspect of the proximal bone. In performing osteoplastic amputations a special saw should be provided—a bow-saw with a scroll-blade of strong, narrow, thin metal, which can be turned in any direction while in the act of making bone-sections, such as the Helferich pattern of saw. (A saw for osteoplastic work is now on trial which is, practically, a Gigli saw held in a bow-handle.) The freshened surfaces of bone are variously held in contact —the edges of the surrounding periosteum may be sutured together—the

bone-surfaces may be wired, pegged, or nailed—or the bone aspects may be

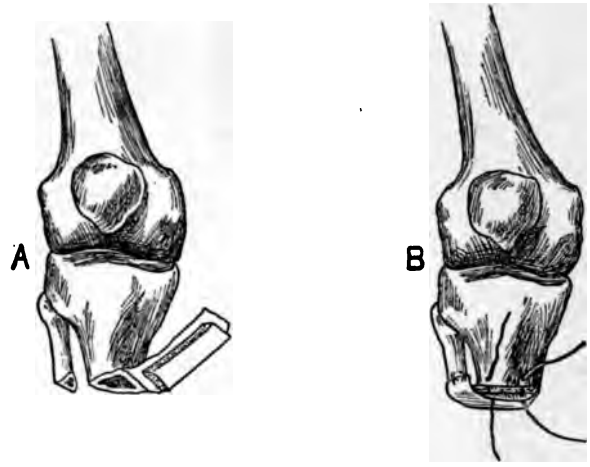

Figs. 284 and 285.—BIER'S OSTEOPLASTIC AMPUTATION OF THE LEG:—A, Showing manner of raising an osseo-periosteal flap from tibia; B, Showing bone-flap brought over sawed ends of tibia and fibula, and its periosteal margins sutured to the margins of periosteum around tibia and fibula. The osseo-periosteal flap is here shown separated from its soft parts, to which it should be adherent. (Modified from Bier.)

held in apposition (especially where there is no strong counter-pull) by the simple suturing of the surrounding soft parts together.

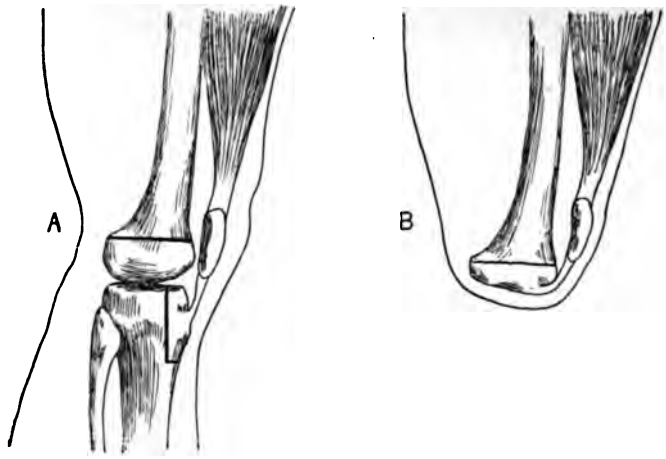

Figs. 286 and 287.—SABANEJEFF'S OSTEOPLASTIC AMPUTATION THROUGH THE THIGH:—A, Showing bone-sections through femur, and in raising an osseo-periosteal flap from tibia; B, Showing apposition of bony parts after amputation. (Modified from Sabanejeff.)

Objects of the Osteoplastic Method of Amputation.—(1) Closure and protection of the medullary canal;—(2) Securing of a solid end of bone to meet pressure—brought about by the rounding off of the section of bone

whose surface becomes united with the end of the main bone;—(3) Avoidance of adhesions between sawed bone and soft coverings—and, by retaining the mobility of these parts, thereby lessening the chance of neuralgia and ulceration in the stump.

Application of the Osteoplastic Method of Amputation.—Up to the present time, the chief sites at which this method of amputation has been used have been in the lower extremity—that is, where pressure-bearing stumps are sought. The following are examples of the osteoplastic method of amputation;—Pirogoff's osteoplastic amputation of the foot (page 361)—Lister's modification of Carden's transcondyloid amputation of the thigh (page 379)—Gritti-Stokes's supracondyloid amputation of the thigh (page 380)—Sabanejeff's amputation of the thigh (Figs. 286 and 287)—Bier's amputation of the leg (Figs. 284 and 285).

THE NEW YORK LIBRARY. ACADEMY OF MEDICINE.

CHAPTER XIII.

EXCISIONS.

GENERAL CONSIDERATIONS.

Definitions.—Excision signifies a cutting-out. By Excision of Joints, is meant the removal of the articular ends (including cartilage and synovial membrane) of the bones entering into the formation of the joint, with a minimum injury to the neighboring parts. The articular extremities of the proximal and distal bones are removed, except in the cases of the shoulder- and hip-joints, where the articular ends of the humerus and femur, respectively, are alone removed, the articular cavities of the scapula and os innominatum being gouged or scraped. In Excision of Bones, the removal of a bone is signified, with minimum injury to neighboring structures. In the Total Excision of a bone, the entire bone is removed, including its articular ends. In the Partial Excision of a bone, a part, only, of the bone is removed. By Resection, is meant the removal of the entire thickness of a bone (thus, a joint is said to be excised by the resection of the ends of its constituent bones) —but the terms excision and resection are generally used synonymously. Osteoplastic Resection signifies the temporary removal of a bone, or part of a bone, covered by its soft parts still attached, for the purpose of exposing more deeply seated structures—the cutaneo-muscular-osseous flap being replaced later.

Object of Excisions.—By the operation of Excision, in the case of the extremities, limbs are often now saved in a state of usefulness which formerly were entirely lost by amputation—thus marking one of the greatest advances of modern conservative surgery.

General Features of Excisions.—(1) Total removal of all diseased tissue. (2) Preservation of a useful limb. The excessive removal of bone, or faulty repair of a wound, or improper after-treatment may result in a flail limb. A movable joint is to be expected everywhere, except in the case of the knee, where ankylosis is sought. (3) The removal of bare bone, free of its periosteum—with minimum disturbance to surrounding soft parts and neighboring parts of bone. (4) Division of bones in such a manner, and at such an angle and height, as to place them in a position favorable to the formation of a new joint—or favorable to ankylosis in the most desirable position. The operation is rarely undertaken in the very young or in the very old.

Indications for Excision.—Joint disease (generally tuberculosis); disease of shaft or articular ends of bones; extensive injury to bone or joint; unreduced dislocation; ankylosis; deformity; compound dislocation or fracture; fracture-dislocation; ununited fracture.

Preparation.—Locally, the part should be prepared as for any extensive operation—the part should be shaved, and should come upon the table in an aseptic dressing. Constitutionally, the patient should be gotten into a condition to stand a long operation—and, subsequently, to meet the demands of a prolonged convalescence. Previous to the operation, an apparatus

should be provided suitable for the double purpose of retaining the part immovable, and, when desired, of enabling passive movement to be accomplished. In no other class of operations does the final result so largely depend upon the mechanical contrivance in which the part is to be subsequently held and passively exercised.

Instruments.—Scalpels, light and heavy; bistouries, sharp and blunt; excision-knives (strong instruments, with good grasping handles and stout blades); scissors, straight and curved, sharp and blunt; saws, large and small, solid-bladed and open-bladed, broad and narrow, especially saws with adjustable and revolvable blades, chain and Gigli saws, key-hole saw, Adam's pattern, Hey's pattern; forceps, dissecting, toothed, and artery-clamp; bone-holding forceps, of various sizes and curves; periosteal elevators, an especially large variety of straight, curved and angular, light and heavy; rugines and raspatories; retractors, angular and curved, toothed and smooth; spatulæ, metal or ivory; directors, ordinary grooved and saw-directors; probes; chisels, narrow and broad, straight and curved; osteotomes, various; bone-gouges and curettes, of various shapes and sizes; drills; flushing-gouge; pins, pegs, and needles; wire; suture and ligature material of silk, gut, chromic gut, silkworm-gut, and wire; needles; needle-holders; Esmarch rubber bandage and tourniquet.

Varieties of Excision.—A joint or a bone may be excised by either the subperiosteal or the open method.

EXCISION BY THE SUBPERIOSTEAL METHOD.

Description.—In this method it is sought to preserve the entire periosteum —from the site at which it is first reached in the operation—on upward or downward to the opposite limit of the wound. In the case of excising a joint, no periosteum covers the articular ends of the bones—the periosteum becoming merged into the fibrous tissue of the capsular ligament—and here a periosteo-capsular covering is separated continuously. The advantages of the subperiosteal method are:—(**a**) Production of new bone from the preserved periosteum; (**b**) Preservation of the capsule of the joint, with the ligaments attached to it—and hence a stronger and more useful joint; (**c**) Preservation of the attachment of tendons to neighboring periosteum—and hence additional strength and movement; (**d**) Less hemorrhage, and less damage to surrounding tissues, as, when the bone is once reached, the operation is henceforth conducted in a comparatively safe area, between bone and periosteum (or between bone and periosteo-capsular covering); (**e**) The neighboring intermuscular planes (except to reach the bone) are not opened up—the operation-site being circumscribed by the periosteal or capsulo-periosteal sheath raised. The disadvantages of the subperiosteal method are the following:—(**a**) Possibility of retaining diseased periosteum; (**b**) Difficulty of the operation, and the likelihood of detaching the periosteum in shreds; (**c**) Time necessary for its performance. To summarize—the subperiosteal method is excellent in theory, but is often difficult, and sometimes contraindicated, in practice. The subperiosteal method should be adopted whenever possible—and carried out as far as possible—where the periosteum is healthy. Always aim for the subperiosteal method, where the periosteum is healthy and there be no contraindication—and, if only partly successful, less damage will have been done to the neighboring tissues, and the result will be more satisfactory, than if the open method had been

undertaken from the start. As a result of a successful subperiosteal excision, bone is reproduced, refilling the periosteal cavity to a greater or lesser extent, and assuming a form largely determined by the limiting periosteum—being poured out, so to speak, into a mould of periosteum or capsulo-periosteum. Sometimes no new bone forms—sometimes an excess. Some reabsorption of the new bone occurs. Exceptionally, reproduction of shafts and joint surfaces of bones is remarkable—and the functioning almost normal. As to the peculiarities of the periosteum,—in the young, it is thick and easily detachable (and also more valuable);—in the old (and in cadavera) it is thinner and more adherent;—in chronic inflammation, it is easily detachable (but often less valuable here).

Preparation.—Given under General Considerations.

Position.—Patient's limb is placed in such a position as to be most accessible to the surgeon, and, at the same time, most relax the overlying parts. Surgeon stands in the same general relation to the limb as in amputating—to the outer side of right and inner side of left limbs. Assistant so stands as to steady the part or retract the lips of the wound. Special positions will be mentioned under special operations.

Landmarks.—Will be mentioned under each operation.

Preliminary Control of Hemorrhage.—While the same need for the control of hemorrhage does not exist as in the case of amputations, as no important vessels are ordinarily cut, yet, to avoid what hemorrhage would otherwise occur, and for the sake of having a clean, dry field, it is best to apply a rubber constrictor above the site of operation. If its application be preceded by elevation and proximal massage of the limb, less regurgitant bleeding will occur. Though oozing may be greater after the removal of an Esmarch than might be the case had it not been used, yet the advantages more than conterbalance the disadvantages. The constrictor should always be removed before suturing the wound, that all vessels which still bleed may be taken up.

Incision.—An incision should be chosen which is simple—which passes to the joint or bone, by the most direct and safest route—which will do the minimum injury to the neighboring structures on its way to the site—which will fall in with the intermuscular planes—and, if possible, with the cleavage line of the skin. The incision should be fully long enough to admit of easy manipulation in the depth of the wound, upon which the subperiosteal method so largely depends. Generally a single straight cut is used. The incision usually passes at first through only skin and fascia—but, in some cases, passes directly to bone.

Operation.—(1) If the primary incision have passed only through skin and fascia, an intermuscular plane is now sought, and, by lateral retraction of the lips of the wound and the underlying muscles, the bone is reached—with the least possible damage to the soft parts and without any further cutting, but simply by separation of fascial planes. In other instances, the way may be partly opened up by separation and retraction, and partly by cutting muscular tissue and less important vessels and nerves. In still other cases, the original incision passes directly to the joint or bone. In any event, the final incision passes down through the periosteum of the lower end of the proximal bone—through the capsule of the joint—and through the periosteum of the upper end of the distal bone—all in one continuous sweep of a stout excision knife. (2) Having once gotten within the periosteum and capsule, the knife is laid aside and this capsulo-periosteal covering of the joint and articular ends of the bones—or the periosteum alone where only

the interarticular portion of the bone is involved—is separated by means of periosteal elevators, which work constantly toward the bone, hugging it always. Where the tendons and muscles are inserted into the periosteum, these are levered off the bone by means of periosteal elevators and rugines—retaining their attachments continuous with the periosteum. In other words, in an ideal case, the osseous tissue is decorticated, or shelled out of its capsulo-periosteal sheath, leaving the periosteum and capsule intact and continuous, as well as the ligaments of the joint and the tendons in the neighborhood. (3) As soon as the articular ends have been sufficiently freed and bared in their capsulo-periosteal sheath, disarticulation is accomplished and the ends of the bones, in turn or together, are protruded through the incision, or incisions, and are excised just above their articular cartilages—the soft parts being protected during the sawing. (4) The sawed ends of the bones are now drawn back within their capsulo-periosteal covering. The tourniquet is then loosened and the vessels not tied during the steps of the operation which bleed are now tied. The edges of the capsulo-periosteal sheath are sutured together with catgut. But where muscles have been cut along the original incision, these are quilted with catgut. Even where no muscle-fibers are laid bare, but only the rounded borders uncut, it is well to quilt together such separated muscles, as the fascia covering them unites and fills the dead spaces and hastens repair of the wound as a whole. Temporary drainage is indicated in the larger excisions. The suturing of the skin should be done with silk or silkworm-gut—which is usually removed about the tenth day.

Application of Retentive Apparatus, and After-treatment.—The future usefulness of the limb depends almost more upon the after-treatment than upon the manner of operation. There is hardly any set of operations in which the ultimate outcome is more dependent upon the care and management subsequent to operation. The usefulness of the limb also largely depends upon non-suppuration, or but limited and brief suppuration. While temporary drainage is at first indicated, the dressings should be dry and infrequent. In applying the first dressing, the limb may be immobilized upon almost any splint—often the permanent position, or method of treatment, cannot be adopted immediately. Or the limb, on the other hand, may be put up in its permanent and special splint from the first. This latter course is preferable when possible. In still another class of cases, as in operating for deformity, it may take some time to bring the limb into its permanent position. The kind of splint or retentive apparatus adopted is extremely important. It should be selected to do the special work in hand—and be very precisely applied. Its features are,—(**a**) that it should firmly grasp the limb above and below the excised joint—and (**b**) that it should be hinged, the hinge corresponding with the joint, so that from time to time the angle of the joint can be changed, while still retaining the relative relations of the ends of the bones. If mobility is to be expected, the ends of the bones should not be put up in direct contact—the amount of separation varying with circumstances—the separation being less in adults, and where much periosteum has been saved, than in the reverse conditions. If ankylosis be desired, the ends of the bones should be put up in close contact in the position desired—and should be kept rigidly in contact until union is solid. As to passive movement, there is no fixed time at which it should begin. It should commence just as soon as acute inflammation and sensitiveness subside (generally in from one to three weeks). General good health, massage, and electricity all aid the favorable course of the traumatism and the final functioning.

What has been said of apparatus and after-treatment in connection with the subperiosteal method of excision, also applies equally to the open method.

Comment.—(1) No vessels of importance are ordinarily injured in the operations of excision—but, if injured, should be ligated. (2) All synovial membrane, and even extra-articular tissue, must be removed if diseased. (3) Where muscles or tendons must be divided, their oblique division is preferable. In any event, they should be sutured with gut. (4) Extensive gouging, or curettage, is a legitimate substitute for typical excision, where the latter is impracticable—as where an epiphyseal cartilage might be destroyed. (5) Where ankylosis is sought, the synovial membrane should be thoroughly dissected away. (6) Retention of the periosteum gives firmness to the cicatrix, even where the amount of bone deposited is little or none—lessens the shortening of the limb—and helps retain the proper relational attachment of the muscles. A periosteo-capsular covering favors the reproduction of a joint with articular cartilages, and gives support to ligaments. (7) Tendons often have to be removed with knife, cutting close to the bone—or may be chiseled away with a thin shell of bone. (8) The removal of tissue must not, ordinarily, be stopped short of the removal of the entire diseased structures. (9) The destruction of the epiphyses in young children should be avoided. (10) When the saw-section does not remove all of the involved bone, it is better to remove the balance with a gouge than to saw another section. (11) The gap of an excised bone may be filled by bone-grafting. (12) The periosteum is easily removable in chronic osteitis and synovitis—and hard to remove in acute periosteitis.

EXCISION BY THE OPEN METHOD.

Description.—No attempt is here made to preserve the periosteum. The continuous attachment, therefore, of periosteum and capsule is sacrificed—though the capsule is preserved. The tendons are peeled from their attachment to the periosteum—and some of the ligaments of the joints are sacrificed. The open method is more rapid, but more damage is done to the neighboring structures, and less satisfactory functioning of the joint is apt to follow. The chief indication for adopting the open method is found in those cases where, from disease, or other cause, the preservation of the periosteum is contraindicated. For further comparison, see under Description of the Subperiosteal Method, page 398. A reckless and careless sacrifice of capsule, tendons, and ligaments in the open method is distinctly unjustifiable. In undertaking the open method, even in disease, the operation should be carried out with the underlying idea of a "modified subperiosteal method as far as consistent."

Preparation—Position—Landmarks.—As in the subperiosteal method.

Preliminary Control of Hemorrhage.—The use of a constrictor is here indicated even more than in the subperiosteal method—as hemorrhage will, usually, be greater, from the greater damage to the involved parts.

Incision.—The line of incision for the open method is generally the same as that for the subperiosteal method. Sometimes, however, the subperiosteal excision of a joint is done through one incision—and the open excision through another. Whether the position of the line of incision be the same or not, the manner of making it and of reaching the level of the bone, or joint, are the same.

Operation.—Up to the point of reaching the level of the joint, or bone,

there is no difference between the open and subperiosteal methods of excision. Once the bone is reached in the open method, however, no attempt is made to preserve the periosteum—although the soft parts are disturbed as little as possible. The periosteum is not cut through over the bones above and below the joint. The muscles and tendons are detached—not cut, but peeled—from the bones as closely as possible. While some of the ligaments of the joint are saved, some are unavoidably lost. This separation is accomplished by rugines, raspatories, and by stout excision knives, rather than by periosteal elevators. The capsule of the joint is cut into as soon as the articular region is sufficiently exposed and cleared. The bones are then disarticulated and their ends protruded and sawed off, during which the soft parts are well protected. The ends of the bones are now drawn back into their musculo-capsular (rather than periosteo-capsular) sheath—the constrictor relaxed—the vessels ligated—the cut or separated muscles quilted—and the limb put up and subsequently treated as in the subperiosteal method.

Application of Retentive Apparatus, and After-treatment—Comment.—As in Excision by the Subperiosteal Method (page 400).

EXCISIONS ABOUT THE FINGERS.

Surgical Anatomy—Surface Form and Landmarks.—See under Amputations of the Fingers, pages 279 and 280.

General Surgical Considerations.—(1) Typical excisions about the

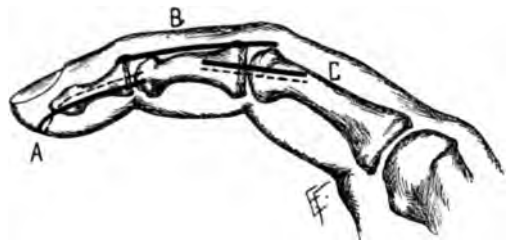

Fig. 288.—Excisions about the Fingers:—A, Excision of terminal phalanx, by U-shaped palmar incision; B, Excision of second phalanx of index, by dorso-external incision; C, Excision of first interphalangeal joint, by two lateral incisions.

fingers are unusual. Incomplete excisions for dead bone are more common. (2) Excision of the terminal phalanx is better than disarticulation at the last interphalangeal joint. (3) Excision of the interphalangeal joints is very satisfactory. (4) Excision of the metacarpo-phalangeal joints often leaves a useless joint—except in the case of the thumb. It should not be done in the young, as it destroys the epiphyses of the metacarpal and phalanx. It is satisfactory in the case of the thumb, especially if the phalangeal epiphysis be left (there is no lower metacarpal epiphysis). (5) In excisions of the phalanges and metacarpals, the subperiosteal method is particularly indicated, although its execution is not very satisfactory. (6) Partial excision of the phalanges and metacarpals is more satisfactory than total excision. (7) About the only phalanges one usually attempts to excise are the last of all the fingers, the second of the index, and the first of the thumb.

Methods of Excision about the Fingers.—(a) For Terminal Phalanx

of Finger or Thumb:—Best Method; U-shaped Palmar Incision. (b) For Second Interphalangeal Joint:—Best Methods; Two Lateral Incisions (for fingers in general); Dorso-external Incision (for index); Dorso-internal Incision (for little finger);—Other Methods; Dorso-lateral Incision; Single Lateral Incision. (c) For Second Phalanx:—Dorso-lateral Incision (for fingers in general—if done at all); U-shaped Palmar Incision (for thumb); Dorso-external Incision (for index); Dorso-internal Incision (for little finger—if done at all);—Other Methods; Two Lateral Incisions. (d) For First Interphalangeal Joints:—Two Lateral Incisions (for fingers in general); Dorso-external Incision (for index and thumb); Dorso-internal Incision (for little finger);—Other Methods; Single Lateral Incision. (e) For First Phalanx:—Dorso-lateral Incision (for fingers in general—if done at all); Dorso-internal Incision (for thumb—and for index, if done in the latter case at all); Dorso-internal (for little finger—if done at all);—Other Method; Two Lateral Incisions.

EXCISION OF TERMINAL PHALANGES OF FINGERS

BY U-SHAPED PALMAR INCISION.

Position.—As for Amputations about the Fingers (page 283).

Landmarks.—Terminal interphalangeal joint.

Incision.—U-shaped incision—beginning opposite the terminal interphalangeal joint-line, with the two limbs about three-fourths of the width of the finger apart, and with the convexity extending downward nearly to the nail-tip (Fig. 288, A).

Operation.—The incision passes directly to the bone—the soft parts are dissected up in the form of a palmar flap—and the terminal phalanx grasped with forceps, disarticulated, and enucleated. The palmar flap is then sutured back into position and the digit dressed upon a palmar splint.

Comment.—Is is better to make a partial excision, if possible, leaving the base of the phalanx—which insures the retention of the epiphysis and the attachment of the flexor profundus digitorum. If a total excision be done, suture the flexor tendon into the stump and close the beginning of the flexor sheath, if demonstrable.

EXCISION OF SECOND INTERPHALANGEAL JOINTS OF FINGERS

BY TWO LATERAL INCISIONS.

Position.—As for Amputations about the fingers (page 283).

Landmarks.—Second Interphalangeal joint-line.

Incisions.—Two straight incisions in the mid-lateral aspects of the fingers, with their center over the joint-line (Fig. 289 A, A′).

Operation.—The incisions pass directly through skin, fascia, lateral ligaments, periosteum, and capsule into joint. By hugging the bones and working between them and the soft parts with a sharp, fully curved small periosteal elevator, the bones are everywhere freed. The articular ends are then disarticulated—thrust out of the wounds—cut off with saw—and the sawed ends drawn back. The musculo-periosteal-capsular sheath is then closed on either side with buried gut sutures. The skin wounds are sutured and the parts dressed on a palmar splint.

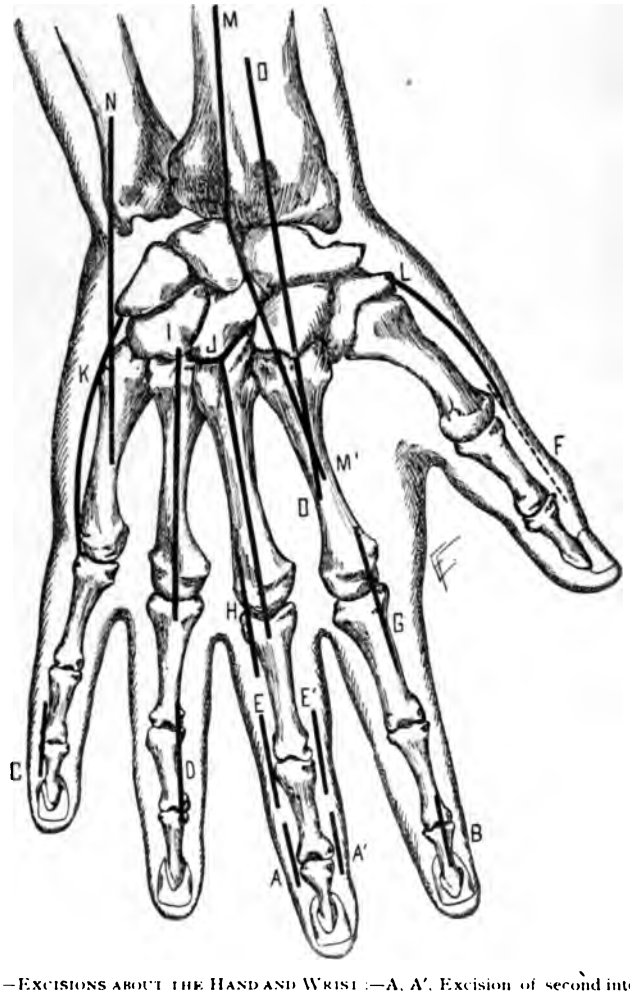

Fig. 289.—Excisions about the Hand and Wrist:—A, A'. Excision of second interphalangeal joint by two lateral incisions; B, Of second interphalangeal joint of index, by dorso-external incision; C, Of second interphalangeal joint of little finger, by dorso-internal incision; D, Of second phalanx of finger, by dorso-lateral incision; E, E', Of first interphalangeal joint, by two lateral incisions; F, Of first phalanx of thumb, by dorso external incision; G, Of metacarpo-phalangeal joint, by dorso-lateral (dorso-external) incision; H, Of metacarpo-phalangeal joint, by dorso lateral (dorso-internal) incision; I, Of metacarpal, by dorsal incision; J, Of metacarpal, by dorsal incision, with added angular incision; K, Of metacarpal of little finger, by dorso-internal incision; L, Of metacarpal of thumb, by dorso-external incision; M, M', Of wrist-joint, by radial incision, and N, ulnar incision (Ollier's operation); O, O, Of wrist-joint, by dorso-radial incision (Boeckel-Langenbeck operation).

EXCISION OF SECOND INTERPHALANGEAL JOINT OF INDEX

BY DORSO-EXTERNAL INCISION.

Position—Landmarks.—As in the above operation.

Incision.—A straight incision placed over the dorsal aspect of the second interphalangeal joint, just to the outer side of the extensor tendon—with its center over the joint line.

Operation.—The incision passes directly through skin, fascia, capsule, and periosteum—going through the last over the ends of the phalanges just above and below the joint. The soft parts are subperiosteally elevated from the joint and ends of the bones. The bones are then disarticulated—protruded—and their ends sawed off just beyond their articular surfaces. The sawed ends are now drawn back into position—the musculo-periosteo-capsular sheath is closed, on either side, with buried gut sutures—the lips of the skin wounds sutured—and the digit dressed upon a palmar splint. (For principle, see Fig. 288, C, and Fig. 289, B.)

EXCISION OF SECOND INTERPHALANGEAL JOINT OF LITTLE FINGER

BY DORSO-INTERNAL INCISION.

Description.—The operation is, in every respect, similar to the above —except that the incision is placed over the dorsal aspect of the second interphalangeal joint of the little finger, just to the inner side of the extensor tendon, with its center over the joint-line (Fig. 289, C).

EXCISION OF SECOND PHALANGES OF FINGERS

BY DORSO-LATERAL INCISION.

Position.—As for Amputations (page 283).

Landmarks.—Second phalanx, and first and second interphalangeal joints.

Incision.—Straight incision placed over the dorsal aspect of the second phalanx, just to the outer or inner side of the extensor tendon—beginning just above the first interphalangeal joint and ending just below the second interphalangeal joint. In the index-finger the incision would be dorso-external (that is, to the outer side of the extensor tendon). In the little finger, if performed at all, it would be dorso-internal. In the thumb, it would be by a U-shaped palmar incision (Fig. 288, B, and Fig. 289, D).

Operation.—The incision passes directly through skin, fascia, periosteum, and capsules of the first and second interphalangeal joints. The soft parts are subperiosteally elevated from the bone and the bone isolated and disarticulated. The lips of the periosteo-capsular sheath are carefully sutured with buried gut sutures. The margins of the skin wound are closed in the usual manner. The finger is dressed upon a palmar splint until new bone has been thrown out.

Comment.—In the case of the thumb, the operation is the same as for the terminal phalanx of the fingers in general.

EXCISION OF SECOND PHALANX OF INDEX

BY DORSO-EXTERNAL INCISION.

Position.—As for Amputations of Fingers (page 283).

Landmarks.—Second phalanx.

Incision.—Straight incision over dorsal aspect of index, placed just to the outer side of the extensor tendon—beginning just above the first interphalangeal joint and ending just below the second interphalangeal joint (Fig. 288, B).

Operation.—As for excision of the second phalanges of the fingers in general.

EXCISION OF SECOND PHALANX OF LITTLE FINGER

BY DORSO-INTERNAL INCISION.

Position—Landmarks.—As in the last operation.

Incision.—Straight incision over dorsal aspect of little finger, just to the inner side of the extensor tendon—beginning just above the first and ending just below the second interphalangeal joint.

Operation.—As for excision of the second phalanges in general.

EXCISION OF FIRST INTERPHALANGEAL JOINTS OF FINGERS.

Description.—The best method of excising the first interphalangeal joints is the same as adopted in the case of the second interphalangeal joints —namely, by two lateral incisions for the fingers in general (Fig. 289, E, E′), —dorso-external incision, for the index or thumb,—and dorso-internal incision, for the little finger. (For principle, see Fig. 289, G and C.) These operations are described at pages 403 and 404.

EXCISION OF FIRST PHALANGES OF FINGERS.

Description.—The excision of the first phalanx of a finger is, ordinarily, not admissible—except in the case of the thumb. If performed at all, the best methods would be the same as those adopted in the case of excision of the second phalanges—namely, by the dorso-lateral incision, for the fingers in general (on either inner or outer side of the extensor tendon),—dorso-external for thumb or index,—and dorso-internal for little finger.

EXCISIONS ABOUT THE HAND.

Surgical Anatomy—Surface Form and Landmarks.—See under Amputations about the Hand, pages 291 and 293.

General Surgical Considerations.—(1) Partial excisions about the hand are successful operations. (2) Total excisions, if subperiosteal, will sometimes yield a firm cicatrix that will render the finger useful. But sometimes the finger is drawn up and useless. (3) Operations for the partial excision of the metacarpals are the same in principle as those for the excision of the entire bone, except more limited—and hence will not be given separately. If a chain or Gigli saw can be passed around the bone in these operations of partial excision, this is preferable to cutting the metacarpal with pliers. If this cannot be done, one can cut through the center of that part which is to be removed with pliers, and then slip a chain or Gigli saw under either end and remove the requisite amount, thus avoiding the crushing effect of the bone pliers. (4) Operations for the removal of individual carpal bones are uncommon. Their removal in the course of excision of the wrist is dealt with under that operation.

EXCISION OF METACARPO-PHALANGEAL JOINTS OF FINGERS

BY DORSO-LATERAL INCISION.

Position.—As for Disarticulations at the Metacarpo-phalangeal joints (page 287).

Landmarks.—Metacarpo-phalangeal joints.

Incision.—Straight incision over the dorsal aspect of the joint, just to the outer or inner side of the extensor tendon, with its center over the joint-line (Fig. 289, H and G).

Operation.—The incision passes through skin, fascia, capsule of the joint, and the periosteum of the ends of the metacarpal and phalangeal bones. The bones are closely hugged and the soft parts are freed from the articular ends and shafts. The articular ends of the bones are disarticulated and the base of the phalanx first protruded and sawed off. The parts are then retracted from about the head of the metacarpal, which is thus made prominent and removed with a small saw, or chain or Gigli saw, while steadying the end of the bone with bone-forceps. The bones are then drawn back in place—the periosteo-capsular sheath sutured with buried gut stitches—the skin wound closed—and the part dressed upon a palmar splint.

Comment.—In excising the metacarpo-phalangeal joint of the thumb or index, a dorso-external incision is used—and, in the case of the little finger, a dorso-internal incision. Otherwise the operations at these sites are similar to the one just described.

EXCISION OF THE METACARPALS

BY DORSAL INCISION.

Position.—As for Disarticulation of the Metacarpals, page 297.

Landmarks.—Carpo-metacarpal and metacarpo-phalangeal joints.

Incision.—Straight incision over the dorsal aspect, immediately to the outer or inner side of the extensor tendon, beginning just above the carpo-metacarpal and ending just below the metacarpo-phalangeal joint. If necessary, the upper and lower ends of the incision may have two short diverging arms continuing from them, to better expose the joints. The incision may be placed directly in the mid-dorsal line, the extensor tendon being carefully drawn to one side, out of harm's way, as soon as the skin is incised (Fig. 289, I and J).

Operation.—After guarding the extensor tendon, the incision passes through periosteum of the metacarpal and the capsules of the two joints directly to the bone. The central portion of the metacarpal is first cleared subperiosteally around its entire circumference by a fully curved periosteal elevator, the interossei being separated with the periosteum. Unless a Gigli saw can be conducted around the shaft of the metacarpal, the center of the bone is divided with cutting pliers (for although they crush the bone, no part of it is to be saved). Each end of the divided bone is then seized in turn with bone-forceps and forcibly drawn backward and manipulated from side to side—during which manipulation the lateral and palmar surfaces are freed and the ligaments at the carpo-metacarpal and metacarpo-phalangeal joints are put upon the stretch and divided. The musculo-periosteal sheath is then sutured with buried catgut stitches and the skin wound closed.

Comment.—(1) The metacarpal may be first disarticulated at the metacarpo-phalangeal joint and then drawn backward—but the above method is easier. (2) The extensor tendons and the structures in the palm of the hand are always especially guarded.

EXCISION OF METACARPAL OF THUMB

BY DORSO-EXTERNAL INCISION.

Position.—The ulnar side of the hand is held against the table, the radial side presenting.

Landmarks.—The metacarpal bone and carpo-metacarpal and metacarpo-phalangeal joints.

Incision.—Straight incision over the dorso-external aspect of the metacarpal, just to the outer side of the extensor brevis pollicis tendon—beginning above the trapezio-metacarpal and ending just below the metacarpo-phalangeal joints. If necessary an angular incision may be added to the ends of the straight incision (Fig. 289, L).

Operation.—Having incised skin, avoid the external branch of the radial nerve—and then cut directly through periosteum and capsules onto bone and into joints. The operation is then completed as in the case of an ordinary finger. The extensor ossis metacarpi pollicis is separated from the base of the metacarpal. The subperiosteal method is here especially to be carried out, if possible.

EXCISION OF METACARPAL OF LITTLE FINGER

BY DORSO-INTERNAL INCISION.

Description.—The operation is the same as that for the fingers in general, except that the incision is placed upon the inner side of the extensor tendon (Fig. 289, K).

EXCISION OF THE WRIST-JOINT.

Surgical Anatomy—Surface Forms and Landmarks.—Given under Disarticulation at the Wrist, page 302.

Position.—See each operation.

General Surgical Considerations.—In complete excision of the wrist-joint, all of the carpals, the lower ends of the radius and ulna, and the articular ends of the metacarpals are removed. When not diseased, it is well, however, to leave the pisiform, unciform process of the unciform and trapezium, as the two former give attachment to many muscles and the latter forms part of the important thumb-joint.

After-treatment.—A splint is indicated which will support the palm; keep the wrist slightly extended; the fingers slightly flexed and the thumb slightly separated from the hand. The fingers should be passively moved within three or four days. The wrist should be kept still until fairly solid and then passively moved, still being held upon a splint, which is generally retained for from three to six months.

Results.—Usually not altogether satisfactory. The hand may become rigid, adducted, and useless. Speedy healing without suppuration, a good splint, and faithful passive movement aid largely in the production of a satisfactory result.

Best Methods—Radial and Ulnar Dorsal Incisions (Ollier's operation). Single Dorso radial Incision (Boeckel-Langenbeck operation).

Other Methods.—Bilateral Incisions (Lister's method). Dorso-ulnar Incision. Median Dorsal Incision (Mayo Robson's method). Single Ulnar Lateral Incision (Heron Watson's method).

Comparison.—The carpal bones are removed with greater ease, and less damage is done to the tendons, by the method of the radial and ulnar dorsal incisions.

EXCISION OF WRIST

BY RADIAL AND ULNAR DORSAL INCISION—OLLIER'S OPERATION.

Description.—The articular ends of the radius and ulnar are removed. The articular ends of the metacarpal bones are gouged only, unless extensively diseased, and, if so, are removed. The pisiform bone, the unciform processes of the unciform bone, and the trapezium are preserved, if possible—for the reasons given below.

Position.—Patient's hand, prone, rests by his side, or, preferably, upon a small table at the patient's side, supported upon a firm cushion. Surgeon sits in front of the hand. Assistant steadies patient's forearm and fingers.

Landmarks.—See Incision.

Incisions.—(1) Radial Incision—begins opposite the center of the dorsal surface of the second metacarpal—passes obliquely upward, just to the outer border of the extensor indicis tendon, to the center of a line connecting the two styloid processes—thence changes its course slightly and passes vertically upward in the long axis of the limb for about 7.5 cm. (3 inches) above the radial styloid process. (2) Ulnar Incision—begins opposite the center of the dorsal surface of the fifth metacarpal—and passes upward 3.2 cm. (1¼ inches) above the tip of the ulnar styloid process, lying to the inner side of the extensor carpi ulnaris (Fig. 289, MM′ and N).

Operation.—(1) The radial incision is at first superficial. The internal branch of the dorsal division of the radial nerve is avoided, if possible. The extensor indicis tendon is exposed and is retracted outward, with its sheath. The tendon of the extensor carpi radialis brevior is crossed by the incision—is followed down to the insertion into the base of the third metacarpal and is drawn outward, but not cut. The upper part of the incision passes down between the extensor indicis (which, with the extensor communis digitorum, is drawn inward) and the extensor longus pollicis (which is drawn outward). This incision is now, after retraction of the muscles and tendons, carried through the posterior annular ligament, capsule of the joint, and periosteum of the carpal, radial, and metacarpal bones. (2) The ulnar incision is also at first superficial. The dorsal cutaneous branch of the ulnar nerve is avoided, if possible. The incision is carried down along the inner border of the extensor carpi ulnaris—upon the ulna, cuneiform, unciform, and fifth metacarpal—going through the posterior annular ligament, capsule, and periosteum of the ulna, carpal and metacarpal bones. (3) Decortication is begun upon the radial side. The periosteum and ligaments are stripped up from the dorsal surface of the carpal bones as far as can be done through the radial incision. All the tendons are raised with their periosteum bodily from their grooves, with their sheaths unopened. The same steps are repeated through the ulnar incision—hugging the bones closely and elevating off all the overlying tissues, working entirely between these tissues and the bones. (4) Removal of the carpal bones. As each carpal bone is outlined and partially separated, it is seized from the dorsum of the hand with strong bone-forceps, and, while being twisted from side to side, its lateral attachments are severed as close to the bone as possible, and its palmar attachments as subperiosteally as possible, and removed. The most convenient order in

which to remove the carpal bones is, scaphoid, semilunar, cuneiform, os magnum, trapezoid, and body of unciform. All are thus freed and removed —except that the pisiform (which is deeply seated and has the attachments of the flexor carpi ulnaris and abductor minimi digiti) is left;—and the unciform process of the unciform bone (which is also deeply seated and has the attachments of the flexor brevis minimi digiti, flexor ossis metacarpi minimi digiti, and anterior annular ligament) should be cut through with bone-pliers and left—and the trapezium (which is rarely diseased and which enters into the important metacarpo-trapezial joint of the thumb, and has the attachments of the abductor pollicis, flexor ossis metacarpi pollicis, flexor brevis pollicis, and anterior annular ligament) should also be left. If any of these be diseased, however, they should be removed. (**5**) The lower ends of the radius and ulna are now freed of periosteum, by following them around from the upper part of the vertical incisions. The soft parts are all then retracted and the ends of the bones protruded through the wound and removed just above the articular cartilages—or, if but little diseased, may be simply gouged without being extensively freed. (**6**) The articular ends of the metacarpals should be gouged, if not much involved—or, if extensively diseased, removed, by being protruded into the wound and a thin slice of bone taken off with a narrow saw. (**7**) Temporary drainage is used—the wound sutured and dressed—and a special splint applied.

Comment.—(1) The subperiosteal method is difficult, but if carefully carried out, no tendons are cut. In the open method the tendons of the extensores carpi radialis longior et brevior are cut—and tendons of the flexor carpi radialis, flexor carpi ulnaris, and extensor carpi ulnaris are in danger of being cut. (**2**) The ends of the radius and ulna may be first disarticulated and sawed, and then the carpal bones removed, if such a course seem more convenient. (**3**) The radial artery and the palmar structures are to be specially guarded.

EXCISION OF THE WRIST-JOINT

BY SINGLE DORSO-RADIAL INCISION—BOECKEL-LANGENBECK OPERATION.

Description.—Same as for the last operation, as to the bones removed—but different in incision of approach.

Position.—As in preceding operation.

Landmarks.—See Incision.

Incision.—Straight incision, between the extensor communis digitorum and extensor indicis, on the inner side, and extensor longus pollicis (extensor secundi internodii pollicis) on the outer side, running close to the outer border of the former—extending from the ulnar border of the dorsal surface of the lower third (or half) of the second metacarpal up over the radius for about 5 cm. (2 inches) above the joint-line (Fig. 289, O, O′).

Operation.—The incision is made carefully, and branches of the radial nerve to the middle finger avoided, if possible. The incision is now deepened toward the second metacarpal, trapezoid, scaphoid, capsule, posterior annular ligament, and radius. In this deeper incision, however, the tendons of the extensor indicis and extensor communis digitorum are retracted when exposed —and the tendons of the extensor radialis longior and extensor radialis brevior are not cut. These latter tendons are isolated and are then freed down to their attachment into the bases of the second and third metacarpals respectively. If the trapezium is to be left, together with the pisiform and unciform

process of the unciform, it is possible, though difficult, to complete the excision without severing these tendons. Otherwise, however, and where the tissues are much infiltrated and bound down especially, these two tendons are detached subperiosteally at their insertion. If not divided, these tendons are shifted from side to side in the subsequent manipulations. If divided, they are sutured back as nearly in their normal positions as possible, at the end of the operation. The remaining steps of the operation—decortication—freeing and excising of the ends of the radius and ulna—removal of the carpal bones—freeing and excising, or gouging, of the ends of the metacarpals—together with the closure of the wound—are all carried out through this single opening, aided by good lateral retraction, just as in Ollier's operation by the double dorsal incisions.

Comment.—The chief objections to the operation are the difficulty of dealing with the bones to be excised without division of the extensores carpi radialis longior et brevior—and damage done to the extensor muscles of the hand, dorsiflexion sometimes being seriously impaired subsequently.

Fig. 290. — Excisions about the Long Bones of the Upper Extremity:—A, Excision of ulna, by long posterior incision; B, Excision of radius, by long externo-dorsal incision; C, Excision of part of diaphysis of humerus, by external vertical incision.

EXCISION OF THE ULNA, IN GENERAL

Surgical Anatomy — Surface Form and Landmarks.—Given under Amputations about the Forearm, pages 307 and 308.

General Surgical Considerations.—The entire ulna, or any portion of its diaphysis, may be removed.

After-treatment.—A long supporting splint for the forearm, with passive movement at the elbow and wrist.

Results.—Satisfactory results have followed the subperiosteal method.

TOTAL EXCISION OF ULNA

BY LONG POSTERIOR INCISION.

Position. — Patient's forearm is pronated and outstretched upon a small table.

Landmarks.—Ulna; elbow- and wrist-joints.

Incision.—In the long axis of the ulna, and placed so as to fall upon its posterior border in the interval between the anconeus and flexor carpi ulnaris above, and between the flexor carpi ulnaris and extensor carpi ulnaris below (Fig. 290, A).

Operation.—Having incised the skin and fascia, the above intermuscular spaces are recognized and followed to the bone—after having sought the dorsal branch of the uinar nerve beneath the flexor carpi ulnaris, about 5

cm. (2 inches) above the wrist-joint, and henceforth guarded it. The periosteum is incised to the bone throughout along the line of incision. The center of bone is then freed of periosteum entirely around its circumference, using a well-curved periosteal elevator. A chain or Gigli saw is now carried between bone and periosteum and the former divided at its center. Each end of the bone is then seized with bone-forceps and, while manipulated, is further freed of periosteum up to and into the capsules of the elbow- and wrist-joints —thus raising a periosteo-capsular covering. Both articular ends are disarticulated—the periosteo-capsular sheath sutured with buried gut stitches—the muscles quilted—the skin-wound closed, except for temporary drainage of the elbow and wrist articulations—and the limb put up upon a long splint.

Comment.—If it be possible to leave one or both articular ends of the bone, it is desirable.

EXCISION OF THE RADIUS, IN GENERAL.

Surgical Anatomy—Surface Form and Landmarks—General Surgical Considerations—After-treatment—Results.—As in the case of the Ulna, page 411.

TOTAL EXCISION OF RADIUS

BY LONG EXTERNO-DORSAL INCISION.

Position.—Patient's forearm lies outstretched and upon its ulnar border, resting on a small table.

Landmarks.—Radius; elbow- and wrist-joints.

Incision.—In long axis of radius, and placed so as to fall upon its externo-dorsal aspect, in the groove between the supinator longus and extensor carpi radialis longior (Fig. 290, B).

Operation.—Having incised the skin and fascia, this intermuscular space is identified and followed to the bone—after having sought the radial nerve beneath the supinator longus and henceforth guarded it. The periosteum is incised to the bone throughout. The insertion of the pronator radii teres is raised from the bone with the periosteum and turned forward. The supinator brevis is bisected vertically, the anterior half being displaced forward with the radial nerve, the posterior half backward with the posterior interosseous nerve. The bone is now freed of its periosteum entirely around its circumference at its center, using a fully curved periosteal elevator. A chain or Gigli saw is passed between bone and periosteum and the former divided. Each end of the bone is then seized with bone-forceps—and the operation completed as in the corresponding operation upon the ulna (page 411).

Comment.—Same as for the Ulna (page 412).

EXCISION OF ELBOW-JOINT.

Surgical Anatomy—Surface Form and Landmarks.—Given under Disarticulation at the Elbow, pages 312 and 313.

General Surgical Considerations.—(1) Excision of the elbow-joint consists in the removal of the lower end of the humerus and the upper ends of the radius and ulna. (2) It is difficult, if not impossible, to save the periosteo-capsular sheath intact. (3) Partial excisions may be done—of the articular ends of either humerus, radius, or ulna. (4) The brachialis anticus

is inserted into the ulna beyond the coronoid process,—and the triceps into the sides as well as the tip of the olecranon, and thence into the deep fascia of both sides of the forearm, especially on the inner side. Therefore as little of these parts is to be sacrificed as possible. The preservation of the bands of fibers continued from the triceps to the fascia of the forearm is important in excising the elbow, as the power to extend the limb is thereby preserved in part. For the relation of the triceps and brachial anticus to the movements of the forearm, see Movements of the Elbow-joint, page 313. **(5)** The ulnar and posterior interosseous nerves are to be especially guarded in these operations.

After-treatment.—A special jointed splint is indicated that will hold the forearm and arm at any angle to each other, with the power to change the angle without removing the splint. The limb is at first put up at an angle of 135 degrees, with the forearm midway between pronation and supination, the ends of the bones being about 1.3 cm. (½ inch) apart, and the fingers free. Where ankylosis is feared (as in children and after the subperiosteal method), or where much bone has been removed, the limb may be put up at a right angle from the start.

Results.—Satisfactory, as a rule. Ankylosis is likely to follow if the sawed ends are kept in contact—and a flail limb, if kept too far apart. There is generally a tendency to the posterior displacement of the bones of the forearm.

Best Methods.—Posterior Median Incision (Langenbeck). Posterior Bayonet-shaped Incision, with or without an additional Ulnar Incision (Ollier). The Radio-ulnar Articulation may be excised by a Posterior Vertical Incision.

Other Methods.—Dorso-radial Angular Incision (Kocher). Lateral Radial and Ulnar Incisions (Hueter). H-shaped Incision (Moreau). Posterior Angular Incision (Nélaton).

EXCISION OF ELBOW-JOINT

BY POSTERIOR MEDIAN INCISION—LANGENBECK'S OPERATION.

Position.—Patient supine, near edge of table. Assistant on side of table opposite to surgeon, holding the operated limb by the wrist and forearm, with patient's forearm across his (the patient's) chest, so that the arm is vertical and the forearm horizontal (nearly at a right angle to the arm)—thus throwing the flexed elbow prominently out toward the surgeon, with the ulna and olecranon uppermost. Surgeon stands to outer side of elbow, on the involved side, and cuts from the forearm toward the arm.

Landmarks.—Lower end of humerus; elbow-joint; upper ends of radius and ulna.

Incision.—About 10 cm. (4 inches) in length, in the long axis of the limb, passing directly over the center of the humerus, olecranon fossa, olecranon process, and posterior crest of ulna—half of the incision being above the tip of the olecranon and half below (Fig. 291, A).

Operation.—(1) This incision is made at once directly through soft parts, periosteum, and capsule to the bone—and, in the above position, will pass from above downward, from the forearm over the olecranon and onto the arm—bisecting the triceps tendon, incising the capsule and passing through the muscular portion of the triceps onto the humerus. (2) The incision is at once deepened to the bone throughout—efficient retraction of

the lips of the wound being very important for the ease of the subsequent steps. The periosteal elevator, of various curves, and the rugine, should closely hug the many irregularities about the joint-structure—raising up the periosteum and the periosteo-capsular sheath with the attachments of the ligaments undisturbed. The surgeon's left thumb aids in the separation, while the knife is used as sparingly as possible—the object being to peel the bones bare of all soft parts, including periosteum. (3) The inner aspect of the wound is first freed. The inner half of the triceps tendon is freed from the olecranon—especial care being observed and the bone being very closely hugged in freeing the groove between the olecranon and internal condyle, that the ulnar nerve may not be wounded. The internal lateral ligament is freed from the humerus and ulna, and, with it, the common origin of the flexor muscles, together with the periosteum. (4) The outer aspect of the wound is next freed. The outer half of the triceps tendon is separated from the olecranon, with especial care that its expansion into the deep fascia of the forearm be not severed. The anconeus, the continuation of the outer portion of the triceps, is similarly separated. The external lateral ligament, and, with it, the common origin of the extensor muscles, are separated from the external condyle, together with the periosteum. The supinator brevis is freed from the external condyle and ulna and turned forward, especially guarding the interosseous nerve between its superficial and deep portions. (5) The bones are now everywhere free except upon their anterior surfaces. The articular end of the humerus is generally first removed. The patient's hand, of the involved side, is placed prone upon the table near his head, and firmly held there, while steadying the forearm in an upright position—while an assistant steadies the arm midway between a vertical and horizontal. By firmly drawing the soft parts downward (toward the shoulder) the assistant protrudes the lower end of the humerus upward. Its anterior surface is now sufficiently cleared—and, while the articular end is steadied with lion-jaw forceps, and the soft parts retracted with spatulæ or retractors, the bone is sawed at a right angle to its axis and generally on a level just below the tips of the condyles, or at whatever height may be indicated. (6) The articular ends of the radius and ulna are now removed. By drawing down (toward the wrist) the soft parts from the radius and ulna, while held in the above almost vertical position, their articular ends are made to protrude, and are freed as far as necessary on their anterior surfaces, care being taken that the attachment of the brachialis anticus is not entirely freed from the coronoid process. The olecranon is seized and

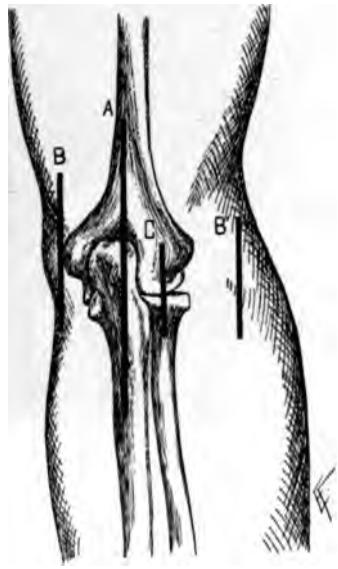

Fig. 291.—EXCISIONS ABOUT ELBOW: —A, Excision of elbow-joint, by posterior median incision (Langenbeck's operation); B, B', Excision of elbow-joint, by radial and ulnar lateral incisions; C, Excision of superior radio-ulnar articulation, by posterior vertical incision.

steadied with forceps, the soft parts well retracted, and the articular end of the olecranon sawed off horizontally to its base, the section including a thin slice from the articular end of the radius. (7) The wound in the periosteo-capsule is sutured with buried gut stitches. The muscles are quilted, also by buried gut sutures. The wound is closed, with temporary drainage provided—and dressed upon a special splint previously provided. (See After-treatment, page 413.)

Comment.—(1) Avoid injury to the ulnar and posterior interosseous nerves. (2) Do not completely detach the insertions of the brachialis anticus and triceps from all their neighboring attachments, as such attachments preserved greatly aid flexion and extension. (3) The biceps insertion is also to be strictly guarded, but is not so much in danger as the others mentioned. (4) Freer access may be given to the articulation by an earlier division of the olecranon. (5) Partial excision of the articular end of the ulna may be readily done through the posterior median incision.

EXCISION OF ELBOW-JOINT

BY POSTERIOR BAYONET-SHAPED INCISION, WITH OR WITHOUT AN ADDITIONAL SHORT VERTICAL ULNAR INCISION—OLLIER'S OPERATION.

Description.—The operation can usually be completed through the bayonet-shaped incision alone. Where insufficient access is thereby given, a short vertical ulnar incision may be added.

Position—Landmarks.—As in the above operation.

Incisions.—(1) Bayonet-shaped incision—the upper part of the incision is vertical, practically parallel with the axis of the humerus, placed in the groove between the triceps and supinator longus, and extends from about 5 cm. (2½ inches) above the joint-line to the tip of the outer condyle,—the middle portion is oblique, placed between the outer head of the triceps and anconeus, and extends from the tip of the outer condyle obliquely downward and inward to the base of the olecranon,—the lower portion is again vertical, placed over the posterior border of the olecranon and extends from the base of the olecranon down the forearm for about 4 to 5 cm. (1½ to 2 inches). (2) Ulnar incision (when used)—is a vertical incision of about 5 cm. (2 inches) and is placed over the lateral aspect of the internal condyle. It is resorted to in order to secure more working-room, especially in cases of disease (Fig. 292, A and B).

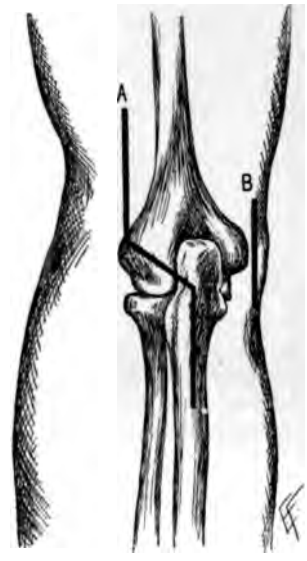

Fig. 292.—EXCISIONS ABOUT ELBOW: — A, Excision of elbow-joint, by bayonet-shaped incision (Ollier's operation); B, Ulnar incision, added to bayonet-shaped incision, if needed.

Operation.—(1) The above incision is at first only superficial. The intermuscular planes above indicated are identified and in these planes the incision is carried to the bones, through the periosteum and periosteo-capsular sheath. (2) Through this wound, by means of rugine and periosteal elevator, are detached, subperiosteally, the triceps insertion, external lateral ligament,

common origin of extensor muscles and insertion of brachialis anticus, and the olecranon and border of the sigmoid cavity are decorticated and the head of the radius exposed. (3) Through the same wound—or through the additional ulnar incision, if necessary—the internal lateral ligament and common origin of flexor tendons are freed, and the internal condyle decorticated, special care being taken of the ulnar nerve in the groove between the olecranon and internal condyle. (4) Disarticulation is now accomplished. The articular ends of ulna and radius are thrust outward, freed to the desired extent, if not already so (being careful to preserve the greater part of the attachment of the brachialis anticus), steadied with forceps and sawed horizontally through at the base of the olecranon, including a slice of the radius. The articular end of the humerus is similarly treated. (5) The periosteo-capsular sheath is sutured—the muscles quilted—temporary drainage established—the wound closed—and the part dressed upon a special splint.

Comment.—(1) The disadvantages of this method are, that the external expansion of the triceps tendon is cut; the anconeus atrophies (for the nerve to it comes from that branch of the musculospiral which supplies the outer head of the triceps and is cut in the oblique portion of the incision); and the ulnar nerve is less easily kept from harm. (2) Partial excision (of the articular ends of humerus, ulna, or radius) may be done through part of Ollier's incision.

EXCISION OF SUPERIOR RADIO-ULNAR ARTICULATION

BY POSTERIOR VERTICAL INCISION.

Description.—An operation sometimes done for unreduced dislocation of the head of the radius.

Position.—As in excision of the elbow-joint by the posterior median incision.

Landmarks.—Elbow and radio-ulnar articulations.

Incision.—Vertical, about 5 cm. (2 inches) in length, with its center over the radio-ulnar articulation, and placed behind and over the posterior part of the supinator longus (Fig. 291, C).

Operation.—Incision passes through skin and fascia. The supinator longus is recognized and is either slightly displaced, the incision passing along its posterior border—or the incision passes directly through its posterior fibers and upon the supinator brevis. This latter muscle is then carefully divided over the head of the radius, preferably in the direction of its fibers (guarding the posterior interosseous nerve between its two layers, and also the musculospiral nerve and the biceps tendon). The orbicular ligament is now severed—the parts well retracted—the head exposed and removed with a Gigli or other saw. The musculo-periosteo-capsular structures are sutured with buried gut stitches—the muscles quilted—the wound closed—and the elbow dressed upon a special splint.

EXCISION OF HUMERUS.

Surgical Anatomy—Surface Form and Landmarks.—Given under Amputations about the Arm, pages 317 and 318.

General Surgical Considerations.—The entire humerus has been excised subperiosteally, followed by a useful arm. Generally, however, only portions of the shaft are excised. The operation for its entire removal will

be described—any portion of the incision being available for the removal of special portions of the bone. The result of the operation, even of a portion of the bone, is often a flail and useless limb.

EXCISION OF HUMERUS

BY LONG EXTERNAL INCISION.

Position.—Patient is turned partly upon his side and the arm so placed as to expose its external aspect.

Landmarks.—Pectoro-deltoid groove; external bicipital sulcus.

Incision.—So placed as to lie between the deltoid and pectoralis major above—and along the external bicipital sulcus below (Fig. 290, C, where incision for partial excision is given).

Operation.—The incision is carried through skin and superficial fascia, and is then carefully deepened between the soft parts, through the periosteum, to the bone throughout. The deltoid fascia is incised and the groove between the deltoid and pectoralis major opened up by retraction—the bicipital fascia incised—and the humerus reached along the outer border of the coraco-brachialis and brachialis anticus. Avoid, by retraction, the acromial thoracic and cephalic vessels in the pectoro-deltoid groove—the circumflex vessels and nerve at the surgical neck—the musculospiral nerve and superior profunda artery to the outer side of the middle of the shaft—and the musculo-cutaneous nerve between the biceps and brachialis anticus in the lower third of the arm. The bone is freed subperiosteally, the insertions of the tendons being raised with the periosteum. The entire circumference of the bone is freed at its center. A chain or Gigli saw is then passed between periosteum and center of humerus and the bone divided—after which either end is grasped by bone-forceps and cleared toward either articulation. The articular ends are disarticulated in a manner similar to the disarticulation in the excision of a joint—except that the ends of the bones are approached from the shaft. The long musculo-periosteal sheath of the diaphysis, and the musculo-periosteo-capsular sheaths of the articular ends, are united with buried gut sutures—the muscles quilted—temporary drainage established at the joint-ends—and the wound closed. The limb is dressed in a long rigid splint, which includes both shoulder and elbow. (See end of preceding page.)

EXCISION OF SHOULDER-JOINT.

Surgical Anatomy—Surface Form and Landmarks.—Given under Disarticulation at the Shoulder-joint, pages 323 and 324.

General Surgical Considerations.—Excision of the shoulder-joint consists in the removal of the articular end of the humerus, with gouging, only, of the glenoid fossa—no part of the scapula being removed with a saw. The subperiosteal method is especially desirable, the best results attained having followed this method.

After-treatment.—The sawed end of the humerus is held in contact with the glenoid fossa, the arm being bound to the side, an axillary pad intervening, and the weight of the extremity being supported by a sling. The axillary pad is important in keeping the head of the bone from being drawn under the coracoid process, which is more likely when the external rotators have been cut and the pectoralis major and latissimus dorsi act unopposedly.

Passive movements should begin as soon as acute inflammation subsides—abduction being the last movement, as it displaces the head inward.

Results.—All movements are to be expected, except abduction beyond a right angle. Weights may also be lifted.

Best Methods.—Anterior Oblique Incision (Baudens, Hueter, and Ollier).

Other Methods.—Anterior Vertical Incision (Langenbeck). Posterior Vertical Incision. Deltoid Flap. Anterior Curved Incision. Posterior Curved Incision.

Comparison of Methods.—The anterior oblique method involves the minimum damage to the deltoid muscle, the chief muscle of the shoulder-joint.

Fig. 293.—Excisions about the Shoulder:—A, Excision of shoulder-joint, by anterior oblique incision; B, Excision of shoulder-joint, by anterior vertical incision; C, Excision of clavicle, by long axial incision.

EXCISION OF SHOULDER-JOINT

BY ANTERIOR OBLIQUE INCISION.

Position.—Patient supine, near edge of table, shoulders raised, arm slightly abducted. Surgeon to outer side of both shoulders. Assistant supports limb.

Landmarks.—Coracoid process; pectoro-deltoid groove; shoulder-joint.

Incision.—Begins just to outer side of tip of coracoid process and passes obliquely downward and outward along the anterior border of the deltoid for 9 to 10 cm. (3½ to 4 inches) (Fig. 293, A).

Operation.—(1) This incision passes, at first through skin and fascia, from the coraco-acromial arch to its lower end. The pectoro-deltoid groove is then demonstrated. The cephalic vein and pectoral muscle are drawn inward—the deltoid outward. The biceps tendon is identified, its sheath opened, and the contained tendon drawn inward. The incision is continued in the original line through the capsule into the joint just to the outer side of this tendon, and through the periosteum onto the humerus. (2) The outer lip of the wound is now cleared. The periosteum, capsule, muscular and tendinous insertions are separated by rugine and periosteal elevator as one continuous layer. An assistant depressing the elbow and rotating the humerus inward, brings the greater tuberosity into the wound, and the insertions of the supraspinatus, infraspinatus, and teres minor are cleared. (3) The inner lip of the wound is similarly cleared. By depressing the elbow and rotating the humerus outward, the lesser tuberosity is brought into the wound. The biceps tendon is now drawn out and the insertion of the subscapularis is separated. (4) The head of the humerus is then disarticulated by depressing the elbow and thrusting the head forward through the retracted wound, while the biceps tendon is drawn inward. The neck of the bone is now cleared posteriorly, hugging the bone carefully to avoid damage to the circumflex vessels and nerve. After disarticulation, the head of the humerus is steadied by lion-jaw forceps and sawed, the section passing from without and slightly downward and inward, the surgeon so standing, on both sides, as to grasp the limb with his left hand distally to the saw-cut, while the soft parts are well retracted by an assistant. Following the section, the margins of the sawed bone may be rounded slightly. The humerus is sawed between the attachments of the pectoralis major, latissimus dorsi and teres major below, and the muscles of the tuberosities above—the section being as high as possible. (5) The glenoid cavity is gouged thoroughly with a sharp spoon, and the capsule of the joint is scraped, if indicated. (6) Temporary drainage is provided through a posterior opening. The head of the bone is drawn into place—the periosteo-capsular wound is sutured with buried gut stitches—the muscles quilted—and the wound closed.

Comment.—(1) The capsule should not be cut transversely, if avoidable. (2) All the muscles, tendons, and ligaments should be raised attached to the periosteo-capsular covering. (3) The head of the bone may be, less advisably, divided *in situ* by means of a chain or Gigli saw.

EXCISION OF CLAVICLE.

Surgical Anatomy.—Anteriorly;—supraclavicular nerves and vein connecting cephalic and external jugular veins cross the antero-superior surface of the clavicle. Inferiorly;—axillary vessels and brachial plexus rest upon the first rib, under the clavicle, the subclavius muscle and dense fascia intervening. Posteriorly;—omohyoid, scalenus anticus, scalenus medius, scalenus posticus, sternohyoid, and sternothyroid muscles; subclavian, suprascapular, and internal mammary arteries; innominate, subclavian, and external jugular veins; brachial plexus, phrenic and posterior thoracic nerves; pleura, apex of lung, and thoracic duct.

General Surgical Considerations.—The clavicle may be removed in whole or in part—or the sternoclavicular or acromioclavicular joints may be separately excised.

TOTAL EXCISION OF CLAVICLE

BY LONG AXIAL INCISION.

Position.—As for ligation of third part of subclavian artery, page 54.

Landmarks.—Clavicle; acromioclavicular joint; sternoclavicular joint.

Incision.—Along the antero-superior surface, following the curve of the bone and extending beyond both sternoclavicular and acromioclavicular joints (Fig. 293, C).

Operation.—The incision passes directly through skin, platysma, supraclavicular nerves, fascia, and periosteum to bone. Once within the periosteum, this membrane is completely detached with a fairly sharp, curved periosteal elevator, together with the attached muscles and coracoclavicular ligament. The clearing is first completed entirely around the center of the bone, and at this point the bone is divided with a chain or Gigli saw conducted between bone and periosteum. Each end is then grasped in turn with bone-forceps and drawn outward—the remaining portions of periosteum being freed to the articular ends while the bone is thus held. The outer end is first removed and then the inner—especially guarding the important structures near the latter. The knife and periosteal elevator, or rugine, hug the bone throughout the entire operation, the soft and important parts being protected by spatulæ. The musculo-periosteal sheath is closed as usual, and the wound closed. The arm is put up as in the case of fractured clavicle.

Comment.—The safety of the operation and the freedom from hemorrhage will depend upon the nearness with which the subperiosteal method is followed out. The chief dangers are the wounding of the structures beneath and behind the clavicle (v. Surgical Anatomy, page 419). Any portion of the clavicle may be removed through a corresponding part of this incision.

Excision of Sternoclavicular or Acromioclavicular Joints.—In excising the sternoclavicular or acromioclavicular articulations, disarticulation is first accomplished—the inner or outer end of the clavicle, as may be, is then elevated sufficiently to slip the Gigli saw beneath—it is then removed, and the sternum or acromion gouged. The bone is closely hugged in these operations, especially when working near its inner end.

EXCISION OF SCAPULA.

Surgical Anatomy.—The chief arteries in the neighborhood of the scapula are the following:—suprascapular, crossing the ligament of the suprascapular notch; posterior scapular, along the vertebral border; subscapular branch of axillary, along the inferior border of the subscapularis; dorsalis scapulæ branch of subscapular, crossing the axillary border; acromial branches of acromial thoracic, about the acromial process. The surgical neck of the bone is marked off by a line from the suprascapular notch through the great scapular notch.

General Surgical Considerations.—(1) The scapula may be removed in whole or in part. The parts usually separately removed are, the acromion, part of the spine, and part of the lower angle. (2) The glenoid, acromion and coracoid processes are to be saved when possible. (3) The chief danger is from hemorrhage. The chief difficulty is in the detachment of the muscles. (4) Temporary drainage is indicated. (5) The excision is generally by the open method. The subperiosteal method is scarcely practicable, and is generally not indicated, as well.

After-treatment.—A pad is placed in the axilla to keep the head of the humerus out. The arm is pushed up so that the head is in its natural position and steadied against the chest—and held there by a sling for three or four months. Passive movement is used in about three weeks.

Results.—A very useful limb often results—capable of all underhand, but no overhand, movements, and of lifting weights.

TOTAL EXCISION OF SCAPULA

BY STRAIGHT INCISIONS ALONG SPINE AND VERTEBRAL BORDER, FORMING SUPERIOR AND INFERIOR FLAPS.

Position.—Patient on sound side, near edge of table, with back to operator. Surgeon behind both scapulæ. One assistant compresses subclavian artery. Another assistant retracts flaps.

Landmarks.—Bony prominences and outlines of scapula.

Incisions.—Vertebral Incision—passes parallel with and just to outer side of vertebral border, from superior to interior angle. Spinal Incision— begins over acromioclavicular joint and passes thence along acromion and spine to junction with vertebral incision, meeting it at almost a right angle. (Fig. 294, C, C′, and B, B′.)

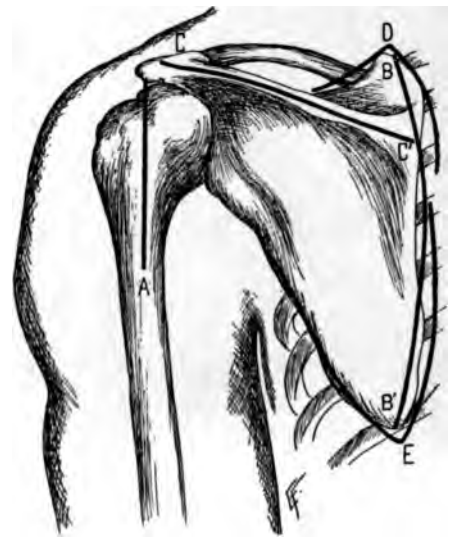

Fig. 294.—EXCISIONS ABOUT THE SHOULDER AND SCAPULA:—A, Excision of shoulder-joint, by posterior vertical incision; B, B′, Vertebral incision, in total excision of scapula by vertebral and spinal incisions; C, C′, Spinal incision, in total excision of scapula by vertebral and spinal incisions; D, V-shaped incision, for excision of superior angle of scapula; E, V-shaped incision, for excision of inferior angle of scapula.

Operation.—(1) These incisions pass through skin and fascia. Raise the superior flap, dividing the trapezius along the upper border of the spine. (2) Raise the inferior flap, dividing the deltoid along the lower border of the spine. (3) Render the vertebral border prominent by drawing the patient's arm across his chest and divide the muscles along that border (levator anguli scapulæ, rhomboidei minor and major)—then further drawing the vertebral border outward, divide the serratus magnus. Ligate the posterior scapular artery near the superior angle. (4) Clear the superior border, severing the omohyoid and ligating the suprascapular artery near the suprascapular notch—the arm still being held across the chest. (5) Render the angle of the shoulder prominent by drawing the arm downward—open the acromioclavicular joint—sever any remaining portions of the deltoid and trapezius—and cut the conoid and trapezoid ligaments as near the clavicle as possible. (6) Manipulate the arm so as to bring the coracoid process as far as possible into the wound made by separating the acromion from the clavicle, and sever the insertion of the biceps, coracobrachialis and pectoralis minor. (7) Divide the capsule and the muscles surrounding it (supra-

spinatus, infraspinatus, and subscapularis)—and also the scapular head of the biceps at the upper part of the glenoid fossa, and the scapular head of the triceps at the lower part of the glenoid fossa. (8) Divide the remaining muscles connecting the axillary border of the scapula to the arm, the teres major and minor, cutting these muscles from in front—seizing and tying the subscapular artery proximal to the origin of the dorsalis scapulæ. (9) The deeper muscles, the supraspinatus, infraspinatus, and subscapularis, are removed with the bone—except that their tendons of insertion into the humerus are left. Drop the flaps into place and suture their margins. Temporary drainage should be used, as oozing is apt to be marked.

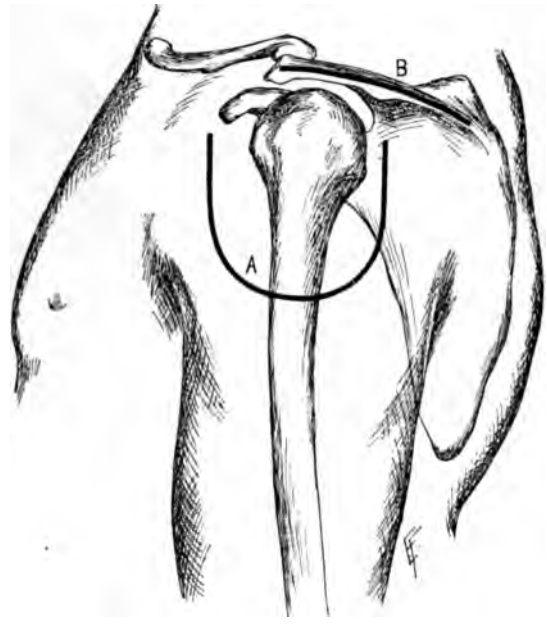

Fig. 295.—Excisions about Shoulder and Scapula:—A, Excision of shoulder-joint, by deltoid flap; B, Incision for excision of acromion and spinous process of scapula.

Comment.—If necessary, the subclavian may be compressed through an incision. The chief vessels, however, may be ligated in advance of incisions for the flaps, that is, before the beginning of the operation proper—but can generally be taken up during the operation, before actually cutting them.

Partial Excisions of the Scapula.—The acromion process may be excised through an incision placed centrally over its prominent contour (Fig. 295, B). The angles of the bone may be removed by V-shaped incisions (Fig. 294, D and E). The body of the scapula is excised through practically the same incisions as are used for the total excision.

EXCISIONS OF BONES AND JOINTS ABOUT THE TOES.

Surgical Anatomy—Surface Form and Landmarks.—Given under Amputations about the Toes, pages 333 and 334.

General Surgical Considerations.—The same general principles apply in excisions about the toes as in excisions about the fingers. The details of the various excisions about the toes will, therefore, not be separately given. Besides, excision of the parts of the toes is quite rare—amputations generally being done instead. This applies to all the toes except the great toe—with reference to which it may be understood that most of the following operations apply.

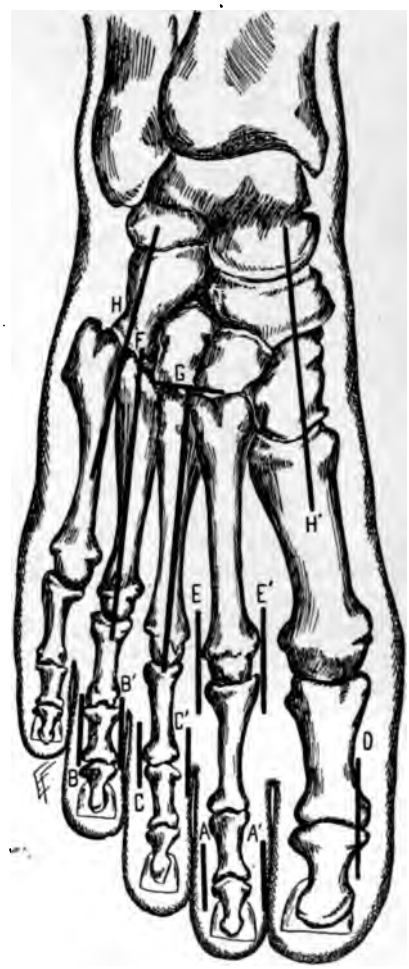

Fig. 296.—EXCISIONS ABOUT THE FOOT:—A, A', Excision of second phalangeal joint by two dorsal incisions; B, B', Excision of second phalanx, by two dorsal incisions; C, C', Excision of first phalangeal joint, by two dorsal incisions; D, Excision of first phalangeal joint of great toe by dorso-internal incision; E, E', Excision of metatarso-phalangeal joint by two dorso-lateral incisions; F, Excision of metatarsal, by dorsal incision; G, Excision of metatarsal by dorsal incision, with additional angular incision; H, H', Osteoplastic resection of anterior tarsus and tarso-metatarsus, by internal and external dorso-lateral incisions.

EXCISION OF TERMINAL PHALANX OF TOES.

Best Method.—U-Shaped Plantar Incision.

Description.—As for the terminal phalanx of finger, page 403.

EXCISION OF SECOND INTERPHALANGEAL JOINT OF TOES.

Best Method.—Two Dorso-lateral Incisions.

Description.—As for the second interphalangeal joint of the fingers (page 403)—except that the incisions are here more dorsal than lateral. (Fig. 296, A, A'.)

EXCISION OF SECOND PHALANGES OF TOES.

Best Methods. — Two Dorso-lateral Incisions—for toes in general. U-shaped Palmar Incision — for great toe.

Description.—As for the second phalanx of the fingers (page 405)—or of the thumb (page 403). (Fig. 296, B, B'.)

EXCISION OF FIRST INTERPHALANGEAL JOINT OF TOE.

Best Method.—Two Dorso-lateral Incisions—for toes in general. Dorso-internal Incision—for great toe.

Description.—As for the first interphalangeal joint of the fingers (page 406)—or of the thumb (also page 406). (Fig. 296, C, C'.)

EXCISION OF FIRST PHALANX OF TOE.

Best Methods.—Dorso-internal Incision—for great toe. Two Dorso-lateral Incisions—for toes in general, if done at all.

Description.—As for the first phalanx of the fingers in general, if done at all (page 406)—or for the thumb (also page 406).

EXCISIONS OF BONES AND JOINTS ABOUT THE FOOT.

Surgical Anatomy—Surface Form and Landmarks.—Given under Amputations and Disarticulations about the Foot (pages 344 to 347).

General Surgical Considerations.—(1) The general features of excisions of the metatarsals are the same as of excisions of the metacarpals. (2) Individual metatarsal bones are not frequently excised. That of the great toe is the one most often excised. (3) The sesamoid bones are left *in situ*, as in the hand. (4) The chief tarsal bones systematically excised are the os calcis and astragalus. Other portions of the tarsus are excised as indicated. And other tarsal bones are wholly or partially excised in such operations as those for the deformities about the foot.

EXCISION OF METATARSO-PHALANGEAL JOINTS.

Best Methods.—Two Dorso-lateral Incisions—for the toes in general. Dorso-internal Incision—for the great toe.

Description.—As for the metacarpo-phalangeal joint of the fingers, in general (page 406)—or of the thumb. (Fig. 296, E, E′.)

EXCISION OF THE METATARSAL BONES.

Best Methods.—Dorsal Incision—for toes in general. Dorso-internal Incision—for great toe.

Other Methods.—Interno-plantar Flap—for great toe.

Description.—As for the metacarpal bones by dorsal incision (page 407)—or of the metacarpal of the thumb by dorso-external incision (page 408) (Fig. 296).

EXCISION OF ASTRAGALUS

BY EXTERNAL CURVED INCISION.

Position.—Patient supine, foot resting on inner side. Surgeon on side of operation. Assistant steadies foot and leg.

Landmarks.—Fibula; astragalus; base of fifth metatarsal.

Incision.—Begins about 7.5 cm. (3 inches) above ankle, at anterior border of fibula—passes vertically downward external to peroneus tertius and musculocutaneous nerve—and curves thence forward over outer surface of astragalus to base of fifth metatarsal (Fig. 297, A).

Operation.—Having incised skin and fascia, retract the peroneus tertius inward and extensor brevis digitorum outward. In the interval thus left, incise the capsule of the ankle-joint and open the medio-tarsal joint. Free the neck of the astragalus and the lower ends of the tibia and fibula. Divide

the calcaneo-astragaloid ligament and anterior and posterior bands of the external lateral ligament. Run along the outline of the astragalus at its junction with the os calcis and scaphoid with a stout knife. Invert the foot forcibly and, while in this semidislocated position, free the inner surface of the astragalus, using special care near the posterior tibial vessels and nerve. The astragalus is now grasped with bone-forceps and removed—severing any further binding ligaments which may hold it, while under tension. The leg then drops down upon the upper surface of the os calcis. The soft parts are brought together with deep and superficial sutures—the deep sutures being of chromic gut and including as much fibrous tissue as possible. Temporary drainage is used—and the foot is put up at a right angle to the leg.

Comment.—Excision of the astragalus by the external curved incision is preferable where the unyielding condition of the tissues does not require two lateral incisions, as in the following operation.

EXCISION OF ASTRAGALUS

BY EXTERNAL ANGULAR AND INTERNAL CURVED INCISION.

Description.—The bone is most easily removed from the outer aspect—the bone being approached between the tendons of the tibialis anticus and tibialis posticus, on the inner side—and, on the outer side, between the tendons of the peroneus tertius and peroneus brevis. The operation is done by the open method.

Position.—Patient supine, foot extending over edge of table and turned to face inward and upward for inner incision and outward and upward for outer incision. The surgeon stands facing the foot. The assistant steadies leg and toes.

Landmarks.—Inner and outer malleoli; articular border of tibia; astragalo-scaphoid joint; astragalo-calcaneal joint.

Incisions.—(1) External Angular Incision;—The Vertical portion begins just above the level of the articular border of the tibia, on its antero-external aspect, and passes downward between the tendons of the peroneus tertius and peroneus brevis, parallel with and just behind the former tendon, for about 6 cm. (2½ inches), and ends over the cuboid bone;—the Horizontal portion, shorter, is at a right angle to the vertical portion, beginning about its center and passing backward and slightly downward, ending just below the tip of the external malleolus. (2) Internal Curved Incision;—begins just above the level of the articular surface of the tibia, on its antero-internal aspect, and passes down immediately in front of the anterior margin of the tibia to slightly below the tip of the internal malleolus, whence it curves backward and ends just below the center of the internal malleolus. (Fig. 297, B, and Fig. 298, C.)

Operation.—(1) These incisions first pass through skin and fascia only. (2) The outer incision is then deepened first, and the two rectangular flaps turned back and the antero-external aspect of the astragalus exposed between the tendons of the peroneus tertius and peroneus brevis. Forcibly extend and invert the foot, retracting the tendons, and divide the ligaments between the astragalus, on the one hand, and the fibula, os calcis, scaphoid, and tibia, on the other—as far as can be accomplished from the outer wound. (3) The inner incision is now deepened and the curved flap turned back and the antero-internal aspect of the astragalus exposed between the tendons of the tibialis anticus and posticus. Forcibly extend and evert the foot, re-

tracting the tendons out of the way, and complete the division of the ligaments binding the astragalus to the tibia, os calcis, and scaphoid—as far as can be

Fig. 297.—EXCISIONS ABOUT THE FOOT:—A, Excision of astragalus, by external curved incision; B, External angular incision, in excision of astragalus by external angular and internal curved incisions; C, Excision of os calcis, by horizontal curved and vertical incisions.

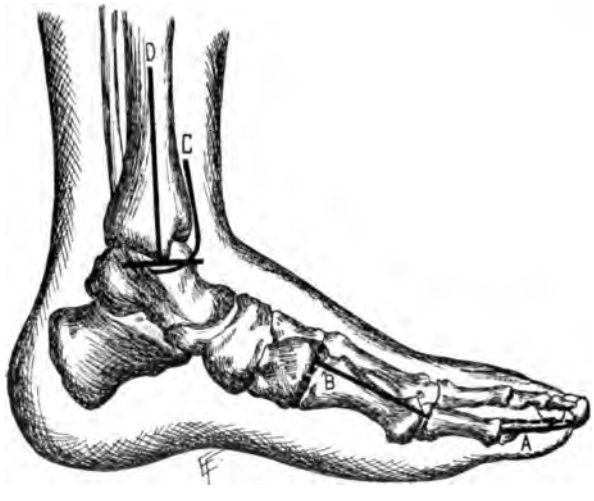

Fig. 298.—EXCISIONS ABOUT THE FOOT:—A, Excision of terminal phalanx by U-shaped palmar incision; B, Excision of metatarsal of great toe, by dorso-internal incision, with or without one or more additional incisions at one or both ends; C, Internal curved incision, in excision of astragalus by external angular and internal curved incisions; D, Internal angular incision, in excision of ankle-joint by external curved and internal angular incisions.

further accomplished from the inner wound. (4) The foot being again firmly extended and inverted, the astragalus is seized with lion-jaw forceps

and strongly whipped out through the outer wound—any remaining connections being severed while on the stretch. (5) Suture the flaps into place—institute temporary drainage—and put up the foot at a right angle to the leg. Prior to suturing the skin-flaps, it is well to apply several buried chromic gut sutures wherever loose portions of fibrous tissue may be brought into contact to strengthen the parts.

Comment.—(1) This excision may be made through simply the vertical portions of these two incisions—by retracting the lips of the wounds and thus reaching the bones. (2) Movement of the ankle-joint is not expected.

Other Methods of Excision.—External Angular Incision. Transverse Incision. Internal and External Vertical Incisions.

EXCISION OF OS CALCIS

BY HORIZONTAL CURVED AND VERTICAL INCISIONS.

Description.—The bone is removed from the postero-external aspect. The operation should be done as subperiosteally as possible.

Position.—Patient lies on sound side with foot supported on inner side and free. Surgeon faces foot. Assistant steadies leg.

Landmarks.—Base of fifth metatarsal; position of posterior tibial vessels; tendo Achillis; calcaneo-cuboid joint.

Incisions.—Horizontal Incision—begins at base of fifth metatarsal—passes horizontally backward, well above the margin of the sole, around the convexity of the heel to its inner side, to a point about 3.2 cm. (1¼ inches) internal to the median line of the heel—stopping well posterior to the posterior tibial vessels and nerve. Vertical Incision—begins about 5 cm. (2 inches) above the horizontal incision, on the outer side of the foot—and passes vertically downward just anterior to the tendo Achillis, and between it and the tendons of the peroneus longus and brevis, and meets the horizontal incision at a right angle. (Fig. 297, C.)

Operation.—(1) These incisions are now deepened and the two small flaps made by them are turned forward and upward, and backward and upward, respectively. (2) The os calcis is exposed behind the peronei tendons and the periosteum incised in the lines of the incisions. By means of a rugine everything is raised from the bone as subperiosteally as possible—on its outer, under, posterior, inner, and upper surfaces, in order. The tendo Achillis is severed and the soft parts and tendons are well retracted during this decortication. (3) The head of the bone is grasped with lion-jaw forceps and is drawn outward—the remaining connections being severed while on the stretch. (4) The flaps are dropped into place and sutured—temporary drainage being established. The foot is put up at a right angle, upon an anterior splint (so as not to exert any undue pressure upon the wound).

EXCISION OF ANKLE-JOINT.

Surgical Anatomy—Surface Form and Landmarks.—Given under Disarticulation at the Ankle, pages 358 and 359.

General Surgical Considerations.—The operation is not frequently performed. Ankylosis results in the majority of cases. The medio-tarsal joint, however, generally takes on considerable compensatory action. Some

shortening results. Sometimes the entire astragalus is removed at the same time.

After-treatment.—The foot is kept at a right angle to the leg in a fixed splint—and in the same straight line with the leg. Although ankylosis is sought by some surgeons, movement is aimed at by the majority—and passive movements are begun early.

EXCISION OF ANKLE-JOINT

BY TRANSVERSELY CURVED EXTERNAL INCISION—LAUENSTEIN'S OPERATION.

Description.—The joint is exposed through a single external incision, and the articular surfaces of the bones brought into the field by disarticulation accomplished by forcible temporary inversion of the foot.

Position.—Patient midway between supine and lateral positions; foot resting upon inner side. Surgeon stands behind heel to make incision, and faces foot to complete operation. Assistant steadies leg.

Landmarks.—Ankle and astragalo-scaphoid joints; peroneus tertius tendon; external malleolus; tendons of peroneus longus, brevis, and Achillis.

Incision.—Begins on dorsum of foot, midway between ankle-joint and astragalo-scaphoid articulation, and over peroneus tertius tendon—passes nearly horizontally backward below and beyond the outer malleolus—and thence upward between the tendo Achillis, on the one hand, and the tendons of the peroneus longus and brevis, until from 5 to 7.5 cm. (2 to 3 inches) above the joint (Fig. 299, A).

Operation.—(1) The skin and fascia are at first carefully divided. The musculocutaneous nerve is identified and drawn inward. The peroneus tertius tendon and extensor tendons are also displaced inward. The external saphenous vein and nerve are not disturbed posteriorly. (2) The incision is deepened between the retracted extensor tendons and fibula down to the astragalus, dividing the capsule of the ankle-joint back to the external malleolus. The three bands of the external lateral ligament are separated from the outer malleolus. The sheath of the peroneus longus and brevis is carefully incised upward posteriorly to the fibula so that it may be subsequently sutured (the sheaths being separate below the tip of the external malleolus and common above the tip). The tendons are then removed from their sheath and retracted backward. By dividing the peroneal sheath high up the leg and freeing of the tendons, sufficient room may often be gotten for disarticulation without severing the tendons—otherwise these tendons must be cut and subsequently sutured with catgut. (3) The periosteum is now divided over the fibula, and it, together with the peroneal sheath, are separated posteriorly, with as much as possible of the periosteum, from the posterior surface of the fibula and tibia. (4) The periosteum is similarly separated from the anterior part of the fibula and anterior surface of the tibia, carrying with it the attachment of the anterior portion of the capsule. The foot is thus freed from its attachments to the outer aspect of the fibula and to the anterior and posterior aspects of the tibia. (5) Forcibly bend the foot inward until disarticulation is so completely accomplished that the inner aspect of the foot rests against the leg and the sole looks upward (toward the crotch), turning upon the internal lateral ligament as a hinge—the ligament being preserved, if possible. All the joint surfaces are thus brought well to view—and no tendons are severed, except as mentioned above. (6) As much of the bones is now removed as indicated. It is especially sought to avoid

sawing off more than the articular surface of the astragalus—and the gouging of the articular surfaces of the tibia and fibula, leaving the malleoli to prevent lateral displacement of the foot. If necessary, however, as much may be removed of the osseous tissues as in the following operation. (7) If the peroneal tendons have been severed, these are now sutured with chromic gut —replaced in their sheath—and the sheath, in any event (whether the tendons have been divided or not), is repaired by chromic gut suturing. Temporary drainage is used—the wound closed—and the foot put up at a right angle.

EXCISION OF ANKLE-JOINT

BY EXTERNAL CURVED AND INTERNAL ANGULAR INCISIONS.

Position.—Patient rests midway between side and back, so as to bring

Fig. 299.—EXCISIONS ABOUT THE FOOT:—A, Excision of ankle-joint by transverse curved external incision; B, External curved incision, in excision of ankle-joint by external curved and internal angular incisions.

inner aspect of foot uppermost during the inner incision, and vice versa; with foot supported. Surgeon faces foot. Assistant steadies limb.

Landmarks.—The lower part of tibia and inner malleolus; lower part of fibula and outer malleolus; tibio-astragaloid joint.

Incisions.—(1) External Incision—(with foot resting on inner aspect) —about 7.5 cm. (3 inches) in length—extends down the antero-lateral aspect of fibula to just below the tip of the outer malleolus—thence curves backward around the external malleolus and passes upward along the posterior border of the fibula for about 2.5 cm. (1 inch) (Fig. 299, B). (2) Internal Incision—(with foot resting upon outer aspect)—about 7.5 cm. (3 inches) in length—extends down inner aspect of tibia to tip of internal malleolus. A second incision may then be added—either a transverse incision meeting the first almost at a right angle, and extending about 1.3 cm. (½ inch) on either side (Fig. 298, D)—or a curved incision passing forward.

Operation.—(1) The outer incision passes down through skin, fascia, and periosteum as far as it lies over the fibula—that portion below the external

malleolus at first passes through skin and fascia alone. The periosteum is now turned forward and backward over the fibula—the external lateral ligament and capsule are split in line with the vertical incision and turned backward and forward with the periosteum. The peroneus longus and brevis tendons are retracted backward. The anterior surface of the fibula, and as much as possible of the anterior surface of the tibia and astragalus, are freed subperiosteally through the outer wound, as well as the posterior surface of the fibula, and as much as possible of the posterior surface of the tibia. (2) The lower end of the fibula is now divided with a chain or Gigli saw, or with a chisel, about 2.5 cm. (1 inch) above its tip—and is grasped by bone-forceps and removed, aided by a touch of the rugine where necessary. (3) The internal incision is made through skin, fascia, and periosteum to bone, where it lies over the tibia—and through skin and fascia; below the tip of the malleolus. The periosteum is similarly freed forward and backward, with the overlying and connected ligaments—freeing, through the inner wound, the outer and remaining portions of the anterior and posterior surfaces of the tibia, and the anterior surface of the astragalus. The internal lateral ligament and capsule are similarly divided vertically and turned forward and backward as part of the periosteo-capsular covering. (4) The anterior and posterior tibial tendons are well retracted while working through the inner incision—and if a lower cross-cut be added to the inner vertical incision, care is taken that it does not extend far enough anteriorly or posteriorly to injure these tendons. (5) The lower end of the tibia is now either divided *in situ* with a chain-saw, or protruded through the inner wound, grasped with forceps, and sawed just above its articular surface. (6) The upper portion of the astragalus is then sawed off with a thin, narrow saw, through the outer wound—or entirely disarticulated and removed, as indicated. (7) The inner and outer wounds are sutured—temporary drainage established—and the foot dressed at a right angle to the leg.

EXCISION OF TIBIA.

Surgical Anatomy—Surface Form and Landmarks.—Given under Amputations about the Leg.

General Surgical Considerations.—Where a subperiosteal excision is done, a very useful limb often results, even after the entire removal of the bone. The articular ends should be left if possible. Any portion of the tibia may be removed through the corresponding part of the following incision.

TOTAL EXCISION OF TIBIA

BY INTERNAL VERTICAL INCISION.

Position.—Patient supine; leg turned outward. Surgeon to outer side of right limb, cutting downward, and vice versa on left.

Landmarks.—Inner aspect of tibia, which is practically everywhere subcutaneous.

Incision.—Passes just in front of the inner border of the entire length of the tibia, from the knee-joint to the ankle joint (Fig. 300, A).

Operation.—The incision passes directly through periosteum to bone—running behind the tendons of the sartorius, gracilis, and semitendinosus above—and the internal saphenous nerve being recognized and retracted

below. Once beneath the periosteum, the shaft of the bone is entirely freed subperiosteally by means of a well-curved periosteal elevator. The periosteum, together with all the muscles and tendons attached, is freed to near the articular ends. A chain or Gigli saw is then passed between the bone and periosteum and the bone divided at its center. Each end of the tibia is grasped in turn, with strong bone-forceps, and drawn outward—during which manœuvre the articular end is freed up to the joint subperiosteo-capsularly —and disarticulated.. The edges of the incision in the periosteum of the shaft, and in the capsules of either end, are now sutured with buried gut stitches. Temporary drainage is instituted at either joint end—the muscles and deep connective tissue quilted together, wherever indicated—the skin wound closed—and the limb put up on a straight splint.

Fig. 300.—Excisions about Long Bones of Lower Extremity:—A, Excision of tibia by internal vertical incision; B, Excision of fibula by posterior vertical incision; C, D, Excision of portions of femur by external vertical incision.

EXCISION OF FIBULA.

Surgical Anatomy — Surface Form and Landmarks.—Given under Amputations about the Leg, pages 362 and 363.

General Surgical Considerations.—(1) The fibula may be removed in whole or in part. (2) Removal of the outer malleolus is apt to be followed by eversion of the foot: A very useful limb, however, generally follows the subperiosteal excision of the bone. (3) The superior tibio-fibular articulation often communicates with the knee-joint —it is, therefore, desirable to leave, if possible, the head of the fibula entirely, or, after cutting it off, gouge out the head, leaving a protective barrier of bone to intervene between the knee-joint. (4) In excising the upper half of the bone alone, a posterior vertical incision (part of the following incision) is used, passing behind the peronei muscles. (5) In excising the lower half alone, an antero-external vertical incision is used, passing in front of the peronei muscles.

EXCISION OF FIBULA

BY POSTERIOR VERTICAL INCISION.

Position.—Patient supine; leg turned well to inner side. Surgeon and assistant stand as in excising the tibia (page 430).

Landmarks.—Outline of fibula; articulations of superior tibio-fibular joint and ankle-joint.

Incision.—Passes the entire length of the bone, from the tibio-fibular articulation to the ankle-joint—running down behind the peroneus longus and brevis muscles, along the posterior aspect of the bone (Fig. 300, B).

Operation.—The above incision is first made through skin and fascia—

and then deepened through periosteum to bone—guarding the external popliteal nerve above, where it winds around the neck of the bone, and the peroneal artery behind the lower half of the bone. The bone is reached, above, between the peroneus longus in front, and soleus, behind—and, below, between the peroneus longus and brevis, in front, and flexor longus hallucis, behind. Once beneath the periosteum, this membrane is raised from the bone in as nearly one layer as possible, and to as near the articular ends of the bone as possible, together with the overlying muscles and tendons still attached. A chain or Gigli saw is then slipped between bone and periosteum and the bone divided in its middle. Each end is then grasped by bone-forceps and drawn outward—and, while so held, is further freed of its periosteum, and, at its articular ends, of its periosteo-capsular covering. The articular ends are then disarticulated at the ankle-joint and at the superior tibio-fibular articulation (see General Surgical Considerations, page 431). Avoid opening into the knee-joint, if possible, and injury to the anterior tibial and musculocutaneous nerves. It is preferable to preserve the upper and lower articular ends *in situ*—making the section just beyond the articulation, unless contraindicated. The long periosteal and peristeo-capsular wound is now sutured with catgut—muscles quilted—temporary drainage instituted, if the articulations have been opened up—the wound closed—and the limb put up on a long splint.

EXCISION OF PATELLA

BY VERTICAL INCISION.

Description.—The patella, which may be considered a sesamoid bone developed in the quadriceps extensor tendon, is simply shelled out of that structure, through a single anterior longitudinal incision, with minimum damage to the surrounding structures, and especially the knee-joint.

Position.—Patient supine; limb extended. Surgeon cuts from above downward on right, and vice versa on left.

Landmarks.—Contour of patella.

Incision.—The incision passes through skin, fascia, prepatellar bursa, quadriceps aponeurotic expansion, and periosteum to bone. Working beneath the periosteum with rugine and curved periosteal elevator, the bone is freed from its soft parts and from the anterior surface of the capsule and thus enucleated. The cut margins of the capsule are now sutured with buried gut stitches—the split quadriceps expansion similarly sutured—the wound closed—and the limb put up in extension.

EXCISION OF KNEE-JOINT.

Surgical Anatomy—Surface Form and Landmarks.—Given under disarticulation at the knee-joint, pages 371 and 372.

General Surgical Considerations.—(1) In excision of the knee-joint, the articular ends of the femur and tibia are removed—the sawed ends of the bones are approximated and firm ankylosis in full extension is sought. (2) The lower epiphysis of the femur is to be saved in the young, if possible. (3) The patella may be left, if healthy—but should be removed, in whole or in part, if diseased. (4) The subperiosteal method of excision is almost impracticable.

After-treatment.—The limb is put up fully extended, and so kept for

one and a half to three months—followed by other support for several months longer. An extra-soled shoe is used for the unavoidable shortening.

Results.—The result is satisfactory where ankylosis in a good position is secured. Flail and useless limbs sometimes occur. There is a tendency of the femur to glide forward. If the whole of the trochlear surface be removed, the epiphysis (the chief source of growth of the lower extremity) will be lost.

Best Method.—Curved Transverse Anterior Incision.

Other Methods.—Anterior U-shaped Flap; Anterior Vertical Incision, with temporary splitting or retraction of patella. Transverse Incision (through patella, or removing patella). Crucial Incisions. H-shaped Incision.

EXCISION OF KNEE-JOINT

BY CURVED TRANSVERSE ANTERIOR INCISION.

Position.—Patient supine, near edge of table, with leg half over end of table. Surgeon on side of operation, or on outer side of right and inner side of left knee. One assistant steadies the thigh—another manipulates the leg. At the beginning of the operation, the knee is slightly flexed, and subsequently bent at a right angle.

Landmarks. — Posterior margins of the femoral condyles; tubercle of tibia.

Incision.—Begins at posterior margin of one femoral condyle (which is about 1.3 cm.—½ inch—above the lowest articular surface) and ends at the posterior margin of the opposite condyle—curving downward in front to midway between the lower margin of the patella and insertion of the ligamentum patellæ (Fig. 301).

Fig. 301. EXCISION OF KNEE-JOINT:—By curved transverse anterior incision.

Operation.—(1) The above incision, made while the knee is slightly flexed, passes through skin and fascia—and is then deepened, cutting through anterior capsule and ligamentum patellæ, thus opening the knee-joint. The division of the ligamentum patellæ at its center will permit of the subsequent suturing of its ends. (2) Turn the patella and its aponeurosis upward—further flex the joint and divide both lateral ligaments and both crucial ligaments. (3) Bend the joint to a right angle, with sole of foot on table and leg supporting thigh. Now clear the femur to the saw-line, retracting the soft parts and guarding the popliteal region. The femur is then sawed (holding the saw vertically) just above the articular line — the antero-posterior section being at a right angle to the shaft of the femur—and the transverse section parallel to the articular surfaces of the condyles. (4) The upper end of the tibia

is now freed while in the vertical position, down to the saw-line—the soft parts retracted—the popliteal region guarded—and the articular end of the tibia sawed off, holding the saw horizontal and parallel with the articular surface. (5) If healthy, the patella may be left. If the articular surface be slightly diseased, the bone is steadied with bone-holding forceps while the articular surface is removed with a saw or chisel, or the diseased bone is gouged away. If badly diseased, it is entirely dissected out. It is often removed, whether healthy or not—but it is better to leave it, if uninvolved. (6) The pouch beneath the quadriceps extensor tendon is opened up and curetted out—and all other synovial recesses similarly treated. (7) The end of the bones are now approximated with extreme care, and retained in position according to the individual ideas of the surgeon (by pegging, wiring, simple suturing of periosteo-capsular sheath and fibrous tissues around the margins of the two ends; or simply by apposition of the ends and the use of a plaster or other splint). (8) If the curved incision have severed the ligamentum patellæ a short distance above the tubercle of the tibia, which is desirable, the cut ends of the ligament are now sutured with chromic gut. (9) Temporary drainage is established from either angle of the wound—the subcutaneous soft parts brought together with buried gut sutures—the skin-wound closed—and the limb put up upon a posterior splint in full extension.

Comment.—(1) Only branches of the articular, anastomotica magna, and anterior tibial recurrent are cut, and rarely require ligature. (2) Much of the ease of the efficient exposure of the joint structures will depend on carrying the limbs of the incision to the posterior margin of the femoral condyles. (3) The posterior ligament is separated from the femur and tibia, in preparing them for the saw—and carefully kept intact throughout the operation, as a barrier to the important popliteal region. (4) The retention of the patella is of no special service, as ankylosis of the joint is sought. If removed, it should be done as subperiosteally as possible, from the articular aspects, to preserve all the overlying tissues, if these be healthy. (5) As little of the femur should be removed as possible, especially in the young. (6) Be on guard for the internal saphenous vein and nerve at the back part of the inner portion of the incision. (7) If the bone sections be not made in the proper planes, the limb may be knock-kneed or bow-legged, accordingly. In such an event, another section of bone should be made, of tibia or femur, or both. The limb should be absolutely straight.

EXCISION OF FEMUR.

Surgical Anatomy—Surface Form and Landmarks.—Given under Amputations about the Thigh.

General Surgical Considerations.—(1) Excision is generally confined to the removal of limited portions of the diaphysis of the femur. But the removal of the entire shaft, subperiosteally, especially in the young, has been followed by the reproduction of bone and a very useful limb.

After-treatment.—In the young, the limb should be under traction to the same length as the other, and held rigidly in a splint. In the old, where only a limited amount of bone is removed and satisfactory reproduction of bone is not likely, the sawed ends are to be approximated, and the shorter limb built up by a shoe on that side, as a solid shorter limb is better than a flail longer one.

EXCISION OF PARTS OF DIAPHYSIS OF FEMUR

BY EXTERNAL VERTICAL INCISION.

Description.—Portions of the entire thickness of the femur, between the articular ends, have been removed with successful result. Also see General Surgical Considerations, page 434.

Position.—Patient on back, turned slightly to one side, to expose outer aspect of thigh. Surgeon stands behind limb, cutting from above downward on right, and vice versa. Assistant opposite surgeon.

Incision.—Down outer side of thigh, in groove between posterior border of vastus externus and biceps—and extending from base of great trochanter to base of external condyle—or part of the way, as indicated—(Fig. 300, C and D).

Operation.—The incision first passes through skin, fascia, and fascia lata. The intermuscular plane just mentioned is identified in the upper portion of the wound and followed to the bone. The transverse terminal branch of the external circumflex artery is encountered above, passing beneath the vastus externus muscle—and the superior external articular artery below, winding around the bone. The incision is carried directly through periosteum to bone. The periosteum is then freed, together with attached muscles and tendons, from the entire circumference of the femur, by means of fully curved rugine and periosteal elevators, especially along the inner and outer lips of the linea aspera. Having freed the center of the shaft, pass a chain or Gigli saw between bone and periosteum—divide the bone—grasp either end with bone-forceps and draw outward—and further free the bone while thus held, as far upward and downward as indicated. Then again pass the chain saw subperiosteally at either end and divide. If feasible, the femur may be freed over the entire length and circumference of the part to be removed, and then a chain saw passed at the upper and lower limits and the bone thus divided but twice. Suture periosteal sheath—quilt the muscles with buried sutures—close the wound—and put the limb up in a rigid, straight splint (v. After-treatment, page 434).

EXCISION OF HIP-JOINT.

Surgical Anatomy—Surface Form and Landmarks.—Given under Disarticulation of Hip-joint, pages 386 and 387.

General Surgical Considerations.—(1) Excision of the hip-joint consists in the removal of the upper end of the femur and scraping of the acetabulum. (2) No tourniquet is necessary—the slight hemorrhage encountered is from small vessels which are controlled as divided. (3) According to some, the section of the bone should, as a rule, be made below the great trochanter, for even where less of the bone is involved, retention of the great trochanter is apt to be followed by harmful pressure. According to other surgeons, as little of the bone should be removed as possible, together with the minimum disturbance of the muscles of the trochanters.

After-treatment.—The limb is kept at absolute rest—in full extension —with the sawed end of the femur slightly separated from the acetabular cavity.

Results.—A movable and useful joint generally follows. Ankylosis or a flail limb is exceptional. Some atrophy generally occurs—and there is always some shortening.

Best Methods.—Anterior Straight Incision (Barker). External Straight Incision (Langenbeck). Posterior Angular Incision (Kocher).

Other Methods.—Curved Retro-trochanteric Incision.

Comparison of Methods.—Each method has its own special indication. The method by external incision is, on the whole, probably the best. The anterior incision does least harm to neighboring structures, dividing no muscles (which the external and posterior incisions do). The posterior incision gives the freest access to the joint and the best drainage.

Fig. 302.—Excision of Knee-joint:—By anterior U-shaped incision.

EXCISION OF HIP-JOINT

BY EXTERNAL STRAIGHT INCISION—LANGENBECK'S OPERATION.

Position.—Patient on sound side; thigh flexed at an angle of 45 degrees and rotated inward. Surgeon to outer side of hip. Assistant, grasping knee and foot, rotates and manipulates the limb as indicated.

Landmarks.—Great trochanter.

Incision.—Begins over the ilium, about 7.5 cm. (3 inches) above the upper border of the great trochanter (which is about opposite the upper margin of the great sacrosciatic notch)—passes downward for 11.5 to 12.5 cm. (4½ to 5 inches) in the long axis of the limb, lying just behind the center of the outer surface of the great trochanter, and ends just below the base

of the great trochanter. (In the above position of the limb, the direction of the incision will be represented by a straight line from the posterior superior iliac spine, passing down the center of the long axis of the limb.) (Fig. 303.)

Operation.—(1) This incision passes, at first, through skin and fascia—then through the gluteus maximus, dividing it, approximately, in the line of its fibers. (2) The gap between the gluteus medius in front, and pyriformis behind, is sought and widened to the joint by retraction—and the capsule of the joint and periosteum of the great trochanter are divided to the bone in the line of the original incision. If necessary, the capsule of the joint is further divided transversely. By means of curved rugine and periosteal elevator, the anterior and posterior capsulo-periosteal flaps are raised, subperiosteally, if possible—or by the open method. (3) The cotyloid ligament is cut by thrusting a stout knife between the head of the bone and the cotyloid ligament and cutting the ligament toward the rim of the acetabulum, and air thus allowed to enter and separate the articular surfaces. In those cases where difficulty is experienced in admitting air to the joint cavity, a small portion of the rim of the acetabulum, with its cotyloid cartilage, may be chiseled away over about 1.3 cm. (½ inch) of the circumference. (4) The muscles attached to the outer and posterior surfaces of the great trochanter are now raised subperiosteally, or severed, while an assistant, grasping the knee and foot, rotates the thigh inward,—and those attached to the anterior surface and lesser trochanter while the thigh is rotated outward. (5) The ligamentum teres is now divided and the head of the bone dislocated backward and outward by depressing the limb (if the thigh partly rests over the end of the table as a fulcrum) and rotating outward. (6) The soft parts are further cleared from the upper end of the femur and retracted. While steadied with bone-holding forceps, the head of the femur is sawed below the great trochanter, with slight obliquity, from above downward, and from without inward. (7) The acetabular cavity is scraped or cleared with a gouge. All synovial recesses are curetted. (8) Temporary drainage is instituted—the capsule sutured—the muscles quilted—the wound sutured—and the limb put up in extension (see After-treatment, page 435).

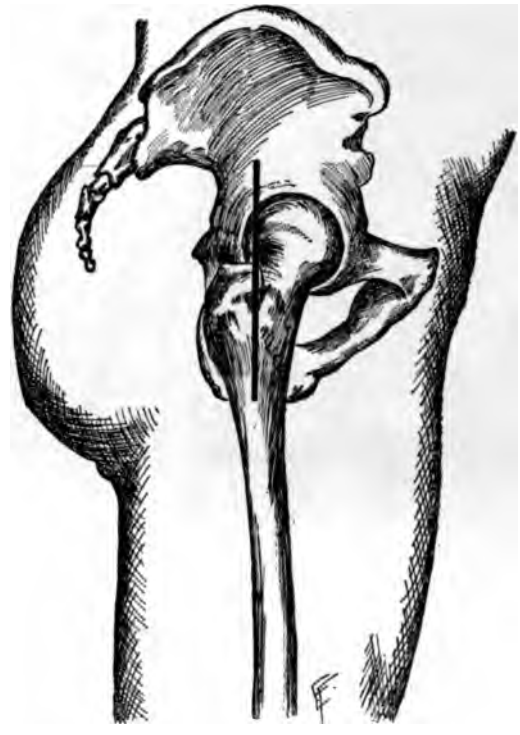

Fig. 303.—Excision of Hip-joint:—By external straight incision (Langenbeck's operation).

Comment.—(1) Only minor hemorrhage occurs, seldom necessitating ligature. (2) The strength of the capsule is increased if its transverse division be avoided. (3) Some surgeons remove as little of the head of the femur as possible, sawing through the neck—but it is generally better to saw below the great trochanter, as this mass of bone, if left, is apt to be drawn up and constantly press the cicatrix. (4) Considerable division of muscle is made.

EXCISION OF HIP-JOINT

BY ANTERIOR STRAIGHT INCISION—BARKER'S OPERATION.

Position.—Patient supine; limb extended. Surgeon on side of operation. Assistant steadies limb.

Landmarks.—Anterior superior iliac spine; groove between tensor vaginæ femoris and glutei on outer side, and sartorius and rectus on inner side.

Fig. 304.—Excision of Hip-joint:—By anterior straight incision.

Incision. — Begins on front of thigh, about 1.3 cm. (½ inch) below the anterior superior iliac spine — passing downward and slightly inward for 7.5 to 10 cm. (3 to 4 inches), in groove formed, on inner side, by sartorius and rectus, and, on outer side, by tensor vaginæ femoris and glutei (Fig. 304).

Operation.—(1) This incision passes through skin and fascia, at first. The external cutaneous nerve is avoided, being retracted outward, if in the way. The above intermuscular groove is recognized and the muscles forming it retracted inward and outward. (2) The terminal branch of the transverse division of the external circumflex artery is encountered and generally requires ligation. The parts are further drawn aside and the joint reached without any division of muscles whatever, or of any vessels or nerves of importance. (3) An incision is now made over the anterior aspect of the joint, in line with the original incision, passing through the capsule into the joint and on to the head of the femur. (4) The cotyloid ligament is incised to admit air into the joint and enable the head of the femur to be drawn down lower. The neck of the bone is exposed and divided *in situ* with a narrow saw, or with a chain or Gigli saw; the soft parts being as much retracted as possible. The severed head is then seized with strong bone-forceps and removed, the ligamentum teres having been cut. (5) The acetabular cavity and recesses of synovial membrane are curetted with Barker's flushing-gouge

—and the operation completed as in the excision by external incision. Temporary drainage is used and is best accomplished through a counter-opening made posteriorly.

Comment.—Disarticulation may be accomplished as in the external incision and the head excised outside of the wound.

EXCISION OF HIP-JOINT

BY POSTERIOR ANGULAR INCISION—KOCHER'S OPERATION.

Position.—Patient on sound side; hip prominent; knee semiflexed and rotated inward. Surgeon stands behind hip. Assistant steadies the part.

Landmarks. — Great trochanter; direction of fibers of gluteus maximus.

Incision.—Begins at base of external aspect of great trochanter—passes thence upward and forward to its anterior superior angle—and then runs obliquely upward and inward in the line of the fibers of the gluteus maximus (Fig. 305).

Fig. 305.—EXCISION OF HIP-JOINT:—By posterior angular incision.

Operation.—(1) The incision passes through skin and fascia, at first. Divide the aponeurosis of the gluteus maximus over the external aspect of the great trochanter—and ligate the cut branches of the external circumflex artery. (2) Divide the fibers of the muscular portion of the gluteus maximus in the upper part of the wound, and ligate the cut branches of the gluteal artery. (3) Dissect through the intermuscular fat and fascia and expose the interval between the gluteus medius and minimus above and pyriformis below—drawing the two former upward and the latter downward. Thus the posterior part of the capsule and acetabulum are approached and exposed. (4) Divide the capsule along the superior border of the pyriformis. Rotate the thigh outward and subperiosteally separate the gluteus medius from the outer surface and the gluteus minimus from the anterior border of the great trochanter, raising a thin layer of bone, with rugine or chisel, if necessary. Then subperiosteally detach the pyriformis, obturator internus, and gemelli from the inner aspect of the great trochanter, and the obturator externus from the digital fossa. (5) Rotate the thigh inward and free the inner and posterior aspects of the great trochanter. The head, neck, and great trochanter are thus cleared. Some branches of the internal circumflex may require ligation near the capsule of the joint, and branches of the external circumflex near the base of the great trochanter. (6) Cut the internal cotyloid ligament to admit air—divide the ligamentum teres from behind, on the head of the

femur while the limb is adducted, flexed, and rotated inward. The head is now dislocated through the wound by outward rotation, and removed. (7) The periosteo-muscular wound is sutured with buried chromic gut stitches —the muscles quilted—temporary drainage established—the wound closed—and the limb put up upon a splint in extension.

Comment.—The above operation is really a development of Langenbeck's external incision, but admits of freer access to the joint and gives better drainage.

EXCISIONS ABOUT THE SUPERIOR MAXILLA.

Articulations of Superior Maxilla.—With frontal; ethmoid; nasal; lachrymal; malar; inferior turbinated; palate; vomer; and its fellow.

Muscles Attached to Superior Maxilla.—Orbicularis palpebrarum; inferior oblique; levator labii superioris alæque nasi; levator labii superioris; levator anguli oris; compressor nasi; depressor alæ nasi; dilator naris posterior; masseter; buccinator; internal pterygoid; orbicularis oris.

Arteries in Neighborhood of Superior Maxilla.—Facial and its following branches:—superior coronary, arteria septi nasi, lateralis nasi, angular, muscular (masseter and buccinator). From temporal:—transverse facial. From internal maxillary:—anterior dental, alveolar or posterior dental, descending or posterior palatine, pterygopalatine, sphenopalatine, infraorbital. From ophthalmic:—inferior palpebral.

Veins in Neighborhood of Superior Maxilla.—(1) Superficial:—Facial, with its following tributaries,—angular, superior and inferior lateral nasal, inferior palpebral, infraorbital, anterior internal maxillary (deep facial, between buccinator and masseter muscles), superior coronary, transverse facial, and muscular branches (masseter and buccinator). (2) Deep:—veins corresponding to branches of internal maxillary artery, forming the pterygoid plexus (situated on the inner surface of the internal pterygoid and partly around the external pterygoid)—ending, anteriorly, in the anterior internal maxillary (or deep facial), joining the facial vein—and ending, posteriorly, in the internal maxillary vein, which unites with the common temporal vein to form the temporomaxillary vein

Chief Nerves in Neighborhood of Superior Maxilla.—(1) From facial: —malar; supraorbital branches of temporofacial division; and buccal branch of cervicofacial division. (2) From superior maxillary division of fifth nerve: —malar; posterior superior, middle superior, and anterior superior dental; palpebral; nasal; labial. (3) From sphenopalatine ganglion—anterior (large) palatine; middle (external) palatine; posterior (small) palatine; superior nasal branches; nasopalatine; upper posterior nasal.

Other Structures in Neighborhood of Superior Maxilla.—Eye; nasal duct; antrum of Highmore.

Surface Form and Landmarks of Superior Maxilla.—The superior maxilla forms the largest part of the face—the outer wall and larger part of floor of nose—the larger part of roof and part of outer wall of mouth—and part of floor of orbit.

General Surgical Considerations in Operations upon Superior Maxilla.—See under Description and Comment, in Excision of the upper jaw, pages 441 and 443.

EXCISION OF SUPERIOR MAXILLA

BY MEDIAN INCISION—FERGUSSON'S OPERATION.

Description.—Ordinarily refers to removal of superior maxilla of one side, as herein described—more rarely, to the removal of both superior maxillæ. The entire bone is removed—except the upper part of the nasal process. In addition to the removal of the entire bone, the following additional bones are removed, in whole or in part:—lower part of malar; part or whole of palate bone; whole inferior turbinated.

Preliminary Steps to Excision.—Preliminary tracheotomy is often performed, with plugging of the larynx, or the use of a tampon-cannula. Preliminary exposure of the external carotid, with temporary ligation of the vessel during the operation, is also often performed. Both of these steps are indicated in difficult cases where especial trouble is anticipated.

Position.—Patient supine; head and shoulders well elevated; face turned to sound side; region shaved; posterior nares plugged (for earlier part of operation). Surgeon to right side, in either case. Assistant opposite surgeon.

Landmarks.—General contour and boundaries of superior maxilla.

Incisions.—Median Incision—begins about 1.3 cm. (½ inch) below the inner canthus — passes down in the naso-facial groove—curves around convexity of ala nasi — passes along margin of nostril, in naso-labial groove, to mid-line of lip—and thence downward through the center of the upper lip. Horizontal Incision — passes from the beginning of the median incision along the lower border of the orbit, to end over the malar bone beyond the outer canthus (Figs. 306, A, and 307, A, B, C).

Fig. 306.—SKIN INCISIONS IN EXCISIONS ABOUT THE MAXILLÆ:—A, Excision of superior maxilla, by median incision (Fergusson's operation); B, Excision of inferior maxilla.

Operation.—(1) The above incision passes everywhere to the bone. While incising from the inner canthus to the septum nasi, and from the inner canthus to the malar, the facial artery is compressed over the inferior maxilla. Just before dividing the upper lip, the lip is compressed on either side of the median line, between thumb and finger, and, when severed, the superior coronary arteries are tied while still compressed. In this median incision are cut the following arteries and corresponding veins—angular, lateralis nasi, superior coronary, arteria septi nasi, and branches of the infraorbital. In the horizontal incision, branches of the infraorbital and transverse facial are cut. (2) Dissect up the flap included in the above incisions—clearing the surface of the superior maxilla as completely as possible, though not subperiosteally. The infraorbital artery is divided during this stage. (3)

Detach the nasal cartilages from the bone. Divide the nasal process of the superior maxilla with a fine saw, from the junction of the nasal process with the lower border of the nasal bone, to the margin of the orbit just below the canal for the nasal duct. (**4**) Raise the periosteum from the floor of the orbit, including the origin of the inferior oblique, and retract them upward, carefully protecting the eye-structures. With a fine, narrow chisel, chisel obliquely across the orbital plate, from the end of the saw-cut dividing the nasal process, to the anterior end of the sphenomaxillary fissure. (**5**) The orbital and external surfaces of the malar bone are now cleared, the former subperiosteally, preparatory to sawing. A chain or Gigli saw is then guided into position through the sphenomaxillary fissure and zygomatic fossa, upon a curved carrier, or aneurism-needle, closely hugging the bone —and the malar bone divided obliquely through its middle, from the anterior end of the sphenomaxillary fissure downward and outward to the center of its lower free border. (**6**) Extract the central incisor tooth of the involved side. Divide the muco-periosteal covering of the hard palate in the median line along the intermaxillary and interpalatal sutures, from the alveolar process to the posterior nasal spine. Similarly divide the muco-periosteal covering of the floor of the nose, with a long knife, cutting as near the septum as possible, from the posterior nasal spine to the anterior nasal spine. Make a transverse incision across the roof of the mouth, at the junction of the hard and soft palates, and separate the latter from the former. Pass a long, narrow saw in through the nose, seeing that its tip passes through the interval between the separated hard and soft palates (not injuring the latter), and divide the horizontal plate of the palate and palatal and alveolar portions of the superior maxillary bone as nearly in the central line as the septum nasi will allow. The descending palatine and nasopalatine arteries are cut here and bleed freely. (**7**) Grasp the superior maxilla with large bone-forceps, catching the orbital and alveolar aspects of the bone, and gently wrench it from side to side to determine the position and extent of the remaining connections which still hold it in place. The two remaining bony connections are, part of the orbital plate, and the union between the pterygoid processes and superior maxilla. These are generally severed with cutting forceps. The former is more accessible. The latter, after depressing the inferior maxilla, and freeing the outer and posterior surfaces of the superior maxilla, is separated by means of angular bone-cutting forceps introduced within the mouth and passed up

Fig. 307.—Bone Sections in Excisions about the Maxillæ:—A, B, C, Lines of bone-division in excision of right superior maxilla, by Fergusson's method; D, Line of division of inferior maxilla, in excision of left inferior maxilla.

behind the maxillary tuberosity—being sure that the soft palate has been entirely separated and held out of the way. Or, after depressing the inferior maxilla, a chisel may be used between the superior maxilla and pterygoid process. The superior maxilla is thus drawn away in the hold of the large forceps, after all bony connections have been divided. The posterior dental, pterygopalatine, and infraorbital arteries are here severed. (8) All bleeding vessels are now secured, and remaining hemorrhage controlled by temporary gauze packing. The wound is sutured throughout—and with especial care through the upper lip, to avoid disfigurement. Drainage is established through the mouth. Feeding is done by a tube for a time. An artificial palate is generally worn after the operation.

Comment.—(1) No attempt is made to remove the superior maxilla subperiosteally in the above operation. (2) Preservation of branches of the facial nerve is important. (3) While the above method of freeing the bone from its final attachments is to be preferred, yet if difficulty be experienced in severing the pterygomaxillary connections by cutting forceps, the superior maxilla may be separated from the pterygoid processes by a quick downward wrench, tearing it away from its bony attachments. (4) The upper jaw may also be excised by the methods of Velpeau, Langenbeck, Liston, Gensoul, Nélaton, Boeckel, Ollier, and others.

Partial Excisions of the Superior Maxilla.—The following parts of the upper jaw may be done through special incisions,—(a) Alveolar and palate processes,—(b) Orbital and nasal portions,—(c) All the superior maxilla below the infraorbital foramen,—(d) All the superior maxilla except the orbital plate.

EXCISIONS ABOUT THE INFERIOR MAXILLA.

Ligaments of Temporomaxillary Articulation.—External lateral; internal lateral; stylomaxillary; capsular; interarticular fibrocartilage. Two synovial membranes.

Muscles Attached to Inferior Maxilla.—To Outer Aspect;—levator labii inferioris; orbicularis oris; depressor labii inferioris; depressor anguli oris; platysma myoides; buccinator; masseter. To Inner Aspect;—Geniohyoglossus; geniohyoid; mylohyoid; digastric; superior constrictor of pharynx; temporal; internal pterygoid; external pterygoid.

Arteries in Neighborhood of Inferior Maxilla.—Facial and following branches:—submaxillary, submental, muscular (pterygoid, masseter, buccinator), inferior labial, inferior coronary. Internal maxillary and following branches:—tympanitic, middle meningeal, inferior dental, pterygoid, masseteric, buccal. From temporal:—transverse facial. (The internal carotid lies considerably to the inner side of the lower jaw.)

Veins in Neighborhood of Inferior Maxilla.—Superficial;—facial, with its following tributaries; transverse facial, inferior coronary, inferior labial, submental, submaxillary, muscular (pterygoid, masseter, buccinator). Superficial and Deep;—external jugular and its tributaries; common temporal, internal maxillary, communicating branch from the facial to external jugular. Deep;—veins corresponding to the above branches of the internal maxillary artery. (The internal jugular vein lies considerably to the inner side of the lower jaw.)

Chief Nerves in Neighborhood of Inferior Maxilla.—From facial;—buccal, supramaxillary and inframaxillary branches of cervicofacial division. From inferior maxillary division of fifth nerve;—internal pterygoid, masse-

teric, temporal, buccal, external pterygoid, auriculotemporal, lingual, inferior dental. (The glossopharyngeal and hypoglossal are considerably to the inner side of the inferior maxilla.)

Other Structures in Neighborhood of Inferior Maxilla.—Parotid gland; submaxillary gland; sublingual gland.

Surface Form and Landmarks of Inferior Maxillary Region.—(1) Steno's duct of the parotid gland crosses the ascending ramus of the inferior maxilla horizontally, about 2 cm. (¾ inch) below and parallel with the zygomatic arch—the transverse facial artery lying above and the facial nerve below it. (2) The facial nerve crosses the parotid gland forward and slightly downward, from the junction of the anterior border of the mastoid process and the ear. (3) The facial artery crosses the inferior maxilla at the anterior border of the masseter muscle—the facial vein lying just behind.

EXCISION OF TEMPOROMAXILLARY ARTICULATION

BY ANGULAR INCISION.

Description.—Consists in removal of condyle of inferior maxilla. The interarticular fibro-cartilage of the joint and the glenoid cavity are, ordinarily, not disturbed.

Position.—Patient's head and shoulders elevated; faced turned to opposite side. Surgeon on side of operation. Assistant opposite.

Landmarks.—Ascending ramus and condyle of inferior maxilla.

Incision.—Vertical portion—begins at lower border of zygoma and passes vertically downward anterior to the temporal artery (which is about 2 cm., ¾ inch, in front of the tragus), ending just above the transverse facial artery (which is from 1.3 to 2 cm., ½ to ¾ inch, below the zygoma). Horizontal portion—passes forward along the lower border of the zygoma for about 4 cm. (1½ inches). (Fig. 308.)

Operation.—Incise through skin and fascia and turn the triangular flap thus raised downward and forward. Be on the lookout for the transverse facial artery, Steno's duct, and facial nerve, all crossing parallel with the zygoma from behind forward, and in the above order from above downward. Retract the lower border of the wound downward to avoid these—and the vertical border backward, with the anterior margin of the parotid gland. Incise whatever portion of the masseter fibers are encountered along the lower border of the zygoma—and along the ascending ramus, if any extend into the field. Incise the capsule of the joint vertically and expose the condyle. Clear the circumference of the neck of the condyle, as near the condyle itself as possible, closely hugging the bone—leaving some of the lower fibers of the external pterygoid, if feasible. Conduct a Gigli saw around the neck of the bone and divide it just below the condyle. This is better than dividing it by chisel or pliers. Seize the condyle with bone-forceps and divide any remaining connections, while putting traction upon the end of the bone—preserving the capsule as intact as possible. Suture the capsule with buried gut. If the masseter have been extensively removed from the zygoma, suture it back to the periosteum. Establish temporary drainage. Close the angular wound—and dress the jaw closed.

Comment.—(1) Both temporomaxillary articulations may require simultaneous excision. (2) The joint may be less satisfactorily excised from within the mouth.

EXCISION OF INFERIOR MAXILLA

BY SINGLE INCISION ALONG INFERIOR AND POSTERIOR BORDERS.

Description.—Ordinarily refers to the removal of the inferior maxilla of one side. Both sides may be removed. The bone is removed subperiosteally, when the preservation of the periosteum is not contraindicated.

Position.—Patient supine; head and shoulders elevated; head to opposite side; face shaved. Surgeon on side of operation. Assistant stands opposite.

Landmarks.—General contour of bone, especially its inferior and posterior borders.

Incision.—Begins in the midline of the chin, just below the free portion of the lip—passes down the front of the chin well around its prominent border

Fig. 308.—Excision of Temporomaxillary Articulation:—By angular incision.

—thence follows the lower border of the inferior maxilla, passing a little nearer the posterior than the anterior aspect of the border (in order to hide the scar) to the angle—thence upward along the posterior border of the ascending ramus—ending about opposite the center of the ascending ramus (about opposite the lobule of the ear). (Fig. 306, B, and 307, D.)

Operation.—(1) This incision is everywhere carried through skin, fascia, platysma, and periosteum to bone—except over the facial artery, where the skin alone is incised. The facial artery is then regularly exposed, doubly ligated and cut between the ligatures. (2) All the structures (see Surgical Anatomy, page 443) covering the outer surface of the inferior maxilla are now raised subperiosteally, working from the free border of the bone toward the alveolar margin, and from the symphysis toward the angle and upward along the ascending ramus. The mental vessels and nerve are divided at the mental foramen. The strong attachment of the masseter muscle is difficult to free from the margin of the angle, except with a sharp rugine, after having

cut through the periosteum to the bone. The bone is closely hugged everywhere. The clearing is continued as high up the ascending ramus as can be reached with the bone *in situ*. (3) The structures along the inner aspect of the horizontal ramus of the jaw are now similarly separated subperiosteally, in the same order as upon the outer surface, as far as they can be reached. Guard against injuring the submaxillary and sublingual glands. (4) The mucous membrane is then divided along the alveolar margin, on the outer and inner sides—all the muscles having been freed from both aspects of the bone. The lower lateral incisor tooth is extracted and a chain or Gigli saw conducted around the bone at the site of the empty socket. As much of the attachments of the digastric, geniohyoid, and geniohyoglossus of the involved side as possible are saved (for their future action). (5) Seizing the anterior end of the severed jaw, and drawing it outward, the remaining structures are detached from the inner aspect—internal pterygoid muscle, inferior dental artery and nerve at the inferior dental foramen, superior constrictor of the pharynx, internal lateral ligament, stylomaxillary ligament. If not already divided, the mylohyoid and posterior part of the mucous membrane of the mouth are now separated. (6) Firmly depress the anterior portion of the inferior maxilla, thereby bringing the coronoid process further forward and downward—and then cut from it the temporal muscle with blunt curved scissors, following the anterior border of the coronoid process upward. (7) Still further depress the inferior maxilla, until the coronoid process is more accessible. This is especially necessary, as the original incision ceases about the center of the posterior border of the ascending ramus, in order to avoid the danger of cutting the important structures near the upper half of the posterior border of the ascending ramus (parotid gland, facial nerve, transverse facial and internal maxillary arteries, Steno's duct, and temporomaxillary vein)—hence the coronoid process is thus approached from before rather than from behind. The inferior maxilla should be depressed only, and not rotated outward—in doing the latter, the internal maxillary artery is apt to be hooked around the inner portion of the condyloid process and dragged out into the wound, and even ruptured. (8) Following the upper inner aspect of the condyloid process, free the insertion of the external pterygoid with elevator, or cut with blunt curved scissors. Divide the capsule and disarticulate the head of the bone forward. If not already divided, sever the internal lateral, stylomaxillary, and pterygomaxillary ligaments, and any binding bands of fascia, or fibers of the external pterygoid muscle. (9) The wound is temporarily drained through the posterior portion of the incision. The skin wound is carefully sutured to avoid scar.

Comment.—(1) Excision, where large growths complicate, may require a preliminary ligation of the external carotid—and a preliminary tracheotomy, with tamponing of the larynx—as well as division of the entire thickness of the lower lip. (2) If the median portion of the inferior maxilla, and therefore the genial tubercles, be removed, the tongue must be stitched forward to keep it from falling backward. (3) The coronoid and condyloid processes may require to be first divided with forceps or chisel, and then withdrawn. (4) Only healthy periosteum is to be saved—otherwise an open operation is indicated. (5) Any portion of the alveolar process, or of the body, may be removed. (6) Both inferior maxillæ may be simultaneously removed, by a repetition of the above procedure. (7) Feeding through a tube is, at first indicated after the operation.

EXCISION OF RIBS.

Surgical Anatomy—Surface Form and Landmarks.—Given under the Thorax, pages 576 and 578.

General Surgical Considerations.—(1) The following extents of rib may be removed;—(a) An entire rib, from and including its chondrosternal articulation, to and including its costovertebral articulation;—(b) Part of a rib (the rib proper), from and including the chondrocostal, to and including the costovertebral articulation;—(c) Part of a rib, from and including the chondrocostal, up to the costotransverse articulation;—(d) Any limited portion of a rib;—(e) Two or more adjacent ribs, in whole or in part. (2) Unless contraindicated, the portion of rib covered by periosteum should be removed subperiosteally (that is, the rib proper).

Best Methods of Excision.—By parallel incision over center of rib—for one rib, or part of a rib. Parallel incision midway between ribs—for two adjacent ribs.

EXCISION OF ENTIRE RIB AND COSTAL CARTILAGE

BY PARALLEL INCISION OVER CENTER OF RIB.

Position.—Patient near edge of table, in such a position as to render site of operation accessible, and resting upon pad so as to render the part prominent. Surgeon on side of operation, or behind, if patient be upon side. Assistant stands opposite.

Landmarks.—Upper and lower border of rib; chondrosternal articulation; costovertebral articulation.

Incision.—The long parallel incision begins over the center of the chondrosternal articulation—passes directly over center of costal cartilage and rib—ending over costovertebral articulation. The posterior end of this incision will be over the center of the vertebral ends of the ribs, in the case of the lower ribs—but will run along their upper border, just above the transverse processes of the vertebræ, in the case of the upper ribs.

Operation.—Incise directly through skin, fascia, overlying muscle, and periosteum, down to bone. Over the costal cartilages there is no periosteum, as such. The treatment of the overlying muscles will be modified by the part of the chest involved—where unimportant, they are cut through—where important and capable of retraction after being cut, they are divided in their cleavage line as far as this is possible—otherwise their fibers must be cut. Important vessels, and especially important nerves, coursing downward from the axillary region, are to be avoided, if possible. The rib is freed subperiosteally—and with especial care along the groove upon the lower, inner aspect, where the intercostal vessels and nerve run—using fully curved periosteal elevator and rugine. Guard the pleura behind the posterior surfaces of the ribs—intrathoracic fascia alone here intervening. Having freed the center of the rib around its entire circumference, a chain or Gigli saw is carried between bone and periosteum and the rib divided. First one and then the other cut end of the rib is seized with bone-forceps and drawn outward—and, while held in this position, is freed toward either end and disarticulated. The musculo-periosteal sheath is sutured with gut—and the wound closed.

Comment.—For excision of two or more consecutive ribs, in whole or in part, see Estlaender's and Schede's operations, pages 604 and 607.

EXCISION OF COCCYX

BY POSTERIOR MEDIAN INCISION.

Description.—Separation of coccyx at sacrococcygeal articulation and removal from its bed of soft parts.

Position.—Patient on side at edge of table; thigh flexed; buttocks separated.

Landmarks.—Tip and outline of coccyx, and position of sacrococcygeal articulation. If necessary, this articulation may be determined by means of a gloved finger introduced within the rectum and the coccyx palpated between this finger within and the thumb without.

Incision.—Begins in middle line, just above sacrococcygeal articulation —passes vertically downward—and ends just below the tip of the coccyx.

Operation.—Incise through skin and fascia to the bone. Separate the gluteus maximus from the posterior surface—the coccygeus from the anterior surface—the sphincter ani from its tip in front and the levator ani from its tip behind—and the sacrococcygeal ligaments from its upper aspect—hugging the bone closely and putting the parts upon the stretch after freeing the tip —thus completing the disarticulation. Sometimes the bone may be more easily removed by freeing its posterior aspect and lateral borders—then disarticulating and levering out its upper end—and, while this is being drawn backward, its anterior surface is freed from above downward. The incised muscles are sutured together deeply with buried gut—and the superficial wound closed.

OSTEOPLASTIC RESECTIONS OF BONES AND JOINTS.

Description.—An osteoplastic operation, in general, consists in the approximation of fresh sections of bone to each other, for the purpose of bringing about union between their opposed aspects. The surfaces brought thus into contact may have been originally in contact, as the margin of an oval of bone turned back from the skull and afterward dropped into its old place, —or some new bony contact may be brought about, as when, after total excision of the tarsus, the sawed ends of the metatarsals are approximated to the sawed ends of the tibia and fibula. Osteoplastic Resection of a Bone consists in the resection, or cutting through, of a bone in such a way as to leave its soft coverings attached, and, in addition, a hinge-like connection of soft parts connecting it with the neighboring bone from which cut—and in then turning, that is, breaking, back the portion of bone, with its soft coverings adherent and soft hinge intact, in some convenient direction, thus admitting of free access to the underlying structures sought in the special operation—and of subsequently, upon completion of the object sought, turning the bone-flap, or bone part, with its connected soft parts, back into its original place—union of the bony surfaces being expected and a reproduction of the *status ante quo*—as in the osteoplastic exposure of the brain, or the osteoplastic exposure of the elbow-joint by temporary resection of the olecranon. Osteoplastic Resection of a Joint is an operation in which, after the ordinary excision of the joint, the sawed bony surfaces immediately beyond the joint are brought into contact for permanent union—and, therefore, implies that no motion is to be expected in that region. The excision of the knee-joint, or of any other joint, where ankylosis is expected, or results, whether expected or not, is, consequently, not, properly speaking, a simple excision, but an osteoplastic excision or resection.

General Surgical Considerations.—(1) The osteoplastic resection of a bone, as to the manner of its performance, is done, in all practical respects, in the same way as an excision of a bone—except that the soft parts are not cleared from the surface of the bone entering into the osteoplastic flap, and that the hinge-like connection of soft parts between the bone-flap and the main bone, or bony surroundings, is disturbed as little as possible. (2) The osteoplastic resection of a joint is performed, as far as the excision itself is concerned, in precisely the same manner as an ordinary excision of a joint—except that after the removal, or excision of the joint surfaces, the cut surfaces of the bones beyond are brought into permanent contact—and solid bony union sought.

OSTEOPLASTIC RESECTION OF ANTERIOR TARSUS AND TARSO-METATARSUS

BY INTERNAL AND EXTERNAL DORSO-LATERAL INCISIONS.

Description.—Consists in the removal of the tarso-metatarsal joints; the entire tarsal bones distal to the astragalo-scaphoid and calcaneo-cuboid, or medio-tarsal, joint (namely, the scaphoid, cuboid, internal, middle and external cuneiform); and the articular surfaces of the astragalus and os calcis; followed by the approximation of the sawed proximal and distal bones. The operation is resorted to in disease, especially tubercle, of the anterior tarsal joints. Where the disease is limited to the bases of the metatarsals, a tarso-metatarsal excision is done—the bases of the metatarsals and adjacent articular surfaces of the cuboid, internal, middle and external cuneiforms are alone removed. Where the disease is more general, in addition to the tarso-metatarsal excision, the anterior tarsus (scaphoid, cuboid, and three cuneiforms) is also excised. And where the disease is still more extensive, the articular surfaces of the posterior tarsus (astragalus and os calcis) are additionally removed

Position.—Patient supine, with foot over edge of table and so manipulated as to bring the site of operation into prominence during the various steps. Surgeon faces foot. Assistant steadies and manipulates foot and leg.

Landmarks.—First metatarsal, internal cuneiform, scaphoid, and head of astragalus, on inner aspect of foot,—and fifth metatarsal, cuboid, head of os calcis, and external malleolus, on outer aspect.

Incisions.—Internal Incision—from the posterior third of the dorsal aspect of the first metatarsal backward over the internal cuneiform and scaphoid to just above the dorso-lateral aspect of the head of the astragalus. External Incision—from the posterior third of the dorso-lateral aspect of the fifth metatarsal (external to the extensor tendons) backward over the cuboid to the dorso-lateral aspect of the os calcis, between the calcaneo-cuboid articulation and external malleolus. (Fig. 296, H, H′.)

Operation.—(1) The internal incision first passes through skin and fascia. Then working upward and toward the middle line of the dorsum, the attachment of the tibialis anticus is separated from the first metatarsal and the internal cuneiform—and the dorsal aspect of the first metatarsal, internal cuneiform, scaphoid, and part of astragalus are bared, as far toward the middle of the dorsum as possible. Then working downward and toward the middle line of the sole, the attachment of the posterior tibial to the tuberosity of the scaphoid and internal cuneiform is separated—and the plantar surfaces of the first metatarsal, internal cuneiform, scaphoid, and part of astragalus are cleared, as far toward the center of the sole as possible. (2)

The external incision also, at first, involves skin and fascia. First working toward the dorsum, the tendon of the peroneus tertius is then separated from its attachment to the base of the fifth metatarsal—and the dorsal aspect of the outer metatarsals, cuboid, and part of os calcis, and as far toward the center of the dorsum as possible, are cleared. Then working toward the sole, from the outer aspect, the attachment of the peroneus brevis is separated from the base of the fifth metatarsal and the tendon of the peroneus longus is detached from the groove under the cuboid and drawn backward—and the under surface of the other metatarsals, cuboid, and part of os calcis are cleared as far toward the center of the sole as possible. (3) The cuboid, three cuneiforms, and scaphoid are removed by being grasped by bone-forceps and dissected out from the lateral wounds. The articular surfaces of the metatarsals below, and astragalus and os calcis above, are then sawed or gouged. (4) The sawed ends of the metatarsals are approximated to the sawed ends of the astragalus and os calcis—the dorsal and plantar redundancy of tissue being eventually taken up. (5) Temporary drainage is established—the two lateral wounds sutured—and the foot put up upon a splint, at a right angle to the leg. Buried chromic gut sutures between the deeper fibrous margins of the wound should be placed wherever indicated.

Comment.—The anterior tarsus alone may be removed, by limiting the incision accordingly.

OSTEOPLASTIC RESECTION OF MID-TARSUS

BY EXTERNAL TRANSVERSE CURVED INCISION.

Description.—Removal of anterior part of astragalus and os calcis, and

Fig. 309.—Osteoplastic Resections about the Foot:—A, Osteoplastic resection of mid-tarsus by external transverse curved incision; B, B', Osteoplastic resection of posterior tarsus by external curved incision; B, C, Incision in osteoplastic resection of foot by externo-lateral curved incision (modification of Wladimiroff-Mikulicz operation).

the posterior part of the scaphoid and cuboid—followed by the approximation of the sawed distal and proximal bones.

Position.—As in the above operation.

Landmarks.—Medio-tarsal joint line (astragalo-scaphoid and calcaneo-cuboid articulations); external malleolus.

Incision.—Begins over dorsal aspect of astragalo-scaphoid joint—curves obliquely downward and outward over upper part of calcaneo-cuboid joint, and passes thence backward to a point on a line with and about 1.3 cm. (½ inch) below the external malleolus (Fig. 309, A).

Operation.—(1) Incise skin and fascia. The musculocutaneous nerve is encountered and retracted at the upper angle of the wound, and the external saphenous nerve and vein at the lower. The tendons of the peroneus tertius and extensor longus digitorum appear at the upper part of the wound and are retracted. The tendons of the peroneus longus and brevis appear at the lower part of the wound—their sheaths are slit and the tendons retracted. (2) The medio-tarsal region is approached in the interval thus made. The capsule is incised over the head of the astragalus—the astragalo-scaphoid joint opened—and the capsule separated from the articular ends of both bones. (3) Retract downward the upper border of the extensor brevis digitorum and open the calcaneo-cuboid joint, and free the capsule from the articular ends of both bones. (4) Sever the greater process of the os calcis and neck of astragalus with chisel and remove with bone-forceps, cutting the binding ligaments under traction. With chisel or gouge, remove as much of the cuboid as indicated—and the whole or as much as necessary of the scaphoid. (5) The sawed scaphoid and cuboid are approximated to the sawed astragalus and os calcis. The slit sheaths are sutured over the peronei tendons—the deep parts brought together with buried chromic gut sutures—the wound sutured—and the foot put up at a right angle to the leg, with the leg flexed. No drainage is established unless articular surfaces are left.

OSTEOPLASTIC RESECTION OF POSTERIOR TARSUS

BY EXTERNAL CURVED INCISION.

Description.—Removal of astragalus and anterior half of os calcis; together with the articular surfaces of the tibia and fibula, and of the scaphoid and cuboid; after which, the anterior sawed surface of the posterior half of the os calcis is approximated to the sawed surfaces of the tarsal bones (scaphoid and cuboid); and the upper sawed surface of the posterior half of the os calcis is approximated to the sawed tibia and fibula.

Position.—Patient supine, with foot resting upon its inner side. Surgeon stands upon the outer side—and an assistant steadies the leg and foot.

Landmarks.—Tendo Achillis; external malleolus; base of fifth metatarsal.

Incision.—Begins upon external border of tendo Achillis, about 7.5 cm. (3 inches) above the ankle-joint—passes down behind the tendons of the peroneus longus and brevis and external malleolus—thence forward, nearer the sole than the external malleolus, to the base of the fifth metatarsal (Fig. 309, BB′).

Operation.—(1) Incise skin and fascia. Slit sheaths of peroneus longus and brevis and retract the tendons forward. Separating the margins of the wound as far as possible, open the capsule of the ankle-joint and, working beneath this with rugine and periosteal elevator, free the surfaces of the astragalus and os calcis, and their articulations with the scaphoid and cuboid, as far as possible in all directions, and working as subperiosteally as possible. The origin of the extensor brevis digitorum is separated from the antero-

external aspect of the os calcis. The articular line of the astragalus is freed as fully as possible. (2) The foot is then forcibly inverted and, while in this position, the astragalus is strongly prized and drawn out by bone-forceps, the binding ligaments being cut under tension. The peronei and tibial tendons are carefully preserved. (3) The calcaneo-cuboid articular surfaces are then separated. The lower ends of the tibia and fibula are projected into the wound (by complete inversion of the foot) and sawed off just above the articular lines, leaving enough of the external malleolus for the peronei tendons to hook behind, if possible. The anterior half of the os calcis is then removed by vertical section with saw or chisel. The posterior half of the os calcis is now depressed forward, so as to render its upper surface accessible, and a horizontal slice of bone is removed from its upper surface, but not involving the tendo Achillis. The posterior articular surfaces of the scaphoid and cuboid are thrust into the wound (by twisting the anterior portion of the foot inward) and a vertical section made just posterior to their articular surfaces. (4) The vertical section of the posterior half of the os calcis and vertical sections of the scaphoid and cuboid are now approximated—and the horizontal sections of the tibia and fibula are dropped down upon and approximated to the horizontal section of the upper aspect of the posterior part of the os calcis. (5) Repair the incised sheaths of the peroneus tendons by suturing them over the tendons with buried gut. The wound is sutured and the foot put up at a right angle to the leg.

Comment.—(1) The tendons of the peroneus longus, brevis, and tertius, and of the tibialis anticus and posticus, and their attachments, are especially preserved intact. (2) The excision of the calcaneo-astragaloid joint alone may be done through this incision.

OSTEOPLASTIC RESECTION OF FOOT

BY TRANSVERSE UPPER AND LOWER AND OBLIQUE LATERAL INCISIONS—WLADIMIROFF-MIKULICZ OPERATION.

Description.—Removal of soft parts of heel, together with astragalus and os calcis, and approximation of sawed tibia and fibula to sawed scaphoid and cuboid. A foot in the permanent position of extreme talipes equinus results, the patent walking upon the balls and phalanges of the toes.

Position.—Patient supine, with knee flexed to enable inner or outer side of foot to be turned uppermost at end of table. Surgeon's position will vary with the varied steps of the operation.

Landmarks.—Tuberosity of scaphoid; base of fifth metatarsal; external and internal malleoli; ankle-joint.

Incisions.—Transverse Plantar Incision—from tuberosity of scaphoid across sole of foot to a point slightly behind the base of the fifth metatarsal. Internal and External Oblique Incisions—pass from the upper extremities of the plantar incisions obliquely upward and backward over the inner and outer aspects of the foot to the bases of the internal and external malleoli. Posterior Horizontal Incision—passes transversely backward around the posterior aspect of the leg, connecting the upper extremities of the inner and outer oblique incisions. (Fig. 310, C, C′, C″, D, and E.)

Operation.—(1) The above incisions are everywhere carried to the bone—the plantar vessels and posterior tibial nerve being divided in the transverse plantar incision. (2) Flex the foot forcibly—divide the tendo Achillis and the posterior ligaments—opening the articulation from behind. Further flex the foot on the leg and complete the disarticulation of the ankle-joint.

(3) By means of rugine and periosteal elevator, and approaching from the lateral incisions, detach the soft parts from the dorsum of the foot as subperiosteally as possible, thus guarding the anterior tibial vessels and extensor tendons. (4) Disarticulate anteriorly at the astragalo-scaphoid and calcaneo-cuboid joints, and remove the astragalus and os calcis with the adherent soft coverings. (5) Divide the tibia and fibula horizontally just above the articular surfaces. Divide the scaphoid and cuboid vertically at about the center of each bone. Approximate the sawed surfaces of the tibia and fibula above, to the scaphoid and cuboid below, in the vertical or extreme talipes equinus position—holding them in place by kangaroo tendon, silver wire, or pegs. (6) Having tied all vessels, approximate and suture the cut ends of the posterior tibial nerve. Establish temporary drainage. Suture the transverse plantar incision and the lower half of the oblique lateral incision, to

Fig. 310.—EXCISIONS ABOUT THE FOOT:—A, Excision of first phalanx of great toe, by dorso-internal incision; B, Excision of metatarso-phalangeal joint of great toe by dorso-internal incision; C, C', C'', Skin incisions in Wladimiroff-Mikulicz's osteoplastic resection of foot; D, Bone-section of scaphoid and cuboid, in same; E, Bone-section of tibia and fibula, in same.

the upper half of the oblique lateral incision and posterior horizontal incision. The limb is then put up in a plaster cast.

Comment.—(1) The redundancy of tissue is soon taken up. (2) The limb is generally permanently a little lengthened, and a special boot is always to be worn. (3) Nourishment of the part occurs through the dorsalis pedis artery and its anastomoses with the plantar. (4) The section of bone below may be made through the three cuneiforms and cuboid.

TOTAL EXCISION OF TARSUS—OR OSTEOPLASTIC RESECTION OF FOOT

BY EXTERNO-LATERAL CURVED INCISION—MODIFICATION OF WLADIMIROFF-MIKULICZ OPERATION.

Description.—Removal of all the tarsal bones, and sawing off of distal articular surfaces of tibia and fibula and proximal articular surfaces of meta-

tarsals—with approximation of sawed tibia and fibula to sawed metatarsals—the foot being brought into a vertical line with the leg. This is a modification of the Wladimiroff-Mikulicz osteoplastic resection of the foot, and is preferable to that operation where the soft tissues of the heel do not have to be sacrificed. The patient walks on the balls of the toes and the phalanges.

Position—Landmarks.—As for osteoplastic resection of posterior tarsus, page 451.

Incision.—As for osteoplastic resection of posterior tarsus—except that the incision extends to near the end of the fifth metatarsal (Fig. 309, BC).

Operation.—The exposure and freeing of the surfaces of the tarsal bones, lower end of the tibia and fibula, and bases of the metatarsals are accomplished in the same manner as described in freeing the bones involved in osteoplastic resection of the posterior tarsus, except that the clearing is more extensive. The origins and insertions of all the muscles and tendons into the bones to be removed are to be separated as encountered. All vessels and nerves are carefully guarded by working close to the bones. The tendons of the peroneus longus and brevis are freed from their sheath and drawn forward. The tendo Achillis is subperiosteally separated from the os calcis. The long dorsal, plantar, external and internal tendons are separated—and the short muscles as well. The tarsal bones are to be removed one by one while the foot is forcibly inverted, access being gained to the region, if necessary, by chiseling off the external malleolus. The articular ends of the tibia and fibula and of the metatarsals are exposed by thrusting them through the external wound and are sawed off. Their sawed surfaces are then placed in contact in a vertical line—the fibrous tissues brought together with chromic sutures, where indicated—the superficial wound closed—and the limb put up in a splint, or plaster, in such a manner as to retain this position.

OSTEOPLASTIC RESECTION OF SUPERIOR MAXILLA

BY VERTICAL AND HORIZONTAL INCISIONS.

Description.—Having made the same incisions, preceded by the same preliminaries, as in the ordinary excision of the upper jaw by Fergusson's method (page 441), and carried them everywhere to the bone—the soft parts are carefully guarded, and are nowhere freed from the bones, except in so far as necessary to reach the bones in making the original incisions. The bones are now divided just as in that operation, everywhere along the line of skin incision—except that no division of the bone is made from the anterior end of the sphenomaxillary fissure through the malar—this portion of bone being preserved for the "hinge." When all other connections have been divided, the bone, with its soft parts adherent, is broken outward and backward through the above indicated undivided portion as a hinge—by putting pressure from without over the region where the bone is to be broken back, and then prizing it outward and backward in that direction. At the end of the operation, the flap of bone and soft parts is turned back into place—and, if necessary, the bone wired.

Comment.—It is better to previously divide the frontal process of the malar, making a limited incision for that purpose, prior to turning back the bone—thus avoiding the uncertainty of the line of breakage and possible harm that might result to neighboring structures through the rougher manœuvre.

CHONDROPLASTIC RESECTION OF NASAL CARTILAGES

TO EXPOSE NOSE AND ANTERIOR NASOPHARYNX BY NASAL ROUTE, BY TRANSVERSE INCISION—ROUGE'S OPERATION.

Description.—The cartilaginous portion of the nose is temporarily separated from the bony nares and turned upward.

Position.—Patient supine, with head elevated and thrown back.

Landmarks.—Line of reflection of mucous membrane of upper lip.

Incision and Operation.—An assistant stands behind the head and draws the upper lip well upward, holding it opposite the angles of the mouth. The surgeon, standing in front, with scissors curved on the flat, cuts the mucous membrane in the line of its reflection from the superior maxilla, from one bicuspid tooth to the opposite one, hugging the bone throughout. Similarly separate the cartilaginous septum from the anterior nasal spine, and alar cartilages from the lateral borders of the maxilla. Having retracted the cheeks well, the anterior nares is now turned upward and backward toward the forehead. At the end of the operation, the nose is dropped back into place and the cut edges of the mucous membrane sutured, if sufficient free margin exist—but suturing is not necessary.

Comment.—This operation gives imperfect access to the nasopharynx—but satisfactory access to the nose. The cheeks must be sufficiently separated from the underlying bones to enable the nose to be turned back.

OSTEOPLASTIC RESECTION OF SUPERIOR MAXILLA

TO EXPOSE NASOPHARYNX BY PALATINE ROUTE, BY TRANSVERSE AND MEDIAN INCISIONS—ANNANDALE'S OPERATION.

Description.—After having exposed the bony anterior nares as in Rouge's operation, the alveolar and palatal processes of the superior maxilla are divided in the median line, and the septum nasi also divided. The two halves of the superior maxilla can then be separated from 1.3 to 2.5 cm. (½ to 1 inch).

Position.—Patient supine, head elevated and thrown back. Surgeon faces patient.

Landmarks.—Anterior and posterior nasal spines; septum nasi; two central incisors.

Incisions.—Transverse Incision—through mucous membrane of upper lip (this portion of the operation being similar to Rouge's). Median Incision—follows the base of the septum nasi, as near to the middle line as possible, and extending along the floor of the nose from the margin of the posterior bony nares to the anterior bony nares, and along the alveolar process of the superior maxilla between the two central incisors, possibly extracting one.

Operation.—Expose the bony anterior nares as in Rouge's operation (page 455). Divide the septum nasi just above the maxillary attachment, from before backward, with a fine narrow saw, or with cutting pliers. Having gagged the mouth open, separate the soft from the hard palate by a short transverse incision crossing the median line. If necessary, the soft palate may be divided. Drill holes in the alveolar process for future wiring. By means of a fine, narrow saw, introduced through the nose, divide the entire length of hard palate and alveolar process of superior maxilla, in the median line. The two halves of the superior maxillæ are now prized apart and the

nasopharynx reached with instruments. Upon the completion of the operation, the alveolar process is wired and the soft palate sutured back to the soft tissues of the hard palate (and together, if divided). The nose-flap of Rouge's operation is dropped back into place and the mucous lips of the wound closed.

Comment.—The room thus furnished is not great. The above operation may be considered the first step of an osteoplastic resection of the entire superior maxilla.

OSTEOPLASTIC RESECTION OF SUPERIOR MAXILLA

TO EXPOSE NASOPHARYNX BY MAXILLARY ROUTE, BY TWO SEMILUNAR INCISIONS—LANGENBECK'S OPERATION.

Description.—A tongue-shaped flap, having its base over the nose and its apex over the malar bone is turned forward and inward upon the nasal bone and nasal process of superior maxilla as a hinge.

Position.—Patient supine; head elevated and turned to opposite side. Surgeon on side of operation.

Landmarks.—Naso-frontal suture; ala nasi; malo-zygomatic arch.

Incisions.—Upper Incision—begins at root of nose and passes downward and outward just below the lower border of the orbit, ending a short distance posterior to the center of the malar. Lower Incision—begins at ala nasi and passes upward and outward across the cheek, joining the outer end of the upper incision. These united incisions may extend further outward as a single incision along the zygoma, if necessary.

Operation.—(1) Incise everywhere through skin, fascia, and muscles, and through periosteum to bone. Separate the periosteum for only a wide enough interval along the lines of incision for a saw to travel—except along the floor of the orbit, where it is stripped to the anterior end of the sphenomaxillary fissure. The masseter is detached from the malar where exposed. The soft parts are not otherwise raised from the bone. (2) Depress the inferior maxilla and pass a sharp periosteal elevator, or pointed director, below the inferior border of the zygoma, opposite its junction with the malar, and thrust it horizontally through the pterygomaxillary fissure to the outer wall of the nasal cavity, which is recognized by a finger in the mouth. Upon this guide, introduce a fine key-hole saw and divide the zygomatic arch upward—continuing the section so as to enter the sphenomaxillary fissure, cutting the posterior wall of the superior maxilla and following the floor of the orbit nearly to the lachrymal bone. If possible, however, it is better to make the saw section follow the line of the upper semilunar incision, thus avoiding the orbital plate. (3) The saw is again passed into the pterygomaxillary fissure and made to cut forward and downward, passing through the walls of the antrum and into the anterior nasal cavity near its floor—following, approximately, the line of the inferior semilunar incision. (4) Pass the periosteal elevator into the pterygomaxillary fissure and prize the severed portion of the superior maxilla upward and inward—bending it over the nasal bone and nasal process of the superior maxilla (which fracture in the act) as a hinge. (5) At the end of the operation, turn the displaced bone, with its soft coverings attached, back into place—and suture the wound.

Comment.—Next to the osteoplastic resection of the entire bone, the above operation gives freer access to the nasopharynx than does any of the other partial osteoplastic resections mentioned.

OSTEOPLASTIC RESECTION OF INFERIOR MAXILLA

TO EXPOSE STRUCTURES IN FRONT OF FAUCES THROUGH DIVIDED SYMPHYSIS BY MEDIAN INCISION.

Description.—The inferior maxilla is divided at the symphysis menti and either side drawn outward—followed by returning the halves into position and wiring

Position.—As for excision of inferior maxilla (page 445).

Landmarks.—Symphysis menti. Hyoid bone.

Incision.—Median incision, in line of symphysis menti, extending from the upper alveolar margin to the center of the upper border of the hyoid bone.

Operation.—The central incisor of the lower jaw is drawn. The incision is then carried through skin, fascia, muscles, and periosteum to bone, over the inferior maxilla,—and through skin and fascia alone, between the inferior maxilla and hyoid. Having freed the anterior surface of the jaw in the middle line, the posterior surface is similarly freed over a narrow area, passing between the digastric, mylohyoid, geniohyoid, and geniohyoglossus, with as little damage as possible to them. Two holes are drilled on either side of the central line for future wiring. A Gigli saw is then conducted through —the bone is divided—and the two lateral halves of the inferior maxilla are drawn aside for the necessary manipulation that the special operation may necessitate. At the end of the operation the two halves of the bone are wired—and the wound closed.

Comment.—Where exposure posterior to the fauces (pharynx) is desired, the lower jaw should be divided in front of the ascending ramus.

THE NEW YORK ACADEMY OF MEDICINE. LIBRARY.

PART II.

THE OPERATIONS OF SPECIAL SURGERY.

CHAPTER I.

OPERATIONS UPON THE HEAD.

I. THE CRANIO-CEREBRAL REGION.

SURGICAL ANATOMY OF SCALP, SKULL, AND BRAIN.

Muscles in Relation with Outer Surface of Skull.—Anteriorly; frontal portion of occipitofrontalis; corrugator supercilii; orbicularis palpebrarum. **Posteriorly;** occipital portion of occipitofrontalis; trapezius; sternomastoid; complexus; splenius capitis; rectus capitis posticus minor and major; obliquus capitis superior; trachelomastoid; digastric; rectus capitis lateralis. **Laterally;** aponeurosis of occipitofrontalis; temporal; attrahens aurem; attolens aurem; retrahens aurem; external pterygoid. **Superiorly;** aponeurosis of occipitofrontalis.

Arteries of Scalp.—Anteriorly; frontal and supraorbital branches of ophthalmic. **Posteriorly;** occipital and posterior auricular branches of external carotid. **Laterally;** superficial temporal branch of external carotid, with its anterior and posterior branches; posterior auricular branch of external carotid.

Veins of Scalp.—Anteriorly; frontal, emptying into angular vein; supraorbital, emptying into frontal and ophthalmic veins. **Posteriorly;** occipital, emptying into deep cervical vein; posterior auricular, emptying into temporomaxillary vein. **Laterally;** anterior, middle, and posterior temporal veins; forming common temporal, which empties into temporomaxillary vein; posterior auricular, emptying into external jugular.

Nerves of Scalp.—Anteriorly; supraorbital branch of ophthalmic. **Posteriorly;** occipitalis major, from cervical plexus. **Laterally;** temporal branches of facial; auriculotemporal branch of inferior maxillary; occipitalis minor, from cervical plexus; auricularis magnus, from cervical plexus.

Parts of Brain.—Medulla oblongata; pons varolii; cerebellum; crura cerebri (mid-brain); cerebrum. The only parts of the brain at present accessible to operation are the cerebrum and cerebellum.

Chief Fissures upon Surface of Cerebrum.—Great Longitudinal Fissure; extending antero-posteriorly in the median line and separating the hemispheres of the cerebrum. **Sylvian fissure;** most important of the incomplete fissures of the brain. Forms boundary between frontal and temporo-sphenoidal lobes. Contains middle cerebral artery. Begins at anterior perforated space, upon base of brain, and, running outward, divides into an anterior limb (passing forward into inferior frontal convolution), an ascending

limb (passing upward also into inferior frontal convolution), and a horizontal or posterior limb (representing the continuation of sylvian fissure, passing backward and upward). **Rolandic fissure;** second most important incomplete fissure of brain. Forms boundary between frontal and parietal lobes. Extends from great longitudinal fissure, at a point about 55 per cent. of the distance from the nasion to the inion, to or nearly to horizontal limb of fissure of Sylvius. **Parieto-occipital fissure;** forms boundary between parietal and occipital lobes. Begins about half-way between rolandic fissure and posterior extremity of brain—its outer portion extending downward and forward upon external aspect of brain for about one inch—its inner portion extending upon internal aspect of hemisphere. These four fissures just mentioned divide the surface of the cerebrum into the five following lobes.

Chief Lobes of Cerebrum.—Frontal lobe; forms forepart of hemisphere—rests upon orbital plate of frontal bone—presents three surfaces. Boundaries; Posteriorly, rolandic fissure,—Inferiorly, orbital plate of frontal bone and horizontal limb of sylvian fissure,—Internally, calloso-marginal fissure. Frontal (supero-external) surface, presents precentral, superior frontal, and inferior frontal sulci,—and ascending frontal, superior frontal, middle frontal, and inferior frontal convolutions. Orbital (inferior) surface, presents triradiate (or orbital) and olfactory sulci,—and internal orbital, anterior orbital, and posterior orbital convolutions. Mesial (internal) surface, is given below. **Parietal lobe;** that portion of convexity of brain lying between frontal and occipital and above temporal lobes. Boundaries; Anteriorly, rolandic fissure,—Posteriorly, external parieto-occipital fissure and a line continuing its course,—Inferiorly, horizontal limb of sylvian fissure and a line connecting this fissure with inferior end of superior occipital sulcus,—Internally, it is continued into the mesial surface of the hemisphere. Sulcus; intraparietal (consisting of superior and inferior vertical and horizontal parts). Convolutions; ascending parietal; superior parietal; supramarginal and angular gyrus. **Occipital lobe;** posterior extremity of hemisphere—rests upon tentorium—continuous with parietal lobe above and temporal lobe below. Boundaries; Anteriorly; external parieto-occipital fissure and a line continuing its course,—Posteriorly; superior fossa of occipital bone,—Inferiorly; tentorium,—Internally; it is continued into the mesial surface of hemisphere. Sulci; superior, middle (often but faintly marked) and inferior occipital. Convolutions; superior, middle, and inferior occipital. **Temporal or temporo-sphenoidal lobe;** that portion of hemisphere within middle fossa of skull—continuous with parietal and occipital lobes behind. Boundaries; Anteriorly and Superiorly; sylvian fissure,—Inferiorly, middle fossa of skull,—Posteriorly; continuous with parietal and occipital lobes. Sulci; superior (first temporal or parallel), middle (second temporal), inferior temporal (on under surface). Convolutions; superior, middle, inferior (or first, second, third) temporal,—and an external occipito-temporal (or fourth temporal) on the under surface. **Central lobe, or island of Reil;** corresponds to floor of embryonic fossa of Sylvius—is situated at base of brain, in fissure of Sylvius—and is composed of five to seven gyri operti divided by the sulci of Reil. Boundaries; separated by anterior sulcus Reilii from posterior orbital convolution; by external sulcus Reilii from inferior frontal, ascending frontal, and ascending parietal convolutions; by posterior sulcus Reilii from temporal lobe.

Mesial Fissures and Lobes of Cerebrum.—Fissures; calloso-marginal; parieto-occipital; calcarine; collateral; dentate. **Lobes;** gyrus fornicatus,

marginal, paracentral, quadrate (precuneus); cuneate; infracalcarine (fifth temporal); hippocampal; uncinate; fourth temporal.

Cerebellum.—Occupies inferior occipital fossæ of skull, separated from occipital lobes of brain by tentorium—and is divided into a central lobe (or worm) and two lateral lobes (or hemispheres). Fissures upon superior surface of central and lateral lobes; precentral, post-central, preclival, post-clival. Lobules upon superior surface of central and lateral lobes; lingula; lobulus centralis; culmen; clivus; folium cacuminis, lobules of the central lobe;—and frænulum; ala; anterior crescentic, posterior crescentic and posterior superior, lobules of the lateral lobes. Fissures upon the inferior surface of central and lateral lobes; post-nodular; prepyramidal; post-pyramidal. Lobules upon inferior surface of central and lateral lobes; tuber valvulæ; pyramid; uvula and nodulus, lobules of central lobe;—and postero-inferior; digastric; amygdala and flocculus; lobules of lateral lobes.

Meningeal Arteries.—Chief meningeal arteries; Middle Meningeal branch of internal maxillary, entering skull through foramen spinosum in middle fossa, ascends a short distance in groove on great wing of sphenoid, dividing into anterior and posterior branches. Anterior Branch of middle meningeal ascends in groove upon great wing of sphenoid, up to and upon anterior inferior angle of parietal bone (corresponding to a point on exterior of skull approximately 3.8 cm. [1½ inches] behind and 2.5 cm. [1 inch] above external angular process of frontal bone), and is continued thence upward and backward, more or less parallel with anterior border of parietal bone, nearly to superior longitudinal sinus, giving off branches running backward. Corresponds, approximately, with points respectively 2.5, 3.8, and 5 cm. (1, 1½, and 2 inches) both above zygoma and behind external angular process. Posterior Branch of middle meningeal runs backward and upward over squamous portion of temporal bone—less regular in its course than anterior branch—gives off branches which pass upward to superior longitudinal sinus and backward to lateral sinus. (For anatomy of these important arteries in greater detail, see Ligations, pages 45–47.) **Other meningeal arteries;** In Anterior Cranial Fossa; anterior meningeal branches of anterior and posterior ethmoidal (through anterior and posterior internal orbital canals); twigs of middle meningeal (through great wing of sphenoid);—In Middle Cranial Fossa; branch of ascending pharyngeal (through cartilage of foramen lacerum medium); meningea parva (through foramen ovale); meningeal branch of internal carotid; twigs of middle meningeal,—In Posterior Cranial Fossa; meningeal branch of occipital (through posterior compartment of jugular foramen); another meningeal branch of occipital (through mastoid foramen); meningeal branch of ascending pharyngeal (through posterior compartment of jugular foramen); another meningeal branch of ascending pharyngeal (through anterior condyloid foramen); meningeal branch of vertebral (through foramen magnum). Another meningeal branch of occipital sometimes enters through parietal foramen.

Chief Cerebral Arteries.—Anterior Cerebral;—Middle Cerebral, larger terminal division of internal carotid and most important, surgically, of the intracerebral vessels, supplying the motor convolutions of the brain—runs upward and outward in fissure of Sylvius, dividing opposite island of Reil into, (1) Ganglionic or Central Branches (caudate branches; antero-lateral branches): Lenticulo-striate branch, or "artery of cerebral hemorrhage," a larger branch of antero-lateral set, enters outer part of anterior perforated space, passes upward between lenticular nucleus and external capsule, pierces internal capsule and ends in caudate nucleus: (2) Hemispheral or

Cortical Branches (inferior or orbitofrontal; ascending frontal; parietal; parieto-temporal);—Posterior Cerebral:—Anterior Communicating;—Posterior Communicating;—Basilar.

Chief Cerebellar Arteries.—Superior cerebellar; anterior cerebellar; inferior cerebellar.

Venous Sinuses of Dura Mater.—(1) **More superficial sinuses;—Superior longitudinal sinus;** extends from foramen cæcum, at lower part of frontal bone, along median line, in attached margin of falx cerebri, to torcular Herophili in depression of internal occipital protuberance. Generally deviates slightly to right in the back part of the skull. Posteriorly, the longitudinal sinus extends 6 mm. ($\frac{1}{4}$ inch) to left, and 15 mm. ($\frac{5}{8}$ inch) to right of external occipital protuberance, which measurement of 2 cm. ($\frac{7}{8}$ inch) represents width of longitudinal sinus, at this site, and attachment of falx cerebri. **Lateral sinus;** extends outward, forward, and downward, passing from internal occipital protuberance along lateral sinus groove of occipital, posterior inferior angle of parietal, mastoid process of temporal and jugular process of occipital, to end in posterior compartment of jugular fossa. From the internal occipital protuberance the lateral sinus forms a slight curve, with upward convexity, to back of ear, on level with upper border of meatus auditorius externus, constituting the transverse portion of the lateral sinus,—and thence passes in a curved line, convexity forward, over prominence of mastoid process to its apex, as far as a point 5 mm. ($\frac{3}{16}$ inch) below lower border of external auditory meatus, thus forming the sigmoid portion of the lateral sinus. The Transverse portion of the Longitudinal Sinus lies above a straight line drawn from the external occipital protuberance to the center of the external auditory canal—its highest portion (which is opposite the posterior inferior angle of the parietal, at masto-parietal suture) lying from 15 to 25 mm. ($\frac{5}{8}$ to 1 inch), generally averaging from 15 to 20 mm. ($\frac{5}{8}$ to $\frac{13}{16}$ inch), above this line, and somewhat external to its center. The Sigmoid portion of the Longitudinal Sinus generally lies from 10 to 12 mm., or $\frac{7}{16}$ to $\frac{1}{2}$ inch (extremes 2 to 12 mm., or nearly $\frac{1}{8}$ to $\frac{1}{2}$ inch), from the posterior wall of meatus auditorius externus (corresponding, approximately, to posterior reflection of skin from pinna of ear to head). Distance of sinus from surface of mastoid process varies from 1 to 15 mm., or from nearly $\frac{1}{16}$ to $\frac{5}{8}$ inch (average distance being about 7 mm., or $\frac{3}{8}$ inch). Width of sigmoid portion of sinus (which is larger than transverse portion) is from 5 to 15 mm. ($\frac{1}{4}$ to $\frac{5}{8}$ inch). Right lateral sinus is generally larger, more forward, and more superficial than left. Junction of transverse and sigmoid portions lies directly below anterior part of parieto-mastoid suture. **Inferior longitudinal sinus;** situated in free margin of falx cerebri. **Straight sinus;** extends along line of junction of falx cerebri and tentorium. **Occipital sinus;** contained within attached border of falx cerebelli. (2) **Sinuses at base of skull;**—circular, transverse, cavernous, superior petrosal, inferior petrosal.

Chief Veins of Cerebrum.—Cortical (Hemispheral or Superficial), consisting of superior and inferior cortical veins, which empty chiefly into the more superficial venous sinuses of the dura mater;—Central (Ganglionic or Deep), collect into two venæ Galeni, which unite to form the vena magna Galeni, which empties into the straight sinus;—Basilar, which enters vein of Galen.

Chief Veins of Cerebellum.—Superior and Inferior veins.

CHIEF CRANIAL LANDMARKS.

Nasion: mid-point of naso-frontal suture; most important anterior median landmark.

Glabella: point in median line between superciliary arches; unreliable, may be an elevation or a depression.

Bregma (anterior fontanelle): point where coronal, sagittal, and frontal sutures meet; just in front of center of line between the two auditory meatuses.

Coronal Suture: on line from bregma to middle of zygomatic arch, running 2.5 to 3.8 cm. (1 to 1½ inches) anterior to rolandic fissure.

Obelion: point on sagittal suture on a line running between the two parietal foramina.

Lambda (posterior fontanelle): junction of lambdoid and sagittal sutures; 8 to 10 cm. ($3\frac{3}{16}$ to 4 inches) behind superior rolandic point (a point 55 per cent. of distance from nasion to inion, on median line), or 6 to 7 cm. ($2\frac{3}{8}$ to $2\frac{3}{4}$ inches) above external occipital protuberance.

Lambdoid (or parieto-occipital) Suture: sometimes an elevation of superior border of occipital bone marks this suture, which is roughly represented by a line from the external occipital protuberance to the lower part of the tip of the mastoid process.

Inion (or external occipital protuberance): most important posterior median landmark.

Superior Occipital Curved Lines (nuchal line): running from the external occipital protuberance outward toward mastoid process, marking the posterior junction of the head and neck.

External Occipital Crest: from external occipital protuberance to center of posterior border of foramen magnum; sometimes palpable.

Nuchal Furrow: depression in median vertical line between posterior muscles of neck, having in its center, above, the external occipital protuberance; its upper end corresponding with inner ends of superior curved occipital lines.

Orbit: margin everywhere palpable.

Supraorbital Arch: palpable throughout.

Internal Angular process: inner end of supraorbital arch.

External Angular Process: outer end of supraorbital arch.

Superciliary Ridge: first prominence above supraorbital arch.

Frontal Eminence: second prominence above supraorbital arch.

Superior Temporal Ridge: especially marked at forepart of lateral aspect, leading downward and forward to external angular process; gives attachment to temporal fascia.

Superior Stephanion: where coronal suture crosses superior temporal ridge.

Inferior Temporal Ridge: indicates upper boundary and attachment of temporal muscle, the contraction of which muscle will aid in determining site of ridge.

Inferior Stephanion: where coronal suture crosses inferior temporal ridge.

Pterion: point in zygomatic fossa, from 3.8 to 5 cm. (1½ to 2 inches) behind external angular process and same distance above zygoma, where parietal, temporal, frontal, and sphenoid bones meet.

Sylvian Point: where sylvian fissure reaches the convexity of the hemisphere, at a point from 2.9 to 3.2 cm. (1⅛ to 1¼ inches) directly behind external angular process.

Parietal Eminence: most prominent postero-lateral eminence.

Malar Bone: palpable throughout.

Retro-orbital Tubercle: apophysis upon posterior border of upper part of frontal process of malar bone, a short distance below malo-frontal suture; the most important anterior lateral landmark.

Zygomatic Arch: palpable throughout; its upper border may be taken as a practically horizontal measurement, in the upright position of the body.

Auricular Point: center of external auditory meatus; most reliable middle lateral landmark.

Preauricular Point: point on Reid's base-line (v. i.) in depression between tragus of the ear and condyle of inferior maxilla.

Supra-auricular Point: point vertically above auricular point, at root of zygomatic process.

Squamous Suture: summit of which is 4.4 cm. ($1\frac{3}{4}$ inches) above zygoma.

Mastoid Process of Temporal: palpable throughout.

Asterion: point behind ear where parietal, temporal, and occipital bones and lambdoid and squamous sutures meet; about 1.8 cm. ($\frac{3}{4}$ inch) behind and 1.2 cm. ($\frac{1}{2}$ inch) above upper part of posterior border of mastoid process.

Note:—For other landmarks of the cranio-cerebral region, see the methods of Chipault (page 472), Reid (page 476), and Chiene (page 478) for localizing the brain areas, and also the data under the following division of the subject.

CRANIO-CEREBRAL TOPOGRAPHY.

Description.—Relation of areas and structures of brain to the cranial bones. While discrepancies are found in the statements of the highest authorities in this department of surgical work, and differences actually exist in different heads, the following may be considered the most generally accepted data, for the average head.

Extent of Cerebral Hemispheres.—(1) **Superior or mesial border;** extends from mid-point of naso-frontal suture to a point averaging 1 cm., or $\frac{7}{16}$ inch (extremes, 5 to 15 mm., or $\frac{1}{4}$ to $\frac{5}{8}$ inch), above the external occipital protuberance, and 5 mm. ($\frac{1}{4}$ inch) to its left and 15 mm. ($\frac{5}{8}$ inch) to its right (representing the width of the superior longitudinal sinus and attachment of the dural walls). It is separated from the opposite hemisphere by the superior longitudinal sinus above, which deviates slightly to right, and by falx cerebri below. (2) **Inferior or lateral border;** (a) Frontal Portion;—begins in median line, opposite floor of naso-frontal groove—arches upward and outward 8 mm. ($\frac{3}{8}$ inch) above center of supraorbital margin of frontal bone—crosses temporal crest just above external angular process—thence descends slightly to a point in temporal fossa about 30 mm., or $1\frac{3}{16}$ inches (extremes, 29 to 32 mm., or $1\frac{2}{16}$ to $1\frac{4}{16}$ inches), directly behind external angular process, where it coincides with margin of temporal lobe at a point where the sylvian fissure reaches the convexity of the hemisphere (the sylvian point)—the frontal lobe in front and above and the temporal lobe behind and below forming a receding angle here. (More roughly outlined, the frontal portion lies just above the eyebrow in front, and just above the upper margin of the zygoma laterally.) (b) Temporo-occipital Portion;—continuing the line of lower margin of frontal portion from the sylvian point, at receding angle formed by sylvian fissure, it curves slightly downward and forward from the lower margin of frontal lobe to a point 20 mm. ($\frac{13}{16}$ inch) above the zygoma, and 15 mm. ($\frac{5}{8}$ inch) behind external angular process (which marks the

anterior pole of the temporal lobe)—thence passes backward on level with upper border of posterior half of zygomatic arch—thence still backward at an average distance of 6 mm., or $\frac{1}{4}$ inch (extremes, 3 to 9 mm., or $\frac{1}{8}$ to $\frac{3}{8}$ inch), above the roof of meatus auditorius externus—continuing horizontally backward it crosses the supramastoid crest—and runs thence to a point 5 to 15 mm. ($\frac{1}{4}$ to $\frac{5}{8}$ inch) above the external occipital protuberance, 5 mm. ($\frac{1}{4}$ inch) external to the protuberance on the left, and 18 mm. ($\frac{3}{4}$ inch) external to it on the right. (More roughly outlined, the temporo-occipital portion coincides with the upper margin of the zygoma laterally, and the superior curved line of the occipital posteriorly.)

Extent of Cerebellum.—Occupies inferior cerebellar fossæ and is in contact with cranial wall, extending upward to lower margin of transverse portion of lateral sinus above, and forward to posterior margin of sigmoid portion of lateral sinus in front.

Great Longitudinal Fissure.—Straight median line from mid-point of naso-frontal suture to center of external occipital protuberance—with a slight tendency to the left, especially posteriorly.

Great Transverse Fissure.—(Between cerebrum and cerebellum.) Represented, approximately, by a line between external occipital protuberance and center of external auditory meatus.

Sylvian Fissure.—The parts of the sylvian fissure may be traced out by measurement, or by means of the sutures of the skull. (**a**) Location of parts of Sylvian Fissure by Measurement; Sylvian Point—found by carrying straight line from posterior margin of fronto-malar junction directly horizontally backward for 3.1 to 3.5 cm., or $1\frac{1}{4}$ to $1\frac{3}{8}$ inches (average, 3.3 cm., or $1\frac{5}{16}$ inches), thence vertically upward for 6 to 12 mm., or $\frac{1}{4}$ to $\frac{1}{2}$ inch (average 9 mm., or $\frac{3}{8}$ inch), the termination of which latter line marks the sylvian point, where the anterior branches of the sylvian fissure are given off. Sylvian Line —found by carrying a straight line from the sylvian point backward and upward to a point from 1.2 to 1.8 cm. ($\frac{1}{2}$ to $\frac{3}{4}$ inch) below the most prominent part of the parietal eminence. Horizontal or Posterior Limb of Sylvian Fissure—that portion just mentioned (from sylvian point to lower part of parietal eminence) having a length of 7.5 to 10 cm. (3 to 4 inches). Ascending Limb of Sylvian Fissure—a line 3 cm. ($1\frac{3}{16}$ inches) long, drawn upward and forward from the sylvian point, at right angle to sylvian line. Anterior Limb of Sylvian Fissure—a line 2 cm. ($\frac{13}{16}$ inch) long, drawn horizontally forward from the sylvian point. (**b**) Location of Parts of Sylvian Fissure by means of Sutures of Skull; Point of Division of Sylvian Fissure—in the pterion, under or very near the spheno-parietal suture, near its posterior end. Horizontal or Posterior Limb of Sylvian Fissure—runs from the point of division backward and slightly upward, following the squamous suture at first, and then crossing the temporal portion of the parietal bone to the inferior temporal line, and thence ascending beneath the parietal eminence. Ascending Limb of Sylvian Fissure—runs from the point of division obliquely upward and forward, crossing the lower end of the coronal suture. Anterior Limb of Sylvian Fissure—runs from point of division forward in the direction of the spheno-parietal suture.

The horizontal limb of the sylvian fissure is more oblique, and further above the squamous suture, up to the third or fourth year than subsequently.

Rolandic Fissure.—The parts of the Rolandic Fissure may also be traced out by measurement, or by means of the sutures and bony landmarks, in the exposed skull; (**a**) Location of position and direction of Rolandic Fissure by Measurement; Superior Rolandic Point—variously estimated at

from 55 to 57 per cent. (average being between 55 and 56 per cent., probably about 55.7 per cent.) of distance from mid-point of naso-frontal suture to external occipital protuberance. Quain, upon another basis, gives the point at 1 cm. ($\frac{7}{16}$ inch) behind the center of the naso-inial line, and Poirier as 2 cm. ($\frac{13}{16}$ inch) behind that center. Where the inion is indistinct, the superior rolandic point may be considered as 18 cm., or $7\frac{1}{16}$ inches, in large (and 17 cm., or $6\frac{11}{16}$ inches, in small) heads posterior to the nasion, in the median line. Direction of Rolandic Line—forms an angle generally averaging about 70 degrees (extremes 64 degrees to 75 degrees) with the median line. (Formerly the angle was generally considered $67\frac{1}{2}$ degrees. Different writers have given the wide variations covered in the above extremes.) The rolandic line coincides with the rolandic fissure more accurately in its upper part—the inferior genu of the rolandic fissure projecting slightly in front of the rolandic line below its center, corresponding to a point 5 to 15 mm. ($\frac{1}{4}$ to $\frac{5}{8}$ inch) above the lower temporal line. Inferior Rolandic Point—lies on the rolandic line generally 1 cm. ($\frac{7}{16}$ inch) above the sylvian line (v. s.). Length of Rolandic Fissure—generally from 8.5 to 9.5 cm. ($3\frac{3}{8}$ to $3\frac{3}{4}$ inches). (b) Location of Rolandic Fissure by Bony Landmarks; lies entirely under the parietal bone, the superior rolandic point being from 4 to 5 cm. ($1\frac{9}{16}$ to 2 inches) and the inferior rolandic point about 3 cm. ($1\frac{3}{16}$ inches) posterior to the coronal suture.

The rolandic fissure is somewhat further forward and more obliquely placed in children under nine years.

Parieto-occipital Fissure.—A line about 2 cm. ($\frac{13}{16}$ inch) long running transversely outward, at right angle to naso-inial line, from a point averaging about 6 mm., or $\frac{1}{4}$ inch (extremes, from lambda itself to a point 15 mm., or $\frac{5}{8}$ inch), in front of lambda. Where the lambda is not distinct, its position lies from 6 to 7 cm. ($2\frac{3}{8}$ to $2\frac{3}{4}$ inches) above the external occipital protuberance, or 8 to 10 cm. ($3\frac{1}{8}$ to 4 inches) behind the superior rolandic point. The above line represents the external portion of the fissure, the internal portion lying upon the mesial aspect of the hemisphere. (If the horizontal limb of the sylvian fissure be continued backward to the median line, its last 2 cm. —$\frac{13}{16}$ inch—would represent, approximately, the external portion of the parieto-occipito fissure.) In children this fissure lies somewhat further forward.

Precentral Fissure.—Runs downward and forward about 15 mm. ($\frac{5}{8}$ inch) anterior to and nearly parallel with the rolandic fissure. Its upper portion lies from 2 to 3 cm. ($\frac{13}{16}$ to $1\frac{3}{16}$ inches) behind the upper part, and its lower portion from 1 to 2 cm. ($\frac{3}{8}$ to $\frac{13}{16}$ inch) behind the lower part of the coronal suture. Its lower end terminates about 1 cm. ($\frac{3}{8}$ inch) above the sylvian fissure.

Postcentral Fissure.—Runs downward and forward about 15 mm. ($\frac{5}{8}$ inch) posterior to and nearly parallel with the rolandic fissure.

Superior Frontal Fissure.—Line running forward, approximately parallel with the naso-inial line, from the precentral fissure, just internal to mid-distance between temporal crest and median line, to the supraorbital notch.

Inferior Frontal Fissure.—Line running forward and slightly downward from the precentral fissure to just above the superior stephanion (intersection of superior temporal ridge and coronal suture), and thence forward, nearly coinciding with the anterior portion of the temporal ridge.

Intraparietal Fissure.—The ascending portion runs upward for about 1.8 cm. ($\frac{3}{4}$ inch) nearly parallel with and about 1.5 cm. ($\frac{3}{8}$ inch) posterior to the rolandic fissure. The longitudinal portion runs thence backward and

slightly inward just above the parietal eminence, being about 4.5 cm. ($1\frac{13}{16}$ inches) from the median line anteriorly, and about 3.5 cm. ($1\frac{3}{8}$ inches) posteriorly, at a point opposite the lambda.

Superior Temporo-sphenoidal (Parallel) Fissure.—General direction of this fissure is represented by a straight line passing from the retro-orbital tubercle to the lambda, which line coincides more accurately with the temporal part of the fissure. This fissure lies beneath the superior part of the squamous portion of the temporal, and posterior part of temporal portion of parietal, and thence turns upward across the temporal lines and passes under the upper division of the parietal bone. Placed somewhat higher in children.

Ascending Frontal Convolution.—Lies beneath the anterior third of the parietal bone.

Superior Frontal Convolution.—Its base lies under the anterior third of the parietal, and its main part corresponds to somewhat less than the inner half of the frontal region of the frontal bone.

Middle Frontal Convolution.—Its base lies under the anterior third of the parietal; its main part corresponds to somewhat more than the outer half of the frontal region of the frontal bone, and its anterior portion lies under the frontal eminence.

Inferior Frontal Convolution.—Its base lies under the anterior third of the parietal; the apex of its triangular part lies under the anterior inferior angle of the parietal; and its orbital part lies beneath the temporal division of the frontal and superoir end of great wing of sphenoid.

Island of Reil.—Pole of the triangular island of Reil corresponds with the sylvian point. Posterior Angle corresponds with a point on the sylvian line 3.5 cm. ($1\frac{3}{8}$ inches) behind the sylvian point. Superior Boundary is indicated by an evenly curved line, with upward convexity, extending from the posterior angle to the upper extremity of the ascending limb of the sylvian fissure, and thence forward in the same curve 1.5 cm. ($\frac{5}{8}$ inch) beyond a vertical line passing upward from the sylvian point. Postero-inferior Boundary extends from the posterior angle downward and forward to a point on the superior temporo-sphenoidal line directly below the sylvian point.

Parietal Lobe.—Lies beneath the parietal bone, the parietal eminence overlying some part of the supramarginal convolution.

Ascending Parietal Convolution.—Lies between the rolandic fissure and the ascending portion of the intraparietal fissure.

Angular Gyrus.—At the intersection of Reid's posterior perpendicular line (v. i.) and the direct continuation of the sylvian line.

Temporal Lobe.—Lies chiefly beneath the squamous part of the temporal and the posterior and inferior fourth of the parietal—its anterior end lying under the great wing of the sphenoid—its posterior part (inferior temporal convolution) lying beneath the occipital lobe.

Occipital Lobe.—Lies in the cerebral portion of the occipital bone, and sometimes slightly beneath the adjoining parietal.

Basal Ganglia.—Consist of the following; nucleus caudatus and nucleus lenticularis, forming the corpus striatum; claustra; amygdaloid nuclei. The optic thalami lie near the corpora striata, but belong to the thalamencephalon or interbrain. The above ganglia, except the amygdaloid nucleus, lie subjacent to the island of Reil—they extend slightly beyond the limits of the island—and are circumscribed by the curved line limiting the main part of the lateral ventricle (v. i.). The following important white fasciculi are closely related to the corpora striata; inner capsule; outer capsule; anterior commissure; tænia semicircularis.

Lateral Ventricle.—Commencing at the anterior extremity of the Anterior Horn, 1 cm. ($\frac{3}{8}$ inch) in front of the most anterior point of the outline of the island of Reil (v. s.), pass backward along the Body of the Lateral Ventricle in a curve following parallel with and 1 cm. ($\frac{3}{8}$ inch) above the superior boundary of the island of Reil, to a point 2 cm. ($\frac{13}{16}$ inch) behind its posterior limit—thence the Descending Horn curves forward and downward to terminate 1 cm. ($\frac{3}{8}$ inch) below the level of the superior temporo-sphenoidal (parallel) fissure and slightly anterior to a line from the lower rolandic point to the preauricular point—while the Posterior Horn passes backward from this curve, a variable distance, toward the back part of the hemisphere, which is somewhat higher than the occipital pole. Another method of locating the lateral ventricle is to take a point 3.1 cm. ($1\frac{1}{4}$ inches) above and the same distance behind the external auditory meatus (Keen). Ordinarily the lateral ventricle lies at a distance of 5.7 to 6.3 cm. ($2\frac{1}{4}$ to $2\frac{1}{2}$ inches) from the surface.

Naso-lambdoidal Line.—Begins at naso-frontal groove—passes directly backward 6 mm. ($\frac{1}{4}$ inch) above the external auditory meatus to end 1 cm. ($\frac{3}{8}$ inch) above the lambda (or, if that is not recognizable, about 7 cm., or $2\frac{3}{4}$ inches, above the external occipital protuberance). It passes through the lower part of Broca's (inferior frontal) convolution—runs along the posterior limb of the sylvian fissure for 4 to 6 cm. ($1\frac{9}{16}$ to $2\frac{3}{8}$ inches)—touches the lower part of the supramarginal convolution—passes through the base of the angular gyrus—and ends in the parieto-occipital fissure.

Superior Longitudinal Sinus.—Is represented by two straight lines, both beginning together from the mid-point of the naso-frontal suture (foramen cæcum) and slightly diverging as they pass posteriorly, one going to a point opposite the external occipital protuberance and 5 mm. ($\frac{3}{16}$ inch) to its left, the other to a corresponding point 15 mm. ($\frac{3}{8}$ inch) to the right of the external occipital protuberance. This divergence represents the attachment of the laminæ of the falx cerebri forming the sinus, which increases in width posteriorly.

Lateral Sinuses.—Transverse Portion forms a slight curve, with upward convexity, from external occipital protuberance to back of ear, on level with upper border of external auditory meatus. The highest part of the sinus (opposite masto-parietal suture) lies from 1.5 to 2.5 cm. ($\frac{5}{8}$ to 1 inch) above a straight line drawn from the external occipital protuberance to the center of the external auditory meatus and a little external to its center. Sigmoid Portion passes from back of ear, on level with upper border of external auditory meatus, in a sigmoidally curved direction (convexity forward) over the prominence of the mastoid process to its apex, lying generally from 10 to 12 mm., or $\frac{7}{16}$ to $\frac{1}{2}$ inch (extremes, 2 to 12 mm., or nearly $\frac{1}{8}$ to $\frac{1}{2}$ inch), behind the posterior wall of the external auditory meatus, and extending downward about 5 mm. ($\frac{3}{16}$ inch) below the lower border of the external auditory meatus. Distance of sigmoid portion from outer surface of mastoid process is about 7 mm., or $\frac{3}{8}$ inch (extremes, 1 to 15 mm., or $\frac{1}{16}$ to $\frac{5}{8}$ inch). Width of sigmoid portion is about 10 mm., or $\frac{3}{8}$ inch (extremes, 5 to 15 mm., or $\frac{3}{16}$ to $\frac{5}{8}$ inch). (For other data concerning the Lateral Sinuses, see Surgical Anatomy of Brain [page 462], and Relations of Mastoid Antrum, [page 502].)

Middle Meningeal Artery and Its Branches.—For course and relations, see under Surgical Anatomy of the Brain (page 461), and under the Surgical Anatomy in connection with the ligation of those vessels (pages 47–49).

Facial Nerve.—Descends in fallopian canal through the mastoid process, lying between the sigmoid portion of the lateral sinus and the external

auditory meatus (very near the latter). For fuller description of its relations, see under Surgical Anatomy of the Mastoid region (pages 502 and 503).

LOCALIZATION OF BRAIN AREAS.

Description.—The determination of the situation of those areas of the Brain which are concerned with certain functions. These centers do not

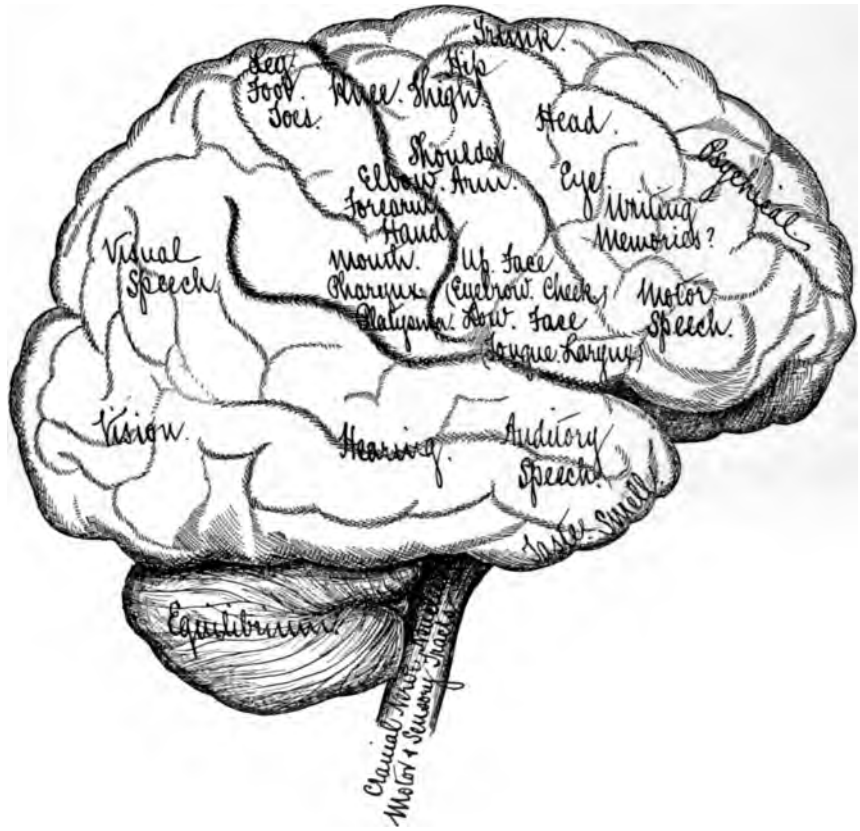

Fig. 311.—LOCALIZATION OF BRAIN AREAS :—Outer aspect of right side. (Modified from Gray, Dalton and Dercum.)

necessarily coincide with fixed convolutions—are not limited in extent by hard and fast lines—often overlap each other—and their position and dimensions are not, in all cases, invariably fixed, nor absolutely ascertained. Each functional center most probably has a wider general representation over the adjacent areas and a more limited special representation, whereby a small area may be removed without total paralysis of that part of the limb specially represented by that area. The following summary may be taken as representing the present state of knowledge of the best authorities.

Sensori-motor Area.—The area of common sensation and motion.

Corresponds with the cortical surface of the anterior and posterior central convolutions, which lie along both sides of the rolandic fissure. Extends, from above downward, from the longitudinal fissure to the sylvian fissure. From before backward, these areas, while chiefly occupying the ascending frontal and ascending parietal convolutions, also occupy convolutions in front of and behind these two chief convolutions. In the right-handed this area is larger upon the left hemisphere.

If this area along the rolandic fissure, from the longitudinal fissure to

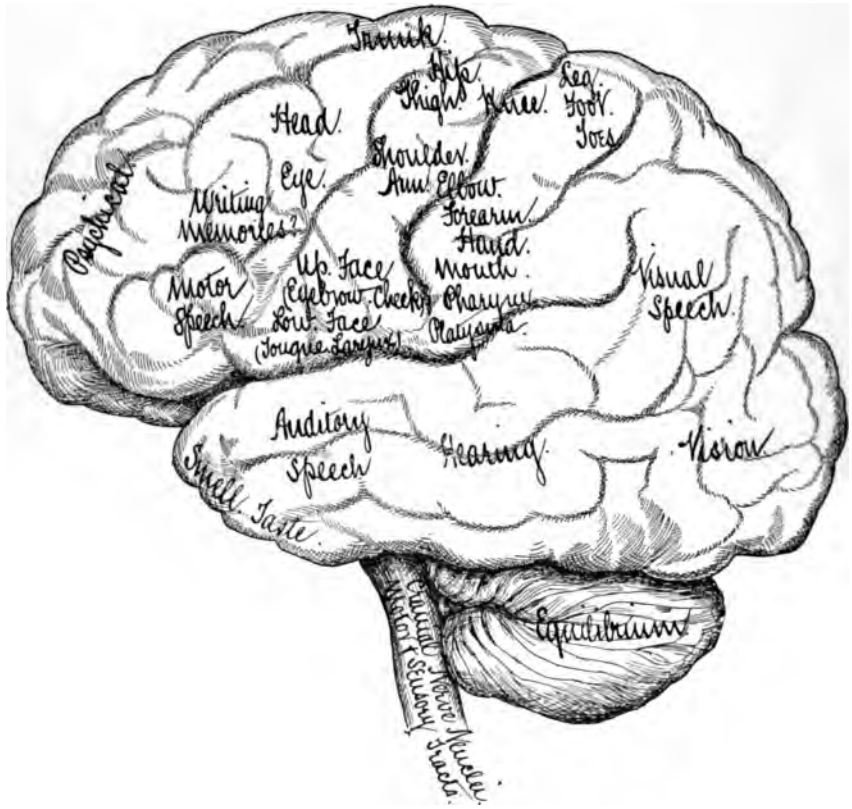

Fig. 312.—Localization of Brain Areas:—Outer aspect of left side. (Modified from Gray, Dalton and Dercum.)

the sylvian fissure, be divided into three approximately equal parts, the functional centers will be distributed as follows; (1) Lower Third of Sensori-motor Area;—(a) In Upper and Forward Part; eyebrows; cheeks; upper face muscles:—(b) In Lower and Forward Part; lower face muscles; tongue; larynx:—(c) In Hinder Part; mouth; pharynx; platysma; (2) Middle Third of Sensori-motor Area:—(a) In Upper and Forward Part; shoulder; arm:—(b) In Middle Part; elbow:—(c) In Hinder and Lower Part; forearm; hand; fingers:—(3) Upper Third of Sensori-motor Area (including the union in the paracentral lobe upon the median aspect of the

hemisphere):—(**a**) In Forward Part; trunk; hips; thigh:—(**b**) In Middle Part; knee:—(**c**) In Back Part; leg; foot; toes. (Figs. 311 and 312.)

In the posterior part of the second frontal convolutions are the centers for the movements of the eyes and head. The sensori-motor area is represented upon the median aspect of the brain in the following order, from before backward;—head; arm; trunk; leg. (Fig. 313.)

Speech Areas.—(In the left hemisphere in the right-handed, and in the right hemisphere in the left-handed.) (**1**) Motor Speech Area (speech memories and power of talking)—in the posterior part of the third frontal convolution. (**2**) Auditory Speech Area (memories of word-sounds)—in first and second temporal convolutions. (**3**) Visual Speech Area (memories of printed words)—in lower parietal region. (**4**) Power of Writing Language

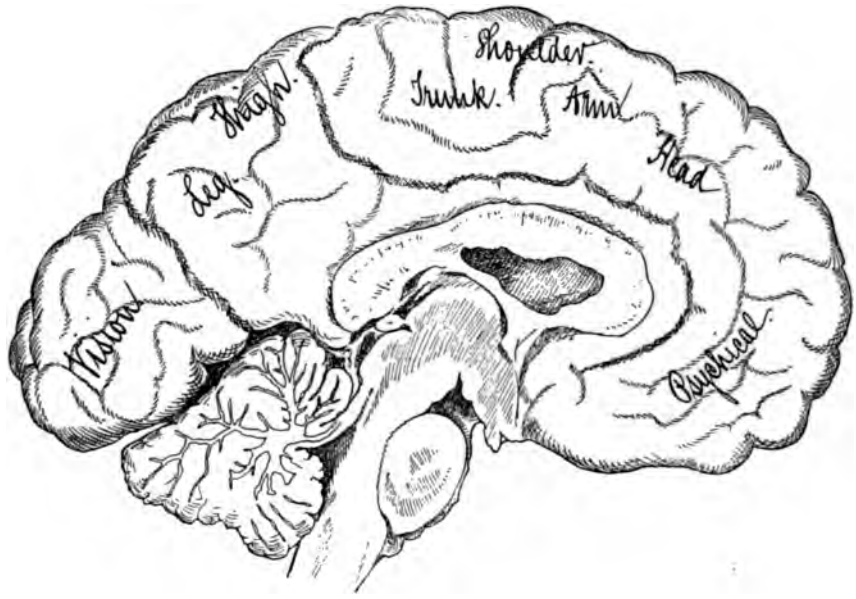

Fig. 313.—LOCALIZATION OF BRAIN AREAS:—Median aspect. (Modified from Gray, Dalton and Ecker.)

(writing memories)—probably in the posterior part of the second frontal convolution, or in the lower parietal convolution.

Area of Sight Sensation.—In the occipital lobe; lying in the cortex of the calcarine fissure and cuneal lobe, upon the median aspect—and upon the convexity of the occipital convolutions, upon the outer aspect.

Area of Sound Sensations.—In first and second temporo-sphenoidal convolutions.

Area of Smell- and Taste-sensations.—Upon the under and inner surface of the tip of the temporo-sphenoidal lobe, resting upon the sphenoidal bone.

Area of Higher Psychical Centers.—Outer and median aspects of the frontal lobes.

Cortex of Basal Surface of Cerebral Hemispheres.—No assignable functions.

Crura Cerebri—Pons—Medulla.—Embrace the centers of various cranial nerve-nuclei—and transmit motor and sensory tracts to the spinal cord.

Basal Ganglia.—Function unknown—disease of these ganglia only made known by also involving the internal capsule.

Cerebellum.—Regulates the equilibrium of the body.

CHIPAULT'S METHOD OF CRANIO-CEREBRAL LOCALIZATION.

Description.—This method of cranio-cerebral localization is based upon the relations of the parts of the brain to the skull, as determined by the percentage measurements of the skull made in the metric system. It is, therefore, equally applicable to skulls of different sizes, shapes, and ages.

Following Fixed Bony Landmarks of Measurement are taken:—Nasion—mid-point of naso-frontal suture (avoid confusing this with the glabella). Inion—external occipital protuberance. Retro-orbital Tubercle—the apophysis upon the posterior border of the upper part of the frontal process of the malar bone, a short distance below the fronto-malar suture. The most prominent part of this apophysis forms the lower limit of the three primary lines of Chipault's method (avoid confusing this with the external angular process of the frontal bone). (Fig. 314.)

Following Percentage Points are Marked upon the Median Naso-inial Line (a line extending in the median line of the head, from nasion to inion)—which percentage points are to become the median or upper limits of lines to be subsequently drawn:—Precentral Point is marked at 45 per cent. of the distance from nasion to inion. Rolandic Point is marked at 55 per cent. of the distance from nasion to inion. Sylvian Point is marked at 70 per cent. of the distance from nasion to inion. Lambdoidal, or Superior Temporo-sphenoidal Point, is marked at 80 per cent. of the distance from nasion to inion. Lateral Sinus Point is marked at 95 per cent. of the distance from nasion to inion. (Fig. 315.)

(Illustration—suppose distance from nasion to inion to be 30 centimeters—then $\frac{45}{100}$ of that distance, or the Precentral point, will be 13.5 cm. from the nasion;—$\frac{55}{100}$, or the Rolandic point, 16.5 cm.;—$\frac{70}{100}$, or the Sylvian point, 21 cm.;—$\frac{80}{100}$, or the Superior Temporo-sphenoidal point, 24 cm.;—$\frac{95}{100}$, or the Lateral Sinus point, 28.5 cm. If measured in inches, and the naso-inial line measured 12 inches, $\frac{45}{100}$ of 12 inches, or the Precentral point, would lie 5.4 inches from the nasion, etc.)

Three Primary Lines are Drawn.—Sylvian Line—from retro-orbital tubercle to sylvian point (70 per cent.)—its anterior portion marking the sylvian fissure. Superior Temporo-sphenoidal Line—from retro-orbital tubercle to lambdoidal or superior temporo-sphenoidal point (80 per cent.)—its anterior part marking the superior temporo-sphenoidal fissure. Lateral Sinus Line—from retro-orbital tubercle to lateral sinus point (95 per cent.)—its anterior part crossing the lower portion of the temporal lobe—its posterior portion marking the upper part of the transverse portion of the lateral sinus, the tentorium cerebelli, and the great transverse fissure of the brain. (Fig. 316.)

These three primary lines are now marked off into tenths of their lengths. (For instance, if the sylvian line measures 21 cm., this line is divided off into ten parts of 2.1 cm. each.)

Two Secondary Lines are Drawn.—Precentral Line—from junction of second and third tenths of sylvian line, to precentral point (45 per cent.)—commencing at the bifurcation of the sylvian fissure, it at first follows the ascending limb of the sylvian fissure, and then corresponds in its two upper thirds to the precentral fissure. Rolandic Line—from junction of third and

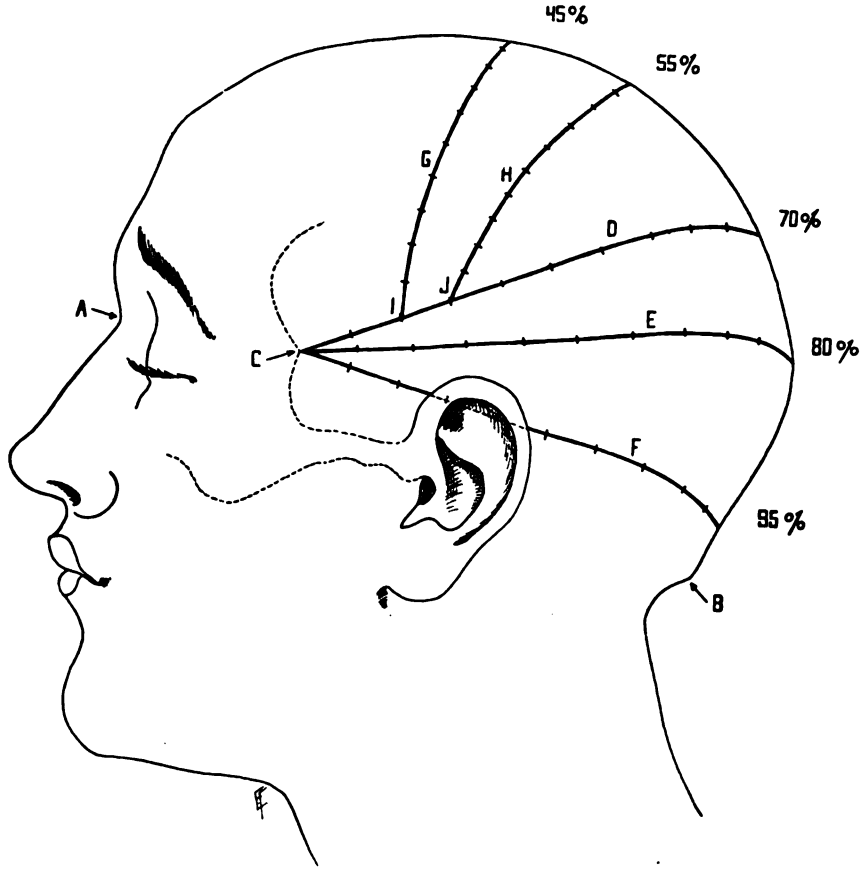

Fig. 314.—CHIPAULT'S METHOD OF CRANIO-CEREBRAL LOCALIZATION—SCALP VIEW:—A, Nasion; B, Inion; C, Retro-orbital tubercle; 45%, or Precentral point; 55%, or Rolandic point; 70%, or Sylvian point; 80%, or Superior temporo-sphenoidal point; 95%, or Lateral sinus point; D, Sylvian line; E, Superior temporo-sphenoidal line; F, Lateral sinus line; G, Precentral line; H, Rolandic line; I, Junction of second and third tenths of sylvian line; J, Junction of third and fourth tenths of sylvian line.

fourth tenths of sylvian line, to rolandic point (55 per cent.)—beginning at lower extremity of rolandic fissure and following its entire length.

These two secondary lines are now divided and marked off into tenths. Thus, with the tenths marked on the three primary lines, sufficient data are furnished for all practical purposes of localization.

Other Points and Lines.—Inferior Frontal Fissure—begins at junction of third and fourth tenths of precentral line Anterior Branch of Middle

Meningeal Artery—crosses the second tenths of the three primary lines. Lateral Ventricle—lies directly opposite the junction of the third and fourth tenths of the superior temporo-sphenoidal line. This point strikes the Body of the lateral ventricle at its posterior part. Hartley has determined that the cavity of the ventricle is reached at a distance from the surface of the brain equal to one-third of the transverse diameter of the brain itself opposite

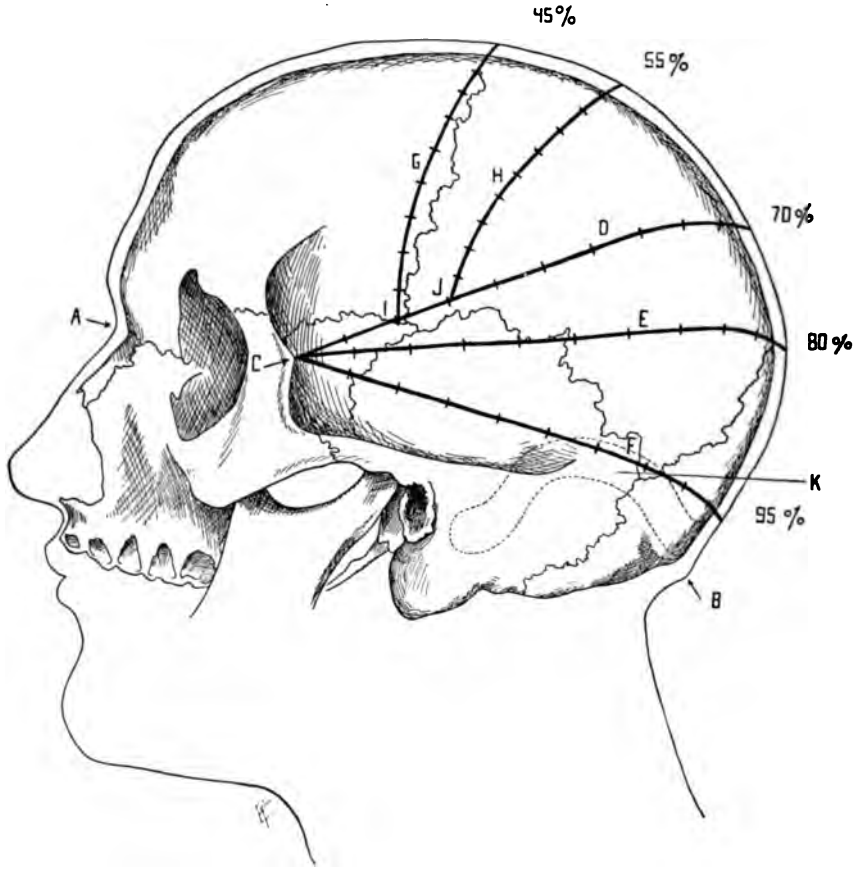

Fig. 315.—CHIPAULT'S METHOD OF CRANIO-CEREBRAL LOCALIZATION—SKULL VIEW:—A, Nasion; B, Inion; C, Retro-orbital tubercle; 45%, or Precentral point; 55%, or Rolandic point; 70%, or Sylvian point; 80%, or Superior temporo-sphenoidal point; 95%, or Lateral sinus point; D, Sylvian line; E, Superior temporo-sphenoidal line; F, Lateral sinus line; G, Precentral line; H, Rolandic line; I, Junction of second and third tenths of sylvian line; J, Junction of third and fourth tenths of sylvian line; K, Lateral sinus.

this point. (For example, take the full diameter of the skull and scalp with calipers, say 15 cm.—take thickness of skull and scalp of the side opened, say 1 cm.—double this for the opposite side—take result of this doubling, say 2 cm., from the total transverse diameter, which will give the diameter of the brain alone, say 13 cm.—take one-third of this, say 4.3 cm.—and enter the brain to that depth upon a direct horizontal line.) To puncture the Descending Horn of the lateral ventricle, Hartley passes through the

middle temporo-sphenoidal convolution in a line directly above the external auditory meatus. To puncture the Posterior Horn of the lateral ventricle, he passes through the middle temporo-sphenoidal convolution in a line with the posterior border of the mastoid process.

Summary.—Having determined the position of the chief fissures of the

Fig. 316.—CHIPAULT'S METHOD OF CRANIO-CEREBRAL LOCALIZATION—BRAIN VIEW:—A, Nasion; B, Inion; C, Retro-orbital tubercle; 45%, or Precentral point; 55%, or Rolandic point; 70%, or Sylvian point, 80%, or Superior temporo-sphenoidal point; 95%, or Lateral sinus point; D, Sylvian line, overlying sylvian fissure; E, Superior temporo-sphenoidal line, overlying superior temporo-sphenoidal fissure; F, Lateral sinus line; G, Precentral line, overlying precentral fissure; H, Rolandic line, overlying Rolandic fissure; I, Junction of second and third tenths of sylvian line; J, Junction of third and fourth tenths of sylvian line; K, Lateral sinus; L, Cerebellum.

brain in the above manner, and knowing the general relations of the convolutions, structures, and functional areas to these fissures, any desired area may be exposed. Preference is given to the method of Chipault over the several others in use, for while none are perfect, or absolutely simple, this method has proved itself quite accurate and fairly easy of application, and furnishes sufficient data from which to locate any desired area of cerebrum or cerebellum.

The manner of applying these (or any other) measurements is to shave the head and mark out the landmarks and the desired areas upon the scalp, by means of a solution of nitrate of silver or a dermographic pencil—then, with a sharp-pointed instrument of small circumference inserted through the scalp to the bone, a slight blow or two is given with a mallet just sufficiently to mark the bone—the soft parts are then turned back and the bone removed by the method elected, preferably some form of motor saw, with or without the aid of previous small trephine-openings outlining the area to be removed. Where a trephine-opening is used as the entire means of exposure, an instrument of sufficiently large diameter should be used to allow of the possibility of a smaller opening not fully covering the area sought. Of course, it is only necessary, in operating in life, to mark out upon the scalp the particular area desired, and then to mark, in the above manner, the corresponding site on the skull—for instance, if one sought a motor center lying along the rolandic fissure, only the sylvian and rolandic points and the sylvian and rolandic lines of the above system need be marked out on the scalp—and only the center of the motor area itself on the bone. For the technique of the operations whereby this method of localization may be applied, see the operations of craniotomy (page 481) and osteoplastic resection of the skull (page 483).

REID'S METHOD OF CRANIO-CEREBRAL LOCALIZATION.

Description.—A method of determining the relations of the principal parts of the brain to the skull, by means of certain lines drawn upon the scalp between known landmarks. (See Fig. 317.)

Fundamental Lines.—Base Line:—a horizontal line from the lowest part of the infraorbital border, through center of external auditory meatus, thence directly backward (Fig. 317, A B). Anterior Perpendicular Line:—from preauricular point (a depression upon the base-line, between tragus and condyle of jaw) to longitudinal fissure (E D). Posterior Perpendicular Line:—along posterior border of mastoid process, from base-line to longitudinal fissure (G F). Some of the structures are located in connection with these lines, and others are located upon other data. An average adult head is supposed.

Longitudinal Fissure.—From mid-point of the naso-frontal suture to external occipital protuberance.

Sylvian Fissure.—Extends from a point 3.1 cm. (1¼ inches) horizontally behind the external angular process to a point 1.8 cm. (¾ inch) below the most prominent part of the parietal eminence (Fig. 317, H J). Main part of the sylvian fissure is represented by the anterior 1.8 cm. (¾ inch) of the above line (H I). Horizontal Limb of the fissure is represented by the remainder of the line (I J). Ascending Limb of the fissure extends from the posterior end of the main fissure vertically upward for 2.5 cm. (1 inch) (I K). Bifurcation of the sylvian fissure, therefore, lies 5 cm. (2 inches) posteriorly to the external angular process, and about 6 mm. (¼ inch) above the level of the external angular process (I).

Rolandic Fissure.—Represented by a diagonal line from upper end of posterior perpendicular line to junction of anterior perpendicular line with the sylvian fissure (L F).

Sigmoid Portion of the Lateral Sinus.—Point on the base-line 1.8 cm. (¾ inch) behind the center of the external auditory meatus (M).

Transverse Portion of the Lateral Sinus.—Point 2.5 cm. (1 inch) behind the center of the external auditory meatus, and 6 mm. (¼ inch) above the base-line (N).

Mastoid Antrum.—Intersection of line drawn along the superior wall

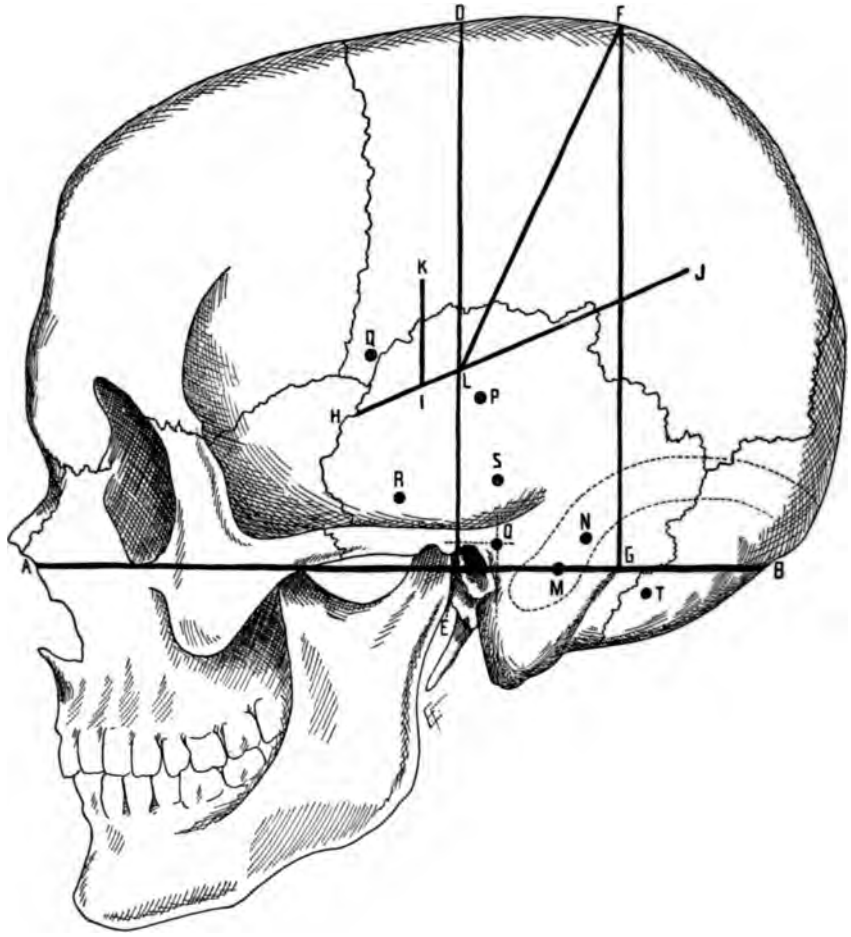

Fig. 317.—Reid's Method of Cranio-cerebral Localization:—A B, Base-line; E, Preauricular point; E D, Anterior perpendicular line; G F, Posterior perpendicular line; H I, Main part of sylvian fissure; I J, Horizontal limb of sylvian fissure; I K, Ascending limb of sylvian fissure; L F, Rolandic fissure; M, Sigmoid portion of lateral sinus; N, Transverse portion of lateral sinus; O, Mastoid antrum; P, Lateral ventricle; Q, Anterior branch of middle meningeal artery; R, Posterior branch of middle meningeal artery; S, Cerebral abscess; T, Cerebellar abscess. (For explanations, see text.)

of the auditory meatus parallel with the base-line, with line drawn along the posterior wall of the auditory meatus perpendicular to the base-line (O).

Lateral Ventricle.—Lies 3.8 cm. (1½ inches) directly above the center of the external auditory meatus (P).

Anterior Branch of the Middle Meningeal Artery.—Encountered

at a point 3.8 cm. (1½ inches) behind external angular process, and 3.8 cm. (1½ inches) above zygomatic arch (Q).

Posterior Branch of Middle Meningeal Artery.—Encountered at a point 4.4 cm. (1¾ inches) behind external angular process, and 6 mm. (¼ inch) above zygomatic arch (R).

Usual Site of Cerebral Abscess.—In the temporo-sphenoidal lobe at a point 1.8 cm. (¾ inch) above the base-line, on a line drawn along the posterior wall of the auditory meatus perpendicular to the base-line (S).

Usual Site of Cerebellar Abscess.—Opposite a point 3.8 cm. (1½ inches) behind center of external auditory meatus, and 6 mm. (¼ inch) below the base-line (T).

CHIENE'S METHOD OF DETERMINING THE ROLANDIC FISSURE.

Take a piece of paper about three inches square—crease it diagonally from A to D, so that A B D coincides with A E D. A E D will then represent an angle of 45 degrees. Then, after opening out the square, crease A B D along A C, so that A B C coincides with A C D, and allow the last folding to remain creased. A C D (half of an angle of 45 degrees) will represent 22½ degrees. Therefore E A C will be equal to an angle of 67½ degrees. Apply figure A E D C to the head so that A E falls upon the median line, with A 1.2 cm. (½ inch) posterior to the midpoint of the line from nasion to inion, with E forward—when the line A C will represent an angle of 67½ degrees with the median line, and, therefore, approximately, the rolandic fissure. (See Fig. 318.)

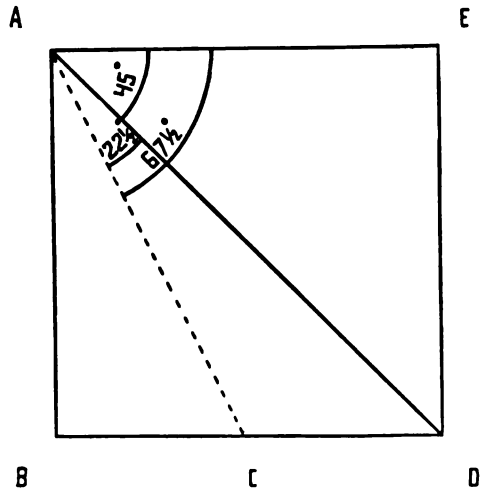

Fig. 318.—CHIENE'S METHOD OF DETERMINING THE ROLANDIC FISSURE:—A B D E, a square; A E D (one-half of A B D E, creased diagonally), an angle of 45 degrees; A B C (one-half of A B D), an angle of 22½ degrees. Therefore E A C represents an angle of 67½ degrees.

As the angle, however, which the rolandic fissure makes with the median line is now generally regarded as somewhat greater than 67½ degrees (see Fissure of Rolando, Cranio-cerebral Topography, page 465), a somewhat greater allowance, say about 70 degrees, should be made.

GENERAL SURGICAL CONSIDERATIONS IN CRANIO-CEREBRAL OPERATIONS.

Relations of Cranial Contents to Cranial Bones.—It has been noted that irregularities of relationships do sometimes occur, and that discrepancies sometimes exist in the statements of the different methods of localizing, as

given by different men of extended experience—but these irregularities and discrepancies are generally so slight that the structures or areas sought are readily accessible through the data given—and if not found directly in the center of the site exposed by operation, are usually within reach of the opening made. As a rule, apparent discrepancies are generally the result of an error in applying the special method of localizing.

Preparation.—Head shaved. Ears cleansed and packed with sterile cotton.

Position.—Patient supine, head elevated upon a firm support, at end of table, and turned so as to give freest access to site of operation. Surgeon on side of operation, or directly behind patient's head. Assistant opposite surgeon, or at his side.

Control of Hemorrhage.—Hemorrhage from the scalp is generally controlled by clamp-forceps, applied immediately upon the completion of the incision, followed by ligation with gut of the clamped vessels. Where extensive bleeding from the scalp is anticipated, especially in removing growths of that structure, a circular constrictor around the lower part of the skull (passing just above the nose and ears and just below the external occipital protuberance) may sometimes be advantageously used—such as the narrow flat band of the Esmarch set, or a rubber tube which flattens as it is applied. To aid in its effectiveness, small compresses may be first placed over the temporal, posterior auricular, and occipital arteries, upon one or, preferably, both sides, and held in place by rubber plaster—and the constrictor applied over these. Intracranial hemorrhage (from middle meningeal arteries, venous sinuses, and the intracerebral vessels) will be specially mentioned among the operations upon the cerebral contents.

Manner of Making the Cranial Section.—The use of a saw (motor or hand, including the trephine, which is practically a circular saw) is preferable for all forms of cranial section. In this category the chain and Gigli saws are also included. Next to the saw, the bone-cutting forceps are to be chosen. And last to be recommended are the various forms of chisels, used with mallets. The only field for these last-mentioned instruments (owing to the concussion caused) is where a moderate blow or two will accomplish the object.

Thickness of Skull.—Average thickness is about 5 mm. ($\frac{1}{5}$ inch). In early life and in old age the skull is thinnest, and at these ages the diploë is absent from the squamous bone, the parietal in the neighborhood of the squamous, and in the fossæ of the occipital. Thinnest parts of the cranial bones—squamous part of temporal; inferior occipital fossæ; over venous sinuses; over frontal sinuses; over grooves for meningeal vessels. Thickest parts of cranial bones—occipital protuberance of occipital; mastiod portion of temporal; lower part of frontal (except over frontal sinuses).

Use of Electrode in Corroborating Motor Centers.—First try to get reaction through dura, without opening this membrane. In applying to brain itself, guard against burning by too strong a current.

Where part of dura is permanently removed, gold-foil, or some similar substance may be advantageously used to prevent cortical adhesions.

Where much brain tissue is removed, as in operations for tumors, etc., temporary packing should be used, to equalize brain pressure.

Cranio-cerebral Operations in Two Stages.—Some surgeons open the cranium, down to the dura, at the first operation—and open the dura and complete the operation several days later—upon the ground of less shock, less hemorrhage, and a better protection of surrounding parts by adhesions.

The majority of operators, however, complete the operation at one sitting, unless specially contraindicated.

INSTRUMENTS USED IN CRANIO-CEREBRAL OPERATIONS.

Scalpels, light and heavy; dissecting forceps; toothed forceps; fine forceps for holding dura, various shapes; artery-clamp forceps; sinus forceps; scissors, sharp and blunt, curved, straight and angular; trephines (of Galt pattern, or with guard), various sizes; trephine brushes; saws, motor and hand; Doyen's saw; chain saw; Gigli saw and carrier; bone-cutting forceps, various sizes and shapes; bone-holding forceps, various; rongeur forceps; periosteal elevator; bone elevator; gouges; curettes; retractors; spatulæ; dural separator; grooved director; probe, with one flat end, to detect depth of trephine cut; tenacula; chisels, various sizes and shapes; mallets; aneurism-needles, various; brad awl; Fluhrer's probe; metal meter measure, in millimeters and centimeters; electrode for diagnosis; measurer of skull-thickness; surgeon's wax for plugging bony canals of vessels; needles, various, especially fine curved; needle-holders; sutures and ligatures, of silk, plain and chromic gut, and silkworm-gut; drains; gauze; rubber-band tourniquet; gold foil; rubber tissue.

CRANIOTOMY IN GENERAL.

Description.—Section of cranial bones. Operations upon the cranio-cerebral region resolve themselves, as far as the operation upon the cranium is concerned, into the making of an opening in the bony vault for the purpose of reaching the object itself of the special operation—and these openings are either simple trephinings, irregular cranial sections, or some form of osteoplastic resection. The operation of cutting through the bones of the skull is, after shaving the head, preceded by either the turning back of a flap composed of the soft tissues of the scalp, or the flap turned back consists of combined soft parts and bone undetached from each other. The flap, in either case, is so planned as to have its pedicle below, that the arteries supplying its nutriment may not be severed. At the end of the operation the flap is dropped back into place and sutured. One or the other of these is the common method of approach, no matter what the subsequent steps may be. When the portion of bone is not returned, the operation becomes, strictly speaking, a partial craniectomy.

Varieties.—(1) Circular Craniotomy, or Trephining; generally performed with the conical (Galt's) trephine. The diameter of the opening thus made may be from 1.2 to 6.3 cm. (½ to 2½ inches). Generally resorted to where a more limited opening will suffice. (2) Linear Craniotomy; division of cranial bones in straight lines—preferably by means of a motor saw, generally preceded by a small trephine-opening through which to begin the section. Generally used as a simple section in the course of some operation. (3) Irregular Craniotomy; openings of irregular outline and varying size, such as may be unexpectedly indicated in the course of some operation. For example, original openings, when found inadequate, may be increased to the desired extent and form by the further application of trephine, saw, chisel, or bone-cutting forceps. (4) Osteoplastic Resection; a form of irregular craniotomy in which an area of scalp and cranium are cut through throughout the greater portion of their extent, but not separated from each other—and are then temporarily turned back, partly by breaking, partly by bending the

unsevered portion—and subsequently replaced. Generally resorted to where the largest openings are required.

TREPHINING, OR CIRCULAR CRANIOTOMY.

Description.—The division of the cranial bones by means of a trephine, preferably of the conical or Galt type—preceded by the temporary turning back of a flap composed of the soft parts. Indications; intracranial hemor-

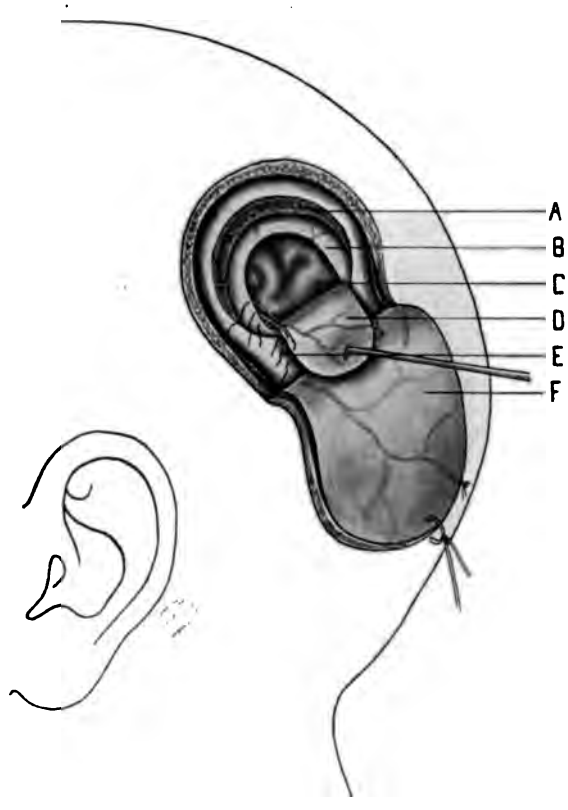

Fig. 319.—TREPHINING, OR CIRCULAR CRANIOTOMY:—A, Circle left by removed disc of bone; B, Incised dura mater; C, Surface of brain; D, Dural flap, with meningeal vessels, turned back; E, Gut-sutures through margins of incised dura and dural flap; F, Scalp-flap, with branches of occipital vessels, turned down.

rhage; abscess; fracture; foreign body; evacuation of cerebrospinal fluid through the lateral ventricle; as a preliminary step to osteoplastic resection and to linear craniectomy; epilepsy; bullet and other wounds; small tumors; drainage of frontal sinus; drainage of mastoid antrum and cells; thrombosis of venous sinuses. (See Fig. 319.)

Preparation and Position.—See General Surgical Considerations in Cranio-cerebral Operations.

Landmarks.—Determined by bony landmarks of skull, or calculated by some method of cranio-cerebral localization, according to special operation.

Control of Hemorrhage.—Ordinarily the hemorrhage is controlled by clamping the arteries in the margin of wound as cut. Excess of bleeding can be temporarily controlled, until arteries are clamped, by digital compression of temporal, occipital, or posterior auricular vessels against the skull. Where much bleeding is anticipated, the arteries may be compressed against the skull by circular constriction, as explained under General Surgical Considerations in Cranio-cerebral Operations (page 479). See also under Comment at end of this operation, and under Operations for Intracranial Hemorrhage (page 489).

Incision.—An incision is made outlining an oval or U-shaped flap, with its convexity toward the crown of the head and its pedicle toward the base, its sides corresponding with the general direction of the vessels and nerves, thus providing for free ingress of arteries into the flap. Where possible, so place the flap as to avoid the main arteries. Size of flap should be considerably greater (at least 1.2 cm., or ½ inch, all around) than the disc of bone to be removed, so that the cicatrix of the soft parts should not overlie the margin of the bone-opening. The center of the soft flap should about correspond with the center of bone-disc to be removed. (The oval-flap incision is distinctly superior to the crucial or other form of incision.)

Operation.—(1) The original incision passes directly through skin, fascia, muscle (or aponeurosis), and periosteum to the bone throughout. Clamp arteries as cut, followed by ligation of main vessels with gut and removal of clamp forceps, so as to avoid encumbering the site of operation with instruments. (2) The periosteum, together with the overlying parts adherent to it, is then detached from the bone, *en masse*, with periosteal elevator (its adherence being firmest along the suture lines), and the entire flap turned down—and either held out of the way by a metallic or thread retractor, or stitched to the neighboring soft parts. (3) When all bleeding has been controlled, apply trephine to desired site, with its pin slightly projecting, withdrawing pin as soon as teeth of instrument have cut a groove in the bone. By repeated right to left pronations and supinations of wrist, continue the half circular movements of the trephine until the section is made through the bone, to but not into the dura. The progress of the trephine is best determined at intervals by withdrawing the instrument and ascertaining the depth of the groove by the tip of the flat end of the ordinary probe, which readily detects the yielding dura. Additional pressure should be made upon that aspect of the incision which is thickest or is least cut, while the trephine is tilted away from the part completely divided. If the teeth of the trephine become blocked with bone-dust, remove such dust with trephine-brush or gauze. Pressure upon the instrument should decrease as the brain is approached. At first, greater resistance in going through the outer table of the skull is offered—then less resistance as the instrument passes through the diploë, and the bone-dust of the diploëtic region is usually more blood-stained—then finally greater resistance is experienced again in passing through the inner table. When section of bone has been almost or quite completed, the button of bone may generally be lifted out by means of an elevator or in the grasp of special curved, thin-bladed trephine-forceps. (4) If more space be required than afforded by the removal of the button, it may be gotten by biting out pieces of bone from the circumference of the opening by means of suitably curved rongeur forceps—or by making an additional contiguous trephine-opening of the same or smaller size, followed by biting out of the intervening bridge-work of bone. (5) The dura mater is now exposed, and should be opened by marking out, on a very small scale, a flap very similar

to the scalp-flap—its pedicle should be placed so as to best preserve its blood-supply (without reference to coinciding with the pedicle of the scalp-flap)—its convexity should lie in the opposite direction and be everywhere sufficiently far from the edge of the bone (at least 6 mm., or ¼ inch) to enable the cut margins of dura to be sutured at the end of the operation. If arteries of fair size cross the dura, they should be ligated, where possible, prior to incising the dura, by passing a small, fully curved needle, armed with fine gut, beneath them, including the dura. Arteries should be tied along the line which will form the convexity of the flap, rather than where they enter its pedicle. If not possible to tie them in advance, they should be caught as soon as cut and tied or twisted. The dura should be carefully incised with a light touch of the point of a fine, sharp knife, or cut with fine curved scissors, aided by grasping the small dural flap with delicate forceps as soon as a margin of it is free, and taking care not to wound the surface of the brain or the vessels coursing over it. (**6**) The special object of the operation, whatever it may be, is now carried out. (**7**) Having accomplished the particular object of the operation, the dural flap is dropped into place and sutured with two or three, or more, fine gut sutures, by means of a small, fully curved needle held by needle-forceps, while the dura is steadied by fine forceps. (**8**) The opening in the bone may now be treated in one of several ways: (**a**) Left without replacement of any bone-tissue, which is especially done in the making of small trephine-openings;—(**b**) The button of bone may be replaced intact upon the dura, and the soft flap of periosteum and other tissues brought over the button—a method which may be pursued in dealing with buttons of larger size;—(**c**) The button may be divided into parts by fragmentation and sprinkled over the dura, where they form the nucleus of new bone growth;—(**d**) A celluloid, metallic, or gutta-percha plate may be placed in the opening. In trephinings of small diameter the button is not generally replaced. In large openings some surgeons do, and some do not, replace the button, whole or fragmented, or some artificial covering. Where the button, either intact or fragmented, is used, it is dropped into warm normal salt solution as soon as removed. (**9**) The flap of scalp tissues is now brought back into its original position—the edges of the periosteum are sutured with catgut—and the edges of the overlying soft parts are sutured interruptedly with silkworm-gut, silk, or catgut, passing through all the soft tissues down to the periosteum. (**10**) No drainage is ordinarily used unless specially indicated—and, if indicated, a few strands of catgut, horsehair, silk, or gauze suffice. A full dressing is applied.

Comment.—Bleeding from the diploë may be stopped by compressing a small part of the bone upon the vessel with bone-forceps, or by plugging with catgut or surgeon's wax Bleeding from the dura may be checked by fine catgut ligature. For bleeding from venous sinuses, see Ligation of Longitudinal and Lateral Sinuses (page 490).

It is probably always best to open the dura in all cases of trephining.

OSTEOPLASTIC RESECTION OF SKULL.

Description.—Temporary partial displacement of a section of the skull, together with its overlying soft parts unseparated—accomplished by partly bending, partly breaking backward, the base of the bony section from the dura, upon a hinge, as it were, of the soft parts, without complete severance

of the vascular supply—followed by the replacement of the flap of bony and soft parts into apposition. (See Fig. 320.)

(The replacement of a trephined button of bone is, strictly, an instance of osteoplastic resection with temporary complete displacement of the excised piece of bone.)

Indications. For exploration; tumors; intracranial abscess; intracranial

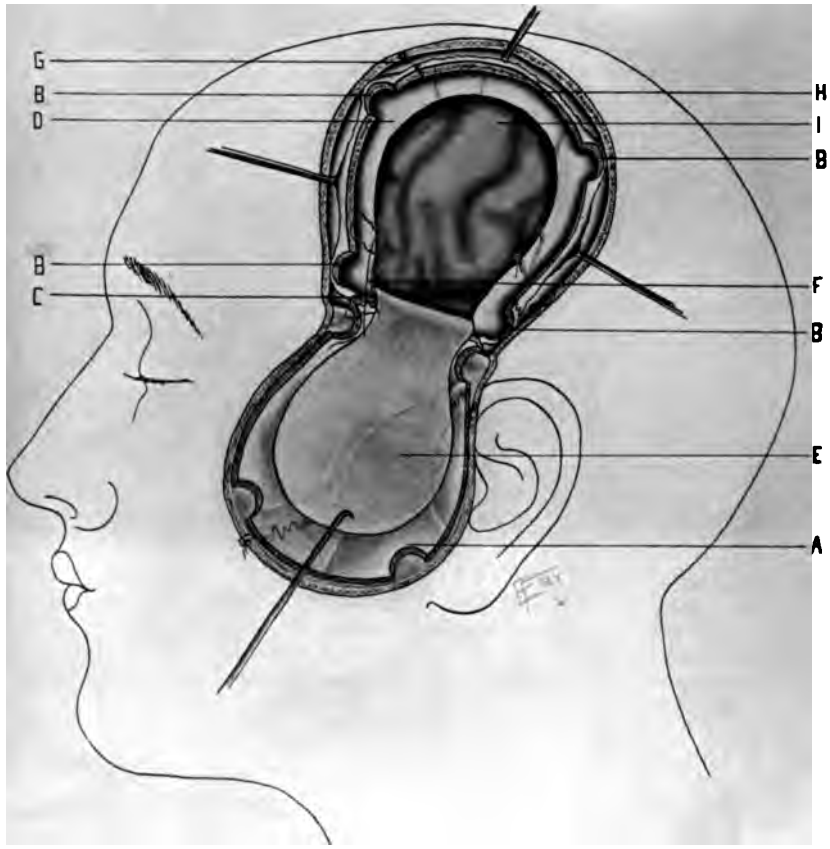

Fig. 320. OSTEOPLASTIC RESECTION OF THE SKULL.—A, Cutaneo-musculo-osseous flap temporarily turned back; the component parts adherent, and with scalp vessels cut along the margin; B, B, B, B, Four trephine openings made preceding the sawing of the bone; C, Line along which the bone was cracked back; D, Incised dura, with divided vessels ligated; E, Dural flap turned back; F, Gut-sutures through margins of incised dura and dural flap; G, Periosteum retracted from line of saw-cut; H, Margin of skull left by temporary removal of osteoplastic flap; I, Surface of brain.

hemorrhage; exposure of Gasserian ganglion; wounds. In general, where the freest access to brain is required.

Preparation and Position. See under General Surgical Considerations in Cranio-cerebral Operations (page 478).

Landmarks. Same as for trephining (*q. v.*).

Control of Hemorrhage from Scalp. Hemorrhages ordinarily controlled as in trephining (*q. v.*). Where extensive hemorrhage is anticipated

the vessels may be controlled by circular constriction, as explained under General Surgical Considerations in Cranio-cerebral Operations.

Form of Cranial Opening.—(1) The best and general form is that of a horseshoe, with its broader convexity upward and its more contracted base downward (Fig. 320)—or an Ω-shaped flap, the horizontal cuts at base (which may or may not be made) serving as liberating incisions. (2) A square, or a rectangular piece longer than broad, may be used—though the process of bending backward is always aided if the base be somewhat narrower than the free portion. (3) A second horseshoe, or square of bone, may be turned back, if the original flap do not furnish sufficient room—the second being either turned back in an opposite direction from the first but in the same line; or from one side of the original opening.

Incision of Scalp.—The form of scalp incision will be regulated by the previously determined form of bone section. Having decided this, the incision through the soft parts should conform, in general outline, with the bone section to be made, but should extend at least 1.2 cm. (½ inch) beyond the line of bone section so that the cicatrix of soft parts will not fall directly over the line of bony union or repair. The incision should be so placed, where possible, as to give free ingress of the neighboring arteries into its substance, especially the chief artery of the region. The removal of an area of bone greater than 7.5 cm. (3 inches) square is rarely called for—and this would require a skin-flap at least 10 cm. (4 inches) broad.

Operation.—(1) The incision passes everywhere through skin, fascia, muscle, aponeurosis, and periosteum directly to the bone. Or the incision may pass down to the periosteum—these allowed to retract, and periosteum cut on line of retracted soft parts, midway between the line of the skin incision and the line of the bone incision so that periosteal and skin cicatrices do not fall together, nor periosteal and bony cicatrices coincide. (2) A rim of periosteum, without separating the overlying soft parts, is carefully detached to the extent of about 1.2 cm. (½ inch) around the horseshoe flap, separating it chiefly toward center of flap, and but slightly upon the outer edge of the incision. (3) Having exposed the entire area for the bone section, the bone is divided about 6 mm. (¼ inch) inside of the division of the periosteum in one of the following ways:—(a) Division of horseshoe figure of bone by motor saw, preferably preceded by a trephine-opening, and the brain guarded throughout by a dural separator traveling with the saw between the bone and dura—a motor saw capable of following a curve is necessary, and very great care is needed in protecting the brain and in approaching the dura if a dural separator be not used. The saw should be held in such a way as to bevel the bone-flap at the expense of its inner surface, so that, when replaced, it will rest upon a ledge of bone furnished by the margin of the opening and be thus prevented from pressing upon the brain. (b) Division of horseshoe figure of bone by Gigli saw, preceded by several small trephine-openings. Four or six small trephine discs of bone, 1.2 cm. (½ inch) in diameter, may be removed along the line of section—a pliable dural separator is then passed from hole to hole, detaching and depressing the dura from the skull—a Gigli saw is then conducted beneath the bone by a special carrier, between two contiguous holes, and the bone divided—and this repeated until the section is completed—the saw beveling the bone as above. (c) Division of a horseshoe figure of bone by a specially grooved chisel which cuts a narrow furrow—but which also involves much jarring to the brain. (4) When the bone has been divided throughout down to the base of the bone-flap, provision must be made for the bending and breaking back of the bone at the site which

will form the hinge of the osteoplastic flap—this hinging of the flap may be accomplished in one of several ways;—(a) When all is in readiness, and without having previously partly divided the bridge of bone at the base of the flap, a stout steel elevator may be inserted under the edge of the convexity of the bone-flap (that part opposite the narrow base of the flap) so as to rest upon the intact portion of the skull—the fingers of the surgeon's left hand pressing upon the skull immediately below the line where it is sought to bend and break the bone—and then with a sudden, sharp (not slow and deliberate) movement of the lever the bone is sprung back—and generally breaks accurately enough for all practical purposes, and drops outward and downward still clinging to its hinge of soft parts. (b) To insure a more accurate line of breakage, as well as against splintering of the bone and wounding of the brain, two small trephine-openings may be made immediately opposite each other, at the base of the bone-flap and on the line to be broken—a pliable dural separator is now passed between the openings—a Gigli saw is conducted beneath the bone—and the bone is sawed sufficiently far through, especially at its edges, to insure an accurate breakage and freedom from splintering when the elevator is used as a lever as just described. (5) As the bone is broken back, it is separated from the dura, where not already detached by dural separator or otherwise. The osteoplastic flap of bone and soft parts is allowed to fall back upon its hinge out of the way. (6) Before proceeding, all bleeding from the diploë is controlled by pressure, plugging the openings with catgut or sterilized wax, or by gently crushing the bony opening together with bone forceps. (7) The dura is now opened in the form of a flap, by picking it up with two forceps, incising with knife, and further cutting with curved, blunt scissors (just as described in trephining, *q. v.*), the division being made sufficiently far from the margin of the bone (at least 6 mm., or ¼ inch) to allow of suturing—and this little flap should be so planned as to preserve the arteries intact which enter its base, ligating them with fine catgut only where they cross the line of incised dura (they are best taken up in advance by passing a small, fully curved needle beneath them). The position of the base of the small dural flap will be determined by the position of the dural vessels, and while it need not necessarily correspond with that of the osteoplastic flap, yet it usually does so in a general way. (8) The dural flap having been turned back out of the way, the surface of the brain is exposed and the special object of the operation accomplished. (9) Upon the completion of the operation the dural flap is sutured back with fine gut to the margin from which cut. (10) The question of drainage of the cerebral structures will be determined by the special operation. If used, provision must be made for silkworm-gut or catgut strands to pass through an unsutured part of the dura. (11) The osseo-cutaneous flap is now turned back into place. The previously freed margin of periosteum clinging to the bone-flap is sutured with interrupted catgut sutures to the margin of the main periosteum from which cut. If muscles of any thickness have been involved, these are united by buried catgut sutures. Finally, the skin wound is closed with silk, silkworm-gut, catgut, or silk, by means of interrupted sutures. If drainage of the extracranial wound be indicated, it is accomplished by strands of silkworm-gut, horsehair, catgut, gauze, or fine drainage-tubing, brought out through an opening made by biting a half-button of bone from the edge of the bone-flap with rongeur forceps. If intracranial drainage be used, it is brought out through this half-button opening—and then serves as an extra-dural and extracranial drain as well.

Comment.—The narrower the pedicle of the horseshoe flap of bone, the easier it is to crack it across at its base, but it should be broad enough to insure nutrition of the osteoplastic flap.

The edges of the bone of the osteoplastic flap and the margin of the cranium may be drilled and the borders of bone united (if thought necessary) by chromic gut sutures. If the osteoplastic flap be beveled, as always should be if possible, suturing is not necessary—and is not generally necessary anyhow, as the adherent scalp usually holds the bone up in place.

It is best to open the dura in all cases calling for osteoplastic resection of the skull.

LINEAR CRANIOTOMY.

Description.—The division of the cranial bones in one or more straight lines variously placed—an operation sometimes resorted to in microcephalus for the purpose of giving increased room to the brain. No portion of the bone is removed, except the buttons of bone from the trephine-openings made preliminary to the use of the saw. (While craniotomy is performed in microcephalus, craniectomy, or the removal of a definite piece of bone, is probably a preferable operation for this purpose.)

The operation of craniotomy is included under that of craniectomy (*q. v.*).

PARTIAL CRANIECTOMY.

Description.—Removal of a section of the cranial bones from one or both sides of the head,—an operation sometimes done in microcephalus for the purpose of increasing room for the growth of the brain.

(Strictly, in trephining and other cranial operations where the button or part of bone is not returned, the operation becomes a Partial Craniectomy though the term is not here used in that sense.)

Preparation and Position.—See under General Surgical Considerations in Cranio-cerebral Operations (page 478).

Landmarks.—Nasion and inion, and the general bony landmarks of the skull.

Control of Hemorrhage.—By means of a flat rubber tourniquet wound several times around base of skull, small compresses having been placed over the main arteries of the scalp and held in place by the tourniquet—as described under General Surgical Considerations in Cranio-cerebral Operations. This method of control is generally indicated, as hemorrhage is apt to be marked.

Incision.—From the junction of the skin of the forehead with the hair, to the inion—passing slightly external to the median line.

Operation.—(1) The incision of the soft parts passes through the skin, fascia, muscle, aponeurosis, and periosteum to bone. Clamp all bleeding vessels uncontrolled by constrictor and ligate the chief ones with gut. (2) The soft parts are raised from the bone by periosteal elevator and turned downward, being held out of the way by retractor, or a stitch or two. The flap thus turned back will be represented by practically the soft parts of one entire side of the skull. (3) Having exposed a large area upon one side of the skull, and having controlled all further hemorrhage, the amount, position, and shape of bone section are determined. An area of bone in the form of a narrow parallelogram represents the section of bone most usually removed,

though other forms of bone-section are used. Supposing the parallel lines representing this figure to be 1.2 cm. (½ inch) or 1.9 cm. (¾ inch) apart, a trephine-opening is made at either end of this figure with a diameter of 1.2 cm. or 1.9 cm. (½ or ¾ inch) accordingly. If the distance between the trephine-openings be too long for a dural separator and guide to travel, one or more intermediate trephine-openings should be made. A pliable dural separator is then passed from opening to opening between bone and dura and traveling in two parallel lines corresponding with the upper and lower margins of the circumference of the trephine-openings. A grooved guide is then passed in the tracks cleared by the dural separator to protect the brain, and the bone then divided in two parallel lines with an electric motor saw (the Powell electric saw answering the purpose well)—first in a line with the upper margins of the trephine-openings and then in a line with the lower margins of these openings. By properly directing the saw both ends of the section may be pointed, going beyond the trephine-openings at both ends. The bone section is best made with a motor saw—it may be made with rongeur forceps—but preferably not with chisel, as chiseling causes too much jarring. In using an ordinary motor saw a trephine-opening is necessary wherever the direction is changed. A Gigli saw passed between the openings also answers well. (4) If there be no special indication for exploration, the dura is not opened. If opened, it is so incised as to admit of subsequent suturing. (5) The bone, of course, is not replaced. The soft parts are sutured into position. No drainage is ordinarily used.

Comment.—(1) Hemorrhage from the diploë is apt to be great and may have to be controlled by plugging with catgut or aseptic wax, by crushing together the walls of the bony canals, or by gauze pressure. (2) Probably it is best to operate upon the second side of the head at a subsequent date. (3) A grooved director for the saw can be used—or the dural separator may be grooved. (4) Where craniotomy is done instead of craniectomy the saw travels only once between the trephine-openings, which are merely large enough to allow of separation of dura and passage of a guide—and no bone (other than the trephine-buttons) is removed. A crescent-shaped piece of bone may be removed, instead of a piece of the above-described shape.

EXPLORATORY PUNCTURE OF THE BRAIN.

Description.—For the purposes of exploration, the needle of an aspiratory syringe may be thrust into the brain substance, especially where pus and fluid tumors or hemorrhage are suspected—the brain having been exposed through a small trephine-opening. A solid needle, or special probe, may be used for the detection of solid bodies.

Preparations and Position.—See General Surgical Considerations in Cranio-cerebral Operations (page 478).

Landmarks.—Position of some lesion and localization symptoms, taken in connection with the special structures to be avoided.

Incision.—That for ordinary trephining.

Operation.—(1) Is the same as that for trephining, up to the raising of the dural flap and the exposure of the brain. (2) The needle is then steadily thrust into the brain in a straight line in any direction indicated by the phenomena present, avoiding the venous sinuses, large vessels, basal ganglia), and ventricles (unless puncture of the latter be indicated). The needle should be withdrawn after each puncture. Whenever it is desired to explore in another direction, the needle is reinserted and always carried in a straight

line, without side to side movement. (3) Having accomplished the object of the operation, or after meeting with a negative result, the wound is closed as after trephining.

Comment.—For further data as to exploratory puncture of the intracerebral structures, see Operations for Cerebral and Cerebellar Abscess (pages 496 and 497), Tumor (pages 498, 499), and Hemorrhage (page 489).

OPERATION FOR INTRACRANIAL HEMORRHAGE IN GENERAL.

Varieties of Intracranial Hemorrhage.—(1) Epidural (Extra-dural); between cranial bones and dura—may be arterial or venous. If arterial—generally from middle meningeal or its branches. If venous—generally from the superior longitudinal, lateral, or occipital sinus. (2) Intrameningeal; if arterial, generally from middle meningeal or branches. If venous, frequently from veins connected with longitudinal or other sinus. If capillary, generally due to traumatism, and site dependent upon trauma. If subdural (into subdural space), it may be caused either by rupture of dura, and is then generally from the middle meningeal vessels; or by a vessel of the pia rupturing through the arachnoid. If subarachnoidean (between arachnoid and pia mater), it is due either to rupture of vessels of pia into the pia-arachnoid, or to rupture of middle meningeal through dura and arachnoid. (3) Intracerebral: generally from middle cerebral or one of its branches, especially the lenticulo-striate.

Only the general features of intracranial hemorrhage will be here considered. For specific operations for hemorrhage from the middle meningeal artery and its anterior and posterior branches, and from longitudinal and lateral venous sinuses, see ligations of those structures (pages 47, 48, 49 and 490).

Preparation and Position.—See General Surgical Considerations in Cranio-cerebral Operations (page 478).

Landmarks.—Determined by circumstances of particular case and by general cranio-cerebral topography. Site of hemorrhage may be determined by external injury or by localization symptoms.

Incision.—As for trephining or osteoplastic resection (according to size of opening required), and placed in accordance with nature of case.

Operation.—(1) Having exposed the area involved, either by a trephine-opening or osteoplastic section (the steps of the operation up to this point being, in all essential features, those of one or the other of these procedures), the site of the blood-clot, if any, is located and the source of the hemorrhage traced. (2) The clot is carefully turned out with such an instrument as the handle of a thin silver spoon—the bleeding vessel is sought and doubly ligated with gut. The dura must, of course, be opened if hemorrhage be subdural—and it is even best to open it though hemorrhage appear to be only epidural, for the sake of verification. Where the hemorrhage comes from the middle cerebral an attempt should be cautiously made, when possible, to reach the site of hemorrhage, by carefully separating the lips of the sylvian fissure and doubly tying the artery with gut. If site of hemorrhage cannot be accurately ascertained and still continues, all that can be done is to carefully pack the region with gauze. (3) Finally, carefully irrigate with warm normal salt solution (except where packing is used)—drain if necessary—closing wound as after simple trephining or osteoplastic resection.

Comment.—If no accurate data lead to source of hemorrhage, it is best

to seek first in the position of the anterior branch of middle meningeal artery —then in the position of the posterior branch.

LIGATION OF TRUNK OF MIDDLE MENINGEAL ARTERY.

See under Ligation of Arteries (page 47).

LIGATION OF ANTERIOR BRANCH OF MIDDLE MENINGEAL ARTERY.

See under Ligation of Arteries (page 48).

LIGATION OF POSTERIOR BRANCH OF MIDDLE MENINGEAL ARTERY.

See under Ligation of Arteries (page 49).

LIGATION OF LONGITUDINAL OR LATERAL SINUS.

Description.—The longitudinal and lateral sinuses are sometimes accidentally injured in operation, or otherwise, or lie directly in the course of some operation—under which circumstances it becomes necessary to control hemorrhage from them, which, when possible, should be done by ligation. (See Figs. 321 and 342.)

Preparation and Position.—See General Surgical Considerations in Cranio-cerebral Operations (page 478).

Landmarks.—Determined by site of sinus involved.

Incision.—Often determined by a preceding injury or local condition —or circumstances calling for ligation may accidentally arise during the course of some other cranio-cerebral operation. If deliberately planned to tie the longitudinal or lateral sinus in the path of an operation (as, for example, preliminarily to exposing a surface of brain more or less covered by a sinus), two small trephine-openings are made on either side and very near the borders of the sinus, after having exposed the site of both trephine-openings by turning back a single oval flap. For course and deviations of the sinuses, see Surgical Anatomy of the Cranio-cerebral Region (page 468).

Operation.—(1) Complete the operation, up to the removal of the two buttons of bone, as an ordinary trephining. (2) The dura and, with it, the sinus are detached from the cranium by passing a dural separator between the bone and dura, from one to the other of these two small trephine-openings immediately adjacent to the outer borders of the sinus. The bridge-work of bone between the two openings is then cut away, preferably with Gigli saw (cutting pliers or rongeur forceps). A limited longitudinal incision of the dura is made safely to the outer aspect of each side of the sinus, which enables a more intelligent and safer passage of the ligature than if it were simply carried blindly beneath the supposed lower limit of the sinus. The sinus is thereby fully exposed and is doubly ligated transversely with chromic gut, by passing a fully curved needle beneath the sinus and through the falx cerebri, and divided between the ligatures. If the sinus be wounded to a limited degree, it is often possible to either laterally ligate the rent, or suture it—as described under the ligation of veins. (3) The operation is completed as indicated by the special circumstances attending it—the button of bone

being replaced, or not, according to the judgment of the operator. Drainage would be used or not, as indicated (generally not, if all bleeding be controlled and wound be clean). The flap of soft parts is sutured into place.

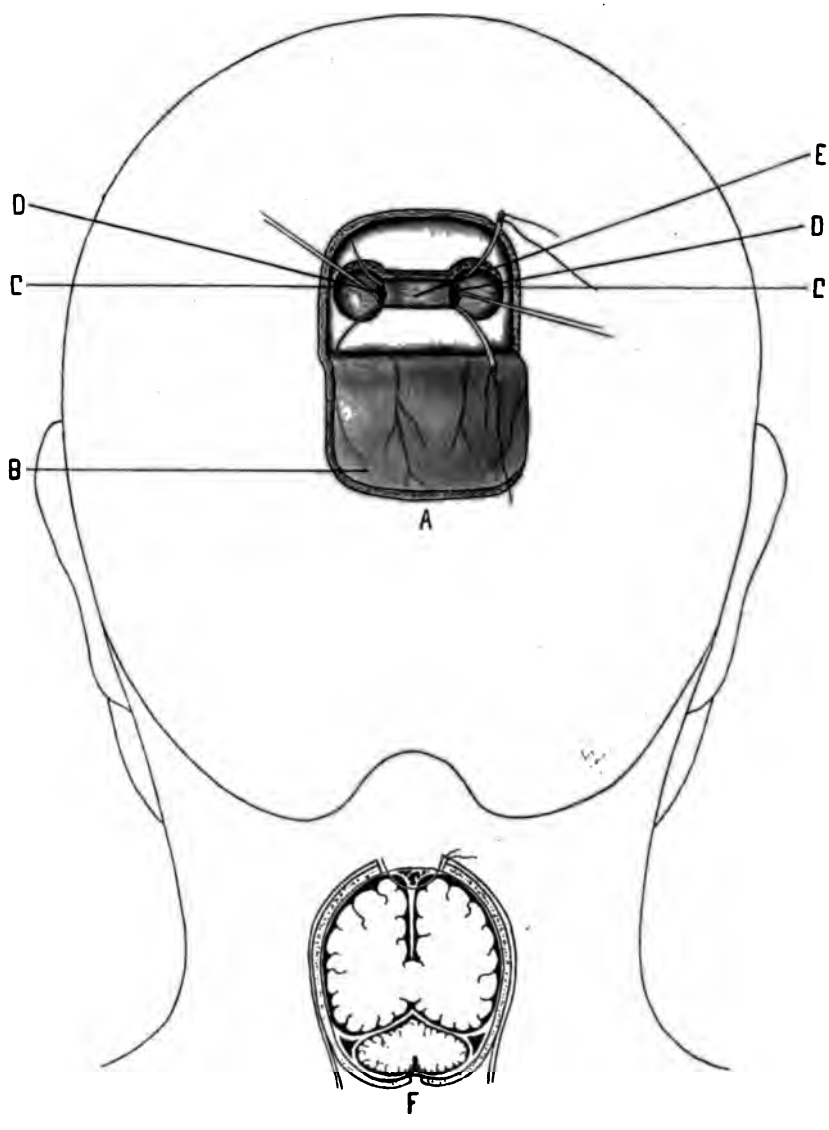

Figs. 321 and 322.—LIGATION OF THE LONGITUDINAL SINUS:—A, Exposure of longitudinal sinus by means of two trephine-openings on either side, followed by cutting away the intervening bridge of bone; B, Scalp-flap turned back; C, Two trephine-openings made near the outer borders of the longitudinal sinus, with intervening bone cut away; D, Incisions through dura, on either side of sinus, for passage of needle and ligature; E, Longitudinal sinus; F, Cross-section of head, showing position of sinuses.

OPERATION FOR THROMBOSIS OF LATERAL SINUS.

Description.—As a result of otitis media, the adjacent sigmoid and transverse portions of the lateral sinus frequently become infected and undergo sinus phlebitis and thrombosis, requiring their exposure, the removal of thrombosed contents and their obliteration by ligature or otherwise. The operation is intimately connected with that for the exposure of the mastoid antrum and cells, which should be reviewed in this connection (page 500).

Preparation and Position.—See General Surgical Considerations in Cranio-cerebral Operations (page 478).

Landmarks.—Lines for sigmoid and transverse portions of the lateral sinus. (See Surgical Anatomy, page 468, and also Fig. 324, L M.)

Incision.—Where this sinus, at junction of transverse and sigmoid portions, is independently exposed, a horseshoe flap is turned down, with pedicle below, so planned as to expose an area with its center about 2.5 cm. (1 inch) behind and 6 mm. (¼ inch) above the center of the external auditory meatus. Where the opening-up of the neighboring sinus is simply a continuation of the mastoid operation (which is usually the case) the incision for the exposure of the sinus is prolonged from the original incision.

Operation.—(1) Proceeding as in the operation of trephining, a trephine having a diameter of about 2.5 cm. (1 inch) is applied over this center and a button of bone carefully removed, without injury to dura and without premature opening of sinus. Whatever additional room may be required can be gotten by biting out the circumference of the trephine-opening by means of rongeur forceps. (2) Thrombosis having been determined by palpation and exploratory needle, the thrombosed sinus is now laid open longitudinally and the contents carefully turned out with a special scoop, as far as accessible in both directions, or until a patulous condition is reached, when the flow is controlled by gut ligature of the sinus, if possible, or by gauze packing. (3) The mastoid antrum and cells, the usual source of the original infection, are generally opened up into continuity with the sinus by means of a gouge, sharp spoon, or chisel. (4) The internal jugular vein is often exposed in the neck, when found in a condition of thrombosis, and ligated. The thrombosed vein may then be opened above the ligature and the vein irrigated from the lateral sinus, and vice versa. (5) The wound is packed, and closed only in part, room being left for drainage.

Comment.—If contents of lateral sinus be fluid, the sinus, if possible, should be ligated prior to opening the thrombosed part. A firm, healthy clot, about to undergo organization, may sometimes be left on the distal side of a ligature.

TREPHINING FOR FRACTURE OF SKULL.

Description.—The seat of fracture is exposed, the depressed pieces of bone are elevated to the common level, and any spiculæ of bone which may be exercising pressure upon the brain are removed.

Preparation and Position.—See General Surgical Considerations in Cranio-cerebral Operations (page 478).

Landmarks.—Determined by the nature and site of the fracture and general cranio-cerebral topography.

Incision.—Where a skin wound exists, this is usually enlarged, or used

as a part of the incision for the exposure. Where the skin is unbroken, the site of fracture is best exposed through a U-shaped flap, as in trephining.

Operation.—(1) The soft parts, including the periosteum, are turned back, in the same manner as in trephining, and site of fracture thus exposed —hemorrhage being controlled as in that operation. Even where the bones of a depressed fracture can be raised by being levered back into position without exposing the brain (which often can be done), it is always best to expose the dura at least—and safer still to open the dura and examine the surface of the underlying brain. (2) The following steps of the operation are conducted very much as in ordinary trephining. The point of the trephine is placed upon sound bone that will resist pressure, avoiding the site of vessels and sinuses, and in a position from which the fractured bone can be best raised—with the major portion of the circle (which should be from 1.2 to 1.8 cm., or ½ to ¾ inch) generally lying over sound bone, and the inner portion overlapping or coming in line with the fractured margin. When the button of bone is removed, if more room be needed, it can be gotten by biting out portions of bone with rongeur forceps. (3) A blunt elevator (an osteotome answers well) is now carefully inserted beneath the fractured bone, resting upon the sound margin of bone, or upon an instrument or a finger stretched across the area as a fulcrum, and the fractured bone levered back into place, without disconnecting it from its natural attachments. (4) Sometimes judicious use of chisel or saw will aid in freeing the fragments. All sharp edges are rounded off. All pieces likely to become detached are removed. (5) The dura, if deliberately opened by the operator, is repaired as after trephining—if wounded by fragments, is repaired by catgut suturing as fully as possible. (6) The manner of treating bone space left by trephining for fracture is the same as after simple trephining. Drainage is used, if indicated—and the wound entirely or partially closed in accordance.

OPERATION FOR BULLET WOUND OF BRAIN.

Description.—For the purpose of seeking the bullet, removing spiculæ of bone and foreign material, and for providing drainage.

Preparation and Position.—See General Surgical Considerations in Cranio-cerebral Operations (page 478).

Landmarks.—Determined by position of wound and position of important underlying structures and areas.

Incision.—An oval (or reversed U-shaped) flap, with pedicle downward, and center corresponding with wound.

Operation.—(1) The soft parts are incised to the bone, the vessels clamped and tied, and the flap raised and turned back. If trephining were not contemplated, the periosteum need not be raised with the flap—but as the use of the trephine or that of the rongeur is practically always indicated, the bone should be completely bared. (2) Access to the brain may be gotten by biting out the circumference of the wound-opening with rongeur forceps, or, better, by trephining with a trephine whose diameter is sufficiently large to make a cut extending around the wound 1.2 to 1.8 cm. (½ to ¾ inches), according to accompanying circumstances, and with the precautions observed in trephining for fracture (*q. v.*). All fragments of bone are removed or elevated into position—and all foreign material is picked out with forceps as encountered. (3) Having thus enlarged the bullet wound, the bullet is sought along its track with such instruments as a long, delicate needle, Fluhrer's

aluminium probe, or Girdner's telephone probe. If the bullet can be reached with special forceps, it may be withdrawn by that means through the original wound, especially if near it. If the bullet be near the far end of the wound-track, it is generally more readily and safely removed through a counter-opening. Such a counter-opening may be made at a point determined by thrusting a probe along the track of the wound, directly in the line of the bullet-track, to the inner wall of the opposite side of the skull—passing the bullet if it lie on the way—followed by tying a piece of silk to the outer end of the probe and carrying the silk across the shaved scalp at different points upon its contour—the common point at which these lines all intersect will indicate the point on the exterior of the skull opposite which the inner end of the probe has come into contact with the inner wall of the skull. At this point a trephine-opening is made. The counter-opening is made with a trephine of 3.8 to 5 cm. (1½ to 2 inches) in diameter, as the bullet is apt to lie an inch or more below the point of striking the inner wall, and room is often necessary for manipulation and exploration. Upon a probe, a grooved director is carried down to the bullet, and upon the director a pair of bullet-forceps, with which the bullet is grasped and removed. When the region does not admit of a counter-opening, as toward the base of the brain, the bullet must be removed through a single opening. (4) Thorough drainage may be instituted by drawing, upon a long probe, a few strands of silk, silk-worm-gut, or rubber drainage-tube. (5) The wound is carefully irrigated, and then closed up to the points of drainage.

Comment.—The bullet may sometimes be located by placing the patient so that the bullet-track is vertical, and then letting the probe drop into the wound as far as possible. It may also sometimes be located by means of *x*-ray shadows taken in two directions.

OPERATION FOR EXPOSURE OF A MOTOR CENTER.

(ILLUSTRATED BY OPERATION FOR FOCAL EPILEPSY.)

Description.—The operation performed for Focal Epilepsy consists in the exposure of an area to which attention has been called by convulsive movements beginning in those parts controlled by that area—or in connection with which some injury has been received—the object being to remove the source of irritation, which may be some form of pressure or an adhesion, or a part of the motor center itself may be removed to a limited extent—the area usually being exposed by trephining. It will be supposed, in the present case, that the epileptic seizures are preceded by muscular twitchings of the muscles of the right fingers, hand and forearm. The exposure of the cortical center presiding over these structures will be indicated, namely, the lower posterior part of the middle third of the sensori-motor area of the left side.

Preparation and Position.—See General Surgical Considerations in Cranio-cerebral Operations (page 478).

Landmarks.—Site of the motor center (here, for example, the center for the right fingers, hand and forearm) is determined by some form of localization method (in this instance, by Chipault's method, page 472).

Incision.—An oval flap (U-shaped), with convexity above and base below, is outlined, having its center about 1 cm. (⅜ inch) posterior to the junction of the lower third and fourth tenths of Chipault's rolandic line (see Chipault's method). For the bone-section, a trephine of at least 3.8 cm. (1½ inches) should be used.

Operation.—(1) The steps of the operation, up to the removal of the button of bone, are the same as for trephining. (2) Open the dura in the form of a small flap, as heretofore described. As soon as the brain is exposed carefully examine for abnormal adhesions between dura and brain, and, if detected, free by cautiously sweeping a bent probe between these structures. If bony growths be found pressing upon brain, remove them by bone-section. (3) If part of a motor center is to be removed, incise the brain substance in the direction of the commissural fibers, making the incision carefully with delicate knife or scissors. (4) Tie all bleeding meningeal and cerebral vessels with fine gut—dividing them in advance, where possible, between double ligatures. Harm pia mater as little as possible, and replace if pushed aside. (5) To avoid readhesion, if previous adhesion existed, or to avoid new adhesion, plates of very thin celluloid, gold leaf, gutta-percha, decalcified bone-plate, india-rubber, etc., are sometimes placed over the pia mater. (6) The dura is carefully sutured with fine gut. The button of bone is replaced or not, according to the surgeon's judgment. The scalp-flap is sutured, without drainage, and speedy union especially sought.

PUNCTURE AND DRAINAGE OF LATERAL VENTRICLES.

Description.—Puncture of the lateral ventricle and withdrawal of cerebro-spinal fluid by aspiration, simple drainage by cannula, or by capillary drainage. Indications; acute hydrocephalus (to withdraw excess of fluid and relieve tension); chronic hydrocephalus (to withdraw excess of fluid and relieve tension, or to inject medicated fluid); meningitis (for drainage).

Preparation and Position.—See General Surgical Considerations in Cranio-cerebral Operations (page 478).

Landmarks.—Junction of the third and fourth tenths of Chipault's temporo-sphenoidal line represents the posterior part of the body of the lateral ventricle. (For this, as well as for the descending and posterior horns, see Chipault's Cranio-cerebral Localization Method, page 473.)

Incision.—An oval or inverted U-shaped flap with its center at the above point is outlined. The bone-section should be made by a trephine of at least 2.5 cm. (1 inch) in diameter.

Operation.—(1) Having made and turned down the flap of soft parts—controlled hemorrhage by clamps and ligature—applied trephine and removed disc of bone—the dura is exposed and a small dural flap turned down. (2) The needle of the aspiratory syringe, or trocar and cannula, is then thrust directly into the substance of the brain, opposite the point indicated above, avoiding all visible vessels—and is made to penetrate horizontally inward for one-third of the transverse diameter of the brain itself (as determined after subtracting the thickness of the scalp and skull of both sides from the total thickness of the head on the line of puncture). (See Chipault's Method, Other Points and Lines, page 473.) Through the needle (or cannula) introduced fluid is withdrawn. (3) Subsequently, before withdrawal of instrument, medicated fluid may be injected, if indicated. Where it is desired to introduce drainage, silk, silkworm-gut, wick, gauze, or a drainage-tube may be introduced through the cannula, if a trocar and cannula have been used—or by means of special forceps alongside an ordinary aspiratory needle before its withdrawal. (4) If no drainage be instituted, the wound is closed as after simple trephining. If drainage be used, the dura and soft parts are only partially sutured, and the button of bone is either not returned, or only a part of it is returned.

Comment.—While it is more satisfactory to open the dura, thus exposing the condition of the brain and the position of the vessels, yet where drainage is not indicated, the lateral ventricles may be aspirated through the unopened dura.

INCISION OF THE CEREBELLAR SUBARACHNOID SPACE FOR DRAINAGE.

PARKIN'S OPERATION.

Description.—The exposure, by trephine, of the membranes in the cerebellar fossa, followed by the incision of the subarachnoid space below the tentorium cerebelli. Sometimes performed for the relief of intracranial pressure by dependent drainage of the cerebrospinal fluid in acute and chronic meningitis and in hydrocephalus.

Preparation and Position.—See General Surgical Considerations in Cranio-cerebral Operations (page 478).

Landmarks.—Lines of lateral and occipital sinuses.

Incision.—An oval (or reversed U-shaped) flap is outlined, with convexity upward and base downward toward the neck, and its center over the center of the right or left cerebellar fossa.

Operation.—(1) The incision outlining the above flap is carried to the bone, the vertical portions of the incision passing, at this site, through considerable thickness of muscular tissue, and rather free bleeding may occur. All vessels are clamped and tied with catgut. The flap is retracted downward and the occipital bone exposed. (2) A trephine of about 1.2 cm. (1 inch) diameter is so applied as to be safely below the lateral sinus, and safely to the outer side of the occipital sinus, and away from the thickness of the external occipital protuberance. The button of bone thus defined is removed, and the dura exposed. (3) The dura is seized with delicate forceps and incised with knife or scissors sufficiently to make a satisfactory opening for drainage—and the subarachnoid space thus entered. (4) Drainage is accomplished by strands of silk, silkworm-gut, wick, gauze, or tubing. (5) The button of bone is not returned. The wound is sutured in part, leaving open only enough space for drainage.

OPERATION FOR CEREBRAL ABSCESS.

Description.—Intracranial abscess may be extradural or intracerebral. The site of abscess (when not directly traceable to an evident cause) is determined, in conjunction with constitutional symptoms, by local compression symptoms referable to the part of the brain pressed upon by the collection of pus—and the operation is done over that area determined by these symptoms.

The most frequent causes of cerebral abscess are otitis media, first of all, and conditions of suppuration in the orbital and nasal cavities. Abscess occurs more frequently on the right side.

Preparation and Position.—See General Surgical Considerations in Cranio-cerebral Operations (page 478).

Landmarks.—The site of abscess, if not otherwise fixed, is determined by pressure symptoms, and localized by known position of center pressed upon.

Incision.—An oval (or reversed U-shaped) flap is outlined for the appli-

cation of a trephine of about 3.8 cm. (1½ inches) diameter—the center of the trephine to be placed over the site determined as above described. A trephine-opening will generally suffice, though an osteoplastic flap is sometimes raised. (See Comment.)

Operation.—(1) The ordinary steps of a trephining (or the raising of an osteoplastic flap) are carried out, up to the exposure of the dura. (2) If an abscess be found between the cranium and dura, it is evacuated (protecting the diploë as much as possible), irrigated, and loosely packed with gauze, a portion of the gauze serving as a drain. The scalp-flap is sutured back in place throughout its greater part, room being left for drain. The button of bone is usually not replaced—if used at all, only a part of the button is returned, the rest being bitten off for drain-opening. (3) If pus be not thus found outside of dura, a flap of dura is raised, as in trephining, and the brain exposed and explored in various directions with a needle (see Exploratory Puncture of the Brain, page 488). Wherever found, especially if deep, the needle is left *in situ* and serves as a guide. The dura over the site is divided by a crucial incision (to provide free exit), a linear incision tending to close. If dura be divided before the presence of abscess is assured, a straight incision of the membrane is made, admitting of subsequent suture if indicated. Before freeing the pus, the cut diploë should be protected from infection as well as possible, by a strip of thin rubber tissue, or by smearing the bone-section with sterile vaseline. The abscess cavity may be cut into by a puncture-like thrust of a knife—or, probably better, a pair of special forceps (or ordinary dressing forceps) may be inserted closed, guided by the needle left *in situ*, and then opened to a limited extent, allowing the pus to drain along the handles, or a grooved director may be used. Two parallel pieces of small-calibered rubber drainage-tubes are then inserted, one serving for inflow of irrigant, the other for the outflow of pus—the tubes being held in place by transfixing them with a safety-pin resting upon the gauze which has been packed around them. (4) The dural and scalp flaps are partly sutured into place, leaving room for drainage.

Comment.—As the most general cause of cerebral abscess is otitis media, the most usual site for the abscess is in the temporo-sphenoidal lobe, in the middle fossa of the skull, adjacent to the antero-superior aspect of the petrous portion of the temporal bone—and the landmark for the operation is, therefore, generally taken as a point 1.8 to 2.5 cm. (¾ to 1 inch) above Reid's base-line (see Reid's Method of Cranio-cerebral Localization, page 476, also Fig. 317, S), on a line drawn vertically upward along the posterior border of the external auditory meatus, at right angle to the base-line—and this point is used as the point at which first to explore, where uncertainty exists. This site having been exposed, if evidence of pus be not found, explore with needle, of fair calibre, and preferably first through the unopened dura—first inward, forward, and downward toward the apex of the petrous portion of the temporal—then upward and forward, and backward and inward, and in other directions—but guarding the basal ganglia and the petrosal sinuses. When pus is located, the dura is always incised.

OPERATION FOR CEREBELLAR ABSCESS.

Description.—Like cerebral abscess, cerebellar abscess may be extradural or intracerebellar. As the cause of abscess is generally, as in the case of the cerebrum, otitis media, the abscess is usually found in the vicinity

of the posterior or postero-superior aspect of the petrous portion of the temporal bone. The site is usually exposed by a trephine-opening.

Preparation and Position.—See General Surgical Considerations in Cranio-cerebral Operations (page 478).

Landmarks.—The external auditory meatus and the lines of the sigmoid and transverse portions of the lateral sinus.

Incision.—Draw a line from the external occipital protuberance to the center of the external auditory meatus. To allow for an unusually low transverse portion of lateral sinus, trephine 1 cm. ($\frac{7}{16}$ inch) below this line. And to avoid the sigmoid portion of the lateral sinus, and also the occipital artery trephine posterior to a vertical line placed 3.5 cm. ($1\frac{3}{8}$ inches) behind the center of the external auditory meatus. Outline an oval (or reversed U-shaped) flap with its center calculated to be over the center of the above indicated area—the limbs of the incision running well into the neck, as the occipital fossa is to be opened below the nuchal furrow.

Operation.—(1) Carry the incision outlining the flap to the bone—control hemorrhage, which is apt to be marked, by clamp and ligature. Retract this thick muscular flap downward, exposing the occipital bone below the superior curved line. (2) Apply, in the site indicated under Incision, a trephine of at least 2.5 cm. (1 inch) diameter and remove the button of bone, exposing the cerebellar dura. (3) The abscess is now sought in a direction forward, upward, and outward; or forward, upward, and inward, in the same general manner as in cerebral abscess—and, if found, dealt with in the same fashion—and the wound finally similarly treated.

Comment.—Cerebellar abscess is often encountered, when it exists, in the course of an operation upon the mastoid region—during an operation where the inner wall of the mastoid process has been exposed and removed, laying bare the lateral sinus and the dura anterior and posterior to it. Where the abscess follows disease of the inner mastoid wall, it generally lies behind the lateral sinus and in contact with the involved bone. Where the abscess is connected with involvement of the labyrinth, it lies in front of the lateral sinus and in connection with the internal meatus or vestibular aqueduct. A fistula generally leads from the diseased bone to the abscess.

OPERATION FOR CEREBRAL TUMOR.

Description.—Removal, *en masse*, of growths from surface or interior of brain. Those involving the basal ganglia, internal capsule, and base of brain generally, are inoperable.

Preparation and Position.—See General Surgical Considerations in Cranio-cerebral Operations (page 478).

Landmarks.—Site of tumor will have been determined by localization symptoms—and site of operation determined accordingly.

Incision.—Amount of room required for recognition and removal of tumor generally necessitates an osteoplastic resection of the skull, which should be planned with reference to the particular case. Or the overlying bone may be totally and permanently removed by making several small trephine-openings and connecting these—or a large trephine may be first used and the margins of the resulting opening bitten out with rongeurs as far as necessary—in either of which cases a horseshoe flap of soft parts is temporarily turned down and then replaced.

Operation.—(1) The steps of the operation, up to the exposure of the dura, are the same as for osteoplastic resection of the skull, hemorrhage

being controlled as during that operation. (2) The dural flap is turned back as in osteoplastic resection. The pia mater is divided in the direction of the length of the tumor—hemorrhage from the pia being controlled by slight tension upon it or by ligature *en masse*. (3) The situation and extent of the tumor are now determined by palpation and exploration. (4) Having reasonably settled both of these questions, the tumor is to be excised. The incision into the brain substance is begun, where possible, at the apex of a convolution and is made in the direction of its commissural fibers—and rather over a convolution than over a sulcus, as there is less hemorrhage. If the tumor be encapsulated, divide the overlying brain and gently retract the cerebral substance, cutting from above downward, and enucleate with a spoon. If the tumor lie beneath the surface but not encapsulated, isolate by carefully incising its connections and enucleating with such an instrument as the curved handle of a thin silver spoon. Cystic tumors sometimes only admit of draining, cauterizing, and packing. (5) The cavity left is lightly packed with gauze if bleeding occurs. Where possible the brain incision is closed with catgut, with or without drainage, as indicated. The dura is sutured. Celluloid or metallic plates are sometimes used to reinforce the opening. The osteoplastic flap or flap of soft parts, according to method of exposure used, is sutured into place, as in the osteoplastic resection or trephining operation respectively.

Comment.—If working in the motor area, use of the faradic electrode may corroborate diagnosis.

OPERATION FOR CEREBELLAR TUMOR.

Description.—The operation is similar to that for cerebral tumor, in essential details—with the following modifications (chiefly from the greater inaccessibility of the cerebellum):—(**a**) A horseshoe flap of soft parts alone is used, with its base toward the neck, as the osteoplastic flap is not easily applicable:—(**b**) The opening in the bone is made with a trephine of as large a diameter as feasible, and is enlarged, if necessary, by biting out its circumference with rongeurs. Thinness of the occipital fossæ; nearness of the sinuses of the occipital bone and proximity of the foramen magnum require especial care.

OPERATIONS UPON THE MASTOID ANTRUM AND CELLS.

See under Operations upon the Bony (Air) Sinuses of Head and Face (page 500).

OPERATIONS UPON THE GASSERIAN GANGLION.

See under Operations upon the Nerves, Plexuses, and Ganglia (pages 155 and 158).

II. THE BONY (AIR) SINUSES OF THE HEAD AND FACE.*

OPERATIONS UPON THE MASTOID ANTRUM AND CELLS.

SURGICAL ANATOMY OF MASTOID ANTRUM AND CELLS.

Muscles of the Mastoid Region.—Retrahens aurem; occipitofrontalis; sternomastoid; splenius capitis; trachelomastoid; digastric.

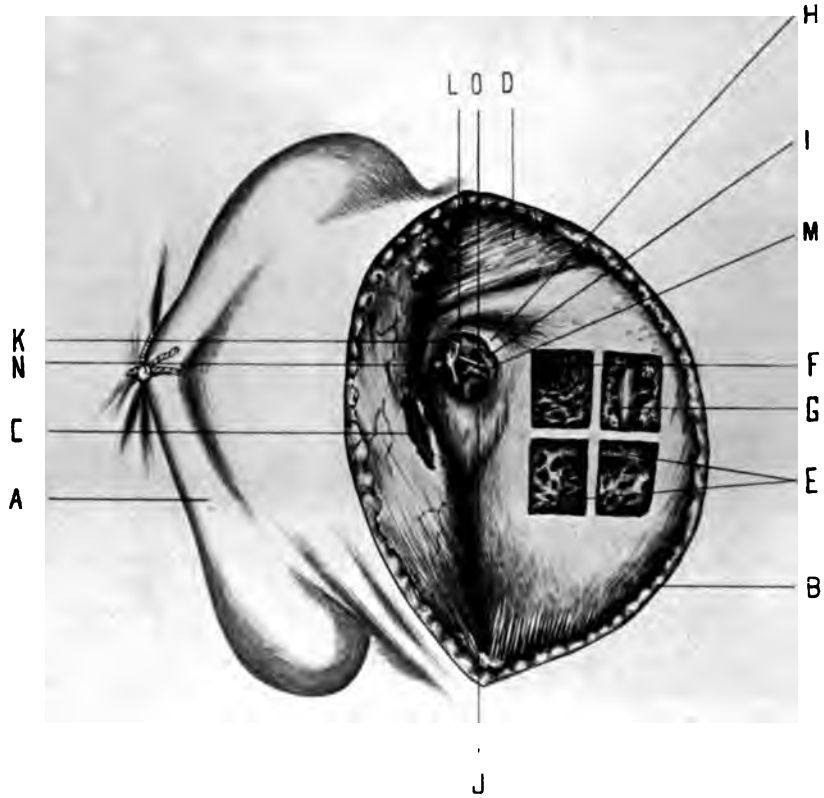

Fig. 323.—Surgical Anatomy of Middle Ear and Mastoid Region.—With membrana tympani removed and four windows chiseled into mastoid process: A, Pinna of ear stitched to cheek; B, Curved incision of exposure, back of ear; C, Soft external auditory canal; D, Temporal fascia; E, Mastoid cells; F, Mastoid antrum; G, Lateral sinus; H, Suprameatal spine; I, Bony plate covering facial nerve; J, Promontory and fenestrum rotundum; K, Malleus; L, Incus; M, Stapedius muscle; N, Tensor tympani muscle; O, Chorda tympani nerve. (From drawing made from cadaver, in Department of Operative Surgery, College of Physicians and Surgeons, by Dr. A. E. Schmitt.)

Arteries of the Mastoid Region.—Posterior auricular and occipital branches of external carotid.

Veins of the Mastoid Region.—Posterior auricular (emptying into temporomaxillary vein); occipital (emptying into internal jugular).

* Among the Bony (Air) Sinuses of the Head and Face, will be considered the Mastoid Antrum and Cells, the Frontal Sinus and the Maxillary Sinus—the Ethmoidal and Sphenoidal Sinuses more properly belonging to the special surgery of the Nose.

Nerves of the Mastoid Region.—Posterior auricular branch of facial; auricularis magnus from cervical plexus; occipitalis minor from cervical plexus; auricular branch of occipitalis major; external branch of posterior division of second cervical nerve.

Mastoid Antrum.—A retort-shaped cavity situated in mastoid portion of temporal bone, communicating with mastoid cells posteriorly, and opening, anteriorly, through aditus ad antrum, into highest part of tympanic cavity, the epitympanic recess (attic of tympanum), thereby communicating with eustachian tube. The epitympanic recess lies above the anterior three-fourths of the orifice of the opening of the antrum into tympanic cavity. The floor of antrum lies below the level of the entrance into antrum, generally

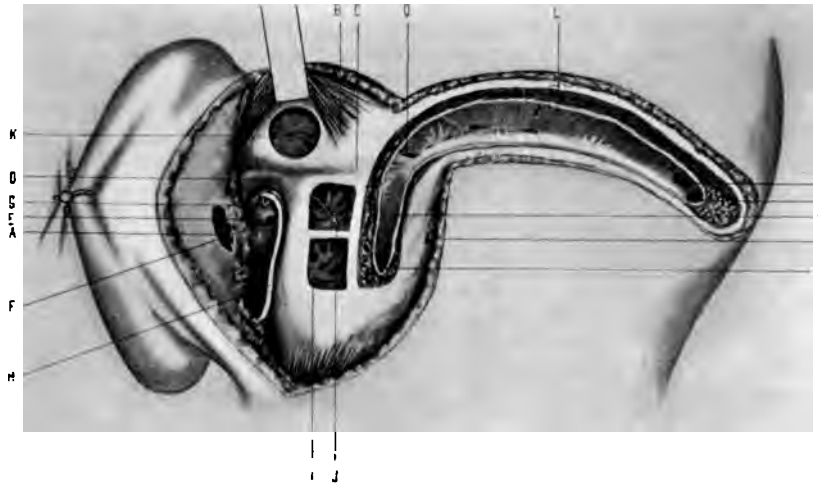

Fig. 324.—SURGICAL ANATOMY OF MASTOID REGION AND MIDDLE EAR:—With membrana tympani removed; mastoid cells, mastoid antrum, and lateral sinus exposed; and trephine disc removed just above temporal crest and ear; A, Soft auditory canal in turned-back ear; B, Temporal muscle; C, Temporal crest; D, Horizontal semicircular canal; E, Promontory; F, Fenestrum rotundum; G, Stapes; H, Facial nerve; I, Mastoid cells; J, Arrow passing from attic to antrum, along aditus ad antrum; K, Trephine-opening exposing posterior branch of middle meningeal artery; L, Horizontal limb of lateral sinus; M, Descending limb of lateral sinus; N, Beginning of internal limb of lateral sinus; O, Opening of opposite lateral sinus; P, Opening of longitudinal sinus; Q, Opening of superior petrosal sinus; R, Mastoid foramen. (From drawing made from cadaver, in Department of Operative Surgery, College of Physicians and Surgeons, by Dr. A. E. Schmitt.)

corresponding with level of center of auditory meatus, or even higher. The communication between antrum and epitympanic recess is triangular in shape, with base upward and rounded angle below; its lower portion being on level with superior wall of external auditory meatus; its measurement being about 4 mm. ($\frac{3}{16}$ inch) both transversely and vertically. The antrum lies from 7 to 14 mm. ($\frac{4}{16}$ to $\frac{9}{16}$ inch) from surface of mastoid bone; and from 7 to 12 mm. ($\frac{4}{16}$ to $\frac{8}{16}$ inch) behind superior posterior margin of tympanic ring—the outer portion of overlying bone being hard, the inner portion more spongy. The antrum measures, longitudinally, 10 to 15 mm. ($\frac{6}{16}$ to $\frac{10}{16}$ inch); vertically, 10 mm. ($\frac{6}{16}$ inch); transversely, 4 to 6 mm. ($\frac{3}{16}$ to $\frac{4}{16}$ inch). In infancy and childhood the antrum is nearly full size, but the mastoid cells rarely develop before twelve years of age. The overlying bone is relatively thin in the young.

Mastoid Cells.—Situated within mastoid process of temporal bone; opening, anteriorly, into mastoid antrum; and extending, postero-inferiorly, sometimes to tip of mastoid process.

Relations of Mastoid Antrum.—(1) Superiorly; antrum is separated from middle cranial fossa of skull by a thin, bony plate, the tegmen tympani, sometimes partially deficient, a fibrous membrane and vascular tissue then intervening. Roof of antrum generally corresponds to supramastoid crest, though sometimes being upon a higher level than crest, in which latter cases the inferior temporal convolution of the cerebral hemisphere may overlap upper part of antrum. (2) Inferiorly; floor of antrum is formed by mastoid portion of petrosal bone. (3) Anteriorly; a thin wall of bone comes between antrum and deep portion of auditory meatus. (4) Posteriorly, extends backward and outward, lying nearer surface posteriorly than anteriorly, approaching sigmoid portion of lateral sinus, sometimes but a thin bony lamina intervening, though distance between the two generally averaging 5 to 10 mm. ($\frac{3}{16}$ to $\frac{6}{16}$ inch) and usually consisting of mastoid cells; the lateral sinus ordinarily lying nearer the surface than the antrum. (5) Externally; outer wall is formed by squamous portion of temporal below supramastoid crest. (Figs. 323 and 324.)

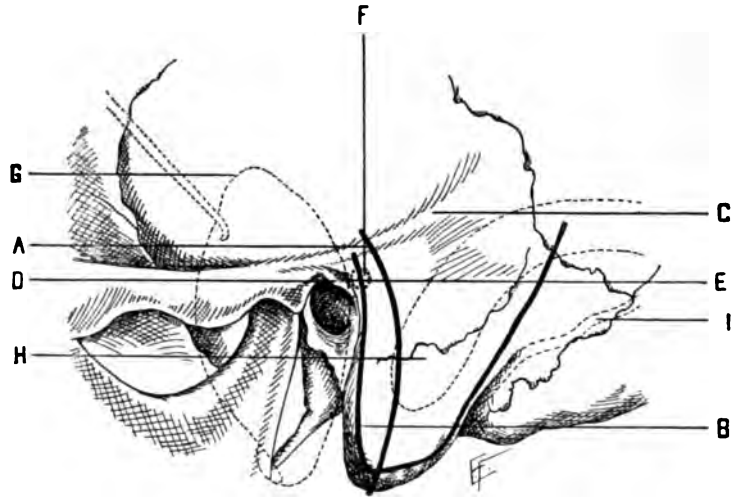

Fig. 325.—Position of Incisions Exposing Mastoid Antrum and Cells:—A, Incision for exposure of mastoid antrum and cells (Antrum Operation of Schwartze); B, Incision for Tympano-mastoid Exenteration (Radical Operation of Schwartze-Stacke); C, Suprameatal crest; D, Suprameatal spine; E, Suprameatal fossa; F, Position of mastoid antrum; G, Auricle drawn forward; H, Lateral sinus; I, Occipital artery.

SURFACE FORM AND LANDMARKS OF MASTOID ANTRUM AND CELLS.

External auditory meatus—varying in shape, size, and in the direction of its longest diameter. Separated from mastoid process by the concha of the ear.

External auditory canal—corresponds with general direction of approach to antrum through mastoid process.

Mastoid process of temporal bone—contour generally capable of being outlined through the skin.

Supramastoid crest (linea temporalis)—continuation of zygomatic ridge backward.

Suprameatal triangle—site of approach to mastoid antrum; having following boundaries; Superiorly, supramastoid crest; Inferiorly and Anteriorly, outer margin of posterior superior quadrant of bony external auditory meatus; Posteriorly, vertical line drawn upward along most posterior margin of bony external auditory meatus. (Fig. 325.)

Suprameatal fossa (fossa mastoidea)—depression in upper posterior angle of suprameatal triangle.

Suprameatal spine—crest of bone separating suprameatal fossa from external auditory meatus.

Suprameatal line—line continuing level of suprameatal spine backward.

Remains of masto-squamosal suture—sometimes exists, with small canals occupied by connective tissue and veins.

GENERAL SURGICAL CONSIDERATIONS IN OPERATIONS UPON MASTOID ANTRUM AND CELLS.

Site and Direction of Operation for Opening Antrum.—(1) Site lies in suprameatal fossa, directly within suprameatal triangle, or immediately behind it. This generally brings upper edge of opening about 3 mm. ($\frac{2}{16}$ inch) below suprameatal line, and about 5 mm. ($\frac{3}{16}$ inch) behind bony external auditory meatus. (2) Direction of opening passes inward and slightly upward and forward, following general direction of bony external auditory canal. This will open into anterior part of antrum, at distance of from 7 to 14 mm. ($\frac{4}{16}$ to $\frac{9}{16}$ inch) (extremes, especially in disease, from 3 to 18 mm., or $\frac{2}{16}$ to $\frac{12}{16}$ inch) from surface of mastoid process.

General Precautions in Operating.—(1) Keep below supramastoid crest—to avoid middle cerebral fossa of skull. Middle cranial fossa sometimes dips down to quite a low level between petrous and squamous portions of temporal bone, and the roof of antrum and tympanum form part of floor of this fossa. The level of floor of fossa may vary as much as 2 cm. ($\frac{13}{16}$ inch) but is never as much as 1 cm. ($\frac{6}{16}$ inch) below supramastoid crest. Where supramastoid crest cannot be felt, keep 3 mm. ($\frac{2}{16}$ inch) below horizontal line running backward from upper edge of bony external auditory meatus, in order to avoid middle fossa. To further avoid the possibility of entering middle cranial fossa, make opening at first directly inward, penetrating from 5 to 8 mm. ($\frac{3}{16}$ to $\frac{5}{16}$ inch) before taking an upward direction. (2) Do not go more than 2 mm. (between $\frac{1}{16}$ and $\frac{2}{16}$ inch) behind posterior limit of suprameatal triangle—to avoid lateral sinus. (3) Check instrument as soon as antrum is entered—to avoid external semicircular canal and facial nerve.

Special Structures to be Avoided.—(1) At inferior aspect of entrance into antrum, inner wall of antrum bulges slightly over external semicircular canal, which lies on median side of aditus, superior to and separated from fallopian canal by thin lamina of bone. It may form the antero-median wall of antrum, if it project backward. To avoid injury to external semicircular canal, check instrument as soon as cavity of antrum is reached. The inner wall of antrum lies about 17 to 20 mm. ($\frac{11}{16}$ to $\frac{13}{16}$ inch) from surface

of mastoid. (2) On inner side of epitympanic recess, inferiorly and anteriorly to the bulging marking external semicircular canal, is the arching osseous canal of the facial nerve. The wall toward antrum is thin and partly wanting. Avoid facial nerve by not directing the opening too far forward. The perpendicular portion of fallopian canal, with contained nerve, may be 3 mm. ($\frac{2}{16}$ inch) internal to posterior periphery of ear-drum, or its position may be almost immediately opposite this posterior periphery. (3) Between external semicircular canal anteriorly, and lateral sinus posteriorly, the air-cells are separated from posterior fossa of skull by bony wall from 1 to 9 mm. (from less than $\frac{1}{16}$ to $\frac{6}{16}$ inch) thick. (4) Extreme curvature of sigmoid portion of lateral sinus may occur. Where this exists, the sigmoid sinus may be in almost direct contact with outer cortex of mastoid, and it may come to within 3 mm. ($\frac{2}{16}$ inch) of posterior wall of bony auditory meatus. As its course cannot be known in advance, it is best avoided by careful use of gouge or chisel (which are preferable to all instruments which approach by boring their way).

Manner of Making Bone-section.—Bone is divided either by chisels and mallet, aided by hand gouges and curettes; or by a burr driven by an engine or worked by hand, followed by use of gouges and curettes.

INSTRUMENTS.

(1) For incision and repair of soft parts, see instruments used in cranio-cerebral operations (page 480). (2) Special instruments used upon mastoid process, auditory canal, and tympanic cavity, are the following: small mallet; chisels; gouges; guard for gouge; scoops; curettes; elevators; small trephine; forceps; burr driven by hand or by engine; bradawl; two or three centimeters of a metallic millimeter measure. (3) Special instruments for intra-tympanic work; straight and angled knives; tenotomy knives; synechia knives: ear-drum knives; incus hooks; fine forceps.

OPERATION FOR EXPOSING MASTOID ANTRUM AND CELLS.

ANTRUM OPERATION OF SCHWARTZE.

Description.—In this operation only the antrum and cells of the mastoid process are opened up, without invading the cavity of the tympanum. Indicated in such conditions as empyema, osteitis, or osteomyelitis occurring in the mastoid process alone. In the following account the description of J. Orne Green is largely followed. (See Fig. 326.)

Preparation.—The ear is irrigated with antiseptic solution and packed with sterile cotton. The hair of the neighborhood is shaved, and the head and neck enveloped in sterile dressings.

Position.—Patient rests upon side, with head elevated and so placed upon its opposite side as to make mastoid region prominent, resting upon a firm cushion to prevent jarring. Surgeon stands behind patient. Assistant stands opposite and to one side of surgeon.

Landmarks.—External auditory meatus; supramastoid crest; mastoid process.

Incision.—Slightly curvilinear, placed behind ear—beginning 1 cm. ($\frac{6}{16}$ inch) above level of upper edge of auditory meatus and passing downward at a distance of 0.5 to 1 cm. ($\frac{3}{16}$ to $\frac{6}{16}$ inch) behind insertion of auricle, and ending at tip of mastoid process. (See Fig. 325, A.)

Operation.—(1) Incision passes through skin, overlying muscles, and periosteum directly to bone (Fig. 326). (2) The soft parts are elevated from the bone with periosteal elevator—anteriorly, until the suprameatal spine is exposed—posteriorly, until the mastoid process is bared. (3) From the suprameatal spine, draw a line horizontally backward. Make an opening with its upper edge 3 mm. ($\frac{2}{16}$ inch) below this suprameatal line, and its anterior edge 5 mm. ($\frac{3}{16}$ inch) behind the auditory meatus—which position will correspond with the suprameatal fossa (fossa mastoidea) when that depression is sufficiently marked for recognition. The area of operation, bounded as above, will extend over a surface 7 to 10 mm. ($\frac{4}{16}$ to $\frac{6}{16}$ inch) in diameter. (4) By

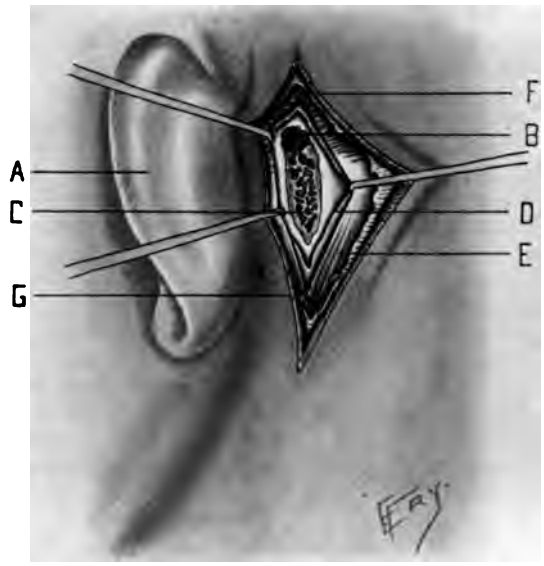

Fig. 326.—Exposure of Mastoid Antrum and Cells (Operation of Schwartze):—A, Auricle drawn forward; B, Mastoid antrum; C, Mastoid Cells; D, Periosteum drawn aside; E, Sternomastoid muscle; F, Temporal muscle; G, Posterior branch of posterior auricular artery.

means of gouge and mallet the bone is removed in thin chips, always keeping the process of excavation in a line parallel with the auditory canal. The amount of bone to be removed varies from a thin lamina up to 1 cm. ($\frac{6}{16}$ inch) before the mastoid cells are reached. (5) As soon as the air-cells are opened, explore with probe—upward, to locate the roof of the mastoid—inward and backward, to locate the posterior fossa of the skull. (6) Break down the intervening wall between the cells, working directly inward for 5 to 8 mm. ($\frac{3}{16}$ to $\frac{5}{16}$ inch). Thence work in a slightly upward and forward direction, with curette, until the antrum is reached, at a distance from the surface of 7 to 14 mm. ($\frac{4}{16}$ to $\frac{9}{16}$ inch). The excavation should not extend beyond 14 or 15 mm. ($\frac{9}{16}$ or $\frac{11}{16}$ inch) from the surface, which is as far as it is safe to go. (7) Carious bone should be removed wherever found, even if it be necessary to expose the dura—and whether the roof of the mastoid lie immediately beneath the cerebrum; or the inner wall, with the lateral sinus and cerebellum, lie just to the inner side. The dura is displaced with a dural

separator and the bone is removed with a curette. (8) The interior of the mastoid process must be dealt with according to indications. Pus should be evacuated—granulations removed and cell-walls broken down. In inflamed diploë, the cancellated structure should be curetted away. In osteitis, curette away softened bone short of harming the labyrinth and facial nerve. The entire external aspect of the mastoid process may be removed to the tip of the process. (9) In completing the operation, pack the cavity left in the mastoid with gauze. Suture the periosteum partially, and the soft parts also in part, leaving room for drainage.

Comment.—(1) Where the interior of the mastoid is partly or wholly diploëtic, proceed with greater care, using curette or hand gouge. Pass directly inward parallel with auditory canal, for 5 to 8 mm. ($\frac{3}{16}$ to $\frac{5}{16}$ inch)—if no air-cells are reached by this time, pass slightly forward, upward and inward to the antrum—but do not go beyond 15 mm. ($\frac{9}{16}$ inch) from the external surface of the anterior edge of the osseous opening, lest the facial nerve or horizontal semicircular canal be injured. (2) In a mastoid affected with osteosclerosis (from long suppuration or previous disease) the usual landmarks, gotten with a probe as one advances, are not so available. Proceed carefully in the same directions and for the same distances as in the diploëtic tissue just mentioned, but working with a chisel and mallet, instead of a hand gouge. Diploëtic bone may be met after passing through 7 to 10 mm. ($\frac{4}{16}$ to $\frac{6}{16}$ inch) of sclerosed bone. Sometimes, though rarely, the antrum may be obliterated by osteosclerosis. (3) Where fistulæ exist, these should be exposed and followed up, rather than to make another opening through healthy bone; or the fistulous tracks may be used in conjunction with the ordinary opening. An externally placed fistula is exposed by reflecting the periosteum from the external surface of the mastoid process. An anteriorly placed fistula is exposed by reflecting the periosteum from the posterior wall of the auditory canal. An inferiorly placed fistula is exposed by reflecting the periosteum from the tip of the mastoid process, toward the digastric groove.

OPERATION FOR EXPOSING MASTOID ANTRUM AND CELLS, TOGETHER WITH INTERIOR OF TYMPANUM AND MEATUS, AND THE EXENTERATION OF THE MIDDLE-EAR CAVITIES.

THE TYMPANO-MASTOID EXENTERATION, OR RADICAL OPERATION, OF SCHWARTZE-STACKE (OR SCHWARTZE-ZAUFAL).

Description.—This operation, much more extensive than the last, consists in the opening up of the mastoid antrum, mastoid cells, tympanum, and meatus, and of the complete exenteration (evisceration) of the middle-ear cavities. The whole interior of the mastoid antrum, aditus, epitympanum, tympanum, and meatus are thereby converted into a single large and continuous cavity—the smooth walls of which are made to heal throughout by epidermization—the epidermis growing in from the meatus and the edges of the wound. Indicated in empyema, osteitis or osteomyelitis of mastoid process occurring in connection with osteitis of the aditus, epitympanum, tympanum, and meatus; and also in cholesteatomatous collections in those parts. In the following account the description of J. Orne Green is largely followed.

Preparation—Position—Landmarks.—Same as in the Antrum Operation (page 504).

Incisions and Operation.—

A. Formation of Skin-flap and Periosteal Flap, and exposure of Operation Site:—(1) Skin-flap—incision begins 3 mm. ($\frac{2}{16}$ inch) above the anterior superior insertion of the auricle—passes downward about 3 mm. ($\frac{2}{16}$ inch), posterior to and parallel with the auricle, to the tip of the mastoid process—thence about 12 mm. ($\frac{8}{16}$ inch) backward—thence upward and slightly backward over the posterior aspect of the mastoid to its upper part. (See Fig. 325, B.) The skin over this triangle is dissected off from the remaining soft parts and displaced upward. (2) Partial separation of auricle—dissect off the auricle, without the periosteum, up to the postero-superior margin of the meatus and displace it forward. (3) Periosteal Flap—incise horizontally backward through the periosteum to bone along the supramastoid crest, from near the meatus to the upper end of the posterior skin incision—and also perpendicularly downward near to meatus. Displace downward the triangular flap of periosteum thus made.

Sometimes this order of raising the flaps is reversed, the skin-flap being turned downward and the periosteal flap upward. Hemorrhage is controlled as encountered.

B. Extirpation of lining of Superior and Posterior aspects of Osseous Auditory Meatus—(1) Detach the cartilaginous meatus from the osseous meatus, with periosteal elevator, along its superior and posterior aspects and displace it forward and downward with the auricle. (2) Incise the lining of the meatus along the antero-superior and postero-inferior walls, beginning at the drum-membrane and ending at the free margin—dicsarding the excised triangular portion of periosteum.

C. Exposure of Antrum, with Removal of posterior wall of Osseous auditory canal, together with Membrana and Malleus—(1) Expose the antrum as in the ordinary antrum operation (*q. v.*). (2) Chisel out a wedge of bone between the anterior edge of the mastoid opening and the posterior edge of the meatus. As the lower chisel-cuts approach the floor of the meatus and grow deeper, they are directed somewhat upward, finally opening into the osseous auditory canal. (3) Dissect out the fibrous tympanic ring by means of a special knife, and remove the membrana tympani and the malleus, if still present. (4) Pass a bent probe, or special guide, by the tympanic route, through the aditus into the antrum, and, upon this as a guide, chisel away the remaining wedge of bone between the antrum and aditus—making as wide an opening as the position of the facial nerve will allow.

D. Extirpation of Epitympanum and Removal of Incus:—(1) Chisel away the outer wall of the epitympanum with a specially curved chisel, exposing the entire epitympanum. (2) Disarticulate the incus from the stapes with a special knife, and remove the incus with forceps.

E. Exenteration of entire Mastoid Antrum, Aditus, and Epitympanum:—(1) Chisel away most of the outer cortex of the mastoid and its cancellated portion. (2) So chisel away the posterior wall of the osseous auditory meatus as to leave a ridge of firm bone between mastoid and meatus, sloping outward and downward from the floor of the aditus. The fallopian canal lies inside this ridge, none of which is to be removed on the median side of the tympanic ring. (3) Smooth, by curette or surgical engine, all bony irregularities in the walls of the mastoid, antrum, epitympanum, and roof of tympanum. Especially search for caries upon the posterior and interno-inferior aspects of antrum, lateral sinus, and roof of tympanum—exposing the dura if required. (4) Guard the horizontal part of the fallopian canal through the tympanum,

and the perpendicular part running down from the aditus—also the horizontal semicircular canal in the inner wall of the aditus.

F. Splitting of Membranous Meatus and Suturing:—(1) Slit the cartilaginous meatus throughout its posterior wall, from near the concha outward. Two triangular flaps are thus formed, whose corners are to be sutured with catgut to the external tissues, one being stretched upward, the other downward. (2) Suture the auricle back into its former position as far down as the supramastoid crest. (3) Turn the skin-flap and periosteal flap into the cavity made, after cleansing and draining it—and tampon them with gauze. (4) Suture the skin over the lower part of the mastoid. (5) Apply a voluminous protective dressing.

G. After-treatment:—Keep every crevice of cavity well packed with gauze, until the cavity fills with granulations, and until granulations are covered with epidermis—which epidermis is gotten partly from epidermization of granulations, partly from the skin-flap turned in—and may also be gotten from grafts.

Comment.—The middle ear is sometimes first exposed by removing the upper and posterior wall of the osseous canal, and then, by means of a probe in the aditus ad antrum, the aditus and antrum are exposed. Thus antra lying further forward than usual would be exposed with less danger to the cranial cavity (Stacke).

OPERATIONS UPON THE FRONTAL SINUSES.

SURGICAL ANATOMY OF THE FRONTAL SINUSES.

Description.—Two more or less triangular air-spaces of variable size, with bases anteriorly and apices posteriorly, situated chiefly in antero-inferior portions of frontal bones, on either side of median line, anterior to ethmoidal notches, and separated from each other by an intervening bony septum. They lie at the antero-internal junction of horizontal and vertical portions of frontal bones, immediately internal to internal angular processes, lying above root of nose and more or less beneath inner portions of superciliary ridges. The sinuses begin to develop at two years, but are insignificant in size until after seven years.

Muscles in Relation with Frontal Sinuses.—Frontal portion of occipito-frontalis; orbicularis palpebrarum; corrugator supercilii; sometimes the anterior part of temporal.

Arteries in Neighborhood of Frontal Sinuses.—Angular; termination of facial; frontal branch of ophthalmic; supraorbital branch of ophthalmic.

Veins in Neighborhood of Frontal Sinuses.—Frontal (emptying into nasal arch and supraorbital); supraorbital (forming, with frontal, the angular vein); angular (becoming the facial); anterior temporal (emptying into common temporal).

Nerves in Neighborhood of Frontal Sinuses.—Supraorbital and supratrochlear branches of frontal division of ophthalmic; sometimes the lachrymal branch of ophthalmic.

Walls and Their Relations.—(1) Anterior Wall: formed by vertical portion of frontal; extends from supraorbital arch below, a variable distance upward (v. i.); contains diploë; thickness of wall varies from 1 to 6 mm. (from less than $\frac{1}{16}$ to $\frac{4}{16}$ inch) in different places, average being from 2 to 3 mm. (from about $\frac{1}{16}$ to $\frac{2}{16}$ inch); has, in relation, the soft parts mentioned above (see muscles, arteries, veins, and nerves). (2) Postero-superior Wall

(or roof): forms part of anterior boundary wall of anterior cranial fossa; dense and brittle; has, in relation, the frontal lobe of brain and the olfactory lobe. (3) Inferior Wall (or floor): (a) Orbital Portion: forms part of roof of orbit; of variable extent; marked by depression for pulley of superior oblique muscle of eye; (b) Nasal Portion: (the part of greater surgical importance); articulates with anterior ethmoidal cells, nasal process of superior maxillary and nasal bones; infundibulum opens through this portion of inferior surface from frontal sinus into middle meatus of nose. (4) Internal Wall: formed by the antero-posterior septum between the sinuses, which generally deviates from median line.

Extent.—(1) Laterally; Average of two hundred cases gave an extension outward from median line of from 2 to 2.8 cm. ($\frac{13}{16}$ to $1\frac{2}{16}$ inches)—Extremes, from mere slits in nasal part of frontal, to cavities extending from median septum into external angular process of frontal. (2) Vertically; averages, from base to apex above, along its inner border (its highest part), from 1.8 to 2.5 cm. ($\frac{12}{16}$ to 1 inch)—extremes, from nasofrontal suture to frontal eminence. (3) Floor, frequently extends back as far as anterior ethmoidal foramen—rarely back to lesser wing of sphenoid.

The size of the frontal sinuses is not determined by neighboring bony prominences and depressions, as they may be largely formed at the expense of the inner table of the skull. It is also often said that one sinus may be absent or rudimentary, the opposite one extending across the median line, but in Lothrop's examination of two hundred and fifty sinuses the orbital portion of the sinus was not once missing.

Septum.—A thin bony septum separates the two sinuses, which may deviate slightly or considerably to one side. Septum generally does deviate to one side, and this deviation may amount to 5 mm. ($\frac{3}{16}$ inch) or more. When deviation is very marked, one sinus partly overlaps the other, an important surgical fact. The septum is rarely absent. Perforation of septum is very exceptionally found (once in one hundred and eighty cases).

Communication with Nose.—By infundibulum, which passes downward and backward behind the nasal process of superior maxillary bone, through anterior portion of lateral mass of ethmoid, and opens into middle meatus of nose, under anterior end of middle turbinated bone, and on a level with the palpebral fissure.

SURFACE FORM AND LANDMARKS.

No external guide exists as to the extent of the frontal sinuses—though, generally, the more prominent and larger the supraorbital area, inclusive of the superciliary ridges and nasal eminences, the greater the extent of the sinuses.

GENERAL SURGICAL CONSIDERATIONS.

It is not safe to make an opening for the exposure of the frontal sinus at any point external to the supraorbital notch—the site at which the sinus is most surely encountered being just above the antero-inferior aspect of the internal angular process of the frontal bone, at a position to one side of the median line sufficiently far to miss the average position of the septum.

INSTRUMENTS USED IN OPERATIONS UPON THE FRONTAL SINUSES.

See those mentioned under the Cranio-cerebral and Mastoid regions (pages 480 and 504).

EXPOSURE AND DRAINAGE OF THE FRONTAL SINUSES.

Description.—The frontal sinus is exposed through its anterior wall—and subsequently drained either through the original wound—or, where possible, through the infundibulum into the middle meatus of the nose, after closing the original wound—or through both routes.

Preparation.—Shave eyebrow. Close eyelid and place a sterile pad over it.

Position.—Patient supine; shoulders elevated; head extended. Surgeon on side of operation, or behind head. Assistant opposite.

Landmarks.—Supraorbital ridge; supraorbital notch (generally detectable through the skin, at the junction of the inner and middle thirds of the supraorbital ridge); sagittal suture (middle line of head); nasofrontal suture (detectable when soft parts are retracted).

Incision.—A horizontal incision is made, beginning to the outer side of the center of the supraorbital ridge, and continued inward to the median line, just above the supraorbital margin (Fig. 327). If more room be needed, this incision may cross the median line, or be curved upward or downward at the median line. (Instead of the horizontal, a vertical incision is sometimes made in the median line, between the superciliary ridges—but leaves more of a scar than an incision through the eyebrow.

Operation.—(1) The incision passes directly to the bone, through the skin, the fascia, transversely through the frontal portion of the occipitofrontalis, longitudinally between some fibers of the orbicularis palpebrarum and through periosteum to bone. The supraorbital vessels and the supraorbital and supratrochlear nerves are cut—but the more important branches of the facial nerve to the occipitofrontalis, corrugator supercilii, and orbicularis palpebrarum are not cut. (2) The periosteum is elevated and, together with the soft parts, is displaced upward and downward by retractors. (3) The bone having been well exposed, and bleeding controlled, an opening is made with a small trephine or burr (or, less desirably, with chisel and mallet). The opening is placed just above the antero-inferior aspect of the internal angular process of the frontal bone—the inner margin of the opening should be external to the median line, to allow for deviation of the septum—the outer margin should never extend beyond the supraorbital foramen—and the lower margin should be above the nasofrontal suture. (4) After penetrating the anterior bony wall, with its diploë, the mucous membrane of the frontal sinus is encountered and divided. (5) Pass a probe through the trephine-opening into the sinus—thence through the infundibulum (which first runs downward and backward a short way, then sharply forward and downward) into the middle meatus of the nose, which it enters under the anterior end of the middle turbinated bone. (6) The interior of the cavity, if necessary, may be curetted. The infundibulum may be forcibly dilated. Drainage, at least temporary, is generally indicated—and may be accomplished in one of the following ways—(a) by drawing a rubber tube through the infundibulum into the middle meatus of the nose, with entire closure of the

external wound—or (b) by combined external drainage through the lower part of the external wound (the upper part of the wound being sutured) and drainage into the middle meatus of the nose by rubber tube or strands of silkworm-gut or silk. It is better to adopt the latter method at first—and the former may be adopted later, when external drainage can be abandoned. The first method alone is preferable if the matter of scarring from a granulating wound be of importance. Suture all of the external wound except that portion required for drainage. The transversely divided muscle tissue should be repaired with catgut.

Comment.—(1) Avoid passing the probe through the ethmoidal cells into the brain. (2) It is well to remove the anterior end of the middle tur-

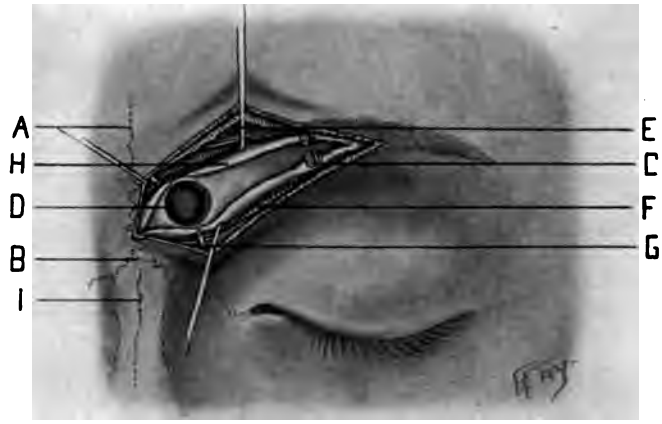

Fig. 327.—Exposure of Frontal Sinus by Transverse Supraorbital Incision:—A, Remains of frontal suture; B, Nasofrontal suture; C, Supraorbital foramen, artery, and nerve; D, Trephine-opening through internal angular process of frontal bone; E, Orbicularis palpebrarum divided longitudinally; F, Occipitofrontalis divided transversely; G, Supratrochlear nerve; H, Periosteum drawn aside; I, Nasal suture.

binated bone, as freer access to and from the infundibulum is thereby given. (3) Where possible, the lips of the wound through the eyebrow should be very carefully approximated and sutured, that the eyebrows may grow out in their proper axes.

OPERATIONS UPON THE MAXILLARY SINUSES.

SURGICAL ANATOMY OF THE MAXILLARY SINUSES.

Description.—A somewhat pyramidal air-cavity generally occupying chief portion of body of superior maxillary bones. Dimensions variable—may be contracted—may extend into malar bone. Small with thick walls in young—larger with thinner walls in old. Communicates by an irregular opening with middle meatus of nose—sometimes more than one communicating opening may exist. Infraorbital canal, for infraorbital nerve, penetrates its superior and anterior walls. Posterior dental canals groove its posterior wall. Bony septa may divide interior of cavity. Floor of antrum uneven from upward projection of roots of teeth. Teeth in contact with

the antrum are the molars, and especially the first and second molars—sometimes the roots of all the teeth of one side may be in contact with floor of antrum of that side.

Muscles in Relation.—(1) In Relation with Anterior or Facial Wall; levator labii superioris alæque nasi; levator labii superioris; levator anguli oris; zygomaticus major; zygomaticus minor; orbicularis oris; buccinator; risorius. (2) In Relation with Posterior or Zygomatic Wall; masseter; temporal; external pterygoid.

Arteries in Relation.—(1) In Relation with Anterior Wall; facial of external carotid; transverse facial branch of temporal branch of external carotid. (2) With Posterior Wall; internal maxillary of external carotid; posterior dental (alveolar) of internal maxillary; descending palatine of internal maxillary. (3) With Internal Wall; sphenopalatine of internal maxillary. (4) With Superior Wall; infraorbital of internal maxillary.

Veins in Relation.—Correspond with arteries.

Nerves in Relation.—(1) In Relation with Anterior Wall; middle superior dental branch of superior maxillary; anterior superior dental branch of superior maxillary; malar branches of facial; infraorbital branches of facial; buccal branches of facial. (2) With Posterior Wall; posterior superior dental branches of superior maxillary; anterior or large palatine nerve from Meckel's ganglion; posterior or small palatine nerve from Meckel's ganglion. (3) With Superior Wall; infraorbital division of superior maxillary (emerges on anterior wall). (4) With Internal Wall; nasopalatine nerve of Meckel's ganglion.

Walls and Their Relations.—(1) Base or Internal (Nasal) Wall; presents the very irregular opening of antrum of Highmore, at its posterior part, communicating with middle meatus of nose—and is partly filled in by vertical plate of palate, unciform process of ethmoid, maxillary process of inferior turbinated, part of lachrymal and by mucous membrane. (2) Apex; formed by malar process of superior maxillary. (3) Superior Wall; orbital plate of superior maxillary. (4) Inferior Wall; alveolar ridge. (5) Anterior Wall; facial surface of superior maxillary. (6) Posterior Wall; zygomatic surface of superior maxillary.

SURFACE FORM AND LANDMARKS.

The antero-external and postero-external walls of the sinus, together with the alveolar ridge, which are the aspects where openings are usually made, are best exposed by upward and backward traction of the upper lip and cheek of that side, sufficiently to obliterate the fold of mucous membrane reflected from cheek to gums.

GENERAL SURGICAL CONSIDERATIONS.

The maxillary sinus may be approached by enlarging its natural opening into the middle meatus of the nose; by making an opening through its external wall; or by going through a socket of one of the molar teeth. The best site for the opening, upon the facial aspect of the bone, is in the interval between the first and second molar teeth, upon the posterior aspect of the malar ridge of the superior maxillary bone, sufficiently high to avoid the roots of the teeth. Above the second molar might be better, but the malar ridge makes it difficult to get high enough up to avoid the root of the tooth

—but this site would be better if the tooth were absent. Where the opening is made through the alveolar ridge the second molar tooth is drawn and the socket penetrated by a burr or drill.

INSTRUMENTS USED IN OPERATIONS UPON THE MAXILLARY SINUSES.

See those mentioned under the Cranio-cerebral and Mastoid regions (pages 480 and 504).

OPENING OF MAXILLARY SINUS (ANTRUM OF HIGHMORE) THROUGH ITS FACIAL ASPECT, ABOVE THE ALVEOLAR MARGIN.

Description.—The upper lip and cheek are displaced upward and backward, and the antrum entered above the fangs of the molar teeth, preferably

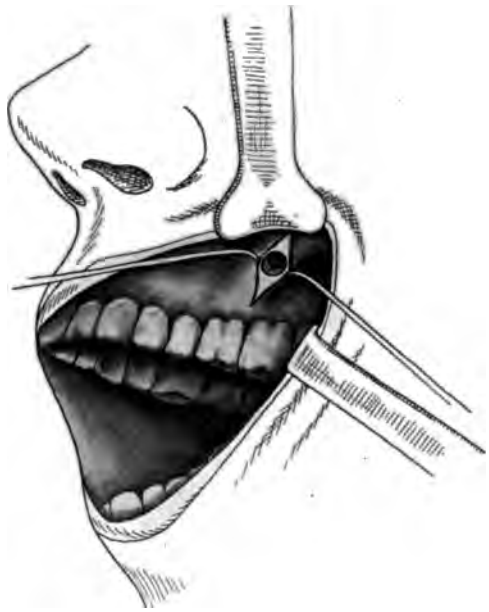

Fig. 328.—EXPOSURE OF MAXILLARY ANTRUM:—Through the malar ridge of the superior maxilla, above the interval between first and second molar teeth fangs.

in the interval between the first and second molars, upon the postero-external aspect of the malar ridge of the superior maxilla. (See Fig. 328.)

Preparation.—Mouth cleansed; sponge so placed as to absorb blood and prevent its reaching throat.

Position.—Patient supine; head elevated, resting upon sound side. Surgeon on side of operation. Assistant opposite.

Landmarks.—Alveolar margin; first and second molars; malar ridge of superior maxilla.

Incision.—Having retracted upward and backward the upper lip and cheek, a vertical incision is made above the roots of the first and second molars and as nearly over the interspace between them as is accessible, being guided in the placing of the incision by the prominent ridge of the superior maxilla leading up to the malar process.

Operation.—(1) Carry the incision through mucous membrane and periosteum to the bone—free the periosteum from the bone by periosteal elevator—retract soft parts anteriorly and posteriorly. (2) Apply a small trephine just above the back part of the root of the first molar and high enough to avoid its fangs, directing it upward, inward, and backward—until it is felt to have entered the cavity. (3) Remove diseased tissue of antrum with scoop or curette. By tilting head forward, irrigation may be made from artificial opening through middle meatus of nose. The opening should be plugged during meals, or a tube with an adjustable plug should be worn.

Comment.—(1) Avoid injury to infraorbital vessels and nerves by keeping below and to outer side of infraorbital foramen. (2) Avoid entering the orbit. (3) This operation is probably better than entering through the socket of a tooth—while the latter gives better drainage, the former better protects from entrance of food into the sinus from the mouth.

OPENING OF MAXILLARY SINUS (ANTRUM OF HIGHMORE) THROUGH THE SOCKET OF THE SECOND MOLAR TOOTH.

Description.—The removal of the tooth alone may accomplish sufficient drainage, as the fangs may open directly into the antrum, save for their thin bony covering, which is easily broken down. If the opening made by the simple withdrawal of the tooth be insufficient (which is usually the case) it may be deepened and enlarged.

Preparation and Position.—Same as in last operation.

Landmarks.—Second molar tooth.

Operation.—Draw second molar tooth. If fangs leave opening communicating with the antrum, deepen and enlarge it with a bone-drill. If no opening be found, drill through the intervening bone. Drain and treat as in the above operation.

Comment.—This operation gives better drainage than the preceding, but is more apt to be contaminated from the mouth, unless the opening be closed artificially by some form of plug, except during irrigation. The loss of the tooth is entailed. The operation is especially indicated when the tooth is already absent.

III. THE EYEBALL AND THE ORBIT.*

OPERATIONS UPON THE EYEBALL.

SURGICAL ANATOMY OF THE ORBIT.

Fibrous Tissues of the Orbit.—(1) Orbital periosteum. (2) Fascia ensheathing muscles, vessels, optic and other nerves, and enclosing lobules of fat. Posteriorly, it blends with periosteum (where the fascia is thinner

* Only the removal of the eye will be here considered, most of the operations upon the contents of the orbit belonging to the special field of ophthalmology.

and looser). Anteriorly, it is thicker and firmer, accompanying the muscles nearly to the equator of eyeball, where it divides into an anterior lamina, forming a complete investment and passing forward to eyelids,—and a posterior lamina, turning backward and covering the hinder third of the globe. (3) Tenon's capsule, a serous membrane (whose layers are separated by Tenon's lymph-space)—surrounding the hinder two-thirds of the eyeball. The visceral layer follows the convexity of the sclerotic, from the ciliary margin of the cornea to entrance of optic nerve, where it is reflected from the eyeball and, becoming the parietal layer, blends with the posterior lamina of the muscle-fascia (v. s.). Anteriorly, Tenon's capsule is continued into the conjunctiva. Posteriorly, it is continued with the subarachnoid space through the sheath of the optic nerve. Tenon's capsule is pierced by the ocular muscles, which are surrounded by sheaths from Tenon's capsule.

Muscles of the Orbit.—Recti superior, inferior, external and internal; obliquus oculi superior and inferior; levator palpebræ superioris.

Arteries of the Orbit.—Ophthalmic and its branches—lachrymal; supraorbital; posterior ethmoidal; anterior ethmoidal; palpebral; frontal; nasal; muscular; anterior ciliary; short ciliary; long ciliary; arteria centralis retinæ.

Veins of the Orbit.—Superior muscular; anterior and posterior ciliary; anterior and posterior ethmoidal; lachrymal; central vein of retina;—all form superior ophthalmic vein. Inferior muscular and lower posterior ciliary form inferior ophthalmic. Superior and inferior ophthalmic veins unite to form the common ophthalmic vein.

Nerves of the Orbit.—Optic; motor oculi; trochlear; lachrymal, frontal and nasal branches of the ophthalmic division of the fifth; ophthalmic (ciliary) ganglion.

ENUCLEATION OF THE EYEBALL.

Description.—Consists of the removal of the eyeball intact, after incising the conjunctiva, severing the attachment of the ocular muscles to the globe and dividing the optic nerve at its entrance into the eyeball. Indicated chiefly in malignant disease and in extensive injury.

Special Instruments Required.—Eye-speculum; toothed fixation forceps; strabismus hook; blunt-pointed scissors curved on the flat.

Position.—Patient supine; head elevated. Surgeon on side of operation. Assistant opposite.

Landmarks.—Reflection of the conjunctiva on to the globe.

Operation.—(1) Insert a spring eye-speculum, an arm passing between the globe and each lid, holding the latter out of the way. (2) Catch up the ocular conjunctiva with toothed forceps and snip it with blunt-pointed scissors all around, near to the cornea. (3) Having opened Tenon's capsule, catch up each rectus tendon—generally beginning with the external, then the superior and inferior, ending with the internal—with a strabismus-hook, drawing them forward and dividing them with scissors close to their sclerotic attachment. (4) Press upon the speculum slightly so as to push it behind the equator of the eye, which will cause the ball to start forward. Pass curved scissors backward, on the outer side of and behind the globe, and divide the optic nerve close to the eyeball. Draw the eyeball forward and cut the superior and inferior oblique muscles near the sclerotic—and remove the eye. (5) The ophthalmic artery is immediately clamped and tied. Other

bleeding vessels are controlled by ligature or by pressure maintained by dressing.

Comment.—(1) Where the globe has collapsed, or collapses during the operation, seize it with forceps and dissect it out. (2) In disease it is often indicated to remove all the soft tissues of the orbit, as well as the eye proper.

EVISCERATION OF THE EYEBALL.

Description.—Consists in the removal of the contents of the eyeball, leaving a stump composed of the tissues of the globe for the better reception of an artificial eye within the original sclerotic. Indicated chiefly in suppuration of the eyes and in limited lesions.

Special Instruments.—Those given under Enucleation, together with the following in addition—Beer knife; sharp scoop; needle-holder; curved needles; silk; glass globes of various sizes, with globe-introducers.

Position and Landmarks.—Same as for Enucleation.

Operation.—(1) Introduce eye-speculum as for Enucleation. (2) Steady eye by grasping conjunctiva with fixation forceps. Remove cornea by incising sclerotic with a Beer knife a little outside of the sclero-corneal junction —continuing the incision a short distance into the sclerotic on each side, at the mid-lateral aspects of the opening—to provide for the insertion of the artificial eye and an easy coming together of the wound. Remove from the sclerotic the entire contents of the globe with a scoop, especially from the uveal tract. (3) Control hemorrhage by hot or cold irrigation. Insert a glass eye of appropriate size and appearance—suturing the edges of the wound over it, the sutures passing through the conjunctiva and sclerotic, around the circumference and uniting the lips of the two lateral incisions.

IV. THE EAR AND EUSTACHIAN TUBE.*

SURGICAL ANATOMY OF THE MEMBRANA TYMPANI.

Description.—The membrana tympani is an ellipsoidal disc (with slight central depression) about 10 mm. (between $\frac{6}{16}$ and $\frac{7}{16}$ inch) in length, 9 mm. (between $\frac{5}{16}$ and $\frac{6}{16}$ inch) in width, and about 0.1 mm. in thickness. It extends obliquely from above downward, its circumference being lodged in the groove of the tympanic ring, at the inner end of the external auditory meatus—forming the boundary between external and middle ear. It consists of three layers—the cuticular covering without, the fibrous layer, and the mucous lining within. The handle of the malleus descends downward and backward between its two inner layers and is attached to the membrana tympani a little below its center, at the umbo. The short process of the malleus and long process of the incus are visible through the membrana tympani at its upper part. A cone of light is generally visible extending from the umbo (end of manubrium or handle of malleus) downward and forward toward the circumference.

*Only the introduction of the ear-speculum and the eustachian catheter and the puncture of the ear-drum will be here considered, most of the operations upon the ear belonging to the special field of Otology.

INTRODUCTION OF EAR SPECULUM FOR EXAMINATION OF MEMBRANA TYMPANI.

Seat patient upright in chair, with a good natural light (other than sunlight) or artificial illumination available—the patient occupying such a position as to enable the light to be reflected by a head-mirror, worn by the operator, into the auditory canal. Warm and moisten a speculum (Gruber's silver speculum, or other)—grasp the upper free portion of the auricle between the bent knuckles of the index and middle fingers of the left hand—draw the ear upward, backward, and outward (suggested by the letters u, b, o), to straighten the canal—insert the speculum, held lightly between right index and thumb, by twirling it forward and backward in a small arc until it has sunk to the right depth in the proper axis of the external auditory canal, when it is steadied by the left thumb placed upon its rim. It may then be manipulated in different directions to expose all portions of the depth of the auditory canal and the surface of the membrana tympani—noticing particularly the color and position of the drum as to whether normally retracted, or abnormally bulging from a collection of fluid in the tympanum.

PARACENTESIS TYMPANI.

Description.—Incision of tympanic membrane for the purpose of drainage of the tympanic cavity and for irrigation. Indicated chiefly in otitis media.

Instruments Required.—Ear-speculum; double-edged paracentesis needle.

Preparation.—Cleansing of auditory canal by antiseptic irrigation.

Position.—Patient sits upright. Surgeon sits opposite the involved ear.

Landmarks.—Handle of malleus showing through the membrana tympani.

Operation.—(1) Insert the ear-speculum—expose the membrana tympani in the field of the speculum—and recognize the handle of the malleus. (2) Incise the ear-drum, making the incision in the posterior half of the membrane, between the handle of the malleus and the posterior border of the membrana tympani, and enlarge the opening vertically—taking care not to wound the middle ear.

INTRODUCTION OF THE EUSTACHIAN CATHETER.

Place the patient in a chair opposite the operator, with head thrown back and supported upon the back of the chair or upon a rest. The surgeon, standing or sitting, places the fingers of his left hand upon the patient's forehead, while his left thumb pushes the tip of the patient's nose upward (to bring the nostril on a level with the floor of the nose). Warm and lubricate the eustachian catheter, having atomized the nasal cavity with a local anesthetic, if necessary—push the tip of the catheter, pointing downward, along the floor of the nose, until it touches the posterior wall of the pharynx—turn the point obliquely outward but not quite horizontal—withdraw the instrument until the point is felt to glide over the projecting posterior border of the eustachian tube—now turn the tip further outward, until the guide-ring at the posterior end of the catheter points to the outer canthus of the eye of

the same side—when the direction of the beak will generally coincide with the axis of the eustachian tube.

V. THE NOSE AND NASAL CAVITIES.

For operations exposing the Nasal Cavities, see Excisions and Osteoplastic Resections (pages 455, 456). Most of the other operations upon the Nose and Nasal Cavities belong to the special field of Rhinology.

VI. THE TONGUE.

SURGICAL ANATOMY.

Connections of the Tongue.—(1) With Os Hyoides; by hyoglossi and geniohyoglossi muscles, and hyoglossal membrane. (2) With Styloid Process; by styloglossi muscles. (3) With Inferior Maxilla; by geniohyoglossi muscles. (4) With Pharynx; by superior constrictors and mucous membrane. (5) With Epiglottis; by median and two lateral glosso-epiglottic folds of mucous membrane. (6) With Soft Palate; by anterior pillars of the fauces (*i. e.*, the palatoglossi muscles covered by mucous membrane). (7) With Gums and Floor of Mouth; by mucous membrane and frænum linguæ.

Muscles Entering into Formation of Tongue.—(1) Extrinsic Muscles (arising externally and terminating in tongue); styloglossi, hyoglossi, geniohyoglossi, palatoglossi, pharyngeoglossal portion of superior constrictors, chondroglossi. (2) Intrinsic Muscles (entirely within tongue and forming its chief bulk); superior, transverse, vertical and inferior linguales.

Arteries of Tongue.—(1) Lingual (for its surgical anatomy, see Ligations); dorsalis linguæ branch of Lingual (arises beneath hyoglossus and passes to dorsum of tongue); sublingual branch of lingual (arises at anterior border of hyoglossus and passes forward between geniohyoglossus and sublingual gland); ranine branch of lingual (arises at anterior border of hyoglossus and passes forward beneath under surface of tongue). (2) Tonsillar branch of facial; muscular branch of facial to styloglossus. (3) Branches of ascending pharyngeal branch of external carotid.

Veins of Tongue.—Correspond with arteries.

Nerves of Tongue.—Lingual branch of trifacial (to papillæ of front and sides of tongue); lingual branch of glossopharyngeal (to mucous membrane of base and sides and to papillæ circumvallatæ); hypoglossal (to muscular substance of tongue); chorda tympani (to lingualis); sympathetic filaments.

GENERAL SURGICAL CONSIDERATIONS IN THE REMOVAL OF PART OR THE WHOLE OF THE TONGUE.

Indications.—Chiefly removed for malignant growth.

Varieties of Operation and Manners of Operating.—(1) Small portions of tongue may be excised by a V-shaped, or other, incision. One half of tongue, transversely or longitudinally, may be removed. The entire organ may be excised. (2) The tongue may be removed through the unaltered mouth; through an incision in the neck; through the mouth after splitting the cheek, or temporarily dividing the inferior maxilla; or after excision of the inferior maxilla. (3) It may be removed with or without

previous ligation of the lingual arteries, either beneath the hyoglossi or at their origin—and with or without previous tracheotomy—dependent upon the difficulties and circumstances of the case. (4) It may be removed by scissors; by knife; by some form of écraseur, applied through mouth or neck; by ligature; or by galvano-cautery.

General Observations.—Where the involvement is strictly limited to the tongue alone, it should be removed through the mouth. Where the floor of the mouth or the cervical glands, and especially both are involved, the tongue should be removed through the neck, together with the simultaneous removal of all the diseased tissues. Where but a limited portion of the tongue is involved, especially where the involvement is at or toward the anterior end of the organ, a limited portion of tissue, or a transverse or longitudinal half may be removed. The natural separation of the two halves of the tongue by a fibrous septum makes it possible to remove one half alone comparatively easy. The tongue is readily split by placing a stout silk retractor in each half, about 2.5 cm. (1 inch) behind the tip and about 1.2 cm. (½ inch) from the median line—while these are drawn in different directions, the tongus is split down the median fibrous raphé with blunt-pointed scalpel or scissors. In removing one half or the entire tongue, it is readily drawn out of the mouth after dividing the frænum and mucous membrane of the floor of the mouth in front, and the anterior pillars of the fauces laterally. The chief difficulties of operating are the narrow working-room and hemorrhage. A good light is necessary in all cases. In exceptional cases the extraction of two or three of the lower teeth to give fuller working-room is indicated—the teeth being subsequently replaced upon a dental splint.

Control of Hemorrhage in Operations upon the Tongue.—The chief hemorrhage is from the lingual arteries, divided in the floor of the mouth, anterior to the hyoglossi (where they are called the ranine)—the position of the cut vessels being the chief difficulty encountered—the hemorrhage being apt to flood the field of operation and get into the air-passages. The head is to be held so as to direct the flow of blood away from the back of the throat. If the mouth be kept well open, the cut arteries are inclined to spurt out of the mouth. By firm pressure applied without upon the neck, between the inferior maxilla and hyoid bone, the stump of the tongue can be brought into view, and the hemorrhage also temporarily arrested by that pressure. The same thing may also be accomplished by hooking a finger or an instrument around the base of the stump and drawing it forward. Hemorrhage can be thus temporarily controlled until the vessels can be clamped and tied. If only the anterior half or two-thirds of the tongue is to be removed, a double ligature may be passed through the center of the organ, well behind the growth and temporarily tied on either lateral aspect of the tongue, thereby controlling hemorrhage. Preliminary ligation of the lingual arteries in the neck insures a comparatively dry field, and therefore more thorough work.

INSTRUMENTS USED IN REMOVAL OF THE TONGUE.

Special mouth-gags; cheek retractors; blunt hooks; tongue depressors; tenacula; tongue forceps; sponges in holders; scalpels, various; dissecting forceps; toothed forceps; artery clamp forceps, long and short; scissors, straight and curved, long and short; aneurism-needles, various; ligature carriers; needles, various; ligatures, silk and chromic gut; sutures, silk and

gut; needle-holder; silk-retractors for tongue; curved needle in handle to carry silk-retractors through tongue; volsella; tracheotomy tubes; tampon cannula; thermocautery; Gigli or chain saw; bone-holding forceps; bone-cutting forceps; drill; wire; wire-cutters (in case lower maxilla is to be divided); hare-lip pins, sometimes used if cheek be split.

EXCISION OF LIMITED PORTIONS OF THE TONGUE.

Description.—Limited portions of the tongue are best excised, where possible, by a V-shaped incision. Where it is possible to do so, the resulting edges of the wound are brought together and sutured with silk—otherwise the margins must heal by granulation. This method is generally applicable to limited involvement of the free portion of the tongue.

Preparation and Position.—As in the removal of the entire organ. (See the following operation.)

Landmarks.—The known attachments of the tongue to the structures of the mouth, and the position of its vessels.

Operation.—Gag the mouth open, as in the complete operation. Place a thread retractor on each side of the area to be removed. An assistant, with a retractor in each hand, draws the tongue forward out of the mouth. The operator seizes the part to come away with toothed forceps held in his left hand—and taking a knife in his right hand, he enters it behind the center of the growth to be removed, allowing a fairly wide area, and cuts forward on one side of the area. The knife is then entered at the same spot and made to cut its way out on the opposite side of the area, thus removing a V-shaped piece. The bleeding vessels are ligatured with gut, or twisted—and the lips of the incision, if practicable, are sutured, otherwise they are left to granulate.

Comment.—For removal of one half of the tongue longitudinally, see the following operation. For removal of one half of the tongue transversely, hemorrhage may be controlled as mentioned under General Surgical Considerations—the tongue is then drawn out of the mouth by thread retractors and the anterior portion removed by curved scissors, cutting transversely just anterior to the temporary ligatures. The lingual arteries are then clamped and tied with chromic gut or silk, the smaller ones being twisted, and the stump left to heal by granulation.

EXCISION OF THE TONGUE THROUGH THE MOUTH, WITHOUT PRELIMINARY LIGATION OF THE LINGUAL ARTERIES.

WHITEHEAD'S OPERATION.

Description.—The tongue is drawn forward with a double silk retractor—its connections with the floor of the mouth and the anterior pillars of the fauces are divided with scissors—its base is similarly divided transversely—the lingual arteries being seized just before division, divided, clamped, and then twisted.

Preparation.—Thorough cleansing of the mouth and teeth.

Position.—Patient lies near right edge of table, shoulders and head raised almost to the sitting position (preferably until his head is nearly on a level with the surgeon's axilla)—his head being turned to the right side and slightly forward, so that blood gravitates out of the mouth. A gag is placed

in position upon the left side of the mouth and held firmly pressed to the left side of the face. Surgeon stands to the right. Assistant opposite.

Landmarks.—The known attachments of the tongue, and the position of its vessels.

Operation.—(1) Having gagged the mouth wide open, pass a heavy double ligature through the anterior portion of the tongue, in the median line, and, by means of this retractor, draw the tongue out of the mouth.

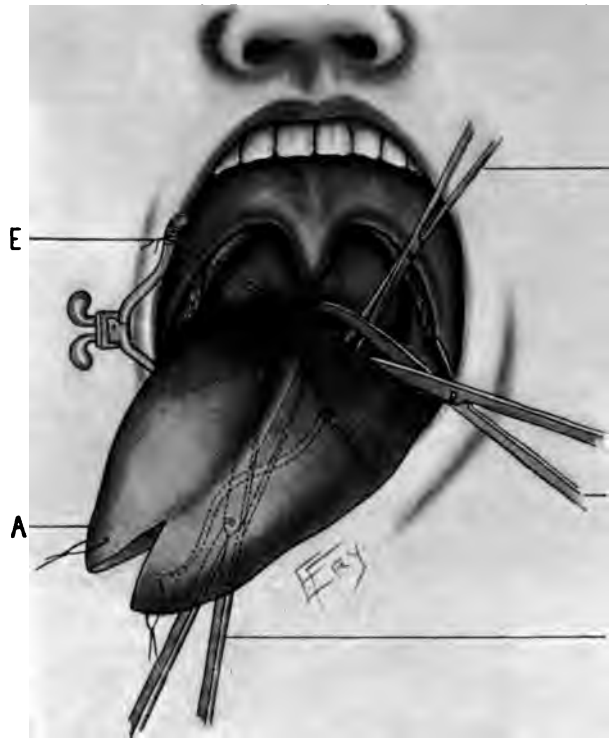

Fig. 326.—WHITEHEAD'S EXCISION OF THE TONGUE THROUGH THE MOUTH:—A, Tongue partly split in the median raphé and drawn out of the gagged mouth by thread retractors; B, Scissors freeing the attachments of the tongue from the floor of the mouth; C, Scissors dividing the anterior pillar of the fauces and base of the tongue; D, Catch-forceps clamping the lingual artery *in situ* prior to its division by scissors; E, Suture through the glosso-epiglottidean fold, placed before its division, for drawing the base of the tongue forward.

(See Fig. 329.) (2) Separate the tongue from the floor of the mouth and the anterior pillars of the fauces by cutting boldly through the frænum linguæ, connective tissues and the anterior pillars, while the tongue is drawn well forward by the thread retractors, freeing the tongue first horizontally to a point behind the focus of disease (or as far as practicable) and then dividing it transversely across its base—cutting not in little snips, but in decided cuts carried boldly on until near the known position of the lingual arteries upon the lingualis, just to the outer side of the geniohyoglossi—sponging away all blood promptly as the division progresses. (3) Just prior to dividing the linguals, they are seized, together with the tissue immediately surrounding, by artery forceps

and clamped—the tissues including the arteries are then cut—after which the arteries are caught by a second pair of clamp forceps, twisted, and let go. (4) Before finally severing the last attachments of the tongue, pass a stout silk retractor through the glosso-epiglottidean fold, to enable the base of the tongue-stump to be drawn forward in case of hemorrhage or difficulty of respiration. Allow this ligature to remain attached for about twenty-four hours, in case of need. (5) The stump receives, at the hands of the author of the operation, an immediate coating of a special antiseptic, styptic varnish. Other surgeons merely dust the stump with some form of powder. Others make no special form of application, merely frequently washing the mouth with an antiseptic solution.

Comment.—(1) The operation is rapidly and boldly done, until the tongue is removed and the arteries and the stump are in view and in control. (2) The thread retractor in the glosso-epiglottidean fold may be omitted, as the tongue may be hooked forward with a finger or an instrument if necessary. (3) Jacobson first splits the tongue in the middle line and removes each half separately. He also cuts a transverse groove through the side and dorsum of the tongue nearly to the artery, and then tears through with the finger and closed scissors until the artery is reached and clamped. (4) If necessary to remove but one half of the tongue, a thread retractor is placed through the tip of the sound side—the tongue is then split through the median fibrous raphé (while the opposite side is held by forceps or another thread retractor) —the connections with the floor of the mouth and the anterior pillars of the fauces are separated on that side alone—and the operation completed as above. (5) Preliminary tracheotomy is not generally done, but may be done if indicated. (6) The lingual arteries may be tied, when exposed in the above way, instead of being merely twisted.

EXCISION OF THE TONGUE THROUGH THE MOUTH, AFTER PRELIMINARY LIGATION OF THE LINGUAL ARTERIES IN THE NECK.

Description.—The two linguals are first tied in the neck, and the tongue is then removed through the mouth by means of scissors.

Preparation, Position, and Landmarks.—As in the preceding operation.

Operation.—The two lingual arteries are first tied in the neck, beneath the hyoglossi—precisely as in the simple ligation of those vessels (see Ligations, page 38)—and the wounds closed and dressed. The tongue is then removed through the gagged mouth by means of scissors, just as in the Whitehead operation previously described. Thus comparatively slight hemorrhage occurs—from the dorsalis linguæ branch of the lingual and from branches of the facial and ascending pharyngeal of the external carotid.

EXCISION OF THE TONGUE, TOGETHER WITH THE CERVICAL AND SUBMAXILLARY GLANDS, BY AN INCISION IN THE NECK, AFTER PRELIMINARY TRACHEOTOMY AND LIGATION OF THE LINGUAL AND FACIAL ARTERIES.

KOCHER'S OPERATION.

Description.—After a preliminary tracheotomy and the ligation of the lingual and facial arteries in the neck, upon both sides, followed by the removal

of the cervical and submaxillary glands (and the sublingual, if necessary) of both sides, the tongue is drawn through an incision made through one side of the floor of the mouth, from the wound in the neck, and removed by division transversely at its base. The preliminary tracheotomy is preferably done a few days in advance, that the patient may have become accustomed to breathe through the tube at the time of the operation. Thus several distinct operations are done—tracheotomy; ligation of both lingual and both facial arteries at their origin; excision of the cervical and submaxillary, and probably sublingual, glands; and the removal of the tongue.

Preparation.—Thorough cleansing of mouth and teeth. A preliminary tracheotomy done several days in advance of the main operation.

Position.—Patient supine, at right edge of table; shoulders elevated; head thrown back and turned to one side; neck prominent. Surgeon on side

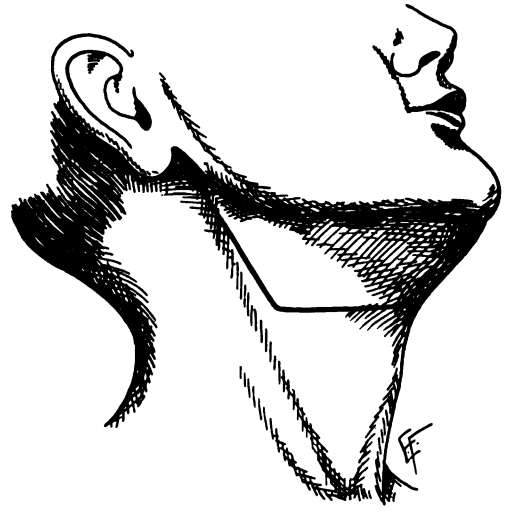

Fig. 330.—Incision for Excision of Tongue through the Neck, together with the Ligation of Facial and Lingual Arteries, and Removal of Glandular Tissue (Kocher's Operation).

of operation. Assistant opposite. (The positions of the principals will differ somewhat with the various steps of the complex operation.)

Landmarks.—Those of the following operations (*q. v.*), tracheotomy, ligation of lingual and facial arteries in the neck, excision of submaxillary, sublingual, and cervical glands, together with the following;—the anterior border of the sternomastoid, the hyoid bone, and the anterior belly of the digastric muscle.

Incision.—See step No. 3 of the Operation.

Operation.—(1) A tracheotomy is first performed in the usual way—and, where possible, several days in advance. (See page 550.) (2) The pharynx is plugged with a sterile sponge attached to a piece of silk—to prevent the ingress of blood into the trachea or esophagus. (3) The incision is now made along the anterior border of the sternomastoid, from the mastoid process to about the center of the muscle—thence transversely forward in the crease between the floor of the mouth and the neck, to the hyoid bone—thence along

the anterior belly of the digastric to the symphysis menti. (See Fig. 330.) (4) Having divided skin and subcutaneous fascia, and ligated the subcutaneous veins, turn back, by dissection, the flap thus marked out, and, displacing it upward, suture it to the cheek. (See Fig. 331.) (5) Expose the anterior border of the sternomastoid, as far down as the great cornu of the hyoid bone, also the anterior belly of the digastric muscle—and remove, *en masse*, all enlarged glands from the upper end of the sternomastoid and from

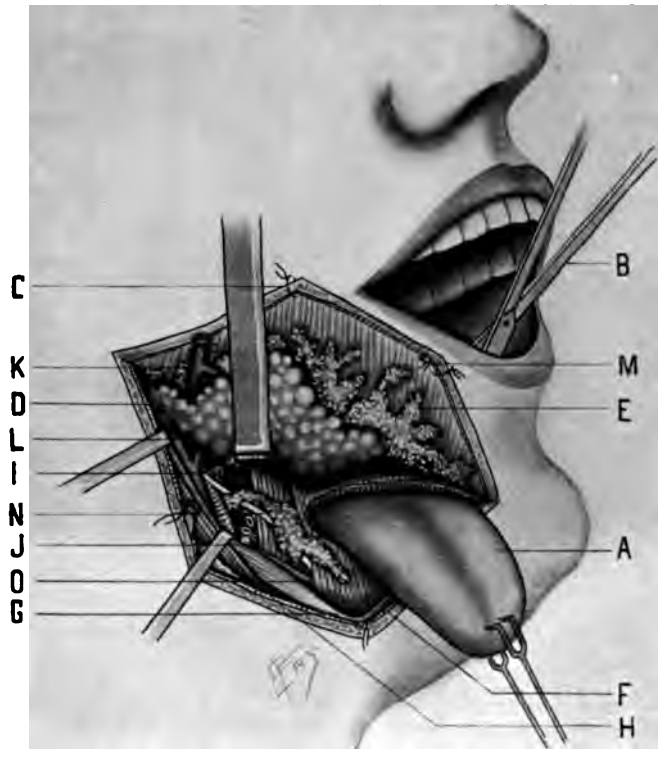

Fig. 331.—Kocher's Excision of the Tongue through an Incision in the Neck:—A, Tongue drawn through incision in mylohyoid muscle; B, Scissors introduced through mouth, cutting base of tongue away from hyoid bone and its remaining attachments; C, Flap raised from neck and stitched to cheek; D, Submaxillary gland being dissected out; E, Lymphatic glands and connective tissue being dissected out; F, Anterior belly of digastric; G, Posterior belly of digastric; H, Sternomastoid muscle; I, Facial artery ligated near origin from external carotid; J, Lingual artery ligated near origin; K, External jugular vein ligated; L, Internal jugular vein and communicating branch with facial; M, Anterior jugular vein; N, Hypoglossal nerve crossing hyoglossus muscle; O, Ranine vein.

beneath the angle and body of the inferior maxilla (see page 134). The veins are ligated as encountered and the mass of involved glands and connective tissue are raised together, exposing the posterior belly of the digastric and stylohyoid muscles posteriorly. (6) The submaxillary gland is dissected up, working from behind, and removed simultaneously with the cervical glands. (See page 571.) The sublingual gland is similarly removed, if involved. (See page 572.) (7) The facial artery is tied near its origin from the external carotid, as soon as exposed in the process of raising the submaxillary gland

(see page 40). The lingual artery is also tied near its origin, before passing under the hyoglossus (see page 38). All veins encountered are ligated. (8) Steps (3), (4), (5), and (7) are repeated on the opposite side, if the entire tongue is to be removed—and also (6) if the submaxillary and sublingual, as well as the lymphatic glands, be involved. (9) The mylohyoid muscle is now exposed and divided as far as necessary. The mucous membrane is then cut close to and parallel with the inferior maxilla—and the mouth thus entered. (10) The tongue is seized and drawn through the floor of the mouth and the wound in the neck. While under tension it is cut away from the hyoid bone, by means of blunt scissors introduced through the mouth. The stump is then drawn forward in the mouth and the few remaining arterial twigs which bleed are twisted. (11) The wound is not sutured—but is allowed to close by granulation, with the freest possible drainage. (12) The tracheotomy tube remains in until the wound is granulating well—the entrance to the larynx being, in the mean time, plugged to prevent lung infection. Feeding is carried on by the introduction of fluids through an esophageal tube. The mouth is frequently washed with an antiseptic solution.

Comment.—If but one half of the tongue is to be removed, an incision is made only upon the corresponding side of the neck—the tongue is then split down its center, from within the mouth, and the diseased half drawn through the wound in the neck and divided at its base by blunt, curved scissors introduced through the mouth.

NOTE.

Operations upon the Teeth; Hard Palate; Lips; Gums; Soft Palate; and Uvula, will not be separately considered.

Operations upon the following structures of the Head will be found under those structures among the Operations of General Surgery, namely, Bones; Joints; Ligaments; Fasciæ; Muscles; Arteries; Veins; Lymphatics; Nerves, Plexuses, and Ganglia.

CHAPTER II.

OPERATIONS UPON THE SPINE AND SPINAL CORD.

SURGICAL ANATOMY OF THE SPINE AND SPINAL CORD.

Muscles in Relation with the Spine.—(1) Cervical Region: Anteriorly; rectus capitis anticus major; rectus capitis anticus minor; rectus lateralis; longus colli. Laterally; scalenus anticus, medius and posticus. Posteriorly; trapezius; levator anguli scapulæ; rhomboideus minor; serratus posticus superior; splenius capitis; splenius colli; cervicalis ascendens; transversalis colli; trachelomastoid; spinalis colli; complexus; biventer cervicis; semispinalis dorsi; semispinalis colli; multifidus spinæ; supraspinales; interspinales; intertransversales; rectus capitis posticus major; rectus capitis posticus minor; obliquus capitis inferior; obliquus capitis superior. (2) Thoracic Region: Antero-laterally; psoas minor. Postero-laterally; trapezius; latissimus dorsi; rhomboideus minor; rhomboideus major; serratus posticus superior; serratus posticus inferior; splenius capitis; splenius colli; longissimus dorsi; transversalis colli; trachelomastoid; spinalis dorsi; complexus; biventer cervicis; semispinalis dorsi; semispinalis colli; multifidus spinæ; rotatores spinæ; interspinales; intertransversales; levatores costarum. (3) Lumbar Region: Antero-laterally; crura of diaphragm; psoas magnus; psoas minor. Postero-laterally; latissimus dorsi; serratus posticus inferior; erector spinæ; longissimus dorsi; spinalis dorsi; multifidus spinæ; interspinales; intertransversales; transversalis abdominis; quadratus lumborum. *Note*—The ligamentum nuchæ extends from external occipital protuberance to spinous process of seventh cervical vertebra. The supraspinous ligament is a continuation downward of the ligamentum nuchæ, stretching between the spinous processes.

Arteries of the Spinal Region.—(1) Arteries in the Neighborhood of the Spine; muscular branches and arteria princeps cervicis of occipital; prevertebral branches of ascending pharyngeal; lateral spinal, muscular, anterior spinal, and posterior spinal branches of vertebral; ascending cervical of inferior thyroid; superficial cervical of transversalis colli; muscular, anterior spinal, and profunda cervicis of superior intercostal; muscular and spinal branches from the posterior branches of the intercostals; muscular and spinal branches from the dorsal branches of the lumbar; middle sacral artery from abdominal aorta; lumbar branch from ileo-lumbar; superior and inferior branches from the lateral sacral arteries. (2) Arteries of the Spinal Cord; anterior spinal—from vertebrals, intercostals, lumbar and other arteries (passing to cord along anterior roots); posterior spinal—from vertebrals, intercostals, and other arteries (running just in front of line of attachment of posterior nerve-roots); anastomotic chain—formed by branches of posterior spinal running behind line of posterior nerve-roots.

Veins of the Spinal Region.—(1) Extra-spinal; anterior spinal plexus (in front of bodies of vertebræ, emptying into neighboring veins); dorsal spinal plexus (around spinous, articular, transverse, and laminar processes,

emptying into vertebral, dorsal branch of intercostal, lumbar and lateral sacral). (2) Intra-spinal; (a) Meningeal Veins; two anterior longitudinal spinal (on each side of posterior surfaces of bodies of vertebræ) connected by transverse branches, into which the venæ basis vertebræ open (emptying into posterior longitudinal veins, the vertebral, intercostal, lumbar, and sacral veins); two posterior longitudinal spinal (between posterior wall of spinal canal and dura mater), emptying into anterior longitudinal, dorsal, and spinal veins. (b) Medullary Veins; coming from substance of cord, empty into the venous ring of each vertebra.

Nerves of the Spinal Region.—Spinal nerves (emerging through the intervertebral foramina at a considerably lower level than their origin from the cord); posterior divisions of the cervical, dorsal, and lumbar nerves; sympathetic ganglia and nerves.

Membranes of the Cord.—(1) Dura Mater; loose, strong, fibrous sheath surrounding the cord—prolonged in tubular form around spinal nerves and cauda equina—separated from spinal canal by lax areolar tissue and plexus of veins which connect its rough external surface to periosteum and ligaments—extends from dura of brain to second or third sacral vertebra, and thence to base of coccyx as sheath of filum terminale—its smooth inner surface is separated by subdural space from arachnoid and is connected to cord by ligamentum denticulatum (a special development of pia mater)—it sends tubular prolongations around spinal nerves, which merge into their epineurium, each tube being divided into an anterior compartment for anterior nerve-root and posterior compartment for posterior nerve-root. (2) Arachnoid; continuous with cerebral arachnoid, surrounding cord down to second or third sacral vertebra—separated from dura by subdural space—separated from pia mater by subarachnoid tissue (subarachnoidean space, for cerebrospinal fluid)—sends tubular prolongations along nerve-roots—connected to pia by incomplete septum posticum. (3) Pia Mater; formed by two layers, only the outer, stronger layer being continuous with cerebral pia mater—outer and inner layers pass into anterior fissure of cord—only inner layer dips into posterior fissure. Ligamenta denticulata—fibrous bands continuous with pia, attached on either side of cord and externally to dura—not piercing arachnoid but its denticulations receiving tubular sheaths from it—extending from foramen magnum above and continuous with filum terminale below. Linea splendens—a linear thickening on anterior surface of cord. Filum terminale—prolongation of pia-matral covering of cord—attached to lower end of sacrum or first piece of coccyx.

SURFACE FORM AND LANDMARKS OF SPINE AND SPINAL CORD.

The spinal cord extends from the upper border of the atlas to the lower part of the body of the first lumbar vertebra, and is thence continued as the filum terminale to the lower end of the sacrum or the first piece of the coccyx. At birth the cord extends to the third lumbar vertebra.

The cervical enlargement of the spinal cord extends from the third cervical to the second dorsal vertebra, and the lumbar enlargement from the ninth to the twelfth dorsal.

The anterior nerve-roots emerge from the cord along the antero-lateral fissure, and the posterior nerve-roots along the postero-lateral fissure—and unite near the outer part of the intervertebral foramina. The intrathecal nerve-roots increase in length as they descend.

The spinous processes of the vertebræ are found in the nuchal, dorso-lumbar, and sacral furrows. The spines of the more central dorsal region overlap each other considerably—those of the lower cervical and upper dorsal but slightly—those of the lower dorsal slightly or not at all—and those of the upper cervical and entire lumbar not at all.

The spinous process of the seventh cervical vertebra (vertebra prominens) is generally easily located, and from this the spines of the vertebræ above and below are readily found by counting—all the spinous processes being more prominent when the vertebral column is bent forward. Other less accurate methods of locating the spines are sometimes used. When the arms are at the side, the superior angle of the scapula corresponds, generally, to the interval between the first and second dorsal spines (and the upper border of the second rib);—the root of the spine of the scapula with the third dorsal spine, or with the interspace between the third and fourth dorsal spines;—and the inferior angle of the scapula with the seventh dorsal spine, or with the interspace between the seventh and eighth (and sometimes with the eighth rib). The twelfth dorsal spine corresponds with the head of the twelfth rib. The third lumbar spine is generally slightly above the umbilicus,—and the fourth lumbar spine is on a level with the highest part of the iliac crests.

The approximate relations of the origins of the roots of the spinal nerves to the spinous processes of the vertebræ are, according to R. W. Reid, as follows;—(**a**) Second Cervical arises opposite the arch of the atlas,—third, from opposite the spine of the axis,—fourth, from opposite the interspace between second and third spines,—fifth, sixth, seventh, and eighth arise opposite the spine of the second cervical vertebra above the intervertebral foramen of exit of each nerve. (**b**) First, second, third, fourth, fifth, and sixth Dorsal Nerves arise opposite the spinous processes of the third vertebra above their respective foramina of exit,—seventh, eighth, ninth, tenth, eleventh, and twelfth arise opposite the spines of the fourth vertebra above their respective foramina of exit. (**c**) Lumbar Nerves arise near the spines of the tenth and eleventh dorsal vertebræ. (**d**) Sacral Nerves arise between the eleventh dorsal and first lumbar spines.

GENERAL SURGICAL CONSIDERATIONS IN OPERATIONS UPON THE SPINE AND SPINAL CORD.

Preparation.—The region is shaved if any hair be present.

Position.—Patient lies in the semi-prone posture, supported by cushions. Surgeon stands behind patient. Assistant at surgeon's side, either above or below site of operation.

Control of Hemorrhage.—Bleeding is apt to be considerable during the division of the soft parts. It is best controlled in the following ways—(**1**) By clamping, and subsequently gut-ligaturing, the larger vessels,—(**2**) Clamping and twisting the smaller vessels,—(**3**) Controlling the general oozing by firm gauze pressure and hot saline solution,—(**4**) By working alternately in the clearing of the vertebral furrows, temporarily packing the first side firmly with gauze, while incising and clearing the second side, then packing the second and returning to the first, and so forth.

Manner of Incising the Soft Parts and Clearing the Vertebral Grooves.—Owing to the depth at which the laminæ lie and the close attachment of muscular and fibrous tissues to the spines, laminæ, and transverse processes of the vertebræ, it is generally, at the first attempt, a difficult matter

to clear the vertebral groove on each side of the spinous processes and expose the laminæ completely bared of all their soft coverings. This process of clearing is more easily and thoroughly accomplished by means of a stout, sharp, bluntly-rounded knife wielded in such a manner as always to cut into the acute or right angle formed by the attachment of the muscles of the vertebral column, rather than toward the obtuse angle (as one would more readily strip the spines of a feather from the quill by cutting from tip to base of the feather). This will sometimes necessitate cutting toward the head, sometimes toward the sacrum, according to the direction of the muscular or aponeurotic tissues at the site of operation. Having thus made a straight incision on each side of the spinous processes, hugging the lateral aspects of the spines from tip to base, the laminæ, and as much of the transverse processes as are indicated, can be readily cleared by levering away their soft coverings by means of an ordinary chisel held against the sides and tips of the spines as a fulcrum, and with its beveled edge away from the soft parts to be levered from the vertebral groove. A periosteal elevator or a raspatory may be less satisfactorily used for the same purpose.

Manner of Dividing the Laminæ.—Many methods have been used for making the section through the laminæ;—the spinous processes having been cut off with bone-pliers, Gigli or chain saw, and the laminæ then divided on each side by thrusting one blade of special curved pliers into the spinal canal and cutting from within outward;—the laminæ have been chiseled out by parallel sections on each side of the spines (at the cost of much jarring and irregular division);—the laminæ have been first trephined and the trephine-openings connected by chiseling or pliers;—the necessary bone has been bitten away by rongeur forceps;—Hey's saw has been used for making the sections. All of these methods are distinctly inferior to the use of Doyen's saw, which probably makes the speediest, easiest, and most accurate division of any instrument now in use.

Manner of Dealing with the Membranes.—If the condition be plainly extra-dural, the membranes should not be opened. If there be the slightest indication to do so, or if there be any question of doubt, the membranes should be opened, and by a posterior median incision. It is unquestionably better to open the membranes in the majority of cases. Having opened the membranes, if there be no contraindication they should be closed at the end of the operation by means of catgut suture. If intra-membranous drainage be indicated, the membranes are sutured in part and strands of gut, silk, or silkworm-gut are introduced within the membranes through the opening in the theca left patulous, and thence out of the spinal wound. If the membranes are sutured, temporary drainage down to the membranes, with rubber tubing or gauze, is nevertheless generally indicated.

Much information is furnished by an examination of the unopened membranes;—a bluish hue indicates hemorrhage,—yellowish, pus,—increased tension, tumor, or increased quantity of cerebrospinal fluid,—absence of pulsation, some blocking of subdural space by pressure, adhesions, etc. Pressure may be found to be extra-dural, not necessitating the opening of the dura. Fracture or hemorrhage or an excrescence of bone may be detected. The cord may be temporarily lifted out of its bed or drawn to one side in order to examine the entire canal—for this purpose the nerves may be considerably stretched, or divided and subsequently sutured with fine catgut.

Comparison of Methods of Exposing the Spinal Cord.—In Laminectomy one or more pairs of laminæ are permanently removed. While a considerable number of laminæ may be thus removed without materially

weakening the spine, it is natural to suppose that the individual would be better off if these laminæ were preserved. In an Osteoplastic Resection of the Spine the laminæ are temporarily turned back and subsequently replaced at the end of the operation, thus leaving the spine practically intact. Where practicable, therefore, an osteoplastic resection of the spine is preferable, to a laminectomy—and by means of Doyen's saw, and with the valuable aid to its accomplishment suggested by Hartley, the mechanical difficulties of the operation are now largely removed.

INSTRUMENTS USED IN OPERATING UPON THE SPINE AND SPINAL CORD.

Stout scalpels and bluntly-rounded knives; large, strong retractors of various shapes and depths of reach; hemostatic forceps; scissors, curved and straight, blunt and sharp; chisel or osteotome (for levering soft parts from vertebral grooves); chisels, different sizes (where necessary to complete a section begun with a saw, by a stroke or two); periosteal elevators; raspatory; Doyen's saw (the instrument of choice for making the section of bone); Gigli, chain and Hey's saws; bone-cutting pliers; rongeur forceps; special bone-cutting forceps (such as Hoffman's, Horsley's, or Keen's); lion-jaw bone-holding forceps; curved sequestrum forceps; mallet; trephine; probe; dural separator; grooved director; dissecting forceps; toothed forceps; needle-holders, large and small; needles, small and fully curved for membranes, and large, straight, and curved, for the main wound, gut and silk sutures and ligatures; drains.

LAMINECTOMY.

Description.—Laminectomy, or Lamnectomy, signifies a complete permanent removal of the laminæ and spinous process of one or more vertebræ —for the purpose of exposing the spinal canal and cord.

Preparation and Position.—See General Surgical Considerations.

Landmarks.—The spinous processes corresponding with the laminæ to be removed—remembering that in the greater extent of the spine the spinous processes extend considerably below the corresponding laminæ.

Incision.—A median vertical incision is made directly over the tips of the spinous processes—the center of the incision being over the center of the area from which the posterior wall of the spinal canal is to be removed, and extending as far above and below the special laminæ to be excised as may be necessary to expose thoroughly the site of bone section (which will necessitate its reaching one or two spines above and the same number below those to be removed, dependent upon the region of the spine). (See Fig. 332, A.)

Operation.—(1) The incision is carried directly over the apices of the spinous processes, through skin and fascia—and then passes boldly down along one side of the spinous processes for the entire length of the wound, hugging the lateral aspect of the spines as closely as possible. This incision is preferably made with a fairly large, stout knife having a somewhat rounded point—the cut being made toward the apex of the acute angle formed by the muscles and aponeuroses attached to the spinous processes. (See General Surgical Considerations.) (2) Considerable bleeding will occur in this long and deep wound—and is to be dealt with as described under General Surgical

Considerations—as is also the hemorrhage which occurs while exposing the laminæ. (3) The entire spinal furrow on each side of the spines is to be now cleared. These furrows are bounded by the spinous processes, laminæ,

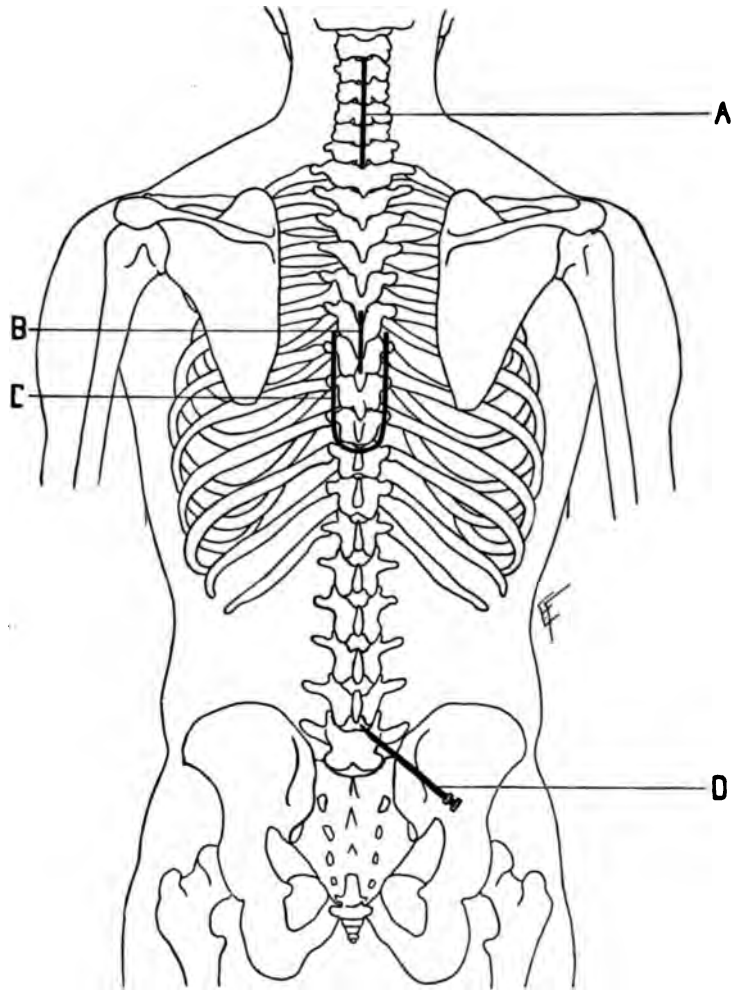

Fig. 332.—Region of the Spinal Column and Cord:—A, Position for incision in laminectomy of fourth, fifth, and sixth cervical vertebræ; B, Position for incision in Hartley's preliminary excision of a spinous process (of sixth dorsal vertebra) preceding osteoplastic resection; C, Position of incision in an osteoplastic resection of seventh, eighth, and ninth dorsal vertebræ; D, Lumbar puncture between the fourth and fifth lumbar laminæ, for spinal anesthesia.

and bases of the transverse processes. They should be thoroughly cleared of muscular and aponeurotic attachments and all hemorrhage controlled before the section of bone is attempted. They are most readily cleared by using a chisel, or osteotome, against the spinous processes as a fulcrum, and levering off all soft attachments from the base of the spinous processes and

laminæ toward the transverse and articular processes. Fibers which have escaped removal with chisel or osteotome thus used, may be removed with the raspatory. When one side has been entirely prepared, it should be firmly packed with gauze, while the opposite side is similarly prepared. The side last prepared is then packed—and the first side is now ready for the division of bone. (See Fig. 333.) (4) Remove the packing and firmly retract the soft parts away from the spines, thus freely exposing the spinal furrow of that

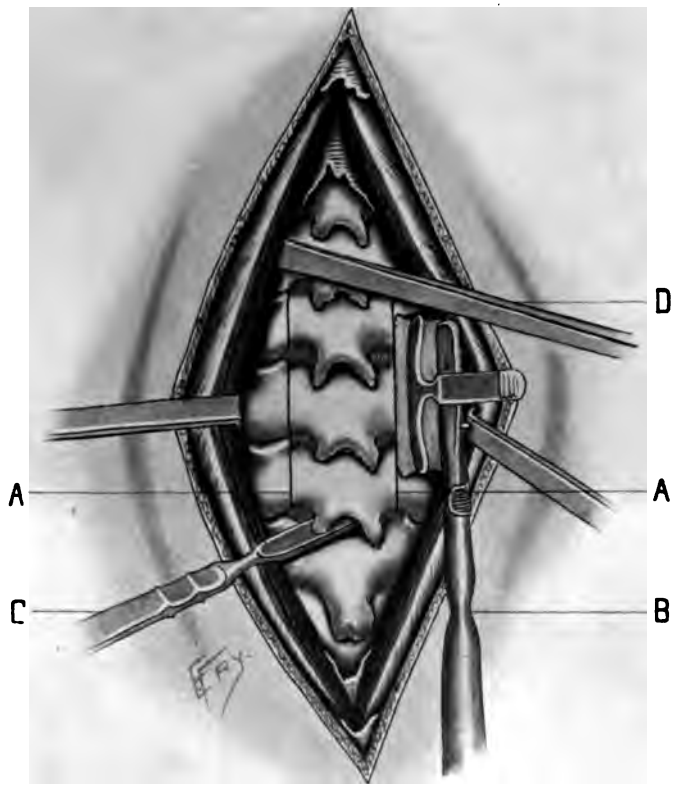

Fig. 333.—LAMINECTOMY: A, A, Saw-cuts through the laminæ, just within their junction with the articular processes; B, Doyen saw in act of dividing the laminæ, its guard (determining the depth of section) being entirely raised at the beginning of the division; C, Knife dividing the ligamenta subflava; D, Osteotome levering away the muscles of the vertebral grooves, using the spinous processes as fulcra.

side, with the bared laminæ lying at its bottom—no opening into the spinal canal itself being as yet made. Doyen's saw is now applied to those laminæ which it is intended to remove. The blade of the saw should be directed at a right angle to the surface of the laminæ which are to be cut—which means that the saw will be directed slightly toward the median line and will pass through the laminæ by the shortest route. If it be directed parallel with the spinous processes, it will pass with slight obliquity through the laminæ

and will, in addition, be apt to run into the articular processes, or into the bases of the transverse processes, and thus cause much difficulty. The saw should travel, at each stroke, the full length of the laminæ to be excised—and should cut to an equal depth throughout. The guard of the Doyen saw will prevent its cutting too deeply into the spinal canal. Even without the guard the progress of the section can be determined by the flat end of a probe. Having completed the section upon one side, the opposite side should be divided in the same manner. The saw-cuts will end above at the upper border of the highest pair of laminæ to be removed, and will end below at the lower border of the lowest pair. When the sections have been carried entirely through the laminæ throughout, it will be found, by grasping the spinous processes, that the excised section can be moved from side to side, showing that the bone has been everywhere divided and that the laminæ are still held in place by the ligamenta subflava, supraspinous and interspinous ligaments. (5) Grasping the spinous process just above the upper one to be removed, with lion-jaw forceps, draw it slightly backward and divide, in order, the supraspinous and interspinous ligaments and the ligamenta subflava, connecting the spinous processes and the laminæ. Similarly grasp the lowest of the spines to be removed and draw it backward from the spine next below and divide the corresponding ligaments—by carrying a knife obliquely between the spines down to and through the ligamenta subflava—being careful not to penetrate far enough into the spinal canal to do damage. (6) Nothing now should hold the excised area—which is grasped by stout bone-holding forceps and lifted out of its position. If it still be held in places by slight bonds, use an osteotome, or periosteal elevator inserted into the grooves made by the saw and lever it out—beginning the process of loosening from below. (Where the Doyen saw is not available, the section is probably best made with bone-cutting pliers in the following manner. Simultaneously retract the soft parts well on both sides, after having cleared both spinal furrows in the above fashion. Divide with a knife, or curved scissors, the supraspinous and interspinous ligaments extending between the apices and between the contiguous upper and lower borders of the spinous processes. Remove the designated spinous processes as near to their bases as possible, by means of angular bone-cutting pliers, or by biting them off with rongeur forceps, or by the Gigli saw—in order to gain access to the spinal canal. Carefully divide the ligamenta subflava [interlaminous ligaments] between the laminæ to be excised. This will open up the connective tissue between the periosteum of the spinal canal and the outer surface of the dura. Cautiously pass an angular or curved bone-cutting forceps between the laminæ where the ligamenta subflava have been severed, and cut the indicated lamina vertically upward as near the base of the transverse process as possible—so as to remove a wide window of bone. Repeat this upon the opposite side, and remove the pair of laminæ wth the remnant of attached spinous process. Repeat this step with as many pairs of laminæ as must be removed—the subsequent laminæ being much more readily removed, and with less danger to the membranes and cord, than the first.) (7) Control, with gentle pressure and hot irrigation, the hemorrhage which is likely to occur from the posterior longitudinal spinal veins and their transverse branches. (8) The spinal cord is now exposed to view, suspended within the spinal canal—often fat and veins intervening between the periosteum and cord. Its preservation from injury during the steps of the operation (for it is but very exceptionally injured) being largely due to its distance from the periosteum of the spinal canal, to its suspended position, and to the toughness of its membranes.

For indications for opening the spinal membranes, see General Surgical Considerations. If it be decided to open the membranes, seize the dura by means of two pairs of toothed forceps, one held by the assistant and the other by the surgeon. While the membranes are thus steadied and drawn away from the cord, a median vertical incision is made in the posterior aspect, for as long a distance as considered necessary, passing between the grips of the two forceps. Having opened the subdural space, and then the subarachnoidean space (from which the cerebrospinal fluid will escape), these areas are carefully examined by means of a bent probe—for tumors, hemorrhage, adhesions, spiculæ of bone, foreign bodies, bony irregularities, diseased products, etc. If the spinal nerve-roots have been severed, they are sutured prior to opening the membranes. (**9**) Having finally thoroughly examined the surface of the cord, the incised membranes are treated as indicated by the particular case. If infection be not anticipated, and where possible to do so (where that membrane has not been destroyed), the incised dura should be sutured with fine catgut, carried upon a fine, fully-curved needle. In other cases the dura should be allowed to fall into place as completely as possible, or may be sutured in part, and temporary drainage of the intramembranous region be instituted by means of strands of silk, fine gut, or silkworm-gut introduced within the theca, and thence out of the general wound. (**10**) In any event, drainage down to the theca, through the depth of the wound, is instituted for a few days, that a free escape may be provided and pressure upon the cord structures be avoided—by means of rubber tubing or gauze. (**11**) The spinal muscles and aponeuroses are quilted together with chromic gut, in one or two tiers. (**12**) The skin is sutured with silkworm-gut or silk, except where drainage comes through. An abundant aseptic dressing covers the site.

Comment.—It is well to excise the spinous process of the vertebra above the highest one the laminæ of which are to be removed, in order to furnish freer access.

For the purpose of removing the scar of the skin wound from the lines of the spines and the deeper wound, some surgeons use a curved incision, its upper and lower ends crossing the median line and its vertical portion lying parallel with and considerably to the outer side of the median line—thus raising a curved lateral flap of skin and connective tissue—which is retracted to the opposite side—and then the muscles are incised and the operation completed as above. If, however, it be found necessary to expose additional spines, the incision becomes complicated. Also for the same reason, some surgeons turn upward or downward a skin and connective-tissue flap, before proceeding to bare the spines.

Sometimes after exposing the part as for ordinary Laminectomy, the laminæ are removed by an osteoplastic operation.

Keep the patient's head dependent while opening the membranes, to allow the cerebrospinal fluid to collect in the skull.

OSTEOPLASTIC RESECTION OF THE SPINE.

Description.—A flap composed of skin, fascia, muscles, together with spinous processes and laminæ (all parts composing the flap remaining adherent to each other and in their relative positions), is partially removed *en masse* and temporarily turned upward and backward, to expose the portion of the cord or spine involved—and then dropped back into place at the end of the

operation. Thus no part of the spine is permanently sacrificed, nor its strength impaired.

In those regions of the spine where the spinous processes overlap it is impossible satisfactorily to turn this osteoplastic flap upward, in the ordinary method of doing the operation, owing to the interlocking of the two adjacent spines—and it is not easy to do so even where the spines do not actually overlap. To avoid this difficulty, Hartley begins the operation by excising, by a separate incision, the spinous process just above the highest one which is to form part of the osteoplastic flap.

For comparison between Laminectomy and Osteoplastic Resection of the Spine, see General Surgical Considerations. A special indication for thus

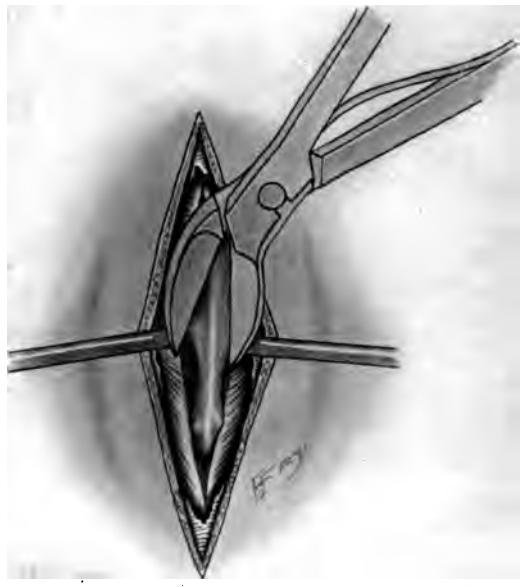

Fig. 334.—Hartley's Method of Preliminarily Excising the Spinous Process Immediately above the Laminæ to be Temporarily Turned Back in Osteoplastic Resection of the Spinal Column.

preserving the spines and laminæ is in Pott's disease, where the bodies of the diseased vertebræ might be too weak if many laminæ and spines were removed.

Preparation—Position—Landmarks.—As in Laminectomy.

Incision.—(**a**) For the preliminary excision of the adjacent spinous process—a median vertical incision of 2.5 to 4 cm. (1 to 1½ inches) is made directly over the spinous process immediately above the highest one entering into the osteoplastic flap. (See Fig. 332, B.) (**b**) For the raising of the osteoplastic flap—a U-shaped incision is outlined; its length determined by the number of laminæ to be removed; its convexity downward, crossing just below the last spine in the flap; its limbs parallel with the spinous processes and placed over the bases of the transverse processes (over the articular processes in the cervical region). (See Fig. 332, C.)

Operation.—(1) In doing Hartley's modification of the operation (which

has for its object the removal of the spine of the adjacent vertebra above, thereby making the turning back of the osteoplastic flap in all regions of the column an easier undertaking), the median vertical incision over this spine

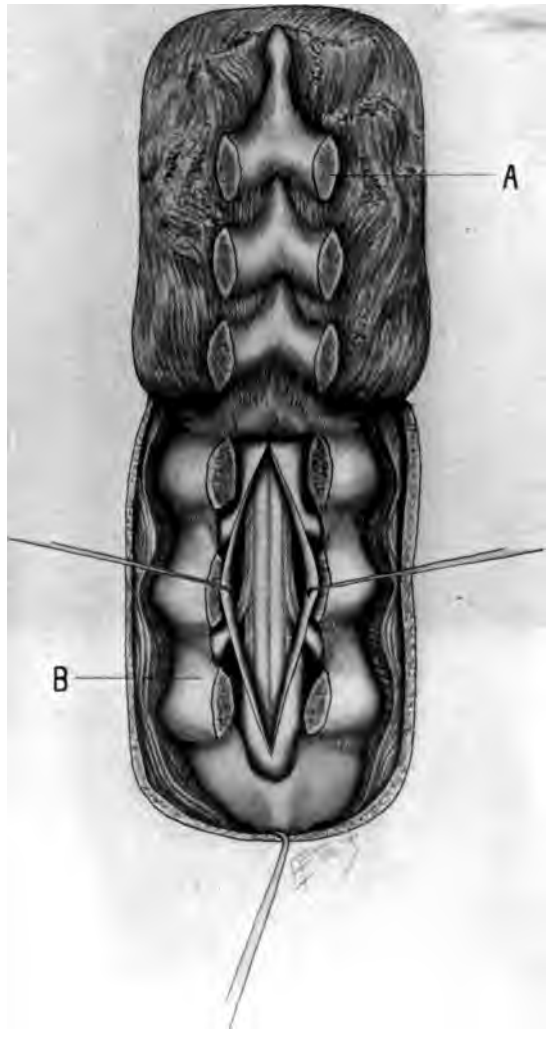

Fig. 335.—Osteoplastic Resection of the Spinal Column:—A, Flap of muscles, laminæ spinous processes, and ligamenta subflava turned back; B, Spinal canal exposed, showing the membranes incised and retracted, together with the nerves and their course to the spinal foramina.

is deepened until its apex is reached, and is then carried along each side of the spine to its base. (**2**) The detached soft parts are retracted laterally and the spinous process bitten off close to its base with bone-cutting pliers, or, better, with Gigli saw. (See Fig. 334.) (**3**) If this wound be at once closed (which is generally best), the muscles are approximated

by two or three buried chromic gut sutures, and the superficial wound sutured. (If difficulty occurs in turning back the flap, or in replacing it at the end of the operation, this wound may be reopened, if it have been closed, and the manipulation aided by a finger introduced through it down to the bony structures.) All is now ready for the operation proper. (4) The incision for the U-shaped flap passes directly to the bone, the knife being directed obliquely so as to pass down along the median surface of the posterior aspect of the transverse processes and come upon the laminæ at the inner margin of the articular processes (directly down to the junction of the laminæ and articular processes in the cervical region). This cut passes boldly to the bottom of the spinal furrows along its vertical limbs, but the lower curved portion is made with special care where it passes between two contiguous spinous processes, cutting the supraspinous and interspinous ligaments and guarding against entering, at this stage, the spinal canal. (See Fig. 335.) (5) Hemorrhage is now controlled as in Laminectomy. (See General Surgical Considerations.) (6) The soft parts are well retracted (both toward the apices of the transverse processes and toward the spines) without detaching soft parts from bones, thus exposing a deep furrow upon one side of the spine, the bottom of which is formed by the laminæ. (7) Having again stopped all bleeding and thoroughly exposed the laminæ, the periosteum of the laminæ is cut through in a vertical line down their center by means of a stout knife, and the periosteum turned away with a periosteal elevator upon each side of this incision just sufficiently to form a bared path for the saw. (While this baring of the laminæ by turning back the periosteum from the saw-groove is not always done, it is better to do so.) (8) This side is now firmly packed with gauze and the opposite spinal groove similarly prepared, before either is sawed. (9) The laminæ are now divided in a vertical line just within the articular processes, by means of Doyen's saw, in exactly the same manner as in Laminectomy (see 4, under Operation, page 532). (10) The ligamenta subflava connecting the lower border of the lowest pair of laminæ to be removed with the upper border of the pair just below, is now carefully divided with knife or curved scissors. (11) By means of an osteotome used as an elevator the entire osteoplastic flap is now carefully elevated and turned upward upon the ligamenta subflava at the upper limit of the section, as a hinge. (12) The cord is thus amply exposed —and the steps of the operation which concern the cord and its membranes are identical with those in Laminectomy. (13) At the end of the operation all bony projections, both upon the spinal column and upon the laminæ in the flap, which are apt to interfere with exact apposition, are removed with the saw while grasped with bone-forceps, or by rongeur forceps. (14) The dura having been sutured (if opened and its closure not contraindicated) and all hemorrhage controlled, the large osteoplastic flap is allowed to fall back into place and is adjusted so as to accurately fit. (15) If necessary to temporarily drain the spinal canal, this should be done by a few strands of silk, catgut, or silkworm-gut conducted into the wound, a small portion of the lower laminæ being bitten away. To provide for drainage of the wound of the soft parts, drainage tubing or gauze may be placed down to its bottom and come out between sutures which have been placed but not tied. (16) The muscles should be quilted in one or two tiers with chromic gut. The skin wound is closed, except where the drainage comes through. A voluminous aseptic dressing is applied.

has for its object the removal of the spine of the adjacent vertebra above, thereby making the turning back of the osteoplastic flap in all regions of the column an easier undertaking), the median vertical incision over this spine

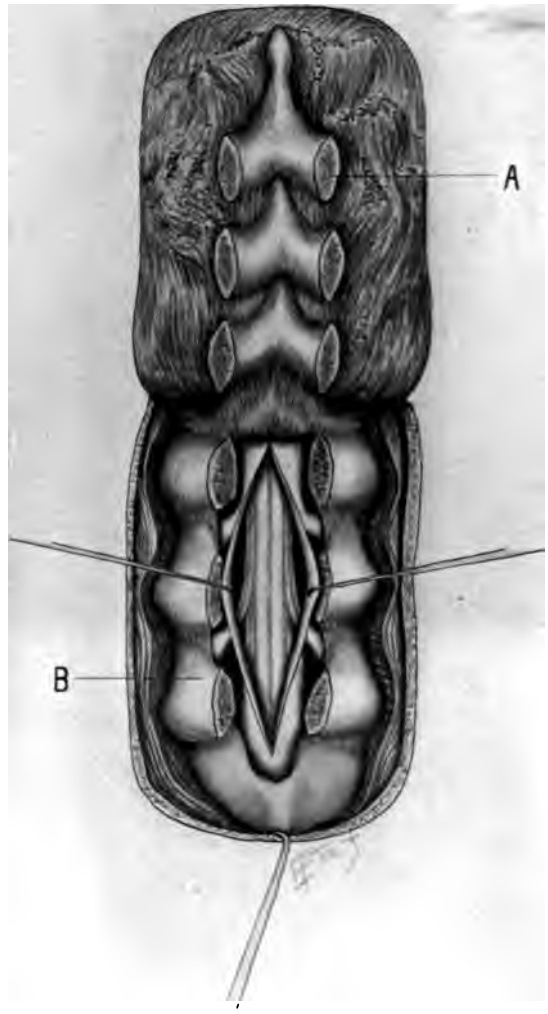

Fig. 335.—Osteoplastic Resection of the Spinal Column:—A, Flap of muscles, laminæ spinous processes, and ligamenta subflava turned back; B, Spinal canal exposed, showing the membranes incised and retracted, together with the nerves and their course to the spinal foramina.

is deepened until its apex is reached, and is then carried along each side of the spine to its base. (2) The detached soft parts are retracted laterally and the spinous process bitten off close to its base with bone-cutting pliers, or, better, with Gigli saw. (See Fig. 334.) (3) If this wound be at once closed (which is generally best), the muscles are approximated

by two or three buried chromic gut sutures, and the superficial wound sutured. (If difficulty occurs in turning back the flap, or in replacing it at the end of the operation, this wound may be reopened, if it have been closed, and the manipulation aided by a finger introduced through it down to the bony structures.) All is now ready for the operation proper. (4) The incision for the U-shaped flap passes directly to the bone, the knife being directed obliquely so as to pass down along the median surface of the posterior aspect of the transverse processes and come upon the laminæ at the inner margin of the articular processes (directly down to the junction of the laminæ and articular processes in the cervical region). This cut passes boldly to the bottom of the spinal furrows along its vertical limbs, but the lower curved portion is made with special care where it passes between two contiguous spinous processes, cutting the supraspinous and interspinous ligaments and guarding against entering, at this stage, the spinal canal. (See Fig. 335.) (5) Hemorrhage is now controlled as in Laminectomy. (See General Surgical Considerations.) (6) The soft parts are well retracted (both toward the apices of the transverse processes and toward the spines) without detaching soft parts from bones, thus exposing a deep furrow upon one side of the spine, the bottom of which is formed by the laminæ. (7) Having again stopped all bleeding and thoroughly exposed the laminæ, the periosteum of the laminæ is cut through in a vertical line down their center by means of a stout knife and the periosteum turned away with a periosteal elevator upon each side of this incision just sufficiently to form a bared path for the saw. (While this baring of the laminæ by turning back the periosteum from the saw-groove is not always done, it is better to do so.) (8) This side is now firmly packed with gauze and the opposite spinal groove similarly prepared, before either is sawed. (9) The laminæ are now divided in a vertical line just within the articular processes, by means of Doyen's saw, in exactly the same manner as in Laminectomy (see 4, under Operation, page 532). (10) The ligamenta subflava connecting the lower border of the lowest pair of laminæ to be removed with the upper border of the pair just below, is now carefully divided with knife or curved scissors. (11) By means of an osteotome used as an elevator the entire osteoplastic flap is now carefully elevated and turned upward upon the ligamenta subflava at the upper limit of the section, as a hinge. (12) The cord is thus amply exposed —and the steps of the operation which concern the cord and its membranes are identical with those in Laminectomy. (13) At the end of the operation all bony projections, both upon the spinal column and upon the laminæ in the flap, which are apt to interfere with exact apposition, are removed with the saw while grasped with bone-forceps, or by rongeur forceps. (14) The dura having been sutured (if opened and its closure not contraindicated) and all hemorrhage controlled, the large osteoplastic flap is allowed to fall back into place and is adjusted so as to accurately fit. (15) If necessary to temporarily drain the spinal canal, this should be done by a few strands of silk, catgut, or silkworm-gut conducted into the wound, a small portion of the lower laminæ being bitten away. To provide for drainage of the wound of the soft parts, drainage tubing or gauze may be placed down to its bottom and come out between sutures which have been placed but not tied. (16) The muscles should be quilted in one or two tiers with chromic gut. The skin wound is closed, except where the drainage comes through. A voluminous aseptic dressing is applied.

opening the spinal membranes. In the cases operated upon the results have not been altogether satisfactory. If, as in one of Abbe's cases, the limb has been amputated and spasms still continue in the stump, as well as the manifestation of pain, the motor roots may also be cut (neurotomy), besides the partial excision (neurectomy) of the posterior roots. In addition to the excision, Keen has suggested the breaking up of the ganglia upon the posterior nerve-roots, for fear of reestablishment of connection. The technique of the operation is simply that of a Laminectomy or, preferably, an Osteoplastic Spinal Resection, as far as the exposure of the membranes and cord are concerned. Care is exercised in choosing the site of the exposure, that the roots of the nerves involved may be accurately located. After the canal is exposed the membranes are opened as described under Laminectomy—the particular nerves are recognized—and as much of the posterior roots as can be resected within the dura is excised—and the membranes and the wound dealt with as in Laminectomy or Osteoplastic Spinal Resection.

NOTE.

For operations upon Bones, Muscles, Joints, Ligaments, Arteries, Veins, and Nerves of the Spinal Region, see General Surgery.

THE NEW YORK LIBRARY. ACADEMY OF MEDICINE.

CHAPTER III.

OPERATIONS UPON THE NECK.

I. THE LARYNX.

SURGICAL ANATOMY OF THE NECK.

For Surgical Anatomy of the antero-lateral region of the Neck, see under "Lymphatic Glands and Vessels," page 133. For Surgical Anatomy of the posterior region of the Neck, see under "Spine and Spinal Cord," page 526.

SURGICAL ANATOMY OF THE LARYNX.

Situation.—Lies in upper forepart of median aspect of neck—below tongue and hyoid bone—in front of pharynx—and between large vessels of neck.

Relations.—**Anteriorly,** skin and cervical fascia;—**Posteriorly,** separated from fourth, fifth, and sixth cervical vertebræ and prevertebral muscles by laryngeal portion of pharynx;—**Laterally,** sternohycid; sternothyroid; thyrohyoid; superior end of lateral lobe of thyroid; portion of inferior constrictor;—**Superiorly,** opens into pharynx;—**Inferiorly,** opens into trachea.

Arteries.—Superior laryngeal branch of superior thyroid; inferior laryngeal branch of inferior thyroid; dorsalis linguæ of lingual.

Veins.—Empty into superior, middle, and inferior thyroid veins.

Lymphatics.—Drain into carotid glands and into glands in front of cricothyroid membrane, or into inferior laryngeal glands.

Nerves.—From superior laryngeal and recurrent laryngeal branches of the pneumogastric, and from the sympathetic.

SURFACE LANDMARKS AND GENERAL SURGICAL CONSIDERATIONS.

The contour of the thyroid and cricoid cartilages, with the intervening cricothyroid membrane, can generally be outlined in the average neck—with the thyrohyoid membrane extending upward from the upper border of the thyroid cartilages, and the rings of the trachea extending downward from the cricoid cartilage. The height of the cricothyroid space is about 1 cm. (nearly ½ inch) in the average adult.

The internal (sensory) branch of the superior laryngeal nerve pierces the thyrohyoid membrane above the superior laryngeal artery. The external branch (principally motor) of the superior laryngeal is distributed to the cricothyroid muscle and to the mucous membrane. The inferior or recurrent laryngeal (motor) runs up in the groove between the trachea and esophagus, and reaches the larynx below the inferior constrictor and just behind the cricothyroid articulation, where it divides into anterior and posterior branches.

The cricothyroid artery (branch of superior thyroid) crosses transversely

over the upper part of the cricothyroid membrane, and is the chief artery complicating laryngotomy.

Small venous trunks cross the laryngeal region irregularly, chiefly emptying into the superior thyroid vein.

INSTRUMENTS.

Scalpels; scissors, sharp and blunt, curved and straight; forceps; dissecting, toothed, and artery-clamp; tenacula; wound hooks; laryngotomy

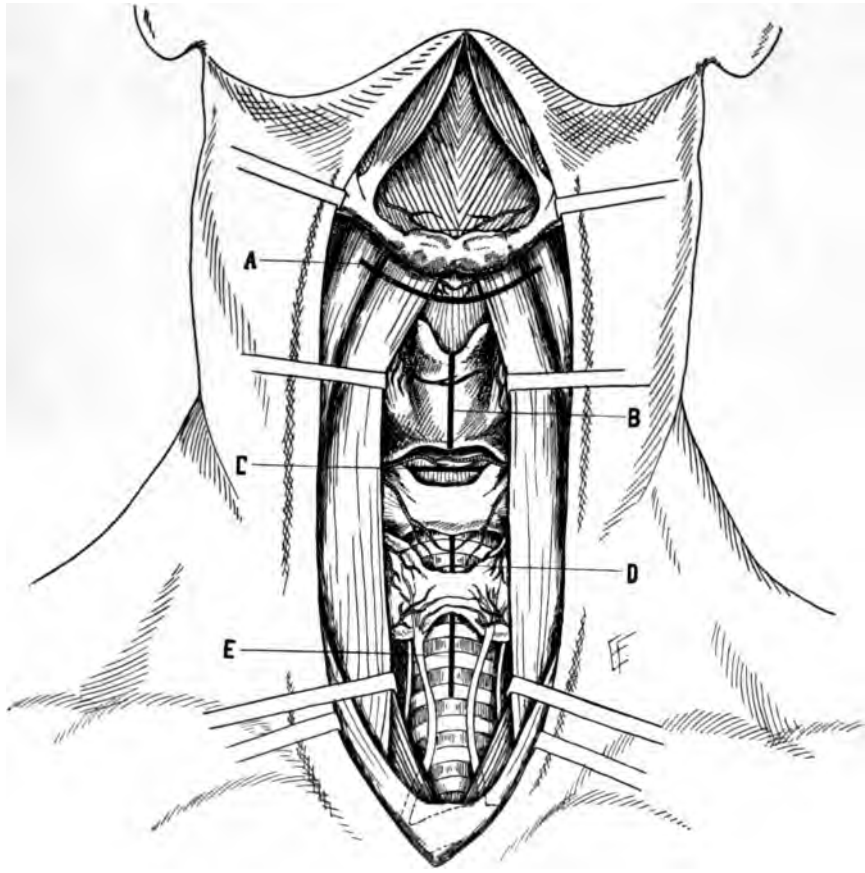

Fig. 336.—Position of Incisions for Opening the Laryngo-tracheal Tract:—A, Suprathyroid laryngotomy (subhyoid pharyngotomy); B, Thyrotomy; C, Laryngotomy; D, High tracheotomy; E, Low tracheotomy. The corresponding skin incisions are longer than the incisions into the laryngo-tracheal tract.

tubes; tampon cannulæ; artificial larynx; laryngeal forceps; artificial feather for cleansing tube; grooved director; mouth-gag; tongue forceps; tongue depressor; wound retractors; dilator for laryngeal wound; laryngeal aspirator; spatulæ; needles, curved and straight; needle-holder; sutures and ligatures,

silk and gut; traction-ligatures; O'Dwyer's intubation set; shield for mouth and eyes of operator; tracheotomy tubes.

LARYNGOTOMY.

Description.—Laryngotomy, or Infrathyroid Laryngotomy, consists in the opening of the larynx through the cricothyroid membrane. The superficial incision is made in the median line of the neck, and the opening into the larynx is made transversely through the cricothyroid membrane, followed by the introduction of a special laryngotomy tube flattened from above downward so as to present an oval opening.

Preparation.—The neck is shaved, if covered by hair.

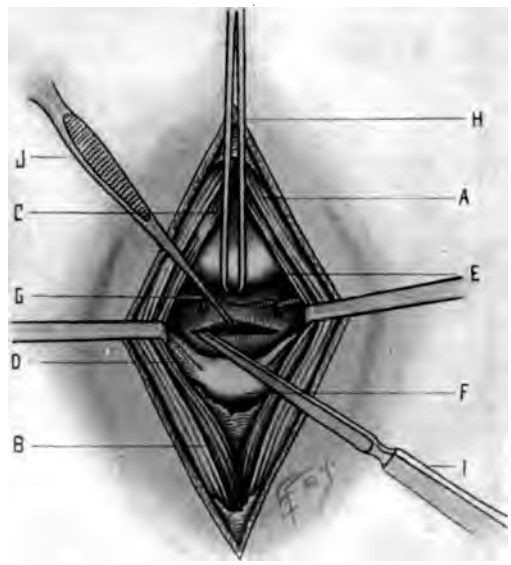

Fig. 337.—LARYNGOTOMY:—A, Sternohyoid muscle; B, Sternothyroid muscle; C, Thyrohyoid muscle; D, Cricothyroid muscle; E, Thyroid cartilage; F, Cricoid cartilage; G, Cricothyroid artery; H, Double tenaculum steadying thyroid cartilage; I, Sharp-pointed knife completing incision of cricothyroid membrane; J, Toothed forceps everting lip of laryngeal incision.

Position.—Patient supine, shoulders supported and head thrown back, so as to round out and tense the laryngeal region.

Landmarks.—Thyroid and cricoid cartilages and cricothyroid space.

Incision.—A vertical incision is made exactly in the median line, from 3 to 4 cm. (about 1¼ to 1½ inches) long—beginning over the lower part of the thyroid cartilage, passing over the cricothyroid membrane, and ending at the lower border or just below the cricoid cartilage—while the larynx is steadied in the middle line between the left thumb and forefinger. (See Fig. 336, C.)

Operation.—(1) Incise the skin, superficial fascia, platysma, and cervical fascia—dividing between ligatures any veins encountered. (2) Recognize the interval between the sternothyroid and cricothyroid muscles and open up this interval by blunt dissection, thus exposing the cricothyroid membrane (see Fig. 337). Retract the tissues laterally. Divide the cricothyroid artery

between two ligatures. (3) Steady the larynx by means of left thumb and forefinger and incise the cricothyroid membrane laterally, carefully stabbing, with a narrow, sharp knife, into the lumen at one side and incising transversely just above the cricoid cartilage in the act of withdrawing the knife. (4) Seize and evert one lip of the laryngeal wound with toothed forceps, and, parting the lips of the wound by a special laryngeal dilator, insert the oval laryngeal tube into the larynx, so that its greatest width corresponds with the length of the wound. Attach tube to the neck by means of a band. (5) If the superficial wound be long, its ends may be sutured, leaving less of an area for granulation. (6) A dressing should be applied between the flange of the tube and the neck.

Comment.—Stab well into the lumen of the larynx (while guarding against stabbing too far), so as to avoid pushing the mucous lining of the larynx ahead of the knife and really not entering the lumen at all. Cut very near the cricoid cartilage, especially if compelled to operate hastily—as the cricothyroid artery runs nearer the lower border of the thyroid cartilage.

Sometimes the cricothyroid membrane is incised vertically, just as the superficial wound—additional room being gotten by dividing the cricoid cartilage in the same line. The above is, however, preferable.

Laryngotomy and Tracheotomy compared;—Laryngotomy is rapidly and easily performed—it is the operation where great haste is necessary and few instruments and limited assistance are at hand. It is inapplicable under thirteen years (the space being too narrow). It is more difficult to insert a proper laryngotomy tube than a tracheotomy tube. The vocal cords are nearer and are more apt to be injured by wearing a laryngotomy tube. Laryngotomy is not applicable where a tube must be worn for some time. In Laryngotomy the cricothyroid artery must be avoided or tied.

THYROTOMY.

Description.—Division of the thyroid cartilage, partially or completely, in the median line, in order to expose the cavity of the larynx. Resorted to for the removal of foreign bodies and growths. Vocalization is apt to be permanently involved. The operation is very similar to Laryngotomy.

Preparation.—As in Laryngotomy. In addition, a preliminary Tracheotomy is done (preferably several days in advance). (A preliminary laryngotomy may be done, but is less satisfactory.) The trachea should be plugged, or a tampon cannula used after the tracheotomy.

Position.—As in Laryngotomy.

Landmarks.—Hyoid bone, thyrohyoid membrane, thyroid cartilage, cricothyroid membrane and cricoid cartilage.

Incision.—A vertical incision is made exactly in the median line, beginning at the lower border of the hyoid bone and ending over the cricoid cartilage—steadying the larynx between the left thumb and forefinger (see Fig. 336, B).

Operation.—(1) Incise skin, superficial fascia, platysma, and cervical fascia—encountering the terminal branches of the superficial cervical and inframaxillary nerves, the communicating branches between the anterior jugular veins, and some small superficial arterial and venous branches. (2) Open up the connective-tissue interval between the sternothyroid and cricothyroid muscles by blunt dissection, exposing the thyroid cartilage and thyrohyoid and cricothyroid membranes. (3) Divide the thyroid cartilage carefully and exactly in the median line, by cutting from above downward and from without inward, with a sharp, fairly heavy, rounded knife. If the upper

margin of the thyroid cartilage can be left uncut, better subsequent adjustment is obtained—but if necessary, not only the entire thyroid may be divided but as much of the thyrohyoid and cricothyroid membranes as indicated. This manner of division is safer than inserting the point of a knife below the thyroid and cutting upward from within. In calcified cartilages a small saw may be necessary. (4) The two alæ of the thyroid cartilage are now drawn aside with small, blunt hooks, exposing the interior of the larynx and enabling the special object of the operation to be carried out. If the alæ cannot be separated sufficiently for the object sought, divide the thyrohyoid or cricothyroid membranes, or both, transversely near their cartilages. (5) Having accomplished the object of the operation, the severed borders of the thyroid are united by chromic catgut—(and the margins of membranes if cut). The external wound is left open in the center, having been closed at the ends. Temporary drainage is used. The tracheotomy tube is retained for several days.

COMPLETE LARYNGECTOMY.

Description.—Excision of the entire larynx. Its removal may or may not be followed by the substitution of an artificial larynx. Generally resorted to for malignant disease.

Preparation.—As for Laryngotomy. In addition, a preliminary tracheotomy should be done ten days or one week in advance. Some form of tampon cannula should be inserted into the tracheotomy wound just before the major operation.

Position.—Patient supine, shoulders elevated, head thrown back, neck prominent over a cushion or sand-bag. Surgeon to patient's right. Assistant opposite surgeon.

Landmarks.—Hyoid bone, thyrohyoid space, larynx, cricoid cartilage and upper tracheal rings, sternomastoid muscles.

Incision.—(1) Vertical incision, exactly in the median line, extending from the center of the thyrohyoid membrane to the second or third tracheal rings;—(2) Transverse incision, carried across at upper limit of vertical incision, passing from one sternomastoid muscle to the opposite one. (See Fig. 343, B.)

Operation.—(1) Having carried the above incisions through skin, superficial fascia, platysma, and cervical fascia; ligated the superficial vessels; and encountered branches of the superficial cervical and inframaxillary nerves, the two rectangular flaps thus outlined are turned outward and downward, exposing the anterior margins of the sternomastoids, thyroid and cricoid cartilages, and trachea. (2) Divide, between double ligatures, the superior thyroid arteries, as they lie at the posterior border of the thyrohyoid muscles, near the superior margin of the thyroid cartilage. Similarly ligate and divide the inferior thyroid arteries at the posterior border of the sternothyroids, at the lower edge of the larynx. The thyroid veins encountered are similarly dealt with. (3) The cricothyroid, sternothyroid, and thyrohyoid of one side, together with the adjacent soft parts, are retracted outward, while the larynx is retracted to the opposite side. (4) The inferior constrictor muscle of that side is now severed from the thyroid cartilage by a curved blunt dissector and scissors—the larynx is drawn forward and the tissues between the cut inferior constrictor and the ends of the superior thyroid arteries are divided —the superior laryngeal nerve is cut—and the thyroid gland is retracted out of the way. (5) The larynx is now drawn to the opposite (freed) side and

the same process of separation is repeated upon the second side. (6) Sever the thyrohyoid membrane and the thyrohyoid ligaments—divide the extra-laryngeal attachments of the epiglottis while putting the parts on the stretch (thyro-epiglottic ligament, hyo-epiglottic ligament, glosso-epiglottic folds, and aryteno-epiglottic folds). (7) Draw the larynx forward and complete the division of the connections of the larynx to the pharynx and esophagus, from side to side and from above downward, guarding the esophagus from injury. (8) If the trachea be bound *in situ* by the preliminary tracheotomy, it will retain its position when cut—if not, it is to be steadied by two silk sutures—and then divided transversely between the cricoid cartilage and the first ring of the trachea, from behind forward. (9) Secure the upper end of the trachea to the surrounding integument by a few interrupted silk sutures. A deeper layer of silver wire or silk sutures may be put in to secure the deeper part of the trachea to the deeper surrounding parts—and another layer uniting the mucous membrane of the trachea to the skin. (10) Suture the transverse part of the wound, packing the rest. The tampon cannula is to be left *in situ* for one or two days, then replaced by the ordinary tracheotomy tube. The patient is fed through a stomach-tube at first. An artificial larynx is to be inserted in from four to six weeks, if one be used.

Comment.—(a) Some surgeons do the tracheotomy only at the time of the main operation. (b) All bleeding vessels are ligated or clamped as encountered. (c) It may be necessary to divide the isthmus of the thyroid gland between ligatures. (d) All enlarged glands encountered are to be removed. (e) Hug the cartilages throughout the entire operation. (f) The larynx may be detached from below upward, dividing transversely below the cricoid cartilage. (g) If in doubt as to the needs of removing the entire larynx, split the larynx and thoroughly examine. (h) The epiglottis is best removed—some leave it—it may interfere with the artificial larynx—or become the seat of returning disease. (i) The cricoid cartilage is best away. Some prefer to leave it as a support to an artificial larynx. Others think its retention interferes with swallowing.

PARTIAL LARYNGECTOMY.

Description.—Excision of one-half (in the middle line) of the larynx. Indicated in the partial involvement of the organ.

Preparation.—Same as for Complete Laryngectomy, including the preliminary tracheotomy.

Position—Landmarks.—Same as in the complete operation.

Incision.—Same as for total Laryngectomy, except that the transverse portion of the incision is made only upon one side. (See Fig. 343, B.)

Operation.—Same, practically, as for the total excision, except that the thyroid cartilage is divided down its center and the involved half removed after being separated from its soft parts by carefully hugging the cartilage during the freeing. The superior cornu of the thyroid cartilage is divided at its base by forceps. The epiglottis is left, the aryteno-epiglottic fold of the involved side being severed near Wrisberg's cartilage—though one-half of the epiglottis may be left and one-half removed. The cricoid cartilage may be left. The after-treatment is practically the same as for the total removal, except briefer.

INTUBATION OF THE LARYNX.

O'DWYER'S OPERATION.

Description.—The introduction, by a special instrument (introductor), into the larynx of a special metallic tube—which, upon the accomplishment of the object, after a shorter or longer time, is removed by another form of special instrument (extractor). Intubation is used in cases of impeded breathing arising in the larynx or upper trachea from causes other than foreign body.

Operation.—(1) Supposing the case to be a child—the nurse sits upright in a straight-back chair—the child, enveloped in a sheet or large bath-towel, thus pinioning its arms, is held upright in the nurse's right lap, her right arm passing forward around the child's shoulders and chest, her left forward around its hands and abdomen—its legs are placed between her knees—its head is thrown slightly backward over the nurse's right shoulder, and is steadied by an assistant standing behind the nurse—the child's mouth is gagged on the left side and the gag held by the assistant's left hand. (2) The surgeon, standing in front of the child (his mouth, eyes, and nose protected from the cough, etc., of the patient, in contagious cases)—inserts his left index into the throat until in contact with the epiglottis, which he elevates by hooking forward and presses against the root of the tongue with the tip of this finger, at the same time also drawing the base of the tongue slightly forward. The tube, with its contained obturator attached to the introductor, is passed into the mouth parallel with the left index as a guide (the handle of the instrument, at this stage, being about parallel with the chest-wall) and is directed in the necessary curve by elevating the handle of the introductor —and is guided through the rima glottidis by the tip of the finger which has drawn the epiglottis forward. As soon as the instrument is felt to be engaged within the larynx, the left index-finger is shifted to the shoulder of the tube and aids in gently pushing it down into place between the cords. The obturator is then detached from the tube by a special mechanical movement, controlled within the handle of the instrument, and is withdrawn together with the introductor. If the safety-thread (which has been previously introduced through the eye of the laryngeal tube) be removed, the left index remains in contact with the tube until the thread is withdrawn. The thread is often retained as a means of hasty and easy withdrawal in case of need, and is tied about a tooth or the ear. (3) To withdraw the tube, let the same position of patient, surgeon, assistant, and nurse be assumed as before—similarly draw the epiglottis forward with the left index—and, having similarly guided the beak of the extractor into the lumen of the laryngeal tube, expand the blades of the beak and withdraw the tube. If the thread have been left *in situ*, the tube may be withdrawn by it.

Comment.—Always be ready, in advance, to do an immediate tracheotomy—in the event that intubation cannot be performed, or that tube get into trachea, or that membrane be protruded ahead of the tube and impede trachea and tube.

To feed the child while the tube is in the larynx—place it upon its back in the nurse's lap—let its head bend over her knee, lower than its shoulders—feed it fluid food from a bottle on to the roof of its mouth (which is now lower than the floor)—the liquid will then flow over the soft palate on to the posterior pharyngeal wall, and thus nothing pass over the laryngeal tube. Some children, however, feed naturally without trouble.

The shoulders of the laryngeal tube are grasped by the superior or false vocal cords.

OTHER OPERATIONS UPON THE LARYNX.

Suprathyroid Laryngotomy.—

Same as Subhyoid Pharyngotomy (page 555). Sometimes employed to expose the upper part of the larynx and the region of the epiglottis.

Laryngo-tracheotomy.—

Larynx and trachea are both opened in one continuous median line—where more room is required than furnished by either laryngotomy or tracheotomy alone.

Tamponing of Larynx.—

The placing of gauze or sponge packing over the entrance of the larynx in order to prevent the entrance of fluids or blood into the air-passages during operations about the oral, pharyngeal, and nasal cavities—a preliminary tracheotomy having been done.

Introduction of Artificial Larynx.—

After the parts have healed, following a total laryngectomy, an artificial larynx is sometimes inserted through the wound in the neck—a mechanical contrivance having a longer tracheal tube which fits into the trachea, a shorter pharyngeal speaking-tube, with its vibrating apparatus, which passes up into the site occupied formerly by the larynx, and an external protected opening occupying the wound in the neck.

Operation for the Removal of Foreign Bodies.—

Foreign bodies are removed either by means of instruments introduced into the larynx through the rima glottidis by way of the mouth—or by opening the cavity of the larynx from without by means of one of the operations above described.

Laryngoscopy.—

Examination of the larynx by means of a laryngoscopic mirror introduced through the mouth.

II. THE TRACHEA.

SURGICAL ANATOMY.

Situation.—The trachea extends from lower border of fifth cervical vertebra above, where it is continuous with the larynx, to fourth or fifth dorsal vertebra below, where it bifurcates into right and left bronchi. Its length is from 10 to 13 cm. (4 to 5 inches)—its width from about 2 to 2.5 cm. ($\frac{3}{4}$ to 1 inch). It lies in a bed of lax connective tissue.

Relations.—(a) **Cervical portion,—anteriorly;** skin; superficial cervical fascia; anterior jugular veins; communicating branch between anterior jugular veins; inferior thyroid veins; thyroidea ima artery (when present); sternohyoid and sternothyroid muscles, separated by deep cervical fascia, and partly overlapping sides of trachea; isthmus of thyroid gland; thymus gland (or its remains). **Posteriorly;** esophagus. **Laterally;** lateral lobes of thyroid gland (especially on left); inferior thyroid arteries; recurrent laryngeal nerves; sheath of common carotid, internal jugular and pneumogastric. (b) **Thoracic portion,—anteriorly;** sternum; remains of thymus; origins of sternohyoid and sternothyroid muscles; left innominate vein; transverse arch of aorta; innominate artery; left common carotid artery; deep cardiac plexus; left recurrent laryngeal nerve. **Posteriorly;** esophagus. **Laterally;** lies between the pleural sacs; pneumogastrics.

Arteries.—From inferior thyroid branch of thyroid axis.

Veins.—End in thyroid plexus.

Nerves.—From trunk of pneumogastric; recurrent laryngeal branch of pneumogastric; sympathetic.

SURFACE FORM AND LANDMARKS.

The isthmus of the thyroid gland crosses the second and third tracheal rings in the adult. It is generally higher in the child.

In an average adult, about 2 cm. ($\frac{3}{4}$ inch) of additional trachea is drawn up into the neck in full extension of the cervical region.

In infants under two years, the thymus gland extends upward nearly or quite to the lower border of the thyroid gland.

Small venous trunks cross the tracheal region irregularly, chiefly emptying into the superior thyroid veins.

A communicating vein between the superior thyroid veins crosses the trachea above the isthmus of the thyroid gland.

Arteria thyroidea ima, when present, passes up from the innominate along the anterior surface of the trachea.

The upper portion of the trachea is comparatively superficial. The lower portion is comparatively deep and the vascular relations more complicated.

GENERAL SURGICAL CONSIDERATIONS.

Tracheotomy may be done in three sites—(1) Above the isthmus of the thyroid gland, or High Tracheotomy (the operation of election, because the trachea is here more accessible),—(2) Below the isthmus, or Low Tracheotomy,—and (3) Behind the isthmus (by its ligature and removal of the isthmus—hardly a separate operation, but generally added to one of the others where more room is required).

Structures of the anterior aspect of the neck more or less involved in tracheotomy above the isthmus of the thyroid,—skin; superficial cervical fascia; superficial cervical nerves; inframaxillary nerves; cutaneous arteries; anterior jugulars and communicating vein; deep cervical fascia; superior thyroid arteries and veins; tracheal layer of deep cervical fascia.

Structures of the anterior aspect of the neck more or less involved in tracheotomy below the thyroid isthmus,—the superficial structures mentioned above; communicating branch between the anterior jugular veins larger; sternothyroids closer; inferior thyroid veins larger; arteria thyroidea ima possibly present; innominate artery may cross seventh tracheal ring; trachea deeper and more movable; thymus gland present up to second year. The innominate and common carotid arteries may be in the way of a low tracheotomy.

The thymus gland or the isthmus of the thyroid gland is to be incised, between ligatures, if in the way.

If the tracheal fascia be not well incised, there is a liability of working between the fascia and trachea rather than in the latter.

INSTRUMENTS USED IN OPERATIONS UPON THE TRACHEA.

Scalpels; scissors, sharp and blunt, curved and straight; forceps, dissecting, toothed, and artery-clamp; tenacula; wound hooks; tracheotomy tubes; tampon cannulæ; tracheal forceps; artificial feather for cleansing tube; grooved director; wound retractors; dilator for tracheal wound; tracheal

aspirator; needles, curved and straight; needle-holder; sutures and ligatures; silk and gut; traction ligatures; Langenbeck's double tracheotomy hook, shield for mouth, nose, and eyes of operator.

HIGH TRACHEOTOMY.

Description.—The opening of the trachea above the isthmus of the thyroid gland. This is the operation of choice, because of the greater accessibility of the trachea here, and because of the fewer important relations.

Preparation.—The neck is to be shaved, if necessary.

Position.—Patient supine, at edge of table, shoulders elevated, head thrown back, neck made prominent by being bent well backward over a

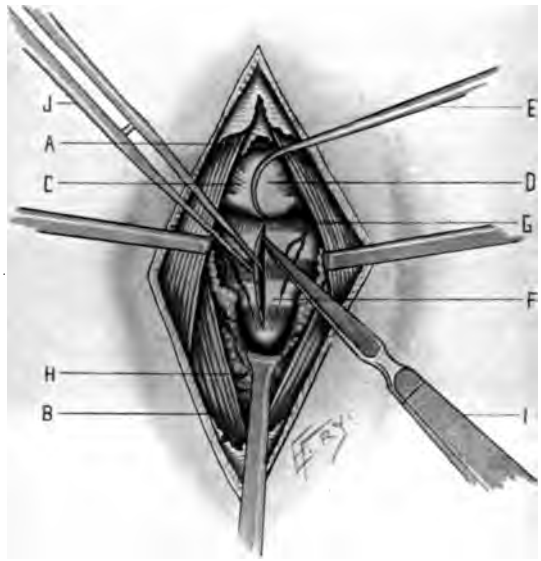

Fig. 338.—HIGH TRACHEOTOMY:—A, Sternohyoid muscle; B, Sternothyroid muscle; C, Cricothyroid muscle; D, Cricoid cartilage; E, Tenaculum steadying cricoid cartilage; F, Trachea, showing first, second, and part of third rings; G, Tracheal branches of superior thyroid artery; H, Thyroid gland, with its isthmus retracted from second and third rings, and with branches of superior and inferior thyroid arteries seen upon its surface; I, Sharp-pointed knife completing incision into trachea; J, Forceps everting lip of tracheal incision, after incision, preparatory to inserting tracheal tube.

cushion or sand-bag, chin kept rigidly in median line. Surgeon to the right of patient. Assistant opposite surgeon.

Landmarks.—Median line of neck; cricoid cartilage; upper rings of trachea.

Incision.—Vertical incision made exactly in the median line of the neck, extending from the upper border of the cricoid cartilage downward for 2.5 to 4 cm. (about 1 to 1½ inches)—the skin and trachea being steadied between the left forefinger and thumb on either side. (See Fig. 336, D.)

Operation.—(1) Divide skin, subcutaneous fatty areolar tissue, possibly the platysma, and the anterior layer of the cervical fascia, cutting between double ligatures any communicating branches between the anterior jugular veins. (2) Recognize and open up the cellular interval between the sterno-

hyoid and sternothyroid muscles by clean, full-length cuts—the inner border of these muscles being separated by blunt dissection. All separated tissues are retracted laterally. (See Fig. 338.) (3) Divide the deeper cervical fascia overlying the trachea, cutting between double ligatures any veins crossing the line of incision—a small venous plexus lies over the isthmus, and a transverse branch between the superior thyroids, crossing above the isthmus, sometimes occurs—also abnormal branches of the superior thyroid arteries may cross the upper part of the trachea. The isthmus of the thyroid gland is exposed, and, if in the way, drawn down by a hook. The tracheal rings are felt for by the finger-tip and exposed to view. The parts are still steadied laterally by the left thumb and forefinger, until the tracheal rings are well in the field. (4) All bleeding having been controlled and the white rings of the trachea being clearly defined, the trachea is to be steadied preparatory to opening. For this purpose, a tenaculum, or, preferably, Langenbeck's double tenaculum hook, is fastened by its point into the antero-inferior aspect of the cricoid cartilage and given to an assistant, who draws the cricoid cartilage upward and forward directly in the median line, gently following the play of the larynx, thus steadying the trachea by making it tense. The tip of the surgeon's left forefinger feels for the upper border of the isthmus of the thyroid gland—and, with a sharp, slender knife, held with its cutting-edge upward, a quick, limited stab is made into the median line of the trachea, just above the thyroid isthmus, and the trachea divided upward toward the chin, to but not into the cricoid cartilage, in the act of withdrawing the knife. (5) Gently seize the right lip of the tracheal wound with toothed forceps held in the left hand, and evert it just sufficiently to cause a slight gap between the cut margins—into which gap gently, quickly, but steadily insert the tracheotomy tube—still steadying the cricoid with the tenaculum until the tube is in place. (6) Having seen that all hemorrhage is controlled, the tube is tied in place by bands passing around the neck, a dressing being applied between skin and instrument. The upper and lower ends of a long wound may be united by suture, to lessen the area to be closed by granulation.

Comment.—Observe the following,—Incise only in the median line; See and feel bare tracheal rings before opening trachea; Be sure the opening is made into the trachea, and not into the surrounding areolar tissue. If possible, control all bleeding before incising the trachea—although often venous hemorrhage, otherwise difficult to stop, will cease as soon as air enters the lungs freely through the tracheal wound.

Where the thyroid isthmus encroaches upon the field, draw it down with a hook or special retractor.

Where the tissues of the neck are very thick, outward retraction by thread or instrument retractors aids in exposing the trachea and keeping the bottom of the wound freer from blood.

It is easier to insert the tube if the neck be straightened just before everting the lip of the tracheal wound, to relax the tension of the structures. The lips of the tracheal wound may be held apart by a tracheal dilator while the tube is being inserted, or by two tenacula.

Modification.—Where it is found that the isthmus of the thyroid gland encroaches too much upon the site of operation to avoid it—or in those cases in which it is elected to perform tracheotomy beneath the isthmus—having incised and separated the tissues down to the isthmus in the usual way, cut vertically directly through the center of the isthmus—immediately seize each cut half with clamp-forceps and allow the clamped ends to drop away from the trachea without any special effort to further dissect or retract them from

the trachea unless the opening be encroached upon. These cut portions are subsequently gut-ligatured. If time allow, the isthmus may be doubly ligated *in situ* and divided between these ligatures.

Modification.—Bose's Bloodless Method of Tracheotomy,—Make a median vertical incision from the middle of the thyroid cartilage downward for 4 to 5 cm. (about 1½ to 2 inches)—the soft parts are retracted laterally—incision is made through the deep layer of the cervical fascia along the upper border of the cricoid cartilage, covering the trachea and binding down the thyroid isthmus—this fascia is detached by blunt dissection and retracted downward by a special hook, carrying the isthmus and vascular supply covering the front of the trachea. The trachea being thus bared, the operation is completed as above.

LOW TRACHEOTOMY.

Description.—Inferior or Low Tracheotomy consists in the opening of the trachea below the thyroid isthmus. The trachea is much deeper here and its relations much more important—and subsequent wound complications more serious.

Preparation—Position.—As in High Tracheotomy.

Landmarks.—Median line of neck; cricoid cartilage; rings of the trachea, recognizing the upper ones, if possible, so as to determine the site of the thyroid isthmus over the second and third tracheal rings.

Incision.—Vertical incision is made exactly in the middle line of the neck, extending from the lower border of the cricoid cartilage downward to within 2 cm. (about ½ inch) of the sternal notch—while the trachea is steadied by the left forefinger and thumb on either side. (See Fig. 336, E.)

Operation.—(1) Divide skin, subcutaneous fatty areolar tissue, anterior layer of the cervical fascia, cutting between double ligatures communicating veins crossing between the anterior jugulars. (2) Having incised the connective tissue, thicker here than in the high operation, expose and separate the inner borders of the sternothyroids and sternohyoids. (3) Incise the deeper cervical fascia, also thicker here than in the high operation, and divide between double ligatures the communicating veins between the inferior thyroids, and whatever other vessels may be encountered, including the thyroidea ima artery, if present—retracting all tissues laterally. (4) The trachea is brought within sight and touch—hemorrhage is controlled by pressure forceps—the trachea is caught by Langenbeck's double tenaculum hook, or an ordinary tenaculum, and lifted upward and forward—the thyroid isthmus being retracted upward if necessary—and a sharp, slender knife is thrust with a controlled stab-movement into the trachea and made to cut through three or four rings in an upward direction as it is withdrawn. (5) The tracheotomy tube (which must have a deeper curve than for the high operation) is inserted as in the higher operation. (6) The treatment of the tube and wound are the same as in the high operation.

OTHER OPERATIONS UPON THE TRACHEA.

Tracheo-laryngotomy.—

An opening, by median incision, involving both the upper rings of the trachea and the cricothyroid membrane of the larynx—performed where more room is required than furnished by either operation alone.

Tamponing of Trachea.—

The use of some form of packing, or some form of inflation, applied around the stem of an ordinary tracheotomy tube, or a special form of tampon cannula, whereby fluids and blood are prevented from entering the lungs during operations upon the oral, nasal, and pharyngeal cavities.

Operation for the Removal of Foreign Bodies.—

Foreign bodies may be removed by means of special forceps introduced through one of the tracheotomy wounds above described.

Tracheoscopy.—

Examination of the upper part of the trachea by means of the laryngoscopic mirror.

Thoracic Tracheotomy.—

Opening of the trachea in the posterior mediastinum (see page 593).

III. THE PHARYNX.

SURGICAL ANATOMY OF THE PHARYNX.

Situation, Extent, and Structure.—A conical, musculo-membranous sac (consisting of nasal and buccal portions) placed base upward, apex downward, behind the nose, mouth, and larynx. It extends downward from base of skull to lower border of cricoid cartilage in front, and fifth (or between fifth and sixth) cervical vertebra behind. It is composed of three coats—Inner Coat, of mucous membrane:—Middle Coat, of pharyngeal aponeurosis (thickest above, where muscles are thinnest; and thinnest below, where muscles are thickest):—Outer Coat, of muscles (inferior, middle, and superior constrictors, reinforced by stylopharyngeus, palatopharyngeus and salpingopharyngeus).

Relations and Boundaries.—**Superiorly,** body of sphenoid; basilar process of occipital:—**Inferiorly,** continuous with esophagus opposite fifth (or between fifth and sixth) cervical vertebra:—**Anteriorly** (incomplete), attached, from above downward, to internal pterygoid plate, pterygomaxillary ligament, inferior maxilla, tongue, hyoid bone, thyroid cartilage, cricoid cartilage:—**Posteriorly,** attached, by lax connective tissue, to prevertebral fascia, longi colli, and recti capitis antici majores muscles, and to cervical vertebral column:—**Laterally,** attached to styloid process and its muscles (styloglossus, stylohyoid, and stylopharyngeus); and in relation with common carotid, internal carotid, and ascending pharyngeal arteries, internal jugular vein, glossopharyngeal, pneumogastric, hypoglossal, and sympathetic nerves, internal pterygoid muscle (above) and lateral lobes of thyroid gland.

Openings Into.—Two posterior nares; two eustachian tubes; mouth; larynx; esophagus.

INSTRUMENTS USED IN OPERATIONS UPON THE PHARYNX.

Scalpels; scissors; forceps, dissecting, toothed and artery-clamp; retractors; probe; grooved director; tenacula; wound hooks; mouth-gag; tongue forceps; tongue depressor; needles; needle-holder; ligatures and sutures; aneurism-needle.

MEDIAN PHARYNGOTOMY

BY MEDIAN VERTICAL INCISION THROUGH THE MOUTH.

Description.—Incision of the posterior pharyngeal wall in the median line, through the mouth. Applicable to cases of retropharyngeal abscess of small size and due to temporary cause (*e. g.*, an acute abscess).

Preparation.—Mouth cleansed by frequent antiseptic washings.

Position.—Patient on side, head elevated and turned to one side, with mouth dependent. Surgeon in front of patient.

Landmarks.—Median line of the prevertebral region; contour of involved region.

Operation.—The mouth is gagged and so directed that pus or other fluid will flow out. A straight, sharp bistoury, protected by wrapping except for about 1 cm. (about ½ inch) at its point, is directed in toward the center of the posterior pharyngeal wall, or toward the most fluctuating point, guided by the left forefinger, which marks the site—an incision about 1 cm. (about ½ inch) long is then made vertically in the median line, either upward or downward. The incised wound is not closed by suture, but allowed to drain.

LATERAL PHARYNGOTOMY

BY CURVED LATERAL INCISION THROUGH THE NECK—KOCHER'S OPERATION.

Description.—Incision of the pharynx through the lateral wall of the neck—for the exposure of the lateral wall of the pharynx, together with the tonsil, base of tongue, and retropharyngeal space. Applicable to cases requiring the fullest exposure of the pharynx.

Preparation.—Shaving of the neck, if necessary. Cleansing of the throat with antiseptic washes.

Position.—Patient supine, shoulders elevated, neck prominent, head to opposite side. Surgeon either in front of or behind the neck. Assistant opposite surgeon.

Landmarks.—Apex of mastoid process; anterior border of sternomastoid muscle; hyoid bone.

Incision.—Begins at the anterior border of the apex of the mastoid process—runs in a slight downward curve, with posterior convexity, crossing the anterior border of the sternomastoid about 2 cm. (about ¾ inch) behind the angle of the jaw—ending at the middle of the hyoid bone. (See Fig. 339, A.)

Operation.—(1) Divide the skin, superficial fascia, and platysma along the above line—cutting between double ligatures the external jugular, facial, and temporofacial veins. (2) Expose the submaxillary region—dissect out the submaxillary gland and either throw it upward over the border of the inferior maxilla, or extirpate it—dividing the facial artery between two ligatures—and preserving, if possible, the auricularis magnus and cervicofacial nerves. (3) The lingual, ascending pharyngeal, and ascending palatine arteries are tied, if necessary, close to their origin—or the external carotid itself. (4) Retract backward the great cervical vessels, with the pneumogastric and spinal accessory nerves—draw the hypoglossal nerve upward—the superior laryngeal nerve and superior thyroid artery remaining under the lower margin of the wound. (5) Work up along the internal surface of the inferior maxilla and of the internal pterygoid in the direction of the mucous membrane of the pharynx, in order to preserve the muscles lying anteriorly

and connected with the act of swallowing. If the muscles must be sacrificed, so cut them that their innervated ends will be as long as possible—dividing the posterior belly of the digastric and stylohyoid near the hyoid (their supply from the facial entering posteriorly)—the styloglossus near the tongue, avoiding the lingual and glossopharyngeal nerves (unless involved, when they must be divided) lying upon it—the stylopharyngeus near the pharyngeal insertion —and the hyoglossus and mylohyoid, to the extent indicated, near their insertion into the hyoid. (6) The wall of the pharynx will now be exposed, the superior constrictor lying above and the inferior constrictor below. Having well retracted the surrounding parts and having incised the constrictors, forming the lateral boundary of the pharynx, its interior is exposed. (7) Having accomplished the object of the operation, in closing the wound suture up the pharyngeal wall as completely as possible, in so far as the mucous membrane is concerned—leaving the center of the outer wound unsutured and packed down to the mucous membrane with gauze, to provide for drainage both from possible leakage from the mouth and from the fluids of the wound—the ends only of the outer wound being closed by suture.

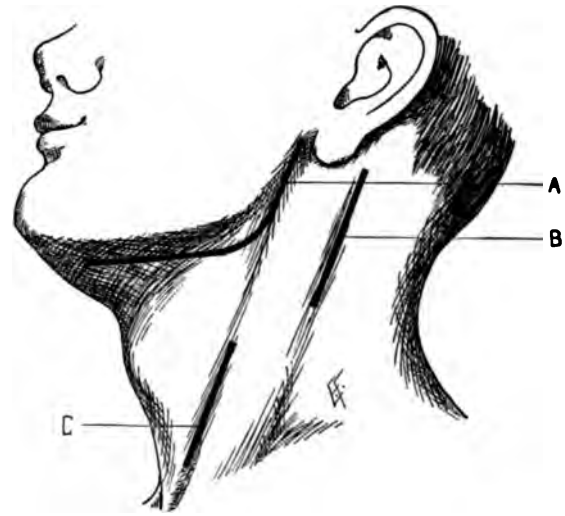

Fig. 339.—Incisions Exposing Pharyngo-esophageal Region:—A, Curved lateral incision for lateral pharyngotomy, and for exposure of tonsil, base of tongue, and retropharyngeal space (Kocher's operation); B, Lateral cervical incision for exposing the retropharyngeal space (Chiene's operation); C Incision for cervical esophagotomy.

Comment.—If a part of the wall of the pharynx be removed, the operation becomes a partial pharyngectomy.

Compare this operation with that for exposure of the tonsils through the neck, page 565.

SUBHYOID PHARYNGOTOMY

BY TRANSVERSE CURVED INCISION THROUGH THE NECK.

Description.—Subhyoid Pharyngotomy, or Suprathyroid Laryngotomy, consists in opening the pharynx through the thyrohyoid membrane, just below the hyoid bone. Chiefly done to expose the entrance of the larynx for the purpose of removing foreign bodies or growths from the upper air-passages, or for abscesses at base of epiglottis.

Preparation.—As for Lateral Pharyngotomy.

Position.—Patient supine, shoulders elevated, head thrown back, neck prominent, resting upon a cushion or sand-bag. Surgeon on patient's right or left. Assistant opposite.

Landmarks.—Hyoid bone, upper border of thyroid cartilage.

Incision.—Transverse curved incision along the lower border of the body and greater cornua of the hyoid bone. In very thick necks a vertical incision may have to be added to this.

Operation.—(1) Having incised the skin, superficial cervical fascia, and platysma, divide between double ligatures the anterior jugular veins and their branches. Some branches of the superficial cervical and cervicofacial nerves are encountered. The hyoid arteries and veins along the hyoid bone are generally not injured—and the superior thyroid artery is generally avoided, running parallel with the incision. (2) Divide most of the muscles attached to the lower border of the hyoid bone (sternohyoids, omohyoids, and most but not all of the thyrohyoids). (3) The thyrohyoid membrane (its middle and lateral portions) is now exposed—and, together with the subjacent mucous membrane lying between the base of the tongue and the superior border of the epiglottis, is incised along the inferior border of the hyoid bone, while a finger in the mouth guides the knife—keeping rather near the hyoid bone to avoid the superior laryngeal nerves piercing the lateral parts of the thyrohyoid membrane (because of the importance of preserving the sensitiveness, and thereby the expulsive power, of the larynx). (4) Seize the epiglottis, which projects into the wound, with toothed forceps and draw it forward, when the interior of the larynx and the lowest part of the pharynx will be exposed to view. (5) Having accomplished the object of the operation, suture the mucous membrane throughout—suture the ends of the external wound—and pack with gauze the central portion of the wound down to the sutured mucous membrane.

EXPOSURE OF THE RETROPHARYNGEAL SPACE

BY LATERAL CERVICAL INCISION ALONG POSTERIOR BORDER OF STERNOMASTOID MUSCLE—CHIENE'S OPERATION.

Description.—The retropharyngeal, or retro-esophageal, prevertebral areolar tissue is opened up—without incising the pharyngeal or esophageal wall. Indicated in cases of retropharyngeal abscesses due to protracted cause (*e. g.*, chronic abscess, generally from tubercular disease of the cervical vertebræ) where drainage is apt to be prolonged;—also in large, acute retropharyngeal abscesses, especially where jaws can no longer be widely opened.

Preparation.—Shave neck, if necessary.

Position.—Patient supine, or turned slightly to one side, shoulders elevated, neck prominent, resting upon cushion or sand-bag and turned to one side. Surgeon on side of operation. Assistant opposite.

Landmarks.—Posterior border of the sternomastoid.

Incision.—Along the posterior border of the sternomastoid, beginning at the mastoid process and descending as far downward as necessary, dependent upon the thickness of the structures of the neck. (See Fig. 339, B.)

Operation.—(1) Incise skin and fascia in the above line—ligate superficial vessels encountered—avoid the transverse and the descending superficial cervical nerves. (2) Recognize the posterior border of the sternomastoid (which overlaps the scalenus anticus somewhat) and draw it forward—the intermuscular groove between the sternomastoid and the scalenus anticus, in the deep cervical fascia, is thus made evident. (3) Follow with a blunt dissector, closely along the anterior surface of the scalenus anticus and in the connective-tissue plane between the scalenus behind and the common sheath

of the great vessels in front, guarding the spinal accessory nerve beneath the sternomastoid as the dissection passes behind its posterior border. (4) Recognize the outer border of the longus colli muscle as soon as reached, and keep behind this, as well as behind the great vessels—and having passed beneath the longus colli the prevertebral areolar tissue of the retropharyngeal space is reached—and the pus thus evacuated through a route behind and comparatively free of important structures. (5) Free drainage is established from the bottom of the wound—only the ends of the original incision being sutured.

Comment.—The retropharyngeal space may be also approached by incising along the anterior border of the sternomastoid, on the level of the larynx (Buckhardt's operation)—passing in front of the common sheath of the great vessels—retracting these and the sternomastoid backward, and the thyroid, larynx, trachea, and anterior cervical muscles forward—opening the fascia covering the longus colli and passing, anteriorly to it, transversely across to its inner side into the retropharyngeal or retro-esophageal prevertebral areolar tissue.

IV. THE ESOPHAGUS.

SURGICAL ANATOMY OF THE ESOPHAGUS.

Situation and Extent.—A muco-areolar muscular canal, from 23 to 26 cm. (about 9 to 10 inches) long—beginning at lower boundary of pharynx, at upper border of cricoid cartilage, opposite fifth cervical vertebra (or between fifth and sixth), passes down through superior and posterior mediastina along front of spine, lying at first behind left part of the aortic arch, then descending along right side of aorta until it curves forward anterior to and somewhat to left of aorta—to descend through esophageal opening in diaphragm into abdomen, ending in cardiac orifice of stomach, opposite tenth dorsal vertebra (or between tenth and eleventh).

Curves of the Esophagus.—The antero-posterior curves of the esophagus follow those of the vertebral column. Laterally, it curves to the left at the root of neck, and at esophageal opening of diaphragm—and is in the middle line at fifth cervical and fifth dorsal vertebræ.

Relations.—(a) **In the neck: anteriorly,** trachea, posterior part of left lateral lobe of thyroid, left recurrent laryngeal nerve. **Posteriorly,** spinal column, left longus colli muscle, prevertebral fascia. **Right,** right common carotid, right recurrent laryngeal nerve. **Left,** left carotid, left inferior thyroid artery and vein, left subclavian artery, thoracic duct. (The relationships are more marked on the left.) (b) **In the thorax: anteriorly,** lower part of trachea, beginning of left bronchus, transverse arch of aorta, left common carotid, left subclavian, posterior surface of pericardium. **Posteriorly,** spinal column, longi colli muscles, thoracic duct, right intercostal arteries and veins, left inferior azygos vein, inferior part of thoracic aorta. **Laterally,** pleuræ, pneumogastrics (forming plexus gulæ below root of lungs, thence left pneumogastric passes to anterior surface and right pneumogastric to posterior surface of esophagus). Vena azyges major lies on the right, and descending aorta on left.

Arteries.—From inferior thyroid branch of thyroid axis; descending thoracic aorta; gastric branch of cœliac axis; left inferior phrenic.

Veins.—Empty into inferior thyroid, azygos, and gastric veins.

Lymphatics.—Empty into inferior cervical and posterior mediastinal glands.

Nerves.—From recurrent laryngeals, pneumogastrics, and sympathetic. (The recurrent laryngeal branches of the pneumogastric run upward on both sides to the interval between trachea and esophagus—the left nerve lying somewhat anterior to the esophagus—the right nerve at some distance from it.)

GENERAL SURGICAL CONSIDERATIONS.

The narrowest parts of the esophagus are—at its beginning (narrowest) —opposite the fourth dorsal vertebra—at the diaphragm.

Distances (in the average adult)—from upper incisor teeth to diaphragmatic opening, about 37 cm. (about 14½ inches)—from same point to aorta, about 23 cm. (about 9 inches)—from same point to upper end of esophagus, about 14 cm. (about 5½ inches).

The deviation from the median line toward the left, in the cervical portion of the esophagus, amounts to about 1 cm. (about ½ inch).

INSTRUMENTS USED IN OPERATIONS UPON THE ESOPHAGUS.

Scalpels; scissors, blunt, sharp, straight, curved; forceps, dissecting, toothed, artery-clamp; retractors; probe; grooved director; tenacula; ligature-retractors; needles, straight and curved; needle-holder; ligatures and sutures, silk and gut; mouth-gag; tongue-forceps; esophageal forceps, various; combined mouth-gag and tongue depressor; esophageal bougies; blunt bistoury; drainage tubing and material; blunt dissector; wound-hooks; elevators; bristle probang; special foreign-body forceps and devices; stomach-tube; dilating bougies; esophagotomes; bougie with string attachment; tubage set.

EXTERNAL CERVICAL ESOPHAGOTOMY.

Description.—Incision of the esophagus in the neck—the opening ordinarily being made on the left side, opposite the natural curve of the esophagus, except when the object is more prominent and more easily reached on the right. Generally indicated for the removal of foreign body, and sometimes for tumor and for dilatation of the esophagus.

Preparation.—The neck is shaved if necessary. Where the operation is for foreign body, the position of the body is sought by instruments before incision, and the position of the incision regulated, as far as possible, by its situation.

Position.—Patient supine, shoulders elevated, neck prominent, upon cushion or sand-bag, head thrown back and turned to opposite side (generally to the right). Surgeon on side of operation—Assistant opposite.

Landmarks.—Thyroid and cricoid cartilages; trachea; anterior border of sternomastoid muscle.

Incision.—Straight incision, generally made on the left side, 8 to 10 cm. (about 3 to 4 inches) in length, beginning opposite the upper border of the thyroid cartilage and continuing downward along the anterior border of the sternomastoid, toward the clavicle, as far as necessary. (See Fig. 339, C.)

Operation.—(1) Incise skin, superficial fascia, and platysma. Ligate, between double ligatures, the communicating veins between the anterior and external jugular veins, and between the anterior jugular and facial, and possibly also the anterior jugular vein. Some branches of the superficial

cervical nerve will also be cut. (2) Expose the anterior border of the sternomastoid and draw it outward—also the sternohyoid and sternothyroid and draw them inward—divide the omohyoid (unless it can be displaced downward). (See Fig. 340.) (3) Divide the thyroid fascia—which is deep cervical fascia forming the capsule of the thyroid gland—which is blended externally with the sheath of the large vessels—and which must be divided before the esophagus can be reached. After dividing this fascia, draw the thyroid gland, larynx, and trachea inward and forward—and the common sheath of the large vessels and pneumogastric, together with the descendens noni nerve, outward. (4) Ligate and divide between two ligatures the inferior thyroid artery as it crosses the longus colli transversely, lying behind the common carotid—also the middle and superior thyroid veins if necessary. Carefully avoid the recurrent laryngeal nerve, ascending in the groove between

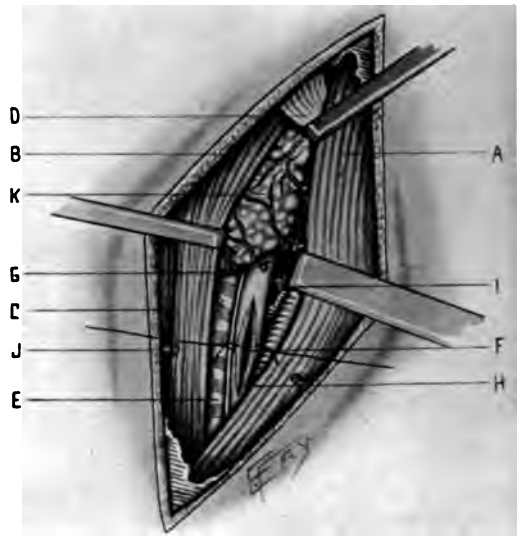

Fig. 340.—Cervical Esophagotomy:—A, Sternomastoid muscle; B, Sternohyoid muscle; C, Sternothyroid muscle; D, Omohyoid muscle; E, Trachea; F, Esophagus, showing incision, with lips of esophageal wall retracted; G, Recurrent laryngeal nerve; H, Common carotid; I, Inferior thyroid artery, ligated; J, Communicating vein between anterior and external jugular; K, Thyroid gland, showing superior and inferior thyroid arteries, and superior, middle, and inferior thyroid veins.

the trachea and esophagus, drawing it downward and inward if necessary. (5) The esophagus, in the form of a red tube, will now appear in the bottom of the wound. Pass a sound or esophageal bougie into the esophagus through the mouth, so as to protrude the esophageal wall prominently into the wound. A vertical incision is now made through the lateral or postero-lateral aspect of the wall of the esophagus, while steadied with toothed forceps, carefully avoiding the recurrent laryngeal nerve. (6) The lips of the wound in the tube are grasped in turn with toothed forceps and a thread-retractor carried through each lip upon a fully curved needle—thus enabling the wound to be held widely open and the interior brought to view for the purpose of inspection, removal of foreign body, or operation. (7) At the conclusion of the operation, unless contraindicated by nature of operation (generally after the simple removal of foreign bodies), the lips of the esophageal wound should

be sutured with gut. The outside wound is sutured at its ends, leaving the portion opposite the wound in the tube open and lightly packed with gauze, until the tube has healed and no longer danger of leakage exists from the esophagus. Where indicated, the wounds in the esophagus and in the neck are both left open until the esophageal wall has healed, when the outer wound is aided to granulate as rapidly as possible, or granulating surfaces may be brought together by suture and the process of union hastened. (8) The patient is temporarily fed by bowel at first—then by stomach-tube carefully introduced.

Comment.—The wound in the esophageal wall is best closed by two rows of fine catgut sutures—one whipping together the edges of the mucous coat—the other passed a short distance from the margins of the wound, after the manner of a Lembert suture, approximating the connective-tissue coats.

CERVICAL ESOPHAGOSTOMY.

Description.—The making of an artificial opening in the esophagus through the neck. Generally resorted to below the site of an inoperable stricture, or during the treatment of an operable one, for the purpose, in the former case, of introducing food into the stomach, and, in the latter, of practising mechanical dilatation.

Preparation — Position — Landmarks — Incision.—As for Esophagotomy.

Operation.—All the steps in the operation are the same as for Cervical Esophagotomy, up to the opening of the esophagus. This having been accomplished, the edges of the esophageal wound (the walls of the esophagus) are sutured to or as near to the skin of the external wound as possible—the external incision being then closed up to the margin of the funnel-shaped wound leading into the esophagus. After healing, the patient is fed by an esophageal tube introduced through the cervical wound—or his stricture is systematically dilated through the same channel. (See Figs. 339 and 340.)

Comment.—Where it is found that a single séance of dilatation, in the case of esophageal stricture, accomplishes the object, the esophageal wound is closed at once—and the operation-wound becomes in name, and in all other respects, an Esophagotomy.

PARTIAL CERVICAL ESOPHAGECTOMY.

Description.—The excision of a portion of the cervical esophagus throughout its entire circumference—with the restoration of the severed ends by suturing, if possible—or as a preliminary to a Cervical Esophagostomy. Generally done for malignant growth of the esophagus.

Preparation — Position — Landmarks — Incision. — As for Cervical Esophagotomy.

Operation.—(1) Having exposed the esophagus as in the above operations, this tube is isolated, being separated by blunt dissection upward and downward—from the trachea in front—from the prevertebral areolar tissue behind—from the connective tissue, lateral lobes of the thyroid, recurrent laryngeal nerves, and the great vessels laterally. (2) The involved portion of the esophagus is then excised by transverse division with scissors above and below. (3) If the gap be not too great, and it be otherwise possible, the proximal and distal ends are now sutured by two tiers of chromic gut—

the first whipping the edges of all the coats of the esophagus together—the second being interrupted Lembert sutures passing through the outer walls of the esophagus a short distance from the lips of the wound in the tube—the suturing being done over an esophageal bougie passed through the mouth and distending the esophagus opposite the site of suturing. (4) If the ends of the esophagus cannot be made to meet, the proximal end is closed, first by whipping, then by suturing the outer coats in the Lembert fashion—and the distal end is sutured into the wound in the neck permanently, as for esophagostomy, the entire circumference of the distal portion being sutured into the cervical wound (differing in this respect from the Cervical Esophagostomy above described, where only the lips of the lateral wound in the esophagus are stitched into the cervical wound). (5) The external wound is left open in either case—temporarily in the first instance—permanently in the second. Figs. 339 and 340 illustrate some common features.)

INTRODUCTION OF ESOPHAGEAL BOUGIE.

Description.—(1) Seat the patient upright, preferably in a chair—head thrown back and slightly to side away from surgeon, and steadied in this position by the individual or by an assistant. Gag the mouth, the handle of the gag being upon the patient's left. Place a small, thin napkin upon the tongue, extending well back. Insert the left index-finger to the base of the tongue, both depressing it and simultaneously drawing it forward, the napkin giving a firmer hold. (2) Upon this left finger as a guide, introduce the lubricated bougie, held between the right index and thumb, straight into the mouth, until its tip reaches the posterior pharyngeal wall—then direct it downward and backward along the esophagus—causing the patient to swallow it as he gags—being guided as to the depth of introduction by the circumstances of the case and the known distances of the structures from the upper incisor teeth. (See General Surgical Considerations.)

OTHER OPERATIONS UPON THE ESOPHAGUS.

Esophagoscopy.—

The introduction into the esophagus of a special instrument, electrically illuminated, and with or without mirrors (an esophagoscope)—whereby the lumen of the canal may be examined as it is withdrawn from the stomach to the mouth (after the manner of an urethroscope).

Internal Esophagotomy.—

The division of the strictured esophagus upon the principle of the strictured urethra—by means of a cutting instrument passed through the narrowed portion upon a guide—or by some special form of esophagotome.

Operation for Foreign Bodies in the Esophagus.—

Foreign bodies high up in the esophagus can often be seen or felt, and removed with special pharyngeal forceps. Those lower down, out of sight and reach, may still often be removed by special instruments for that purpose, introduced through the mouth. Impacted bodies not removable by instruments alone, are removed by instruments introduced, in the majority of cases, through an esophageal wound—generally a cervical esophagotomy. Foreign bodies very low down may be reached by forceps or the fingers through the cardiac orifice of the stomach, introduced through a gastrotomy wound.

Direct Dilatation of the Esophagus for Stricture.—

The dilating bougies or instruments of increasing sizes, are passed directly from the mouth through the narrowed esophagus, in the same manner as described under the Introduction of the Esophageal Bougie, the stricture being gradually distended.

Direct Divulsion of Esophageal Stricture.—

The passage, from the mouth, in quick succession, of increasing sizes of dilators—thus rupturing, in a minor degree, the surrounding contracted tissues.

Retrograde Dilatation of the Esophagus for Stricture.—

Here the dilating instrument is passed from below—through a gastrotomy wound, in cases where but one sitting of the retrograde method is necessary, followed by the immediate closure of the stomach wound,—or through a gastrostomy wound, where frequent resorts to the method are necessary. Dilatation may be begun by passage of the instrument from the stomach through the strictured esophagus (as the title indicates)—but is often commenced by causing the patient to swallow, prior to anesthesia, a thread with a split shot attached—this is found in the stomach, and upon it the dilating rubber tubes. or other instruments, are drawn from the mouth, through the esophagus, out of the stomach wound—or vice versa.

Retrograde Divulsion of Esophageal Stricture.—

The same as Direct Divulsion—except performed in the reverse direction, through a gastrotomy or gastrostomy wound.

Division of Esophageal Stricture by String Friction (Abbe's Operation).—

A preliminary gastrostomy is done—after recovery from which a small bougie, with attached silk thread, is passed from the mouth into the stomach—the ends of the thread are grasped by fingers at the mouth and stomach—the small bougie is then withdrawn—another large enough to gently engage the stricture is introduced—the thread is then drawn back and forth, and the frictioning process, as it passes between the engaged bougie and the esophageal wall, soon causes the engaged bougie to become loose—and it is then similarly replaced by a larger size, until the desired caliber is reached. Sometimes the thread is passed through a cervical esophagostomy wound, instead of through the mouth, and then out of the stomach. When sufficient dilatation has been secured, the gastrostomy wound is closed (and also the esophagostomy wound, if one have been made).

Division of Esophageal Stricture by String Friction (Bryant's Operation).—

A special form of bougie, carrying a thread passed through an opening near its tip and running over a concealed pulley, is passed through the mouth and down the esophagus, until well engaged in the stricture—when by the sawing motion of the thread the stricture is worn down as in the above operation. By this method, gastrostomy may often be dispensed with.

Treatment of Esophageal Stricture by Permanent Tubage.—

Consists in the passage through the stricture of a funnel-shaped rubber tube, by means of a guide, until the funnel portion of the tube rests above the stricture—a piece of silk attached to a hole in the tube being also tied to the ear of the patient. The tube remains *in situ* for ten days at a time, and is then cleansed and replaced—fluid food being taken through it. Applicable to some otherwise inoperable cases of malignant disease.

V. THE TONSILS.

SURGICAL ANATOMY OF THE TONSILS.

Situation.—In the recesses between the anterior pillars of the fauces (the palatoglossi muscles) and the posterior pillars of the fauces (the palatopharyngei muscles)—corresponding, externally, to the angle of the inferior maxilla.

Relations.—Externally, inner surface of superior constrictor—which, together with the pharyngeal aponeurosis, separates the tonsil from the internal carotid and ascending pharyngeal arteries. **Internally,** free. **Anteriorly,** palatoglossi muscles. **Posteriorly,** palatopharyngei muscles.

Arteries.—Dorsalis linguæ of lingual; ascending palatine of facial; ascending pharyngeal from external carotid; tonsillar of facial; descending palatine of internal maxillary; branch from small meningeal of internal maxillary (or from middle meningeal).

Veins.—End in the tonsillar plexus, outside of the tonsil.

Nerves.—From Meckel's ganglion, and from the glossopharyngeal.

GENERAL SURGICAL CONSIDERATIONS.

The internal carotid artery lies about 2 cm. (about ¾ inch) to the postero-external aspect of the tonsil—and nearer when tortuous—separated from it by the superior constrictor, styloglossus, and stylopharyngeus. The facial artery, when tortuous, may approach the anterior border of the tonsil. The ascending pharyngeal artery and the glossopharyngeal nerve lie to its outer side.

INSTRUMENTS USED IN OPERATIONS UPON THE TONSILS.

(1) For Operations through the Mouth:—bistouries, straight and curved, sharp-pointed; Whitehead's combined tongue-depressor and mouth-gag; head-mirror; tonsillotomes; scissors, long-handled, sharp and blunt, straight and curved; forceps, long-handled; artery-clamp forceps, long-handled; tenacula, long-handled; aneurism-needles, long-handled, straight and laterally curved; sponge-holders; needle-holder, long-handled; curved needles; ligatures; sutures. (2) For Operations through the Neck:—Same as those used for approaching the esophagus, omitting those for use within the esophagus.

TONSILLOTOMY.

Description.—Incision of the tonsil by means of a knife introduced through the mouth. Indicated in abscess.

Preparation.—Mouth is washed frequently with antiseptic solutions.

Position.—Patient sits upright in a chair, in a good light—mouth gagged on the opposite side—head thrown back and steadied. Surgeon sits in front—assistant stands behind patient's head, steadying it and gag, and pressing tonsil into the field by fingers in the neck.

Operation.—A straight or slightly curved sharp-pointed bistoury, wrapped with plaster or silk to within a little more than 1 cm. (about ½ inch) of its point, is made to enter the mouth flatwise (its surfaces looking upward and downward), with the back of the blade toward the cheek—it passes backward horizontally and is made to enter the protruding anterior border of the tonsil

(which border generally extends out beyond the anterior pillar of the fauces) in this position—passes into the gland parallel with its free inner surface—and cuts its way from within outward on to its free aspect, in the act of withdrawal.

PARTIAL TONSILLECTOMY THROUGH THE MOUTH.

Description.—Excision of the free portion of the tonsil (generally hypertrophied)—by means of a special instrument (tonsillotome)—or by means of scissors or knife, aided by forceps.

Preparation—Position.—As for Tonsillotomy.

Operation.—(**a**) With the Tonsillotome; Having applied a combined mouth-gag and tongue-depressor, introduce the tonsillotome flatwise, with blade drawn back, until the pharynx is reached—then rotate it through a quarter circle, holding its handle parallel with the median line—engage the tonsil in the ring of the instrument, encircling it everywhere to an equal depth, drawing the tonsil out with a tenaculum if necessary—push the blade home firmly and steadily—and withdraw the instrument with the attached portion of the tonsil. (**b**) With long, curved, blunt scissors; Having similarly applied a combined mouth-gag and tongue-depressor, and supposing the tonsil to be the left one, this tonsil is grasped with long forceps held in the operator's left hand—the scissors, held in the right hand, are introduced closed—and are then opened and made to seize the portion of the tonsil protruding beyond the pillars of the fauces, between the grasp of the forceps and the pillars, and to sever the tonsil with one stroke—which is withdrawn in the hold of the forceps. In operating on the right side, hold the instruments in the opposite hands. (**c**) With long straight, blunt bistoury; The operation is done as with scissors.

COMPLETE TONSILLECTOMY THROUGH THE MOUTH.

Description.—The entire tonsil is excised through the mouth—preceded, where difficulty is anticipated, by a preliminary tracheotomy, a temporary ligation of the common carotid, and, if necessary, by a temporary splitting of the cheek. Indicated in those cases where the growth is limited to the tonsil, or but slightly involves the adjacent portion of the base of the tongue or pillars of the fauces, but in which the tissues of the neck are not infiltrated.

Preparation.—As for Tonsillotomy.

Position.—Patient supine, shoulders and head raised, and head turned so as best to expose and illuminate field—Surgeon on side opposite operation—Assistant opposite surgeon. Positions for the preliminary operations will be determined by those operations.

Landmarks.—Anatomical boundaries (see Surgical Anatomy, page 563).

Preliminary Operations.—(**a**) Preliminary tracheotomy, with plugging of the larynx, or the use of a tampon-cannula—performed several days in advance of the operation, preferably (or may be done at the time of the operation). (**b**) Preliminary temporary ligation of the common carotid—performed at the time of the operation. (**c**) Preliminary splitting of the cheek, if considered necessary—from the angle of the mouth backward to the masseter, with twisting or gut-ligaturing of both ends of the facial artery—performed at the time of the main operation.

Operation.—(**1**) Having completed the preliminary tracheotomy and the temporary ligation of the common carotid, expose the region of the tonsil

by means of a gag on the opposite side, and by splitting of the cheek on the same side, and by drawing the tongue well out of the mouth. The tumor is now dealt with as indicated. (2) Where a movable, encapsulated tumor is encountered, the overlying mucous membrane is incised and the tumor shelled out by means of blunt dissection and the fingers. These simple cases hardly call for such extensive preliminary operations. (3) Where the tumor is immovable, and involves to some extent the fauces and the base of the tongue,—the soft palate is divided in the middle line and thence outward, with scissors—the growth is seized with forceps or tenaculum and drawn toward the median line—while its boundaries are attacked with long, blunt, curved scissors, removing the pillars and tonsillar tumor *en masse*—together with the entire gland and growth, and as much of the fauces and tongue as necessary, all being deliberately dissected out of their bed—controlling hemorrhage by pressure-forceps, or by twisting or traction upon the temporary ligature around the common carotid until the vessels can be controlled. (4) No suturing of the parts about the bed of the tonsil is done. If necessary, the region is packed with gauze, and pressure kept up without and within. (5) The wound of the cheek is neatly repaired by interrupted external and internal sutures, the latter being applied first. The wound of the common carotid is closed. The tracheotomy tube is retained *in situ* for a few days. The mouth is frequently rinsed with antiseptic washes.

COMPLETE TONSILLECTOMY THROUGH THE NECK.

CHEEVER'S OPERATION.

Description.—The lateral pharyngeal wall is exposed by means of a careful dissection through the neck, and removed to the indicated extent, together with the tumor, tonsil, and all lymphatic glands and involved tissues adjacent. The operation is at first a cervical pharyngotomy, and becomes a partial pharyngectomy, in proportion to the amount of pharyngeal wall removed. Indicated in large, adherent diffused tumors of the tonsillar region, with lymphatic involvement of the neck.

Preparation.—Mouth frequently cleansed with antiseptic washes. Neck and side of face shaved, if necessary.

Position.—Patient supine, shoulders elevated, head thrown back and to opposite side, over a cushion or sand-bag, rendering neck prominent—Surgeon on side of operation (or on opposite side leaning over)—Assistant opposite surgeon.

Landmarks.—Lobule of ear; anterior border of sternomastoid; hyoid bone; lower border of inferior maxilla and its angle; known anatomical relations of the tonsil.

Incision.—(1) Oblique incision begins opposite lobule of ear—passes down anterior border of sternomastoid as far as the level of the hyoid bone, or to below the level of the lower border of the tumor. (2) A second nearly horizontal incision begins from the oblique one, opposite the angle of the jaw, and is continued transversely forward along the lower border of the inferior maxilla. (See Fig. 341, A.)

Operation.—(1) These incisions are carried through skin, platysma, and superficial fascia—the external jugular and temporofacial veins are divided between two ligatures—branches of the cervicofacial nerve encountered are guarded as far as possible. (2) The flaps thus marked out are drawn, the one upward and forward, the other downward and forward, and

the dissection carried on deeply in the submaxillary and superior carotid triangles (see Surgical Anatomy of the neck, page 133)—dividing the stylohyoid, styloglossus, stylopharyngeus, and probably the digastric—dividing the facial artery and vein between double ligatures—and guarding the hypoglossal and glossopharyngeal nerves. (3) The parotid gland is displaced upward—the submaxillary gland forward—and the internal carotid artery and internal jugular vein outward—these structures being held out of the way by retraction. (4) The pharyngeal wall is now exposed and opened—and the tonsil removed, together with as much of the pharyngeal wall and adjacent tissues, including cervical glands, as are involved, by scissors or knife. (5) The pharyngeal wall, upon completion of the operation, is sutured as well as possible, and a temporary drain is placed from the pharyngeal wall

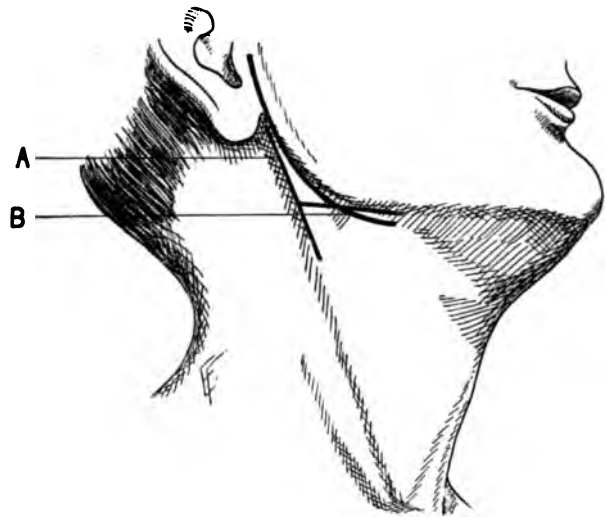

Fig. 341.—Incisions for Excision of Tonsil and Parotid Gland:—A, Incision for complete tonsillectomy through the neck (Cheever's operation); B, Incision for excision of the parotid gland.

through the lower part of the cervical wound, the remainder of the outer wound being sutured.

Comment.—The operation may be aided by a finger in the mouth, outlining the growth and pressing it outward. The cheek may also be split and the tonsil attacked from both sides.

Other Methods of Pharyngotomy for Exposure of the Tonsil.—

Czerny's Method—a preliminary tracheotomy is performed, a tampon-cannula being used—the inferior maxilla is then divided and its parts temporarily turned aside.

Mikulicz's Method—a preliminary tracheotomy, with a tampon-cannula, is performed—and a part or all of the ascending ramus of the inferior maxilla is excised.

VI. THE PAROTID GLAND AND STENSON'S DUCT.

SURGICAL ANATOMY.

Situation.—The parotid gland lies upon the side of the face just below and in front of the ear, overlapping the angle of the ramus of the inferior maxilla anteriorly, and extending behind it posteriorly.

Boundaries.—Superiorly; root of zygoma. **Inferiorly;** angle of inferior maxilla, and line drawn thence to mastoid process. **Anteriorly;** overlaps masseter muscle to a variable extent. **Posteriorly;** external auditory meatus; mastoid process; sternomastoid; posterior belly of digastric (somewhat overlapping it).

Relations of Surfaces.—Anterior surface; grooved by posterior border of ascending ramus of inferior maxilla—lying, in front of ramus, over masseter muscle—and passing, behind ramus, between external and internal pterygoid muscles. **External surface;** lobulated and covered by parotid fascia, platysma, and skin, with several lymphatic glands resting upon it, as well as facial branches of auricularis magnus nerve. **Internal surface;** in relation with styloid process and its muscles, and with internal carotid artery and internal jugular vein—and passes deeply into neck by three large processes—(1) Pterygoid process, running forward under ramus of inferior maxilla, between external and internal pterygoids—(2) Glenoid process, running inward under temporomaxillary articulation into back of glenoid cavity—(3) Carotid process, running inward to surround styloid process and pass between carotid vessels. **Separated** from submaxillary gland by stylomaxillary ligament.

Arteries.—From the external carotid and from its branches.

Veins.—Empty into the external jugular.

Lymphatics.—Empty into the superficial and deep cervical glands.

Nerves.—From carotid plexus; facial; auriculotemporal; auricularis magnus.

Structures Passing through the Parotid Gland.—Arteries; external carotid passes deeply into gland from below and posteriorly, and gives off within the gland—transverse facial, emerging from front of gland—temporal, emerging from above—posterior auricular, emerging from behind—and internal maxillary, passing inward between neck of jaw and internal lateral ligament. **Veins;** temporomaxillary; connecting vein from temporomaxillary to internal jugular. **Nerves;** facial, entering gland at its posterior border, crossing external carotid in its passage forward, and dividing in the gland into—temporofacial division, emerging upward and forward from anterior border of gland—and cervicofacial division, emerging downward and forward from anterior border of gland; branches of auricularis magnus, entering from below to join facial; auriculotemporal branch of inferior maxillary, emerging from upper part of gland.

Structures in Proximity to Bed of Parotid Gland.—Internal carotid artery; internal jugular vein; spinal accessory, glossopharyngeal, and pneumogastric nerves.

Stenson's Duct.—Formed by branches converging from anterior part of gland—runs transversely forward, crossing masseter muscle, piercing buccinator muscle, and passing obliquely forward between this muscle and the mucous membrane of the mouth, to open upon the inner aspect of cheek opposite the crown of the second upper molar tooth. Its general course is about a finger's-breadth below the zygoma. The transverse facial artery passes above it, and branches of the facial nerve below it.

Socia Parotidis.—Sometimes exists as a separate gland, lying upon the masseter between the zygoma and Stenson's duct.

INSTRUMENTS USED IN OPERATIONS UPON THE PAROTID GLANDS.

See those mentioned under the Esophagus (page 558) and Tonsils (page 563)—especially those used in exposing these structures.

EXCISION OF THE PAROTID GLAND.

Description.—The total removal of even the normal parotid gland is very difficult—and when involved by a large, adherent tumor, it is practically impossible to remove the entire gland. When the tumor is small and the combined mass of tumor and gland is movable, the excision is somewhat less difficult.

Preparation.—Neck and side of face are shaved, if necessary.

Position.—Patient supine, shoulders elevated, neck prominent, head turned to opposite side. Surgeon on side of operation. Assistant opposite surgeon.

Landmarks.—Anatomical boundaries of the parotid, and the contour of the tumor.

Incision.—Vertical incision beginning midway between mastoid process and condyle of jaw—extending downward parallel with the ascending ramus of the jaw to just below its angle—rounding thence forward just beneath the lower border of the inferior maxilla to the anterior border of the masseter muscle. Additional room may be gotten by adding a posterior incision to the vertical one opposite the forward curve just described. Also the vertical incision may be continued on downward along the anterior border of the sternomastoid below the point at which the anterior or posterior addition to the vertical incision comes off, as determined by the size and nature of the tumor. (See Fig. 341, B.)

Operation.—(1) The flap of integuments marked out by the vertical incision with the forward curve beneath the inferior maxilla, should be raised and turned upward upon the face and stitched to the cheek—and the posterior margin of the wound drawn well backward. Doubly ligate the superficial veins as encountered, and divide them between the ligatures. (See Fig. 342.) (2) The chief hemorrhage may be controlled in one of three ways, dependent upon the nature and extent of the operation and the judgment of the operator —(a) By the ligation of the vessels as encountered in the steps of the operation —(b) By the early exposure and double ligation of the external carotid with its division between the ligatures—(c) By the early exposure and temporary ligation of the common carotid. The first method may be resorted to in the simplest cases—the third in the most difficult. (3) The gland and tumor are approached from the inferior and posterior aspect—dissected from their bed and drawn upward and forward and held under traction of vulsella. During this step the external carotid will be brought into view and should be doubly ligated and divided between the ligatures (unless done as a preliminary operation—and should be done even if the common carotid have had a temporary ligature thrown around it, as the branches of the external carotid help to hold the gland in its bed). And all arterial and venous branches subsequently encountered entering or leaving the gland, as it is raised from its bed, are to be similarly divided between double ligatures. (4) The treat-

ment of the facial nerve is difficult. If the nerve be involved in large, adherent tumor-growth, its sacrifice is almost certain—and, under these circumstances, it is often deliberately divided. If the tumor be more friable, and danger of leaving infecting material not thereby materially increased, one should endeavor, by means of a blunt dissector and the fingers, to break away overlying and encompassing gland and free the main divisions (temporofacial and cervicofacial) of the nerve and preserve them intact. In any event, where possible and not contraindicated, an attempt should be made to save the branches of the nerve as long as possible—and, where they have been divided, after the removal of the gland, to gut-suture the proximal and distal ends of those severed (neurorrhaphy). (5) The deeper portions of the gland (pterygoid, glenoid, and carotid lobes) are to be now dissected from

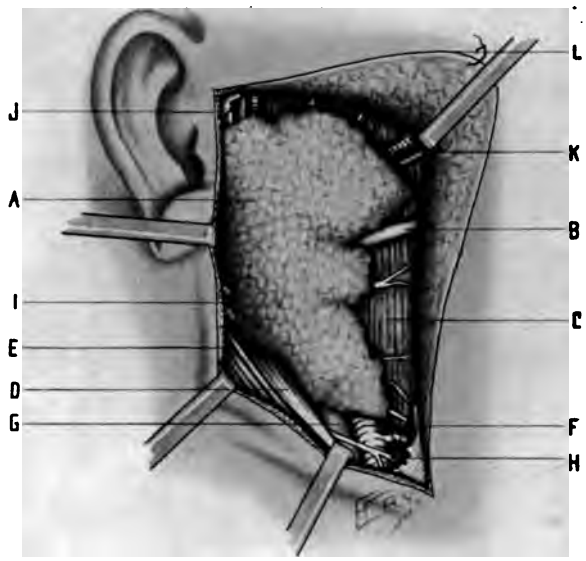

Fig. 342.—Excision of Parotid Gland:—A, Parotid gland; B, Stenson's duct; C, Masseter muscle; D, Stylohyoid muscle; E, Sternomastoid muscle; F, External carotid artery; G, Jugular vein; H, Hypoglossal nerve; I, Posterior auricular artery and vein; J, Temporal artery and vein and auriculotemporal nerve; K, Transverse facial artery and vein. Temporofacial branches of facial nerve are seen emerging upward and forward from the gland—and cervicofacial branches downward and forward. The pterygoid, glenoid, and carotid processes of the gland are hidden from view. L, The flap stitched back to the cheek.

their beds chiefly by means of a blunt dissector and curved scissors, with extreme care—remembering that these processes of the gland rest upon the internal carotid artery and internal jugular vein—and that the pneumogastric, glossopharyngeal, spinal accessory, and hypoglossal nerves lie in comparatively close proximity. Injury to the internal jugular vein is the chief danger here. Slight additional room is gained at this difficult stage, in the deep wound between the jaw and the mastoid process, by pushing the jaw well forward and to the opposite side. Where difficulties appear insurmountable, the deeper lobes, or parts of them, must be cut off and left behind. (6) The tumor is now drawn upward and the facial portion dissected out. (7) Stenson's duct is ligated with chromic gut and severed a short

distance from the gland—its distal end being touched with the actual cautery, or carbolic acid, and left *in situ*. (8) All hemorrhage having been controlled, a dependent drainage is temporarily introduced and the remainder of the wound sutured and a firm compress applied.

Comment.—The vessels from which hemorrhage is to be expected are the superficial temporal, transverse facial, occipital, posterior auricular, internal maxillary, and external carotid arteries; the external jugular and temporomaxillary veins, and branches between the external and internal jugular veins; and numerous unnamed and enlarged anastomoses.

The ramus of the lower jaw may be turned aside in an osteoplastic flap to give more room.

Where the tumor of the parotid is encapsulated, the tumor alone may be removed and the gland left intact, except for the incision into the gland for the enucleation of the growth.

VII. THE SUBMAXILLARY GLAND AND WHARTON'S DUCT.

SURGICAL ANATOMY.

Situation.—The submaxillary gland lies below the base and internal surface of the inferior maxilla and above the digastric muscle—occupying the anterior part of the submaxillary triangle.

Relations.—Covered by; skin; platysma; superficial cervical fascia, facial vein, inframaxillary branches of facial nerve; deep cervical fascia; submaxillary fossa of body of inferior maxilla; lymphatic glands. **Rests upon;** mylohyoid in front; hyoglossus behind; styloglossus above; and also upon facial artery, mylohyoid branch of inferior dental artery, and mylohyoid branch of inferior dental nerve. **Anteriorly;** anterior belly of digastric. **Posteriorly;** stylomaxillary ligament, which separates it from parotid gland.

Other Relations.—(**a**) Bulk of submaxillary gland is separated from sublingual gland by mylohyoid muscle. (**b**) Facial artery grooves posterior and superior aspects of the gland. (**c**) Lingual branch of fifth and hypoglossal nerves lie between the gland and hyoglossus muscle. The glossopharyngeal nerve lies beneath the hyoglossus muscle. (**d**) Deep portion of submaxillary gland passes around posterior free border of mylohyoid muscle on to the hyoglossus muscle.

Arteries.—Submaxillary and submental branches of facial, and branches of lingual.

Veins.—Branches corresponding with arteries.

Nerves.—From submaxillary ganglion; mylohyoid branch of inferior dental; sympathetic.

Wharton's Duct.—Runs inward between mylohyoid and hyoglossus—then between mylohyoid and geniohyoglossus—and finally under mucous membrane of mouth, between geniohyoglossus and sublingual gland—to empty at side of frænum linguæ. It runs between the lingual of fifth and hypoglossal nerves on hyoglossus muscle—passing under lingual nerve at anterior border of hyoglossus, and then lying above it.

INSTRUMENTS.

See those used in exposing Esophagus and Tonsils.

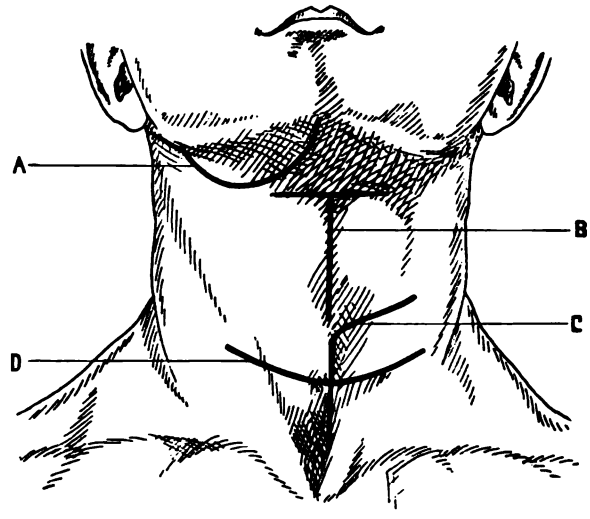

Fig. 343.—POSITION OF INCISIONS FOR OPERATIONS UPON THE LARYNX AND SUBMAXILLARY AND THYROID GLANDS:—A, Excision of submaxillary gland; B, Total laryngectomy; C, Partial thyroidectomy; D, Total thyroidectomy.

EXCISION OF SUBMAXILLARY GLAND.

Description.—The submaxillary gland is frequently removed for tumor.

Preparation—Position.—As for the Parotid Gland (page 568).

Landmarks.—Anatomical boundaries of the gland, and the contour of the tumor.

Incision.—Curved incision, with downward convexity, extending from just below median line of inferior maxilla to just below angle of inferior maxilla—reaching below to hyoid bone. (See Fig. 343, A.)

Operation.—(1) Incise skin, platysma, superficial fascia along above line—dividing, between double ligatures, the superficial veins encountered (tributaries of facial, anterior jugular, external jugular). The inframaxillary branches of the facial nerve are encountered crossing the line of incision and are safeguarded as far as possible by retraction. (2) The flap of superficial structures thus formed is dissected back—retracted upward toward the face—and either held out of the way, or stitched to the cheek. (3) The special compartment of deep cervical fascia enclosing the submaxillary gland is now incised transversely at its lower part and the gland exposed. The connective tissue attachments of the gland to the hyoid bone and digastric tendon are divided. (4) The gland is now raised from the mylohyoid and hyoglossus and retracted upward over the lower border of the jaw. (5) The facial artery is tied and cut between two ligatures as soon as it presents in the field. The hypoglossal nerve is guarded as it lies between the submaxillary gland and the lower part of the hyoglossus; and the lingual of the fifth as it lies behind the gland and the upper part of the hyoglossus and styloglossus; (the glossopharyngeal lying beneath the hyoglossus and out of the way). (6) The gland is now drawn downward and outward and separated from the submaxillary fossa of the inferior maxilla by blunt dissection—and its deep portion drawn and dissected out from behind the mylohyoid muscle. (7) Wharton's duct is ligated a short distance from the gland and divided—

and its distal end touched with the actual cautery or carbolic acid. (8) Temporary drainage may be used at the dependent angle of the wound—which is elsewhere closed—and a firm compress applied.

VIII. THE SUBLINGUAL GLAND AND DUCT OF BARTHOLIN.

SURGICAL ANATOMY.

Situation.—The sublingual gland lies beneath mucous membrane of forepart of mouth, near to frænum linguæ, in contact with sublingual fossa of inferior maxilla, and rests upon mylohyoid and geniohyoglossus muscles.

Relations.—Superiorly; mucous membrane of mouth. **Inferiorly;** mylohyoid muscle. **Anteriorly;** sublingual fossa of inferior maxilla; its opposite fellow. **Posteriorly;** deep part of submaxillary gland (mylohyoid separating it from bulk of submaxillary gland). **Internally;** geniohyoglossus, from which lingual nerve and Wharton's duct separate it.

Arteries.—Sublingual and submental.

Veins.—Correspond with arteries.

Nerves.—From gustatory and sympathetic.

Duct of Bartholin.—The main duct of the gland—running along with, and opening in common with, Wharton's duct.

Ducts of Rivinus.—Eight to twenty secondary ducts—opening on floor of mouth.

INSTRUMENTS.

See those used in exposing the Esophagus (page 558) and Tonsils (page 563).

EXCISION OF SUBLINGUAL GLAND

THROUGH FLOOR OF MOUTH.

Description.—The sublingual gland may require removal for tumor, or for embedded calculus.

Preparation.—Frequent antiseptic rinsings of mouth.

Position.—Patient supine, shoulders and head elevated, mouth gagged open and tongue held to opposite side—Surgeon on side of operation—Assistant opposite.

Landmarks.—Anatomical relations of gland, and outline of tumor.

Incision.—A straight incision made in floor of mouth, beginning at the median line, a short distance back of the alveolar margin, and carried obliquely backward and outward, parallel with the alveolar margin, for about 4 cm. (about 1½ inches).

Operation.—(1) Having incised mucous membrane of mouth and retracted margins of wound, the upper aspect of the gland is exposed immediately beneath it. (2) Having well exposed the upper portion of the gland by retraction of the margins of the wound, the gland is seized with toothed forceps and drawn upward, while being separated by means of a blunt dissector—from the mylohyoid muscle below—from the geniohyoglossus muscle, lingual nerve, and Wharton's duct internally—from its opposite fellow in front and on the opposite side—and from the deep part of the submaxillary gland behind. (3) Having raised it from its bed, its ducts are divided. (4) The mucous membrane is sutured over its site—one end being left open for temporary drainage, if thought necessary.

Comment.—The gland may be partially excised (in cystic enlargements) by picking up its upper wall with toothed forceps and cutting out a large piece of the wall and gland with curved scissors.

IX. THE THYROID GLAND.

SURGICAL ANATOMY.

Situation.—The thyroid gland is situated at the upper part of the trachea —consisting of two lateral lobes, which extend from nearly as high as the oblique line on the ala of thyroid cartilage, down to fifth or sixth tracheal ring—and of an isthmus from 0.5 to 2 cm. (about ¼ to ¾ inch) broad, which generally covers the second and third (and sometimes fourth) tracheal rings.

Relations.—Anteriorly; covered by sternohyoid; sternothyroid; omohyoid; and slightly overlapped by anterior border of sternomastoid. **Laterally;** sheath of great vessels. Upper part of lateral lobe lies between the sternothyroid and inferior constrictor, the latter separating it from the ala of thyroid cartilage. **Posteriorly;** embraces trachea and larynx, reaching backward to lower part of pharynx, and, especially on left, to esophagus; recurrent laryngeal nerves; branches of inferior thyroid artery.

Middle or Pyramidal Process.—May be developed in connection with the thyroglossal duct—extending upward from the isthmus or left lobe—and connected to the thyrohyoid membrane or body of the hyoid bone.

Suspensory Ligaments of the Thyreoid Gland.—Two ligaments pass from inner and posterior aspect of lobes upward to sides of cricoid cartilage. Recurrent laryngeal nerves lie in contact with their outer surface.

Arteries.—Two superior thyroid arteries from external carotid to superior, internal and anterior parts of lateral lobes; two inferior thyroids from thyroid axis to external and posterior parts of lateral lobes; and sometimes thyroidea ima from innominate or aorta.

Veins.—Two superior and two middle thyroid emptying into internal jugular; two inferior thyroid, emptying into innominate. These veins form a plexus upon the surface of the gland and trachea.

Lymphatics.—Empty into thoracic duct and right lymphatic duct.

Nerves.—From inferior and middle cervical ganglion.

Other Relations.—Recurrent laryngeal nerves ascend obliquely to side of trachea, running either behind or in front of inferior thyroid arteries—requiring, therefore, special care to avoid them.

Middle cervical ganglion—lies opposite sixth cervical vertebra—generally lying upon or near the inferior thyroid artery.

It is necessary to distinguish the deep cervical fascia surrounding the thyroid gland from the capsule of the gland itself.

INSTRUMENTS.

See those used in exposing the Esophagus (page 558) and Tonsils (page 563).

PARTIAL THYROIDECTOMY

BY ANGULAR INCISION—KOCHER'S OPERATION.

Description.—Consists in the removal of one lobe of the thyroid gland. The features of the removal of a large goitrous thyroid can be but very

imperfectly illustrated upon a normal thyroid gland—but the steps of the operation for the former condition will be given.

Preparation.—Neck shaved.

Position.—Patient supine, shoulders elevated, neck prominent, head at first slightly to opposite side and then held in median line. Surgeon in front of neck, on side of lobe to be removed (or on opposite side leaning over). Assistant opposite surgeon.

Landmarks.—Outline of sternomastoid muscle; upper border of thyroid cartilage; anatomical position of thyroid gland; contour of tumor.

Incision.—Begins over the prominence of the sternomastoid muscle, on a level with the thyroid cartilage—runs forward nearly transversely, to median line, inclining slightly downward in the crease of the neck—thence passes vertically downward to the suprasternal notch, or, in large tumors, on to the manubrium. (See Fig. 343, C.)

Operation.—(1) The above incision passes through skin, superficial fascia, and platysma. (2) In the Horizontal Portion of the Wound;—the anterior jugular and connecting branch between it and the external jugular are divided between double ligatures. (The external jugular lies behind the posterior end of this incision.) Branches of the superficial cervical and inframaxillary nerves are encountered and are guarded as well as possible by retraction. Externally, the anterior edge of the sternomastoid is exposed, freed, and drawn backward. Internally, the sternohyoid and sternothyroid are exposed, the overlying fascia being displaced upward. (3) In the Vertical Portion of the Wound;—the cervical fascia between the sternohyoid and sternothyroid is divided. The transverse vein above the suprasternal notch is divided between double ligatures. The inner margins of the two above muscles are freed and partly divided toward their upper ends, with double ligature and division of the vessels encountered. (4) The Outer Capsule of the Goitre now alone intervenes between the Gland;—divide this and separate it from the lateral aspects of the goitre with blunt dissector—dividing between double ligature the superior and inferior accessory veins which may pass from the capsule to the goitre. Displace the outer capsule of the goitre, with the overlying muscles, by passing a finger beneath the goitre from the outer side. (5) Dislocation of the Goitre is now done; which is accomplished, after inserting a finger beneath the goitre, by lifting it forward out of its bed and turning it toward the opposite side—exercising care that the vessels, especially the inferior thyroids, are not stretched sufficiently to give way. (6) The Chief Vessels are now Ligated between Double Ligatures;—these are brought into the field in proportion to the dislocation of the tumor from its bed. The inferior thyroid artery and vein are first sought by drawing the tumor upward and forward—the artery is isolated with especial care, as the recurrent laryngeal nerve is in very near relation, either anteriorly or posteriorly to it—and if any doubt exist, it should be left until the last. The superior thyroid artery and vein are sought above the isthmus, being freed with blunt dissector while the tumor is drawn downward and forward. The middle thyroid vein and the branches of unnamed enlarged vessels are similarly tied and divided. (7) Isolation of the Isthmus;—expose if possible, and divide between double ligatures, a superior and inferior communicating vein, and probably some arteries, at the upper and lower borders of the isthmus. By means of a director, or blunt dissector, the isthmus is separated from the trachea—a stout double ligature is passed beneath, tied on either side, and the isthmus divided between them—while the tumor is further lifted out of its bed and away from the trachea by fingers passed beneath the growth.

Be especially careful of the recurrent laryngeal nerve in the separation of the posterior portion of the gland from the trachea—for which reason it is well to cut through the posterior portion of the capsule of the gland in order to protect the recurrent laryngeal nerve. (8) The depth of the wound is temporarily drained—the major portion of the wound being sutured—and a firm, compressing dressing applied.

Comment.—Many additional unnamed vessels are present in large goitres.

COMPLETE THYROIDECTOMY

BY TRANSVERSE CURVED INCISION—KOCHER'S OPERATION.

Description.—Where both lobes of the thyroid gland are involved, both lobes of the gland are removed—except that a small portion of the healthy gland tissue is left, if possible, in order to maintain the special function of the gland and thus prevent the cachexia strumipriva which is apt to supervene when the entire thyreoid gland tissue is removed. The full difficulties of the operation are very imperfectly appreciated in the excision of a normal gland, as compared with those encountered in a large goitrous tumor.

Preparation.—Neck shaved.

Position.—As for Partial Thyreoidectomy, except that the position of the head is changed from time to time to meet the indications of the steps of the operation.

Landmarks.—Those of the partial operation.

Incision.—Transverse curved incision, with slight downward convexity, is made across the prominence of the tumor, so as to subsequently fall along the cleavage line of the neck—extending laterally over the sternomastoids—and extending further upward and backward on the side of greater enlargement. (See Fig. 343, D.)

Operation.—In all essential features the operation is similar to the one just described, with such modifications as the larger size of the tumor suggests. (1) After having cut through skin, superficial fascia, and platysma, and ligated the superficial vessels, the sternohyoid, sternothyroid, and omohyoid muscles (which are often thinned over the tumor by pressure) are divided transversely over the tumor, internally, and their ends drawn upward and downward,—and the sternomastoids are partly cut through (entirely if necessary) from their anterior border and the uncut portions retracted outward. (2) The tumor is thus completely exposed, covered by its outer capsule—and its further removal is accomplished practically as in the partial thyroidectomy. First one lateral lobe and then the other is attacked—dislocated—and its vessels tied—the isthmus isolated and divided between ligatures—the details of the steps and the termination of the operation being similar to the unilateral operation.

Comment.—The least amount of transverse division of muscles done the better, as marked retraction and deformity are apt to follow if the muscles do not reunite. All muscles severed, whether wholly or in part, should be repaired with catgut suture at the end of the operation.

The transverse curved incision, where the muscles do not have to be divided, makes a better skin scar—and the angular incision leaves a more marked skin scar but does not divide the muscles.

Goitres are also treated by Enucleation-resection—by Enucleation—by Exothyropexy (freeing the gland from the capsule and fixing superficially in the wound to granulate and shrink)—by injection—etc.

CHAPTER IV.

OPERATIONS UPON THE THORAX.

I. THE THORACIC WALL AND CONTENTS.

SURGICAL ANATOMY.

Boundaries of Thorax.—Anteriorly; manubrium, gladiolus, and ensiform portions of sternum; costal cartilages; muscles of anterior thoracic region; vessels and nerves. Posteriorly; dorsal vertebræ; ribs, from vertebral extremities to angles; muscles of posterior thoracic and spinal regions; vessels and nerves. Laterally; ribs, from costal cartilages to angles; muscles of lateral thoracic regions; clavicles and their muscles; scapulæ and their muscles; vessels and nerves. Superiorly, upper opening of thorax. Inferiorly, lower opening of thorax, closed by diaphragm.

Contents of Thorax.—Heart and pericardium; lungs and pleuræ; trachea and bronchi; esophagus; thoracic vessels and nerves; thoracic duct; superior, anterior, middle, and posterior mediastina; thoracic aspect of diaphragm. (For contents of mediastina, see each mediastinum, pages 587, 588, and 592.)

Boundaries of Upper Opening of Thorax.—Anteriorly; upper border of manubrium sterni. Posteriorly; body of first dorsal vertebra. Laterally; first rib. Dimensions; averages 12.7 cm. (5 inches) transversely, and 6.3 cm. (2½ inches) antero-posteriorly.

Structures Passing through Upper Thoracic Opening.—(1) Centrally; sternohyoid and sternothyroid muscles; thin layer of deep cervical fascia; thymus gland (in infants) or its remains; middle thyroid artery (sometimes); trachea; esophagus; prevertebral fascia; longi colli muscles. (2) Laterally; innominate artery (on right side); common carotid and left subclavian arteries (on left); internal mammary and superior intercostal (on both sides); innominate and inferior thyroid veins; pneumogastric, cardiac, phrenic, sympathetic, left recurrent laryngeal, and anterior branches of first dorsal nerves; apices of lungs and their pleuræ; thoracic duct (on left); right lymphatic duct (on right).

Boundaries of Lower Thoracic Opening.—Anteriorly; ensiform cartilage; cartilages of seventh, eighth, ninth, tenth, and eleventh ribs. Posteriorly; body of twelfth dorsal vertebra. Laterally; twelfth ribs. Floor; formed by diaphragm, varying in elevation with respiration.

Structures Passing through Floor of Thorax: (Diaphragm).—Through Aortic Opening of Diaphragm; aorta; vena azygos major; thoracic duct; left sympathetic nerve (occasionally). Through Esophageal Opening; esophagus; pneumogastric nerves; esophageal branches of thoracic aorta. Through Caval Opening; vena cava inferior; branches of phrenic nerve. Through Right Crural Opening; greater and lesser right splanchnic nerves; right sympathetic nerve. Through Left Crural Opening; greater and lesser left splanchnic nerves; vena azygos minor; left sympathetic nerve (generally). (For attachments, relations, and position of diaphragm, see that structure.)

Structures of Thoracic Wall Opposite an Intercostal Space (between costal cartilages and angles of ribs).—Integument; superficial fascia, with

superficial arteries, veins, lymphatics, and nerves; special thoracic muscles overlying ribs (dependent upon site); deep fascia; external intercostal muscles; intermuscular areolar tissue between intercostal muscles, with intercostal arteries, veins, lymphatics, and nerves; internal intercostal muscles; endothoracic fascia; subpleural areolar tissue; parietal pleura. (The external intercostal muscles extend from tubercles of ribs, posteriorly, to costal cartilages, anteriorly, and from the anterior ends of the external intercostals the external intercostal fascia is continued to the sternum. And beneath this fascia, the internal intercostal muscles intervening, lies the triangularis sterni muscle, extending from second or third costal cartilage above, to seventh costal cartilage below, and to outer end of costal cartilages externally. The internal intercostal muscles extend from the sternum, anteriorly, to the angles of the ribs, posteriorly, and from the posterior ends of the internal intercostals the internal intercostal fascia is continued to the vertebral column. And beneath this fascia, the external intercostal muscles intervening, lie the infracostales muscles, extending from the angles of the ribs toward the vertebral column.)

Structure of Thoracic Wall Opposite a Rib (between costal cartilages and angles of ribs).—Integument; superficial fascia, with superficial arteries, veins, lymphatics, and nerves; special thoracic muscles overlying ribs (dependent upon site); deep fascia; external layer of costal periosteum; rib; internal layer of costal periosteum; endothoracic fascia; subpleural areolar tissue; parietal pleura.

Relations of Overlying Bones to Chest-wall.—Clavicle; its inner end articulates with supero-external aspect of manubrium (forming the lateral boundaries of suprasternal notch). The inner third of clavicle passes obliquely over the manubrium, costal cartilage, and inner end of first rib, lying 0.6 to 1.2 cm. (¼ to ½ inch) above rib, and passes thence outward to its articulation with acromion, crossing about the center of second rib, from 3.2 to 3.8 cm. (1¼ to 1½ inches) above the rib. Scapula; rests upon postero-external aspect of thorax, from second to eighth ribs. When arms are by side, superior angle is on level with upper border of second rib (opposite interval between first and second dorsal spines), inferior angle being on level with seventh intercostal interval, or sometimes upper border of eighth rib (between seventh and eighth dorsal spines), and root of spine on level with interval between third and fourth dorsal spines.

Muscles Covering and Forming Thoracic Wall (extracostal, intercostal, and intracostal muscles).—*Anteriorly;* pectoralis major; subclavius, internal intercostals; triangularis sterni (and attachments of sternomastoid, sternohyoid, and sternothyroid to manubrium; and attachments of aponeuroses of external oblique, internal oblique, and transversalis abdominis and diaphragm to ensiform cartilage). *Laterally;* platysma myoides; pectoralis major; pectoralis minor; latissimus dorsi; serratus magnus; external intercostals; internal intercostals; diaphragm (and parts or all of some of the more particularly clavicular and scapular muscles—subclavius; deltoid; omohyoid; supraspinatus; infraspinatus; subscapularis; teres minor; teres major; trapezius,—and parts of some of the muscles attached to the upper ribs—scalenus anticus and medius,—and parts of some of those attached to the lower ribs—external oblique; internal oblique; transversalis abdominis). *Posteriorly;* trapezius; latissimus dorsi; quadratus lumborum; serratus magnus; levator anguli scapuli; rhomboideus major and minor; scalenus posticus; serratus posticus superior and inferior; splenius capitis and colli; ilio-costalis; musculus accessorius ad ilio-costalem; cervicalis ascendens;

longissimus dorsi; transversalis colli; trachelomastoid; spinalis dorsi; complexus; biventer cervicis; semispinalis dorsi and colli; multifidus spinæ; rotatores spinæ; supraspinales; interspinales; intertransversales; levatores costarum; internal intercostals; infracostales; diaphragm.

Chief Arteries of Thoracic Wall.—Internal Mammary of thyroid axis, giving off following branches—sternal; anterior intercostal (two in each of five or six upper spaces); perforating (five or six branches to the five or six upper spaces); musculophrenic (furnishing anterior intercostal branches for five or six lower spaces). Superior Intercostal of thyroid axis, to first intercostal space. Suprascapular of thyroid axis. From Transversalis Colli of thyroid axis—posterior scapular. From Axillary—superior thoracic; acromial thoracic; long thoracic; alar thoracic; subscapular. From Thoracic Aorta—ten or eleven aortic intercostals, giving off anterior and posterior branches—the anterior, or true intercostal arteries, dividing into superior and inferior, supplying each intercostal space from the second to the space below twelfth rib, and anastomosing with anterior intercostals of internal mammary and musculophrenic. From Abdominal Aorta—phrenic arteries.

Chief Veins of Thoracic Wall.—Correspond with arteries.

Chief Nerves of Thoracic Wall.—From Posterior Divisions of Cervical Nerves—branches from third, fourth, fifth, sixth, seventh, and eighth nerves. From Cervical Plexus—supraclavicular branches; deep muscular branches. From Brachial Plexus—muscular branches; posterior thoracic; suprascapular; anterior thoracic; subscapular. From Dorsal Nerves—anterior branches of upper eleven nerves (the intercostal nerves); posterior branches of upper eleven nerves.

SURFACE FORM AND LANDMARKS.

Suprasternal Notch is formed by upper border of manubrium and inner aspects of non-articular portions of inner ends of clavicles.

Superior border of sternum (during inspiration) is on level with cartilaginous disc between second and third dorsal vertebræ.

Transverse ridge at junction of manubrium and gladiolus corresponds with costal cartilage of second rib, and is opposite fifth dorsal vertebra.

Lower end of gladiolus is opposite ninth dorsal vertebra, and corresponds with termination of seventh costal cartilages.

Infrasternal depression lies between seventh costal cartilages, and corresponds with ensiform cartilage.

Structures behind manubrium sterni—Left innominate vein lies slightly below superior border; Innominate, common carotid, and subclavian arteries come off from aortic arch about 2.5 cm. (one inch) below upper border; Trachea bifurcates opposite manubrio-gladiolar junction; Esophagus.

Pectoral furrow (sternal furrow) is the median vertical furrow between pectoral muscles, its bottom corresponding with center of sternum.

Subcostal (abdomino-thoracic) arch is formed by ensiform cartilage and cartilages of seventh, eighth, ninth, and tenth ribs and extremities of eleventh and twelfth ribs. The subcostal angle varies from 60 degrees to 80 degrees, averaging about 70 degrees in male and 75 degrees in female.

Apices of lungs, with their pleuræ, rise from 1.2 to 4.4 cm. ($\frac{1}{2}$ to $1\frac{3}{4}$ inches) above clavicle.

Right sterno-clavicular articulation is in relation with innominate artery, right innominate vein, and pleura.

Left sterno-clavicular articulation is in relation with left innominate vein, left carotid and pleura.

First rib is almost covered by clavicle and scapula.

Infraclavicular fossa is the space, or hollow, between lower border of clavicle and upper border of second rib.

Coracoid process lies about 1 inch below junction of outer and middle thirds of clavicle.

Nipple, in male, lies over infero-external part of pectoralis major, generally between fourth and fifth ribs, about $\frac{3}{4}$ inch to outer side of junction of ribs and costal cartilages, and a little more than 4 inches from median line.

Inferior border of pectoralis major corresponds with fifth rib.

Internal mammary artery is 0.5 to 1.5 cm. ($\frac{1}{4}$ to $\frac{5}{8}$ inch) from outer border of sternum, above—and 1 to 2 cm. ($\frac{7}{16}$ to $\frac{13}{16}$ inch) from it below.

Costo-vertebral groove is occupied by the erector spinæ and multifidus spinæ, and their subdivisions.

Tips of the spinous processes at the upper and lower parts of thorax correspond, approximately, with the neck of the rib below the particular spine, but the tips of those spines near the center of the series about correspond with the neck of the second rib below.

Distance from upper central incisor teeth to bodies of first, second, third, fourth, fifth, and tenth dorsal vertebræ is, approximately, 20.3, 21.8, 23.8, 25.7, 28, and 38 cm. (8, $8\frac{5}{8}$, $9\frac{3}{8}$, $10\frac{1}{8}$, 11, and 15 inches) respectively, in the average person of 5 feet 8 inches, as measured by esophageal route (which data are of use in locating obstructions of the esophagus).

INSTRUMENTS USED IN OPERATIONS UPON THE THORAX.

Exploratory syringe; cannula and trocar; scalpels; cartilage knives; probe-pointed bistoury; dissecting forceps; toothed forceps; artery-clamp forceps; tracheal and esophageal forceps; scissors, curved and straight; retractors, various; saws, Gigli's, chain, Doyen's; probe; large sound; grooved director; tenacula; periosteal elevators, straight and curved; costotome; bone-cutting forceps; rongeur forceps; bone-holding forceps; bone-drill; wire; aneurism-needles, straight and curved; needles, various; needle-holder; sutures and ligatures of silk, plain and chromic gut, and silkworm-gut; drainage-tubes; gauze.

OPERATIONS UPON THE THORACIC WALL AND CONTENTS.

For operations upon the Thoracic Viscera, Mediastina, Diaphragm, and Mammary Gland, see those structures in the following sections. For operations upon the Bones, Joints, Arteries, and Nerves of the Thorax, see those structures in Part I, General Surgery.

II. THE FEMALE MAMMARY GLAND.

SURGICAL ANATOMY.

Description and Position.—A hemispherical eminence consisting of glandular, fatty, and areolar tissue, lying between the two layers of the superficial pectoral fascia, the lower layer resting upon the sheaths of the pectoralis major and serratus magnus muscles, and the upper layer being covered by the skin. The superficial pectoral fascia (continuous above with the super-

ficial cervical fascia) divides, opposite the upper border of the mamma, into anterior and posterior layers, passing, respectively, in front and behind the gland, and holding it, as it were, in a sling. From the anterior layer of this superficial pectoral fascia numerous processes pass into the gland and support its parenchyma. The posterior layer of this fascia is separated from the deep thoracic fascia by a loose, easily separable layer of areolar tissue.

Arteries of Mammary Gland.—Anterior intercostals of internal mammary, of second, third, fourth, and fifth spaces; perforating branches of internal mammary, of second, third, fourth, and fifth spaces; intercostals of thoracic aorta, of second, third, fourth, and fifth spaces; long thoracic of axillary; external mammary, of axillary (if present).

Veins of Mammary Gland.—Form circulus venosus around base of gland and empty into branches corresponding with arteries.

Lymphatics of Mammary Gland.—Empty into axillary and anterior mediastinal glands. (For position of axillary glands, see Axilla, under Lymphatic Glands and Vessels, page 138.)

Nerves of Mammary Gland.—Anterior and lateral cutaneous branches of second, third, fourth, and fifth intercostal nerves; supraclavicular branches of cervical plexus.

SURFACE FORM AND LANDMARKS.

The female mammary gland extends vertically generally over the third, fourth, fifth, and sixth (and sometimes seventh) ribs, and transversely from the border of the sternum to the anterior axillary margin.

GENERAL SURGICAL CONSIDERATIONS.

Three grades of excision for the removal of the female breast may be done;—(1) Radical excision of the entire breast, with the removal of the entire lymphatic and areolar tissue of the axillary region, and of the thoracic wall between the breast and axilla (whether visibly or palpably diseased or not), with or without removal of parts of the pectoral muscles. Indicated in cases of malignant disease of mammary gland. (2) Ordinary or non-radical excision of entire breast, either without opening of axilla, or with limited opening of axilla for the removal of only the palpably enlarged glands. Indicated in non-malignant growth of the mammary gland, and also used by some operators for malignancy of the gland. (3) Partial excision of the breast. Indicated where a benign growth is limited to a comparatively small portion of the breast.

For instruments used in operating upon the breast, see those mentioned under "The Thoracic Wall and Contents" (page 576).

INCISION OF BREAST.

Description.—Division of mammary gland tissue. Most frequently indicated in abscesses, which may be antemammary (in areolar tissue between skin and gland), intramammary (within the glandular tissue), or postmammary (in areolar tissue between gland and pectoral muscle). In the first and third varieties the abscess should be opened by a route not involving the gland. In the second variety (which is here considered) the gland substance itself is incised.

Preparation.—Site of incision and irregularities of nipple are scrubbed. Axilla is shielded from operation-site.

Position.—Patient supine, at edge of table. Surgeon on side of operation.

Landmarks.—Contour of breast, together with situation of abscess.

Incision.—All incisions into gland substance should be straight, and made somewhere in a straight line radiating from nipple to circumference of gland, so as to damage lactiferous ducts as little as possible. Incision should not extend too near nipple.

Operation.—Incise skin, superficial fascia, and the gland substance intervening between fascia and outer wall of abscess, generally with one cut of knife. Having laid open cavity of abscess, and controlled hemorrhage with clamp-forceps, if necessary, its walls are well curetted, so as to leave clean, raw surfaces. The resulting walls of cavity may then be approximated by deeply buried gut sutures, followed by closure of more superficial wound. Or cavity may be temporarily packed with gauze, after curettage and irrigation, and the superficial wound closed up to the exit of gauze drainage. The latter course is better in acute and the former in chronic abscesses.

Comment.—It is sometimes possible to excise the entire abscess, without opening its cavity, and close the entire wound at once by deeply buried and superficial cutaneous sutures.

PARTIAL EXCISION OF MAMMARY GLAND

BY ELLIPTICAL INCISION.

Description.—Removal of a limited portion of the breast.

Preparation.—Breast and nipple scoured; breast shaved, if necessary; axilla protected from field of operation.

Position.—Patient supine, at edge of table. Surgeon on side of operation. Assistant opposite Surgeon.

Landmarks.—Contour of breast, together with position of growth; plane of pectoral muscle.

Incision.—An ellipse is outlined so as to include the growth by a wide margin, with the two arms of the incision meeting between the inner aspect of the growth and the nipple, and between the outer aspect of the growth and the periphery of the gland, the general direction of the ellipse radiating from nipple to circumference. When indicated, the nipple is also included in the ellipse and removed.

Operation.—Incise skin and superficial fascia, first along one side of ellipse, then along opposite side, controlling bleeding with clamp-forceps. Slightly retracting tissues in a direction away from the ellipse, incise through the glandular tissue along the lines of the original incision, passing downward toward the base of the gland, with a tendency for the incisions to approach as they deepen. The part to be removed is thus entirely surrounded and its depth finally reached, either before the entire thickness of the mammary gland has been traversed, or at the pectoral muscle, after traversing its entire thickness, and is removed *en masse*. All bleeding vessels are tied with gut. The depths of the wound are approximated by buried gut sutures, and the margins of the wound united with silk or silkworm-gut.

Comment.—When the part removed is considerable, it may be necessary to undercut the tissues laterally to enable the walls and surface of the wound to be approximated without too great tension. The principle of the subcutaneous excision of the mammary gland (*q. v.*) may also be applied to the excision of a part of the gland.

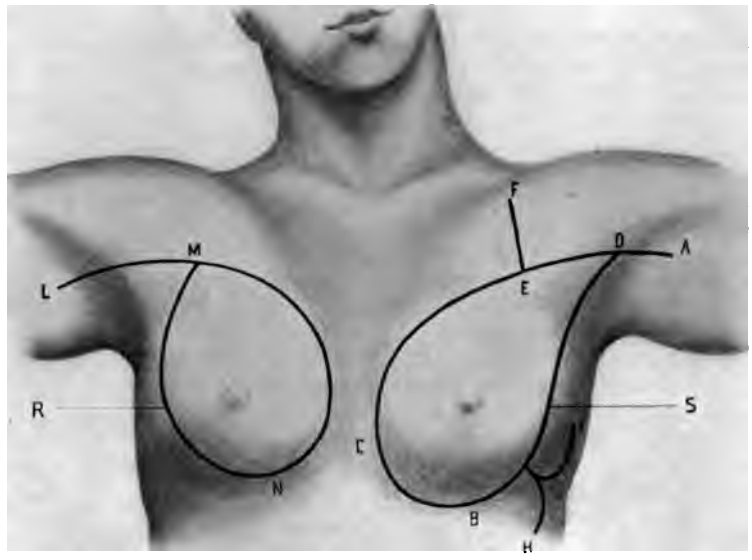

Fig. 344.—OPERATIONS UPON THE MAMMARY GLAND:—R, Radical excision of the breast, Halsted's operation; S, Radical excision of the breast, Warren's operation. For explanation of the reference-letters, see text.

RADICAL EXCISION OF MAMMARY GLAND.

HALSTED'S OPERATION.

Description.—Consists in complete excision of breast, together with removal of the entire pectoralis major (or all save its clavicular portion), as well as a transverse division of the pectoralis minor, with the turning outward of its outer part, and clearing, *en masse*, of fatty-areolar-glandular tissue from axilla. The substance of the operation, as described by Halsted, is given in the following account.

Preparation.—Breast, nipple, and axilla scrubbed; chest-wall and axilla shaved.

Position.—Patient supine, at edge of table, with head and shoulders elevated and arm held at right angle to side. Surgeon on side of operation. Assistant opposite.

Landmarks.—Contour of breast and growth; landmarks of axilla and pectoral muscles.

Incision.—Begins directly above the upper circumference of mammary gland, well beyond all detectable involvement, and passes outward and downward along outer border of gland; curves below around breast and ascends upon inner side upward in a curve to point of beginning, thus entirely encircling gland; and thence, without stopping, is continued in a curved direction along anterior surface of pectoralis major, to and slightly down upon the anterior fold of the axilla (Fig. 344, M N L).

Operation.—(1) Incise, throughout, through skin and fatty areolar tissue, clamping or tying all bleeding vessels. (2) Reflect the triangular flap of skin only (L M N) outward to base-line (L N). Dissect back, as a separate flap, the fatty areolar tissue (corresponding to this triangle of skin)

to inferior border of pectoralis major, where it becomes a part of the axillary areolar-fatty tissue. (3) Divide costal insertions of pectoralis major, and split the muscle itself in the groove between costal and clavicular portinso outward to about opposite scalenus anticus tubercle on first rib (which lies nearly opposite junction of inner and middle thirds of clavicle). (4) Cut through (opposite scalenus tubercle on first rib) the clavicular portion of pectoralis major, directly to clavicle, cutting at right angle to fibers of clavicular portion, thus exposing apex of axillary space. (5) Retract pectoralis major upward and dissect out areolar tissue from under its clavicular portion. (6) Continue splitting of pectoralis major, in original line, out to humerus and sever the humeral attachment of the costal (sternal) portion. (7) Raise the entire mass of integument, mamma, and fatty-areolar tissue upward and outward, and while the submuscular fascia is thus put upon the stretch, this mass is stripped from the chest-wall and pectoralis minor, closely hugging the ribs and removing, if possible, the fascial sheath of the pectoralis minor, beginning above at the upper and inner part of the wound and proceeding downward and outward. (8) Having reached in this clearing, and well exposed, the lower (outer) margin of pectoralis minor, divide that muscle just below its center, at right angle to its fibers. (9) Divide fascia and areolar tissue over coracoid attachment of pectoralis minor and turn them inward, preparatory to the upward reflection of outer part of pectoralis minor. (10) Retract upward and outward the severed outer part of pectoralis minor with the retractor that had heretofore retracted pectoralis major alone. (11) Dissect out the loose fatty-areolar tissue beneath pectoralis minor near its insertion, carefully clearing the small vessels (mainly veins) and ligating them off close to axillary vein. (12) Expose subclavian vein at its highest subclavicular point and dissect away the entire contents (fat, areolar tissue, glands, and many small vessels) of the axilla, with extremest care and thoroughness and with a sharp knife, aided by forceps. Expose and strip axillary vein absolutely clean of all extraneous tissue, ligating its branches close to main trunk, holding the tissues and pushing the vein from them, rather than the reverse. Expose axillary artery, in the majority of cases, and remove all loose tissue above the axillary vessels and axillary plexus of nerves. (13) Having cleared axillary region, grasp mass of tissues to be removed, drawing it outward and somewhat upward with left hand, to put upon slight stretch, and cut away the mass of fascia from the lateral thoracic wall (inner axillary wall), closely hugging ribs and serratus magnus. (14) Just prior to reaching junction of posterior and lateral axillary walls, the original triangle of skin (freed early in the operation) (R) is drawn outward by an assistant, to aid in exposing the tissues lying upon the subscapularis, teres major, and latissimus dorsi. The surgeon, taking a new hold upon the mass to be removed, now cleans out the posterior axillary wall, from within outward. Thus the subscapular vessels are conveniently exposed, and are tied or clamped before being cut. The subscapular nerves are exposed, and may or may not be removed, their retention being preferable. (15) Turn the mass of tissues back into their original position and divide their connection with the thorax by a single stroke of the knife passing along the first incision made, namely, from L to N, removing everything in one piece. (16) Approximate circumference of wound by a buried purse-string suture of strong silk. Only the base, L N, of the triangular skin-flap (L M N) is included in the purse-string. The apex and rest of the triangular flap are shifted to a new and lower position so as to form a lining for the fornix of the axilla. (17) No drainage is established. Uncovered portion of wound

frequently heals by organization of the blood-clot and should be covered with rubber tissue.

Comment.—Every bleeding point in this extensive field of operation is immediately clamped. The divided pectoralis minor should be sutured with chromic gut.

RADICAL EXCISION OF MAMMARY GLAND.

WARREN'S OPERATION.

Description.—Consists in complete excision of breast, together with removal of sternal part of pectoralis major entirely; and also in removal of entire pectoralis minor, or a simple turning back of its divided ends; with clearing out, *en masse*, of fatty-areolar-glandular tissues of axilla, aided by a transverse division of clavicular portion of pectoralis major; and the formation of one or two cutaneo-areolar flaps from the lateral thoracic wall to cover over the main wound, in conjunction with its own margins.

Preparation—Position—Landmarks.—Same as in the Radical Excision of the Breast by Halsted's method (page 582).

Incisions.—(1) Outer Primary Incision (Fig. 344, S) begins at anterior margin of axilla, at its junction with the arm, and passes along just above anterior border of axilla and the lower margin of pectoralis major, encircling the lower circumference of the breast to its inner and lower quadrant. (2) Inner Primary Incision (D C) begins at center of anterior axillary border (D) and, passing inward and downward, diverges from first incision to encircle upper and inner part of circumference of breast and meet first incision at point of its ending (C). (3) Upper Secondary Incision (E F) is made later, passing from point E, on upper primary incision, to clavicle (F), dividing the clavicular portion of pectoralis major at right angle to its fibers. (4) Lower Secondary Incisions (H and I) are made at end of operation, for the purpose of raising flaps to cover the main wound, the incisions (one, or both if necessary) begin from lower primary incision at point G (not shown in figure), and pass upward (I) and downward (H).

Operation.—(1) Incise through skin and fatty-areolar tissue along above primary lines, clamping all bleeding vessels. (2) Dissect back margins of wound so as to expose base of gland in its entire circumference, carrying incision to pectoralis major, which is freely exposed along entire upper incision. (3) Divide sternal portion of pectoralis major from thorax, and throw entire mass outward and downward. (4) Sever humeral insertion of pectoralis major, exposing pectoralis minor and axilla. (5) Upper secondary incision is now made, to expose axillary vessels up to where they pass beneath the clavicle. (6) Divide the pectoralis minor transversely and reflect halves outward and inward, or entirely remove them. (7) Clear, by careful dissection, axilla of all extraneous tissues and unimportant vessels, from clavicle to lower part of axilla, including all fatty, glandular, and areolar tissue lying in front and behind the vessels, as well as the areolar tissue between serratus magnus and subscapularis. Branches of axillary vein and artery are tied close to their vessels, and any thoracic or scapular nerves which are in the way of thorough clearing of the axilla are sacrificed, unless they can be temporarily displaced. (8) Reflect mamma, with pectoral muscles and adherent axillary contents, outward and sever them from thorax in one continuous mass by a few sweeps of the knife along the outer primary incision. (9) Lower secondary incisions are now made, and the cutaneo-areolar flaps represented by them are raised by undercutting, and are ready to be shifted inward. (10)

Margins of original primary incisions, together with the margins of the flaps raised for that purpose, are approximated by suture, so as to entirely, if possible, cover in the whole wound and secure primary union. (11) Temporary horsehair or gauze drainage is used for twenty-four hours. (12) Voluminous dressings, including binding of arm to chest, are used.

Comment.—Whatever muscle tissue has been divided and not subsequently removed, should be repaired by chromic catgut suturing at the end of the operation. If indicated, the upper secondary incision may be continued above the clavicle and the supraclavicular glands removed from the posterior cervical triangle.

ORDINARY EXCISION OF MAMMARY GLAND

BY ELLIPTICAL INCISION.

Description.—Breast is circumscribed by an elliptical incision, with a straight continuation outward to the center of the axilla, and another straight

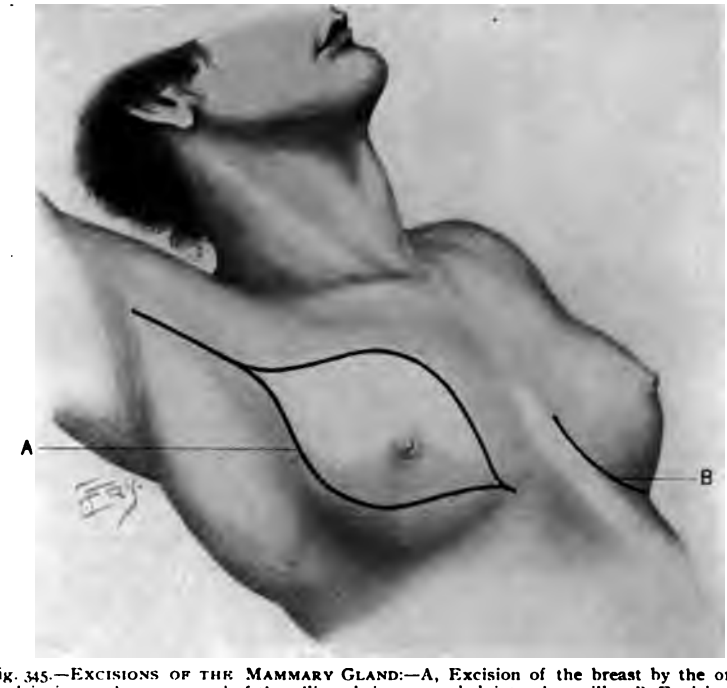

Fig. 345.—Excisions of the Mammary Gland:—A, Excision of the breast by the ordinary elliptical incision, the upper end of the ellipse being extended into the axilla; B, Excision of the breast subcutaneously, by an inferior curved incision.

incision continued downward toward the sternum. Mamma is simply dissected from pectoralis major muscle. Axilla is not invaded unless glands are felt through upper end of wound, and, if so, these glands are removed by blunt dissection through a limited exposure of axilla.

Preparation.—Same as for Radical Excision (page 582).

Position.—Same as for Radical Excision (*q. v.*). Or patient's hand may be placed behind nape of neck. Surgeon may stand on side of operation, cutting from above downward on right, and from below upward on left; or

may stand on right side for either breast, leaning over thorax and cutting from above downward when operating on left side.

Landmarks.—Same as for Radical Excision (*q. v.*).

Incision.—An elliptical incision is made, with its long axis parallel with anterior axillary fold (with arm in above position); its center corresponding with nipple; its width regulated by size of breast (or tumor); its upper and lower angles being just beyond the mamma. The ellipse itself does not extend the full length of the incision. From the upper angle of the ellipse a straight incision is carried up to opposite the center of the axilla. From the lower angle of the ellipse another straight incision is also carried downward a short distance below the breast. (See Fig. 345, A.)

Operation.—(1) Keeping parts tense by left hand, the full length of the incision, including upper curve of ellipse, is completed at one stroke. The lower curve of the ellipse is made with a second stroke of the knife, joining the straight portions of the first incision at upper and outer and at lower and inner circumference of breast, respectively. Incise through skin and superficial connective tissue throughout. (2) Having clamped bleeding vessels, the incision is carried down to pectoral muscle along upper line of ellipse, while skin above is drawn upward by assistant and breast downward by surgeon's left hand, the incision passing well above the upper limit of the breast. (3) Drawing breast away from thoracic wall, surgeon frees it from pectoralis major, beginning along the upper line. (4) Assistant now draws breast upward, and surgeon, retracting skin downward with left hand, cuts down to thoracic muscles along lower line of ellipse, the incision passing well below the lower limit of the breast. (5) While under traction, the connective tissue of breast to thorax is now severed toward its axillary aspect, together with the vascular connections, which are the last cut, and the breast thus freed from chest. All vessels cut are at once clamped, and clamped in advance of section, where possible. The pectoralis major is left bare. (6) Right index-finger is inserted into axilla through upper end of wound and enlarged glands felt for. If none be found, axilla is not opened up further. (7) If enlarged axillary glands be felt, the incision is continued upward into armpit, the axillary space exposed, and the glands removed with as little disturbance and damage to neighboring tissues as possible, and generally by blunt dissection. (8) Margins of wound, even the elliptical portion, are generally capable of being brought into apposition, and are sutured throughout. (9) If temporary drainage be indicated, it is provided for at the lower angle of wound. Abundant dressing is applied and arm bound to side.

Comment.—Where breast is involved by small innocent tumor, merely the elliptical portion of the above incision is used, the straight portions extending above into axilla and below toward sternum being omitted.

SUBCUTANEOUS EXCISION OF MAMMARY GLAND

BY INFERIOR CURVED INCISION.

Description.—Through a curved incision made in the inferior mammary fold, the breast is turned upward and dissected (enucleated) in whole or in part from out of its overlying capsule of skin and fascia, generally leaving the nipple intact. Indicated in non-malignant conditions for partial or complete removal of the mamma.

Preparation—Position.—Same as for Radical Excision.

Landmarks.—Inferior mammary fold (at junction of lower circumference of breast with chest-wall).

Incision.—Curved incision passing around beneath the lower margin of breast in the mammary fold, extending sufficiently far up on either side to enable breast to be turned upward and backward. (See Fig. 345, B.)

Operation.—Incise through skin and fascia down to pectoral fascia. Having gotten between the deep layer of the superficial pectoral fascia and the sheath of the pectoralis major, the breast is readily detached by blunt dissection and turned upward and outward—and then freed from its cutaneo-areolar covering from behind forward. The nipple is left, if possible, to lessen disfigurement. All bleeding vessels are ligated with gut. The remaining portion of the breast, if any, is returned to its normal site (otherwise the cutaneo-areolar capsule of the enucleated breast is turned back into place) and the margins of the wound are carefully sutured to avoid scarring. No drainage is used. A snug dressing is applied, to obliterate dead spaces.

III. THE SUPERIOR MEDIASTINUM.

SURGICAL ANATOMY.

Description.—The mediastinum is the region of the thoracic cavity between the pleuræ laterally, and the thoracic walls anteriorly and posteriorly. That portion above the upper level of the heart is the superior mediastinum. That portion below the upper level of the heart is divided into anterior, middle, and posterior mediastina, the anterior being in front of the heart, the posterior behind the heart, and the middle enclosing the heart.

Boundaries of Superior Mediastinum.—Anteriorly, manubrium sterni. Posteriorly; bodies of first, second, third, and fourth dorsal vertebræ. Laterally; pleuræ. Superiorly; upper opening of thorax. Inferiorly; plane passing horizontally backward from manubrio-gladiolar junction to lower portion of body of fourth dorsal vertebra—nearly coinciding with upper portion of pericardium.

Contents of Superior Mediastinum.—Origins of sternohyoid and sternothyroid, and lower ends of longi colli muscles; transverse arch of aorta; innominate, thyroidea ima, left carotid, and left subclavian arteries; innominate, superior vena cava, and left superior intercostal veins; pneumogastric, left recurrent laryngeal, phrenic, and cardiac nerves; trachea; esophagus; thoracic duct; thymus gland, or its remains; bronchial lymphatic glands; superior sterno-pericardiac ligaments.

SURFACE FORM AND LANDMARKS.

The planes limiting the upper and lower boundaries of the superior mediastinum are, respectively, those corresponding with the upper opening of the thorax above, and the junction of the manubrium and gladiolus below.

GENERAL SURGICAL CONSIDERATIONS.

The superior mediastinum (as well as the anterior and middle mediastina) is exposed in the operation of anterior mediastinal thoracotomy (page 588). It is also exposed in the operations upon the innominate artery, in excisions of the sterno-clavicular articulation and of the manubrium.

IV. THE ANTERIOR MEDIASTINUM.

SURGICAL ANATOMY.

Boundaries.—Anteriorly; all of gladiolus sterni, with parts of left fourth, fifth, sixth, and seventh costal cartilages. **Posteriorly;** pericardium. **Laterally;** pleuræ.

Contents.—Origin of triangularis sterni muscle; areolar tissue; lymphatic vessels and glands (anterior mediastinal glands); thymus gland (or its remains); inferior sterno-pericardiac ligaments.

ANTERIOR MEDIASTINAL THORACOTOMY

BY LONG MEDIAN INCISION—MILTON'S OSTEOPLASTIC ANTERIOR MEDIASTINOTOMY.

Description.—Exposure of the superior, anterior, and middle mediastina through a temporary longitudinal division of the sternum in the median line. (The posterior mediastinum may also be reached, in part, by this incision, but is better approached by a separate operation.) Resorted to for gaining very free access to the entire contents of the mediastina mentioned, especially for the removal of anterior mediastinal growths and pus,—the esophagus, trachea, and bronchi being more readily reached and treated from behind (Posterior Mediastinotomy).

Preparation.—Beard and presternal hair shaved, if necessary.

Position.—Patient supine, shoulders elevated, head supported, neck prominent—Surgeon to right—Assistant opposite.

Landmarks.—Median line of neck and sternum; thyroid cartilage; ensiform cartilage.

Incision.—From lower part of thyroid cartilage to base of ensiform cartilage, made in median line of neck and sternum. (The cervical portion of the incision is to give room for the lateral retraction of the split sternum.) (See Fig. 346, A.)

Operation.—(1) Incise through the skin and superficial connective tissue along the neck—and down to the bone over the full length of the sternum. Clamp or ligate superficial vessels. (2) Deepen the cervical incision by retracting the sternohyoid and sternothyroid muscles and dividing the deep cervical fascia, controlling all vessels encountered. The trachea is thus exposed from the thyroid cartilage to the episternal notch, except that the isthmus of the thyroid gland is not divided. If necessary, it may be divided between two ligatures. Expose the episternal notch by separating the fascia from it outward on either side to the origins of the sternomastoids. (3) Free the posterior surface of the manubrium sterni downward as far as possible, by means of curved periosteal elevator and finger, depressing the important structures downward. The more nearly this is done subperiosteally, the greater the protection to the soft parts adjacent. (4) By means of a thin, special saw, divide the sternum longitudinally in the median line, from above downward—dividing it through its entire thickness above, where the saw-teeth can be protected by a thin metallic guide or spatula slipped behind the upper portion of the sternum—but dividing it elsewhere, at first, very nearly but not quite through, and not extending the division below the base of the ensiform cartilage. (5) Detach the ensiform cartilage from the gladiolus by stout, curved, blunt scissors or bone-forceps, avoiding the neighboring structures of importance, especially the peritoneum. (6) Grasp the margins of

the sawed sternum on both sides by means of broad retractors with teeth—and steadily and carefully draw the divided bones apart by outward and slight upward traction. Draw the ensiform cartilage downward. Pass a director or thin spatula upward, inserting it between the lower end of the gladiolus and the disconnected ensiform cartilage, hugging the posterior surface of the lower portion of the gladiolus—and, upon this protector, complete the division of the lower part of the gladiolus by means of the special saw or bone-cutting forceps, working from below upward. (7) The bony division having been completed, additional traction is made upon the divided edges of the sternum, the separation being started by prizing the split sides of the sternum asunder with some stout, blunt instrument—detaching by

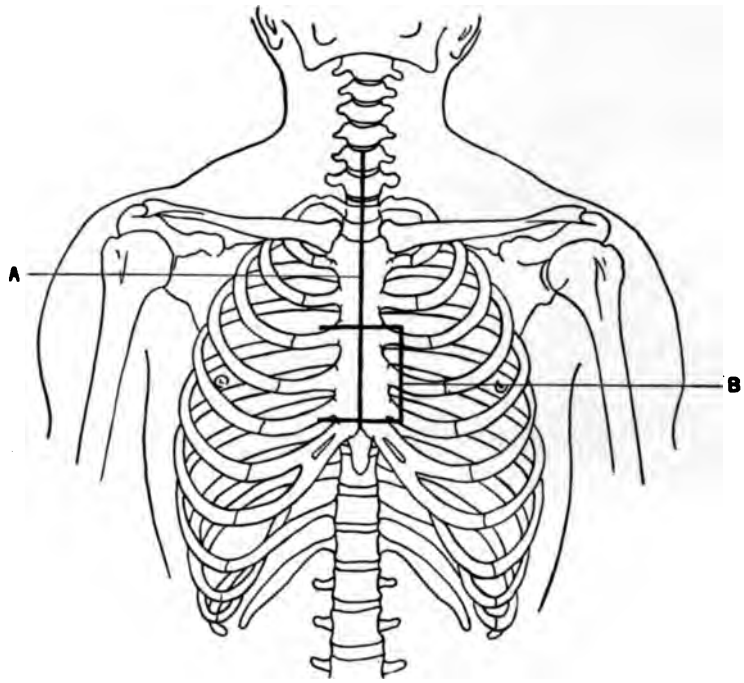

Fig. 346.—INCISIONS FOR EXPOSING THE MEDIASTINA:—A, Milton's anterior mediastinal thoracotomy, for exposing the superior, anterior, and middle mediastina; B, Incision for anterior mediastinal thoracotomy by an osteoplastic resection of the part of the sternum corresponding with the third, fourth, and fifth costal cartilages (exposing the anterior and middle mediastina).

blunt dissection all binding tissues, or dividing them with scissors, as soon as revealed by the gradual separation of the parts, and, where necessary, taking renewed holds upon the edges of bone with the retractors, as the gap increases. (8) An interval of between 5 and 8 cm. (about 2 to 3 inches) is thus ordinarily attainable. Through this opening the contents of the superior, anterior, and middle mediastina are readily reached—and even the posterior mediastinum may also, though of course less easily, be thus reached on the right side, after separating the pericardium and pleura. The further steps of the operation will depend upon the object for which performed—but, in any case, should be carried on with exceptional care, owing to the unusually important nature of the parts involved, and should be done chiefly by means

of blunt dissection. (9) At the close of the operation, the edges of the sternum are approximated by four to six silver-wire sutures passed through drill-holes —gauze or other drainage having been temporarily introduced behind the sternal notch and below the lower end of the gladiolus—and the skin wound closed except opposite the drainages.

Comment.—The pleura and peritoneum are both in great danger of injury—wounds of these should be immediately closed by circular ligation of their mouth, if small; and by suture, if large.

The principal tissues which interfere with the separation of the parts are those about the left innominate vein, crossing behind the manubrium sterni, in the line of the division, above; and about the ensiform cartilage below.

Especial care is necessary as to respiration, due to collapse of lungs, and a Fell-O'Dwyer instrument should have been provided previously for maintaining artificial respiration. Costal breathing ceases with division and separation of the sternum, though the lungs may not collapse on that account alone. In special cases where dyspnœa may be anticipated, a preliminary tracheotomy is sometimes done.

ANTERIOR MEDIASTINAL THORACOTOMY

BY OSTEOPLASTIC RESECTION OF PART OF STERNUM CORRESPONDING WITH THIRD, FOURTH, AND FIFTH COSTAL CARTILAGES.

Description.—The anterior mediastinum, and also the middle mediastinum, may be exposed by the osteoplastic resection of that portion of the sternum corresponding with the third, fourth, and fifth costal cartilages—which portion is temporarily turned back, exposing a large part of the anterior and middle mediastina and their contents. This operation is less extensive and severe than Milton's, and is indicated where a more limited exposure will suffice—especially for the removal of glands, small growths, evacuation of pus; and for the exposure of the heart and pericardium in the treatment of wounds and evacuation of pus.

Preparation.—Chest-wall shaved, if necessary.

Position.—Patient supine, chest elevated and resting upon some object which will render the anterior thoracic aspect prominent. Surgeon on left. Assistant opposite.

Landmarks.—Gladiolus sterni, between chondro-sternal articulations of third, fourth, and fifth costal cartilages; line of internal mammary artery (see page 59).

Incision.—(1) Upper transverse incision passes on a level with the upper border of third costal cartilages, not extending more than 1.2 cm. (about ½ inch) beyond either sternal border (to avoid the internal mammary artery). (2) The lower transverse incision passes similarly on a level with the lower border of the fifth costal cartilages, between points about 1.2 cm. (about ½ inch) beyond the sternal borders. (3) The vertical incision joins the left ends of the two transverse incisions, passing down between the left internal mammary artery and the left margin of the sternum. These incisions outline three sides of a square, having the hinge of the flap at the right margin of the sternum. (See Fig. 346, B.)

Operation.—(1) Incise through skin, fascia, and fibers of the pectoralis major, down to the sternum and intercostal membranes, using care over the intercostal spaces that the knife does not penetrate the thorax. Clamp and ligate the superficial vessels cut along the lines of incision—but do not separate the skin and fascia from the sternum. (See Fig. 347.) (2) The costal

cartilages are well exposed where the vertical incision crosses them and are divided with blunt-pointed cartilage-pliers with great care, to avoid injury to pleura and pericardium. This having been done, the left margin of the sternum, thus freed of its third, fourth, and fifth cartilages, is now drawn slightly forward with toothed retractor, and, while held in this position, the posterior surface of that portion of the sternum is freed of triangularis sterni muscle and connective tissue by means of a slightly curved periosteal elevator. (3) The sternum is now divided where the upper and lower transverse incisions cross it—and this is best accomplished, in those cases where it has been possible to clear the posterior surface of the sternum entirely across to the opposite border, by means of a Gigli saw conducted beneath the sternum, with which the section is readily made. In other cases the section may be made (though with less neatness and precision and more danger) by means of stout, curved, blunt-pointed, bone-cutting pliers, the lower blade hugging the sternum closely. (4) This section of the sternum having been freed upon



Fig. 347.—Anterior Mediastinal Thoracotomy, by an Osteoplastic Flap Consisting of Soft Parts and Sternum Corresponding with Third, Fourth, and Fifth Costal Cartilages:—A, Osteoplastic flap turned to left; B, Pectoralis major muscle; C, C, Intercostal arteries; D, Costal cartilage divided by instrument; E, Costal cartilage partly broken in hinging back the flap; F, F, Drill-holes; G, Triangularis sterni muscle; H, H, Lungs and pleuræ, the latter extending further toward the middle line; I, Heart and pericardium.

three of its sides, its posterior surface having been cleared, and with the soft parts still adherent to its anterior surface, it is now to be partly turned, partly broken back upon the structures along its right margin, as upon a hinge, the costal cartilages generally snapping in part or entirely, though sometimes bending. (5) The anterior mediastinum, and also the middle mediastinum (although of course less fully), are now exposed—and their contained structures may be reached by gentle manipulation and blunt dissection—and the special object of the operation accomplished. (6) At the close of the operation, the osteoplastic flap is turned back into place. It is well to drill holes (two above and two below) for chromic gut ligatures, or silver wire, along the upper and lower transverse divisions of the sternum, before replacing the flap (holding the detached piece of sternum with strong bone-forceps while drilling; and protecting the inferior surfaces of the margins of the upper and lower intact pieces)—and tightening the sutures when the piece is in place.

If thought necessary, the costal cartilages may be similarly drilled and tied on either side of the line of section. (7) Temporary drainage should be provided—which may be done by excising a small portion of one of the costal cartilages at its articulation with the sternum, as well as a limited portion of the margin of the sternum at that point, in the form of a semicircle. The skin-portion of the osteoplastic flap is sutured throughout most of its extent, leaving an opening for drainage.

Comment.—Instead of the above window opening laterally upon a vertical hinge, one may be (though less easily) formed opening upward or downward upon a transverse hinge across the sternum, by making two vertical incisions just outside of the borders of the sternum and the transverse incision on a level with the lower border of the fifth costal cartilage (where the hinge is to be above).

The window may be placed higher or lower than indicated in the above operation.

OTHER OPERATIONS UPON THE ANTERIOR MEDIASTINUM.

See all operations upon the Heart and Pericardium—which, lying in the middle mediastinum, are reached through the anterior mediastinum.

V. THE MIDDLE MEDIASTINUM.

SURGICAL ANATOMY.

Boundaries.—Anteriorly; limits of anterior mediastinum. **Posteriorly;** limits of posterior mediastinum. **Laterally;** pleuræ.

Contents.—Heart and pericardium; ascending aorta; pulmonary artery and its two branches; arteries of the phrenic nerves; superior vena cava; right and left pulmonary veins; vena azygos major; phrenic nerves; roots of lungs; bifurcation of trachea; two bronchi; bronchial lymphatic glands.

OPERATIONS UPON THE MIDDLE MEDIASTINUM.

For operations upon the Middle Mediastinum, see operations upon the Heart and Pericardium (pages 614 and 619).

For other operations exposing the Middle Mediastinum, see operations upon the Anterior Mediastinum (pages 588 to 592).

For operations upon the thoracic esophagus and trachea and upon the bronchi, see Posterior Mediastinal Thoracotomy (page 593)—the first being in the Posterior Mediastinum—the last two in the Middle Mediastinum, but best reached through the Posterior Mediastinum.

VI. THE POSTERIOR MEDIASTINUM.

SURGICAL ANATOMY.

Boundaries.—Anteriorly; pericardium; roots of lungs. **Posteriorly;** vertebral column (below inferior border of fourth dorsal vertebra). **Laterally;** pleuræ.

Contents.—Descending aorta; greater and lesser azygos veins; pneumogastric nerves; splanchnic nerves; esophagus; thoracic duct; posterior mediastinal lymphatic glands.

POSTERIOR MEDIASTINAL THORACOTOMY

BY THORACOPLASTIC FLAP—BRYANT'S OPERATION.

Description.—Exposure of the posterior mediastinum by means of an osteoplastic flap about 8 to 10 cm. (about 3 to 4 inches) square, and generally including the width of three ribs raised over the site of the operation—part of the central rib being permanently sacrificed from angle to outer end of transverse process, and similar parts of the other two returned. Usually performed for the removal of foreign bodies in the esophagus, trachea, and bronchi, and for the evacuation of pus. Some of the more posterior contents of the middle mediastinum are thus also accessible from this opening.

Position.—Patient partially upon side and chest, with the side of operation uppermost, and resting upon some object in order to increase the width of the intercostal intervals at the site of operation. The scapula is drawn forward to increase the interval between the vertebræ and the vertebral border of the scapula. Surgeon on side of operation. Assistant opposite.

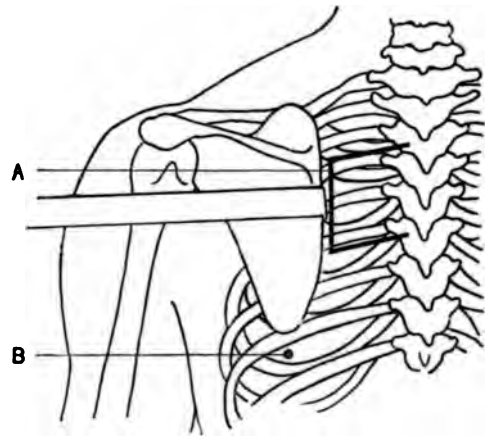

Fig. 348.—OPERATIONS UPON THE THORACIC CAVITY: —A, Posterior mediastinal thoracotomy, by thoracoplastic flap; B, Position for paracentesis thoracis in the eighth intercostal space in the line of the inferior angle of the scapula. The scapula is here represented retracted slightly outward, to increase working-space between vertebræ and scapula in the removal of parts of the fourth, fifth, and sixth ribs.

Landmarks.—Position of upper ribs; spinous processes of upper dorsal vertebræ, with corresponding ribs; vertebral border of scapula; root of spine of scapula (which generally corresponds to the interspace between third and fourth dorsal spines). The site of the operation is determined by the position of the foreign body to be removed. Parts of three ribs are generally included in the operation, the central one being at the center of the field. Somewhat readier access is gotten to the esophagus from the left side, though at the level of the usual operation the esophagus is practically in the middle line. The trachea usually bifurcates opposite the fourth dorsal vertebra (sometimes the fifth). Where the site of the operation cannot be previously determined, the left fourth, fifth, and sixth ribs are generally chosen.

Incision.—In the form of three sides of approximately a three-inch square—the fourth side being represented by the spinous processes of the vertebræ. This area is so placed as to have its center over the central one of the three ribs to be removed—the upper and lower parallel incisions passing above and below the other two ribs respectively. (See Fig. 348, A.)

Operation.—(1) Incise the three sides of the outline indicated above, through skin, fascia, and muscles down to the ribs, carefully avoiding penetrating the intercostal spaces. Clamp all cut vessels. Free up the thick flap of soft parts from the ribs and turn it over the spinous processes to the opposite side. Ligate the previously clamped vessels, and others as exposed.

(See Fig. 349.) (**2**) Make a longitudinal incision over the center of the outer aspect of the central one of the three ribs, through the periosteum, from the outer end of the transverse process of the vertebra to the angle of the rib—free it subperiosteally with curved periosteotome (or by a piece of silk conducted between bone and periosteum)—pass a Gigli saw between rib and periosteum, guarding the pleura, and remove the portion of rib above indicated, and discard. (**3**) The inner and outer ends of the exposed portions of the upper and lower ribs are now similarly exposed subperiosteally, without

Fig. 349.—Posterior Mediastinal Thoracotomy, by Thoracoplastic Flap:—A, Skin and muscle flap turned horizontally backward; B, Flap of part of fourth rib and intercostal muscles turned upward; C, Flap of part of sixth rib and intercostal muscles turned downward; D, D, Vertebral ends of fourth and sixth ribs, drilled for wiring; E, Intercostal artery, vein, and nerve; F, F, F, Fourth, fifth, and sixth dorsal nerves exposed and retracted; G, Pleura and lung; H, Broad retractor displacing pleura and lung; I, Thoracic aorta; J, Left bronchus; K, Esophagus protruded into wound by sound introduced through mouth. The operations of Bronchotomy and Thoracic Esophagotomy are shown at J and K, respectively. The pulmonary and bronchial vessels are omitted, for clearness.

freeing the intervening portions more than can be helped, and especially without isolating the upper rib from its upper attachment and the lower rib from its lower attachment. Two holes are drilled at either end of the yet undivided ribs for future wiring. Both ribs are then divided between the pairs of drilled holes, by means of a Gigli saw. (**4**) The intercostal arteries in the field are now ligated at the inner and outer side of the wound. The intercostal nerves are carefully retracted throughout the operation, it being unnecessary to divide them. The periosteum forming the bed of the central

rib is now very carefully divided lengthwise of its course. Through this opening the pleura is carefully detached and is further separated by the finger from the muscular and bony wall of the thorax corresponding to the extent of the wound, the separation being accomplished during expiration. At either side of the wound, in line with the divided ribs, the remaining chest-wall is divided while the pleura beneath is carefully guarded by an instrument or the finger. These two vertical incisions last made, crossing the transverse one through the bed of the middle rib's periosteum, make, by an H-shaped incision, two small flaps—the upper one, containing the upper rib as extensively adherent as possible (for nutrition), is now turned upward upon its hinge of soft parts—and the lower one, with the lower rib similarly attached, is turned downward in like fashion—care being taken not to injure the intercostal vessels and soft tissues above the upper rib, nor below the lower rib. (5) The posterior mediastinum is thus exposed—and its contents, as well as some of the more posteriorly situated contents of the middle mediastinum, are accessible after careful separation of important structures by means of blunt dissection, instrumental retraction, and the use of the fingers. The pleura, especially, is carefully pushed externally out of the way and so guarded as to avoid opening it. The trachea, bronchi, and esophagus may be both felt and seen. The important vessels of the posterior and middle mediastinum (see Surgical Anatomy) are to be carefully guarded. When trachea, bronchi, or esophagus are to be opened, they are incised, after being steadied with toothed forceps, in their longitudinal axis—and subsequently not sutured—but the wound packed down to the incised tube, for the escape of all drainage through a drainage-tube placed in the center of the gauze packing. (6) In completing the operation, the middle one of the three ribs is not replaced—the upper and lower ribs are turned back into place and wired (or sutured with chromic gut) through the previously drilled holes. The drainage will pass out of chest through the incision in the bed of the middle rib—and will escape externally through a convenient opening left beneath the skin and muscle flap which is only partially stitched into place.

Comment.—(1) The scapula should be displaced forward out of the way, and so held by an assistant. (2) It might be better to plan the skin incision on a somewhat larger scale (say 2.5 cm., or about 1 inch, larger) so that the skin suture-line would not directly coincide with the bone-sections. (3) All bleeding should be controlled as encountered—first by clamp, then by ligature. (4) The pleura is to be widely separated around the margin of the opening by the finger—to enable freer displacement of the mediastinal contents. (5) Below the arch of the aorta the esophagus is more readily reached from the right—above the arch, it may be reached from either side, although somewhat better from the left. (6) Removal of a body from the esophagus below the body of the ninth dorsal vertebra is very difficult and hardly justifiable. (7) The left bronchus is reached with greater difficulty and risk of hemorrhage.

VII. THE DIAPHRAGM.

SURGICAL ANATOMY.

Attachments of Diaphragm.—Anterior (sternal) part; inferior and posterior border of ensiform cartilage; neighboring posterior surface of anterior aponeurosis of transversalis muscle. **Lateral (costal) part;** inferior border and inferior surface of the cartilages and bony parts of the sixth or

seventh inferior ribs. **Posterior (vertebral) part; (a)** ligamentum arcuatum externum (the thickened anterior layer of lumbar fascia extending from tip of transverse process of second lumbar vertebra to tip of twelfth rib); **(b)** ligamentum arcuatum internum (the thickened iliac fascia arching over the psoas, from the side of body of second lumbar vertebra to tip of transverse process of same vertebra). **(c)** right crus of diaphragm (arising from anterior surface of bodies of first to third, or fourth, lumbar vertebra; from intervening fibro-cartilages; from anterior common ligament); **(d)** left crus of diaphragm (arising from anterior surface of bodies of first to second, or third, lumbar vertebra; from intervening fibro-cartilages; from anterior common ligament). **The insertion** of these various origins is into the anterior, posterior, and lateral aspects of the central tendon of the diaphragm.

Structures in Relation with Diaphragm.—Superiorly (thoracic cavity); pleuræ and lungs; pericardium and heart. **Inferiorly** (abdominal cavity); peritoneum; liver; stomach; spleen; pancreas; kidneys; suprarenal capsules.

Upper Limits of the Diaphragm.—Right Leaflet, on level with junction of fifth costal cartilage with sternum (about 2.5 cm., or 1 inch, below the nipple). Left Leaflet, on level with junction of sixth costal cartilage with sternum. Central Tendon, about on level with end of sternum, or seventh chondro-sternal articulation.

Boundaries of Lower Thoracic Opening.—See Thoracic Wall, page 576.

Structures Passing through Floor of Thorax (Diaphragm).—See Thoracic Wall, page 576.

Other Relations of Diaphragm.—(a) The fibers of diaphragm are absent or deficient in the interval between the sides of the muscular strip from ensiform cartilage to cartilages of neighboring ribs—areolar tissue occupies this position, covered above by pleura, and below by peritoneum. **(b)** The central tendon of the diaphragm is blended with the pericardium. **(c)** After forced expiration, the right diaphragmatic arch is on a level, anteriorly with fourth costal cartilage; laterally, with fifth, sixth, and seventh ribs; posteriorly, with eighth rib; similar measurements on left generally being from one to two ribs' width lower. In forced inspiration, there is a descent of from 2.5 to 5 cm. (about 1 to 2 inches). **(d)** Circumferentially, the diaphragm is higher in the median line, and lower at the sides—but the central tendon supporting the heart is lower than the sides. **(e)** For a narrow interval around the lower and posterior circumference, the diaphragm is not covered by pleura, but is in immediate contact with the chest-wall. **(f)** The costo-phrenic sinus is that area over which the parietal and visceral layers of the pleura are in constant contact, whether in inspiration or expiration—and is represented by the line of reflection of the diaphragmatic pleura onto the intrathoracic wall.

TRANSTHORACIC EXPOSURE OF DIAPHRAGM

BY PARTIAL EXCISION OF TWO OR THREE RIBS.

Description.—The upper (thoracic) surface of the diaphragm is exposed (at the site of the diaphragmatic lesion) by means of the partial excision of two or three ribs performed subperiosteally, through a single incision between them. Or the site may be exposed by turning back a flap of overlying soft parts and then excising the indicated parts of the ribs,—or an osteo-thoraco-plastic flap may be temporarily turned aside and replaced at the end of the

operation. (See operations upon the pleura and heart.) Having opened the chest-wall over the area, the diaphragm may be approached in one of several ways—below the reflection of the pleura,—subpleurally (after detaching and pressing back the unopened pleura),—transpleurally (the pleuræ being non-adherent),—or through adherent pleural surfaces. Indicated for the evacuation of pus in subphrenic abscess; for the repair of wounds of the diaphragm; for hernia through the diaphragm. In subphrenic abscess, the approach is usually made by the lumbar, iliac, or lateral thoracic routes, in order of preference—parts of the ninth and tenth ribs being incised in simple subphrenic abscess—and part of the eighth if the pleura be involved. The site of the operation may be on either side and will be determined by the lesion and the physical signs. Generally from 7.5 to 10 cm. (about 3 to 4 inches) of the ninth and tenth ribs, between the anterior axillary and scapular lines,

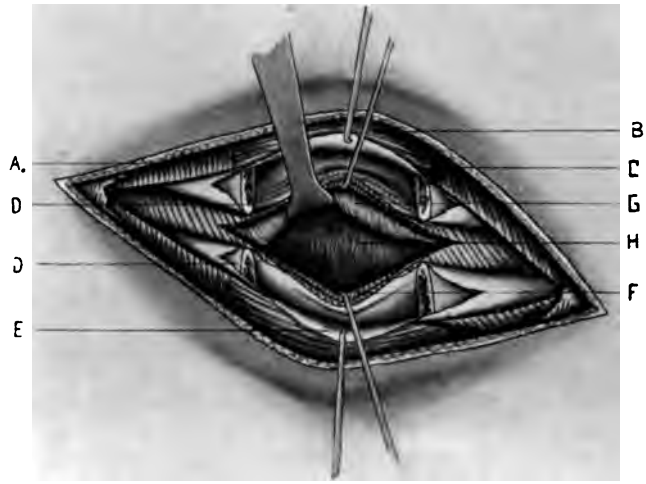

Fig. 350.—Transthoracic Exposure of Diaphragm through the Right Ninth Intercostal Space:—A, Latissimus dorsi muscle; B, Serratus magnus muscle; C, Obliquus externus abdominis muscle; D, D, Resected ends of ninth and tenth ribs, the periosteal bed extending between the exposed ends, the intercostal vessels and nerves showing through the periosteum; E, Anterior layer of periosteum retracted and everted; F, Posterior layer of periosteum, together with external and internal intercostal muscles, retracted; G, Pleura displaced upward; H, Diaphragm.

as indicated, are excised through a single incision made between them, in the case of an abscess between the liver and diaphragm, which is usually approached subpleurally. Where the abscess is near the dome of the diaphragm, the transpleural approach at a higher level generally must be used. The excision of one or more costal cartilages in the mammary line may suffice.

For operations for hepatic abscess and empyema, see Operations upon the Liver and Pleura.

Position.—Determined by the lesion—and will be such as to conveniently expose the area—in this case in the semi-prone position.

Landmarks.—Site of lesion; line of pleura; line of diaphragm.

Incision.—In the center of the interspace between the ninth and tenth ribs—the center of the incision being midway between the anterior axillary and scapular lines—and about 13 cm. (about 5 inches) in length, so as to provide for the removal of about 9 cm. (about 3½ inches) of each rib.

Operation.—(1) Incise through skin, fascia, and overlying thoracic muscles, down to the plane of intercostal muscles, clamping all bleeding vessels. Free back the upper and lower lips of the wound upon this same plane, until the ninth and tenth ribs are reached and exposed in their entire width—the soft parts being retracted well above and below their limits. (2) Subperiosteally excise about 9 cm. (about 3½ inches) of each rib, in the usual manner (see the Subperiosteal Excision of the Ribs, page 447)—carefully guarding the parietal pleura from the slightest nicking or injury (Fig. 350). (3) Incise the intercostal tissues longitudinally in the center of the interspace between the two excised ribs. If necessary, the intercostal arteries of the excised ribs may be ligated at both ends, though this may be omitted generally, as they are usually not in the way unless it be indicated to carry an incision across their course. Preserve the intercostal nerves by retraction. The removal of these two ribs generally gives ample room for exposure when the upper and lower limits of the wound are well retracted. (4) Five methods of reaching the diaphragm are now open to the operator; (a) If the site of operation be below the level of the reflected pleura, where the diaphragm and chest-wall are in contact, the diaphragm may be approached at once,—(b) If the pleura be encountered as soon as the chest-cavity is opened, its parietal layer should be most carefully detached with the fingers and by means of blunt dissection and peeled back from its connection with the endothoracic fascia and surface of the diaphragm—peeling it backward with the tips of the fingers and constantly pushing it from the freed area with the back of the fingers—continue this freeing back of the unopened pleura until the site of the diaphragmatic operation is reached—and then hold the pleura in place by gauze packing,—(c) If both surfaces of the pleura are found adherent, thus shutting off the general pleural cavity, the incision may be carried directly down to the diaphragmatic site without danger of entering the pleural cavity (unless the adhesions be pulled apart in the manipulations), —(d) If the two pleural surfaces are not adherent, and it be impracticable to detach the pleura as described under (b), the two pleuræ may be united by suture around an area sufficiently large to admit of operating within and thus reaching the diaphragm at once. (e) If the two pleural layers be found not in contact by adhesion, and cannot be separated and displaced upward as mentioned under (b), and if time be to spare, adhesion between the two surfaces may be brought about by gauze packing, with the accomplishment of the rest of the operation two or three days later, when the cavity will have been closed off by adhesions. Where it is possible to choose the route, it is better to approach the diaphragm either below the level of the pleural reflection—or to detach the unopened pleura and reach the diaphragm beneath the pleural cavity. (5) The surface of the diaphragm having been exposed, the special object of the operation is now accomplished—the abscess incised—the wounded diaphragm sutured—or the hernial opening closed—upon the same principles practised elsewhere. Owing to the constant movement of the diaphragm, it is somewhat more difficult to deal with its structure. An abscess cavity should be evacuated by the most direct route, especially guarding the pleural cavity from infection. If a newly made wound exist, it is sutured at once. If the wound be old, or the opening be a hernia, the edges are seized with toothed forceps to steady them and then freshened with curved blunt scissors—the moving lung being held out of the way, if necessary, by gauze packing—and with a fully curved needle, held in special needle holder, the margins of the wound or opening are brought together with chromic gut sutures. (6) The pleural sac, previously held

out of the way by packing, is now allowed to fall into place. Temporary drainage is established, if indicated, through an unsutured part of the external wound—the remaining portion of the outer wound being closed.

Comment.—(**a**) If the pleura be nicked, ligate or suture it at once. (**b**) If necessary to gain more room, free back the soft parts and excise the same amount of the rib above or below—especially is this the case when it is needed to reach the diaphragm nearer its dome. (**c**) A U-shaped flap, with base forward or backward, may be used to expose the ribs. (**d**) On the left side all calculations are made somewhat lower.

VIII. THE PLEURÆ.

SURGICAL ANATOMY.

Relations.—(1) **Pleura costalis** (Parietal Layer of Pleura); beginning at sternum, pleura lines thoracic cavity, covering inner aspect of costal cartilages, ribs, intercostal muscles—passing, posteriorly, over heads of ribs, thoracic ganglia and branches, lateral surfaces of bodies of dorsal vertebræ—thence to side of pericardium, which it partially covers—thence to root of lung, where it becomes pleura pulmonis. (2) **Pleura pulmonis** (Visceral Layer of Pleura); beginning at root of lung, pleura passes around posterior border, over convex outer aspect, from base to summit—over sides of fissures between lobes—around its anterior border—on to anterior aspect of root—thence upon pericardium to inner aspect of sternum. (3) **Pleura cervicalis;** apex of pleura closely covers apex of lung, projecting, with it, from 1.3 to 4.5 cm. (about $\frac{1}{2}$ to $1\frac{3}{4}$ inches) above the first rib—but not above level of neck of first rib. Subclavian artery arches over it, grooving its internal and anterior aspect just below its apex. Scalenus anticus and medius muscles are in contact with it externally. (4) **Pleura diaphragmatis;** covers superior surface of diaphragm, except narrow interval along its circumference, which is in contact with costal parietes. (5) **Pleura mediastinalis;** forms lateral boundaries of mediastina.

Relations of Margins of Pleuræ to Chest-wall.—(1) **Anterior margin;** extending from apex of lung, passes from sterno-clavicular articulation downward and inward, meeting opposite pleura at upper border of sternum—thence both pleuræ descend in contact to upper margin of fifth costal cartilages, whence they diverge. Right Pleura continues nearly vertically downward to lower end of gladiolus, thence turns outward. Left Pleura diverges from median line at upper margin of fifth costal cartilage, so as to be 1.5 cm. (about $\frac{5}{8}$ inch) to outer side of left border of sternum at level of sternal end of fifth costal cartilage—2 cm. (about $\frac{13}{16}$ inch) at level of sternal end of sixth—3.5 cm. (about $1\frac{3}{8}$ inches) at level of sternal end of seventh (Luschka). In many cases this deviation of left pleura is not so marked, the margin lying much nearer the median line. (2) **Lower margin;** reflected on to diaphragm along line extending from lower end of sternum outward behind seventh costal cartilage nearly to sternal end of rib. (Melsome says this margin follows lower border of sixth costal cartilage on left side.) The lower border of the pleura corresponds in height with the following structures at the following points:—In the Nipple line, with eighth rib,—In Mid-axillary line, with tenth rib on left, and ninth rib on right,—In Posterior Scapular line (vertical line from tip of inferior angle of scapula), with twelfth rib,—At Spine, with vertebral end of twelfth rib; sometimes with transverse process of first lumbar vertebra. The lower margin of the lung will correspond with a point two ribs higher in each case.

Attachments of Pleuræ.—(1) Ligamentum latum pulmonis, passes from lower portion of posterior part of root of lung to diaphragm—formed by two layers of pleuræ continuous above with the layers in front and behind root of lung. (2) Expansion of fascia covering and strengthening apex, and extending across from posterior border of first rib to anterior border of transverse process of seventh cervical vertebra—and further strengthened by few fibers of scalenus anticus. (3) Interpleural Ligament, passing between two pleuræ behind esophagus and in front of aorta.

Supplemental or Complemental Pleural Spaces.—These spaces are situations where two portions of parietal pleuræ are in contact, even during forcible inspiration—(1) Between Chest-wall and Diaphragm (Costo-phrenic sinus), where costal pleura is reflected on to diaphragm, best marked posteriorly, where costal and diaphragmatic parts of pleuræ are in contact from about tenth to twelfth ribs,—(2) Between Chest-wall and Pericardium on left, opposite lower portion of gladiolus.

Arteries.—From intercostal, internal mammary, musculophrenic, thymic, pericardiac, bronchial.

Veins.—Correspond with arteries.

Nerves.—From phrenic and sympathetic.

SURFACE FORM AND LANDMARKS.

The interval between the two pleuræ is considerable above and below, but opposite the gladiolus (second, third, and fourth costal cartilages) they are more nearly approximated, or are in contact.

The anterior margins of the two pleuræ are more nearly parallel and in a vertical line than the corresponding margins of the lungs, that is, the left anterior pleural margin extends further over the pericardium than does the lung.

The right pleura is shorter and wider than the left (owing to the liver), though it reaches slightly higher in the neck.

There is a tendency for the left pleura to extend lower down than the right—most markedly upon the lateral aspect of the chest-wall—somewhat so upon the anterior aspect—and even slightly so behind.

In some cases the pleura has extended into the abdomen, beneath the ligamentum arcuatum externum, and uncovered by diaphragm at this site.

The outer surface of the pleura is firmly adherent to the surface of the lung, to the pulmonary vessels emerging from the pericardium, to the upper surface of the diaphragm, and to the triangularis sterni—elsewhere it is less firmly adherent.

If the twelfth rib be well developed and full length, the pleura is generally in contact with only its inner half. If the twelfth rib be very short, the pleura may be in contact with all of its anterior surface—and the pleura may extend to the transverse process of the first lumbar vertebra.

The outer margin of the erector spinæ muscle cuts the twelfth rib about its middle. Where the twelfth rib is present and extends beyond the outer border of the erector spinæ, the lower border of that portion of the rib external to the border of the muscle can be cut upon with reasonable certainty of not opening the pleura. Where the twelfth rib is absent or short, the above is not available

Never take for granted that the last rib is the twelfth rib—always count from the first rib. If the twelfth were absent and one were to cut down

upon the eleventh (mistaking it for the twelfth), the pleura would almost certainly be opened.

Where the twelfth rib is absent or short, one may cut to within 2.5 cm. (about 1 inch) of the apex of the angle formed by the outer margin of the erector spinæ and the lower border of that portion of the eleventh rib projecting to the outer side of the muscle—that is, one should not cut higher than the position the twelfth rib would occupy if present (Melsome).

PARACENTESIS THORACIS.

Description.—Paracentesis thoracis (thoracentesis, or pleuracentesis) consists in the penetration of the pleural cavity by means of a hollow needle or cannula, for the purpose of exploratory aspiration or the evacuation of fluid.

Sites usually Selected for Thoracentesis.—Sixth (or seventh) intercostal space in the mid-axillary line; eighth (or ninth, especially on left) intercostal space in the posterior scapular line.

Position.—Patient supine at edge of table for lateral punctures—and rolled slightly forward for posterior punctures—with arm of affected side elevated above head (to widen intercostal spaces, and draw skin upward, which will subsequently come back into place valve-like over the opening). For simple puncture, if patient can sit upright in a chair, this position will better enable fluid to gravitate downward.

Landmarks.—Sixth (or seventh) intercostal space in the mid-axillary line—or the eighth (or ninth) space in the line of the inferior angle of the scapula. The posterior puncture secures better drainage. (See Figs. 352, C, and 348, B.)

Operation.—Having cocainized the part, grasp a needle, or cannula and trocar, so as to control its progress and limit the depth of the puncture —and having displaced the skin upward with the left thumb and forefinger, so as subsequently to form a valve—the point is entered nearer the upper than the lower border of the ribs limiting the special interspace (in order to escape the more important lower intercostal artery, while also missing the upper one)—and is made to pass inward and upward (so as to avoid wounding the lung and diaphragm)—passing through skin, fascia, thoracic muscles, intercostal muscles, endothoracic fascia, and parietal layer of pleura—its entrance into the free pleural cavity being recognized by the sensation imparted to the finger guarding its onward progress. When the needle, or cannula point, is felt to be within the pleural cavity, the contents are slowly withdrawn, the opening being subsequently sealed with sterilized cotton and collodion.

Comment.—Puncture may be made wherever physical signs indicate fluid within the area of the pleura—but the above sites are the most usual. The puncture may be preceded by a limited incision of the skin alone—or, if difficulty occur, the incision may extend down to the intercostal muscles. To avoid the intercostal arteries, the puncture should not be made posteriorly to the angle of the ribs.

INTERCOSTAL THORACOTOMY.

Description.—Intercostal thoracotomy, or pleurotomy, consists in the exposure and incision of the pleura in an intercostal space for the evacuation of fluid. A simpler though generally less satisfactory operation than thora-

cotomy through the partial excision of a rib, though often sufficient in minor cases.

Sites Usually Selected for Intercostal Thoracotomy.—In the sixth (or seventh) intercostal space in the mid-axillary line; in the eighth (or ninth, especially on the left) intercostal space in the posterior scapular line—*i. e.*, in the same sites as for paracentesis, avoiding a position in which the diaphragm or scapula would interfere with free drainage.

Position.—As for paracentesis thoracis—except that here the opening must not be valulvar, but, on the contrary, it is planned that the cutaneous and pleural openings are opposite.

Landmarks.—As for paracentesis thoracis.

Incision.—Midway between the two ribs, in the long axis of the intercostal space—extending about 5 cm. (about 2 inches) in a thin chest-wall, and about 7.5 cm. (about 3 inches) in a thick chest-wall—the center of the incision being, as above indicated, generally in the mid-axillary line for the sixth intercostal space, and in the posterior scapular line for the eighth interspace.

Operation.—(1) Incise through skin, fascia, external thoracic muscles (serratus magnus in sixth space; chiefly the latissimus dorsi in eighth space), and intercostal muscles down to the endothoracic fascia. Clamp and ligate all bleeding vessels encountered—the incision lying between the upper and lower intercostal arteries and not generally involving them. Retract the soft parts upward and downward, including the ribs bounding the space—and the parietal pleura is exposed. (2) The tense pleura is then deliberately incised in the axis of the intercostal space (not by stabbing)—preceded, if necessary, by an exploratory puncture—the opening being increased, if indicated, upon a grooved director, or with blunt scissors or blunt bistoury—and the fluid evacuated. (3) Drainage is then established by some form of not easily collapsible drain (to withstand the tendency of the adjacent ribs to narrow the opening). The ends of the external wound are sutured, leaving room for the exit of the drain.

Comment.—Where the incision can be made to the outer margin of the latissimus dorsi, lesser thickness of muscle presents.

THORACOTOMY BY PARTIAL EXCISION OF ONE OR MORE RIBS.

Description.—Exposure and incision of pleura through a thoracic opening made by the excision of parts of one or two (or more) ribs. Generally resorted to for the evacuation of intrapleural fluids where a larger opening is required than furnished by an intercostal thoracotomy. Part of one rib alone is generally excised—where more room is required part of the rib above or below, or both, may be excised. From 2.5 to 5 cm. (about 1 to 2 inches) of bone are ordinarily removed—and more if necessary.

Sites usually Selected for the Excision of Ribs.—Wherever a collection of fluid is indicated by physical signs (that is, determined by the physical signs of localized collection)—where the collection is a localized one. Where the fluid is in the free pleural cavity, the site generally chosen is the sixth or seventh rib in the mid-axillary line—or the eighth or ninth rib just external to the posterior scapular line—the latter situation usually being preferable. (Kocher gives the sixth rib in the mammary line—the ninth rib on the right, and the tenth on the left, in the lateral line—and the twelfth on both sides posteriorly in the scapular line.) But the position should be so chosen that

the drainage will not be interfered with by either diaphragm or scapula in the functioning of these structures.

Position.—As for Intercostal Thoracotomy (page 601).

Operation by Partial Excision of One Rib.—(1) An incision of about 8 cm. (about 3 inches) is made directly over the center of the chosen rib, passing through skin, fascia, overlying muscles, and periosteum. (See Fig. 351.) (2) The rib is then freed subperiosteally for nearly 5 cm. (about 2 inches), carefully avoiding injury to the intercostal vessels and pleura—which are in safety as long as the operation is subperiosteal. About 2.5 to 4 cm. (about 1 to 1½ inches) is now removed with a Gigli saw, as in the ordinary partial excision of a rib. (3) The intercostal vessels are then easily isolated in the bed of the rib, and are treated according to circumstances—they may be tied at both ends of the wound and divided, where they are likely to be

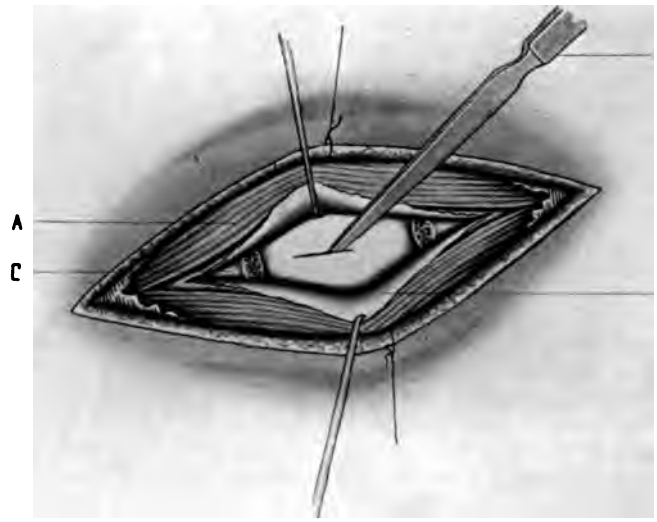

Fig. 351.—THORACOTOMY BY PARTIAL EXCISION OF A RIB:—A, Thoracic muscles divided down to rib, directly over its center; B, Periosteum raised and turned back, in the subperiosteal exposure of the rib; C, Transverse section of rib, indicating portion of rib removed by means of a Gigli or chain saw conducted between rib and periosteum; D, Knife incising through periosteal bed and endothoracic fascia into pleural cavity.

injured—or they may be left intact, the incision into the pleura being made between and parallel with the upper and lower intercostal vessels. (4) An incision of about 2.5 to 4 cm. (about 1 to 1½ inches) is now carefully made through the center of the periosteal bed and in the axis of the former rib, passing through the costal periosteum, endothoracic fascia, and parietal pleura into the pleural cavity—and drainage thus established—the drain used being so placed and of such a nature as not to impinge upon the lungs during respiration.

Operation by Partial Excision of Two or More Ribs.—(1) If it be found, after excising part of one rib, that it is desirable to excise part of the rib above or below, or both, add two vertical incisions to the horizontal one, extending from the ends of the former horizontal incision upward to the upper border of the rib above—or two vertical incisions extending downward

to the lower border of the rib below—or both. A flap of overlying soft parts may thus be turned upward or downward, or in both directions, exposing the two or three ribs—which are then partially excised just as a single rib in the above operation. (2) Where it is wished, from the first, to excise parts of two ribs—make an incision of about 10 cm. (about 4 inches) midway between the two ribs—passing through skin, fascia, and overlying muscles, down to the level of the outer surface of the ribs and intercostal muscles—then retract the upper lip of the wound upward until the upper rib is well exposed—and the lower lip downward until the lower rib is similarly exposed—incising muscle tissue, or separating by blunt dissection, in the approach toward the upper border of the rib below and the lower border of the rib above, maintaining an even thickness of soft covering everywhere. The ribs thus exposed are partially resected as in the single rib operation. (See Figs. 350 and 351.) (3) Where it is wished to excise parts of three ribs from the first, make an incision in the long axis of the middle one of the three ribs—join this by a vertical incision at either end of the transverse incision, from the upper border of the rib above to the lower border of the rib below (making an H-shaped incision)—and turn one flap upward and the other downward (as explained in (1) above). Parts of three ribs are then excised—the intercostal arteries are ligated at both ends—the nerves are retracted—and an incision made vertically in the center of the area. At the end of the operation, the external wound is closed along the lines of incision, except that drainage is provided for through an unsutured part of the wound. (4) Where more than part of a single rib is excised, the soft parts which intervene between the beds of the excised ribs, and including the beds, are carefully incised in a vertical direction, down to the endothoracic fascia—and the pleura is then incised in the same direction. Prior to this, the intercostal vessels corresponding to each rib are ligated at either end of the original wound, so that when divided in their center no bleeding of any consequence occurs. The nerves are drawn out of their beds and retracted upward and downward, out of the way, if possible.

Comment.—Parts of three ribs may be excised by a single incision (about 15 cm., or 6 inches, long), made over the central rib, followed by good retraction.

After making a thoracic opening at the chosen site, lower openings, or counter-openings, for better drainage, can be made by cutting down upon a curved sound introduced through the original opening and directed to a lower part of the cavity

THORACOPLASTY.

ESTLAENDER'S OPERATION.

Description—This operation, suggested by Warren Stone, and established by Estlaender, consists, as now practised, in the subperiosteal excision of parts of several contiguous ribs over a pleural cavity, together with the removal of their periosteum, the intercostal tissues, endothoracic fascia, and the parietal pleura—thereby allowing the corresponding soft thoracic wall to sink in and obliterate the abnormal cavity by the approximation and union of this thoracic wall of integumentary and muscular tissues to the visceral pleura, which has been freshened by curettage. The number of ribs which are partially excised, and the amount of each rib removed, will depend upon the position and extent of the involved area, as determined by the physical signs before operation; or by probing, or by the amount of fluid contained,

after opening the cavit·—and usually corresponds with that area. From the second to the ninth ribs, inclusive, have been excised—but generally from the second to the seventh, inclusive, are the ones taken. From the costal cartilages to the tubercles, in amount, has been resected—but the average is from about 13 to 15 cm. (about 5 to 6 inches)—the amount being greatest where the cavity is widest, and vice versa. The operation is applicable to long-standing cases of empyæma which have resisted drainage, and in which the lung no longer expands and the pleura is much thickened. Originally Estlaender did not remove the costal periosteum and intercostal tissues, nor the parietal pleura. The pleural surfaces were allowed to fall into contact if possible. The pleura was not opened, other than for the drainage which may have been previously resorted to—but the external wall with its parietal pleura, minus ribs, was merely allowed to come into contact with the visceral pleura Now both the costal periosteum is excised (to prevent regrowth of bone) together with the intercostal muscles and fascia, and the parietal pleura and endothoracic fascia removed, and even the visceral pleura scraped (to destroy pyogenic membrane and to approximate fresh surfaces for union)—and the outer wall held in contact with the visceral pleura by dressings, as far as possible.

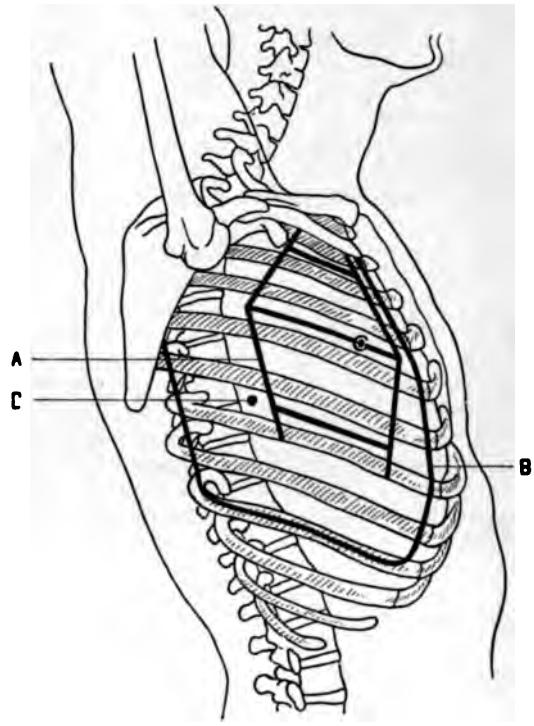

Fig. 352.—Operations upon the Pleural Cavity:—A, Incision for Estlaender's thoracoplasty (removing, in this case, parts of second to seventh ribs, inclusive, through three intercostal incisions); B, Schede's thoracoplasty (removing nearly all of the second to ninth ribs, inclusive); C, Position for paracentesis thoracis in the sixth intercostal space, in the mid-axillary line.

Preparation. — The thoracic wall is shaved, where necessary.

Position.—Patient is so placed as to best expose the special site involved, generally resting upon one side—surgeon usually stands in front in operating upon the left side, and behind in operating upon the right side—assistant stands opposite surgeon.

Landmarks.—Outline of the empyæmic cavity to be obliterated, as determined by physical signs; normal limits of lung and pleura; relation of important adjacent organs.

Incision.—Supposing that parts of the second to seventh ribs, inclusive, are to be removed, from the right antero-lateral aspect of the chest-wall--say 8 cm. (about 3 inches) of second rib—10 cm. (about 4 inches) of third—13

cm. (about 5 inches) of fourth—15 cm. (about 6 inches) of fifth—18 cm. (about 7 inches) of sixth, and 20 cm. (about 8 inches) of seventh—then transverse incisions somewhat longer than the length of the part of the rib to be removed (to allow for sufficient retraction of soft parts to get at the required length of rib) are made in the center of the long axis of each alternate interspace, as follows—between the second and third ribs, for removal of those ribs—between the fourth and fifth ribs, for the removal of those ribs—between the sixth and seventh ribs, for the removal of those. If an uneven number of ribs were to be removed, three of them could be removed through an incision placed over the central one of the three. The greatest length will be removed from that rib which spans the greatest width of cavity, whether at the middle or either end—and narrower lengths toward the tapering or narrowing aspects of the cavity. An equal length of each rib is sometimes removed. (See Fig. 352, A, where a kite-shaped excision is shown.)

Operation.—(1) Incise through skin, fascia, and overlying thoracic muscles, until down to the external intercostal muscles (on a level with the ribs). Tie all bleeding vessels. Retract upper lip of wound, in its full thickness, upward, exposing the rib above—cutting, where necessary, muscular fibers close to the level of the external intercostal muscles and external aspect of the rib (so as to keep as thick a flap of soft parts as possible). The lower lip of the wound is similarly retracted, exposing the lower rib. (2) The upper and lower ribs are now excised subperiosteally to the requisite extent. (3) The above steps are repeated for the second and third pairs of ribs. (4) The intercostal vessels are now tied at both ends of each intercostal bed. (5) There are now three long incisions, and two bridge-like strips of external soft parts, composed of skin, fascia, and outer thoracic muscles. These bridge-like parts are carefully preserved. Beneath these lie a deeper continuous layer of soft parts composed of costal periosteum (beds of ribs), external and internal intercostal muscles, endothoracic fascia, and parietal pleura (the last often very much thickened)—all forming the outer wall of the empyæmic cavity. Having retracted upward (*i. e.*, outward), out of the way, the above-described bridge-like strips of soft parts, this deeper layer of soft parts just mentioned is all cut away with scissors—well within the ligated intercostal arteries, on either side—and along the highest and lowest intercostal space of the involved and freed area. (6) The visceral pleura, especially if much thickened, is advantageously curetted. (7) The three original incisions are now sutured throughout, except a part of the lowest is left open for drainage, where drainage is instituted. The new outer wall of soft thoracic tissues is now allowed to come into contact with the freshened visceral pleura —and is held in contact by dressings as far as possible, to promote union and obliteration of the cavity.

Comment.—Considerable hemorrhage occurs throughout the operation, which is controlled by clamp, ligature, pressure, and hot solution.

There is not, as now practised, as distinct a difference between Estlaender's and Schede's operations of Thoracoplasty as formerly—modern operators using the good features of both in each.

The second rib is left where possible.

The external soft parts may be raised as one flap (as Schede does)—or as several smaller flaps (as Jacobson advises)—or the necessary amount of ribs over a small cavity may be exposed by a vertical incision over the designated ribs, followed by firm retraction (as Pearce Gould suggests).

A cavity wider than long requires the excision of more of fewer ribs—a cavity longer than wide requiring the excision of less of more ribs.

Where the cavity involves the posterior part of the upper ribs (those behind the scapula), their anterior ends may be severed in the usual way—the posterior ends being severed from the interior of the chest with stout, curved cutting-pliers—after freeing the rib of soft parts.

THORACOPLASTY.

SCHEDE'S OPERATION.

Description.—This operation, more extensive than Estlaender's, differs in detail from the latter, while being conducted upon the same general principle, and in the same general type of cases. A large U-shaped flap is raised, corresponding in extent to the underlying cavity (sometimes to nearly the entire pleural cavity) and consisting of all the soft parts overlying the ribs. The ribs, intercostal tissues, endothoracic fascia, and parietal pleura outlined by this incision are then excised *en masse*—the visceral pleura scraped—and the external flap allowed to fall into contact with the freshened pleura, being sutured back in place and held in contact with the visceral pleura by the dressings—opening for drainage being left. Generally resorted to in old empyæmic cases of the worst type, especially where the pleuræ are very much thickened, and which have resisted all other measures, and represents the most radical operation of its kind available, consisting, practically, of the removal of nearly the entire chest-wall of one side beneath the plane of the thoracic muscles. The number of ribs removed is determined by the vertical extent of the cavity, but is generally from the second to the ninth inclusive. The amount of each rib removed is likewise determined by the width of the cavity, but is often from the costal cartilages to the tubercles of the ribs.

Preparation—Position.—As for Estlaender's Thoracoplasty (page 604).

Landmarks.—Where adapted to a localized cavity, the outline of that cavity and the position of important adjacent structures will determine the landmarks. Where the maximum removal of the thoracic wall is indicated, that amount of each rib (from and including the second downward) which is in contact with the pleural cavity—in the average case, from the second to the ninth, inclusive, and from the costal cartilage to the tubercle. This latter extent will be understood in the following operation.

Incision.—Begins anteriorly at the upper border of the second costo-chondral articulation (about 2.5 cm., or 1 inch, from the sternal border)—passes downward following the curve of the chondro-costal articulations slightly outward (the cartilages increasing in length as they descend) to the eighth rib in the nipple-line—to the ninth rib in the mid-axillary line on the right side (the tenth on the left)—thence transversely backward to the posterior scapular line—thence upward along a line midway between the vertebral border of the scapula and the spinous processes of the vertebræ, to the second rib. (Some surgeons begin the incision at the outer border of the pectoralis major, above the level of the fourth rib—and retract from this point upward to expose the third and second ribs.) (See Fig. 352, B.)

Operation.—(1) Incise down to and upon the ribs and intercostal muscles throughout the line of incision—bearing lightly over the intercostal spaces to avoid penetrating the thorax. (2) This entire flap of overlying soft parts is dissected *en masse* from the bony and intercostal muscular wall of the thorax, hugging the ribs and intercostal muscles closely (so that the extensive flap may be as thick and well nourished as possible). The scapula, with the subscapularis muscle, are drawn upward and away from the trunk so as to

give access to the upper ribs and to enable the anterior part of the upper ribs, especially where the incision only extends upward anteriorly to the fourth, to be freed. (3) The ribs are now to be divided in front and behind, about 1.5 cm. (about ½ inch) within the line of division of the soft parts (so that the cicatrix will not fall directly over the line of the ends of the divided ribs). This division is best accomplished in the following way, devised by Hartley,—Where each rib is to be divided, anteriorly and posteriorly, the periosteum is divided over the center of the rib, midway between upper and lower borders, by an incision about 4 cm. (about 1½ inches) long, with the center of the incision at the point where each section of rib is to be made. To this more or less horizontal incision, at the two ends of the ribs, add a vertical incision through the periosteum, beginning at the center of the horizontal incision, or at both of its ends, and ending at the lower border of the rib. With a curved periosteal elevator, free the lower half of anterior and posterior ends of the ribs where the sections are to be made, for the extent of about 1.5 cm. (about ½ inch)—especially freeing the intercostal groove with the intercostal vessels. Complete this process of freeing at each end of each rib before proceeding to the next step. Now grasp the lower half of each rib, where cleared of periosteum, with rongeur forceps, inserting the lower lip of the rongeur forceps, between bone and periosteum, and bite out a half-button of bone (⌓) which will include the subcostal groove, and the removal of which will well expose the intercostal vessels. Complete this half-button excision at the inner and outer ends of each rib before proceeding further in the operation. (4) The intercostal vessels are all now ligated at both ends of the exposed part of each rib, being easily accomplished by passing a curved needle armed with chromic catgut, beneath them as they lie fully exposed—plainly in view, or very accessible in their beds, or are made accessible by a very little dissection. The arteries and veins should be picked up separately or together—but especial care should be exercised not to include the intercostal nerves. The vessels thus tied are the inferior intercostal vessels. The upper intercostal vessels are generally much smaller and may usually be taken up with clamp forceps and tied as divided in the osseo-periosteo-muscular flap. If considered necessary, the superior intercostal vessels may be exposed in the same manner as the lower ones, by biting out part of the upper border of the rib with rongeur forceps. (5) The ribs may now be freely divided at both ends by passing a Gigli saw between periosteum and bone—the saw-carrier easily passing between the rib and the separated part of the periosteum which had been freed in excising the half-buttons of bone, and for the balance of the way from the end of the separated area up to the upper border of the bone, hugging the rib closely on its inner aspect and emerging between the upper border of the rib and the position of the superior intercostal vessels. Both ends of all the ribs are thus divided. (6) Nothing now remains but to divide with blunt-pointed scissors the intercostal tissues in the line of the severed ribs on both sides, along the upper border of the second rib above, and along the lower border of the ninth rib below—thus removing the entire lot of ribs, intercostal tissues, endothoracic fascia, and parietal pleura *en masse* in a single sheet. (7) The thickened visceral pleura covering the remnant of contracted lung is thoroughly scraped and as much adventitious tissue removed as possible. (8) The flap of skin, fascia, and muscles is now allowed to fall into contact with the freshened visceral pleura—its margin being sutured to the margin of the thoracic opening, except a dependent opening left for drainage. The region is so dressed as to keep the flap in contact

with the freshened visceral pleura and aid in early union of the surfaces and obliteration of the cavity—the arm being bound to the side. In this step of closing the wound, all divided thoracic muscles along the line of incision are quilted together by means of a buried row of chromic gut sutures, before placing the final tier of sutures.

Comment.—(1) After the flap of soft parts has been turned back each rib may be excised subperiosteally and then the intercostal tissues cut away, as in Estlaender's operation—but much more time is consumed. (2) While removing the deeper flap composed of ribs, intercostal muscles, endothoracic fascia, and parietal pleura, a sound or a finger within the cavity should guide the scissors along the contour of the portion being excised. (3) The second rib is left where possible. (4) The scapula is displaced forward during the posterior incision. (5) The upper ribs may be removed from within the cavity, after division at both ends, as explained in Estlaender's operation.

OTHER OPERATIONS UPON THE PLEURÆ.

See Operations upon the Lungs (pages 609 to 614)—and Operations upon the Liver (pages 800 to 815).

IX. THE LUNGS.

SURGICAL ANATOMY.

Relations.—Apex; extends from 1.2 to 4.5 cm., averaging 2.5 (from ½ to 1¾ inches, averaging 1), above level of first rib into the neck (but not extending higher than the neck of the first rib)—lying beneath subclavian artery, and behind interval between two heads of sternomastoid and inner end of clavicle —and covered by subclavian artery and scalenus anticus. Right apex may project slightly higher than left. **Base;** rests upon convexity of diaphragm. **External surface;** chiefly corresponds to cavity of thoracic wall. **Internal surface;** in contact with pericardium and lateral pleural wall of mediastina. **Anterior border;** overlaps anterior surface of pericardium on right, and partially so on left. **Posterior border;** fits into concavity on either side of vertebral column. **Inferior border;** fits into space between inferior ribs and costal attachment of diaphragm.

Relations of Margins of Lungs to Chest-wall.—Anterior margins; extend from their apices (at an average point of 2.5 cm., or 1 inch, above the first rib, and nearer posterior than anterior border of sternomastoid) downward and inward across sternoclavicular articulation and manubrium sterni to near center of articulation of manubrium and gladiolus, where the two margins meet, or very nearly meet—thence both borders descend parallel to each other and just beyond the middle line (the right sometimes slightly overlapping it) to midway between the level of the articulations of the fourth costal cartilages with the sternum—from which point they diverge unequally. Right margin continues to descend almost vertically downward to sixth chondro-sternal articulation (sometimes to lower end of gladiolus), whence it curves downward and outward along that cartilage to sixth costo-chondral articulation. Left margin, from point of divergence, passes along lower border of fourth rib outward with a downward inclination, and then downward across fourth interspace and fifth rib with an outward inclination to apex of heart (a point 3.8 cm., or 1½ inches, below, and 2.5 cm., or 1 inch, to inner side of left male nipple in fifth interspace)—thence to sixth costo-

chondral articulation. **Lower margins;** marked by a slightly curved line, with downward convexity, extending from sixth costo-chondral articulation to spinous process of tenth dorsal vertebra—crossing (while arms are elevated at right angle) the nipple-line at sixth rib—mid-axillary line (arms still raised) at eighth rib—scapular line (arms now lowered) at tenth rib. Lower margin of left lung starts on level with sixth costo-chondral joint, but much further out than right—about 7.5 cm. (3 inches) to left of median line in fifth interspace. Sometimes lower margin of left lung may be one rib lower than right. **Posterior margins;** marked by line from level of spinous process of seventh cervical vertebra, passing vertically downward on either side of spine, over the costo-vertebral articulations, to spinous process of tenth dorsal vertebra.

Excursion of Lower Borders of Lungs in Forced Respiration.—Extend about 3.8 cm. (1½ inches) below the line given above for the relation of the lower margin, in deep inspiration—and rise above it in forced expiration.

Relations of Fissures of Lungs to Chest-wall.—(1) Great or Lower Fissure of Right Lung:—draw line from fourth dorsal vertebra forward and downward around chest to intersection of anterior margin of lung and seventh rib. (2) Lesser or Upper Fissure of Right Lung:—draw line from point of intersection of preceding line with mid-axillary line, to fourth chondro-sternal articulation. (3) Fissure of Left Lung:—draw line from third dorsal vertebra forward and downward around chest to intersection of anterior margin of lung with sixth costal cartilage.

Structures of Roots of Lungs, and their Relations.—Structures of each root; bronchial tube, pulmonary artery, pulmonary veins, bronchial artery (generally one on right and two on left), two bronchial veins, anterior pulmonary plexus of nerves, posterior pulmonary plexus of nerves, bronchial lymphatic glands, areolar tissue—all being enclosed within pleura. **Relations of right root:** Anteriorly; right auricle, superior vena cava, ascending aorta, phrenic nerve, anterior pulmonary plexus. Superiorly; vena azygos major arching to join superior vena cava. Posteriorly; pneumogastric nerve, posterior pulmonary plexus. Inferiorly; ligamentum latum pulmonis. **Relations of left root:** Anteriorly; phrenic nerve, anterior pulmonary plexus. Superiorly; arch of aorta. Posteriorly; descending aorta, pneumogastric nerve, posterior pulmonary plexus. Inferiorly; ligamentum latum pulmonis. **Order of structures of right root:** From Before Backward; pulmonary veins, pulmonary artery, bronchus, and bronchial vessels. From Above Downward; bronchus, pulmonary artery, pulmonary veins. **Order of structures of left root:** From Before Backward; pulmonary veins, pulmonary artery, bronchus, and bronchial vessels. From Above Downward; pulmonary artery, bronchus, pulmonary veins.

Position of Hilum of Lung.—Upon inner aspect, slightly above middle, and much nearer posterior than anterior border—on level with bodies of fifth, sixth, seventh, and sometimes eighth dorsal vertebræ.

Bifurcation of Trachea and Bronchi.—Trachea bifurcates opposite the spinous process of fourth dorsal vertebra—right bronchus passing nearly horizontally outward and dividing into three chief bronchial tubes—left bronchus passing more directly downward and dividing into two chief bronchial tubes.

Arteries.—Pulmonary; bronchial.

Veins.—Pulmonary; bronchial.

Nerves.—From anterior and posterior pulmonary plexus, formed mainly by sympathetic and pneumogastric.

Lymphatics.—End in bronchial glands.

PNEUMOTOMY

THROUGH A THORACOPLASTIC FLAP.

Description.—Incision of lung tissue through a temporary opening made in the chest-wall. This opening may be made in the form of an intercostal thoracotomy,—through the partial resection of one or more ribs,—or through an osteothoracoplastic flap. In the present instance, a partial resection of three ribs will be made, after raising a thoracoplastic flap. Generally resorted to in cases of abscess, gangrene, hydatid cyst, and sometimes for bronchial dilatation and tuberculous cavities.

Preparation.—Chest-wall is shaved where hairy growth exists.

Position.—Patient so placed as to render site of operation accessible during exposure of lung—but placed so as to render site dependent before cutting into lung tissue (that fluid may not flow into bronchial tubes opened by incision, in addition to that which may be drawn into them). Surgeon on side of operation—assistant on same side, or opposite.

Landmarks.—Determined by physical signs locating disease, and generally verified by preliminary exploration; known position of important structures.

Incision.—A U-shaped flap is outlined, with base generally upward and convexity downward—usually extending over two or three ribs, and of sufficient size to well include the incision into the lung, with room for manipulation. (Vitality of flap would be better assured if base were forward or backward and convexity in opposite direction.)

Operation.—(1) This U-shaped flap of all the soft parts down to the ribs and intercostal muscles is raised. (2) Having controlled hemorrhage, the necessary parts of the indicated ribs are excised subperiosteally—calculating that the line of division of the ribs will fall about 1 cm. (nearly ½ inch) within the line of flap-incision (that cicatrix of latter may not fall over ends of ribs). (3) An exploratory needle may now be introduced through the periosteal bed of a rib, thus avoiding the intercostal vessels—and the needle may be left *in situ* as a guide. (4) An incision is now carefully made in the long axis of a space, or, preferably, in the bed of a rib, avoiding intercostal vessels, —if in a space, passing through intercostal muscles and endothoracic fascia—if in the bed of a rib, passing through periosteum and endothoracic fascia. In the transverse incisions sufficient room can usually be gotten by upward and downward retraction of the soft parts, without requiring the division of the vessels. If it be elected to make a vertical opening, after removing the ribs, then the intercostal vessels are ligated at both ends of the exposed beds of the excised ribs—so that when the vertical incision is made in the center of the exposed area, little or no hemorrhage will occur. This vertical incision is in the center of the area from which the ribs have been partially excised, and extends between the intact ribs above and below. In any event, the incision should be made, if possible, down to but not directly through the parietal pleura, at this stage. (5) Here one of two conditions will be found;—(A) The parietal and visceral pleuræ may be adherent—the general pleural cavity will then be walled off, and the incision may be made directly into the lung tissue—having determined its depth by exploratory puncture. (B) Parietal and visceral pleuræ may be non-adherent; (a) If it be necessary to proceed with the operation at once, suture the two surfaces of the pleuræ together with catgut, in a sufficiently large circle—thus closing off the general pleural cavity by suture and by packing the outer circumference of the circle with gauze. The incision may be then made at once into the lung through

the above circle. (b) If no need of haste exist, pack the wound with gauze a little firmly, so that the pleural surfaces are held in contact—and in two or three days the surfaces will be united for some distance around, and incision into lung tissue may be made through the united surfaces, without fear of invading the general pleural cavity. This adhesion is made more certain and firmer by also suturing the pleuræ in a circular manner at the time of the exposure. (6) Incision into the lung is usually made in the direction of the original incision by which it has been approached—the incision extending through the full thickness of the variously thick layer of lung tissue overlying the cavity. (7) Drainage is provided for—the drain coming out through an unsutured lower part of the flap, the remainder of the flap being sutured back into place—or the drain may come out through a convenient opening in the flap, the circumference of the flap being sutured throughout.

Comment.—(1) Usually the removal of parts of one or two ribs suffices to expose the site. (2) The distance of the cavity from the surface should be determined by needle before incising. (3) The following methods of incising the lung tissue are used;—actual cautery—best for soft lung tissue; incision by knife—safe in hardened lung tissue; exploratory needle and small grooved director introduced simultaneously—the needle is withdrawn and director left *in situ*—upon which dilators of increasing size are slipped into cavity, which is then dilated; blunt dissection; trocar and cannula. (4) If hemorrhage occurs from lung tissue, pack with gauze. (5) Collapse of lung is very apt to follow going through the opened pleural cavity (where the two surfaces are not united by adhesion)—requiring the use of a Fell-O'Dwyer instrument. (6) Pneumotomy may be performed by means of an osteo-thoracoplastic flap, as described under Pneumectomy—or by any method which satisfactorily exposes the lung.

PARTIAL PNEUMECTOMY

THROUGH AN OSTEO-THORACOPLASTIC FLAP.

Description.—The excision of part of a lung involved in some lesion—an uncommon though possible operation. Access may be obtained by the permanent excision of parts of several ribs, after raising a thoracoplastic flap, as described under Pneumotomy—or, better still, by the turning back temporarily of a window consisting of the entire thickness of the soft and bony parts of the chest-wall. The operation has generally been resorted to for the removal of malignant and hydatid tumors of the lungs—and also for localized tuberculosis. In the latter cases the part excised has usually been the apex.

Preparation—Position—Landmarks.—As in Pneumotomy.

Incision.—(1) Supposing the tumor to be of the middle lobe of the right lung—an incision is to be planned outlining an upper, a lower, and an anterior side of a square or rectangle, the fourth or posterior side forming the hinge—the square including the antero-lateral aspect of the fourth, fifth, and sixth ribs. The upper line will lie in the middle of the third interspace, in its long axis—the lower line will be similarly placed in the center of the sixth interspace—the anterior line will run vertically about 2.5 cm. (1 inch) outside of the costal cartilages—and the posterior side will be parallel with the anterior and from 10 to 13 cm. (about 4 to 5 inches) behind it. (2) Supposing the case to be one of localized tuberculosis of the apex of the left lung—a U-shaped flap is planned, with its convexity over the middle of the sternum; its

base reaching nearly to the anterior axillary line; its upper horizontal limb in the middle of the first intercostal space; its lower horizontal limb in the middle of the third intercostal space.

Operation.—Carrying out the steps of the operation indicated in the first incision given above—(1) Incise through skin, fascia, and overlying thoracic muscles; down to the ribs and intercostal muscles, along the upper, lower, and anterior sides only. (2) Along the anterior line, where the ribs are intersected by the vertical portion of the incision, retract the soft parts a limited distance on each side over the ribs—and make a short incision directly over the center of their long axes, passing through the periosteum (not through the skin)—free the circumference of the ribs here subperiosteally with a curved periosteal elevator over the least width of rib possible to accomplish its freeing. Do not yet divide the rib. (3) A short incision is now made directly over the center of the long axis of the ribs posteriorly, through all the overlying soft parts down to and through the periosteum—the center of each incision being an imaginary line connecting the posterior ends of the upper and lower lines (just as the center of the trans-periosteal incisions anteriorly was the real line connecting the anterior ends of the horizontal lines of incision). The ribs are here freed subperiosteally as in front—their circumference being bared over the smallest space practicable. (4) A Gigli saw is now carried beneath the freed portions of the ribs in front and behind —thus entirely freeing the bony connections of the flap. (5) The upper, lower, and anterior sides of the square, or rectangle, are now carefully incised through their soft structures not already divided, down to the endothoracic fascia, carefully avoiding penetration of the parietal pleura. (6) This large cutaneo-musculo-osseous flap is now carefully elevated and turned backward upon its posterior hinge (which hinge, as far as the soft parts and the integrity of their blood-supply go, has been very little injured by the longitudinal cuts over the ribs)—carefully separating it from the parietal pleura as it is turned backward. (7) If it be found that the two surfaces of pleuræ are not adherent, the wound is rather snugly packed with gauze—the flap turned as far back into place as the gauze will allow—and adhesion is awaited for three or four days. Or the vitality of the flap and the firmness of adhesion would probably be more safely and thoroughly secured if the parietal and visceral pleuræ were sutured around the extreme margin of the wound with catgut —allowing the flap to fall fully into place, where it could either rest, or be sutured, the necessary time for adhesions to form—and subsequently raised for the excision of the growth. Or the pleura may be incised and the operation completed immediately, after the suturing together of the pleural surfaces. (8) At the time of the removal of the tumor, the method of the removal will be somewhat determined by the character of the tumor. Whether fluid (*e. g.*, hydatid cyst) or solid (*e. g.*, primary malignant tumor), if its accessibility will allow, it is best to ligate off the surrounding lung tissue by carrying chromic gut in a large, fully-curved needle around the growth in segments—and then excise by actual cautery, knife, or blunt dissection, where possible. (See Pneumotomy, page 611.) Sometimes previous ligation is impossible—the tumor is then removed without it, and hemorrhage controlled by packing the cavity with gauze. It sometimes happens in hydatid cysts that the tumors have to be incised, their contents evacuated and their walls curetted, the remainder being allowed to slough out—although complete removal of their walls is much preferable. (9) The cavity left by the removal of a tumor should be temporarily packed with gauze—which is brought out for drainage through a convenient opening made at a margin of the flap—the flap being

elsewhere sutured back into its normal position. As the ribs are adherent to the soft part of the flap, which will be sutured to the thorax around its margin, the ribs will thereby be held in place and prevented from being materially displaced. If, when the section of the ribs is made, it be done in a beveling fashion (at the expense of the inner aspect of the parts of the ribs in the flap), when the flap is turned back into place this beveling will additionally steady the rib ends in place. If desired, the contiguous ends of the severed ribs, in front and behind, can be united by chromic gut or silver wire, after having been previously drilled.

Comment.—(1) In carrying out the steps of the operation indicated in the second incision given above, the description given under Pneumotomy by a Thoracoplastic Flap will sufficiently cover, being practically similar. The indurated apex of the lung, when exposed, is seized with forceps—detaching it, if necessary, from its adhesions—and withdrawn through the thoracic opening—a chromic gut ligature is then carried below the involved portion—or a double ligature is passed through upon a needle and each side tied separately—the apex is now excised—the lung replaced, after bringing together the raw surfaces of the lung by gut suture, if possible—and the edges of the parietal pleuræ sutured with catgut. The operation is completed as in Pneumotomy by Thoracoplastic Flap. (2) Tuffier has removed portions of tubercular lung through a simple intercostal thoracotomy in the second interspace—opening the pleura and delivering and excising the involved portion of lung. (3) Where the ligature is not used, the actual cautery is the safest means with which to excise lung tissue. (4) The operation is simplified if the neighboring healthy lung is adherent to the parietal pleura. Collapse is also much less likely. (5) The lower two-thirds of the first rib are sometimes alone excised.

X. THE PERICARDIUM.

SURGICAL ANATOMY.

Position.—Occupies middle mediastinum of thorax, lying between anterior mediastinum, in front (opposite sternum and third, fourth, fifth, sixth, and seventh costal cartilages)—posterior mediastinum, behind—and pleuræ, laterally. Consists of visceral and parietal layers. Has general outline of heart, except where reflected on to great vessels at base of heart.

Attachments.—**Apex;** covers great vessels for about 5 cm. (2 inches) and is held in position by them. **Base;** attached to central tendon of diaphragm and adjacent surface. **Anterior surface of pericardium;** attached to posterior surface of manubrium and ensiform process by superior and inferior sterno-pericardial ligaments.

Relations.—**Superiorly;** great vessels of heart. **Inferiorly;** diaphragm. **Anteriorly;** thymus gland (or remains); areolar tissue; margins of lungs (especially left); sterno-pericardial ligaments; triangularis sterni muscle; internal mammary vessels; anterior mediastinum; sternum. **Posteriorly;** bronchi; esophagus; descending aorta; pneumogastric nerves; posterior mediastinum. **Laterally;** pleuræ; anterior margins of lungs (especially left); phrenic nerves; accompanying phrenic vessels.

Structures Covered by Pericardium.—Aorta; superior vena cava; pulmonary artery and bifurcations; ductus arteriosus; four pulmonary veins.

Arteries.—Pericardiac and musculophrenic from internal mammary;

pericardiac, esophageal, and bronchial from descending aorta; coronary from ascending aorta; phrenic from abdominal aorta.

Veins.—Pass to azygos, internal mammary and phrenic trunks, cardiac veins emptying into right auricle.

Nerves.—Branches from pneumogastric, phrenic, and sympathetic.

Lymphatics.—Empty into mediastinal glands.

SURFACE FORM AND LANDMARKS.

The anterior surface of the upper portion of the pericardium is from 3 to 5 cm. (about 1¼ to 2 inches) posterior to the sternum—and the anterior surface of the lower portion is about 1 cm. (about ⅜ inch) posterior to the sternum.

Normally there is a collapsed cul-de-sac at the base of the anterior portion of the pericardium, which is much distended in effusion. This is the site sought in drainage.

According to Voinitch-Sianojentsky, the interpleural pericardial area extends vertically from the lower border of the left fifth chondro-sternal articulation to the left seventh chondro-sternal articulation—lying mainly behind the sternum but also corresponding to the sternal end of the sixth intercostal space—wherefore, puncture of the pericardium in the sixth space may be made directly inward—whereas it should be directed very obliquely downward if made in the fifth interspace, to avoid the heart (that is, it runs parallel with the heart after entering the pericardium).

A cartilaginous bridge unites the sixth and seventh costal cartilages—and sometimes also the fifth and sixth—and thereby the intercostal area for puncture, between the inner border of the cartilaginous bridge and the left border of the sternum, may be considerably encroached upon.

The internal mammary artery runs down at an average distance of about 1.2 cm. (about ½ inch) to the outer side of the sternal border—to the sixth interspace, where it divides into the superior epigastric and the musculo-phrenic.

For outline of Pleura, see Anatomy of Pleura.

PARACENTESIS PERICARDII.

Description.—Penetration of the pericardium by a hollow needle attached to a vacuum syringe—for the purpose of exploration of contents, or aspiration of fluid.

Preparation.—Region shaved, if necessary.

Position.—Patient supine, preferably resting upon some object which will render chest prominent and increase the width of the intercostal spaces. Surgeon on left of patient.

Sites of Puncture.—Puncture may be made in either the fifth or sixth interspace—and either internal to or external to the internal mammary artery. In the fifth interspace, the width is greater near the sternal border, and is the space usually chosen. In the sixth interspace, the internal mammary artery and the pleura are both further from the left sternal border, and puncture may be made more directly inward. Where sufficient width of space exists, the sixth interspace may be chosen. Puncture should, by preference, be made internal to the internal mammary artery, as the pleura is in less danger of injury, especially in the fifth space—and even in the sixth space, the punc-

ture would have to be about 2.5 cm. (about 1 inch) outside of the border of the sternum to be sure of avoiding the internal mammary artery, and then it is apt to strike the pleura. (See Fig. 353, G.)

Landmarks.—Fifth left intercostal space (or sixth); left margin of sternum; course of internal mammary artery; anterior border of left lung and pleura; right border of heart. See the Surgical Anatomy of these structures.

Operation —(1) An incision should be made in the long axis of the sternal end of the fifth intercostal space, through skin, fascia, pectoralis major, down to the intercostal membrane, clamping all bleeding vessels. (2) Expose the intercostal membrane by retraction of the edges of the wound. Grasping the needle with right forefinger and thumb, so placed as to prevent its suddenly entering too far, pierce the fifth intercostal space near the left border of the sternum, and near the upper border of the sixth costal cartilage—penetrate straight backward about 0.8 cm. (about $\frac{5}{16}$ inch), which is, approximately, the thickness of the sternum—then penetrate inward toward the posterior surface of the sternum for 1 to 2 cm. ($\frac{3}{8}$ to $\frac{13}{16}$ inch), to avoid the possible forward extension of the pleura—thence penetrate downward and inward through the pericardium—the sensation generally indicating when the pericardium is entered. Briefly stated —pass backward, inward, and downward (Delorme and Mignon). Where the sixth intercostal space is used, the needle is passed directly inward and backward, close to the sternum and in the middle of the interspace (Voinitch-Sianojentsky).

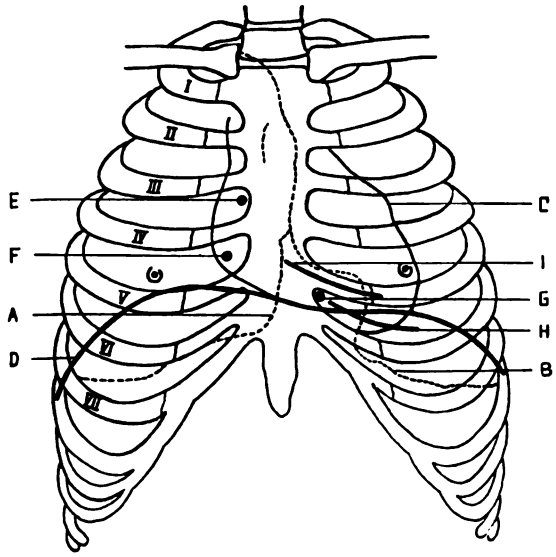

Fig. 353.—Incisions and Paracenteses about the Heart and Pericardium:—A, Outline of right lung; B, Outline of left lung; C, Outline of heart; D, Elevation of diaphragm; E, Paracentesis of right auricle; F, Paracentesis of right ventricle; G, Paracentesis of pericardium; H, Pericardiotomy through an intercostal space; I, Exposure of pericardium and heart by excision of left fifth costal cartilage. (Modified from Gray.)

Comment.—Puncture may be made without previous incision, but preliminary incision is better, as the intercostal space and border of the sternum are exposed, and the course and depth of the needle and entrance into the pericardium are better appreciated. Also the bridge of cartilage across the intercostal space, when present, may be avoided.

PERICARDIOTOMY

THROUGH AN INTERCOSTAL INCISION.

Description.—Incision of the pericardium through the fifth intercostal space—generally resorted to for purposes of drainage. The method here

described will be the simpler one of exposing and incising the pericardium through an intercostal incision. The more extensive exposures involve the removal of part of the cartilaginous or bony wall of the thorax. The interspace where the operation of intercostal pericardiotomy is usually done is so narrow that the operation by excision of the fifth costal cartilage is much preferable.

Preparation and Position.—As for Paracentesis Pericardii.

Landmarks.—Sternal end of left fifth intercostal space (between fifth and sixth rib-cartilages); and other landmarks mentioned under Paracentesis Pericardii.

Incision.—Incision in center of fifth intercostal space, parallel with its long axis—beginning at the left sternal border and extending 5 to 7.5 cm. (about 2 or 3 inches) in length. (See Fig. 353, H.)

Operation.—(1) Incise skin, fascia, pectoralis major, external intercostal membrane, internal intercostal muscles—ligating all bleeding vessels. (2) Internal mammary artery is either divided between two ligatures, or, preferably, drawn outward. (3) Triangularis sterni muscle is divided, or its fibers separated by blunt dissection. If the pleura be in the field, it will be exposed after passing through the triangularis sterni, and should be carefully displaced outward. (4) The pericardium is now within sight and touch—and is carefully seized and steadied by two toothed forceps and incised for 1 to 2.5 cm. (about ½ to 1 inch) between them, in a direction downward and outward from the border of the sternum. (5) The edges of the pericardium are sutured into the deeper plane of the thoracic wound—that is, at the opening through the internal intercostal muscle. Drainage is established from the interior of the pericardium through the lowest part of the outer wound, the upper portion of which may be closed.

Comment.—(a) The pericardium should be opened with scissors, and the opening increased by blunt-pointed scissors or probe-pointed knife. (b) Pericardiotomy may also be performed, but less safely, through the costo-xiphoid angle (Larrey's space).

EXPOSURE OF PERICARDIUM AND HEART

BY EXCISION OF LEFT FIFTH COSTAL CARTILAGE.

Description.—Exposure of pericardium and heart after excision of the left fifth costal cartilage—and, where more room is required, also of the fourth and sixth costal cartilages. Generally resorted to for suturing wounds of the heart and pericardium and for drainage of the latter—especially in those cases where more space is required than attainable by the intercostal operation.

Preparation—Position.—As for Paracentesis Pericardii.

Landmarks.—Left fifth costal cartilage; and other landmarks mentioned under Paracentesis Pericardii.

Incision.—Directly over center of fifth costal cartilage—beginning over center of sternum and ending just beyond chondrocostal articulations. (See Fig. 353, I.)

Operation.—(1) Incise skin, superficial fascia, pectoralis major, and deep fascia directly down upon the full length of the fifth costal cartilage, ligating all vessels severed. (2) Isolate the fifth costal cartilage from its neighboring structures (external intercostal membrane, internal intercostal muscle, and triangularis sterni, if any of the last be attached) as completely

as possible, by hugging and clearing the cartilage closely. Divide its sternal and costal ends with blunt-pointed pliers—or, preferably, with Gigli saw. (3) Ligate the intercostal vessels at both ends of the wound and divide them between the ligatures. Divide tissues which intervene between bed of cartilage and internal mammary artery. Cut the internal mammary artery between two ligatures, or draw it outward. Incise the triangularis sterni if necessary, or separate it from the sternum and push it to the right. Displace the pleura outward, after careful separation from the pericardium and sternal structures. (4) The pericardium is now in the field, and is treated as indicated by the object of the operation;—In Pericardiotomy (for drainage) the pericardium is steadied between two toothed forceps and carefully incised obliquely downward and outward from close to the border of the sternum;—In Pericardiorrhaphy (for incised wounds of the pericardium) the lips of the pericardial wound are approximated and so sutured with catgut as to bring

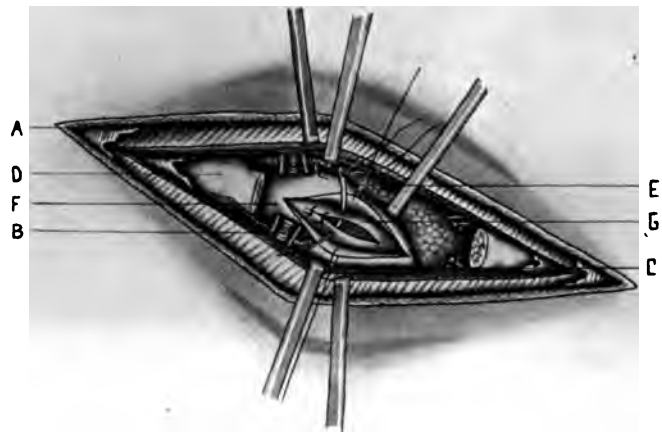

Fig. 354.—Exposure of Pericardium and Heart by Partial Excision of Left Fifth Costal Cartilage:—A, Pectoralis major muscle retracted, overlying the retracted intercostal muscles and membrane; B, Internal mammary vessels; C, Intercostal vessels; D, Sternum and part of fifth costal cartilage; E, Pleura and lung retracted; F, Pericardium, incised and margins retracted; G, Heart, showing incised wound being sutured.

the serous surfaces together. (5) Where the pericardium has been incised for drainage, it is sutured into the lower plane of the outer wound—that is, the triangularis sterni and internal intercostal muscles. The external wound is closed in greater part, and drainage provided from the interior of the pericardium through the part of the thoracic wound left open. Where the pericardium has been sutured, temporary drainage of the external wound only is instituted, through a limited opening—the remainder of the thoracic wound being closed. (See Fig. 354.)

Comment.—(a) This may be considered the best manner of exposing the pericardium and heart—and the opening of the pericardium after free exposure may, ordinarily, be considered safer than puncture or aspiration through an unopened thorax. (b) Having excised the fifth costal cartilage by the above incision, if more room be required, or it be desired also to remove the fourth and sixth costal cartilages in addition, the object may be accomplished by making a vertical incision at the inner end of the original incision,

down the center of the sternum, and another vertical incision at the outer end of the original incision. Where both the fourth and sixth costal cartilages are to be removed, these two vertical incisions will extend from above the fourth to just below the sixth cartilages, thus making an ⊢-shaped incision, and enabling two flaps of soft parts down to the cartilages to be turned, the one upward, and the other downward. If it be desired to remove only the fourth cartilage in addition, then only the upper parts of the vertical incisions are added. If only the sixth cartilage must be additionally removed, then only the lower parts of the vertical incisions are used. If it be known from the start that two or more costal cartilages must be removed, an oval or modified horseshoe flap of soft parts with its base over the sternum and its convexity extending beyond the outer limit of the excision, may be used,—or an I-shaped incision, the vertical portion being from 1 to 2 cm. (about ½ to ¾ inch) from the sternum, the transverse parts corresponding with the uppermost and lowermost ribs to be removed, may be used, the two flaps thus outlined being turned inward and outward. Additional room may always be gotten by resecting, with rongeur forceps, the left border of the sternum.

EXPOSURE OF PERICARDIUM AND HEART

BY OSTEO-THORACOPLASTIC RESECTION OF ANTERIOR CHEST-WALL.

See the osteoplastic resection of the chest-wall for exposure of the anterior and middle mediastina (page 590). Used where the most extensive exposure of the pericardial and cardiac regions is indicated.

PERICARDIORRHAPHY.

Consists in the suturing of wounds of the pericardium. The operation is sufficiently described under Exposure of the Pericardium and Heart by Excision of the Left Fifth Costal Cartilage (page 617).

XI. THE HEART.

SURGICAL ANATOMY.

Position of the Heart and Its Various Parts.—Occupies greater portion of middle mediastinum—lying obliquely behind lower two-thirds of sternum—and projecting about 7.5 cm. (about 3 inches) to left of median line, and about 4 cm. (about 1½ inches) to right of median line—extending from above to the right, to below and to the left. **Base;** directed upward, backward, and to the right, corresponding to interval between fifth and ninth dorsal vertebræ. **Apex;** directed downward, forward, and to left, corresponding to chest-wall between fifth and sixth costal cartilages—at a point about 2 cm. (about ¾ inch) to inner side, and about 4 cm. (about 1½ inches) below left male nipple. **Inferior border;** corresponds to right ventricle and rests on central tendon of diaphragm. **Anterior border;** corresponds to right auricle. **Left border;** corresponds to left ventricle. **Anterior surface;** formed mainly by right ventricle and part of left. **Posterior surface;** formed mainly by left ventricle.

Relations of Heart to Chest-wall.—**Base;** corresponds to line from point on lower border of second left costal cartilage 2.5 cm. (1 inch) from sternum, to upper border of third right costal cartilage 1.2 cm. (about ½ inch)

from sternum. **Apex**; corresponds to point 3.8 cm. (about 1½ inches) below, and 2 cm. (¾ inch) internal to left male nipple—which is about 9 cm. (about 3½ inches) to left of median line, and between fifth and sixth costal cartilages, and just internal to end of fifth rib. **Lower border**; corresponds to line from apex, with slight downward convexity, to seventh right chondro-sternal articulation. **Right border**; represented by line joining right extremity of base-line with right extremity of lower border-line (seventh right chondro-sternal articulation), with a slight outward convexity projecting about 3.8 cm. (about 1½ inches) from median line. **Left border**; represented by line joining left extremity of base-line with apex-point, with slight convexity to left—extending about 7.6 cm. (about 3 inches) to left of median line of sternum.

Relations of Parts of Heart to Chest-wall.—Right auricle; behind sternal ends of third, fourth, fifth, and sixth costal cartilages of right side; corresponding intervening spaces; right border of sternum. **Right auricular appendix**; behind or to left of median line, on level with third costal cartilages. **Left auricle**; extends vertically from level of lower border of second left costal cartilage to upper border of fourth—and corresponds, horizontally, with body of seventh dorsal vertebra and heads of adjoining left ribs. **Apex of left auricular appendix**; behind third costal cartilage, about 3.2 cm. (1¼ inches) to left of sternum. **Right ventricle**; extends from third costal cartilage above, to seventh costal cartilage below, on left side. **Right auriculo-ventricular sulcus**; line obliquely upward, from sternal end of sixth right costal cartilage, to third left costal cartilage. **Left ventricle**; not in contact with chest-wall, except small part of apex of left ventricle during expiration.

Relations of Orifices of Heart to Chest-wall.—Pulmonary orifice (Pulmonary Semilunar Valves); behind junction of upper border of left third costal cartilage with sternum. **Aortic orifice** (Aortic Semilunar Valves); behind left half of sternum, opposite lower border of third costal cartilage. **Left auriculo-ventricular opening** (Mitral Valves); behind sternum, to left of median line, opposite fourth costal cartilage. **Right auriculo-ventricular opening** (Tricuspid Valves); behind center of sternum, opposite fourth intercostal space.

Relations of Uncovered Area of Heart to Chest-wall.—The triangular area of the heart uncovered by pleura is represented within the three following lines;—(**a**) Draw line downward and to left from middle of sternum, between fourth costal cartilages, to apex of heart; (**b**) Draw line from starting-point of first line down the lower third of the central line of the sternum;—(**c**) Draw line from sternal end of sixth right costal cartilage through seventh left costal cartilage.

Arteries.—Anterior and posterior coronary.

Veins.—Correspond with arteries, emptying into right auricle.

Lymphatics.—End in thoracic and right lymphatic ducts.

Nerves.—From cardiac plexus.

PARACENTESIS OF RIGHT AURICLE OF HEART.

Description.—Puncture of right auricle of heart by needle of aspiratory syringe—for the purpose of withdrawing a portion of the blood in cases where the right side of the heart is engorged from obstruction to the circulation through the lungs.

Preparation—Position.—As for Paracentesis Pericardii.

Landmarks.—Position of right auricle.

Operation.—An aspiratory needle, so held as to control the depth of puncture, is entered in the right third intercostal space, close to the margin of the sternum—and thrust directly backward through skin, fascia, pectoralis major, external intercostal membrane, internal intercostal muscle, probably through fibers of triangularis sterni, through areolar tissue of anterior mediastinum, both layers of pleura, periphery of right lung, into the right auricle—its entrance generally being recognized by the sensation, and verified by the free flow of blood into the syringe. The requisite amount of blood is withdrawn—and the wound is sealed with sterile cotton and collodion. (See Fig. 353, E.)

Comment.—(**a**) A preliminary incision may be made in the intercostal space, down to the intercostal membrane—whereby the entrance of the needle into the auricle, especially in thick thoracic walls, is more readily recognized. However, in using a vacuum syringe, this is not generally necessary. (**b**) It is necessary to withdraw blood by suction, as the blood-pressure in the right auricle is not sufficient to cause spontaneous flow. (**c**) The right auricle is preferable to the right ventricle for operation, because its position is not apt to be altered and its internal antero-posterior diameter is greater than that of the right ventricle.

PARACENTESIS OF RIGHT VENTRICLE OF HEART.

Description.—Puncture of right ventricle of heart by needle of aspiratory syringe, or by fine trocar and cannula—in the same cases as mentioned under Paracentesis of Right Auricle (*q. v.*).

Preparation—Position.—As in Paracentesis of Right Auricle.

Landmarks.—Position of Right Ventricle.

Operation.—The cannula and trocar, or needle, are entered in the fourth right intercostal space, 2.5 cm. (about 1 inch) from the right sternal border. It is manipulated as in Paracentesis Auriculi—and passes through practically the same structures—but is directed inward as well as backward, in order to strike the right ventricle, which, normally, might not be certainly reached, but which is reached with greater certainty when thus engorged. The requisite amount of blood is allowed to flow spontaneously—and the wound is then sealed with sterile cotton and collodion. (See Fig. 353, F.)

Comment.—Blood-pressure in the right ventricle is sufficient to cause spontaneous flow through the cannula. See Comment under Paracentesis Auriculi.

CARDIORRHAPHY.

Description.—Suturing of wounds of the heart-muscle—after having freely exposed that organ by one of the operations described under the Pericardium and the Mediastina.

Preparation—Position.—As for Paracentesis Auriculi.

Landmarks.—The landmarks will be those of the operation by which the heart is exposed. For the fullest exposure, the osteoplastic resection for exposure of the anterior and middle mediastina is probably best—see page 590. For a less extensive exposure, the resection of the fifth costal cartilage may be used—see page 617. Additionally, the landmarks of the parts of the heart should be noted.

Operation.—(**1**) The pericardium having been exposed and the wound in it enlarged, if necessary, the heart is brought into the field. (**2**) Chromic gut upon a fully curved needle, held in a good needle-holder, is used. The

needle is quickly, but gently and steadily, inserted during diastole only, and no attempt is made to proceed with the operation except during diastole. The needle enters about 4 to 5 mm. (about $\frac{2}{16}$ to $\frac{3}{16}$ inch) from one edge—penetrates moderately deeply only (never entering the endocardium)—crosses the gap between the walls of the wound (or may dip beneath the bottom of the wound, if the wound does not entirely penetrate the wall of the heart and there is room beneath it for suture to pass without entering the endocardium)—and makes its exit at a corresponding point on the opposite side. During a subsequent diastole the thread is drawn through the lips of the wound—and, during still another, knotted. After the first suture has been placed, gentle traction upon it steadies the heart while placing the others. (3) The pericardial wound might also be sutured in a perfectly clean case—but, practically, it is better to temporarily leave it open, lightly packing the mouth of the pericardial wound and carrying drainage through that part of the external wound not closed. (See Fig. 354.)

Comment.—When the needle enters the heart, there is a momentary stoppage, followed by brief tumultuous action.

XII. THE THORACIC TRACHEA.

SURGICAL ANATOMY.

See Trachea under Operations upon the Neck (page 548).

THORACIC TRACHEOTOMY

BY POSTERIOR MEDIASTINAL OSTEOPLASTIC FLAP OPERATION.

See Posterior Mediastinal Thoracotomy (page 593). The exposure and incision of the trachea in the posterior mediastinum is resorted to for the removal of foreign bodies situated too low in the trachea to be accessible and removable from a cervical tracheotomy wound.

XIII. THE BRONCHI.

SURGICAL ANATOMY.

Relations.—(1) **Right bronchus;** vena azygos major passes above bronchus from behind forward, on its way to superior vena cava; right pulmonary artery lies at first below and then in front of bronchus. (2) **Left bronchus;** passes beneath arch of aorta, resting upon esophagus, thoracic duct, and descending aorta; left pulmonary artery lies at first above and then in front of it.

Differences in the Bronchi.—(1) **Right bronchus;** about 2.5 cm. (about 1 inch) long; wider, shorter, and more horizontal than left; enters right lung opposite fifth dorsal vertebra. About 2 cm. (about $\frac{3}{4}$ inch) from origin, the upper or eparterial branch of bronchus is given off above right pulmonary artery to upper lobe of lung; the main bronchus, or hyparterial branch, passes below and behind right pulmonary artery and divides into two branches, for middle and lower lobes. (2) **Left bronchus;** about 5 cm. (about 2 inches) long; smaller, longer, and more oblique than right; enters left lung opposite sixth dorsal vertebra (about 2.5 cm., or 1 inch, lower than right). Left bronchus is entirely below left pulmonary artery (hyparterial), and divides into two branches, for upper and lower lobes. *Note.*—In majority of cases, right bronchus seems a more direct continuation of trachea

than left (that is, the dividing ridge between the two bronchi lies more to the left)—although the left is the more oblique in direction—wherefore, foreign bodies are more frequently lodged in the right bronchus.

Arteries.—Bronchial branches of thoracic aorta.

Veins.—Bronchial—emptying into vena azygos major on right side—and into superior intercostal vein on left.

BRONCHOTOMY.

Description.—Exposure and incision of the bronchial tubes. Generally resorted to for the removal of foreign bodies—and sometimes for the drainage of bronchiectatic cavities. The manner and site of the operation will depend upon the circumstances of the individual case—the manner of approach being by one of the procedures already described.

Where Bronchotomy is done for the removal of foreign bodies, the main bronchi are the ones usually opened—and are exposed through a Posterior Mediastinal Thoracotomy, by means of the osteoplastic flap operation described at page 593. The bronchi are opened as the trachea is opened in that operation—either directly over the foreign body—or at the site most accessible to the object—the object being sought, in the latter case, by slender, curved forceps introduced through the opening in the bronchus. Both the bronchial wound and the outer wound are treated as in the operation to which reference has been made.

Where Bronchotomy is performed to afford drainage in a case of dilated bronchial tube, in Bronchiectasis, the operation is practically the same as Pneumotomy for abscess, etc. The operation is rarely of much avail, unless it be practically a single, defined cavity in an accessible site, previously well located. (See Fig. 349, J.)

XIV. THE THORACIC ESOPHAGUS.

SURGICAL ANATOMY.

See Esophagus under Operations upon the Neck (page 557).

THORACIC ESOPHAGOTOMY

BY POSTERIOR MEDIASTINAL OSTEOPLASTIC FLAP OPERATION.

See Posterior Mediastinal Thoracotomy (page 593).

Exposure and incision of the esophagus in the posterior mediastinum are resorted to for the removal of foreign bodies situated too low in the esophagus to be accessible and removable from a cervical esophagotomy.

Having isolated the esophagus, as described in the operation mentioned, and having located the foreign body, the esophagus is steadied with toothed forecps, if necessary—an incision in its longitudinal axis is made—the lips of the wound are held apart by two pairs of toothed forceps, and the foreign body removed with appropriate forceps. The opening into the esophagus should be made upon its lateral aspect (generally the left aspect). The wound in the esophagus, in favorable cases, may be sutured with catgut—for drainage may take place into the stomach (where in a corresponding operation upon the trachea, or bronchi, drainage is by means of the external wound, and suturing of the trachea or bronchus is not indicated). Drainage is instituted from the wall of the esophagus through the outer wound. (See Fig. 249, K.)

LIBRARY.

CHAPTER V.

OPERATIONS UPON THE ABDOMINO-PELVIC REGION.

I. THE ABDOMINO-PELVIC WALL.

SURGICAL ANATOMY OF THE ABDOMINO-PELVIC WALL.

Boundaries of the Abdomino-pelvic Cavity.—Above; concave dome of diaphragm. **Below;** levatores ani and coccygei muscles ("diaphragm of pelvis"). **Laterally;** lower thoracic, and abdominal and pelvic walls.

Boundaries of Abdominal Cavity.—Superiorly; central tendon of diaphragm (rising to about inferior end of sternum, or seventh chondro-sternal joint); right half of diaphragm (to about level of fifth rib, or about 2.5 cm., or 1 inch, below right male nipple); left half of diaphragm (rising not quite so high as right); costal arches and ensiform process of sternum. **Inferiorly;** ileo-pectineal lines, laterally; crest of pubic bones, anteriorly; base of sacrum and sacro-vertebral angle, posteriorly; Poupart's ligaments, superficially.

Boundaries of Pelvic Cavity.—Superiorly; ileo-pectineal lines, laterally; crest of pubic bones, anteriorly; base of sacrum and sacro-vertebral angle, posteriorly. **Inferiorly;** Anteriorly; pubic arch and subpubic ligament; rami of os pubis and ischium;—Posteriorly; great sacro-sciatic ligaments and tip of coccyx;—Laterally; tuberosities of ischia.

Regions of the Abdomino-pelvic Cavity and Their Contents.—Basis of divisions; Two horizontal lines are drawn—one corresponding with the lowest part of the tenth costal arch—the other with the most prominent lateral points of the iliac crests;—and two vertical lines are made to intersect these passing upward from the center of Poupart's ligaments—thus forming the nine following regions (Quain);—**Epigastric;** most or all of left lobe of liver; part of right lobe of liver; gall-bladder; part of body and cardiac and pyloric orifices of stomach; first and second parts of duodenum; duodeno-jejunal flexure; pancreas; supero-internal part of spleen; parts of both kidneys; suprarenal bodies. **Right hypochondriac;** most of right lobe of liver; hepatic flexure of colon; part of right kidney. **Left hypochondriac;** portion of stomach; greater part of spleen; tail of pancreas; splenic flexure of colon; part of left kidney; part of left lobe of liver (sometimes). **Umbilical;** most of transverse colon; third part of duodenum; some convolutions of jejunum and ileum; part of mesentery; part of great omentum; part of right kidney (sometimes parts of both). **Right lumbar;** ascending colon; portion of right kidney; part of ileum (sometimes). **Left lumbar;** descending colon; part of jejunum; small part of left kidney (sometimes) **Hypogastric;** convolutions of ileum; bladder in children (and in adults when distended); gravid uterus; sigmoid loop; upper portion of rectum. **Right iliac;** cæcum, with vermiform appendix; end of ileum. **Left iliac;** sigmoid colon; convolutions of jejunum and ileum.

Apertures in the Abdominal Wall.—Above; those through the diaphragm (see that structure, page 596). **Below;** for femoral vessels; for spermatic cord. **Anteriorly;** umbilicus.

Structures of Antero-lateral Abdominal Wall.—(From without inward)—skin; superficial fascia, superficial and deep layers; general areolar tissue overlying external oblique muscle, and special intercolumnar fascia of external abdominal ring; external oblique and its aponeurosis; internal oblique and its aponeurosis; transversalis and its aponeurosis; rectus; pyramidalis; fascia transversalis; subperitoneal areolar tissue; peritoneum.

Structures of Posterior Abdominal Wall.—(1) Osseous Portion—five lumbar vertebræ and interarticular fibro-cartilages; postero-lateral portions of ilia;—(2) Soft Portion (from without inward)—skin; subcutaneous areolar tissue; lumbar aponeurosis (posterior layer); erector spinæ; lumbar aponeurosis (middle layer) attached to transverse processes of lumbar vertebræ; quadratus lumborum; lumbar aponeurosis (anterior layer); psoas; crura of diaphragm; kidney, areolar tissue, and colon; subperitoneal areolar tissue; peritoneum.

Arteries of Antero-lateral Abdominal Wall.—Superficial epigastric, superficial circumflex iliac, and superficial external pudic from femoral; lowest two intercostals from thoracic aorta; abdominal branches of lumbar arteries from abdominal aorta; ilio-lumbar from internal iliac; deep circumflex iliac and deep epigastric from external iliac; superior epigastric and musculophrenic from internal mammary.

Arteries of Posterior Abdominal Wall.—Lumbar branches of abdominal aorta.

Veins of Antero-lateral Abdominal Wall.—Correspond, chiefly, with the arteries.

Veins of Posterior Abdominal Wall.—Correspond, chiefly, with the arteries.

Lymphatics of Antero-lateral Abdominal Wall.—Superficial vessels above umbilicus empty into axillary glands:—superficial vessels below umbilicus empty into inguinal glands:—deep vessels above umbilicus empty into sternal glands (probably):—deep vessels below umbilicus empty into iliac glands.

Lymphatics of Posterior Abdominal Wall.—Median (aortic) lumbar glands:—lateral (psoas) lumbar glands.

Distribution of Nerves to Antero-lateral Abdominal Wall.—**Lower intercostal nerves;** emerging from intercostal spaces behind costal cartilages (except twelfth, which is subcostal), they pass forward between internal oblique and transversalis (generally intercommunicating here)—penetrate outer edge of sheath of rectus—supply rectus—pass through its substance—penetrate anterior layer of rectal sheath—and are distributed to skin. **Lateral cutaneous branches of lower intercostal nerves;** divide into Anterior Branches (to skin up to outer border of rectus, and superficial part of external oblique) and Posterior Branches (to skin of outer part of back). **Sixth intercostal;** supplies region between lower end of sternum and tip of ensiform cartilage. **Seventh intercostal;** distributed to region near lower end of ensiform cartilage. **Eighth intercostal;** runs up under cover of costal arch and supplies area of middle linea transversa, between tip of ensiform cartilage and umbilicus. **Ninth intercostal;** runs directly forward on level with ninth costal cartilage and supplies region just above umbilicus. **Tenth intercostal;** runs directly forward on level with tenth costal cartilage and supplies skin about umbilicus. **Eleventh intercostal;** runs forward and downward, supplying the region a little below the umbilicus. **Twelfth intercostal;** passes in front of quadratus lumborum, along lower border of twelfth rib—pierces transversalis and runs forward between transversalis and internal

oblique—(**a**) Anterior Branch of Twelfth Intercostal, penetrates rectus and is distributed below a point midway between umbilicus and pubis—(**b**) Lateral Cutaneous Branch of Twelfth Intercostal, penetrates internal oblique, then emerges from external oblique from 2.5 to 8 cm. (about 1 to 3 inches) above the iliac crest, and is distributed to skin over front of hip. **Ilio-hypogastric branch of first lumbar;** emerges from upper outer border of psoas —runs in front of quadratus lumborum to iliac crest—piercing transversalis posteriorly, and divides between transversalis and internal oblique, about 6.5 cm. (about 2½ inches) posterior to anterior superior iliac spine into—(**a**) Hypogastric Branch, passing forward between transversalis and internal oblique, pierces internal oblique, then pierces aponeurosis of external oblique about 2.5 cm. (about 1 inch) above and just to outer side of external abdominal ring, and supplies skin of hypogastric and external ring region,—(**b**) Iliac Branch, piercing internal oblique and external oblique directly above crest of ilium, and supplying skin of gluteal region posterior to lateral cutaneous branch of twelfth dorsal nerve. **Ilio-inguinal branch of first lumbar;** passes from outer border of psoas just inferior to ilio-hypogastric—runs obliquely across quadratus lumborum and iliacus—penetrates transversalis near anterior part of iliac crest (communicating here with ilio-hypogastric) —runs forward between internal oblique and transversalis, piercing internal oblique a little in front of anterior superior iliac spine—passes forward beneath aponeurosis of external oblique, accompanying cord through inguinal canal and emerging at external abdominal ring—supplying skin of upper and inner aspects of thigh—and scrotum in male, and labium in female.

Distribution of Nerves to Posterior Abdominal Wall.—Posterior divisions of lumbar nerves; dividing into internal and external branches. **Genitocrural nerve;** arising from first and second lumbar nerves, passes obliquely through psoas, emerging from its inner border opposite disc between third and fourth lumbar vertebræ—passing downward upon anterior surface of psoas and dividing, at outer side of external iliac artery, into—(**a**) Genital Branch, piercing fascia transversalis and descending on posterior part of spermatic cord through inguinal canal—emerging at external abdominal ring and supplying cremaster muscle in male, and round ligament in female.—(**b**) Crural Branch, descending on external iliac artery and piercing femoral sheath about 5 cm. (about 2 inches) below Poupart's ligament, to be distributed to skin of upper central part of thigh. **External cutaneous;** arising from second and third lumbar nerves, emerges from center of outer border of psoas and runs obliquely over iliacus muscle to notch just below anterior superior iliac spine, where it escapes beneath Poupart's ligament on to thigh. **Anterior crural; obturator; accessory obturator nerves**—descend to their distributions through the postero-lateral aspect of the abdomino-pelvic wall.

Summary of Distribution of Anterior Abdominal Nerves.—Seventh and eighth run upward and inward and supply upper third of abdominal wall;—ninth and tenth run nearly transversely inward and supply middle third;—eleventh and twelfth, and Ilio-hypogastric and Ilio-inguinal, run downward and inward and supply lower third of abdominal wall.

Anterior Sheath of Rectus.—Formed, above, by blending of aponeuroses of external oblique and outer lamella of internal oblique—below, by blending of aponeuroses of external oblique, internal oblique, and transversalis.

Posterior Sheath of Rectus.—Formed, above, by blending of aponeuroses of inner lamella of internal oblique and transversalis; next to which

come, in order, transversalis fascia, subperitoneal areolar tissue, and parietal peritoneum,—below semilunar fold of Douglas, by transversalis fascia alone; next to which come, in order, subperitoneal areolar tissue and parietal peritoneum.

Linea Alba.—A tendinous raphé, extending from ensiform cartilage to symphysis pubis, down median line of abdominal wall, and formed by the union of the aponeuroses of the obliquus externus and internus and the transversalis, between the inner margins of the rectus muscles. Most distinct just above the umbilicus. Practically absent below semilunar fold of Douglas —because from that line downward the aponeuroses of external oblique, internal oblique, and transversalis all pass in front of rectus (the linea alba being formed by the junction of the anterior and posterior aponeuroses which form the sheath of the rectus).

SURFACE FORM AND LANDMARKS OF THE ABDOMINO-PELVIC WALL.

Linea alba—extending from apex of ensiform cartilage to symphysis pubis —broader above, narrower below the umbilicus—incomplete posteriorly (only) in its lower fourth, where the transversalis fascia replaces it. One or both borders of the recti are apt to be incised in operating below the umbilicus. Represents junction of inner borders of aponeuroses of the flat abdominal muscles.

Lineæ semilunares—represent the line of division of the aponeuroses of the abdomen—correspond with the outer borders of the recti muscles—extend from lowest part of seventh costal cartilages to spines of os pubis, so curved that opposite the umbilicus they are 6 to 7.5 cm. ($2\frac{1}{2}$ to 3 inches) from the median line.

Lineæ transversæ—three tendinous intersections in the substance of the recti muscles, forming transverse furrows upon their surface—the upper one, opposite, or just below, the tip of the ensiform cartilage,—the middle one, between the tip of the ensiform cartilage and the umbilicus (about opposite the tenth costal cartilage),—the lower one, opposite the umbilicus,—(and sometimes a fourth one, below the umbilicus).

Semilunar fold of Douglas—below which the posterior sheath of the recti is formed by transversalis fascia alone—about opposite the junction of the upper three-fourths and the lower fourth of the recti muscles—about 3 cm. ($1\frac{1}{4}$ inches) below the umbilicus.

Abdominal furrow—extends from infrasternal fossa to, or a little below, the umbilicus, where it becomes lost. Its bottom is formed by the linea alba.

Umbilicus—situated in the linea alba—always above the level of the highest points of the crests of the ilia (generally from 2 to 2.5 cm., $\frac{3}{4}$ to 1 inch, above) —from 2 to 2.5 cm. ($\frac{3}{4}$ to 1 inch) above and to the inner side of the bifurcation of the abdominal aorta—opposite the tip of the third lumbar spine, or the intervertebral disc between the third and fourth lumbar vertebræ.

Spine of the os pubis—found by following up the tendon of the abductor longus—nearly on the same horizontal line as the upper edge of the great trochanter—gives attachment to the outer pillar of the external abdominal ring.

Anterior superior iliac spine—the most prominent landmark of the lower antero-lateral abdominal wall.

Crests of the iliac bones—continuations backward of the anterior superior iliac spines—found at the bottom of the iliac furrows, in the fleshy.

Poupart's ligament—represented by a line curved slightly downward, between the anterior superior iliac spine and the pubic spine.

Iliac furrow—corresponds to the iliac crests—and formed by the attachment of the external oblique muscles to these crests.

Sacral promontory—represented by a transverse line between the two anterior superior iliac spines.

Internal abdominal ring—situated about 1.3 cm. (½ inch) above the center of Poupart's ligament.

External abdominal ring—situated just superior and external to the crest of the os pubis.

Aponeuro-muscular limits of external oblique—the line representing the junction of the aponeurotic and muscular portions anteriorly, is one passing from the anterior superior iliac spine to the ninth costal cartilage (or one slightly anterior to these points);—The lower limit of the fleshy part of the external oblique is represented by a transverse line from a point on the iliac crest 2.5 to 5 cm. (1 to 2 inches) posterior to the anterior superior iliac spine, to a corresponding point on the opposite side. The fibers of the muscle and aponeurosis run about at a right angle with a line from the anterior superior iliac spine to the umbilicus.

Aponeuro-muscular limit of the internal oblique—Above, by an oblique line from a point below the anterior end of the twelfth rib extending upward parallel with the costal arch,—Internally, by a line extending from the middle of Poupart's ligament upward and slightly outward. The upper line marks the upper limit of the muscular part.

Aponeuro-muscular limit of the transversalis—the median limit of the fleshy part of the transversalis is nearer the middle line of the body above and below than at the center.

Deep epigastric artery—runs from a point just internal to the middle of Poupart's ligament upward and inward to the inner aspect of the internal abdominal ring—thence still upward and inward to about midway between the pubes and umbilicus—and, passing beneath the semilunar fold of Douglas, runs between the sheath of the rectus and the muscle, finally piercing the muscle.

Abdominal aorta—bifurcates about 2 cm. (¾ inch) below and to left of the umbilicus.

Cœliac axis—situated from 10 to 12.5 cm. (about 4 to 5 inches) above the umbilicus.

Superior mesenteric and suprarenal arteries—arise just below the cœliac axis.

Renal arteries—arise about 1.2 cm. (½ inch) below the superior mesenteric.

Inferior mesenteric—arises about 2.5 cm. (1 inch) above the umbilicus.

Peritoneal reflection from bladder on to lower abdominal wall—see under the Bladder, page 877.

Posterior superior spinous process of ilium—generally marked by a depression on a level with, and on either side of, the spinous process of second sacral vertebra.

Spinous process of third sacral vertebra—generally to be felt below the second sacral vertebra, which last is nearly always detectable.

Outer border of erector spinæ—generally felt by deep palpation made to the outer side of and parallel with the vertebral column. See Surgical Landmarks of the Kidney, page 839.

GENERAL SURGICAL CONSIDERATIONS IN OPERATIONS UPON THE ABDOMINO-PELVIC CAVITY.

Guide to the choice of special abdominal incisions—that incision should be chosen which most satisfactorily accomplishes the following (in order of importance):—free access—avoidance of nerves—separation of muscular and aponeurotic fibers rather than their division—avoidance of vessels.

Separation of the fibers of muscles and aponeuroses in their cleavage line should always be done in preference to a division of those fibers transversely or even obliquely.

Blood-vessels, as compared with nerves, are of secondary importance—though the deep epigastric artery (the most important of the abdominal wall), and its anastomosis with the superior epigastric of the internal mammary, should be spared when possible.

Better to cut through muscle than through aponeurosis (where cleavage separation is not possible)—as the former is more resistant to hernia (Hyrtl).

Median Incisions—available for parts most accessible thereby. Through a median incision above the umbilicus; the stomach, liver, pancreas, and intestines may be reached. Through a median incision below the umbilicus; the intestines, bladder, ureters, uterus, and ovaries may be reached.

Lateral Vertical Incisions—(along the outer border of the rectus)—not advisable ordinarily, as they divide the motor nerves to the rectus muscle, and thereby predispose to hernia. When done, generally done for the gall-bladder and ducts, duodenum, ascending and descending colons, spleen, and kidneys.

Transverse or slightly Oblique Incisions—preferable for reaching those sites laterally placed. The incisions are more or less parallel with the nerves—the muscles are separated in their cleavage lines, where possible, and retracted—the nerves are recognized in the intermuscular planes (especially between internal oblique and transversalis) and held to one side. This incision may be used for the appendix, ascending and descending colons, kidneys, stomach, liver, gall-ducts, intestines, and ureters.

Special Abdominal Incisions—see the different methods of abdominal section following.

In the above summary of abdominal incisions no hard-and-fast rule exists as to their application—it merely being meant to mention some cases in which each category of incisions may be used—more specific data being given under the different viscera.

All abdominal incisions should avoid, where possible, the anterior branches of the dorsal and lumbar nerves—which run obliquely from behind downward and forward between the muscular abdominal planes. The lower abdominal nerves run inwardly somewhat more transversely than do the fibers of the external oblique muscle and aponeurosis—so that in an oblique incision parallel with the fibers, one or more nerves may be encountered—but should be recognized, and can generally be spared.

All vertical incisions of the abdominal wall, of any length, except those in the median line, cut one or more nerves.

Vertical incisions over the center of the rectus divide the motor nerves to the inner half of the rectus muscle.

Long cutaneous and fascial incisions are harmless—and are desirable if thereby free access to the site be gained.

Longer incisions are necessary in the intramuscular separation than where the muscle-fibers are cut.

Longer incisions are necessary in very fat and thick abdominal walls.

Hernia is more apt to follow incisions in the lower than in the upper part of the abdomen—and in the anterior rather than in the lateral and posterior portions.

Linea alba is broader above than below the umbilicus, hence both inner rectal borders are more likely to be exposed by a median incision below than above the navel. If it be desired to identify the linea alba, after cutting through the superficial fascia, make a slightly oblique superficial incision over the median line—until the linea alba is recognized as a white fascial line or as a cord extending between the inner borders of the recti.

Pyramidales (one or both) may overlap the median line and their fibers may be divided in a median abdominal section performed low down.

Lineæ transversæ do not extend all the way through the rectus to its posterior aspect.

Avoid cutting through the umbilicus, ordinarily. Also pass slightly to its left to avoid the round ligament. Incision may be made directly through the center of the umbilicus itself—inclining slightly to the left just above it, to avoid the round ligament. Kelly mentions, after cutting through the umbilicus, that it is well, in closing the wound, to "split it on each side before putting in sutures, to convert the naturally thin surface between skin and peritoneum into a broader area for better approximation."

If the round ligament of the liver be cut during operation, no harm of consequence is done. It should be repaired with chromic gut suture.

Peritoneum is more loosely connected with the linea alba above and below the umbilicus—and more closely in the neighborhood of the umbilicus.

A transverse vessel in the subcutaneous fat, about 2 cm. ($\frac{3}{4}$ inch) above the symphysis pubis, is mentioned by Kelly, which spouts arterial blood from one side and venous blood from the other when cut. He also mentions one or more veins ("celiotomy veins") lying just over the peritoneum in the lower third of the linea alba, running very nearly parallel with the linea alba and ending in the vesical plexus at the neck of the bladder.

Empty the bladder before operating—and, if necessary, outline the bladder with a sound during operation.

In all operations involving the pelvic and lower abdominal regions, the Trendelenburg position is desirable—causing a displacement of the intestines and viscera above away from the field of operation. It should be assumed just before the operation and continued during it—at an angle of from 18 to 45 degrees, the average being about 30 degrees.

Intestines and viscera are best held out of the way by means of flat pads of sterilized non-absorbable cotton covered with non-absorbable gauze.

As soon as the peritoneum is incised, and in order to make less likely the stripping of the peritoneum from the muscular wall, a silk ligature may be passed into either lip of the peritoneum, including the muscular wall, and used as a retractor, after being knotted.

In incising the abdominal wall the peritoneum is at first only opened to a limited extent—the opening being increased after intra-abdominal examination by means of a finger introduced.

Avoid mistaking the transversalis fascia for subserous areolar tissue—and subserous areolar tissue for omentum—and especially intestine for peritoneum.

In cleansing the abdomino-pelvic cavity, the natural fossæ should receive especial attention—especially Douglas's cul-de-sac, rectal, duodenal, jejunal, renal, and cæcal.

Part or all of the omentum may be ligated off and removed.

Suture-materials—For peritoneum; fine, plain catgut. For fascial and

aponeurotic planes; chromic gut, kangaroo tendon, silk, silver wire. For muscles; chromic gut, plain gut, silk, kangaroo tendon. For subcutaneous tissue; plain or chromic gut, silk. For skin; silkworm-gut, silk (gut).

Avoid including omentum and intestinal walls in the tightening of sutures.

Just before tightening the last suture or two, press upon the abdominal wall to expel air or fluids.

Quilt sutures may be used for the fascial planes of suturing.

Relaxation sutures may be used—about 2.5 cm. (1 inch) apart, and from about 1.2 to 2 cm. (½ to ¾ inch) from the edges of the wound.

In all kinds of suturing the process is aided by the use of wound-hooks, which render the edges straight, parallel, and tense, and lift away the abdominal wall from the underlying intestines and viscera.

Sutures are removed from the tenth to the fifteenth day.

INSTRUMENTS USED IN OPERATIONS UPON THE ABDOMINO-PELVIC WALL.

Scalpels; probe-pointed bistoury; scissors, pointed and blunt, straight and curved; forceps, dissecting and toothed; artery-clamp forceps; retractors, various; probe; grooved director; tenaculum; wound-hooks; sponge-holders; aneurism-needle ; needles, curved and straight ; needle-holder; ligature-carriers; ligatures and sutures, plain and chromic gut, silk, silkworm-gut; gauze pads; drainage-tubes.

MEDIAN ABDOMINAL SECTION.

Description.—The opening of the abdominal or abdomino-pelvic cavity through an incision in the median line of the abdomino-pelvic wall. The site of this incision may be anywhere between the tip of the ensiform cartilage and the symphysis pubis—dependent upon the object of the operation. Abdominal section, except in cases where done for exploration, is generally but the preliminary step preceding some special operation.

Preparation.—Anterior abdominal wall shaved, especially along site of linea alba. Recesses of navel thoroughly cleansed. Bladder is emptied, especially if incision is to extend very low.

Position.—Patient supine, at edge of table, with arm beneath back. Operation-site is walled off with sterilized towels. Surgeon on right, cutting from above downward. Assistant opposite.

Landmarks.—Median line (linea alba). The center of the lower portion of the sternum, the umbilicus, and the suprapubic notch all are in the median straight line of the body in the normal abdomen.

Incision.—Is placed directly in the median line—above, below, or including the umbilicus, as indicated. If more room be needed than planned in the original incision, it may be gotten by continuing the incision upward or downward. After incising to within 5 cm. (2 inches) of the bladder, great care should be exercised and the bladder protruded away from the line of incision by the fingers of the left hand—for, although empty, if adherent unusually high, it may be wounded. In passing the site of the umbilicus the incision may be carried directly through its center, with a slight tendency to the left just above the umbilicus, to avoid the suspensory ligament of the liver—or may pass, when quite near the upper or lower aspects of the umbilicus, in a curved direction around it—the curve passing to the left, thereby

avoiding the round or suspensory ligament (the remains of the fetal umbilical vein) between the umbilical fissure of the liver and the umbilicus—which is, in consequence, left adherent to the right lip of the wound. (See Fig. 355, A and B.)

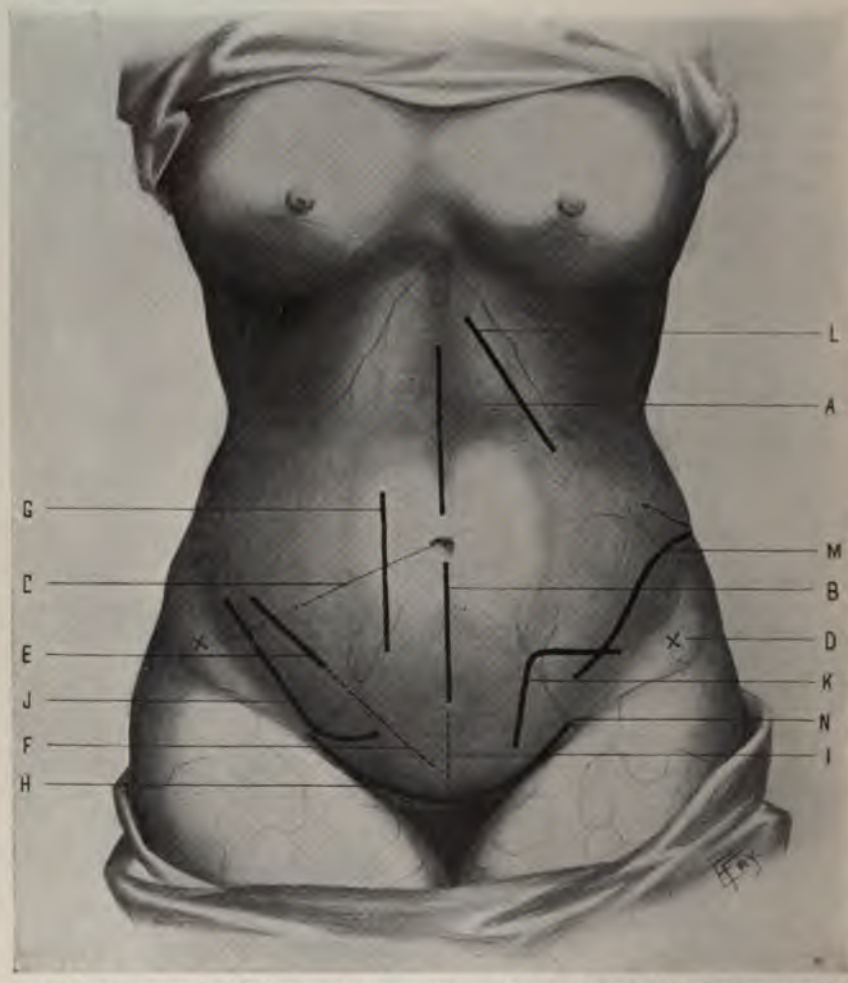

Fig. 355.—Incisions for Abdominal Sections:—A, Median Abdominal Section, supra-umbilical; B, Median Abdominal Section, infra-umbilical; C, Imaginary line from umbilicus to anterior superior iliac spine; D, Anterior superior iliac spine; E, Incision for McBurney's Intramuscular Abdominal Section; F, Incision (skin portion) for Weir's prolongation of the antero-lateral Intramuscular Abdominal Section; G, The Battle-Jalaguier-Kammerer Incision; H, Superficial transversely curved incision of Pfannenstiel's Median Inferior Abdominal Section; I, Deep vertical incision of Pfannenstiel's Median Inferior Abdominal Section; J, Meyer's "Hockey-stick" Incision; K, Fowler's Angular Incision; L, Oblique Subcostal Incision; M, Vischer's Lumbo-iliac Incision; N, Position of deep epigastric vessels.

Operation.—(1) Having steadied and rendered tense the abdominal wall by left thumb and forefinger (or middle finger) on either side of the median line, the incision is made the full length of the predetermined distance, at one clean sweep of the knife, passing through skin and connective tissue.

In very fat subjects the skin and thick fatty areolar tissue may be divided by two or three successive sweeps of the knife. Throughout the passage through the abdominal wall, all incisions should be made the full length of the original skin incision. (See Fig. 356.) (**2**) Clamp all bleeding vessels upon the lips of the wound, and subsequently tie with gut those likely to bleed. (**3**) Continuing to retract the lips of the wound with left thumb and

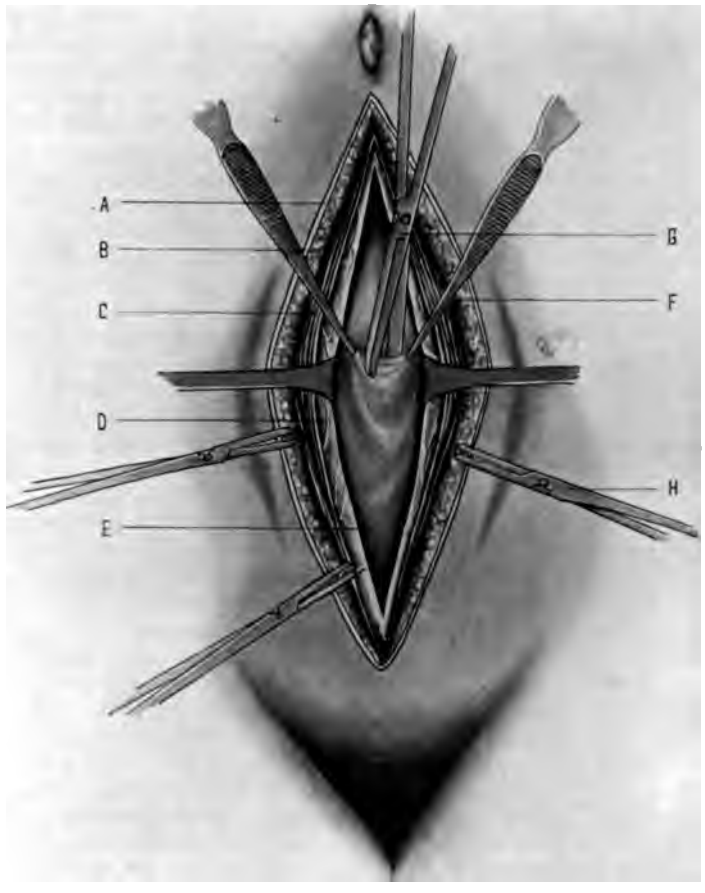

Fig. 356.—MEDIAN ABDOMINAL SECTION:—A, Skin; B, Fascia; C, Inner borders of the recti and pyramidales muscles; D, Transversalis fascia and subperitoneal areolar tissue; E, Peritoneum; F, Forceps grasping and lifting up the peritoneum; G, Scissors cutting through the fold of peritoneum made prominent by traction; H, Clamp-forceps controlling severed vessels.

forefinger, incise the aponeurosis of the recti directly to the median line. While aiming to cut between the inner margins of the recti muscles, along their line of junction, without dividing their muscular fibers, it is found, especially when operating below the umbilicus, that frequently one or both recti, together with their sheaths, are cut, or the pyramidales, where the latter overlap inwardly. The linea alba is not as distinct below the umbilicus as above it. In the upper three-fourths of the anterior abdominal wall,

directly in the median line, after passing through the skin and fascia, one divides the aponeurosis between the inner borders of the recti; and just to one side of the median line, one divides the outer layer of the rectal sheath, the rectus muscle, the inner layer of the rectal sheath (which inner layer is formed by the aponeurosis of the transversalis and inner lamella of the internal oblique). In the lower one-fourth of the anterior abdominal wall, directly in the median line, after passing through skin and fascia, one divides the aponeurosis between the inner borders of the recti; and just to one side of the median line, one divides the outer layer of the rectal sheath, the pyramidalis, the rectus muscle, and comes directly down upon the transversalis fascia, which here alone forms the posterior layer of the rectal sheath. All bleeding vessels encountered in passing through the aponeurotic and muscular planes of the abdominal wall are clamped or tied. (4) The fascia transversalis is now exposed in the whole length of the wound, lying beneath the posterior layer of the rectal sheath in the upper three-fourths of the linea alba—and forming the posterior layer in the lower fourth—and is similarly incised. (5) The subperitoneal areolar tissue lies between the transversalis fascia and the peritoneum, and is generally divided together with the transversalis fascia. It may be quite thick in the very fatty. All clamped vessels are now tied before opening the peritoneum. (6) The peritoneum is now encountered lying directly beneath the subperitoneal areolar tissue—its position being anticipated by a recognition of the structures and layers through which the incisions have passed—and its actual presence is further recognized by its commoner characteristics, available in the majority of cases—its glistening, bluish, arborescent surface, and tough nature (which are less available in adhesions and other abnormalities). Having controlled all bleeding, the peritoneum, the final barrier to the peritoneal cavity, is now to be opened. It is important that the peritoneum should be isolated from all underlying structures, and especially the intestines, before being incised. This is best done by picking it up lightly with a pair of toothed forceps, in the form of a small fold. Thus grasping the peritoneum, the forceps should be shifted laterally and vertically to determine that they hold nothing in their teeth but peritoneum alone. Should intestines, omentum, or other structures have been grasped, in addition to the peritoneum, a new and lighter hold should be taken. While thus held in the grasp of the forceps—or, better still, between the grasps of two pairs of forceps, one held by the surgeon and the other by the assistant—the peritoneum is at first opened to a very limited extent, by making a carefully guarded scissors-cut or knife-incision, in the median line, near the tip of the single pair of forceps—or between the tips of the double pair. One limb of a pair of straight, blunt scissors, or a probe-pointed bistoury, is now introduced into this small opening, and the incision enlarged by cutting in the median line—introducing the left first and second fingers as a guide (formed by their palmar surface) as soon as sufficient opening has been made—after which the peritoneal opening is enlarged to correspond with the length of the rest of the wound, which should nowhere be funnel-shaped, but of equal depth throughout. (7) Having opened the peritoneum and widely retracted the lips of the abdominal wound, the special object for which the abdominal section was made is now carried out. (8) Having completed the object of the operation, and prior to closing the abdominal wound, the abdominal cavity should be cleansed of all fluid, by means of gauze mops or sponges—especially in the regions of Douglas's pouch, in the female, the iliac fossæ, the renal and hepatic regions, and among the intestinal coils and recesses. Where the abdominal cavity has been extensively soiled,

especially by tenacious fluids, a general flushing of the cavity may be indicated, until the irrigating fluid comes away clear, followed by light sponging with gauze mops. Having cleansed the cavity, stopped all bleeding by ligature, and counted all instruments and sponges, or pads, used in the operation, the abdomen is ready for closure. (9) Several methods of suturing the lips of the wound are in use. Preceding the adoption of any particular method, the underlying intestines and viscera are protected and held out of the way by a broad pad of absorbable gauze. This pad also absorbs any suture-bleeding which may occur, and remains *in situ* until nearly the entire length of the deepest layer (or nearly all of the single layer, where but one layer of sutures is used) is placed and tied (if interrupted), or tightened (if continuous)—and is then withdrawn through one end. (a) Interrupted sutures of all layers in a single tier:—Having armed a fully curved needle, held in a needle-holder, with fairly stout silk, the sutures are passed from without into the abdominal cavity through one wound-lip, and thence outward through the opposite, passing through all of the constituents of each lip, in the following manner: While the lips of the wound are held under slight tension by wound-hooks at either end, the surgeon grasps the entire thickness of one lip between his left thumb and finger and sees that all of the component structures of that lip are brought into line at the margin of the wound, so as to be within bite of the point of the needle. This is particularly necessary in the case of the peritoneum, which is often partially separated from the rest of the abdominal wall in the subperitoneal areolar plane and is thus apt not to be included in the suture. While thus holding the lip of one side, the needle is passed from without inward, passing through all the structures of the lip at the same distance from their free edge and entering the abdominal cavity. The opposite lip is similarly grasped and the needle similarly passed but from within outward, emerging at a corresponding point on the side opposite to that entered. Each of the in-

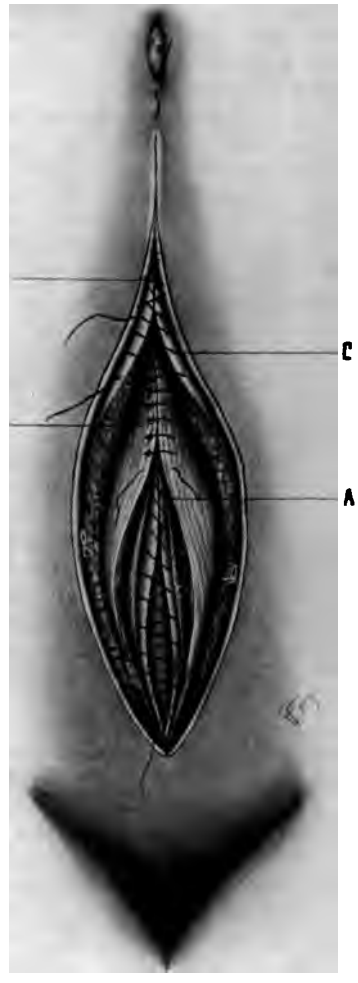

Fig. 357.—Tier-suturing of the Wound following Median Abdominal Section:—A, Continuous suture approximating edges of peritoneum; B, Interrupted suture bringing together the cut margins of the subperitoneal areolar tissue, transversalis fascia, and recti and pyramidales muscles (and also the aponeuroses of the rectal sheaths); C, Continuous suture of the fascia; D, Continuous subcuticular suture of the skin.

terrupted sutures will penetrate the lips of the wound at about 0.5 cm. ($\frac{3}{16}$ inch) from their edge, and will be about 1 cm. ($\frac{3}{8}$ inch) apart. When all are placed, the free ends of the sutures on either side should be grasped and drawn upon, to see if the lips come well and evenly together. While the lips are still under tension the sutures are tied, generally beginning at one or the other end. Just prior to completing the tying, the gauze pad over the intestines must be withdrawn. Superficial sutures may be put through the skin and connective tissue between the others, if necessary. Where much tension exists, deep relaxation sutures, placed about 1.2 cm. ($\frac{1}{2}$ inch) from the lips of the wound, and about 2 cm. ($\frac{3}{4}$ inch) apart, may be placed. Chromic gut may be similarly used. Silkworm-gut may be used, but requires especial care in tying the knot. (b) Tier-suturing:—First Tier—peritoneum. (To shut off the abdominal cavity.) A buried, continuous (may be interrupted), fine, chromic catgut suture, passed upon a straight needle, at a distance of about 0.3 cm. ($\frac{1}{8}$ inch) from the edge. Second Tier—aponeuroses of rectal sheath, including transversalis fascia and subperitoneal areolar tissue, and margins of recti where they have been cut. (Chief suture of strength.) Interrupted, buried, chromic catgut suture, introduced upon a curved needle, about 0.5 cm. ($\frac{3}{16}$ inch) from the edge and about 1 cm. ($\frac{3}{8}$ inch) apart. Third Tier—subcutaneous areolar tissue, that is, all tissues between the outer layer of the rectal sheath and the skin. (To obliterate dead spaces.) A continuous, buried, chromic catgut suture, introduced upon a straight needle. Fourth Tier—skin. (To shut off outside contamination.) A continuous, subcuticular silk suture passing through the tough corion, introduced upon Keith's long, straight abdominal needle. (See Fig. 357.) Interrupted silkworm-gut may be used for the fourth tier (though stitch-abscesses are more frequent). Or strong, fine catgut may be used—and need not be removed. Interrupted silk sutures are often used. The tier method of suturing is preferable to the single-layer suture. Often but three tiers are used—Continuous chromic suture of peritoneum;—Interrupted chromic gut suture of subperitoneal and transversalis fasciæ, rectal aponeuroses (or recti themselves) *en masse*;—Interrupted silkworm-gut, or silk suture, of skin and subcutaneous fascia. Sometimes only two tiers are used—Continuous chromic gut of peritoneum;—and Interrupted silk or chromic gut of the remaining tissues. (10) No drainage is ordinarily used. Several layers of gauze and cotton are placed over the wound—and one of the various forms of abdominal binders applied.

Complications Occurring during Abdominal Section.—(a) **Adhesions;**—(1) Adhesions of the intestines, viscera, or omentum with each other, or with the parietal wall, may be encountered. (2) When, in the presence of adhesions, there is doubt as to whether the peritoneal cavity has been reached, pick up and roll the tissues between the finger-tips, thus judging of their nature. (3) The general principle to be adopted in the management of adhesions is to find the plane of cleavage in the abnormal union—and, following it up, separate it as carefully as possible by fingers or blunt dissection. Where this is impossible, areas, dependent upon their nature, have to be ligated or clamped and cut, with the sacrifice of some portion of the least important structure. Ligatures are best made with plain gut for small adhesions, and chromic gut for large adhesions. While slighter adhesions may be mechanically separated, denser ones are to be clamped or ligated, *en masse* or piecemeal, and cut. (4) Intestinal Adhesions. Thin membranous adhesions may be stripped apart. Dense, organized adhesions must be separated by careful dissection, requiring especial care, as no part of the entire thickness

of the adhesion can be taken from the one and left as a patch on the other, as may be done in some adhesions in other localities. (5) Omental Adhesions. These must be stripped off, or ligated and excised. The entire omentum may be ligated and excised, if necessary. Omental adhesions are ligated on their proximal side—by pushing forceps through the free spaces and drawing back the gut ligature and tying—and repeating the step, always tying over the free edge left by the preceding ligature. See Omentum, page 652. (6) Visceral Adhesions:—Where separation cannot be accomplished—and where the step is possible, a layer, or the entire thickness, of the less important structure is left attached to the more important one—after ligaturing and blunt dissection or incision. The serous covering of the viscera should be preserved wherever possible—thereby aiding in the preservation of nutrition and the avoidance of adhesions and sloughing. Such denuded surfaces may have omental grafts applied. See Omentum, page 652. In the median abdominal section it is to be remembered that an adherent bladder, though empty, may not be able to descend out of the way of the incision,—and thereby may not escape injury unless specially guarded. For further consideration of adhesions, see the Peritoneum, page 647. Also see Fig. 362. (B) **Hemorrhage**:—Tie, where possible, all vessels prior to their division, or immediately afterward—as encountered in the steps of the operation after entering the abdominal cavity. Vessels which have been cut without recognition, should be immediately clamped and then tied. In the abdominal incision, prior to entering the cavity, the vessels are clamped as cut and tied before opening the peritoneal cavity. Gauze pressure and hot douching often control bleeding from indefinite sources. (C) **Irrigation**:—Unless the abdominal cavity be contaminated or soiled, or unless much hemorrhage have occurred, irrigation is generally not indicated. If indicated, hot normal salt solution is used. Localized infection can often be treated by localized flushing and wiping—general infection by general flushing and drying with gauze mops. (D) **Drainage**:—Not indicated in uncomplicated cases. Indicated in (a) Localized and general infection (in the former, generally—in the latter always),—(b) After intestinal or hollow-visceral suturing, where there is uncertainty of efficiency of the suturing or integrity of the intestine or viscus,—(c) In persistent hemorrhage. Nature of drainage materials,—gauze, rubber tubing, glass tubing, strands of gut, silk, or horsehair. Where drainage is used, the wound should have the suturing placed throughout, and just as though the entire wound were to be closed—and those at first left untied for the passage of the drain, should be tightened and tied when all occasion for drainage has ceased.

Comment.—See under General Surgical Considerations, page 629.

ANTERO-LATERAL ABDOMINAL SECTION.

BY McBURNEY'S INTRAMUSCULAR ("GRIDIRON") INCISION.

Description.—Having divided skin and fascia, the various musculo-aponeurotic planes of the abdominal wall are divided in the order encountered and in a line with the muscular and tendinous fibers composing those planes—thus avoiding the division of any important nerves; the transverse division of any of the component muscular fibers; the retraction of transversely cut muscular and tendinous fibers—and, therefore, avoiding the consequent paralysis of parts supplied by severed nerves, and weakening of cut muscles.

While McBurney's operation is chiefly applicable to the antero-lateral abdominal region (where the external and internal oblique and the transver-

salis muscles are all present), the principle of intramuscular separation should be applied to all sites of the abdominal wall where it is possible to do so. The operation is principally resorted to for the removal of the appendix vermiformis, especially in the quiescent stage of appendicitis.

Preparation.—Site of incision to be shaved.

Position.—As in Median Abdominal Section.

Landmarks.—Where the operation is done in connection with Appendicectomy, McBurney's point is located, which is a point on an imaginary line extending from the anterior superior iliac spine to the umbilicus, at a distance of 3.8 cm. (1½ inches) internal to the anterior superior iliac spine.

Incision.—In cases of Appendicectomy, the incision commences about 2.5 cm. (1 inch) above the imaginary line just mentioned, and passes obliquely downward and inward in the direction of the fibers of the external oblique

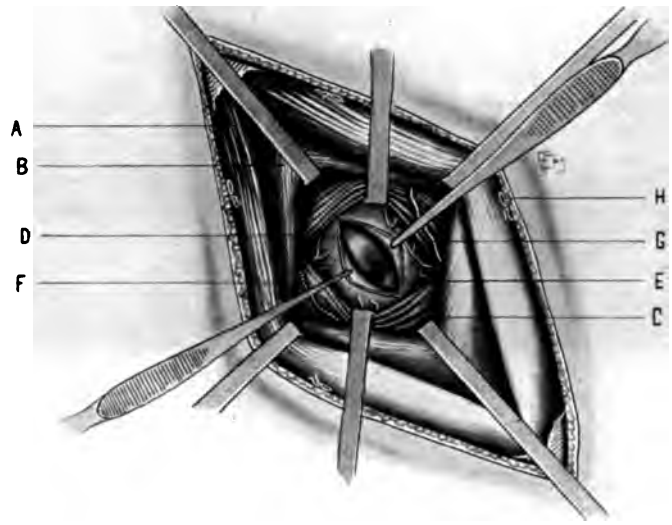

Fig. 358.—Antero-lateral Abdominal Section by McBurney's Intramuscular ("Grid-iron") Incision:—A, External oblique muscle; B, Internal oblique muscle; C, Transversalis muscle; D, Transversalis fascia, subperitoneal areolar tissue, and peritoneum; E, Coils of small intestine; F, Branch of deep circumflex iliac, or of one of the lumbar arteries; G, Twelfth intercostal, or iliohypogastric nerve; H, A superficial vessel.

muscle and aponeurosis—crossing the above line at McBurney's point—and ending about the same distance below as above it. The length of the incision may be greater or less than the above, according to the space required. A free skin incision greatly aids the muscular retraction. (See Fig. 355, E.)

Operation.—(1) Having incised the skin and fascia in the above line (which will correspond with the cleavage line of the skin), and having controlled hemorrhage and retracted the lips of the wound, the muscular and tendinous fibers of the external oblique will be exposed. (See Fig. 358.) (2) Incise the external oblique, with a sharp scalpel, directly in a line with its muscular fibers above, and their tendinous continuation in the aponeurosis below—continuing the separation with scalpel or scissors, incising between the fibers without severing them. The two lips of the incised external oblique are drawn respectively upward and inward, and downward and outward—

thus exposing the intermuscular fascia between external and internal oblique. (3) The sheath and fibers of the internal oblique (the muscle being here quite thick) are now similarly separated by scalpel, scissors, or blunt dissection, in the line of their cleavage (which is nearly at a right angle to the cleavage line of the fibers of the external oblique), the center of the separation of the fibers being about opposite the anterior superior iliac spine. The lips of the internal oblique are now retracted respectively upward and outward, and downward and inward—thus exposing the intermuscular fascia between internal oblique and transversalis. Guard with especial care all nerves lying in this intermuscular plane. (4) The fibers of the transversalis, which, for practical purposes, run very nearly in the same direction as those of the internal oblique, are now similarly separated in their cleavage line. The lips of the transversalis may be separately retracted upward and downward, but are generally included in the grasp of the same retractors which retract the internal oblique. The transversalis fascia at the bottom of the wound is thus exposed for an inch or more. (5) The transversalis fascia is grasped with forceps and divided in the line of the transversalis muscle (transversely)—when the subserous areolar tissue and peritoneum will be exposed. (6) The peritoneum is grasped with two delicate-toothed forceps, manipulated as in the median abdominal section, and divided with scissors to a limited and guarded extent. One blade of the scissors is then carefully introduced within the abdominal cavity and the opening enlarged toward the median line and the anterior superior iliac spine. The subperitoneal areolar tissue, transversalis fascia, and peritoneum may be simultaneously incised—but it is better to incise down to and recognize the peritoneum, and then incise the peritoneum separately and alone. (7) The special object of the operation is now accomplished. The wound is then ready for closure. (8) Separate continuous suturing of the following layers with catgut is made;—(a) peritoneum, subserous areolar tissue, and transversalis fascia—(b) transversalis—(c) internal oblique—(d) external oblique—(e) subcutaneous fascia, especially where thick—(f) and the skin is closed by subcuticular silk suture, or interrupted silkworm-gut. The subcutaneous areolar tissue and skin are often included in one tier, where interrupted suturing of these two structures is done. All parts are thus brought together along their original cleavage lines and accurately approximated.

Comment.—(1) But small part of the muscular portion of the external oblique is exposed. (2) The twelfth intercostal nerve, and, when the incision is long, the iliohypogastric nerve are in danger (as they run somewhat more transversely than the fibers of the external oblique) and should be retracted out of danger. (3) This is the best method of entering the abdominal cavity, where applicable.

ANTERO-LATERAL ABDOMINAL SECTION

BY WEIR'S PROLONGATION OF THE ANTERO-LATERAL INTRAMUSCULAR INCISION THROUGH THE RECTAL SHEATH, WITH TEMPORARY DISPLACEMENT OF THE RECTUS.

Description.—Having entered the abdominal cavity by the intramuscular operation just described, an extension or enlargement of that incision, with a fuller exposure of the abdominal, pelvic and iliac cavities, may be obtained by continuing that incision to the outer border of the rectal sheath, tearing off the "denuded fascia of the external oblique muscle," incising transversely the remaining structures forming the anterior layer of the rectal sheath and

displacing the rectus muscle toward the median line, followed by the transverse division of the posterior rectal sheath. While the operation is chiefly applicable to the region of the appendix, it may be used on either side of the abdomino-pelvic region, and also in the region of the liver and gall-bladder where additional room is necessary. It will be here described in connection with appendicectomy.

Preparation—Position.—As in McBurney's Intramuscular Operation (page 637).

Landmarks.—McBurney's point (see McBurney's Operation, Landmarks, page 638); linea alba; semilunar line.

Incision.—Begins as an ordinary McBurney intramuscular incision—and, after prolonging the incision to the outer border of the rectus, and after

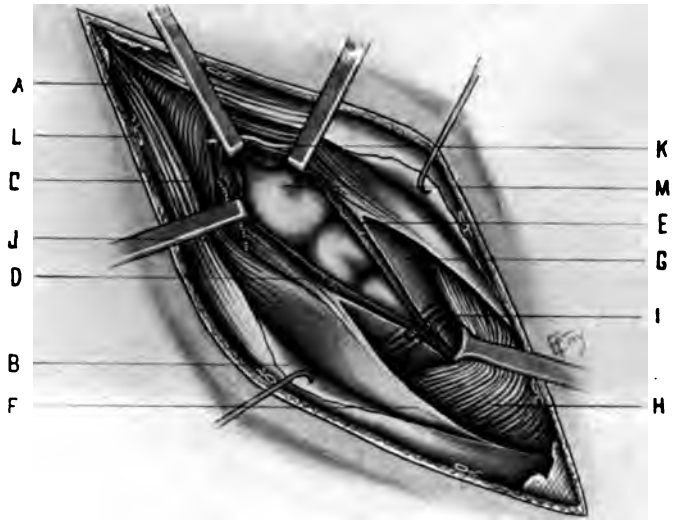

Fig. 350.—ANTERO-LATERAL ABDOMINAL SECTION BY WEIR'S METHOD:—A, External oblique muscle; B, External oblique being separated from the anterior layer of the rectal sheath; C, Internal oblique muscle; D, Transversalis muscle; E, Transversalis fascia, subperitoneal areolar tissue, and peritoneum; F, Anterior layer of rectal sheath; G, Posterior layer of rectal sheath; H, Rectus muscle; I, Deep epigastric vessels; J, Branch of deep circumflex iliac, or of one of lumbar arteries; K, Twelfth intercostal, or iliohypogastric nerve; L, A superficial vessel; M, Coils of small intestine.

tearing off and retracting inward the fascia of the external oblique from the sheath of the rectus, the incision is continued across the anterior layer of the sheath of the rectus in a prolongation of the same line with the intramuscular opening into the peritoneum (or may be continued transversely across)—followed by the inward retraction of the rectus muscle and transverse division of the posterior rectal sheath. (See Fig. 355, F.)

Operation.—(1) Proceed exactly as in the McBurney operation, up to the point of entering the abdominal cavity—whether operating upon the right or left side. (2) Continue the separation of the fibers of the external oblique muscle and aponeurosis, in the line of their cleavage, right up to the linea semilunaris (outer border of the rectal sheath). Also continue the separation of the fibers of the internal oblique and transversalis until the inner aspect of the common opening is brought up to the outer margin of the rectal sheath.

(See Fig. 359.) (3) The already denuded fascia of the external oblique is now separated by blunt dissection from the anterior layer of the sheath of the rectus, from the linea semilunaris inward to the median line—retracting or dividing the overlying structures where necessary. (4) While the denuded and displaced fascia of the external oblique is held retracted, the remaining structures forming the anterior layer of the rectal sheath (aponeuroses of internal oblique and transversalis) are divided transversely, or slightly obliquely, inward, in a line continuing the external oblique intramuscular incision—or, if the abdominal cavity have been already opened and more room be needed, in a line with the intramuscular opening into the peritoneum. (5) Separate the outer border of the rectus from its sheath and retract the muscle inward as far as necessary, lifting it away from the posterior layer of the sheath. (6) Doubly ligate and divide the deep epigastric artery and veins lying upon the transversalis fascia—unless they may be temporarily displaced by retraction. (7) Incise transversely the posterior layer of the sheath of the rectus (which, in the lower part of the abdomen, consists of transversalis fascia alone) and peritoneum, both in the same line as the incision through the anterior layer—thus opening up the abdomino-pelvic cavity toward the median line. (8) The abdominal, pelvic, and iliac cavities are thus exposed and the object of the operation accomplished. (9) The suturing of the general wound is done as in the McBurney operation (page 639, paragraph 8). In closing the portion involving the rectal sheath, the posterior layer of the sheath is sutured with continued catgut—the rectus muscle is then allowed to fall back into place—and the anterior layer of the sheath is similarly closed.

Comment.—Additional exposure is secured by the Trendelenburg position, or by sand-bags under the hips. This is the best one of the modifications of the intramuscular operation, for giving increased room.

ANTERIOR ABDOMINAL SECTION THROUGH THE RECTAL SHEATH, WITH TEMPORARY DISPLACEMENT OF THE RECTUS,

BY THE BATTLE-JALAGUIER-KAMMERER METHOD.

Description.—Consists, after a vertical incision of skin and fascia, in the vertical division of the anterior layer of the sheath of the rectus, with the retraction of the entire rectus inward—followed by the vertical division of the posterior layer of the rectal sheath, somewhat nearer the median line, together with the subserous areolar tissue and peritoneum. At the end of the operation the rectus is allowed to resume its normal position, and the divided rectal sheath is repaired. Chiefly used in the quiescent stage of appendicitis—and also applicable in some operations upon the stomach, liver, and gall-bladder.

Preparation—Position.—As in Median Abdominal Section.

Landmarks.—Linea alba and linea semilunaris, forming, respectively, the inner and outer boundaries of the rectal sheath.

Incision.—Vertical incision about 7.5 cm. (3 inches) long, and calculated, as nearly as possible, to fall from 1 to 2.5 cm. ($\frac{3}{8}$ to 1 inch) internal to the outer border of the rectus. (See Fig. 355, G.)

Operation.—(1) Incise skin and fascia in the above line—clamp vessels—retract overlying tissues—and expose the rectal sheath. (2) Incise the anterior layer of the sheath of the rectus vertically, at a distance of from 1 to 2.5 cm. ($\frac{3}{8}$ to 1 inch) internal to its outer border. (See Fig. 360.) (3) Retract outward the outer portion of the divided rectal sheath, so as to expose the

outer border of the rectus muscle—and then retract the intact rectus muscle inward. (4) Incise the posterior layer of the rectal sheath somewhat nearer the median line than in the case of the anterior layer. Or, in operating in the neighborhood of the deep epigastric artery, in order to avoid this vessel, the incision in the posterior layer may be made somewhat further outward than the incision through the anterior layer. The artery may, however, be readily ligated if in the way. (5) In the same line as the division of the posterior layer of the rectal sheath, incise vertically the subjacent tissues—which will consist of transversalis fascia, subperitoneal areolar tissue, and peritoneum, except below the semilunar fold of Douglas, below which line

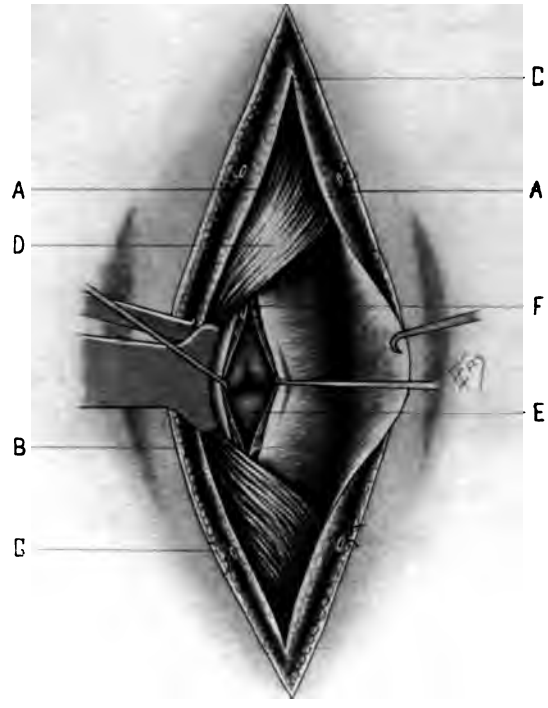

Fig. 360.—Abdominal Section by the Battle-Jalaguier-Kammerer Incision:—A, A, Anterior layer of rectal sheath; B, Posterior layer of rectal sheath; C, Incision through anterior layer of rectal sheath; D, Left rectus muscle displaced toward median line; E, Incision through posterior layer of rectal sheath (further toward median line than incision through outer rectal sheath) exposing coils of intestine; F, Transverse fascia, subperitoneal areolar tissue, and peritoneum; G, A superficial vessel.

the posterior layer of the sheath itself consists of transversalis fascia alone, and the subjacent tissues consist of subperitoneal areolar tissue and peritoneum. (6) Having accomplished the object of the operation, the structures are to be sutured in the following layers,—peritoneum, subserous areolar tissue, and posterior layer of the rectal sheath, with interrupted or continuous catgut suture;—anterior layer of rectal sheath with interrupted gut sutures, which also pass partly through the rectus muscle (the displaced border of the rectus should also be sutured to the outer margin of the rectal sheath);—the fascia with gut—and the skin with subcuticular silk, or interrupted silk-worm-gut sutures (or skin and fascia may be sutured together).

Comment.—The chief objection to the operation is the division of the nerves corresponding with the incision, and consequent atrophy and paresis of the rectus. The nerves severed in the site where the operation is usually performed (for appendicitis) being generally the tenth, eleventh, and twelfth dorsal, with or without the iliohypogastric. The deep epigastric artery is usually divided, although this is of no great consequence.

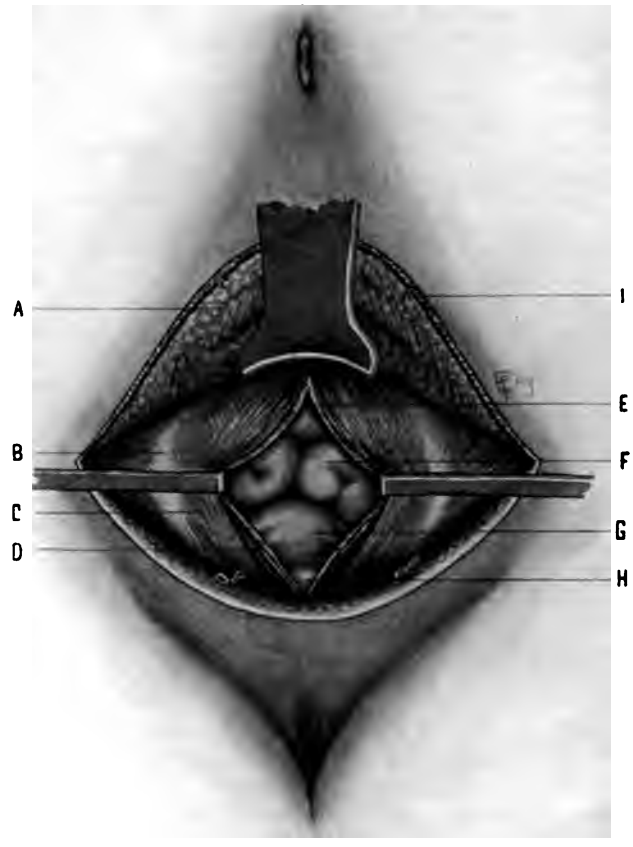

Fig. 361.—Abdominal Section by Pfannenstiel's Superficial Transversely Curved and Deep Vertical Incisions:—A, Flap, with anterior layer of rectal sheath adherent, turned upward; B, Linea semilunaris; C, Rectus muscle; D, Pyramidalis muscle; E, Transversalis fascia, subperitoneal areolar tissue, and peritoneum; F, Coils of small intestine; G, Uterus; H, Bladder; I, A superficial vessel.

MEDIAN INFERIOR ABDOMINAL SECTION

BY PFANNENSTIEL'S SUPERFICIAL TRANSVERSELY CURVED AND DEEP VERTICAL INCISIONS.

Description.—A method of entering the peritoneal cavity in the lower median abdominal region—by means of a superficial curved incision, with downward convexity, just above the inner halves of Poupart's ligaments and the symphysis, with an upward retraction of the outlined flap of skin, fascia,

and anterior rectal sheath—followed by a deep vertical division in the median line. A median scar is avoided, and the transverse scar lies partly hidden by the hair-line. Hernia is supposed to be less apt to follow. Chiefly used for limited operations upon the tubes, ovaries, uterus, bladder, and pelvic cavity.

Preparation—Position.—As for Median Abdominal Section.

Landmarks.—Linea alba; position of deep epigastric arteries; Poupart's ligaments; symphysis pubis.

Incision.—(1) Superficial transversely curved incision, with downward convexity, beginning and ending over the deep epigastric arteries, passing just above the inner halves of Poupart's ligaments and the symphysis pubis, in the hair-line;—(2) Deep vertical incision, after the anterior layer of the rectal sheath has been retracted, passes between the inner borders of the recti muscles, in the median line, from just above the symphysis pubis upward. (See Fig. 355, I and H.)

Operation.—(1) Incise skin, fascia, and anterior layer of rectal sheath in the superficial transversely curved incision. Clamp vessels. Dissect and retract the curved flap thus formed upward, including the anterior rectal sheath, thereby exposing the bared recti muscles. (See Fig. 361.) (2) Incise between the inner borders of the recti and pyramidales muscles, just as in median abdominal section, until the peritoneal cavity is reached, which is entered just as in that operation. (3) Having accomplished the object of the operation, the wound is sutured in the following manner;—the posterior layer of the rectal sheath is closed with continued catgut suture, including the edges of the peritoneum and subserous areolar tissue—the inner margins of the recti are next sutured with gut—the cut edge of the transversely divided anterior rectal sheath is similarly sutured with gut—and the skin wound is closed with silk, or silkworm-gut.

Comment.—Care is necessary to avoid wounding the bladder, which should be empty at the time of operation.

INFERIOR ANTERO-LATERAL ABDOMINAL SECTION

BY MEYER'S "HOCKEY-STICK" INCISION.

Description.—A method of entering the lower antero-lateral abdominal cavity, partly by intramuscular separation, partly by transverse division of muscle, by means of an incision shaped somewhat like a "hockey-stick." Resorted to for the purpose of gaining a greater degree of exposure of the abdomino pelvic cavity than afforded by the simple McBurney incision. Used by its originator for some complicated cases of appendicitis.

Preparation—Position.—As in McBurney's Operation.

Landmarks.—Imaginary line from umbilicus to anterior superior iliac spine, with the location of McBurney's point (see McBurney's operation, Landmarks, page 638); Poupart's ligament; outer border of the rectus; deep epigastric artery.

Incision.—(1) Primary Incision,—begins about 1.3 cm. (½ inch) above an imaginary line from the umbilicus to the anterior spine of the ilium, at a point 2 cm. (¾ inch) to the inner side of the anterior superior iliac spine (that is, midway between McBurney's point and the anterior superior iliac spine), and passes thence in a direct line toward the point where the femoral artery runs under Poupart's ligament, ending about 1.3 to 2 cm. (½ to ¾ inch) above Poupart's ligament. (2) Secondary incision, which is only made sub-

sequently, for the purpose of gaining more room, passes upward and inward, or curves directly inward, from the lower end of the primary incision toward the outer border of the rectus. (See Fig. 355, J.)

Operation.—(1) Incise skin and fascia in the line of the primary incision—clamp vessels—and retract margins of wound. (2) Split the fibers of the external oblique muscle and its aponeurosis in their cleavage line. (3) Divide the internal oblique and transversalis in the same line as made by the separation of the fibers of the external oblique—which will cut the fibers of the internal oblique transversely and those of the transversalis obliquely. (4) Incise the transversalis fascia, subserous areolar tissue, and peritoneum transversely. (5) If more room be now necessary, the left index is passed into the abdominal cavity to the deep epigastric artery, as a guide and protector, and the lower end of the incision is extended upward and inward, or directly inward, to the outer border of the rectus muscle. (6) If still more room be needed, the rectus muscle itself can be displaced inward and the peritoneum incised beneath it. (7) The object of the operation is now accomplished. The wound is then closed by tier-suturing.

Comment.—The deep epigastric vessels are doubly ligated and divided, if necessary.

INFERIOR ANTERO-LATERAL ABDOMINAL SECTION

BY FOWLER'S ANGULAR INCISION.

Description.—Founded, in part of its application, upon the same principle as McBurney's intramuscular operation—and planned to give freer access to the contents of the ileo-cæcal region, and especially to the base of the appendix. Especially intended by its author for cases of appendicitis in which the process is still limited to the appendix.

Preparation—Position.—As in McBurney's operation.

Landmarks.—Anterior superior iliac spine; outer border of the rectus.

Incision.—Begins at the upper border of the anterior superior iliac spine—runs horizontally inward to the outer border of the rectus muscle—curves thence downward and runs parallel with the outer border of the rectus for 5 to 7.5 cm. (2 to 3½ inches). (See Fig. 355, K.)

Operation.—(1) Incise skin and fascia in the above line—clamp vessels—and turn downward and outward this triangular flap of skin and fascia, exposing the aponeurosis of the external oblique beneath. Place retractors at the center of the transverse incision and at the lower angle of the wound, and retract in the cleavage line of the external oblique. (2) Incise the external oblique muscle and aponeurosis in the cleavage line of their fibers, and retract in the direction opposite to their cleavage line. (3) Expose and open the sheath of the rectus and retract the rectus muscle, with the deep epigastric vessels, strongly toward the linea alba—while retracting the aponeurosis to the outer side. (4) Incise transversely, in line with the horizontal part of the skin incision, the internal oblique and transversalis muscles, transversalis fascia, subserous areolar tissue and peritoneum, all as one structure—beginning at the outer margin of the retracted rectus. And retract the deep lips of the wound, exposing the abdominal cavity. (5) The special object of the operation is now accomplished. (6) At the completion of the operation, the structures are sutured in the following order;—peritoneum, subserous areolar tissue, transversalis fascia, transversalis and internal oblique muscles are all sutured in one layer, with continuous chromic gut;—the rectus is allowed to fall back into place;—the external oblique aponeurosis and

muscle are sutured with continuous kangaroo tendon, in which layer the rectal sheath is also included;—and the skin is closed by a subcuticular silk suture (and the fascia separately with gut, if it be very thick).

Comment—In applying the above operation to cases of appendicitis Fowler considers the base of the appendix to be most generally found at the intersection of a transverse line between the anterior superior iliac spines with a vertical line running midway between the median line of the body and the anterior superior iliac spine.

This operation gives no more room than Weir's—and the latter operation does not divide muscle-fibers transversely.

SUPERIOR ANTERO-LATERAL ABDOMINAL SECTION

BY OBLIQUE SUBCOSTAL INCISION.

Description.—A method of entering the abdominal cavity parallel with and a short distance below the costo-chondral arches. Generally resorted to for the exposure of the subhepatic, gastric, and splenic regions.

Preparation—Position.—As in Median Abdominal Section.

Landmarks.—Costo-chondral arches.

Incision.—Generally parallel with and about 2.5 cm. (1 inch) below the costo-chondral arch of one or the other side—with the center of the incision over the object sought. (See Fig. 355, L.)

Operation.—(1) Incise skin, and fascia—clamp vessels—retract lips of wound. (2) Incise external oblique, which will be aponeurotic above and muscular below—the incision crossing its fibers about at a right angle. (3) Separate the fibers of the internal oblique in their cleavage line—which may be done external to the outer border of the rectal sheath. (4) Incise the transversalis parallel with the costo-chondral border, which will be perpendicular to their fibers. (5) Incise the transversalis fascia, subserous areolar tissue, and peritoneum in the same line with the preceding incision—and thus enter the peritoneal cavity. (6) Having completed the object of the operation—suture the structures in the following layers, with buried catgut;—peritoneum, subserous areolar tissue, transversalis fascia;—transversalis and internal oblique muscles;—external oblique;—and fascia and skin with silk or silkworm-gut.

Comment.—This incision corresponds with the cleavage line of the skin—and especially corresponds with the course of the seventh and eighth intercostal nerves, which run upward and are thereby uninjured. The incision can be prolonged up to the rectus muscle followed by a transverse incision of its anterior sheath, with inward retraction of the intact muscle—and a similar transverse division of its posterior sheath—the sheath being sutured at the end of the operation. For the application of this incision, see operations upon the stomach.

LATERAL ABDOMINAL SECTION

BY VISCHER'S LUMBO-ILIAC INCISION.

Description.—Consists in the separation of the muscular and tendinous fibers of the abdominal muscles of the lumbo-iliac region, just above the center of the iliac crest, in their cleavage lines, without transverse division of muscle-fibers, or harm to abdominal nerves—and exposing the operation-site by retraction of the separated muscles. Applicable to exposure of struc-

tures in the above region, and especially for suppurating cases of appendicitis—being advantageous because of the ability to extend the opening from either end of the original incision.

Preparation.—As in McBurney's operation.

Position.—Patient partly turned toward opposite side, with pad placed beneath involved side, to render site of operation prominent. Surgeon on side of operation. Assistant opposite to surgeon.

Landmarks.—Crest of ilium; anterior superior iliac spine; Poupart's ligament.

Incision.—Runs 2.5 cm. (1 inch) above and parallel with the crest of the ilium, beginning at the outer border of the external oblique (which corresponds with about the center of the iliac crest) and ending opposite the anterior superior iliac spine—or may extend forward parallel with the outer part of Poupart's ligament. (See Fig. 355, M.)

Operation.—(1) Incise skin and fascia in the above line—clamp vessels—retract lips of wound, exposing the external oblique. (2) The fibers of the external oblique are now separated in their cleavage line. As the fibers of the muscular portion run somewhat more vertically here than the line of the skin incision, a good, free length of separation is necessary, with firm retraction inward and upward, and outward and downward, respectively, in order to expose the internal oblique. (3) The fibers of the internal oblique, which run upward and inward, are similarly separated in their cleavage line, and retracted upward and backward, and downward and forward—carefully guarding all important nerve structures between the internal oblique and transversalis, which latter muscle is now exposed. (4) The fibers of the transversalis, running transversely inward, practically in the same line with the internal oblique, are now separated in like manner in their cleavage line, and retracted upward and downward, exposing the transversalis fascia. (5) The transversalis fascia, subserous areolar tissue, and peritoneum are divided vertically—and the peritoneal cavity entered. (6) Upon completion of the operation, the structures are sutured as in McBurney's operation (page 639).

Comment —More room may be gotten anteriorly, by continuing the separation of the aponeurotic fibers of the external oblique parallel with Poupart's ligament, in the line of the original incision,—and posteriorly and superiorly, by continuing the separation of the muscular fibers and lumbar aponeurosis. A branch of the deep circumflex iliac artery, between transversalis and internal oblique, is clamped and divided.

Note.—Other incisions are given under the different abdomino-pelvic viscera.

II. THE PERITONEUM.

SURGICAL ANATOMY.

Course of the Peritoneum Forming the Greater Sac—In Longitudinal Section.—Passing down from the umbilicus, the peritoneum lines the anterior abdominal wall—covers the urachus and obliterated hypogastric arteries—passes onto the bladder, from its upper aspect to the trigone—is reflected onto the anterior and upper part of the lateral aspects of the rectum, in the male, forming the recto-vesical pouch. In the female, the reflection is from the bladder onto the uterus (utero-vesical fold)—extending thence over the upper portion of the posterior vaginal wall—and thence to the rectum (recto-vaginal pouch). From the rectum, the sigmoid flexure of the colon is entirely covered (sigmoid mesocolon)—the ascending and descending colons being

covered, generally, only anteriorly and laterally—and passing from the spine downward, the peritoneum covers the small intestines, forming the lower leaf of the mesentery—and thence back again, completing the investment of the small bowel, forming the upper leaf of the mesentery—and passes backward over the transverse portion of the duodenum to the pancreas—thence forward to form the inferior layer of the transverse mesocolon—covers the inferior and part of the anterior aspect of the transverse colon—thence runs downward to form the posterior layer of the great omentum—returning to form the anterior layer of the great omentum—thence to the stomach, covering its antero-superior aspect—thence to the under surface of the liver, forming the anterior layer of the lesser or gastro-hepatic omentum—thence covers the inferior surface of the liver, from the transverse fissure to its anterior border—whence it is reflected over the anterior border to cover the superior surface of the liver to the posterior peritoneal limit—thence it passes to the inferior concave surface of the diaphragm (superior layer of the coronary ligament)—thence over the anterior portion of the concavity of the diaphragm to the anterior abdominal wall—whence it passes down the anterior abdominal parietes to the umbilicus, to the place of beginning.

Course of the Peritoneum Forming the Lesser Sac—In Longitudinal Section.—Beginning at the posterior aspect of the stomach, which it covers, the peritoneum of the lesser sac passes upward to the inferior surface of the liver, behind the transverse fissure, forming the posterior layer of the lesser or gastro-hepatic omentum—and having covered the postero-inferior aspect of the liver, it passes on to the under surface of the diaphragm (inferior layer of the coronary ligament)—thence passes downward over the posterior portion of the concavity of the diaphragm to the spine, covering the great vessels—thence to the pancreas—thence forward, forming the upper layer of the transverse mesocolon—covers the supero-anterior aspect of the transverse colon—descends, forming the innermost layer of the great omentum—then ascends to the greater curvature of the stomach—and covers its posterior wall, to the place of beginning. The lesser sac is in relation with the inner aspect of the spleen, forming the inner layer of the gastro-splenic omentum—and also in relation with the superior portion of the left kidney.

Layers and Folds of Peritoneum.—(1) Parietal Layer—connected by subperitoneal areolar tissue with the walls of the abdomino-pelvic cavity. (2) Visceral Layer—covers some part, or the entire surface, of all the viscera of the abdomino-pelvic cavity. (3) Mesenteries—folds of peritoneum connecting parts of the intestinal tract with the posterior abdomino-pelvic wall. See page 654. (4) Omenta—folds of peritoneum connecting the stomach with other viscera. See page 652. (5) Ligaments—reflections of peritoneum from parts of the abdomino-pelvic walls and diaphragm to the various abdomino-pelvic viscera other than the intestines—for example, those of the liver, spleen, uterus, etc. For these ligaments, see the various viscera of the abdomino-pelvic region.

Foramen of Winslow.—Communication between the greater and lesser peritoneal sacs—revealed by lifting the liver upward and to the right, and depressing the first part of the duodenum and intestines downward and to the left. Bounded:—Superiorly; by caudate lobule of liver;—Inferiorly; by first part of duodenum and first part of hepatic artery;—Anteriorly; by ligamentum hepato-duodenale (right free edge of lesser omentum), with its contained ductus communis choledochus, vena portæ, and hepatic artery, in order from right to left—the vena portæ lying somewhat posterior to artery and duct.

Viscera Almost Entirely Covered by Peritoneum.—Liver; stomach;

spleen; first portion of duodenum; jejunum; ileum; transverse colon; cæcum; sigmoid flexure of colon; upper half of rectum; uterus; ovaries.

Viscera Partly Covered by Peritoneum.—Descending and transverse parts of duodenum; ascending and descending colons; mid-portion of rectum: upper part of vagina; posterior wall of bladder.

Viscera in Contact with Peritoneum without Being Especially Covered by It.—Kidneys; suprarenal capsules; pancreas.

Viscera Uncovered by Peritoneum.—Lower end of rectum; neck, base and anterior aspect of bladder; anterior and inferior portion of posterior wall of vagina.

GENERAL SURGICAL CONSIDERATIONS IN OPERATIONS UPON THE PERITONEUM.

Where the peritoneum is attacked surgically it is generally dealt with incidentally, as a part of some special operation. The technic, therefore, of dealing with the peritoneum is described in those special operations. In some cases, however, the peritoneum is the structure primarily dealt with—and will be so considered in the present section.

The surface form and landmarks of the peritoneum, as well as the instruments used, are sufficiently given under the operations upon the viscera of the abdomino-pelvic cavity.

OPERATIONS FOR THE SEPARATION, DIVISION, OR LIGATION OF PERITONEAL ADHESIONS.

Description.—Adhesions, resulting from the union of the serous surfaces of the peritoneum, may occur in the form of thin, thick, narrow or broad sheets or membranes;—in the form of fragile, dense, short or long bands;—or as limited or extensive surfaces loosely or intimately united. Adhesions may be vascular or comparatively non-vascular. Adhesions may be encountered in any operation involving any serous cavity—therefore, the special features, anatomical relations, and all steps preliminary to the discovery of the adhesions, will depend upon the operation in question.

Two general methods of dealing with adhesions are available; (1) By blunt dissection, with or without ligature,—more applicable in non-vascular, loose and limited adhesions;—(2) By division between ligatures,—more applicable to vascular, firmer and more extensive adhesions.

Separation of Adhesions by Blunt Dissection, with or without Ligation.—The underlying principle in this method of dealing with adhesions is to find the plane of cleavage in the abnormal union and follow it up, separating the adherent surfaces as carefully as possible. This separation is best accomplished by means of a blunt dissector, the handle of a knife, the closed ends of a pair of blunt scissors, or the tip of the finger. If the last be used, a better hold may be gotten upon the parts by stretching a single thickness of gauze over the finger-tip. The adhesions are gently torn apart, always endeavoring to adhere strictly to the cleavage line, especially where important structures are involved, as in the serous coverings of viscera. If the adhesions be limited and but little vascular, ligation is generally unnecessary. If they be vascular, and especially if somewhat extensive and dense, they should be ligated in two places from 1.3 to 2.5 cm. (½ to 1 inch) apart, according to circumstances, and then divided between the ligatures. The preferable liga-

ture is plain gut for small adhesions—and chromic gut for larger ones. Adhesions are often first divided and then ligated. (See Fig. 362, D.)

Division of Adhesions between Ligatures.—The adhesions are first carefully isolated—and then treated according to their nature. If they be in the form of bands, double ligatures of chromic gut are thrown around them

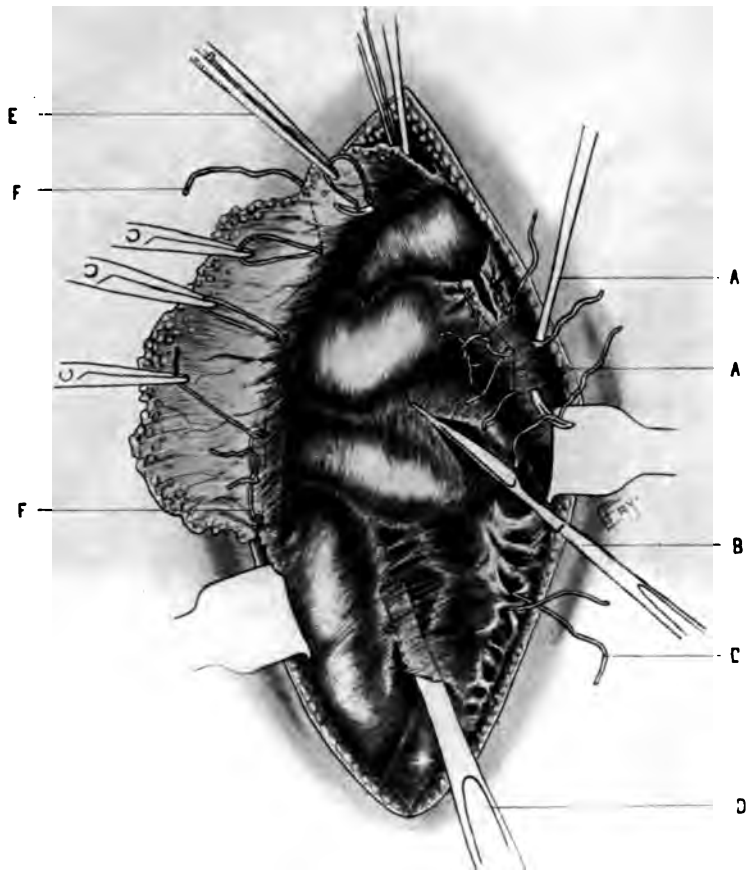

Fig. 362.—Operations for the Separation of Peritoneal Adhesions and the Ligation of Omentum:—A, A, Dividing, in sections, thick layers of intestino-abdominal adhesions between double ligatures; B, Incising thin layers of inter-intestinal adhesions; C, Ligating isolated bands of intestino-abdominal adhesions; D, Separation of membranous inter-intestinal adhesions by blunt dissection; E, F, F, Tying off, in sections, adherent omentum, preparatory to excision of distal portion—E, by means of individual ligature carried by aneurism-needle—F, F, by means of continuous ligature applied to the posterior and drawn through the anterior aspect of the omentum in sections, by catch-forceps.

and tied, and the bands are then divided between them. If the adhesions be in the form of broad surfaces, they are ligated in sections and divided upon the distal side of the ligatures—or between two ligatures, if indicated. (See Fig. 362, A.)

Visceral Adhesions to the Abdomino-pelvic Wall.—When entering the abdominal cavity where adhesions may be suspected, or where, in the

neighborhood of known adhesions, it is uncertain as to whether the peritoneal cavity have been entered, the underlying tissues should be picked up and rolled between the fingers, to enable a judgment to be formed by the sensation imparted. If the peritoneal cavity be entered in the immediate vicinity of an adhesion, this should be at once recognized by sweeping the finger around the vicinity of the opening—and the adhesion separated by blunt dissection, or divided between double ligatures if necessary. Where the opening made comes directly down upon adhesions, these shou'd be recognized as soon as possible, that the progress toward the peritoneal cavity may be known—and then an endeavor be made to reach a free margin of the adhesion, from which the remainder of the separation, or division, may be made on the general principles mentioned. (See Fig. 362, A, C.)

Intestinal Adhesions.—The thin, membranous or velamentous adhesions may generally be separated by blunt dissection with the fingers—by putting the parts gently upon the stretch and keeping the adhesion in a broad, thin layer, rather than in a thick, twisted cord. Dense, organized adhesions require careful dissection—that no part of either wall may be dangerously thinned. (See Fig. 362, B, D.)

Inter-visceral Adhesions.—Or adhesions between growths and viscera—should be dealt with by putting the adhesion upon moderate stretch—by traction upon one or both viscera, until the bond of adhesion is demonstrated—then first ligate or clamp on each side, safely to the outer side of the viscus, and divide the adhesion between the ligatures or clamps.

Omental Adhesions.—Adherent omentum may often be stripped off with the fingers. If too dense, or too firmly united for this, it should be ligated with a single ligature, or in sections, and divided. Large portions of the omentum—and even the entire omentum—may be amputated. The omentum may require only a proximal, or may require double ligaturing. (See Fig. 362, E, F, F.)

Comment.—(1) While the separation in the plane of the abnormal adhesion should always be the course attempted, where this is impossible it often happens that areas, dependent upon their nature, have to be ligated, or clamped, and cut, with the sacrifice of some portion of the least important structure. (2) Where the separation of an adhesion between viscera and neighboring structures (visceral or otherwise) is impossible, and where the step is permissible, one or more layers, or even the entire thickness, of the less important structure is left attached to the more important one—after ligating and blunt dissection, or incision, of the adhesion—thus leaving a limited area of adherent tissue attached to an organ, rather than risk injuring the organ by further attempt at removal. In such cases the portion left is reduced to its smallest and thinnest size. (3) It is always desirable to preserve the serous covering of a viscus (to aid nutrition and avoid adhesions and sloughing)—and sometimes surfaces left raw by separating adhesions may be covered, and hemorrhage also controlled, by suturing adjacent serous surfaces over them—or by attaching omental grafts. (See page 654.)

Note.—For further consideration of this subject, see Complications of Median Abdominal Section, page 636.

PARACENTESIS ABDOMINIS.

Description.—Puncture of the peritoneal cavity for diagnostic purposes, or for evacuation of fluid.

Preparation.—Shave abdominal wall. Empty bladder and bowels. Area of dulness verified by percussion immediately before paracentesis. Cocainization of the area of puncture.

Position.—Patient, where possible, sits upright in chair—where impossible, lies upon edge of bed. A many-tailed, sterilized bandage, or ordinary towel, with a central opening corresponding to the site of paracentesis, is placed around the patient, and tightened posteriorly by an assistant as the abdominal enlargement decreases with the evacuation of fluid. Surgeon sits immediately in front of patient.

Landmarks.—Linea alba; umbilicus; limit of upper aspect of bladder (see that structure, page 877).

Special Instruments.—For exploratory punctures, aspiratory syringes with needles of small caliber. For evacuation of considerable quantity of fluid, a straight cannula and trocar of fairly large size is used. Aspirators of the Dieulafoy and Potain type may be employed. Where the skin is to be preliminarily incised, a knife is necessary—and a needle and thread, where the incision, or trocar-wound, is to be closed by suture.

Site of Paracentesis.—Generally in the linea alba, midway between umbilicus and symphysis pubis. Sometimes the puncture is made in the lower half of either semilunar line.

Operation.—(1) Having so placed the broad bandage that the opening is opposite the site of paracentesis, and having grasped the exploratory or aspiratory needle, or trocar, in such a way as to predetermine, by means of the right index, the depth to which it is to enter, which will be decided by the estimated thickness of the abdominal wall, the instrument is quickly but guardedly thrust through the abdominal wall into the free peritoneal cavity, in a single movement. In the case of the exploratory syringe, sufficient fluid is withdrawn for examination—the needle withdrawn, and the wound closed with collodion and cotton. (2) In the case of the evacuation of large amounts of fluids by means of cannula and trocar (or aspirator) the trocar is withdrawn and the cannula left *in situ*—the fluid is then allowed to flow, the bandage being tightened *pari passu*. At the end of the operation, the cannula is withdrawn—and, if it have been of large size, an interrupted gut suture is made to close the opening by being passed on a curved needle, from side to side, through a part of the thickness of the abdominal wall. The outer aspect of the opening is then closed with collodion and gauze, or cotton.

Comment.—(1) Where a large size instrument is used, it is best to make a small preliminary incision through the tough skin. (2) A cannula should preferably be used the end of which is not pointed or sharp. (3) If the cannula be obstructed during the flow, it may generally be freed by the passage of a sterile probe down its length. (4) As the fluid escapes, the inner end of the cannula (especially if dull) may be shifted so as to furnish the best evacuation. (5) The fluid should be made to escape slowly—and may be retarded by a compress over the outer end of the cannula—to avoid syncope.

III. THE OMENTUM.

SURGICAL ANATOMY.

Description.—The omenta are folds of peritoneum connecting the stomach with other viscera. They consist of the great or gastro-colic, small or gastro-hepatic, and gastro-splenic omenta.

Great or Gastro-colic Omentum.—Passes down from the greater curvature of the stomach as an apron in front of the small intestine, thence upward to be fused with the transverse colon, being connected with the gastro-splenic omentum on the left, and with the hepatic flexure of the colon and descending colon on the right;—consisting of four layers, two descending and two ascending; the two middle layers belonging to the lesser sac and the two superficial layers to the greater sac;—its vessels coming chiefly from the gastro-epiploica sinistra of the splenic artery, and to a less extent from the gastro-epiploica dextra of the gastro-duodenal branch of the hepatic artery.

Small or Gastro-hepatic Omentum.—Extends from transverse fissure of liver to lesser curvature of stomach, being continuous on the right with the first part of the duodenum (there forming the ligamentum hepato-duodenale), and, on the left, with the gastro-splenic omentum;—formed of two layers, one from the lesser and one from the greater sac;—and having the following relation of vessels between the layers of the hepato-duodenal portion of the gastro-hepatic omentum: ductus communis choledochus, on the right: hepatic artery, on the left: vena portæ, between the two and somewhat posterior to them.

Gastro-splenic Omentum.—Extends from the fundus of the stomach to the gastric surface of the spleen;—and transmits the vasa brevia of the splenic artery to the stomach.

GENERAL SURGICAL CONSIDERATIONS IN OPERATIONS UPON THE OMENTUM.

The remarks made under this head in connection with the Peritoneum are applicable to this section. See page 649.

LIGATION OF THE OMENTUM.

Description.—In the course of intra-abdominal operations, it is often necessary to ligate portions of the omentum, either for the purpose of freeing adhesions, or as a preliminary step to the removal of a part, or even the whole, of the great omentum.

Ligation of Omental Adhesions.—The general principle of dealing with adhesions by separation by blunt dissection, or by ligature and division, described under the operations for peritoneal adhesions (see page 649), applies equally to those of the omentum. Where the separation can be accomplished by blunt dissection, this should be done. Where division by knife or scissors is necessary, this should generally be preceded by ligation with chromic gut. The ligature may be conveniently passed by means of an aneurism-needle—either around a single band of adhesion, or in sections through broader extents of adhesion. The omentum is then divided distally to the ligature—or, where indicated, as is generally the case in dense adhesions, between double ligatures. (See Fig. 362, E, F, F.)

Ligation of the Omentum Preparatory to Removal of Larger Portions.—The omentum may be so irregularly and completely bound down as to require ligature and division in piecemeal, as in tying off adhesions, as just described. Where, however, it is largely or entirely free, a tier of ligatures may be quickly run across the free portion just above the line of subsequent division. This tier may be applied in sections by means of an aneurism-needle. (See Fig. 362, E.) Or it may be more quickly placed by holding the ligature in contact with the back or opposite side of the omen-

tum, and then, at proper intervals, piercing the omentum from the front with a pair of catch-forceps, or a Cleveland ligature-carrier, grasping the ligature and drawing it through—it is then cut at each opening through which drawn, interlocked with its neighbor by a half-turn, and tied—as shown in Fig. 362, F, F.

OMENTAL GRAFTING.

Description.—Consists in the using of isolated pieces of omentum to repair peritoneal defects. These pieces of omentum are excised from the great omentum and sutured to wounded or denuded surfaces, or suture-lines, of the abdomino-pelvic viscera normally covered by peritoneum. They are especially used to reinforce suspicious intestinal sites—but may be applied to any of the serous surfaces of other viscera. They become adherent within a few hours—and thus strengthen weakened sites.

Operation.—The application of omental grafts is called for during the course of intra-abdominal operations—and the technic of the operation is simple. A small piece of the great omentum, preferably its free aspect,

Fig. 363.—OMENTAL GRAFTING:—Graft of omentum reinforcing circular enterorrhaphy, sutured to the mesentery and partly sutured to the intestine.

calculated in shape and size to cover the defect by a good margin, is cut away with scissors, distally to previously placed ligatures of gut—and this graft is placed in contact with the area to be reinforced, preceded or not by slight scarification of the site with a needle-point—and is held in contact by means of a few loosely applied, interrupted, fine gut-sutures. If the grafts cannot be used immediately after being cut, they are placed in warm normal salt solution until required, when they are partially dried between gauze. The grafts used to reinforce circular enterorrhaphy generally average from 4 to 5 cm. (1½ to 2 inches) in width, and should be long enough to completely surround the site in question. (See Fig. 363.)

IV. THE MESENTERY.

SURGICAL ANATOMY.

Description.—The mesenteries are peritoneal folds connecting any portion of the gastro-intestinal tract to the posterior abdomino-pelvic wall.

Divisions.—Mesogastrium; mesoduodenum; mesentery proper; mesenteriolum (mesentery of the vermiform appendix); ascending mesocolon (sometimes present); transverse mesocolon; descending mesocolon (sometimes present); sigmoid mesocolon; mesorectum.

Mesentery (proper).—A fan-shaped fold of peritoneum beginning at the spinal column and following and covering the anterior aspect of the superior mesenteric vessels to the loops of the small intestine, enveloping all the coils of the jejunum and ileum (but not those of the duodenum)—returning thence along the posterior aspect of the superior mesenteric vessels to the vertebral column. The root of the mesentery extends from the left lateral aspect of the body of the second lumbar vertebra downward—crossing obliquely the spinal column, aorta, vena cava inferior, and third portion of the duodenum, ending at the right sacro-iliac synchondrosis, or in the right iliac fossa. It contains, between its right upper and left lower layers, the mesenteric arteries and veins, lacteals, lymphatics and nerves, all held together by fatty areolar tissue. The right upper layer of the mesentery passes from the root of the mesentery to the lower layer of the transverse mesocolon. Laterally the layers are continuous with the inner lamellæ of the right and left colons. Below, the left layer is continuous with the peritoneum covering the lumbar vertebræ, and passing thence over the pelvic organs. In dimensions, its length (convex intestinal border) is about 6.45 m. (21 feet)—its width averages 20.5 to 23 cm. (8 to 9 inches), its greatest width (opposite the central and lower loops of the intestine) being from 20 to 25 cm. (8 to 10 inches).

GENERAL SURGICAL CONSIDERATIONS IN OPERATIONS UPON THE MESENTERY.

The mesentery is involved surgically chiefly in the operation of partial enterectomy.

PARTIAL EXCISION OF THE MESENTERY.

See under Partial Enterectomy, page 672.

SUTURING OF THE MESENTERY.

See under Partial Enterectomy, page 672.

V. THE INTESTINES.

SURGICAL ANATOMY OF THE SMALL INTESTINES.

Description.—Extend from pylorus of stomach to ileo-cæcal valve. About 7.6 meters (25 feet) long.

Divisions.—**Duodenum** (from 25.5 to 30.5 cm., or 10 to 12 inches)—consists of First or Superior Curved Portion (Superior Hepatic Curve) (not quite 5 cm., or 2 inches);—Second or Descending (Vertical) Portion (not quite 7.5 cm., or 3 inches);—Third or Transverse (Preaortic) Portion (about 12.5 cm., or 5 inches);—Fourth or Ascending Portion (about 2.5 to 5 cm., or 1 to 2 inches);—Fifth or Duodeno-jejunal angle. **Jejunum**—about upper two-fifths of remaining small intestines (about 2.9 meters, or 9 feet 7 inches). **Ileum**—about lower three-fifths of remaining portion (about 4.3 meters, or 14 feet 5 inches).

General Form of Duodenum.—Usually has the form of a U, with which the above description corresponds—but is sometimes V-shaped.

Course and Relations of First or Superior Curved Portion (Superior Hepatic Curve) of Duodenum.—Course; from pylorus, passes upward and backward to right, ending at neck of gall-bladder. **Superiorly and anteriorly;** quadrate lobe of liver; neck of gall-bladder; foramen of Winslow (duodenum forming its lower boundary); hepatic artery. **Inferiorly;** head and neck of pancreas. **Posteriorly;** common bile-duct; vena portæ; gastro-duodenal artery; vena cava inferior; first lumbar vertebra.

Course and Relations of Second or Descending (Vertical) Portion of Duodenum.—Course; descends from neck of gall-bladder down right side of vertebral column, from first to body of third or fourth lumbar vertebra —transverse colon crossing its middle third. **Anteriorly;** right lobe of liver (duodenal impression); right end of transverse colon; transverse mesocolon; small intestine; mesentery (right leaf). **Posteriorly;** right kidney, and suprarenal capsule (sometimes); renal vessels; common bile and pancreatic ducts; inferior vena cava; spermatic vessels. **Internally** (to left); head of pancreas; common bile and pancreatic ducts; pancreatico-duodenal vessels; first to fourth lumbar vertebræ and intervertebral discs.

Course and Relations of Third or Transverse (Preaortic) Portion of Duodenum.—Course; from right side of body of third or fourth lumbar vertebra, crosses vertebral column in horizontal or slightly ascending manner, in front of great vessels and crura of diaphragm, moulding itself over these structures. **Superiorly;** head of pancreas; superior mesenteric vessels; inferior pancreatico-duodenal artery. **Anteriorly;** root and right and left layers of mesentery; lower layer of transverse mesocolon; superior mesenteric vessels; small intestines. **Posteriorly;** inferior vena cava; aorta; diaphragmatic crura; third and fourth lumbar vertebra.

Course and Relations of Fourth or Ascending Portion of Duodenum. —Course; ascends vertically along left side of spine, from third or fourth lumbar vertebra to side of second or first lumbar vertebra. **Anteriorly;** transverse colon; transverse mesocolon (lower layer); small intestine; mesentery (left layer); antrum pylori (sometimes). **Posteriorly;** left diaphragmatic crus; left psoas; left renal vessels; spermatic vessels; kidney (interno-inferior part). **Internally** (to right); head and neck of pancreas; aorta; fourth or third and second lumbar vertebræ.

Course and Relations of Fifth Part, or Duodeno-jejunal Angle: Position; at left side of second or first lumbar vertebra. **Superiorly;** body of pancreas. **Anteriorly;** mesentery (left layer). **Externally;** left kidney (inner border).

Peritoneal Covering of Duodenum.—First part; covered by peritoneum, except parts of posterior surface near vena cava and neck of gall-bladder. **Second part;** covered in front only (except that no peritoneum covers the front opposite the divergence of two layers of transverse mesocolon). **Third part;** covered in front only (except that there is no peritoneum in front opposite root of mesentery). **Fourth part;** covered entirely in front, and partly at sides. **Fifth part;** entirely covered by peritoneum where it becomes jejunum.

Ligaments of Duodenum.—Ligamentum Hepato-duodenale (suspensory ligament of duodenum)—right edge of lesser omentum—from hilus of liver to first part of duodenum. Ligamentum Cystico-duodenale—from neck of gall-bladder to first part of duodenum. Ligamentum Duodeno-renale—from summit of right kidney to outer aspect of first part. Ligamentum

Duodeno-mesocolica—from junction of left layer of mesentery with lower layer of transverse mesocolon, to outer aspect of fourth part of duodenum.

Other Fixation-points of Duodenum.—Common bile-duct and pancreatic duct; cœliac axis and superior mesenteric artery; fibro-nervous structures; muscle of Treitz (passing from duodeno-jejunal angle upward beneath pancreas to left crus of diaphragm).

Fossæ in Neighborhood of Ascending Duodenum and Duodeno-jejunal Angle.—Inferior duodenal fossa; superior duodenal fossa (these two may coexist); duodeno-jejunal (mesocolic) fossa (non-coexistent with above two).

Position of Jejunum.—Extends from duodeno-jejunal angle to beginning of ileum. Position not fixed—coils of jejunum generally to be found upon left side of abdominal cavity, in left lumbar, left inguinal, and left half of umbilical regions. The upper loops are apt to be more transverse than the lower.

Characteristics of Middle Portion of Jejunum (as Compared with Middle Portion of Ileum).—Diameter about 4 cm. (1½ inch). Walls thicker, more vascular, and mucous membrane more complex. Weight of given length greater. No valvulæ conniventes (or poorly marked). Its position.

Mesentery of Jejunum and Ileum (Attachment of Jejunum and Ileum) —(1) Passes obliquely from left side of body of second lumbar vertebra downward and to right, crossing spinal column, aorta, inferior vena cava, and third part of duodenum, to right sacro-iliac synchondrosis (or to right iliac fossa). (2) Middle and inferior loops of small intestine have longest mesentery—and are, therefore, generally found in pelvis. Duodenum has no mesentery. Lower part of Ileum has shortest mesentery (opposite right psoas muscle). (3) Mesentery extends from distal end of duodenum to ileo-cæcal junction. Its upper (right) layer is continuous with inferior layer of transverse mesocolon and with peritoneum of ascending colon. Its lower (left) layer joins peritoneum enclosing descending colon and forming sigmoid mesentery. (4) Average length of mesentery (from spine to intestines) from 20 to 25 cm. (8 to 10 inches).

Position of Ileum.—Extends from lower end of jejunum to ileo-cæcal valve. Position not fixed—coils of ileum generally to be found on right side of abdomen and pelvis, in right lumbar, right inguinal and in right half of umbilical and hypogastric regions. The lower loops are apt to be more vertical than the upper.

Characteristics of Middle Portion of Ileum (as compared with Middle Portion of Jejunum).—Diameter about 3 cm. (1¼ inch). Walls thinner, less vascular, and mucous membrane simpler. Weight of given length less. Valvulæ conniventes. Its position.

Meckel's Diverticulum of Ileum (remains of vitelline duct).—Blind diverticulum of ileum and directly continuous with its lumen. Length, from 5 to 7.5 cm. (2 to 3 inches)—extremes, from 1 to 18 cm. (½ to 7 inches). Arises about 109 cm. (43 inches)—extremes, from 30.5 to 305 cm. (1 to 10 feet)—above ileo-cæcal junction. Generally lies free in abdominal cavity (instead of passing to umbilicus, as in fetus). But distal end may be connected with umbilicus, or other site, by strong band (remains of enlarged omphalo-mesenteric vessels). Its presence occurs in about 50 per cent.

Arteries of Small Intestines.—(1) Duodenum; pyloric of hepatic; superior pancreatico-duodenal branch of gastro-duodenal branch of hepatic;

inferior pancreatico-duodenal of superior mesenteric. (2) Jejunum and Ileum; superior mesenteric.

Veins of Small Intestines.—Correspond with arteries — a single vein accompanying each artery.

Lymphatics of Small Intestines.—End in mesenteric lacteals.

Nerves of Small Intestines.—From superior mesenteric plexus, formed by nerves from cœliac plexus, semilunar ganglion, and right vagus.

SURFACE FORM AND LANDMARKS OF THE SMALL INTESTINES.

Upper limit of attachment of mesentery (duodeno-jejunal angle) generally lies from 8 to 10 cm. (3 to 4 inches) above the umbilicus, slightly to left of median line. Lower limit is about 10 cm. (4 inches) from middle of right Poupart's ligament, on a line directed upward and inward in the course of psoas muscle.

SURGICAL ANATOMY OF THE LARGE INTESTINES.

Description.—Extend from lower end of ileum to anus. About 1.5 to 1.8 meters (5 to 6 feet) long.

Divisions.—Cæcum; Ascending Colon; Hepatic Flexure; Transverse Colon; Splenic Flexure; Descending Colon; Sigmoid Flexure (Sigmoid Colon); Rectum.

General Characteristics of Large Intestines (as compared with small intestines).—Greater size; greater fixity of position; sacculations; longitudinal bands; appendices epiploicæ. (Last three characteristics not present in rectum).

Cæcum.—(About 7.5 cm., or 3 inches, broad, and 6.3 cm., or 2½ inches, long.) **Position;** lies in right iliac fossa, above outer half of Poupart's ligament, generally resting upon psoas muscle—sometimes upon iliacus only—sometimes bulk of cæcum rests on iliacus and apex on psoas—sometimes free of both, being entirely in pelvic cavity, or even projecting beyond median line. Its apex, or lower point, lies slightly to inner side of middle of Poupart's ligament, just behind anterior abdominal wall and opposite inner portion of psoas. The cæcum is entirely covered by peritoneum and lies free in abdominal cavity. There is no mesocæcum. Several forms or types of cæcum occur (see Appendix). **Anteriorly;** abdominal parietes above outer half of Poupart's ligament. **Posteriorly;** ilio-psoas; appendix (origin). **Superiorly;** ileo-cæcal valve. **Internally;** ileum (termination).

Ileo-cæcal Fossæ.—Superior Ileo-cæcal Fossa, an anterior pouch between end of ileum and ascending colon. Inferior Ileo-Cæcal Fossa, an inferior pouch under ileum, between it and cæcum.

Appendix Cæci.—Description; small blind tube, generally hollow to tip, its lumen continuous with that of cæcum and sometimes guarded by valve. Average length, 9.2 cm., or 3¾ inches (extremes, from 3.1 to 23 cm., or from 1¼ to 9 inches). Diameter, about 6 mm. (¼ inch) at base—5 mm. ($\frac{3}{16}$ inch) at apex. Origin, generally arises 1.7 cm. ($\frac{11}{16}$ inch) below ileo-cæca valve, upon its inner and posterior aspect—but sometimes forms the true apex of cæcum. **Course;** variable—(1) According to Treves, the appendix generally passes upward from behind cæcum toward spleen, lying behind lower end of ileum and its mesentery. (2) According to Berry, the order of frequency of position is, "(a) pelvic; (b) retrocæcal; (c) internal to cæcum, *i. e.*, Treves's position; (d) variable." (3) According to Bryant, in order of

frequency, "(**a**) inward; (**b**) behind cæcum; (**c**) downward and inward; (**d**) into true pelvis." **Relations to peritoneum;** Mesentery always present but not extending to tip—about distal third being entirely enveloped in peritoneum and free. Meso-appendix, of triangular form—derived from left leaf of mesentery—containing, in its free margin, posterior branch of ileo-cæcal artery (from ileo-colic). **Relations to cæcum;** four types of cæcum occur (Treves)—(**a**) appendix arising from apex of cæcum; (**b**) appendix arising between two sacculi of equal size; (**c**) appendix arising between two sacculi of unequal size (about 90 per cent. of cases); (**d**) appendix appearing to arise from ileo-colic junction. **Relations to anterior abdominal wall;** (**1**) According to McBurney,—draw straight line from anterior superior iliac spine to umbilicus, and beneath this line, from 4 to 5 cm. (1½ to 2 inches) internal to the spine, the base of the appendix is found (in right iliac fossa). (**2**) According to Clado,—draw a line along outer edge of rectus—another between anterior superior iliac spines—opposite the junction of these the base of the appendix is found (in hypogastric region).

Ileo-cæcal Valve.—Opens upon postero-internal aspect, at upper border of cæcum.

Ascending Colon.—Description; About 20 cm. (8 inches) in length. Extends vertically upward from cæcum to inferior surface of right lobe of liver, at right of gall-bladder (hepatic flexure). Covered by peritoneum anteriorly and laterally, which binds it to posterior abdominal wall. Its posterior surface (where peritoneum is absent) is bound by areolar tissue to quadratus lumborum, transversalis, and right kidney (antero-external part). Mesentery (ascending mesocolon) present in 26 per cent. (Treves). **Relations; Anteriorly;** ileum; abdominal wall. **Posteriorly;** quadratus lumborum; transversalis; kidney (antero-external part). **Superiorly;** liver (right lobe).

Hepatic Flexure of Colon.—Upon under surface of liver, near gall-bladder, the ascending colon bends from posterior abdominal wall sharply to front and left, to become transverse colon.

Transverse Colon.—Description; About 51 cm., or 20 inches (extremes, from 30 to 84 cm., or 12 to 33 inches), in length. Extends from inferior surface of liver, in right hypochondrium (hepatic flexure), transversely across anterior abdominal wall, with slight downward and forward convexity at its center, to the spleen in left hypochondrium (splenic flexure). Transverse mesocolon is long, and connects transverse colon to posterior abdominal wall—most movable part of large intestine. Transverse colon lies above the umbilicus four times out of five—and below it one time out of five (usually on a line connecting lowest parts of costal arches). Peritoneum entirely surrounds transverse colon. **Relations; Anteriorly;** abdominal wall; great omentum. **Posteriorly;** transverse mesocolon; descending duodenum; small intestines; superior curvature of stomach (at times). **Superiorly;** liver and gall-bladder (inferior surfaces); great curvature of stomach; spleen (inferior end); pancreas (tail). **Inferiorly;** small intestines.

Splenic Flexure of Colon.—Situated beneath lower end of spleen—further back in abdomen than hepatic flexure. Connected by phreno-colic ligament (a fold of peritoneum) passing between splenic flexure to diaphragm, between tenth and eleventh ribs.

Descending Colon.—Description; About 21.5 cm. (8½ inches) long. Extends from splenic flexure vertically through left hypochondrium and lumbar regions to sigmoid flexure. Peritoneum covers it similarly to ascending colon (*q. v.*). Mesentery (descending mesocolon) present in 36 per cent.

(Treves). **Relations:—Anteriorly;** abdominal wall; jejunum. **Posteriorly;** diaphragm; left kidney (infero-external part); quadratus lumborum; transversalis. **Superiorly;** spleen; phreno-colic ligament.

Sigmoid Flexure of Colon (Sigmoid Colon).—Description; An S-shaped curve, about 31 cm. (13 inches) long, lying in left iliac fossa, beginning at iliac crest and ending at brim of true pelvis, opposite left sacro-iliac synchondrosis (or opposite upper edge of sacrum). **Divisions;** First Portion, of Colic Limb, tends downward, inward, and slightly forward toward outer aspect of Poupart's ligament and abdominal wall—generally has a short mesocolon (though sometimes peritoneum only anteriorly and laterally). Second or Rectal Part, tends to hang into true pelvis—mesentery about 7.5 cm. (3 inches)—very movable. **Insertion of Sigmoid Mesocolon;** in line extending obliquely from left iliac crest across psoas and left iliac vessels (at about their bifurcation) to join mesorectum at sacral promontory. **Note;** More properly the sigmoid colon, or flexure, should include that portion of large intestine usually described as the first part of the rectum—and then would end where the mesorectum ceases, opposite the third piece of the sacrum, thus having more of an omega than a sigmoid appearance. **Relations; Anteriorly;** abdominal wall; small intestines. **Posteriorly;** left ilio-psoas; posterior pelvic wall; rectum.

Intersigmoid Fossa.—In the layers of the mesocolon, generally over bifurcation of iliac vessels—looks downward to left. Sometimes found in children—rarely in adults.

Rectum.—(Length, about 20 to 23 cm., or 8 to 9 inches.) **Divisions:** First or Superior Part; Second or Middle Part; Third Part, or Anal Canal. **Note;** The rectum will be here described as consisting of three parts, as mentioned. More properly it consists of but two parts, corresponding with the second and third parts just mentioned—the first part above mentioned being, strictly, a portion of the Sigmoid Colon (see "note" under Sigmoid Flexure of Colon). **First or Superior Part;** 8 to 9 cm. (3¼ to 3½ inches) long. Corresponds with lower part of Sigmoid Colon, as sometimes described. Runs obliquely from left pelvic brim (beginning opposite either sacro-iliac synchondrosis, or sacral promontory, or even right side of base of sacrum) downward, backward, and to right to third sacral vertebra in the median line. Almost entirely enveloped in peritoneum, except posteriorly. Mesorectum connects its posterior aspect to anterior surface of sacrum. Mesentery continuous with sigmoid mesocolon and terminates at third sacral vertebra. **Relations of first part; Anteriorly;** small intestine; sigmoid colon; bladder (posterior surface) in male; uterus (posterior surface) in female. **Posteriorly;** mesorectum; left pyriformis muscle; left sacral plexus; left internal iliac artery and veins; first, second, and one-half of third sacral vertebræ. **Externally;** left ureter; left internal iliac artery and veins. **Description of second or middle part;** 10 to 11 cm. (3 to 4 inches) long. Extends in a curve from middle of third sacral vertebra to opposite apex of prostate gland—running at first along right aspect of fourth sacral vertebra—thence back to median line about the sacro-coccygeal articulation—and passes thence downward and forward to opposite a line connecting the anterior aspects of the two ischial tuberosities, which is opposite the apex of prostate gland, and about 2.5 cm. (1 inch) below tip of coccyx. Partially covered by peritoneum—covered above, anteriorly and laterally—then only anteriorly—and about 2.5 cm. (1 inch) above prostate gland (never more than 8 cm., or 3⅛ inch) it is reflected from anterior surface of rectum to posterior surface of bladder, in male, or to posterior surface of upper one-fifth of vagina, in female (forming

recto-vesical or recto-vaginal pouch). No mesorectum exists. On posterior surface of rectum there is no peritoneum below a point 12.5 cm. (5 inches) above anus. **Relations of second or middle part of rectum; Anteriorly;** (**a**) In Male; recto-vesical pouch; small intestines; bladder (trigone); vesiculæ seminales; vasa deferentia; prostate gland (inferior aspect); (**b**) In Female; vagina (posterior surface); recto-vaginal pouch; recto-uterine pouch; small intestines. **Posteriorly;** sacrum (lower portion); coccyx; ano-coccygeal body; middle sacral vessels; pyriformis muscles. **Description of third part, or anal canal;** About 2 to 3 cm. ($\frac{3}{4}$ to $1\frac{1}{4}$ inch)—little less in female. Passes downward and backward, from a point opposite apex of prostate gland (about 2.5 cm., or 1 inch, below tip of coccyx) to end in anus. No peritoneal covering. Surrounded by sphincter muscles. **Relations of third part, or anal canal; Anteriorly;** bulb and membranous part of urethra (male); perineal body (female). **Posteriorly;** ano-coccygeal body; coccygei muscles. **Laterally;** fatty areolar tissue of ischio-rectal fossæ; levatores ani muscles.

Anus.—Surrounded by internal sphincter, levatores ani, and external sphincter. (See Perineum.)

Arteries of Cæcum and Colon.—Ileo-colic, colica dextra, and colica media, from superior mesenteric; colica sinistra and sigmoid, from inferior mesenteric.

Veins of Cæcum and Colon.—Superior and inferior mesenteric, emptying into portal system.

Lymphatics of Cæcum and Colon.—Those of ascending, transverse, and descending colon empty into mesenteric glands. Those of sigmoid colon empty into lumbar glands.

Nerves of Cæcum and Colon.—Cæcum, ascending and proximal half of transverse colon are supplied by superior mesenteric plexus, from cœliac plexus. Distal half of transverse colon, descending and sigmoid colon are supplied by inferior mesenteric plexus, from aortic plexus.

Arteries of Rectum.—Superior hemorrhoidal (of inferior mesenteric); middle hemorrhoidal (of internal iliac); inferior hemorrhoidal (of internal pudic); branches from sacra media (of abdominal aorta); branches from sciatic (of internal iliac); branches from vaginal, in female (of internal iliac).

Veins of Rectum.—Chiefly from superior hemorrhoidal to inferior mesenteric, and thence to portal system. Some blood passes back by systemic system to inferior vena cava. Anastomosis between systemic and portal systems occurs in rectum.

Lymphatics of Rectum.—Empty into anterior sacral and inguinal glands.

Nerves of Rectum.—From cerebrospinal system (sacral plexus)—and from sympathetic system (hypogastric and inferior mesenteric plexuses).

SURFACE FORM AND LANDMARKS OF THE LARGE INTESTINES.

Cæcum lies in right inguinal region, its lower border corresponding, at its center, with the center of a line drawn from anterior superior iliac spine to symphysis pubis.

Ascending Colon ascends through right lumbar and hypochondriac regions to hepatic flexure.

Hepatic Flexure lies beneath the liver in the right hypochondrium.

Transverse Colon crosses the abdomen transversely at about the junction of the umbilical and epigastric regions—its superior border lying just below the greater curvature of the stomach—its inferior border just above the umbilicus.

Splenic Flexure is posterior to the stomach in the left hypochondrium.

Descending Colon descends through the left hypochondriac and lumbar regions to the sigmoid flexure.

Sigmoid Colon lies in the left inguinal region.

Note.—For the more detailed description of the relations of the parts of the large intestines, see Surgical Anatomy of the special parts.

GENERAL CONSIDERATIONS IN OPERATIONS UPON THE INTESTINES.

Preparation of Patient.—Bowels are to be emptied. Abdomen should be shaved.

Position.—Patient lies supine, usually in a horizontal position, near the edge of the table. Surgeon may stand on either side of patient, but usually stands on the patient's right, incising from above downward. Assistant stands opposite surgeon.

Portion of the Intestinal Wall where the Laminæ of the Mesentery Separate to Enclose the Intestines.—In the case of those portions of the intestines which have a mesentery, the laminæ of the mesentery begin to separate (in order to surround the wall of the gut) about 1.5 to 2 cm. ($\frac{3}{4}$ to $\frac{3}{4}$ inch) from the intestine, leaving, upon these viscera, a triangular interval with a base of about 8 mm. ($\frac{5}{16}$ inch) where the muscular coat is uncovered by peritoneum—this triangular space being occupied by fatty areolar tissue, vessels, and nerves. The practical bearings of the above fact being;—(1) The necessity of being particularly careful in ordinary suturing, or the adoption of some special form of suturing, in operations upon the intestines, in order to bring the peritoneum of the cut margins into contact with the wall of the intestines at the mesenteric border, thus securing the covering of the denuded tract with peritoneum and also securing apposition of serous surfaces when two ends of intestine are brought together;—(2) The guarding of the blood-supply to the intestines transmitted through this triangular space. *Note*—the method of dealing with this area of the intestine will be mentioned under special operations.

Note.—For other general considerations bearing upon operations upon the intestines, see the introductions to the special classes of intestinal operations.

INSTRUMENTS USED IN OPERATIONS UPON THE INTESTINES.

I. Instruments used in entering the peritoneal cavity—see the instruments for performing Abdominal Section (page 631).

II. Instruments used in general intestinal operations;—intestinal clamps; artery-clamp forceps; dissecting and toothed forceps; scissors; bistouries; aneurism-needles; probe; grooved director; tenaculum; needles, ordinary straight cambric, curved, calyx-eyed, Keith's abdominal; needle-holder; fine silk; catgut; gauze pads; gauze sponges; sponge-holders; drains of gauze, wick, rubber tubing, glass tubing. Special instruments and mechanical contrivances required in special operations upon the intestines in general particularly in the operations of entero-enterostomy.

III. Instruments used in operations upon the rectum and anus—see the operations upon those structures.

ENTEROTOMY.

Description.—Incision of intestine, with closure of wound at the same sitting. Generally resorted to for the removal of foreign bodies from the intestinal canal, or as a step in some operation. Formerly used in the same sense as enterostomy.

Preparation—Position—Landmarks—Incision.—As in Median Abdominal Section (page 631).

Operation.—(1) Having exposed that portion of the intestine which is to become the site of the operation, the coil involved is lifted out of the abdominal cavity and placed upon a warm, wet, sterile towel—the rest of the abdominal cavity and the other coils of intestine being protected by gauze packing. (2) The intestinal contents are pressed away from the site to be opened and the intestine is clamped proximally and distally to the operation-site. (3) Incision into the intestine is made upon its anti-mesenteric border, in the long axis of the gut—exercising care that the opposite intestinal walls be not injured. If the canal contain a foreign body, this may usually be cut down upon directly, its presence protecting the other coats. Otherwise the assistant should so hold the gut that its walls are separated while the surgeon makes a rapid, controlled stab into the lumen with a sharp, narrow bistoury, in order that the mucous membrane may not be simply protruded ahead of the incision. The keeping of the opposite walls apart during incision is best accomplished by gently grasping the lateral aspects of the intestine (a little nearer the anti-mesenteric than the mesenteric border) with forceps (or with the fingers, or thread retractors passing only through the outer coats) and drawing them apart laterally, while the mesenteric border is simultaneously drawn downward, thus forming a hollow triangle within the lumen of the gut. The wound in the intestine may be enlarged in the act of withdrawing the original bistoury—or by means of a blunt-pointed bistoury separately inserted—or one blade of blunt-pointed scissors may be introduced and the opening thus enlarged. (4) Care is used in preventing any unnecessary escape of intestinal contents—and all sites of possible infection are packed off. (5) The object of the operation having been accomplished, the wound in the intestine is closed by one of the methods of intestinal suturing described under Enterorrhaphy (usually with Lembert sutures). The abdominal wound is closed in the ordinary manner.

ENTERORRHAPHY IN GENERAL.

Description.—Union of intestinal tissue by suturing. Sutures are of two kinds—Interrupted, each suture being formed of a separate thread;—Continuous, the entire line of suturing being formed of one thread. The features in favor of interrupted sutures are:—the strain is upon many rather than upon one thread, and is more evenly distributed; the blood-supply of the edges of the intestine is less interfered with; the giving-way of one thread is not so serious. The feature in favor of the continuous suture is its rapidity of application. Linear Enterorrhaphy is generally used of suturing limited wounds or incisions of the intestine, whether in the long axis or transversely.

Circular Enterorrhaphy is usually used of suturing the entire circumference of intestine after complete transverse or oblique division of the gut.

Characteristics of a Satisfactory Intestinal Suture.—The following, modified from Treves, are the features possessed by the best forms of suture;—(**a**) Two broad peritoneal surfaces should be brought into contact. (**b**) Closure should be tight enough to hold water. (**c**) The mucous membrane, if included, should not be penetrated by the same suture which passes through the serous coat (which might enable the intestinal contents to escape by capillarity). If only one tier of suturing be used, the mucous membrane should not be included. (**d**) Suturing should not be sufficiently tight to strangulate the edges of the intestine compressed by the sutures. (**e**) The method should be simple enough to be easily and rapidly carried out. (**f**) The suture should take a sufficiently firm hold of the intestine to run no chance of tearing out when put to a fair test. (**g**) The suture should pass through the serous, muscular, and part of (into) the relatively strong and thick submucous coat. (**h**) The material of suture must be sufficiently durable and of non-irritating quality.

Suture Materials.—Silk, fine, strong and preferably colored black (for more easy detection). Catgut, fine, plain, or chromic, may also be used, though less trustworthy and not capable of making so neat a suture knot line. All suture-materials should be tested before being used.

General Considerations in Intestinal Suturing.—(**1**) The intestine involved is exposed through the simplest incision, generally by median abdominal section, or by enlargement of a previous wound. The portion of intestine to be operated upon is drawn out of the abdomen and laid upon a warm towel wrung out of sterile normal salt solution, and steadied by an assistant. (**2**) Some form of intestinal clamping should be used to prevent the escape of the contents of the gut. One clamp should be placed upon the proximal and one upon the distal side of the site operated upon. The index-finger and thumb of each hand may be used in place of an instrumental clamp, though generally less satisfactorily. Before the application of any manner of clamping, the contents of the intestine should be pressed away from either side of the site of operation by a process of manipulation resembling that of milking—so that the tract included within the clamps may be as free of intestinal contents as possible. (**3**) Avoid, as completely as possible, the escape of intestinal contents—and if the escape be inevitable, provide for the catching of the escaping fluid upon abundant gauze packing, which is immediately removed and other put in its place. (**4**) Control all unnecessary hemorrhage by making incisions in as non-vascular regions of the site to be operated upon as possible. All bleeding vessels are caught with artery forceps and tied with fine silk or catgut, preferably the latter, in the case of smaller vessels. (**5**) The general feature of intestinal suturing is to bring surfaces of serous membrane into contact for union—preceded or not by a primary tier of suturing which approximates the mucous coats alone, or all the coats. (**6**) Theoretically, it is well to aim at including part of the submucous coat, but, practically, what is generally done is to include all of the serous and most of the muscular coats. The submucous coat of the intestine is tough and strong, and it should be the aim to include it in all intestinal suturing—though it is sometimes difficult to include the submucous without also including the mucous coat. (**7**) While theoretically it is well not to have the same suture which passes through the serous also pass through the mucous coat, yet practical experience has shown that in many instances where this is done no harm has resulted—and some surgeons

do not attempt to avoid it—though it should, however, be avoided if possible. (8) All sutures should be tied with a surgeon's knot. In intestinal suturing it would seem that the use of two tiers of different kinds of suture makes a better juncture than the two tiers of one kind—thus a continued and interrupted combine may be considered better than two continued or two interrupted. (9) Interrupted sutures have a tendency to permit lateral expansion at the site of suturing—continuous have the opposite tendency—and therefore, theoretically at least, the latter encroach more upon the lumen of the gut. The interrupted form of suturing may generally be considered the better form of intestinal suturing in the majority of cases. (10) Often the suturing can be expedited by placing two or four temporary silk traction sutures through the serous and muscular coats in such a position as to draw into two parallel folds or ridges the two edges to be apposed when the traction sutures are held by an assistant who draws upon them. (11) Needles should be used which displace rather than cut the tissues through which they pass on their way through the intestinal coats. The straight domestic needle or the instrument-makers' round straight or curved needle is the best. The curved needle always, and the straight needle sometimes, require a needle-holder. (12) The abdominal cavity should be cleansed, if soiled, at the end of the operation—by means of gauze mops, with or without irrigation, as indicated. (13) Whether or not the abdomen will be closed without drainage will depend upon the nature of the case. In simple, clean suturing, the abdomen is closed without drainage. (14) Very many forms of intestinal suture are used—only those most generally employed will be here given.

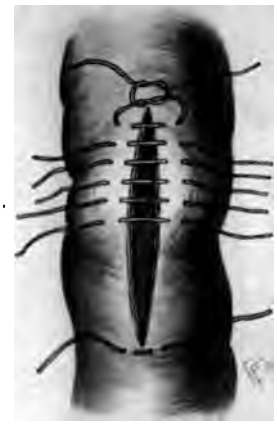

Fig. 364.—ENTERORRHAPHY BY THE LEMBERT INTERRUPTED SUTURE.

ENTERORRHAPHY BY LEMBERT'S INTERRUPTED SUTURE.

Description.—(1) The suture is carried across at a right angle to the line of intestinal wound to be closed—the needle picking up a fold on one side of the wound—and a similar fold on the directly opposite side—whereby, when the knot is tied, the serous surfaces of the two lips of the wound are approximated and the edges of the wound are invaginated into the lumen of the gut. (2) The fold of serous, muscular, and part of submucous coats

picked up will be about 2 to 2.5 mm. ($\frac{1}{12}$ to $\frac{1}{10}$ inch in width)—the needle emerging about 2.5 to 3 mm. ($\frac{1}{10}$ to $\frac{1}{8}$ inch) from the edge of the wound—entering the opposite lip of the wound at the same distance from its edge and traversing the same amount of tissue as on the first side. The sutures will be about 2.5 to 3 mm. ($\frac{1}{10}$ to $\frac{1}{8}$ inch) apart. (3) All sutures are placed before any are tied--except that where the line to be sutured is somewhat long, a few sutures may be applied at intervals and at once tied, so as to evenly divide and fix the parts. The knots are not to be tied too tightly (for fear of cutting through or strangulating the parts)—and are cut quite short (so as not to interfere with the process of invagination of the edges). (4) The sutures are generally applied with one long thread and a single need'e, cutting the thread at the end of each completed suture. Or numerous needles may be threaded with short lengths of thread. (5) Four temporary traction-sutures, passed through the outer coats of the intestine, placed on the opposite sides of the wound and at each of its ends, if drawn upon in a line with the suturing, will raise two parallel folds which will make the insertion of sutures easier, more rapid, and more regular. They should be placed just to the outer side of the lips of the wound so that the folds caused by their traction will represent the surfaces which are to be approximated by the permanent sutures. (6) For manner of application, see Fig. 364, and also Fig. 365, A.

Comment.—The best all around suture.

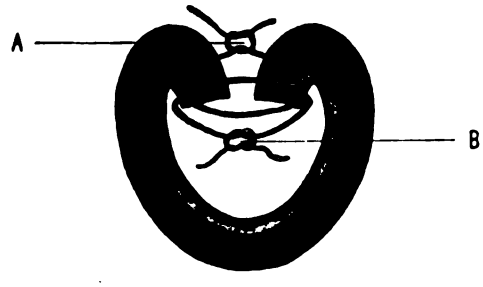

Fig. 365.—ENTERORRHAPHY BY THE CZERNY-LEMBERT INTERRUPTED SUTURE:—A, Interrupted Lembert suture through serous, muscular, and part of submucous coats—applied from without; B, Interrupted Czerny suture through mucous and part of submucous coats—applied from within. The latter is applied first. (Modified from Esmarch.)

ENTERORRHAPHY BY THE CZERNY-LEMBERT INTERRUPTED SUTURE.

Description.—(1) By this method the mucous membrane is first separately sutured with the Czerny suture, the sutures being so introduced as to bring the knots within the lumen—and then the serous, muscular, and part of the submucous coats are united by the ordinary Lembert method. (2) The passage of the Czerny suture is a little difficult if it be desired to have all the knots fall within. The mucous membrane of one side of the wound is caught with delicate forceps and steadied, and, at the same time, drawn forward into view and slightly everted—a curved needle, held in a holder, is then passed from the mucous surface of the mucous membrane outward entirely through that membrane and part of the submucous coat--then the mucous membrane of the opposite edge of the wound is similarly

seized with forceps, and, while similarly held, except without eversion, the needle is now passed in the reverse direction, from without inward, through part of the submucous coat and the mucous membrane. The two ends of the thread are therefore toward the lumen and, when tied, the knot will be within. When tying the last one or two knots, it will be necessary to protrude them within the lumen with the blunt end of a probe. The above method of applying the sutures is especially necessary in suturing short wounds and in completing the line of circular suturing after resection of the intestine. For two-thirds of the distance in circular enterorrhaphy, following intestinal resection, the Czerny sutures can be readily applied—it is only toward the latter part, when the lumen is almost excluded, that their application becomes more difficult. If there be any likelihood of the first part of the last one or two knots slipping, make that part a friction-knot. (3) The passage of the Lembert sutures is accomplished in the usual fashion—and, when tied, completely covers in the Czerny sutures. (4) Some surgeons apply the sutures through the mucous membrane in the ordinary manner, tying the knots toward the surface, depending upon the Lembert row to bury them. (5) For the manner of applying the suture, see Fig. 365; also see Fig. 384 (Czerny-Lembert Entero-enterostomy).

Comment.—Confusion often exists between the Czerny-Lembert and the Wölfler sutures. They are practically the same.

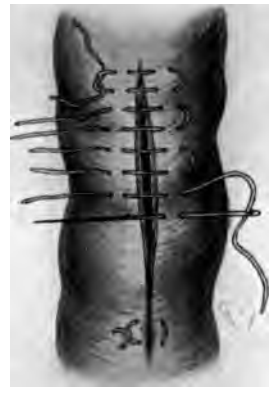

Fig. 366.—ENTERORRHAPHY BY HALSTED'S INTERRUPTED QUILT (OR MATTRESS) SUTURE.

ENTERORRHAPHY BY HALSTED'S INTERRUPTED QUILT- OR MATTRESS-SUTURE.

Description.—(1) This is a modification of the Lembert principle—and consists in an ordinary quilt- or mattress-suture (the terms being used synonymously) so applied that the looped end is upon one side of the wound and the two free ends upon the opposite side—the thread passing through the serous, muscular, and especially a part of the tough submucous coats. (2) As to the manner of their application, each quilt-suture may be regarded as composed of two parallel Lembert sutures, united by the loop. When the knot is tightened, folds of serous surfaces from the two sides are brought

into contact—the fold on one side being held by the loops—on the other, by the knots. (3) For manner of application, see Fig. 366.

Comment.—It is claimed that these sutures compress the tissues less, take a stronger hold, and approximate the parts more accurately. It is probably the next best interrupted suture to Lembert's.

ENTERORRHAPHY BY LEMBERT'S CONTINUOUS SUTURE.

Description.—(1) This suture passes diagonally back and forth from side to side, between the lips of the intestinal wound, passing through serous, muscular, and part of submucous coats. When the suture is drawn tight, two folds of serous surfaces, parallel with the edge of the wound, and parallel with each other, are brought into contact. (2) The general principle of the introduction of the continuous Lembert suture follows that of the interrupted Lembert suture—except that the former is applied continuously, and the needle-punctures are made in a direction slightly obliquely to the cut margins

Fig. 367.—Enterorrhaphy by the Lembert Continuous Suture.

of the intestinal wound—the general rule as to the distances being about the same in both methods. (3) For the manner of application, see Fig. 367.

Comment.—The most quickly applied of the regular continuous intestinal sutures (those approximating serous surfaces).

ENTERORRHAPHY BY CUSHING'S RIGHT-ANGLED CONTINUOUS SUTURE.

Description.—(1) In this suture the thread is carried along in its onward progress exactly parallel with the edge of the wound in the intestine—and when the wound is crossed, the crossing is always directly at right angles to the course of the wound. The suture is everywhere buried except where it crosses the wound, and even this part of the suture is buried by the invagination of the lips of the wound when the thread is drawn tight. (2) Having begun the suture by passing through the serous, muscular, and into the submucous coats, a short distance from and directly opposite one end of

the wound, the thread is knotted in the ordinary manner—the needle is then carried outside of the intestinal wall onward to a point a short distance to one

Fig. 368.—ENTERORRHAPHY BY CUSHING'S RIGHT-ANGLED CONTINUOUS SUTURE.

side of the edge of the wound—passes beneath the serous, muscular, and into the submucous coat, parallel with the edges of the wound—emerges a short distance beyond—crosses, outside, at a right angle to the wound—to a point

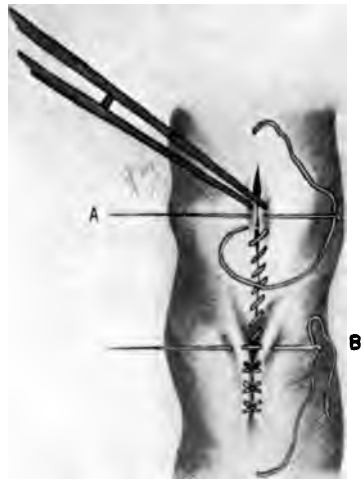

Fig. 369.—ENTERORRHAPHY BY COMBINED OVERHAND CONTINUOUS SUTURE OF ALL THE COATS, FOLLOWED BY INTERRUPTED LEMBERTS OF THE OUTER COATS:—A, Continuous overhand suture; B, Interrupted Lemberts.

on the other side directly opposite its last emergence—travels similarly forward beneath the serous, muscular, and part of the submucous coat for a

short distance—thence back across the wound at a right angle, to the original side—and thus on to the opposite end of the wound, beyond which it is carried a short distance and then knotted. Before the final knotting the thread is drawn tight, thus infolding the margins of the wound and approximating the serous surfaces. (3) For manner of application, see Fig. 368.

Comment.—Cushing's method of knotting, at either end, is unnecessarily complicated.

ENTERORRHAPHY BY COMBINED OVERHAND CONTINUOUS SUTURE OF ALL COATS, FOLLOWED BY INTERRUPTED LEMBERT SUTURING OF OUTER COATS.

Description.—(1) This method consists, first, in whipping together the edges of the wound by a simple, running, continuous, overhand suture, passing through all the coats of each margin of the wound, as a preliminary suture of approximation and strength—which is then followed by a secondary tier of generally either the interrupted or continuous Lembert sutures passing through the serous, muscular, and part of the submucous coats. (2) For manner of application, see Entero-enterostomy by simple suturing (page 676), for the general description of the method,—and Fig. 369, for its application to a limited wound.

ENTERORRHAPHY FOR WOUNDS OF THE INTESTINE.

Description.—Wounds of the intestines may be divided into five classes; (a) Longitudinal wounds, incised or lacerated; (b) Transverse wounds, incised or lacerated; (c) Irregular wounds, incised or lacerated; (d) Complete transverse division of the intestine; (e) Contused wounds.

Preparation—Position—Landmarks.—As for median abdominal section.

Incision.—In the majority of cases the incision will be in the median line, as for median abdominal section. If the abdominal wound, which may already exist, lie outside of either rectus, and especially if it be indicated that the wound has not ranged toward the median line, the incision is frequently made vertical over the external abdominal wound.

Operation.—(1) Having entered the abdominal cavity, the edges of the wound should be well retracted in order to expose the involved coils of intestine. (2) All bleeding vessels should be controlled by clamp and gut-ligature before proceeding to the intestinal operation. (3) If the omentum be found wounded, the lips of the wound should be approximated by gut-suture. (4) Unless the wounded coil of intestine be readily detected, it is best to systematically examine the intestines, beginning at the stomach—lifting the stomach and transverse colon to trace the duodenum—and then, catching up the beginning of the jejunum beneath the ligament of Treitz, follow down the rest of the small and large intestines. (5) Some surgeons clamp each wound, in the case of gunshot wounds, as found—and suture none until all are clamped in order to control intestinal contents. (6) Coils of intestine temporarily removed from the abdominal cavity should be surrounded with warm, wet, sterilized gauze or towels, with or without a preliminary enveloping with sterile rubber tissue. (7) All escaped intestinal contents should be wiped away with gauze, or, if excessive, by irrigation. (8) If the mesentery be wounded, the edges of the wound should be sutured

with gut sutures. (9) Having brought the involved portion of intestine into the field of operation, the wound is repaired as indicated by the special case. (10) Simple longitudinal wounds are closed by a line of interrupted Lembert sutures. (11) Simple transverse wounds are closed in the same manner as longitudinal ones. (12) In irregular wounds, if consisting of a transverse and longitudinal wound (the two arms crossing each other at a right angle or diagonally) and not too extensive, the part of the transverse wound on one side of the longitudinal wound should be first closed with interrupted Lembert sutures—then similarly the part of the transverse wound on the other side—then the entire length of the longitudinal wound by interrupted Lemberts placed transversely to its length. (See Fig. 370.) Sometimes the two parts of the transverse wound and the ends of the longitudinal are closed as just described—and then the remaining portions of the sides of the longitudinal are sutured after the fashion of suturing the intestine in Enteroplasty for stricture. (See Comment.) Such an irregular wound as that made by a bullet, if not too large, may be treated as an ordinary wound, being sutured with Lembert sutures in such a way as to infold its margins. Sometimes the

Fig. 370.—ENTERORRHAPHY IN IRREGULAR WOUNDS OF THE INTESTINES:—The two limbs of the transverse wound being first sutured with interrupted Lemberts, and then the two limbs of the longitudinal wound.

ragged edge of a bullet wound may be advantageously trimmed with curved scissors before suturing. Where destruction has been great, resection of a portion of the intestine, followed by some form of intestinal anastomosis, is generally safer. (13) Complete transverse division of the intestine will necessitate an end-to-end anastomosis, by means of a simple suturing or some mechanical device. (14) Contused wounds, if at all bad, should be treated as lacerated wounds, as the walls of such wounds are rendered of lowered vitality by the traumatism. The contused surface is thus turned into the lumen of the gut by Lembert sutures, where, if sloughing of the portion within the line of sutures occurs, no harm is done. (15) The injury to the intestine having been repaired, the abdomen is closed as in median abdominal section, with or without drainage, as indicated by circumstances.

Comment.—(1) Lembert or Halsted interrupted sutures are generally best in suturing intestinal wounds. (2) If any doubt exist as to the efficiency of the first row of sutures, a second tier, generally continued Lembert, may be put in, burying the first. (3) Areas of suspicious suturing may be strengthened by suturing over them omental grafts (elliptical pieces taken from the omentum followed by suturing up the lips of the wound thus made in the

omentum)—these are applied over the intestinal suturing and held in place by two or three gut sutures. (4) Resection, followed by an entero-enterostomy, is preferable to any form of suturing, if by such form of simple suturing the lumen of the gut will be reduced to less than half its diameter. (5) Transverse suturing interferes less with the vascular supply than the longitudinal—especially when the longitudinal is near the mesenteric border. (6) A longitudinal wound of considerable length, and more or less breadth, the ordinary suturing of which might reduce its calibre too greatly, may be repaired by what is termed "elbowing" (such as is seen in the joining of segments of stove pipes). The intestine is bent somewhat upon itself, the center of the bending being the center of the wound—then one half of one side of the wound is joined, by interrupted Lembert sutures, to the other half of the same side—and the same steps are carried out on the opposite side. This is applicable only to wounds on or toward the antimesenteric border. The edges of the wound may be sometimes trimmed prior to suturing. Too great narrowing, as might result from simple suturing, or even resection, is hereby avoided.

PARTIAL ENTERECTOMY.

Description —By partial enterectomy is meant the excision, or resection, of a part of the intestinal canal, with or without the excision of the corresponding portion of the mesentery. By prefixing the name of the part of the canal, the site of the partial excision is designated—Partial Duodenectomy, Jejunectomy, Ileectomy, Cæcectomy, Colectomy (ascending, transverse, or descending), Sigmoidectomy, Rectectomy. By the term Enterectomy alone is usually understood an excision of some part of the small intestine. As, of course, excision of the whole intestine is never considered, Enterectomy is generally used in the sense of a partial excision, without the preceding word "partial." Enterectomy carries with it the idea of three operations—partial excision of the intestine—partial excision, or incision, of the mesentery—intestinal junction. The operation is generally resorted to where the disease or injury to a part of the intestine, or its mesentery, is so extensive that a portion of the intestine must be cut out and sacrificed.

Preparation - Position—Landmarks—Incision —As for median abdominal section (page 631).

Operation —(1) Having opened the abdomen, the portion of intestine involved is brought out into the field of operation. (2) Before excising any portion of the intestinal tract, the contents of that part should be removed from it as much as possible—which is best accomplished by "milking" the intestines in opposite directions from a central point, the center of the part to be excised—and then clamping the intestines, proximally and distally, beyond the site to be removed. Various forms of clamps are used for this purpose, which may be divided into three categories;—(**A**) Special intestinal clamps, which are generally best (Fig. 371, C);—(**B**) Improvised clamps may be used, such as; (**a**) Pierce the mesentery near the intestinal border with the closed ends of a pair of forceps -grasp a small rubber tube in the bite of the forceps and draw it through the mesentery—and tie the two ends over the intestine (Fig. 371, E); (**b**) Pass a sterilized wooden toothpick through the mesentery, near the intestine, and make a figure-of-8 with a rubber band over it, compressing the intestine between toothpick and rubber band (Fig. 371, D); (**c**) Pass the pin of a safety-pin through the mesentery, near the intestine—and fasten, in the act of closing the pin, a small piece of flat sponge over the intestine (Fig. 371, A), (**d**) Pass

a piece of gauze through the mesentery, near the bowel, and tie over the intestine after the fashion of the rubber tube in (e) above:—(C) The thumb and index of each hand of an assistant may be used to compress the intestine in the position a pair of clamps would occupy—after having pressed away the intestinal contents (Fig. 371, B). (3) The indicated portion of the intestine is now excised—by dividing the gut on either side of the segment to be removed, with scissors or knife, exactly at a right angle to the length of the intestine at the part divided—so that the cut ends may be afterward approximated without any tension at either mesenteric or antimesenteric aspect. (There is somewhat greater retraction of the antimesen-

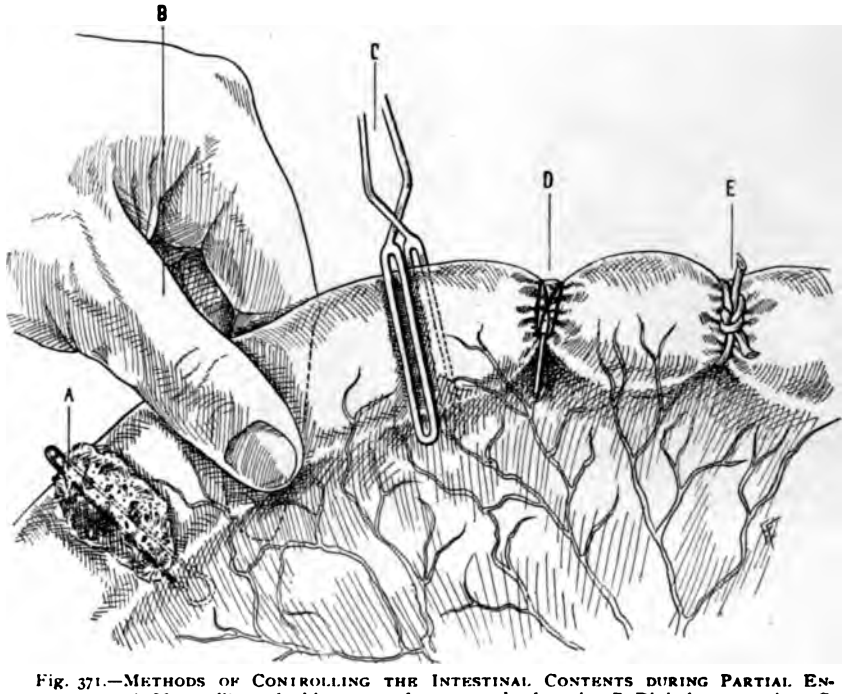

Fig. 371.—Methods of Controlling the Intestinal Contents during Partial Enterectomy:—A, Maunsell's method by means of sponge and safety-pin; B, Digital compression; C, Special intestinal clamps; D, Toothpick, or similar object, piercing the mesentery, with an ordinary rubber-band passed over it in figure-of-eight fashion; E, Rubber tube passed through mesentery and tied over the intestine. (Whichever method of control be used, the same method is generally applied on each side of the area to be excised.)

teric border naturally.) Division of the intestine with a knife is better than by means of scissors, which latter compress the edges somewhat. It is well to have, if possible, a good artery left just to the proximal side of the proximal intestinal incision, and one on the distal side of the distal intestinal incision—to furnish nourishment to the uniting edges. The triangular space, at the separation of the leaves of the mesentery, will be opened up—and care should be exercised not to bare the intestinal tube further than necessary. (4) The treatment of the mesentery corresponding with the excised portion of the intestine differs—one of the following methods may be used:—(a) Probably the best plan, after having excised the portion of intestine, is to remove a triangular or V-shaped piece of the mesentery—whose base will be a little

narrower than the section of the intestine removed—whose sides will pass down obliquely toward each other in the direction of the root of the mesentery, but meeting midway between the two free ends of the intestine and before reaching the root of the mesentery. The division is made with a knife or scissors, from a line with the free ends of the divided intestines at their mesenteric borders—taking care to preserve the artery supplying the free end of the intestine, proximally and distally. In suturing, the edges of the cut mesentery are approximated with gut by continuous or interrupted suture (Fig. 372, A and B). Or the edges may be slightly overlapped and then sutured, uniting laterally (Fig. 372, C). All vessels which fall along the line of division of the mesentery, whose position is shown through the thin mesentery, should be ligated, proximally in advance of the division—by

Fig. 372.—Methods of Suturing the Mesentery in Partial Enterectomy:—A, A V-shaped portion of mesentery excised, with suturing of edge to edge by continuous suture; B, Same, with suturing of edge to edge by interrupted sutures; C, Same, with edges overlapped by running suture; D, Mesentery left intact, with free edges sutured together by continuous overhand stitch; E, Same, with suturing of both free border and free fold of redundant mesentery to main mesentery, together with closure by continuous suture of entrance to mesenteric pocket. Note—Several mesenteric vessels are shown ligated, by the passage of needle and gut-ligature beneath them.

passing a curved needle armed with gut, beneath them,—or the vessels may be clamped immediately after division and then ligated (see Fig. 372). This method is especially advisable in malignant disease where the mesenteric glands may be involved. (**b**) Another method is, after dividing the intestine at both ends, simply to cut away the excised portion close along the mesenteric attachment, after having ligated its vessels as in the above method. In suturing, the redundant mesentery is simply folded upon itself and a few gut sutures passed from side to side, along the angle of junction with the rest of the mesentery—and by whipping the free margins with a gut suture, to prevent a hernia occurring through the opening. This method probably insures a better blood-supply to the intestine (Fig. 372, D). (**c**) In addition to the steps mentioned in the last method, the entire triangular fold may

be sutured back to the general mesentery by sutures along its folded border, as well as along its free border (Fig. 372, E).

Comment.—Partial Enterectomy is an incomplete operation in itself—and naturally carries with it the idea of suturing together the two free ends of the intestinal canal left open after the excision, and thus repairing the intestinal tract—but since the junction of these two ends is accomplished by a separate and distinct operation, it will be treated of separately. (See Entero-enterostomy.)

ENTERO-ENTEROSTOMY.

INTESTINAL ANASTOMOSIS, APPROXIMATION, AND IMPLANTATION, IN GENERAL.

Intestinal Anastomosis was originally applied to the operation of establishing a communication between the intestine above and the intestine below the seat of obstruction, without the removal of the portion of intestine in which the obstruction was situated. As a result, the larger part of intestinal contents would flow by the new route, thus "short-circuiting" the obstruction, while the smaller portion would flow through the partially obstructed canal, until the obstruction was relieved or became complete. As, in such cases, no portion of the intestine was removed, the Anastomosis was always a Lateral Anastomosis, that is, the joining of the lateral aspect of one coil with the lateral aspect of another coil. Subsequently, however, Intestinal Anastomosis came to be used, by many surgeons, in the same sense as Intestinal Approximation, and applied to both end-to-end and to lateral joinings.

Intestinal Approximation was originally used to signify the union of the portions of the intestinal tract following the excision of a part of the canal—the approximation being either end-to-end or lateral. In End-to-end Intestinal Approximation, after the excision of a part of the intestine has been accomplished, the free ends of the intestine above and below are approximated and united. In Lateral Intestinal Approximation, after the partial enterectomy has been performed, the free ends of the intestine above and below are closed by suture, and then the lateral aspect of the closed upper end is approximated and united to the lateral aspect of the closed lower end.

Intestinal Implantation has generally been used to signify the implantation, or union, of the end of one piece of intestine into an opening in the lateral, antimesenteric aspect of another coil—following the excision of a segment of intestine. This process of union imitates the union of the ileum with the colon (cæcum).

Entero-enterostomy signifies the junction of the lumen of some part of one intestinal coil with the lumen of some part of another. Strictly speaking, therefore, Entero-enterostomy is a term of broader significance than those above used, and includes Anastomosis, Approximation, and Implantation. No hard-and-fast rule, however, exists as to the use of the terms designating the union of coils of intestine, but the shades of difference expressed in the terms Intestinal Anastomosis, Approximation, and Implantation might probably be more accurately expressed by the terms Entero-enterostomy by Lateral Anastomosis—Entero-enterostomy by End-to-end Approximation—Entero-enterostomy by Lateral Approximation—Entero-enterostomy by End-in-side Implantation. While, therefore, Entero-enterostomy expresses the junction of lumina of segments of intestine, the method of that junction is best expressed by following the term with some qualifying words.

The Scope of the Methods of Intestinal-joining.—Many of the methods used for variously uniting segments of the intestines to each other are also used to unite portions of the intestines with different parts of the stomach—and also with the gall-bladder. The range of usefulness of any method of intestinal joining, therefore, is measured by the ability of that special method to meet the requirements of the following operations involving the intestines:—Entero-enterostomy by Lateral Anastomosis; Entero-enterostomy by End-to-end Approximation; Entero-enterostomy by Lateral Approximation; Entero-enterostomy by End-in-side Implantation; Simple Gastro-enterostomy (by lateral anastomosis, or end-in-side implantation); Gastro-enterostomy following pylorectomy; Cholecystenterostomy.

The Methods of Accomplishing Intestinal Joinings—(1) Union of portions of Intestinal, Gastro-intestinal, and Cholecyst-intestinal tracts by simple suturing;—(2) Union of portions of Intestinal, Gastro-intestinal, and Cholecyst-intestinal tracts by absorbable mechanical devices;—(3) Union of portions of Intestinal, Gastro-intestinal, and Cholecyst-intestinal tracts by non-absorbable devices;—(4) Union of portions of Intestinal, Gastro-intestinal, and Cholecyst-intestinal tracts by mechanical means temporarily used during suturing.

Note.—In the various operations of Entero-enterostomy it is not necessary that any previous excision (partial enterectomy) must have been done—though such an excision may have been done. In the following operations of Entero-enterostomy the joining of the portions of intestine will (to make the operation more complete) be supposed to follow, in the majority of cases, excision of some part of the gut. Of course, the same operations which are applicable after the excision of a part of the intestine are also applicable after a circular division (circular enterotomy) of the gut without any excision of a part of the canal.

(A) ENTERO-ENTEROSTOMY BY METHODS OF SIMPLE SUTURING

IN GENERAL.

Union is here accomplished by the ordinary methods of suturing, unaided by mechanical devices other than sutures.

(1) For the general principles of intestinal suturing, see Enterorrhaphy in General. (2) Fine silk or fine chromic gut may be used throughout. Or silk may be used for the first tier and chromic gut for the second. This applies whether the first tier includes all the coats or only the mucous membrane. (3) Some surgeons prefer to use only interrupted sutures throughout in intestinal suturing—upon the ground that in continuous suturing (especially when of silk) the size of the opening becomes more or less fixed and less capable of the distention which, on the other hand, may readily occur in all forms of interrupted sutures. (4) It is well to bear in mind that sometimes Lembert interrupted sutures which may appear to be near enough in the undisturbed condition of the gut become too far apart when it is distended. (5) No matter what form of suturing be used for the first tier, the second tier should include only the serous, muscular, and, if possible, part of the submucous coats—and should bury in the first tier. (6) Difficulties encountered in placing sutures may be largely overcome by seizing the site to be sutured with delicate forceps and thus causing that part to meet the needle with its proper aspect rendered prominent by eversion, inversion, traction, etc. (7) When segments of unequal size are to be approximated end-to-end, the only way this can be done by simple suturing

is either, (**a**) to partially close the opening of the larger gut down to the size of the smaller, which may be accomplished by taking a V-shaped piece out of the antimesenteric aspect of the larger gut and then suturing together the edges of the V before making the junction,—or (**b**) by cutting the opening of the smaller gut obliquely (Wehr's method) instead of transversely, at the expense of the free border, and thus increasing its size to match the larger gut. The best methods, however, of uniting segments of unequal size are probably either by the Murphy button or the Maunsell method.

ENTERO-ENTEROSTOMY BY SIMPLE CONTINUOUS OVERHAND SUTURE OF ALL COATS, FOLLOWED BY INTERRUPTED OR CONTINUOUS LEMBERT SUTURES OF OUTER COATS.

Description.—The first tier of suturing is for approximation and strength —the second, for union of the serous surfaces and occlusion of the intestinal lumen.

Preparation—Position—Landmarks—Incision.—As for median abdominal section.

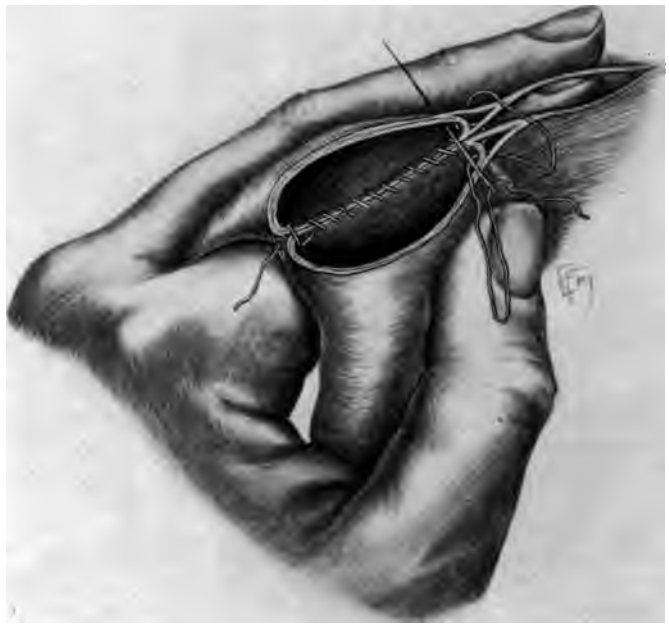

FIG. 373.—ENTERO-ENTEROSTOMY BY SIMPLE CONTINUOUS OVERHAND SUTURING OF ALL COATS, FOLLOWED BY INTERRUPTED OR (CONTINUOUS) LEMBERT SUTURES OF OUTER COATS:—A method of holding the intestine and introducing the first tier of simple continuous overhand suturing of all coats. Author's method.

End-to-end Approximation—Author's Method.—(1) Open the abdomen—isolate and bring forward the indicated coil of intestine—press away the intestinal contents—apply intestinal clamps, proximally and dis-

tally, to the site to be excised—and excise the portion of intestine, with or without the corresponding portion of mesentery (see Enterectomy). The two ends of the intestine are now brought into convenient apposition for suturing, and are held in apposition during the placing of the first tier of sutures. (2) The first row of continuous suturing passes through all the coats of proximal and distal segments of intestine, and consists of a continuous silk or gut suture carried upon a straight needle held in the fingers. The surgeon holds the approximated borders of the two coils of intestine over the radial aspect of his left first finger, approximating the opposite borders with the left second finger and thumb (or holds them over his

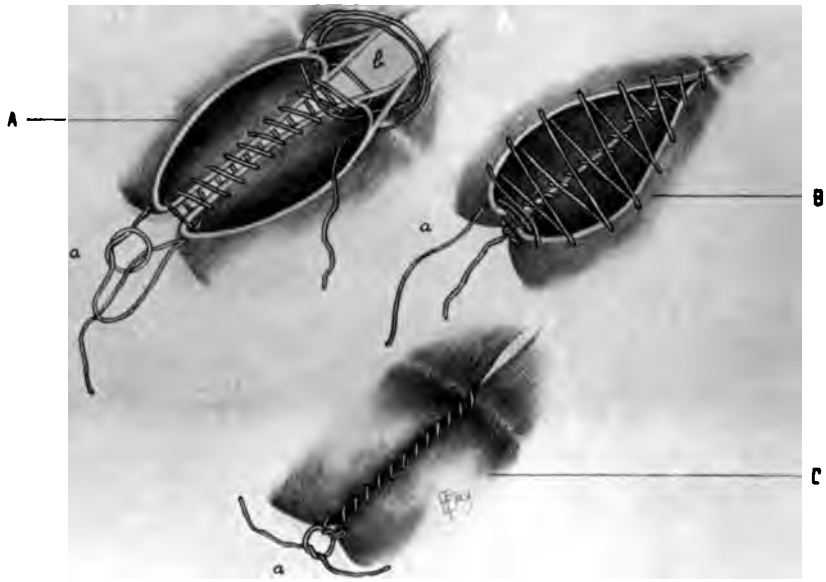

Figs. 374-376.—Details of Simple Continuous Overhand Suturing of All Coats, shown in Fig. 373.—A, Manner of knotting and beginning suture, at *a*—traversing posterior edges of intestines and including laminæ of mesentery at *b*, whence the suture starts to return; B, Manner of traversing anterior edges of intestines—and ending the suture at *a*, preparatory to knotting; C, Manner of tying final knot of first tier of sutures at *a*, and appearance of suture-line and approximated leaves of mesentery. Author's method.

left second finger, approximating with his left index and thumb). (See Fig. 373.) Four thicknesses of gut are thus brought together, two from the proximal and two from the distal end of the divided intestine. The adjacent aspects of the apposed edges should be first sutured. (See Fig. 374, A.) The needle should first enter at the antimesenteric borders, the first stitch being so placed as to leave the free end of the suture, after knotting, on the outside, which is done by beginning the stitch from without and then passing the needle back into the lumen after tying the first knot. After the needle has passed back into the lumen it should always, in going toward the mesenteric attachment, travel from within outward through the wall of the intestine on the right (nearer the operator) then from without inward through the wall of the intestine on the left (further from the operator) and so on, descending toward the

mesenteric aspect. The last stitch, before beginning the return, includes, besides the two thicknesses of the gut, also the two laminæ which are adjacent (one from the proximal and one from the distal portion of gut). And the first stitch, after beginning the return, includes, besides the two thicknesses of gut, also the two laminæ of mesentery (one from the proximal and one from the distal portion of gut) which are furthest from each other at the taking of the stitch, but which will be brought into contact by the stitch. (See Fig. 375, B.) The suturing is then continued back to the antimesenteric aspect in an overhand stitch, as before—passing, now, from without inward through the wall of the intestine nearer the operator, and from within outward through the wall of the intestine further from the operator. When the last stitch is reached, its free end on the outer side is knotted to the free end left on the outer side at the start.

Fig. 377.—ENTERO-ENTEROSTOMY BY SIMPLE CONTINUOUS OVERHAND SUTURING OF ALL COATS, FOLLOWED BY INTERRUPTED (OR CONTINUOUS) LEMBERT SUTURES OF OUTER COATS:—A method of holding the intestine and introducing the second tier of interrupted Lembert sutures, which is seen burying in the first tier of continuous overhand suturing. The assistant's hands are held in pronation while suturing the anterior, and in supination while suturing the posterior aspect. Author's method.

(See Fig. 376, C.) During the return-row of suturing care is taken that the stitches do not penetrate the coats already whipped together by the first row—which is easily avoided, as the edges are all in plain view as each needle-puncture is made. (3) The second row of suturing consists of interrupted Lembert sutures passing through the serous and muscular, and probably also the submucous, coats. The sutures are silk or chromic gut, carried upon a straight needle held in the fingers. The barrel of intestine is now held out straight by an assistant, who grasps it about 10 cm. (4 inches) on either side of the suture line—while the operator picks up a transverse fold of the gut wall near the original suture line by means of delicate forceps held in his left hand—and a similar fold just beyond the suture-line—passing the needle through both folds in the ordinary Lembert fashion. (See Fig. 377.) One half of the circumference of

the gut is sutured from one side, after which the intestine is turned over and the other half sutured from the opposite side. The sutures are inserted in the usual manner of the Lembert method—the forceps picking up the tissue in transverse folds and thus drawing it away from the opposite wall, thereby making the passage of the suture easier, and the penetration of the opposite wall impossible. Especial care is necessary as the diverging laminæ of the mesentery are encountered, in order that each lamina may be closely approximated to the barrel of its own segment of intestine and to the opposite lamina on the same side of the intestine. The Lembert sutures should, therefore, be continued on



Figs. 378 and 379.—Entero-enterostomy by Simple Continuous Overhand Suturing of All Coats, followed by Interrupted (or Continuous) Lembert Sutures of Outer Coats:—A. Another method of holding the intestines and introducing the first tier of simple continuous suturing of all coats; B. Diagram showing manner of introducing the three preliminary traction-sutures. Author's method.

down to the very junction of the mesentery with the intestine and slightly beyond.

Note. Instead of holding the intestines as above described during the placing of the first tier of sutures, several methods of holding them in apposition may be employed. Three interrupted sutures may be placed and knotted in loops as temporary traction-sutures—each including all the coats of the two adjacent walls of the proximal and distal segments of intestine—one placed at the mesenteric aspect—and the other two dividing the circumference of the severed ends into three equal parts. An assistant now draws these three loops in different directions (which a single assistant can do by hooking them over his fingers, if the loops are not too long)—whereby two objects are accomplished;

—one-third of the margins of each gut are brought into contact,—and the margins of the other two-thirds are held out of the way (and thus the penetration of their wall by the needle rendered impossible). While held in this manner, the adjacent margins of each third are whipped together by a continuous overhand suture—after which the temporary traction-loops are cut and withdrawn (or may be tied and cut short, as permanent interrupted sutures reinforcing the continuous ones). (See Figs. 378 and 379.) The second tier of interrupted

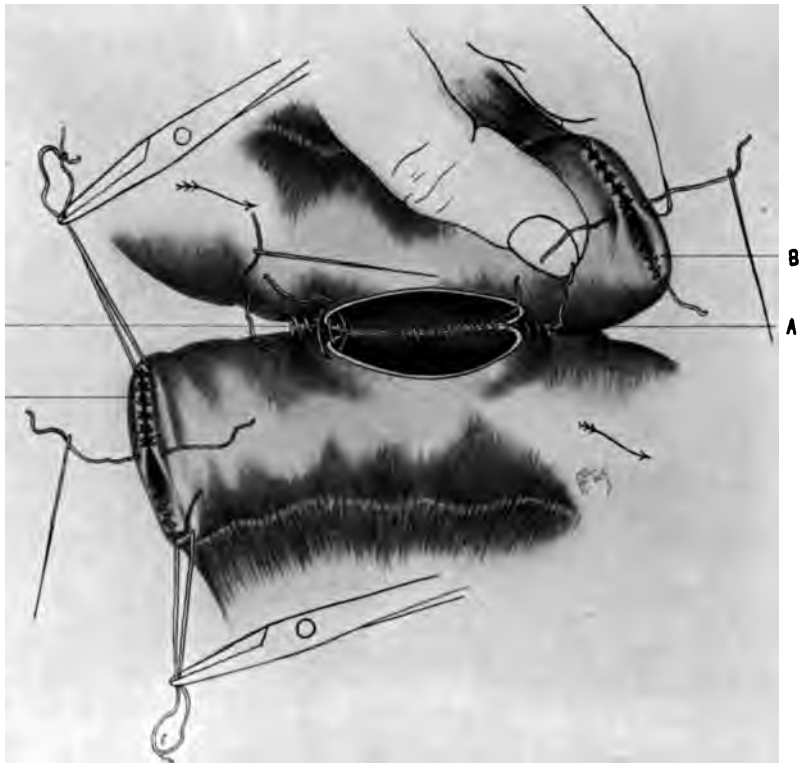

Fig. 380.—Lateral Intestinal Approximation by Simple Continuous Overhand Suturing of All Coats, Followed by Interrupted (or Continuous) Lembert Sutures of Outer Coats:—A, Showing manner of placing sutures along posterior aspect and at ends of incisions; B, Manner of holding end of intestine between thumb and index while placing the double suture; C, Manner of holding the ends with temporary traction-sutures passed through outer coats, while invaginating.

Lembert sutures is applied as just described. Or the traction sutures may be retained until the Lemberts are placed, to draw the edges parallel.

Lateral Approximation.—(1) Excise the indicated portion of intestine, with or without the corresponding piece of mesentery, as described under Enterectomy. (2) The proximal and distal free ends of the intestine are now each closed by one of the following methods: (a) Hold the free end of the intestine between the left thumb and index, and whip together the parallel walls by an overhand continuous suture of all the coats—followed by an invagination of this line of suturing by means of a line of interrupted or continuous Lemberts

(see Fig. 380, B).—(**b**) Pass a traction-suture at the mesenteric aspect, and another at the antimesenteric aspect, near to but not quite at the free margins—and, while these are drawn upon by an assistant, whip the free edges together as above—and, while further drawing upon them, invert the first suture-line with a probe, and place a row of Lemberts so as to permanently invaginate the first tier (see Fig. 380, C).—(**c**) The free ends of the intestine may be closed by a continuous overhand suture of all the coats while the walls of the intestine are still held in contact by the special forceps grasping the whole width of intestine, and along which they have been divided in the operation of enterectomy—followed by an invaginating Lembert tier, as above (see Fig. 381, B).—(**d**) The free end of each piece of intestine may be gathered together by an ordinary

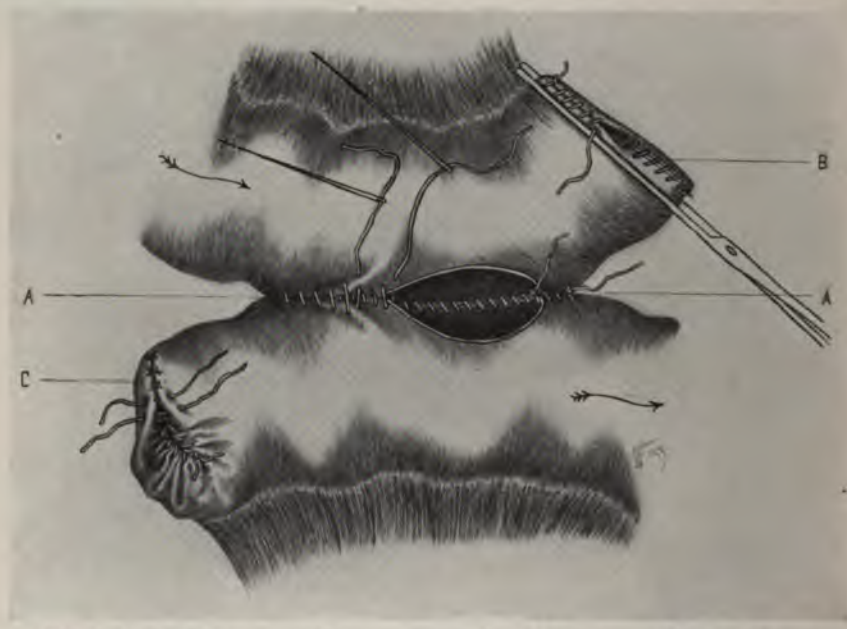

Fig. 381.—Lateral Intestinal Approximation by Simple Continuous Overhand Suturing of All Coats, followed by Interrupted (or Continuous) Lembert Sutures of Outer Coats:—A, Showing manner of carrying suture around ends and along anterior aspect of incisions; B, Manner of holding end of intestine with clamp-forceps while suturing; C, Manner of closing end of intestine with purse-string suture preparatory to placing final tier of end-sutures.

purse-string suture—and this first tier then further invaginated by a second tier of Lemberts, as above described (see Fig. 381, C). (**3**) Having closed the open ends of the gut, approximate these ends so that they overlap about 5 to 7.5 cm. (2 to 3 inches), with their antimesenteric aspects in contact—and have an assistant hold them in this position. (**4**) Place a tier of continuous Lembert suturing, of gut carried upon a curved needle held in a needle-holder, along what will be the posterior line of union between the serous surfaces—extending the line of suturing out at either end, in a somewhat elliptical form, beyond the limits of the future incision—leaving one end of the suture, after knotting, long and free—and the other end, also after half knotting, long and threaded upon the needle. (See Fig. 380.) (**5**) Incisions in the long axis of both pieces of intestine are now made opposite each other in the corresponding aspects of

the guts—and sufficiently far from the posterior suture-line to leave two free edges for suturing—and equidistant from what will form the anterior suture-line of the serous surfaces. These incisions will begin and stop short of reaching the outer limits of the surrounding Lembert suture-line which will enclose them. (6) The corresponding free margins of the wounds are now sutured with continuous overhand silk suture, carried in a curved needle held in a needle-holder. Begin the suturing at the right end of the posterior aspect (furthest from operator)—knot the suture and leave one end of the thread free—and continue the suturing toward the operator, until the posterior lips are united. Having reached the limit of the posterior aspect of the opening, the direction of the suturing now changes and is made to traverse the anterior aspect of the wound, similarly whipping together the anterior lips of the intestinal incisions from

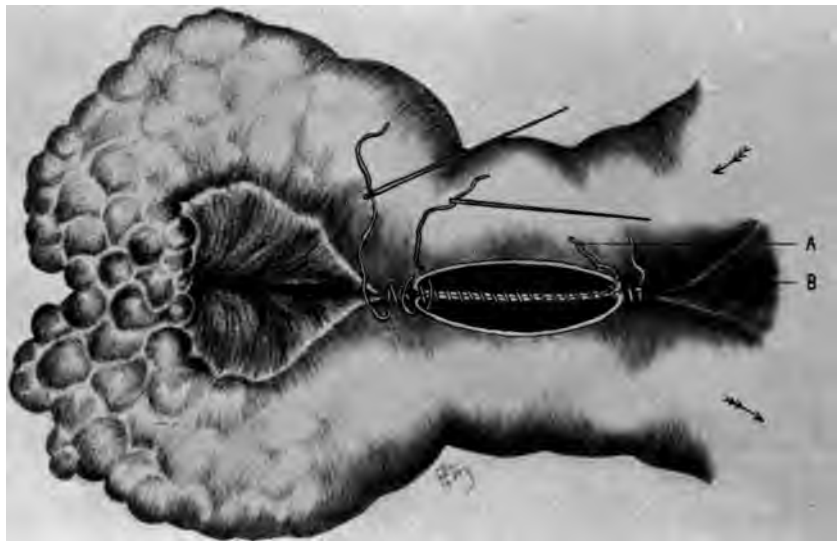

Fig. 382.—Lateral Intestinal Anastomosis by Simple Continuous Overhand Suturing of All Coats, followed by Interrupted (or Continuous) Lembert Sutures of Outer Coats:—A, Simple continuous overhand suture of all coats; B, Continuous Lembert suture of outer coats. The intestinal current passes as indicated by arrows, "short-circuiting" the cancerous growth.

left to right, away from the operator—until the point of beginning is reached, when the end from which the needle has just been withdrawn is knotted to the end previously left free—thus completely approximating the lips of the openings throughout. (7) The threaded needle of the original serous suture, which had been temporarily dropped, is now taken up—and this line of continuous Lemberts is carried on around the outside of the line uniting the edges, at the same distance from their edge as the posterior serous line passed—until the free end of line of serous suture, left at starting, is reached, when they are knotted together,—which completes the union between the intestines. (See Fig. 381.) (8) The mesentery is now sutured as indicated.

Lateral Anastomosis.—The operation is here performed in a precisely similar manner to the last (Lateral Approximation)—omitting the excision of any portion of the intestinal canal—the antimesenteric aspects of the gut being

brought into apposition. Care is taken that the intestinal coils are not twisted out of their natural relations. (See Fig. 382.)

Note.—In Lateral Approximation and Lateral Anastomosis, in order to prevent bagging, and sagging away of the intestines near the site of union, it is well to slightly scarify and suture (or suture alone) the free portions of the intestine together for about 2.5 cm. (1 inch) on either side of the union.

End-in-side Implantation.—(**1**) Following excision (for example, of the cæcum) the free end of the intestine, the lateral aspect of which is to receive the implanted gut, is closed by a double line of suturing in precisely the same manner as described under Lateral Intestinal Approximation. (**2**) An incision is

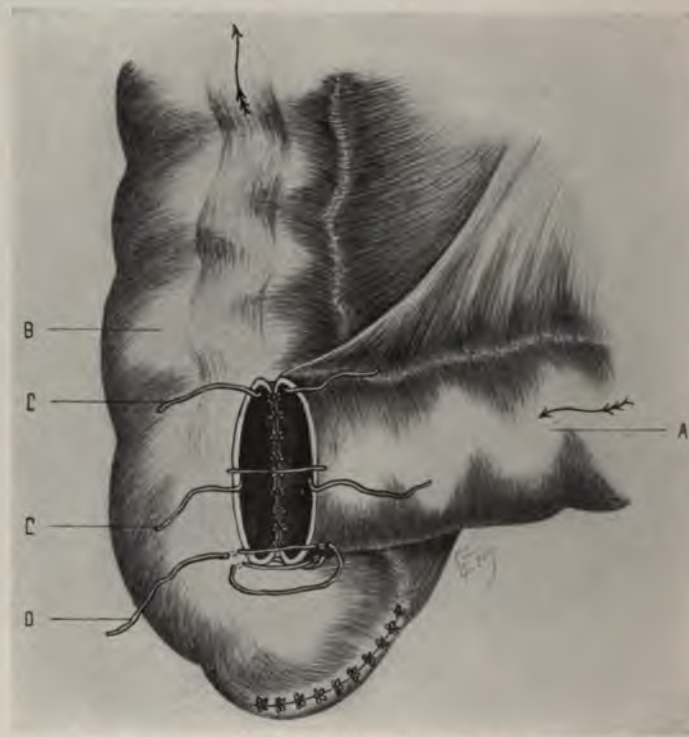

Fig. 383.—End-in-side Intestinal Implantation by Simple Continuous (or Interrupted) Overhand Suturing of All Coats, followed by Interrupted (or Continuous) Lembert Sutures of Outer Coats:—A, Ileum; B, Ascending colon; C, C, Interrupted sutures of all coats of both intestines; D, Continuous suture of outer coats.

made near the end of the invaginated gut corresponding with the end of gut to be implanted. (**3**) The open end of the gut which is to be implanted (usually of smaller calibre) is now brought into apposition with the incision upon the antimesenteric aspect of the gut which is to receive the implantation, at about 5 cm. (2 inches) from its sutured end—and held in contact by an assistant throughout the operation. A line of continuous overhand silk sutures, carried upon a curved needle held in a needle-holder, is placed through all the coats of both pieces of the intestine, in exactly the same manner as described under the Lateral Approximation operation, the difference in the direction of apposition of the two pieces of gut in the end-in-side implantation making no differ-

ence in the manner of application of the sutures. Interrupted sutures may be used instead of the continuous. The margins of the end-opening in one piece of intestine and the lateral openings in the other are thus brought together throughout. (4) A continuous or interrupted Lembert suture is now carried through the serous and muscular (and probably into the submucous) coats of the two pieces of intestine, in such a manner as to surround the first line of through-and-through suture in a somewhat elliptical fashion. (5) The mesenteric borders are sutured in such a manner as to leave no opening through which coils of intestine may pass. (See Fig. 383.)

Note.—(1) The same ultimate method of union may be accomplished in a somewhat different order. The serous surface near the free margins of the smaller gut may be attached, by Lembert sutures, to the serous surface of the invaginated gut, in such a position as to correspond with the future opening—the attachment being first along the posterior aspect, as in Lateral Approximation. An opening is then made by incision into the invaginated end corresponding with the partly attached free end of intestine. The free edges of the opening are then united throughout by continuous silk suture—after which the continuous or interrupted Lembert suture of the serous surfaces is carried around the anterior aspect of the opening—thus completing the union. (2) The process of union may be mechanically aided by using Senn's rubber band as a temporary ring within the segment of intestine to be implanted—where it is held for a time by gut sutures—and is afterward liberated and passed down the canal.

ENTERO-ENTEROSTOMY BY THE CZERNY-LEMBERT INTERRUPTED SUTURE.

Description.—The edges of the mucous coat are brought together by the interrupted Czerny suture, which passes through this coat alone—followed by the ordinary interrupted Lembert suture through the serous, muscular, and part of the submucous coats. The method of application is the same as that described under "Enterorrhaphy by the Czerny-Lembert interrupted suture" (page 666).

Preparation—Position—Landmarks—Incision.—As for median abdominal section.

End-to-end Approximation —(1) The ends of the intestines are held in convenient apposition—as described in the same operation by the last method. The suture consists of silk or gut, carried upon a curved needle held in a needle-holder. The manner of manipulating is described under Enterorrhaphy by this method. The sutures are interrupted and are introduced and knotted from within, in the Czerny fashion. When the circular enterorrhaphy is almost completed, the last suture or two are somewhat more difficult to place, owing to the tendency of the knot to remain upon the outer aspect—which may be allowed, as this tier will be subsequently buried in—or, better, may be invaginated within the lumen of the gut by a probe. (See Fig. 384, B.) (2) Having completed the first or mucous tier of sutures, the second or outer tier of interrupted Lemberts is carried through the serous, muscular, and part of the submucous coats—and consists of silk or gut carried upon a straight needle held in the fingers—and is introduced in every respect as the interrupted Lemberts are introduced in the method just described. (See Fig. 384, A.)

Lateral Approximation—Lateral Anastomosis—End-in-side Implantation.—The methods of holding the segments of intestines in contact and the general principles of completing the entero-enterostomy are the same as in the

corresponding operations by the overhand continuous suture of all the coats, followed by the interrupted or continuous Lembert suturing of the outer coats

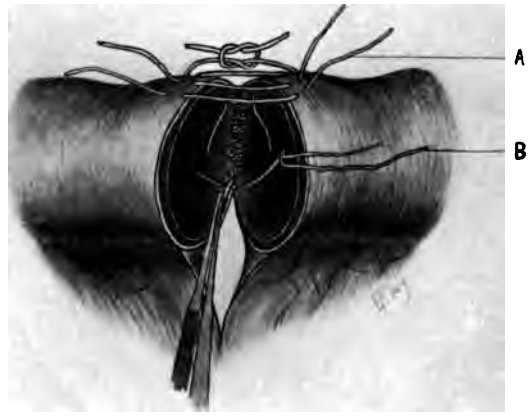

Fig. 384.—ENTERO-ENTEROSTOMY BY THE CZERNY-LEMBERT INTERRUPTED SUTURE:—B, Czerny interrupted suture passing through mucous and part of submucous coats—applied from within; A, Lembert interrupted suture passing through serous, muscular, and part of submucous coats—applied from without.

—with the exception that the first tier of suturing, in the present method, is of the mucous coat alone, and the second tier of the outer coats.

Note.—The Czerny suture should include some of the submucous coat, to hold well.

ENTERO-ENTEROSTOMY BY HALSTED'S METHOD OF INTERRUPTED MATTRESS SUTURES.

Description.—The opposite intestinal walls are brought and held in contact by a single tier of the characteristic Halsted mattress or quilt interrupted suture, passing through the serous, muscular, and part of the submucous coats. The general method of application of this form of suturing to circular enterorrhaphy is identical with the method described under "Enterorrhaphy by Halsted's interrupted mattress suture" (page 667). In the end-to-end approximation, six "presection sutures" are used additionally.

Preparation—Position—Landmarks—Incision.—As for median abdominal section.

End-to-end Approximation.—The details of the application of the Halsted sutures in performing entero-enterostomy without artificial aids are precisely the same as employed in the Halsted operation of entero-enterostomy by means of an inflatable rubber cylinder (page 710). The technic of the operation, therefore, will be found under the latter head—and may be used here, omitting the use of the cylinder, and accomplishing the junction of the segments of intestine by end-to-end approximation by means of simple suturing. The ends of intestine to be approximated are, in this case, simply held in convenient contact by an assistant the steps are otherwise the same as in the more elaborate operation.

Lateral Approximation.—(1) Having excised the required portion of intestine, the free ends of both pieces of gut are closed by a single row of the Hal-

sted interrupted mattress sutures, introduced in the Halsted manner (see Fig. 385). (2) The antimesenteric aspects of the two pieces of intestine are then held in contact at about 5 cm. (2 inches) from their free ends. A posterior row of interrupted Halsted sutures is now placed along the line which is to form the posterior boundary of the intestinal junction, generally being about eight in number. At either end of this line two additional sutures are placed, coming slightly more forward, in continuation of the posterior longitudinal line in a forward curve. All of these sutures are first placed before any are tied—and then all are tied before placing the final ones. (See Fig. 385.) The anterior row of interrupted sutures is now similarly placed before any are tied—and so planned as to form an elliptical figure surrounded by sutures. (3) The sutures forming the anterior row are now drawn apart in the center (without drawing any of them entirely out), and a longitudinal opening is made in each gut, midway between the two lines of sutures and not extending quite to the ends (so as to be

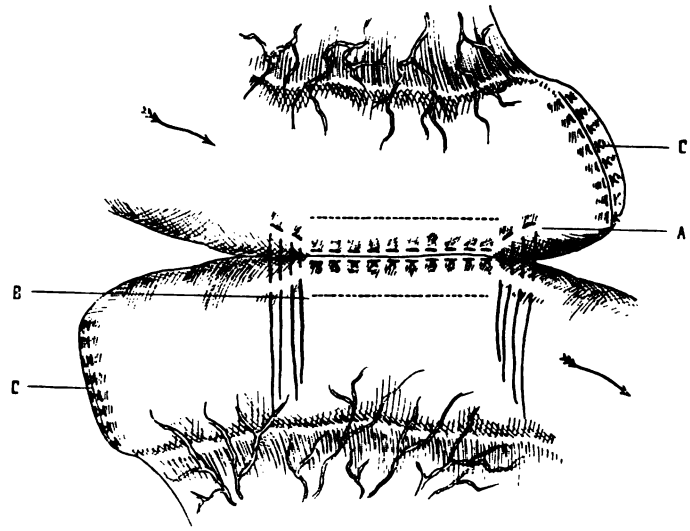

Fig. 385.—Lateral Intestinal Approximation by Halsted's Quilt Sutures:—A, Showing posterior line of sutures, and end sutures beginning to outline an ellipse; B, Line of future incision into intestine, corresponding to similar line on opposite intestine; C, C, Ends of intestines closed by same kind of sutures. (Modified from Halsted.)

well included within the enveloping line of sutures). (See Fig. 386.) (4) The sutures forming the anterior line are now knotted—thus completely apposing the site of union and enclosing the common opening between proximal and distal segments. (5) The edges of the mesentery are treated as indicated.

Lateral Anastomosis.—The operation is here performed in every respect exactly as in Lateral Approximation, except that no excision of intestinal tract is done—and, consequently, no invagination of free ends of intestine is required. Two convenient antimesenteric aspects of intestine are brought together and the union made at once by the method of suturing just described.

End-in-side Implantation.—If this somewhat unusual operation be called for, it is accomplished in the following manner;—the free end of the bowel to be implanted is brought into contact with the antimesenteric aspect of the portion of bowel to receive the implantation (the free end of which has been closed as

in Lateral Approximation)—while held in this relation, the interrupted Halsted sutures are placed, passing from just beyond the edge of the opening in the latter piece of bowel, to just beyond the free edge of the former piece, and back to the latter piece—thus drawing, by means of the loop, the inverted edge of the



Fig. 386.—Lateral Intestinal Approximation by Halsted's Interrupted Quilt Sutures: —Showing all the posterior and half the end sutures tied—and the anterior sutures in position to be tied. The two corresponding intestinal incisions are seen. (Modified from Halsted.)

free end of the bowel above, down upon the inverted edge forming the incised opening in the bowel below—approximating serous surfaces entirely around the opening by the tying of the knots.

ENTERO-ENTEROSTOMY BY MAUNSELL'S INVAGINATION METHOD.

Description.—In intestinal joinings made by this special method of simple suturing a temporary window is cut in the intestinal tract, near one of the two sites to be united (always in the larger piece of gut)—and through this opening the two ends of intestine are temporarily invaginated by means of traction-sutures. The free edges of gut, brought concentrically through the window, are now united by interrupted sutures—after which they are drawn back into their normal position and the window is closed by suturing—thus completing the operation.

Preparation—Position—Landmarks—Incision.—As for median abdominal section.

End-to-end Approximation.—(1) Having brought the coil of intestine into the field of operation, excise the indicated portion, together with the corresponding V-shaped part of the mesentery—and bring together the edges of the mesentery with gut sutures. (2) Two horsehair sutures (or silk) are now introduced, which are temporarily left long and serve, primarily, as traction-sutures—after which they are cut short and serve as two of the permanent

sutures. The first is placed at the antimesenteric aspect—the needle being made to penetrate all the coats of the proximal intestine, near its free border, from within outward—then all the coats of the distal segment of gut at a corresponding point, but now from without inward. (See Fig. 387.) This suture is then knotted upon the inner side, one thread being cut short, the other left temporarily long as a traction-suture. The second suture, somewhat more complicated, is placed at the mesenteric aspect—beginning with that segment of gut of larger calibre (which becomes the intussuscipiens), the needle passes from within the lumen of intestine outward, penetrating the intestine near its free border and entering the triangular space where the two laminæ of the mesentery separate to embrace the barrel of the intestine—then going through the corresponding lamina of that side of the intestine, is carried across to the opposite segment of gut (which is to become the intussusceptum), there penetrating, from without inward, the lamina of the mesentery of the same side—and, passing onward, pierces the corresponding wall of intestine, emerging upon its inner aspect—crosses thence to the opposite side of the same segment of gut—pierces its wall from within outward, passing through the correspond-

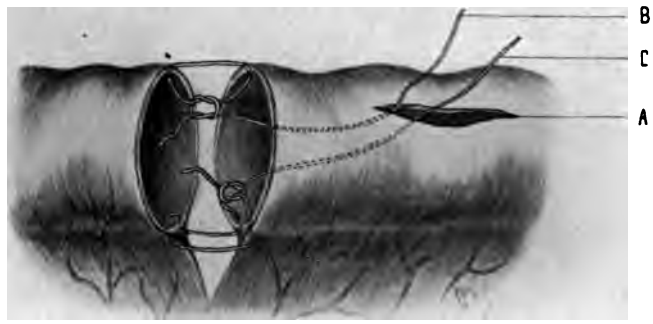

Fig. 387.—ENTERO-ENTEROSTOMY BY MAUNSELL'S INVAGINATION METHOD—PREPARATORY TO INVAGINATION:—A, Window in antimesenteric aspect of intussuscipiens; B, Manner of placing the antimesenteric traction-suture; C, Manner of placing the mesenteric traction-suture.

ing lamina of mesentery of that side—thence across to the opposite segment of gut—where it pierces, from without inward, the lamina of the mesentery of the same side—passing thence onward and emerging in the lumen of that segment of gut at which the suture was started. This important suture is now drawn tight, thus approximating, by the peculiar manner of its passage, the laminæ of the mesentery closely to the barrel of the two segments of intestine at their most unprotected sites. Its knot having been tied on the inner side, one thread is cut short and one left temporarily long as a traction-suture. (3) A temporary window is now made in the segment of intestine of larger calibre, independently of its being proximal or distal. If both pieces are of the same size, the window is generally made in the proximal portion. The opening is made upon the antimesenteric aspect of the intestine, in the form of a longitudinal slit of about 4 cm. (1½ inches) in length, beginning about 2.5 cm. (1 inch) from the divided end of the gut and extending in the opposite direction. This slit is often made by pinching up a fold of intestine longitudinally, between the left thumb and index, passing a knife through it and cutting upward—but as this is very uncertain and inaccurate, it is best to have an assistant so hold the

intestine as to separate its walls and then make the slit by a controlled stab-like incision with a sharp, narrow bistoury, increasing its dimensions with the same instrument or with a pair of scissors—or, even better still, carefully catch the antimesenteric aspect of the intestine with two forceps, about 1.3 cm. (½ inch) apart, raising a transverse ridge, which is cut with scissors in the long axis of the bowel, after which one blade of the scissors is introduced and the opening enlarged. (4) A pair of forceps is introduced through the window and grasps first one and then the other of the traction-sutures, drawing them out through the opening. While the intestines are steadied in the left hand, the traction-sutures are drawn upon, until the free end of the segment of gut further from the window is drawn into the lumen of the gut containing the window—the free edge of the latter being turned inward and invaginated by the opposite segment as it enters—the process of invagination continuing until the free ends of both emerge at the window as two concentric

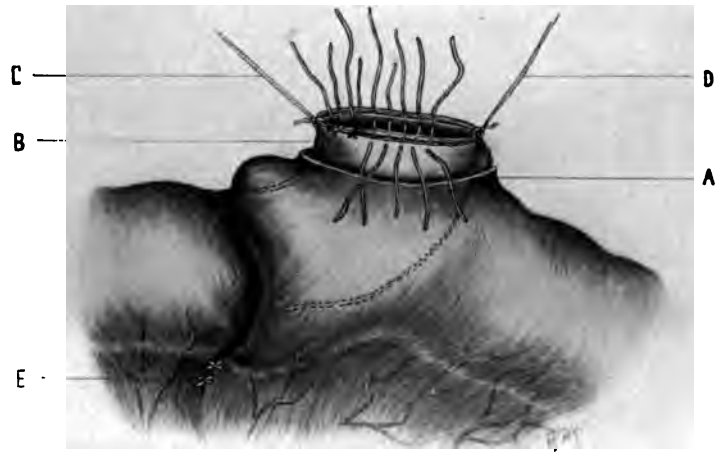

Fig. 388.—ENTERO-ENTEROSTOMY BY MAUNSELL'S INVAGINATION METHOD—THE INVAGINATION ACCOMPLISHED:—A, Window in intussuscipiens; B, Concentric ends of two pieces of intestine of equal size; C, Antimesenteric traction-suture; D, Mesenteric traction-suture; E, Edges of mesentery sutured.

circles, which are drawn sufficiently far out through the window for subsequent manipulations. Both peritoneal surfaces will thus be in contact. (See Fig. 388.) (5) While the ends of the intestines are held upward and away from the opening by the traction-sutures in the hands of an assistant, a long needle threaded with horsehair (or silk) is passed straight across the concentric circles about midway between the two traction sutures, passing through all the coats of the four thicknesses of intestines at about 5 mm. ($\frac{3}{16}$ inch) from the free borders. After the passage of the needle, leaving a long piece of suture at either side, the suture is caught with forceps at the center of the opening of the concentric guts and drawn upward and outward a short distance and cut. Each suture is then tied over the free borders of the two thicknesses of gut embraced by it. Thus about twenty (or more if needed) sutures are placed at equidistant sites by the passage of ten lengths of horsehair (or silk)—and are tied and cut. The two long ends of the traction sutures are now cut short.

(If they have been placed at inconvenient sites, in relation with the other sutures, they may be cut out and removed.) (6) By gentle traction in the reverse direction the invagination is reduced—the intestines now forming one continuous length. (7) The window is then closed by continuous (or interrupted) Lembert sutures (see Fig. 389), thus completing the operation.

Comment —(1) The above method is an imitation of nature's successful manner of performing enterorrhaphy, namely, by invagination and sloughing. (2) Maunsell used horsehair—others have used silk and silkworm-gut. (3) By suturing the edges of the excised mesentery before rather than after uniting the intestines there is less danger of further separating the laminæ of the mesentery. (4) At the end of the operation the serous surfaces should be in contact —and all of the knots at the end of the intestines should be within the gut. In thin-walled guts there is a tendency for the knots and threads not to be so well buried as in the thicker walls. (5) The sutures may be passed through the walls of the concentric guts in the ordinary manner and tied one by one, instead of in the above manner. (6) The sutures should not be tied too tightly.

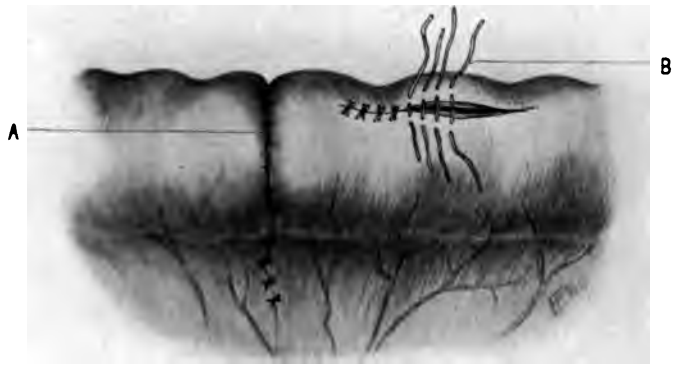

Fig. 389.—ENTERO-ENTEROSTOMY BY MAUNSELL'S INVAGINATION METHOD—THE INVAGINATION REDUCED:—A, External view of suture-line; B, Closing the window with interrupted Lemberts.

(7) This is an instance of using a single layer of through-and-through sutures in intestinal work—but practical experience has proved the method a good one. To avoid the possibility of drainage-infection of the peritoneum by the sutures which pass through all the coats, some surgeons place additional interrupted Lembert sutures outside of the regular row. Fine gut may be thus used.

Where Segments of Intestines of Unequal Size are to be United End-to-end.—(1) The traction-suture through the mesenteric borders is introduced in the above manner. A second traction-suture is introduced in precisely the same manner as the antimesenteric traction-suture above, but so placed as to pass through the edge of the upper part of the smaller gut and through the edge of the larger gut on its side, at a distance from its mesenteric attachment about equal to the diameter of the smaller gut. A third traction-suture is passed through the antimesenteric border of the larger gut alone (see Fig. 390). (2) The window is now made in the larger gut—and the invagination accomplished as in the above case. The two free ends of the gut will not now be concentric, as in the above instance, owing to the difference in size and to the fact

that the circumference of the smaller gut is fixed to the circumference of the larger in two places by suture. (3) The suturing of the borders of these two non-concentric circles can be best accomplished by the passage of a needle through only the two walls in contact at a time—instead, of simultaneously through these two and the opposite two, as in suturing coils of similar calibre. Each suture is at once tied. The first and second traction-sutures become permanent—the third (through the larger gut alone) is removed. It is well to put the sutures in alternately on the two sides, proceeding from the mesenteric toward the antimesenteric border, until the edges of the small intestine have been sutured to those of the larger. When near the antimesenteric aspect of the smaller gut, the redundancy of the larger gut will be apparent. This redundancy, if at all marked, is best disposed of by cutting, with scissors, a V-shaped piece out of the antimesenteric aspect of the larger gut, of a size calculated for the individual case. This V is now carefully sutured by approximation of its margins by an overhand stitch, from its apex toward the antimesenteric aspect

Fig. 390.—ENTERO-ENTEROSTOMY BY MAUNSELL'S INVAGINATION METHOD IN INTESTINAL COILS OF UNEQUAL SIZE—PREPARATORY TO INVAGINATION:—A, Window in intussuscipiens; B, Mesenteric traction-suture; C, Traction-suture which is antimesenteric for the smaller and lateral for the larger gut; D, Traction-suture which is antimesenteric for the larger gut.

of the smaller gut, being especially careful to approximate the edges of the larger intestine, at the base of the V, with the edges of the antimesenteric border of the smaller gut. (See Fig. 391.) (4) The invagination is reduced by gently drawing upon the intestines—and the window is closed as in the regular operation. While an elbow, marking the excess of the larger over the smaller intestine, will be present, the union will be secure. (See Fig. 392.)

Lateral Approximation.—(1) Excision of the intestine and corresponding mesentery is done, the clamps having been placed especially well away from the site of operation. (2) The two ends of intestine are overlapped upon their free, antimesenteric borders, and a continuous Lembert suture (leaving the end of beginning long, after knotting) is run along what will be the posterior aspect of the junction, extending at either end slightly beyond the line of future union around the common opening—and left long and threaded. (See Fig. 393.) (3) Two corresponding incisions in the long axis of both guts are made. (4) The posterior edges of the wounds are sutured together by an overhand, continuous suture of all the coats, leaving the end of beginning long, after knotting,

and also the end of ending long and threaded. (5) Forceps are protruded through the opening and out either free end of the intestine, catching up the

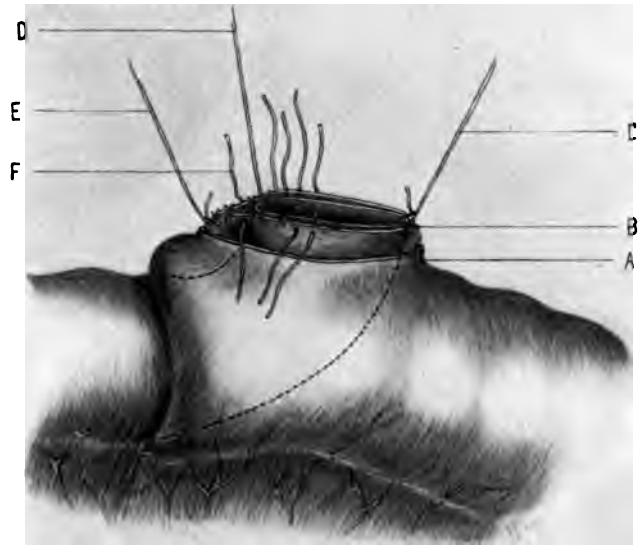

Fig. 391.—ENTERO-ENTEROSTOMY BY MAUNSELL'S INVAGINATION METHOD IN INTESTINAL COILS OF UNEQUAL SIZE—THE INVAGINATION ACCOMPLISHED:—A, Window in intussuscipiens; B, Non-concentric ends of two pieces of intestine of unequal size; C, Mesenteric traction-suture; D, Traction-suture which is antimesenteric for the small and lateral for the large gut; E, Traction-suture which is antimesenteric for the large gut; F, One of the sutures uniting the opposite edges of the redundant portion of the large gut.

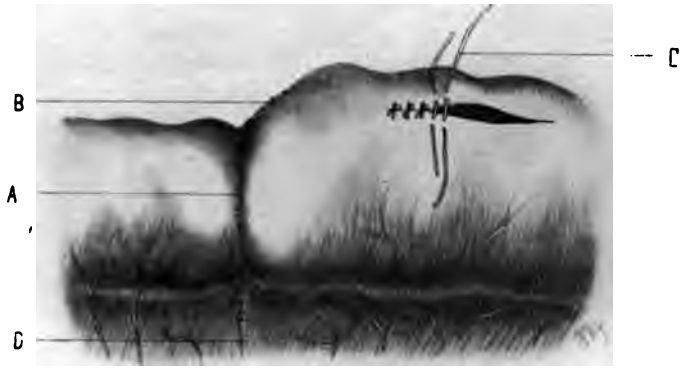

Fig. 392.—ENTERO-ENTEROSTOMY BY MAUNSELL'S INVAGINATION METHOD IN INTESTINAL COILS OF UNEQUAL SIZE—THE INVAGINATION REDUCED:—A, External view of portion of suture-line representing the end of the small intestine; B, External view of portion of suture-line represented by the redundancy of the large intestine; C, Closing the window with interrupted Lembeits; D, Interrupted sutures approximating the edges of the cut mesentery.

free end in their grasp and drawing (invaginating) it into the lumen and through the opening. A circular silk ligature is then tied around either free

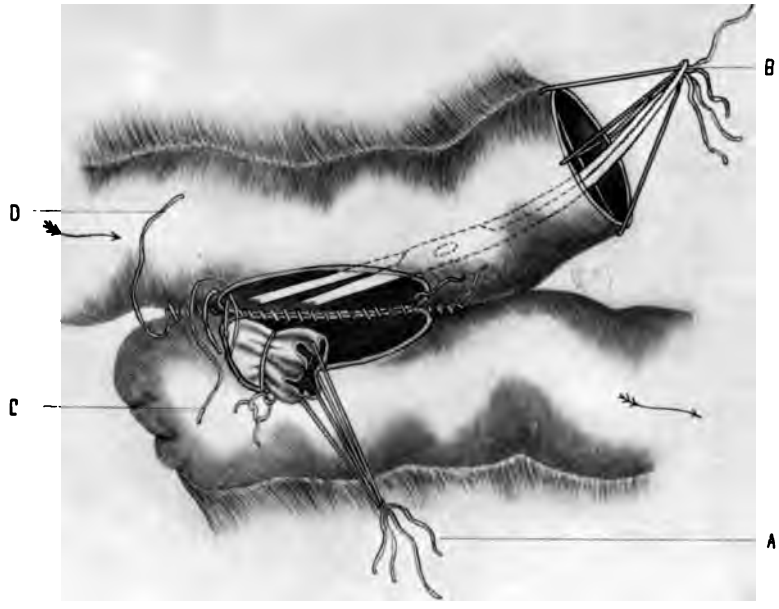

Fig. 393.—Lateral Intestinal Approximation by Maunsell's Invagination Method:—A, End of intestine invaginated through window and circular ligature placed around it; B, Traction-ligatures grasped by forceps in act of invaginating opposite end of intestine; C, Continuous overhand suture of all coats; D, Continuous Lembert suture of outer coats.

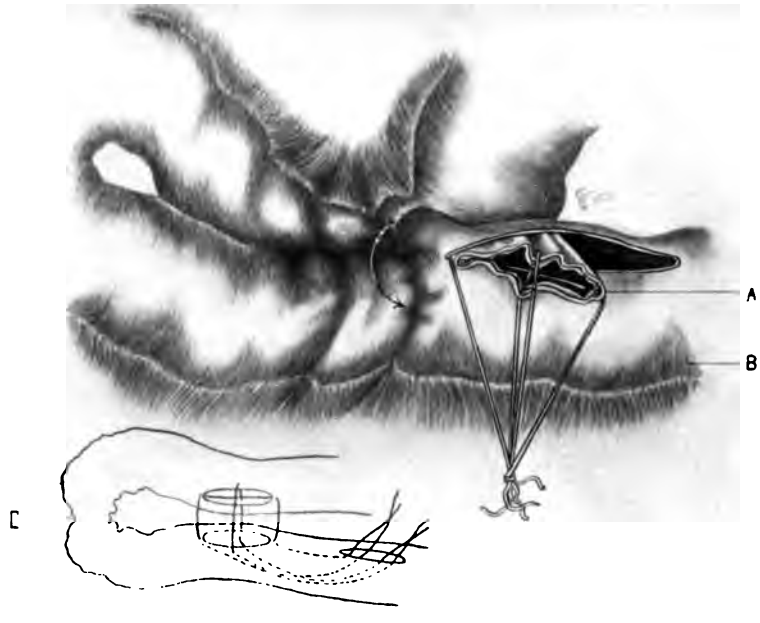

Figs. 394 and 395.—Lateral Intestinal Anastomosis by Maunsell's Invagination Method:—A, Intussusceptum drawn through window; B, Intussuscipiens, with window in its antimesenteric aspect; C, Diagram showing manner of placing traction-sutures.

end and they are dropped into their respective lumina. (6) The needle attached to one end of the "whipping over" suture then continues the process until the corresponding edges of the entire circumference are brought together and the long ends tied. (7) Then the needle upon the serous suture is taken up and the continuous Lemberts through the serous and muscular coats are continued around the anterior aspect of the wound, burying in the first layer. The edges of the mesentery are sutured as indicated.

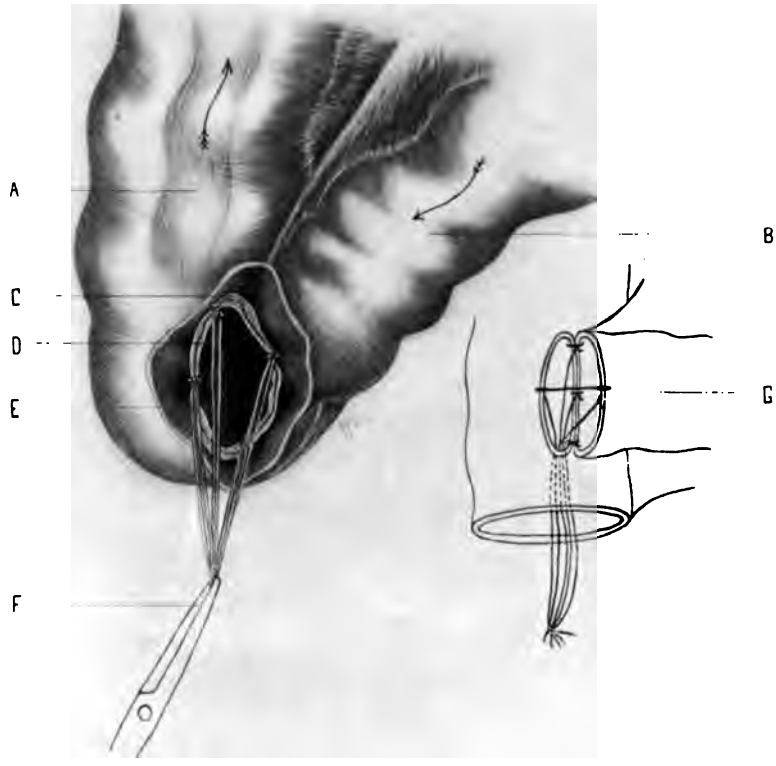

Figs. 396 and 397.—End-in-side Intestinal Implantation by Maunsell's Invagination Method:—A, Colon; B, Ileum; C, Free edge of lateral window in colon; D, Free edge of end of ileum; E, Free, open end of colon; F, Traction-sutures invaginating free end of ileum and lateral opening of colon through open end of colon; G, Diagram showing manner of placing traction-sutures.

Comment.—The circularly ligated ends of intestine may be reinforced with interrupted or continuous Lemberts.

Lateral Anastomosis.—Two knuckles of intestine are apposed along their antimesenteric borders—two corresponding axial incisions are made—a window is then cut about 2.5 cm. (1 inch) above—four traction-sutures are applied to the cut margins and knotted within—a pair of forceps, passed through the window, catches the four traction-sutures and draws them back through the opening—by means of these traction-sutures the lateral aspects of the two pieces of intestine are invaginated through the window—sutures are applied to their margins, as in the end-to-end approximation—the invagination

is reduced—and the window closed by interrupted or continuous Lembert sutures. The line of anastomosis may be reinforced by Lemberts, if considered necessary. (See Figs. 394 and 395.)

End-in-side Implantation.—Excise the portion of intestine, with the corresponding part of mesentery—bring the free end of the smaller gut to the antimesenteric aspect of the larger gut, near its end—about 2.5 cm. (1 inch) from the free margin of the latter, upon its antimesenteric aspect, make an axial incision, corresponding in length to the diameter of the free end to be implanted—place four traction-sutures, knotting them within—draw these traction-sutures out through the free end of the gut in which the lateral opening was made, by means of forceps—suture together the margins of the free end and the lateral opening of the larger gut, as in end-to-end approximation—reduce the invagination—close the free end of the gut with the lateral opening first by continuous, overhand silk sutures, which are then buried by interrupted gut sutures of the Lembert type—thus completing the operation. The edges of the mesentery are so sutured as to close all openings. The site of implantation may be reinforced by Lembert suturing, if considered necessary. (See Figs. 396 and 397.)

Note.—In all the operations by the Maunsell method, the traction-sutures may be dispensed with—the invagination being accomplished by forceps introduced through the windows, as in Ullmann's modification of Maunsell's operation (page 699).

(B) ENTERO-ENTEROSTOMY BY MEANS OF ABSORBALE MECHANICAL DEVICES LEFT WITHIN THE INTESTINE.

IN GENERAL.

Description.—(1) The mechanical devices, which are made of some absorbable material and are inserted into the intestinal tract to serve as distending frameworks over which the suturing may be conveniently applied, are bobbins, buttons, cylinders, plates, etc. They are left within the lumen of the intestinal tract, either to be entirely absorbed, or to be partially absorbed and the residue passed by nature. While possessing, in common with non-absorbable devices, the property of aiding in the approximation of the parts, they possess the additional advantage of becoming absorbed after having accomplished their purpose—with the concomitant disadvantage of possibly sometimes becoming absorbed before having done their work completely. (2) The bobbins are in the form of two cones united at their apices, which is their smallest part. Their shape has a greater tendency to approximate the intestinal surfaces than has the button, or reel. The buttons are very much like ordinary buttons, or possibly more like reels. The size of the barrel is everywhere equal between the flanges. Various forms of plates are used, of which the best known are probably Senn's bone-plates. Some forms of cylinders are used. The terms designating these devices are sometimes used interchangeably. (3) These devices are made of various materials—the most usual being decalcified bone, or some form of vegetable (such as potato, carrot, turnip, etc.). In some, the bulk of the device is made of entirely absorbable material, and a small part of the center, where the pressure is to be borne, is made of more imperfectly absorbable or of non-absorbable material. (4) These devices are always used in connection with some form of suturing—never alone. (5) As to their range of applicability—their chief field of usefulness is in end-to-end approximation—

and only to a limited extent in lateral approximation, lateral anastomosis, end-in-side implantation, gastro-enterostomy, and cholecystenterostomy. Some are used only in lateral methods of entero-enterostomy (as the Senn bone-plates).

ENTERO-ENTEROSTOMY BY MEANS OF ABSORBABLE BOBBINS.

Description.—The Allingham partially decalcified bone bobbin will be taken as representing this type—the steps of the operations being the same whether the bobbin be of this or vegetable material. In Allingham's bobbin the bone is decalcified to within 3 mm. ($\frac{3}{16}$ inch) of its very center, which is left firm to resist pressure made by the suture. The two portions of the intestinal tract are approximated over the center of the bobbin by running sutures inserted, in purse-string fashion, in the free end of each piece of intestine.

Preparation—Position—Landmarks—Incision.—As for median abdominal section.

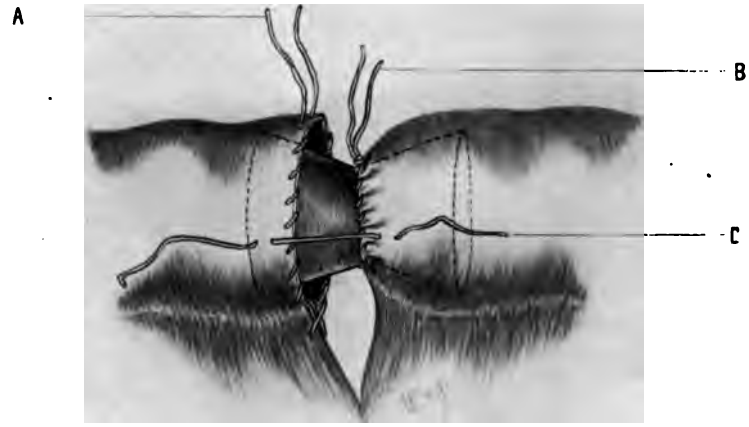

Fig. 398.—End-to-end Intestinal Approximation by an Absorbable Bobbin:—Position of bobbin is shown partly in outline; A, Purse-string suture in position ready to be tightened; B, Purse-string suture tightened and tied; C, Interrupted Lembert suture in position to be tied.

End-to-end Approximation.—(1) Having completed the steps of a preliminary enterectomy, place a running, overhand purse-string suture of silk in the ends of each piece of intestine, passing through all their coats, the thread entering and coming out at the antimesenteric borders—leaving both free ends long. (See Fig. 398.) While less simple, a more satisfactory form of purse-string suture (owing to the manner in which it approximates the laminæ of the mesentery) is the one used in connection with the operation of entero-enterostomy by means of the Murphy button (page 703)—and this suture is equally applicable here. (2) Insert one end of the bobbin into the proximal, or distal, end of the intestine—and, having made the double turn of the friction-knot, draw the purse-string rather tightly down upon the intestine over the center of the bobbin—but do not tie the final knot. Insert the opposite end of the bobbin into the end of the opposite piece of

intestine and similarly tie it. (3) When both segments of intestine are moulded well into position, so that the serous surfaces are well approximated, each suture is tightened with moderate firmness and the final knot in each tied—thus securely bringing and fastening the ends of the intestines at the center of the bobbin, and holding in contact rather extensive serous surfaces for union. (4) The serous surfaces may be scarified with a needle for about 1 cm. ($\frac{3}{8}$ inch) around the line of suture, to cause exudation of lymph and firmer union. (5) A few interrupted Lemberts of fine gut may be applied around the line of union, further approximating the serous surfaces, if thought necessary. (6) The mesentery is treated as in other operations of entero-enterostomy.

Comment.—While especially applicable to end-to-end approximation, the method may also be used for lateral approximation, lateral anastomosis and end-in-side implantation—applying the same general principles mentioned in the preceding descriptions of those operations. As the junction in the last three operations mentioned is not so perfect as in end-to-end approximation, additional Lembert sutures should always be used to reinforce the line of union.

ENTERO-ENTEROSTOMY BY MEANS OF ABSORBABLE BUTTONS.

Description.—The Landerer potato button will be taken as representative of this type of mechanical device. A purse-string suture is inserted into each end of the intestinal opening—these are tightened over the barrel of the button, or reel, thus relatively approximating the ends of the intestine.

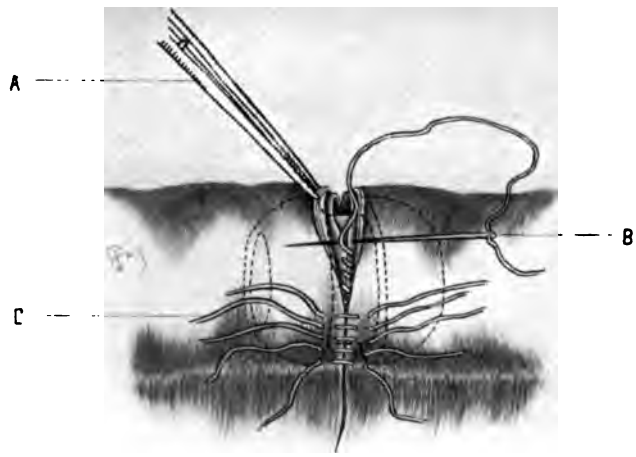

Fig. 399.—End-to-end Intestinal Approximation by an Absorbable Button:—Position of button is shown in outline; A, Forceps everting lips of intestine to aid suturing; B, Continuous suture of mucous coat; C, Interrupted Lembert sutures of serous and muscular coats.

But as the barrel of the button or reel is of the same dimension for some distance, there is not the same tendency for the approximated ends of the intestine to be held in close contact as is the case in the bobbin, where there is the narrowest part of the barrel at the center, into which the segments

may be readily tied. An overlying line of interrupted or continuous Lembert sutures is, therefore, placed over the ends approximated by the purse-strings—and thus securely apposes serous surfaces.

Preparation—Position—Landmarks—Incision.—As for median abdominal section.

End-to-end Approximation.—(1) Having completed the steps of a preliminary enterectomy, a purse-string suture of silk or of chromic gut is inserted into the end of each piece of intestine—in the same manner, preferably, as in Murphy's button-operation (page 703). (2) Each end of the intestine is drawn over the flange of the button on to the barrel—the purse-string is then moderately tightened and cut short, thus bringing the two ends of the intestine into contact. (The narrower the barrel of the button, the closer will be the contact at this stage.) (3) The circumferential margins of the intestines are united with a line of interrupted or continuous Lembert sutures of the serous and muscular coats. (4) The mesentery is repaired as in other operations of entero-enterostomy.

Comment.—The comment made under "Entero-enterostomy by means of Absorbable Bobbins" is equally applicable here. Union may also be accomplished by an inner tier of continuous suture of the mucous coat, and an outer interrupted tier of Lemberts through serous and muscular coats. (See Fig. 399.)

ENTERO-ENTEROSTOMY BY MEANS OF ULLMANN'S MODIFICATION OF MAUNSELL'S OPERATION.

Description.—Up to the application of the Ullmann modification, which is applied after the invagination of the ends of the intestines through the window in one of the pieces of gut, the steps of the operation are identical with those described under the Maunsell method (page 688). The two ends of intestine having been brought through the window, a carrot (or other vegetable, or decalcified bone) bobbin is inserted within their concentric lumina, so that its groove is grasped by their walls, which are then tied over the groove in a circular manner, with gut or silk. The invagination is then reduced—and the longitudinal wound, forming the window, closed.

Preparation—Position—Landmarks—Incision.—As for median abdominal section.

End-to-end Approximation.—(1) The operation, up to the point of invagination, is precisely the same as in Maunsell's operation (page 688). (2) The invagination is now accomplished by passing two catch-forceps through the window—one catching the mesenteric and the other the antimesenteric aspects of the end of the proximal gut (the gut in which the window usually is)—and draws these out simultaneously through the window. The mesenteric and antimesenteric aspects of the edges of the distal gut are similarly caught by two catch-forceps introduced through the window—which are also drawn out simultaneously through the opening. These last two forceps are removed from the distal gut and made to grasp the edges of both guts at their sides. The first two are then also removed from the first gut and made to grasp the edges of both guts at the same site each was grasped by a single forceps. Thus the concentric ends of the two intestines are readily held open by the four pairs of forceps equidistantly placed. These forceps are given to an assistant, who holds them with one hand, while holding the bobbin with the other. (See Fig. 400.) (3) The bobbin is now introduced into the concentric openings of the intestines—the walls of the two guts are

then tied down into the groove of the bobbin with thick catgut or silk (which will not likely cut through). (4) The forceps are relaxed—the invaginated intestines are reduced—the window is closed by interrupted or continuous

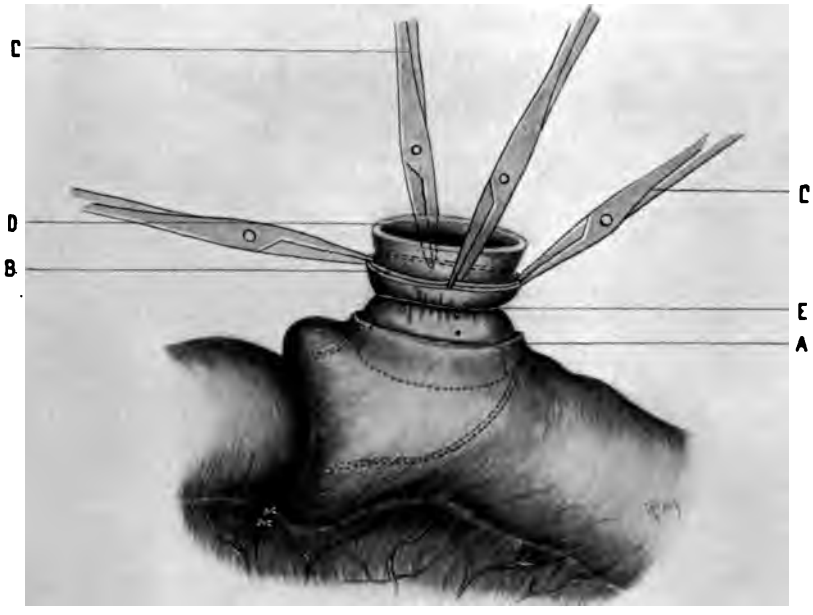

Fig. 400.—ENTERO-ENTEROSTOMY BY ULLMANN'S MODIFICATION OF MAUNSELL'S INVAGINATION METHOD:—A, Window in intussuscipiens; B, Concentric ends of intestines drawn through window; C, C, Traction-forceps drawing ends of intestines through window; D, Absorbable bobbin within concentric ends of intestines; E, Ligature binding ends of both pieces of intestine to groove of bobbin.

Fig. 401.—ENTERO-ENTEROSTOMY BY ULLMANN'S MODIFICATION OF MAUNSELL'S INVAGINATION METHOD:—Showing the reduction of the invagination and closure of the window—bobbin and ends of intestine being shown in outline.

Lembert sutures—the mesentery is repaired—and the operation concluded. (See Fig. 401.)

Comment.—Although more applicable to end-to-end approximation, the

Ullmann modification of the Maunsell method may be applied to lateral approximation, lateral anastomosis, and end-in-side implantation.

ENTERO-ENTEROSTOMY BY COFFEY'S METHOD.

Description.—The free ends of intestine, after having been first united at their mesenteric aspects by two or three Connell sutures, are drawn over a vegetable tube (made of potato, carrot or turnip, preferably the first) and made to meet and overlap at its center by means of two long needles passed through tube and intestines transversely, at right angles to each other—after which any form of suture desired is applied—the pins then withdrawn—and the potato-tube pushed on down and crushed.

Preparation—Position—Landmarks—Incision.—As for median abdominal section.

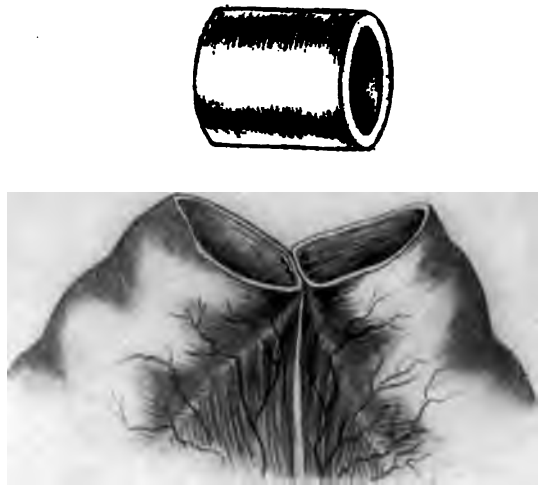

Fig. 402.—END-TO-END ENTERO-ENTEROSTOMY BY COFFEY'S METHOD:—I. Ends of intestine brought together and their mesenteric aspect united by three Connell sutures—preparatory to inserting hollow potato-tube shown above. (Modified from Coffey.)

Operation.—(1) Having completed, one may suppose, the steps of an excision of a portion of the intestines, the free ends are brought into contact and, while thus held by an assistant, three Connell sutures placed at the mesenteric aspect, the central one embracing both laminæ of the mesentery of both ends of the intestine—each suture passing from within the lumen of one end outward through its own wall, and from without inward through the corresponding site of the opposite end—then from within outward from the lumen of the opposite end, and from without inward through the corresponding site of the original end, back into the lumen of the original end—where the free ends of the suture are tied within the first piece of intestine. (Fig. 402.) (2) One end of the united pieces of intestine is then drawn over the potato-tube up to the center of the tube—and is held there until the opposite end of the intestine is similarly drawn over the opposite end

of the tube to meet it, and also held in position. (3) Two long needles (or hat-pins, knitting-needles, probes, or toothpicks) are now passed transversely through the potato-tube and through the ends of the intestine, at right angles to each other—one entering near the mesenteric, and one at the mid-lateral aspect. As these needles enter and emerge, they are made to pierce the overlapped edges of intestine—and thus hold them in four places—overlapped where the needles penetrate, and overlapped or in comparatively close contact throughout the rest of the quadrants (Fig. 403). (4) While the ends of intestine are thus held, any form of suture desired may be placed—interrupted Lemberts—continuous Lembert—the Halsted quilt suture—or a double line of sutures. (5) Having completed the suturing, the pins are

Fig. 403.—End-to-end Entero-enterostomy by Coffey's Method:—II, Two ends of intestine drawn over tube and held in relation with each other by long needles thrust through the potato-tube at right angles to each other and piercing the overlapped edges of intestine. While thus held interrupted Lembert (or other) sutures are applied—after which, needles are withdrawn—and potato-tube may be crushed. (Modified from Coffey.)

withdrawn. In the case of interrupted sutures, those stitches which were placed while the needles were *in situ* can now be more satisfactorily drawn together after the removal of the needles. The potato-tube is carefully pressed away from the site of operation, distally to it—and is then crushed into comparatively small pieces. (6) The abdomen is closed in the usual manner.

(C) ENTERO-ENTEROSTOMY BY MEANS OF NON-ABSORBABLE MECHANICAL DEVICES LEFT WITHIN THE INTESTINAL CANAL.

IN GENERAL.

Description.—These devices, usually made of metal, serve, as in the case of absorbable devices, as frameworks over which the intestinal joinings are

made—but are left within the intestinal tract to be passed out at the anus by the efforts of nature. The Murphy button may be taken as the most generally used representative of this class.

ENTERO-ENTEROSTOMY BY MEANS OF THE MURPHY BUTTON.

Description.—The junction between the intestinal coils is accomplished by inserting one half of an ingenious button into the free end of each portion of intestine—these half-buttons are held in place by specially applied sutures—and the two halves of the button are then approximated. The opposite surfaces of the two cups of the button, aided by a spring in one of the cups, keep up a constant pressure upon the opposed surfaces of intestine, thus holding their approximated serous surfaces in contact. Union

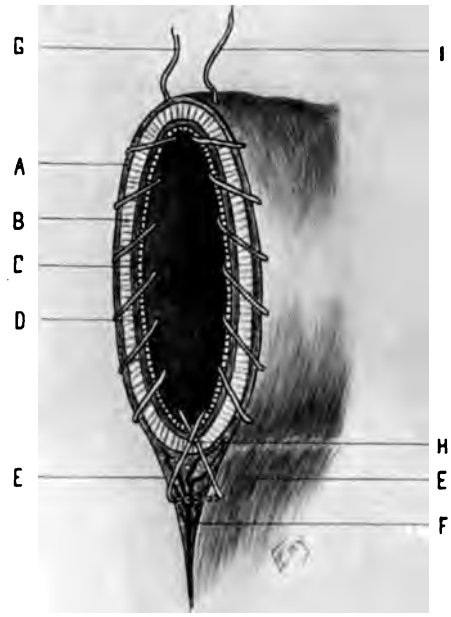

Fig. 404.—Cross-section of Intestine, Showing Manner of Placing the Purse-string Suture:—A, Serosa; B, Muscularis; C, Submucosa; D, Mucosa; E, E, Laminæ of mesentery; F, Mesenteric vessel and connective tissue; G, Beginning of suture; H, Crossing of suture, approximating laminæ to each other and to barrel of intestine; I, End of suture, ready to be knotted with opposite end.

takes place between the surfaces thus held together, especially along their circumferential aspects—while the buttons are freed by pressure-necrosis and are generally passed by bowel.

Preparation—Position—Landmarks—Incision.—As for median abdominal section.

End-to-end Approximation.—(1) Having opened the abdominal cavity, complete the partial enterectomy in the usual manner. (2) Preparatory to the insertion of half of the button into each free end of the gut, a silk suture is applied in a special manner. (See Fig. 404.) A long, straight needle is

threaded upon a piece of silk about 30 cm. (12 inches) long—this suture begins just to the right of the center of the antimesenteric border, entering about 3 mm. ($\frac{1}{8}$ inch) below the free edge, and passing from without directly inward—thence, following the right-hand margin, in an overhand stitch, over (not through) the border of the intestine to the outer side—thence through the wall from without inward—and so on, until the lamina of the mesentery belonging to that side is reached. As the suture passes from within the lumen, over the wall outward for the last time on that side, it also passes obliquely over the lamina of the mesentery of the opposite side. The suture is then carried through both laminæ of the mesentery as a reversed stitch—emerging at the outer aspect of the opposite lamina. It is now obliquely carried over the lamina of the original side (and across the first limb of the suture that was carried over the opposite lamina) into the lumen of the intestine, toward its opposite wall—and passes through this wall of the intestine from within outward. The order is now reversed, and (to get out of the

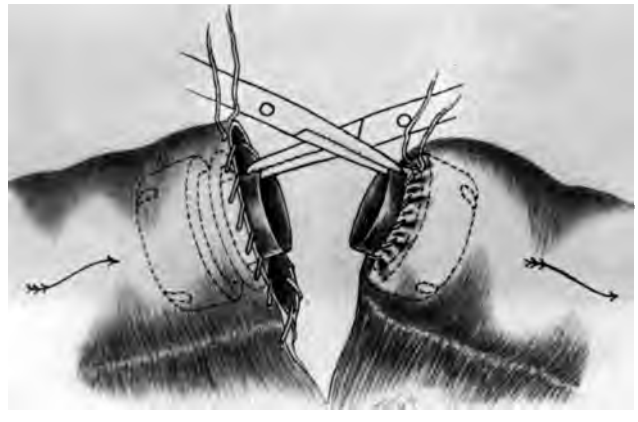

Fig. 405.—END-TO-END INTESTINAL APPROXIMATION BY MURPHY'S BUTTON:—Showing manner of introducing button into lumen of intestine,—male button on left, with purse-string ready to be tightened;—female button on right, with suture tightened.

lumen on the left side) the thread is always carried through the free border of the intestine from within outward—thence passes over (not through) the wall from without inward into the lumen—and so on, until it enters the lumen for the last time, at the antimesenteric border—here, at a distance of about 5 mm. ($\frac{3}{16}$ inch) from its point of entrance, and on the same level, the needle passes through the intestinal wall from within outward. Thus a "puckering" or "draw-string" is formed, so applied that when drawn about the button, it will approximate the leaves of the mesentery closely about the ill protected triangle at its base—and the two threads emerging side by side upon the outer aspect are ready to be tied about the button. Although these sutures pass through all the coats of the intestine, they are within the spring, or pressure-cup, of the button. Similar sutures are inserted into the free ends of the opposite piece of intestine. (See Fig. 405.) (3) Each cup, or button, is now grasped by its stem (not, as so often shown in pictures, by the cup itself) by the tip of a pair of special or pointed forceps (forceps

with rounded or squarish points would tend to bend the perfectly circular opening of the stems). Both are now ready for introduction. (4) The male button (one with smaller stem) is always introduced into the end of the proximal gut (because when its stem has slipped into the stem of the female button, a slight elbow or projection is formed where its free margin ends—which is harmless while in the direction of the intestinal current, but might cause obstruction by particles of solid food lodging against it, if in the opposite direction). This male half of the button is introduced into the proximal gut just far enough for the free end of the gut to come well around the stem. The suture is then drawn moderately tight and tied with a double knot (the first being a friction-knot) around the stem—evenly distributing the puckered gut with a probe as the thread is tightened. An assistant takes the forceps and so holds them that the stem of the button does not slip within the intestine. (5) The female button (one with larger stem) is similarly introduced into the distal end of the gut. The suture is similarly placed and tightened about it—and the forceps given to an assistant to hold in the

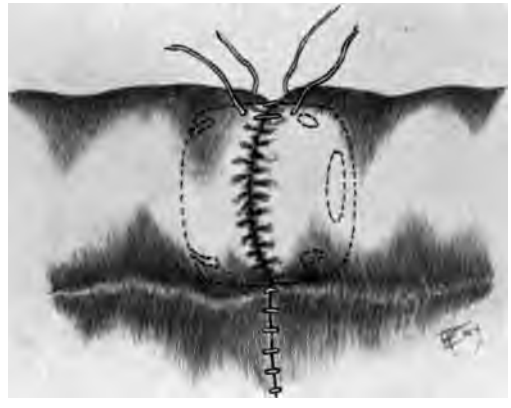

Fig. 406.—END-TO-END INTESTINAL APPROXIMATION BY MURPHY'S BUTTON:—The half-buttons approximated and pressed home. Two loose, interrupted Lembert sutures are shown in the position which a tier of these sutures would occupy, if used.

same manner as with the male button. (6) The assistant holding the buttons, so crosses the handles of the forceps as to present the buttons to the surgeon in their right relation for immediate approximation. (See Fig. 405.) The surgeon now grasps a button in the thumb and first two fingers of each hand, with the hollows of the buttons looking toward each other. The assistant then simultaneously releases the hold of the two forceps upon the stems of each half-button. At the moment of release the surgeon guards the buttons lest they slip out of reach into the intestines (by pressing them against the binding sutures). The surgeon now approximates the two half-buttons, one held in the fingers of each hand—calculating, in their slow and deliberate approximation, that the intervening intestinal walls will be so disposed as to make an even layer over the cups of the buttons—adjusting the deficiency or excess of the puckered intestine with a probe, as indicated—and finally pressing the two halves home as far as his judgment deems necessary to secure good apposition without too great compression. (See Fig. 406.)

(7) The edges of the mesentery are sutured and the intestine dropped back into the abdomen.

Comment.—(1) Segments of intestine of unequal size may be thus united by end-to-end approximation with the Murphy button—care being exercised in tying the button into the end of the larger gut, and especially in the act of approximating the two buttons, to see that the puckered excess of the intestinal tissue, particularly in the case of the larger gut, is evenly distributed around the stem of the buttons—and that when the halves of the buttons are finally pressed home the serous surfaces everywhere come together. (2) A line of interrupted or continuous Lemberts is used by some surgeons to reinforce the margins where the buttons meet, after their apposition. While not generally necessary, such a line of reinforcing sutures may be used where considered indicated. (See Fig. 406.) (3) See that

Fig. 407.—Lateral Intestinal Approximation by the Murphy Button:—The manner of placing the purse-string suture is shown upon the lower intestine,—and the male button introduced, with suture tightened, is seen within the upper intestine.

the purse-string sutures are, after knotting, cut close, and that their ends are not held by the cups of the buttons—thus retarding the escape of the button, and possibly serving as infectors of the peritoneal cavity. (4) All buttons used should be of a size that will not press upon the intestinal walls, else sloughing may occur.

Lateral Approximation.—(1) Having excised the portion of intestine, the free ends of the two pieces of gut are first closed by overhand, continuous suture of all the coats—fellowed by a second tier of interrupted or continuous Lemberts burying in the first row. (2) Purse-string sutures are now placed. (See Fig. 407.) These consist of silk and are carried by an extra long, straight needle (such as Keith's abdominal needle). The site for the insertion of the half-button into each segment of gut having been chosen, which will

be upon the antimesenteric aspect of the guts, beginning about 2.5 or 5 cm. (1 to 2 inches) from their ends, it is necessary to calculate the length of the incision to be made, as its length will regulate the length and position of the purse-string suture. If the oblong button be used, the length of the incision will be a little less than the transverse diameter of the button,—and if the round button, a little less than the diameter—in order that when the button is insinuated through an opening requiring slight distention for its entrance, it will close about it sufficiently to slightly grasp it. The sutures should be put in so that their looped end is toward the free end of the gut. The suturing passes through all the coats. Conceiving an imaginary straight line, running longitudinally, upon the center of the antimesenteric aspect of the bowel to mark the site for the future incision for the reception of the button, the needle is made to enter the wall of the gut about 6 mm. (¼ inch) above (or below, as the case may be) this imaginary line, and about 3 mm. (⅛ inch) to one side—passing through all the coats into the lumen—again passing outward (always traveling in a straight line parallel with and about 3 mm. [⅛ inch] from the imaginary line) and emerging about 6 mm. (¼ inch) from the point of entrance—and so on, until it emerges finally about 6 mm. (¼ inch) beyond the opposite end of the imaginary line—here the loop is formed, the needle crossing over and entering the intestinal wall at a point corresponding with its last emergence, but on the opposite side of the imaginary line—and travels down this side in the reverse direction, but in the same manner as on the opposite side—finally emerging at a point corresponding with the entrance on the original side. Both ends of the suture are left long and the loop loose. (3) An assistant now so holds the bowel (which has been clamped at some distance from the free ends) as to separate its walls—while the surgeon, by a quick, controlled stab of a narrow, sharp bistoury, incises the gut midway between the two parallel lines of the purse-string suture, and makes an opening a little less in length than the diameter of the button to go through it—and especially considerably less in length than the length of the surrounding purse-string. Care is taken that the mucous membrane is not simply pushed ahead of the knife, instead of being cut, and that the lumen is well opened up. (4) The button, grasped by forceps, as in the ordinary end-to-end operation, is now insinuated into the opening, placing the male button in the proximal gut. The purse-string is drawn tightly enough to approximate the walls of the gut to the stem of the button and tied—evenly distributing the puckered intestine around the stem. The forceps holding the button is then given to an assistant, who holds it as in the end-to-end operation. (5) The opposite end of the intestine is similarly treated and the female button inserted. (6) The surgeon, grasping a button in the fingers of each hand, with their stems facing (as they have been directed by the crossing of the forceps), signals to the assistant to release the buttons by relaxing the forceps—and then pushes home the two halves—using the same precautions as in the end-to-end approximation, for the even distribution of the intestinal walls. (See Fig. 408.) (7) The management of the mesentery will here differ from its management in the end-to-end operation, as the continuity of the intestinal canal will not be continued in one straight line. It is better (unless otherwise indicated) not to excise a V-shaped portion of mesentery, but simply to fold over and suture in contact with each other, and with neighboring mesentery, the layers of the redundant fold of mesentery. If a V-shaped portion be excised, the two free borders of the mesentery left should be so sutured down to adjacent mesentery as to leave no openings for hernia.

Comment.—(1) See the general comments under the end-to-end approximation. (2) Care should be used that in approximating the two ends of the intestines the direction of the intestinal flow should be maintained. (3) The button used may be of the oblong type, which is better for this purpose—or of the ordinary round type. (4) The operation of lateral approximation after closure of the ends of the resected gut is but rarely indicated—the usual method of junction following excision being by end-to-end approximation. (5) Instead of using the purse-string suture to hold the button-halves in place, Carle approximates the borders of the intestinal opening by one or two interrupted Lembert sutures placed at either end of the incision, thus lessening its length and grasping the button. But the regular method is probably better.

Lateral Anastomosis.—In this operation the two buttons are inserted



Fig. 408.—Lateral Intestinal Approximation by the Murphy Button:—The two half-buttons are shown approximated. Interrupted or continuous Lembert sutures may reinforce the contiguous surfaces, if considered necessary.

into the antimesenteric aspects of the two indicated coils of intestine—the method of insertion being identical with that used in Lateral Approximation by the button. No excision of intestine takes place. The oblong button is to be preferred. Reinforcing Lemberts may be used. The Carle method of tying in the buttons, just mentioned, may be used.

Lateral Anastomosis with Weir's Modification of Murphy's Button, Introduced by Gallet's Method.—The male half of the original button is so modified, by being sharpened and beveled, that it can be made to penetrate the walls of the intestine. Both buttons are introduced, by means of special forceps, through a common opening in a knuckle of intestine—each being carried down a separate limb of the gut—and are then approximated—followed by the closure of the incision in the knuckle. Following are the steps

of the operation; (1) The sites of the anastomosis must be in such positions upon the antimesenteric aspects of the intestine that, when the length of the intestine is doubled upon itself, the site to be occupied by each button will not be beyond the reach of the special forceps to be introduced through an opening at the knuckle formed by bending the intestine upon itself. (2) An incision in the longitudinal axis of the gut is now made at this knuckle. A button held in the grasp of the special forceps is then introduced through the opening down one limb of the gut—the male button in the proximal limb. The female button, similarly held, is then introduced down the opposite limb. (3) By pressure upon the forceps holding the male button, its stem is made to pierce the walls of its own side and the opposite gut—and is then directed into the stem of the female button. (4) The buttons are then pressed home—the adjacent surfaces of intestine being held in contact without any form of suturing. (5) The treatment of the opening in the knuckle of gut is as indicated. In the cases where the operation is simply a lateral anastomosis, the incision in the knuckle would be closed by interrupted or continuous Lembert sutures of gut or silk. In the majority of cases where this operation is done, however, it is performed in connection with a gastro-jejunostomy, for the purpose of aiding in the prevention of bile and intestinal regurgitation from the duodenum into the stomach—so that as soon as the intestinal anastomosis has been accomplished, the opening in the knuckle of intestine is sutured to a corresponding opening in the anterior wall of the stomach, thus completing the gastro-jejunostomy. (See Fig. 466.)

Note.—The ordinary Murphy button may be used in practically the same manner. After opening the knuckle of gut, one half of the button may be dropped into each limb of the intestine—these are caught and held by the fingers of an assistant at corresponding positions within the two pieces of gut, with the free portion of their stems held against the antimesenteric aspect of the gut. While the intestinal wall is thus drawn tightly over the hollow stems, a limited crucial incision is made in the center of the stems, just sufficiently large for the stems to be pressed through, with the walls of the intestine clinging closely around them—immediately following which the two halves are pressed together, bringing the antimesenteric aspects of the two portions of gut into accurate apposition—no reinforcing suture being necessary. The opening in the knuckle of gut is closed as usual. (See Figs. 467 and 468.)

Multiple Lateral Intestinal Anastomosis (Jaboulay-Braun's Operation).—In addition to the single lateral intestinal anastomosis formed after gastro-enterostomy, as above described (Braun's operation), sometimes a second, or even a third, lateral intestinal anastomosis may be made—for the purpose of further avoiding the likelihood of intestinal regurgitation by furnishing as direct and easy a descent from the stomach to the anus as possible. Supposing, therefore, that a gastro-jejunostomy has been performed, a lateral jejuno-jejunostomy may be done by Gallet's method of using Weir's modification of the Murphy button, at the time the intestine was opened to unite it to the stomach—and then another jejuno-jejunostomy, or a jejuno-ileostomy, could be performed lower down by the ordinary lateral anastomosis method, thus short-circuiting by two routes the contents of the intestines.

Note.—Multiple intestinal anastomosis can, of course, be performed by simple suturing, as well as by other methods.

End-in-side Implantation.—Supposing the cæcum to have been excised and the mesentery ligated, the male Murphy button is introduced into the

free end of the ileum and tied in place, as in the ordinary end-to-end approximation. The edges of the free end of the cæcum are then united by overhand continuous silk sutures through all the coats—and these are buried in by the interrupted or continuous Lemberts of gut or silk. An opening is then made 2.5 to 5 cm. (1 to 2 inches) from the sutured end of the cæcum, upon its antimesenteric aspect, and the female button tied into place, just as in lateral intestinal anastomosis. The two buttons are now brought together in the usual fashion. The line of union should be here reinforced by a tier of interrupted Lembert sutures. The borders of the mesentery should be sutured as indicated.

(D) ENTERO-ENTEROSTOMY BY MECHANICAL MEANS TEMPORARILY USED FOR APPROXIMATING THE INTESTINAL EDGES DURING SUTURING.

IN GENERAL.

Description.—Various more or less ingenious forms of devices have been introduced for the purpose of holding in contact the opposite margins of the intestines during the act of suturing—to be withdrawn just prior to the completion of the suturing. Many of these, at the same time, distend the otherwise flaccid gut, and render the application of sutures easier. The following instruments, and the description of their application, will represent this class of work.

ENTERO-ENTEROSTOMY BY MEANS OF HALSTED'S INFLATABLE RUBBER CYLINDER.

Description.—Halsted's instrument consists of an inflatable rubber cylinder, attached, by means of a rubber tube, to a syringe with a two-way stopcock. The segments of intestine are first united by five or six fixation-sutures, those toward the mesentery being tied, those toward the antimesenteric aspect being left temporarily untied. Between these latter sutures the collapsed cylinder is inserted—it is then inflated by pumping air into it until of the desired size—and over this the Halsted mattress sutures are applied—all being placed, and most being tied, before the cylinder is withdrawn Between the last few untied sutures the exhausted cylinder is removed—and these last sutures tied. The method is of considerable aid in the suturing of the flaccid intestine and in the approximation of segments of unequal size—serving, at the same time, to keep the intestinal contents away from the line of suturing. The method is applicable to end-to-end approximation only.

Preparation—Position—Landmarks—Incision.—As in median abdominal section.

End-to-end Approximation.—(1) Having opened the abdomen and exposed the site of excision, clamp off the region with rubber bands wound in a figure-of-eight fashion over some object (such as a sterile, round, wooden toothpick) carried through the mesentery close to the barrel of the intestine (see Fig. 371, D), so planning the excision that the blood-supply will come up to the very edges of the ends of the gut. Ligate the mesenteric vessels prior to excising the mesentery. (2) Before excising the gut, five or six "presection" sutures, of the Halsted type, are placed, just beyond the line

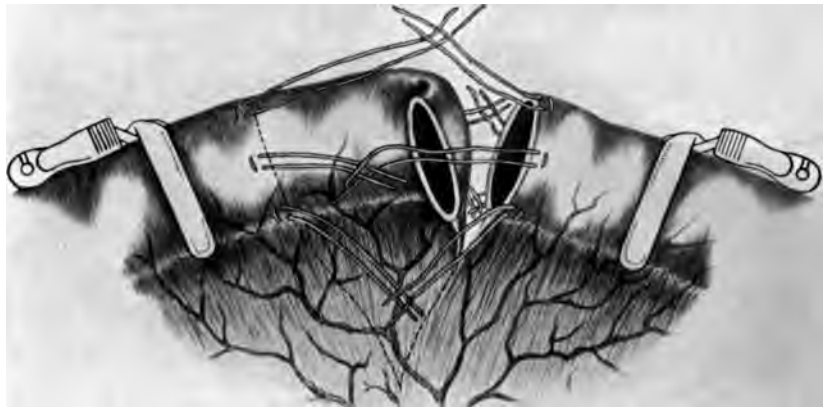

Fig. 409.—ENTERO-ENTEROSTOMY, END-TO-END, AIDED BY AN INFLATABLE RUBBER CYLINDER —HALSTED'S METHOD:—Showing the line of excision of intestine and mesentery, and the position of the "presection sutures." (Modified from Halsted.)

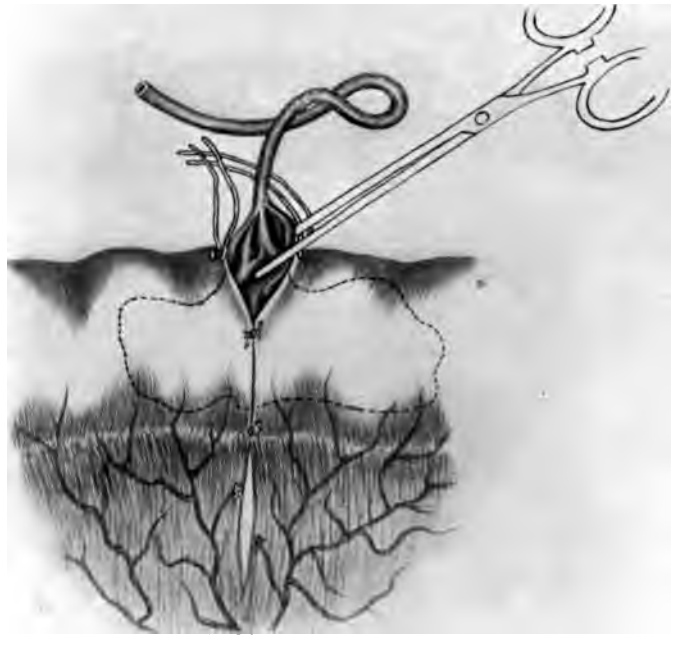

Fig. 410.—ENTERO-ENTEROSTOMY BY HALSTED'S METHOD. All the presection sutures tied except one pair, through the interval left by which the rubber cylinder is being introduced within the lumen of the gut by means of forceps. (Modified from Halsted.)

of future excision—two at the mesenteric aspect—two toward the lateral aspects—and two toward the antimesenteric aspect—with the free ends toward each other. While aiming to carry these sutures through only the serous, muscular, and part of the submucous coats, it is of no consequence if they enter the lumen, as they are buried by the next row. (See Fig. 409.) (3) Excise the intestine, with scissors, between the presection sutures, cutting quite close to them, and preserving the blood-supply to the ends of the gut. Repair the edges of the mesentery after completing the excision—or, preferably, the suturing together of the mesenteric edges may be deferred until

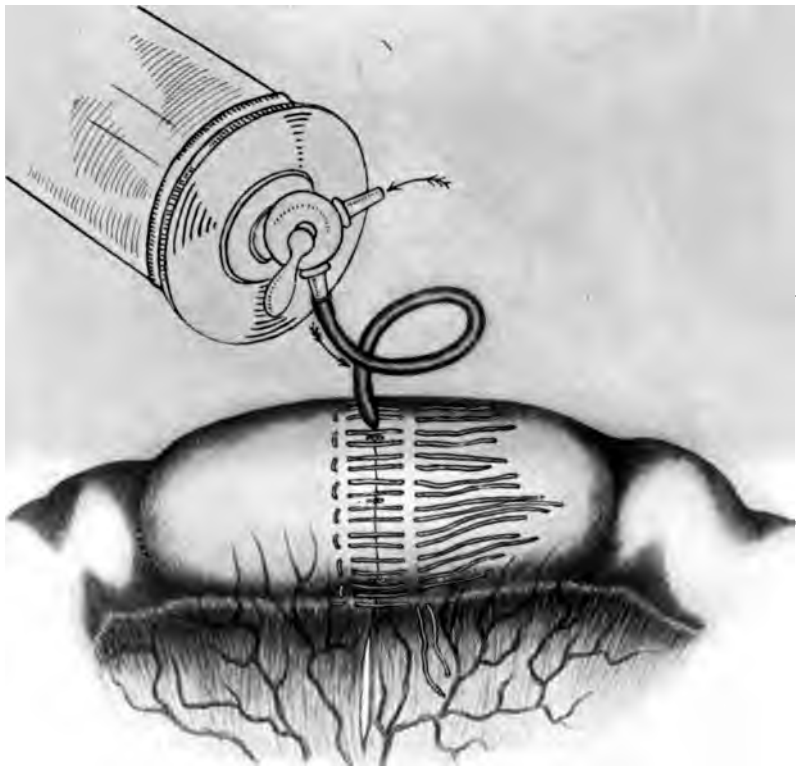

Fig. 411.—ENTERO-ENTEROSTOMY BY HALSTED'S METHOD:—The cylinder inflated—and the mesenteric and mattress sutures inserted. (Modified from Halsted.)

the union of the intestines and the withdrawal of the rubber cylinder. (4) Tie the presection sutures, knotting those of the proximal gut with the corresponding ones of the distal gut—but leaving temporarily untied those presection sutures toward the antimesenteric aspect. (See Fig. 410.) (5) Through the opening left by the untied presection sutures, the collapsed rubber cylinder, held in the grasp of long, slender forceps is introduced—so that one half will lie in the proximal and one half in the distal gut. The cylinder is now inflated to the desired extent. (See Fig. 411.) (6) The mesenteric stitch is the one first applied and tied—and the Mitchell and

Hunner suture is the form of stitch employed—which is, practically, equivalent to a Lembert suture applied to the intestinal wall on each side of the mesentery by means of a single suture introduced in the manner shown in Fig. 412, and puckering up the serous, muscular, and especially part of the submucous, coats, the tightening of which turns in the bowel and approximates the leaves of the mesentery. (7) A line of Halsted sutures, of the mattress or quilt type, is now applied around the approximated edges and slightly beyond the presection sutures, at intervals of about 2 mm. (somewhat more than $\frac{1}{16}$ inch)—applying all before tying any—then tying all but just enough to allow, by their separation, the withdrawal of the rubber cylinder. These sutures pass through the serous and muscular and into the submucous coat. None of the intestinal vessels should be obliterated by the passage of these

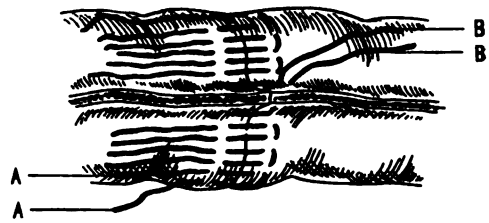

Fig. 412.—ENTERO-ENTEROSTOMY BY HALSTED'S METHOD:—A, A, Mattress or quilt sutures; B, B, The Mitchell and Hunner mesenteric suture. (Modified from Halsted.)

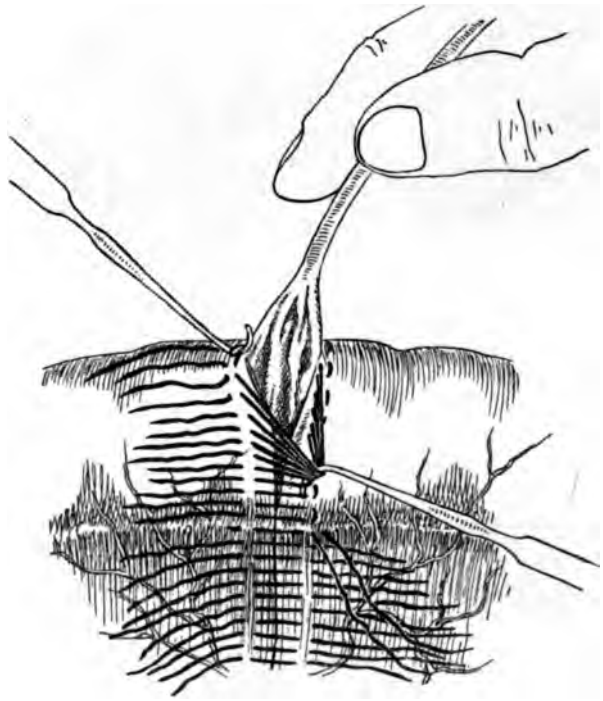

Fig. 413.—ENTERO-ENTEROSTOMY BY HALSTED'S METHOD:—The deflated cylinder is being withdrawn, while some of the sutures are temporarily retracted. (Modified from Halsted.)

sutures—avoiding them by carrying the sutures over or under them. (8) The cylinder is now allowed to collapse and is withdrawn—and the sutures between which it has been withdrawn are then tightened. (See Fig. 413.) (9) Having replaced the intestine, the abdomen is closed.

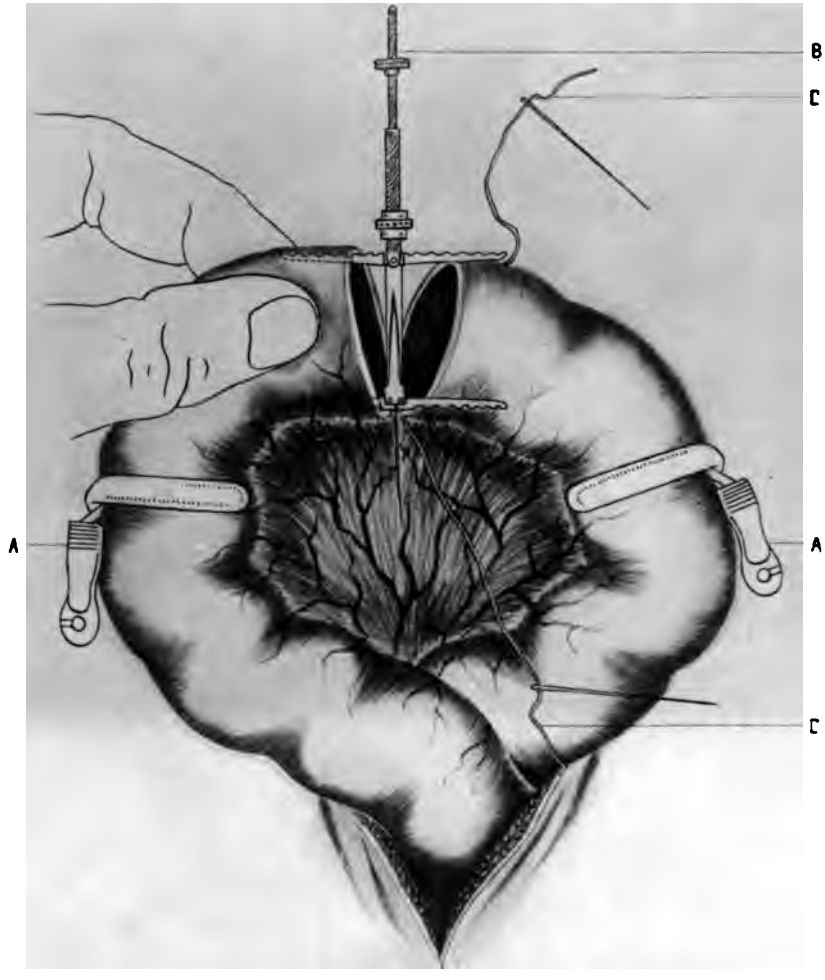

Fig. 414. END-TO-END ENTERO-ENTEROSTOMY BY LEE'S INTESTINAL HOLDER:—A, A, Clamps upon a coil of intestine from which a portion has been excised; B, Intestinal holder being inserted into the ends of intestine—its blades extended; C, C, The two ends of the mesenteric suture. (Modified from Lee.)

ENTERO-ENTEROSTOMY BY MEANS OF LEE'S INTESTINAL HOLDER.

Description.—The instrument, though simple in principle and construction, is difficult to describe clearly—but its manipulation is easy. The holder is introduced into the approximated ends of the intestine closed—is then opened—and serves as a framework upon which suturing is done—and is then finally closed and withdrawn. A single instrument fits any part of the intestinal tract and any suture may be used in conjunction with it. Lee uses a modification of the Connell stitch. The method is only applicable to end-to-end approximation.

Preparation—Position—Landmarks—Incision.—As for median abdominal section.

End-to-end Approximation.—(1) Open the abdomen—clamp off the site—and excise a portion of the intestine, with or without a part of its mesen-

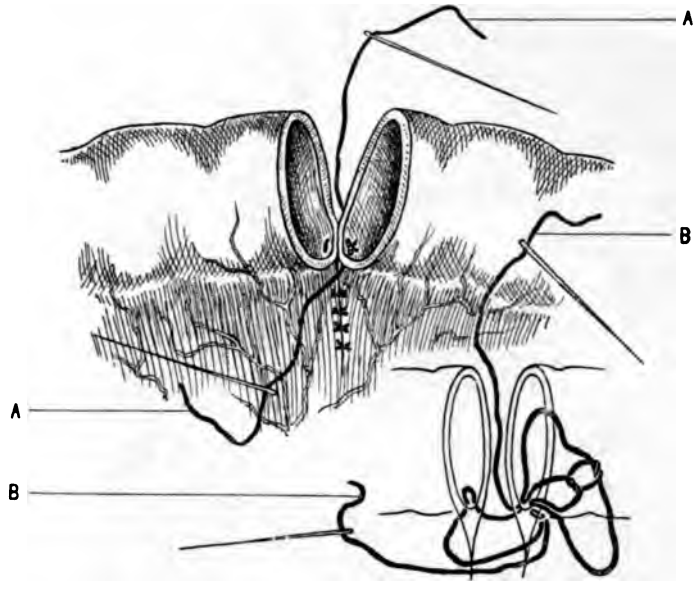

Fig. 415.—ENTERO-ENTEROSTOMY BY LEE'S INTESTINAL HOLDER :—A, A, Mesenteric suture tied and ends passed out of intestine ; B, B, Showing, first, manner of tying mesenteric suture—and, secondly, manner of passing ends of suture out of intestine. (Modified from Lee.)

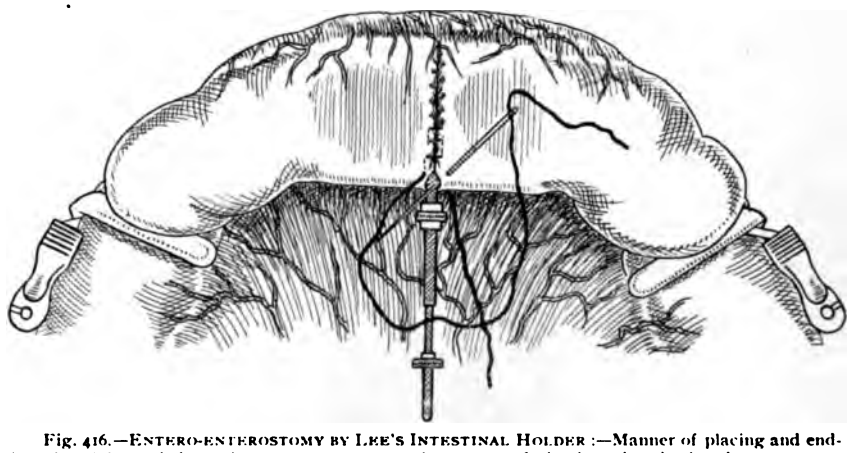

Fig. 416.—ENTERO-ENTEROSTOMY BY LEE'S INTESTINAL HOLDER :—Manner of placing and ending the right-angled continuous sutures upon the aspect of the intestine further from surgeon. (Modified from Lee.)

tery. (See Fig. 414.) (2) The mesenteric suture is passed—exactly as the mesenteric traction suture is passed in Maunsell's operation (page 688). Both ends of the silk are left long and are knotted within the lumen of the

gut—thus approximating the mesenteric aspects of both guts and both laminæ of the mesentery to the barrel of the gut (Fig. 415). Each end of the threads

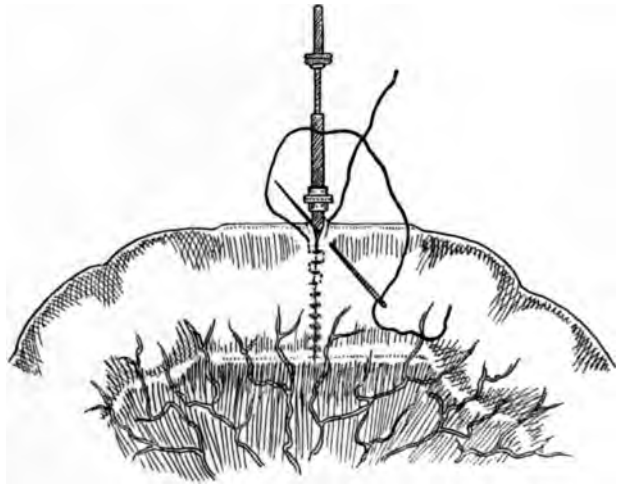

Fig. 417.—ENTERO-ENTEROSTOMY BY LEE'S INTESTINAL HOLDER:—Manner of placing and ending the right-angled continuous sutures upon the aspect of the intestine nearer the surgeon. (Modified from Lee.)

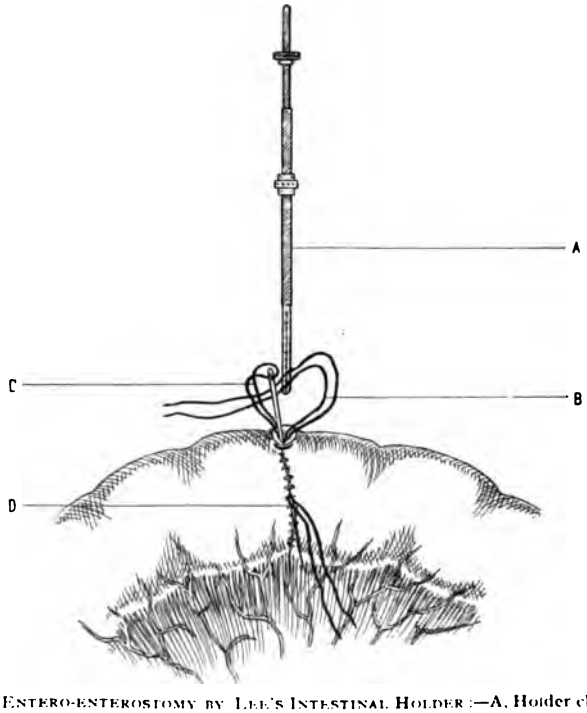

Fig. 418.—ENTERO-ENTEROSTOMY BY LEE'S INTESTINAL HOLDER:—A, Holder closed and withdrawn from intestine; B, Ends of the two sutures emerging from the same side and within the intestine; C, Loop introduced upon head of needle through suture-line at D, under which loop the ends of the main suture are caught and withdrawn at D. (Modified from Lee.)

is then needled—and the needles are made to pass out of the gut near the knot and the threads are drawn after. (3) The intestinal holder is now introduced and opened—distending each gut flatwise—the distal arms being against the mesenteric border and the proximal arms against the antimesenteric border—the free borders of intestine lying in parallel contact—there being no marked tension anywhere. (4) The half of the intestine nearer the surgeon is now sutured with right-angled continuous suture (Fig. 416), passing through all the coats, tightening the thread after each stitch. When the site of the emergence of the stem of the instrument is reached, the final stitch is made on the side opposite to the one on which the preceding stitch was made—and this final stitch is only a half-stitch, passing from without and ending on the interior of the gut (Fig. 416). (5) The instrument is

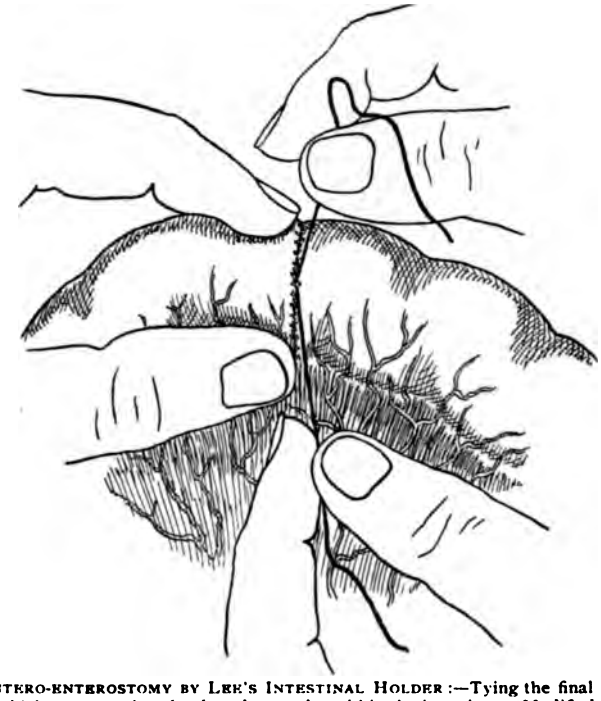

Fig. 419.—ENTERO-ENTEROSTOMY BY LEE'S INTESTINAL HOLDER:—Tying the final knot upon the outside—which, upon cutting the threads, recedes within the intestine. (Modified from Lee.)

now so turned as to present the opposite side (Fig. 417)—which is sutured in a similar manner—the final half-stitch ending on the same end of gut as the last half-stitch of the first side, and on the interior of the gut. (6) The instrument is now folded and withdrawn (Fig. 418)—leaving two free ends of silk ready to be tied. (7) To enable the ends to be knotted on the interior, a threaded needle is insinuated between the stitches of the opposite side, the eye first—and is pushed upward until the threaded eye protrudes through the opening formerly occupied by the handle of the instrument. The thread of the needle is then loosened into a loop, under which the free ends of the two sutures are passed—and by means of which these free ends are drawn out when the needle is withdrawn through the line of suturing, at the point where the head of the needle was pushed through. (8) These

sutures are then knotted, during which process the bowel is flattened and its mucous membrane near the final half-knots is approximated to the site where the sutures are being tied—the sutures are then cut short—and the knots slip into place and the intestine regains its form by a little manipulation (Fig. 419).

Comment.—Any other less intricate form of suturing may be used. Reinforcing Lemberts may be used if thought necessary.

ENTERO-ENTEROSTOMY BY LAPLACE'S INTESTINAL ANASTOMOSIS FORCEPS.

Description.—The complete instrument consists of two pairs of forceps, each blade ending in a half-ellipse. When the parts are clamped together two concentric and parallel ellipses are formed, which may be approximated and separated by means of the handles. In joining parts of the gastro-intestinal tract, a blade is passed into each opening—and when the blades are approximated, the walls of the free ends of each piece of intestine are held in position, serosa to serosa—while any desired form of suturing is applied around the circumferential border of the approximated intestines. The forceps are then unlocked and withdrawn, piece by piece—a few sutures being applied where the handles entered. Five sizes of the forceps are made, including one for cholecystenterostomy and uretero-enterostomy. The method is applicable to end-to-end and lateral approximation, lateral anastomosis, and end-in-side implantation.

Preparation—Position—Landmarks—Incision.—As in median abdominal section.

End-to-end Approximation.—(1) Having opened the abdomen and clamped off the region involved, the portion of intestine is excised, with or without its mesentery corresponding. (2) Four fixation sutures are inserted into the free margins of the gut—one, including both laminæ of the mesentery, at the mesenteric border—one at the antimesenteric border—and one on each side. (See Fig. 420.) (3) The forceps are introduced closed between a lateral and an antimesenteric suture—one blade being opened into the lumen of one gut—and the other into that of the opposite. As the blades open the intestinal walls are pushed inward or inverted—so that when the blades are closed the serous surfaces are pressed against serous surfaces. If this inversion does not readily occur, it may be aided by the fingers or an instrument, or by a string passed circularly between the blades of the forceps just before closing, and withdrawn as they close. (See Figs. 421 and 422.) (4) Interrupted Lemberts, or other form of suture, are now applied around the clamped surfaces, except where the forceps emerge—approximating serous and muscular coats of one gut to those of the other. During these steps the parts are conveniently manipulated by the handles of the forceps. (5) The forceps are now unclamped and carefully removed—and the opening through which they are withdrawn is closed by two or three Lemberts. (See Fig. 423.) (6) The mesentery is then sutured and the gut returned to the abdomen.

Lateral Approximation.—Having completed the excision of the indicated portion of the intestine, the end of each piece of intestine is seized with Laplace's invagination forceps (a long and slender instrument) and invaginated into the lumen of the gut, preliminarily to making the approximation. While the end of the intestine is thus held invaginated, the serous surfaces are

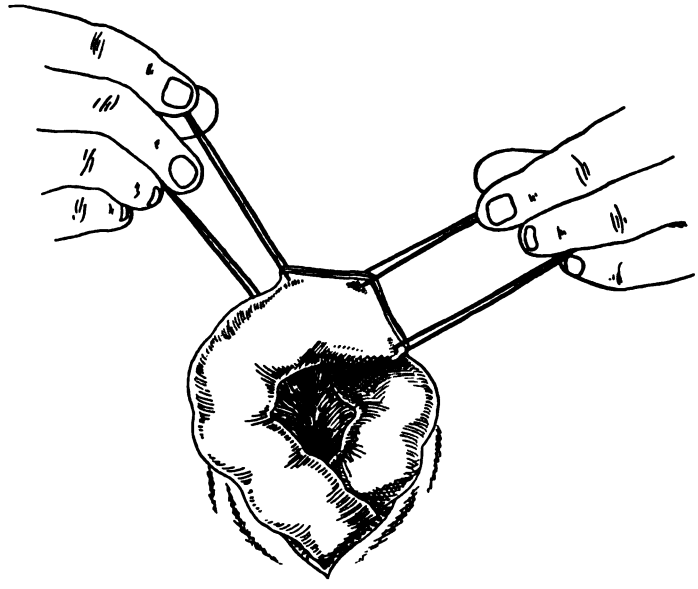

Fig. 420.—END-TO-END ENTERO-ENTEROSTOMY BY MEANS OF LAPLACE'S INTESTINAL ANASTOMOSIS FORCEPS:—Manner of placing the four preliminary fixation-sutures. (Modified from Laplace.)

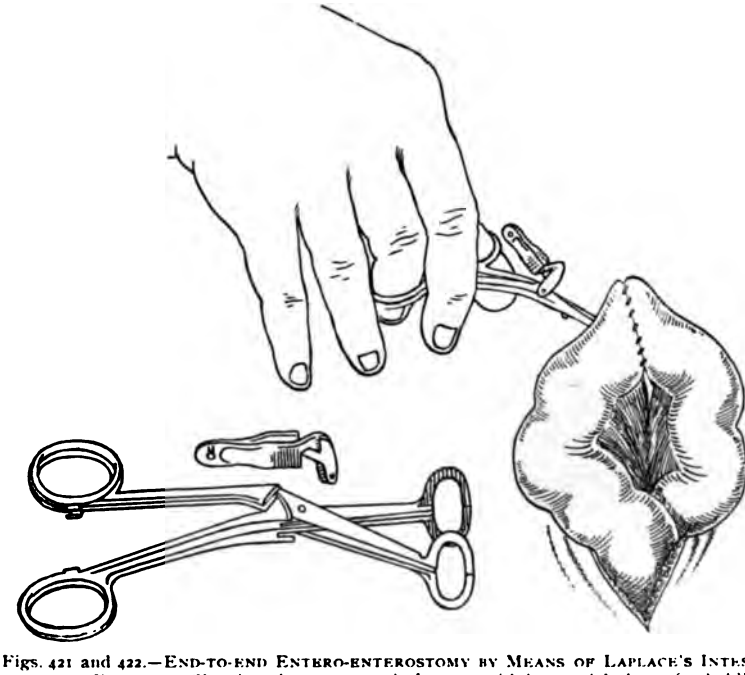

Figs. 421 and 422.—END-TO-END ENTERO-ENTEROSTOMY BY MEANS OF LAPLACE'S INTESTINAL ANASTOMOSIS FORCEPS:—Showing the anastomosis forceps, with its special clamp for holding the blades together,—and the manner in which it approximates the ends of the intestine. A line of continuous Lembert suturing unites the coils. (Modified from Laplace.)

brought together by interrupted or continuous Lembert sutures—the forceps being withdrawn just before the last two or three stitches are tied—immediately following the withdrawal of which the opening left by their withdrawal is similarly closed. The invagination of both ends having been accomplished, approximate the two antimesenteric aspects to be united—make two corresponding axial incisions about the length of the diameter of the rings to be used—place four fixation-sutures, one at each angle and one on each side—insert the closed blades between two of the approximation sutures—open one blade into the lumen of one and the other into that of the other intestine

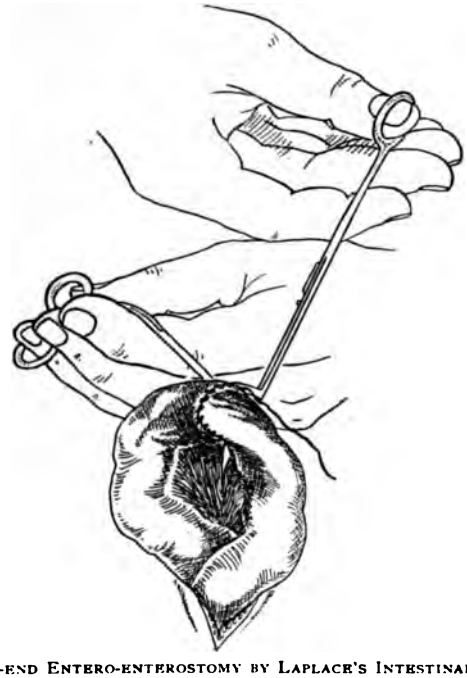

Fig. 423.—End-to-end Entero-enterostomy by Laplace's Intestinal Anastomosis Forceps:—Showing the manner of withdrawing the blades before tightening the last few sutures. (Modified from Laplace.)

—the walls of the intestines being inverted over the blades as they open (as in the end-to-end method)—then close the blades so as to press serosa against serosa—and suture as in the end-to-end form—after which the forceps are unclamped and withdrawn—the opening through which they are withdrawn being closed by two or three Lemberts.

Lateral Anastomosis.—The junction is accomplished as in lateral approximation—omitting the resection.

EXCISION OF THE ILEO-CÆCUM.

Description.—Consists in the removal of the cæcum, together with more or less of the adjoining portions of the ileum and ascending colon—followed by some form of entero-enterostomy between the small and large intestines. The operation is generally resorted to for malignant or tubercular disease of this region, or for intussusception of this portion.

Preparation—Position—Landmarks.—As for Appendicectomy (page 722).

Incision.—About 13 cm. (5 inches) long, beginning in the anterior axillary line (a vertical line from the anterior border of the axilla), midway between the lower margin of the costal cartilages and the iliac crest—passing downward to within about 4 cm. (1½ inches) of the anterior superior iliac spine—and thence obliquely downward and forward, parallel with the outer half of Poupart's ligament, ending to the outer side of the position of the external iliac artery.

Operation.—(1) Divide the skin, fascia, external oblique, internal oblique, transversalis, transversalis fascia, subperitoneal connective tissue, and peritoneum. The size and condition of the parts generally necessitates an operation of a magnitude too great for the intramuscular method of opening the abdomen—but in so far as this method can be adopted, it should be carried out. Both the muscular and aponeurotic portions of the external oblique can ordinarily be separated in the cleavage line. The abdominal vessels and nerves should be preserved as far as possible. Having exposed the abdominal cavity, retract the lips of the wound well and deeply. (2) If adherent omentum be encountered, ligate off with gut and divide. (3) Separate the cæcum from the iliopsoas fascia upon which it lies. This is accomplished by displacing the cæcum and colon inward and cutting through the peritoneum along the outer aspect of the cæcum and colon where it binds those structures to the posterior abdominal wall, ligating where necessary with gut. These structures are then displaced outward and the peritoneum divided along the inner side—but on this side the colic vessels are encountered as they diverge to supply the bowel—so that this region is ligated off in sections and divided. This inner line will cross the ileum where it joins the colon. The mesentery of this small intestine is ligated in sections, as far as may be necessary, and divided. (4) Having thus freed the cæcum and several inches of both colon and ileum, the contents of the bowel are pushed away, the intestines clamped, the neighboring regions protected with gauze packing, and the intestines divided at a right angle to their axis. (5) Having excised the ileo-cæcal region, an entero-enterostomy is accomplished in one of the following ways (previously described in detail):—(a) End-to-end approximation by simple suturing, by Murphy's button, or by Maunsell's invagination method—the first or second probably being preferable; (b) Invaginate the ends of both guts by overhand followed by Lembert sutures, and then make a lateral anastomosis between the ileum and colon by simple suture, or by a Murphy button (or by one of the other methods already described); (c) Divide the ileum obliquely, to give a larger opening, and unite it to the transversely divided colon by simple suturing—(often the ileum has been distended so long, by obstruction below, that it has become the same size as the colon); (d) Close the end of the colon by invagination, by a double row of sutures, and then implant the end of the ileum upon the lateral aspect of the colon (resembling nature's junction of the small and large intestines). (6) Drop the parts back into the abdomen, and close the abdomen, with or without drainage, as indicated, as in abdominal section.

Comment.—Remove all diseased glandular tissue.

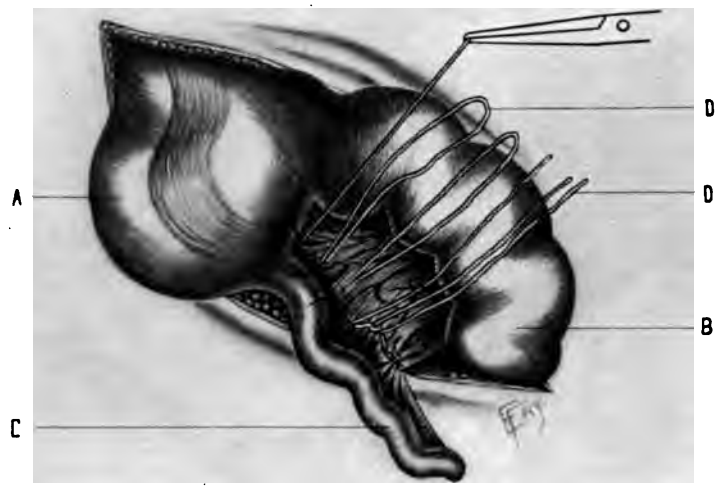

Fig. 424.—APPENDICECTOMY:—A, Cæcum; B, Ileum; C, Appendix; D, D, Ligatures tying off the mesentery of the appendix.

APPENDICECTOMY

BY McBURNEY'S INTRAMUSCULAR OPERATION.

Description.—Appendicectomy consists in the removal of the appendix vermiformis. The feature of McBurney's operation is based upon the exposure of the appendix through a successive separation, in the cleavage line, of the overlying abdominal muscles and aponeuroses. The fibers of the muscles and aponeuroses are not cut but are separated. The appendix is exposed and is treated by one of several methods. This form of the operation is chiefly applicable to the "interval period" of appendicitis—but is sometimes used in acute cases and in pus cases.

Preparation—Position—Landmarks—Incision.—Given under Abdominal Section by McBurney's Intramuscular Incision (page 637).

Operation.—(1) Having opened the abdomen in the manner described under the above operation, the right index-finger is inserted within the abdominal cavity and the appendix sought. The caput coli, or some part of the ascending colon, is generally encountered at once—and may even bulge into the wound. Sometimes the appendix itself presents at once—though exceptionally. If the appendix is not at once manifest, its base is sought in its usual position—that is, upon the internal and posterior aspect of the cæcum, about 1.7 cm. ($\frac{11}{16}$ inch) below the ileo-cæcal valve. If the appendix is not readily found by this manœuvre, draw out the first part of the ascending colon encountered, and then follow it down to the caput coli—the anterior of the three longitudinal bands of the colon will lead to the base of the appendix. The appendix is now drawn out of the wound, and its treatment will depend upon the nature of the appendix and the individual views of the operator. (See Fig. 424.) (2) As soon as the appendix has been delivered without the abdominal cavity, it is well to pass a silk ligature, upon an aneurism needle, around the appendix, about 2 cm. ($\frac{3}{4}$

inch) from its base, piercing its mesentery. This ligature may be tightened at once or later—it is only a temporary traction-ligature. The mesentery of the appendix should be ligated off with chromic gut, carried in a laterally curved aneurism-needle, proceeding from apex to base, or in the opposite direction if more convenient—and tied in sections—the mesentery being then divided between appendix and ligatures. If bound down by adhesions, these should be separated by blunt dissection, or ligated and cut. Often the mesentery of the appendix must be ligated off within the wound, before the appendix can be delivered. (3) The appendix is now treated in one of several ways—in all of which, however, the patulousness of the lumen must be determined, in advance, by the passage of a probe through its canal into the cæcum, that drainage into the main intestine may be assured. The following methods



Fig. 425.—APPENDICECTOMY:—A, Edges of the mesenteriolum sutured together; B, B, Purse-string suture placed, the loop being grasped by forceps and the ends free.

of closing the appendix may be used;—(a) Dawbarn's Purse-string Method; a continuous, silk, purse-string suture, carried upon a straight needle, is passed through the serous and muscular coats of the cæcum in a circle, about 6 mm. (¼ inch) from the base of the appendix, but not at first tied. (See Fig. 425.) The loop opposite the free ends of this purse-string suture is grasped by forceps held by an assistant, to steady the appendix against the counter-pull of the operator who holds the free ends. The appendix is then divided transversely about 1.2 cm. (½ inch) from its base—the canal of the stump may be dilated with special fine forceps (to aid in invagination)—and sometimes sterilized by the actual cautery point—the free end of the stump is then seized with the same forceps and invaginated into the cæcum. (See Fig. 426.) While the stump of the appendix is held invaginated into the cæcum, the operator draws upon the free ends of the purse-string suture (which have been loosely knotted with a friction-knot) until the slack of the loop held by the assistant is taken up—the assistant, letting go his grip



Fig. 426.—APPENDICECTOMY:—Dilatation of canal of appendix by means of forceps, preparatory to invagination.

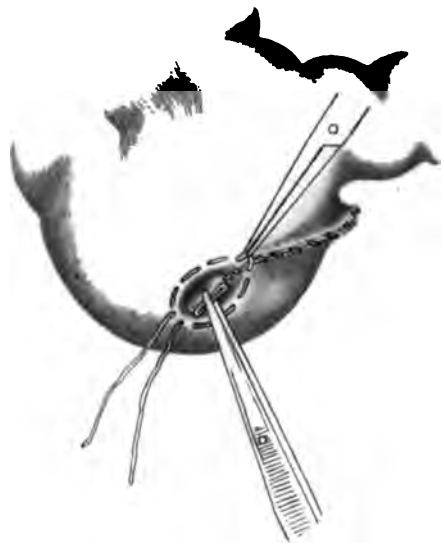

Fig. 427.—APPENDICECTOMY.—The stump of the appendix being invaginated in the grasp of forceps, and the purse-string about to be tightened.

of the loop with the forceps, takes the two free ends of the suture—tightening the friction-knot accurately at the very moment the operator quickly withdraws the invaginating forceps. A second knot is tied and the ends cut short. (See Fig. 427.) If considered necessary, two or three interrupted gut Lemberts may be used to further bury in the stump. (See Fig. 428.) This method of closure is especially applicable to appendices whose walls are of more or less natural thickness and softness—capable, in other words, of invagination. (**b**) Divide circularly the peritoneal coat of the appendix about 6 mm. ($\frac{1}{4}$ inch) from the cæcum—peel back this serous coat toward the cæcum—and, on a level with the turned-back serosa, divide the middle and internal coats of the appendix very near the cæcum. (See Fig. 429.) See that the lumen of the stump is patulous by means of a probe, and cauterize the interior of the stump with a fine Paquelin point. The edges of the stump are then brought together either by fine silk sutures, or by circular ligature.

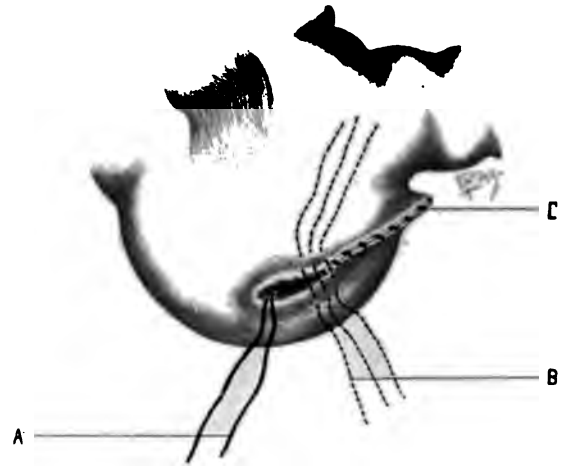

Fig. 428.—APPENDICECTOMY:—A, The free ends, after knotting, of the purse-string which has invaginated the stump of the appendix into the cæcum; B, Position which reinforcing Lemberts would occupy, if used; C, The sutured edge of the mesenteriolum.

This short stump itself is then depressed (rather than invaginated) into the cæcum (see Fig. 430)—and, after suturing the serosa over the stump, the surrounding area of the cæcum, to the extent of 3 mm. ($\frac{1}{8}$ inch) from the base of the appendix, is invaginated by means of a purse-string suture which had been previously placed in the same manner as in the last method. (See Fig. 431.) Additional interrupted gut Lemberts may bring the edges of the furrow together, if considered necessary. This method is particularly applicable to thick, hard, narrow-calibred appendices. (**c**) The peritoneal coat may be peeled back—the middle and internal coats divided transversely—and the peritoneal coat sutured over the cut middle and internal coats with Lemberts. (**d**) The mucous coat may be excised with fine, curved, sharp-pointed scissors, or burnt out with the actual cautery—and the serous and muscular coats sutured over it. (**e**) The same steps may be carried out as in "b," except that the stump may be simply depressed into the cæcum and the walls of the cæcum brought together with Lembert sutures in a

straight line. (4) The appendix having been removed and its stump sutured, the bowel is returned to the abdominal cavity—and the wound closed as



Fig. 429.—APPENDICECTOMY:—A METHOD OF DEALING WITH THICK APPENDICES, BY LIGATION AND DEPRESSION INTO CÆCUM:—A, Clamping off appendix from cæcum: B, Cuff of serosa turned back; C, Stump of appendix ligated; D, Edges of mesenteriolum sutured.

Fig. 430. APPENDICECTOMY: A, Stump of appendix depressed into cæcum; B, Interrupted Lembert sutures closing serosa over stump; C, Sutured edges of mesenteriolum.

in McBurney's Intramuscular Abdominal Incision. Drainage is ordinarily not employed unless specially indicated.

Fig. 431.—APPENDICECTOMY:—The depressed appendix-stump and the invaginated serosa themselves invaginated into the cæcum by a purse-string suture of the surrounding area.

Comment.—If at any time during the operation more room be required, this may be gained by continuing the separation either upward or downward. In the latter direction, the separation is accomplished by Weir's method (page 639).

APPENDICECTOMY

BY THE ORDINARY METHOD.

Description.—In this operation no attempt is made to separate the muscle-fibers of the abdominal wall, which are freely cut where they cross the line of incision. The method is applicable to "interval" and to pus cases—but guards the abdominal wall from hernia less well than does the method just described.

Preparation—Position.—As in the Intramuscular Operation (page 637).

Landmarks.—Anterior superior iliac spine; umbilicus; outer border of right rectus muscle.

Incision.—Draw an imaginary line from the anterior superior iliac spine to the umbilicus—the incision will begin about 2.5 cm. (1 inch) above this line, and will run obliquely downward and inward, parallel with and about 1.2 cm. (½ inch) to the outer edge of the right rectus muscle.

Operation.—(1) The incision divides skin and fascia—passes through the external oblique approximately parallel with its fibers—divides the internal oblique and transversalis more or less transversely, and just to the outer side of the ending of their muscular fibers. (2) All bleeding vessels are seized, and the wound well retracted. (3) Divide the fascia transversalis, subperitoneal areolar tissue, and peritoneum in the line of the original wound and with the usual precautions—especially guarding against adhesions. (4) Having opened the abdomen and retracted the lips of the wound well, the isolation and treatment of the appendix are carried on just as in the Intramuscular operation of McBurney (page 637). (5) And the wound is closed as in median abdominal section (page 635, paragraph 9).

ENTEROSTOMY IN GENERAL.

Description.—(1) Enterostomy consists in the making of a more or less permanent opening into some part of the intestinal canal, for the purpose

of relieving obstruction or of furnishing nourishment—the opening thus made communicating with the external abdominal surface. This opening may be a Jejunostomy, Ileostomy, or Colostomy. When not specially designated, Enterostomy is generally understood to mean an opening of the small intestine, in which sense it will be here used. (Enterotomy has been incorrectly used to designate this operation.) If the opening be made high up in the small intestine, it may serve as an artificial mouth for nourishment (*e. g.*, jejunostomy, near the stomach). If the opening be low down in the small intestine (*e. g.*, an ileostomy, low down), or anywhere in the large intestine (*e. g.*, colostomy), it will serve the rôle of artificial anus. In the last category of cases it is generally performed for some more or less permanent obstruction, the opening being, of course, above the seat of obstruction. (**2**) The manner of performing enterostomy will differ—as to whether a temporary opening is sought, which will, of its own accord, tend to close,—namely, a fecal fistula, which is generally done in some form of removable obstruction,—or whether a permanent opening is desired, which will, through a spur-like formation, tend to remain patulous—namely, an artificial anus, which is generally done in some form of irremovable obstruction. The technic of enterostomy, whether for artificial mouth, temporary fecal fistula, or permanent artificial anus, is practically the same as that for colostomy performed for temporary fecal fistula or permanent artificial anus—the chief difference being in the site of the operation. (**3**) Enterostomy (of the small intestine) is generally done upon the right side, and as near the cæcum as possible. Where the operation is done for obstruction, the site is, naturally, always above the obstruction. The operation may be done in the median line or upon the left side. Frequently, especially in desperate and weak cases, the first coil of distended gut is opened. A permanent artificial anus is generally made, where possible, in the course of the descending colon, a description of which is given under colostomy. (**4**) The cause having been removed, for which the fecal fistula or artificial anus has been made, it is indicated to close the opening by operation if nature does not do so. (**5**) The site of choice for opening the intestine for temporary fecal fistula, or permanent artificial anus, is in the colon. (See Colostomy, page 731.)

RIGHT INGUINAL ENTEROSTOMY (OR ILEOSTOMY), FOR THE ESTABLISHMENT OF A TEMPORARY FECAL FISTULA.

Description.—An incision having been made in the right inguinal region, the first distended coil of intestine above the cæcum is drawn out and attached to the abdominal wall, on a level with, or but slightly projecting above, its surface. While the operation, as originally devised by Nélaton, did not follow the intramuscular lines, it should do so where possible. No attempt is ordinarily made to remove the cause of the obstruction. The opening is meant to be but temporary, and if it does not close spontaneously it is closed by operation subsequently.

Preparation.—As for median abdominal section.

Position.—Patient supine, with right side near edge of table. Surgeon on side of operation—assistant opposite.

Landmarks.—Outer portion of Poupart's ligament; deep epigastric artery.

Incision.—About 5 to 7.5 cm. (2 to 3 inches) (according to the thickness of the abdominal wall)—placed about 4 cm. (1½ inches) above and parallel

with the outer part of Poupart's ligament, and external to the deep epigastric artery.

Operation.—(1) Having followed the steps of the intramuscular incision of the abdominal wall (page 637) and retracted the lips of the wound, the cæcum is sought with the finger and located as a rallying-point. The site of the obstruction is then located if possible, and, if so, the first distended coil of intestine above the obstruction is caught and brought into the wound. Where the source of obstruction cannot be found, any distended coil of intestine is taken and brought forward (which will probably be a portion of the lower ileum). In bringing the gut forward into the wound, its normal relations and direction should be maintained, as far as possible—and only its convex, antimesenteric aspect should project from the wound, but this aspect should well fill the portion of the wound to be left open, and any excess of intestine from above should be returned to the cavity, that the upper part may not sag down upon the lower. (2) The excess of length of the wound is now closed from either end, either by through-and-through suturing of all layers with silkworm-gut or silk, or by layer-suturing with chromic gut. When shortened to the desired extent, in cases where the length has been excessive—or from and beginning with the first suture at either end, where the length has only been moderate—the serous and muscular coats of the intestine are included in the suture at either end of the wound, thus fixing the gut to the abdominal wall at the same time the lips of the ends of the wound are approximated. If necessary, two fixation-sutures may be applied laterally, passing through serosa and musculosa of the intestine and all the layers of the abdominal wound. (3) An elliptical area of the presenting gut is now sutured to the parietal peritoneum by a continuous or interrupted fine silk suture, passing through serous and muscular coats of the intestine, on the one hand, and peritoneum and transversalis fascia, on the other. A second row of continuous or interrupted silk or gut sutures may then be placed, uniting the skin of the abdominal wound to the serous and muscular coats of the intestine, including the free margin of the parietal peritoneum external to the elliptical suture in the presenting gut. Or the second row of sutures may simply unite the edge of the abdominal skin to the free margin of the parietal peritoneum. A union considered firmer by some may be secured by first suturing the parietal peritoneum to the skin all around the permanent opening—and then suturing the intestine to this. (4) If haste be necessary, an opening is at once made into the lumen of the gut, by a quick, controlled stab with a narrow, sharp knife and increased to the desired extent with blunt scissors (having ascertained that all the coats of the intestine have been pierced before inserting the blade of the scissors). If no haste be necessary, a delay of two or three days for union of the serous surfaces and exclusion of the abdominal cavity is preferable ("operation in two stages"). The intestinal contents are allowed to escape of their own accord.

Comment.—(1) The operation may be performed through a median or other incision—or the obstruction may be located through a median incision and enterostomy done through a lateral incision—thus giving greater room for diagnosis and possibly for correcting the cause of trouble—the excess in length being closed in at either end before attaching the intestine. Left inguinal enterostomy may also be done. (2) Avoid wounding the deep epigastric artery and twisting the gut. (3) As small an opening as consistent with efficient emptying should be made, to make the subsequent closing easier.

RIGHT INGUINAL ENTEROSTOMY (OR ILEOSTOMY) FOR THE ESTABLISHMENT OF A PERMANENT ARTIFICIAL ANUS.

Description.—Enterostomy for the establishment of a permanent artificial anus differs from enterostomy for temporary fecal fistula, in that the former is performed in cases where the obstruction is irremovable, and also where it is sought to prevent the passage of intestinal contents into the limb of the bowel below the opening. The typical operation of enterostomy for the establishment of a permanent artificial anus is seen in the operation of Colostomy (as performed for inoperable obstruction of the rectum, *q. v.*). The operation to be here considered is simply an application of those principles to cases of the small intestine where, upon opening the small bowel above the seat of obstruction, it is found the opening must be more or less permanent. It is even of greater importance that a permanent artificial anus of the small intestine should be lower down than a temporary fecal fistula. It is well to follow the intramuscular manner of abdominal incision, where possible—both as a guard against hernia and for gaining something of a sphincteric control of the intestinal opening. The only practical difference between this and the preceding operation is in the manner of attaching the knuckle of intestine to the abdominal wound.

Preparation—Position—Landmarks—Incision.—As for Right Inguinal Enterostomy for Fecal Fistula.

Operation.—(1) The early steps of the operation are the same as when a temporary fecal fistula is to be made (page 728). (2) When the knuckle of bowel to be drawn into the wound is isolated, it is important and necessary to determine which is the proximal part of the coil. This having been done, and the knuckle having been drawn into the wound, the excess of intestinal length which tends to sag down into and out of the upper angle of the wound is taken up and passed on down through the lower angle of the wound (so as to do away with the likelihood of future hernia of the proximal limb of the intestine through the wound). (3) The desired knuckle of intestine having been isolated and retained within reach by a temporary loop of silk passing through the antimesenteric aspect of its outer coats, the two ends of the wound are closed toward the center, as far as thought necessary, by tier suture or by through-and-through suture. (4) The parietal peritoneum is drawn out and sutured to the abdominal skin, or as nearly in contact with it as possible all around the wound. (5) The knuckle of intestine is now drawn entirely out of the wound, until the mesenteric attachment is on a level with the skin. Care is taken that the intestine is not twisted and that the normal relations are maintained, as nearly as possible. Care is also especially taken that the proximal limb of the loop is identified and kept uppermost in the wound, is given plenty of room in the opening, and that it is made to compress the distal limb against the lower angle of the wound (to prevent the passage of intestinal contents from the proximal into the distal limb). While held in this position, the knuckle of intestine is sutured into permanent position—by continuous or interrupted silk sutures passing through the serous and muscular, and part of the submucous, coats of the intestine, on the one hand, and the parietal peritoneum (which has been already attached to the skin) on the other. (6) If no haste exist, the opening of the intestine is deferred for two or three days, until serous adhesions have occurred. If haste be necessary, the opening may be made at once, by cutting out transversely, with scissors, a triangular piece of the whole thickness of the

intestine, with its base at the free border and its apex at the mesenteric attachment.

Comment.—(1) This, as well as the operation for fecal fistula, may be made in the median or left lateral regions, but it is even more important than in temporary fecal fistula that the opening be as low as possible, to prevent starvation. (2) A somewhat smaller opening in the peritoneum is generally made than in fecal fistula. (3) A glass rod may be run through the mesentery, as is sometimes done in colostomy—to hold the coil of intestine in place. (4) It is well to put a few interrupted Lembert sutures along the lateral aspect of the two limbs of the knuckle, where they come in contact. (5) Where the intestine must be opened at once, only a limited opening is then made—the permanent opening being made after adhesions form.

COLOSTOMY IN GENERAL.

Description.—Colostomy signifies the establishment of an artificial opening, either temporary (fecal fistula), or permanent (artificial anus), in some part of the Colon. While a similar opening of the cæcum is termed cæcostomy, and of the sigmoid colon, sigmoidostomy, both operations are generally, though less specifically, included under the term colostomy. The descending colon is the site generally chosen—the cause usually being obstruction, or some condition, distal to the site of operation.

Chief Varieties of Colostomy.—(1) Inguinal Colostomy (Iliac Colostomy, Anterior Colostomy, operation of Littré) signifies the opening of the sigmoid flexure of the colon in the left iliac region, through the peritoneal cavity. The ascending colon is much less frequently opened. (2) Lumbar Colostomy (Posterior Colostomy, operation of Amussat) signifies the opening of the ascending or descending colon, preferably the latter, through the loin, extraperitoneally.

In Favor of Inguinal Colostomy.—The artificial anus is more conveniently placed;—the operation is both easier and quicker;—the position for anesthesia is better;—the wound is not so deep;—there is no chance of failing because of the presence of a mesentery (which sometimes interferes, by its presence, with the operation posteriorly);—the exploration of the abdomen is possible;—the shallower wound makes the formation of a spur, or any other indicated step, easier.

In Favor of Lumbar Colostomy.—The peritoneum is generally not opened;—where the sigmoid colon is bound down, and therefore not easily accessible by the anterior operation;—prolapse (hernia) is not so likely.

Observations.—(1) Left Inguinal Colostomy is the operation of choice. Lumbar colostomy is now rarely performed. (2) The ascending colon has a mesentery in 26 per cent.—and the descending colon in 36 per cent. of cases (Treves). This means that in those cases where a mesentery is encountered, in operating posteriorly, the operation cannot be completed extraperitoneally unless the leaves of the mesentery can be separated and the mesenteric aspect of the colon thus approached. (3) The positions of the ascending and descending colons are represented, in the loins, by vertical lines drawn upward from a point 1.3 cm. (½ inch) posterior to the center of the crest of the ilium (that is, a point 1.3 cm., or ½ inch, posterior to a point midway between the anterior and posterior superior iliac spines). (4) If a temporary fecal fistula be sought, no spur should be formed in suturing the knuckle into position. If a permanent artificial anus be sought, a spur

should be made in the knuckle, to prevent the flow of contents of the proximal into the distal gut. (5) By operating in the intramuscular manner, hernia is less apt to follow—and, additionally, greater sphincteric control is secured. (6) Where a temporary opening is sought, the bowel is opened longitudinally—and transversely where a permanent opening is planned.

LEFT INGUINAL COLOSTOMY.

Description.—Left Inguinal (Iliac or Anterior) Colostomy consists in making a more or less permanent opening in the sigmoid flexure of the colon, in the left iliac region, through the peritoneal cavity. The manner of suturing the intestine to the abdominal wall will differ, dependent upon whether a temporary fecal fistula or a permanent artificial anus be sought. Also the final steps of the operation will differ, dependent upon whether the bowel is to be opened at once, or whether the operation is to be performed in two stages and the bowel opened in three or four days, after adhesions have formed and the peritoneal cavity is shut off – and also as to whether the opening is to be temporary or permanent. The operation is generally done upon the left side—though it may be done upon the right—the steps being the same in either case. The operation is generally done for some obstruction (usually cancer of the rectum), or other condition, distal to the site of the colostomy.

Preparation—Position.—As for median abdominal section.

Landmarks.—Umbilicus; left anterior superior iliac spine; Poupart's ligament.

Incision.—About 5 to 6.5 cm. (2 to 2½ inches) long—crossing, at right angles, an imaginary line from the umbilicus to the left anterior superior iliac spine, at a point about 4 cm. (1½ inches) internal to the iliac spine, the center of incision being upon this imaginary line. The incision will, therefore, be about parallel with Poupart's ligament and with the fibers of the external oblique. This incision corresponds with McBurney's incision for appendicectomy, except that it is upon the left (see Fig. 355).

Operation.—Up to the opening into the peritoneal cavity, the steps are practically the same as in McBurney's intramuscular operation for the removal of the appendix (page 637). (1) Incise the skin and fascia in the above line, clamping the bleeding vessels. (2) Separate and retract the fibers of the aponeurosis of the external oblique in the line of their cleavage. (3) Separate and retract the fibers of the internal oblique in their cleavage. (4) Similarly separate and retract, intramuscularly, the fibers of the transversalis. (5) Divide the transversalis fascia and subperitoneal connective tissue in the line of separation of the transversalis muscle, for about 4 to 5 cm. (1½ to 2 inches). (6) While holding the parts apart, replace the retractors which have retracted the several tissues in their cleavage line by two retractors—drawing the lips of the wound asunder in the two most convenient directions. (7) Introduce the right index-finger into the peritoneal cavity toward the left iliac fossa—entering at the outer angle and passing downward and toward the median line, with the finger held in a hook-like fashion—hooking up the sigmoid flexure of the colon and bringing it out into the wound—recognizing it by its appendices epiploicæ, its sacculations, and its longitudinal bands. After drawing the loop well out, return into the lower angle of the wound all the excess drawn out of the upper angle, until checked by the mesocolon—thus assuring that there will be no downward

sagging of the intestine from above, with consequent tendency to hernia of the proximal gut through the artificial opening. The steps of the operation from this point on will be determined by, (a) the object sought, as to permanency of opening—and, (b) as to whether the intestine must be opened at once. (a) **Where a temporary fecal fistula is intended**:—In this case the presenting convexity alone (representing from one-half to three-fourths of the circumference of the intestinal tube) is sutured into the wound, the convexity of the gut being held, during suturing, into contact with the wound by two silk traction-sutures passed through the serous and muscular coats, preferably through the superior longitudinal band of the colon—(or this aspect of the intestine may be gently grasped with forceps). (See Fig. 432.)

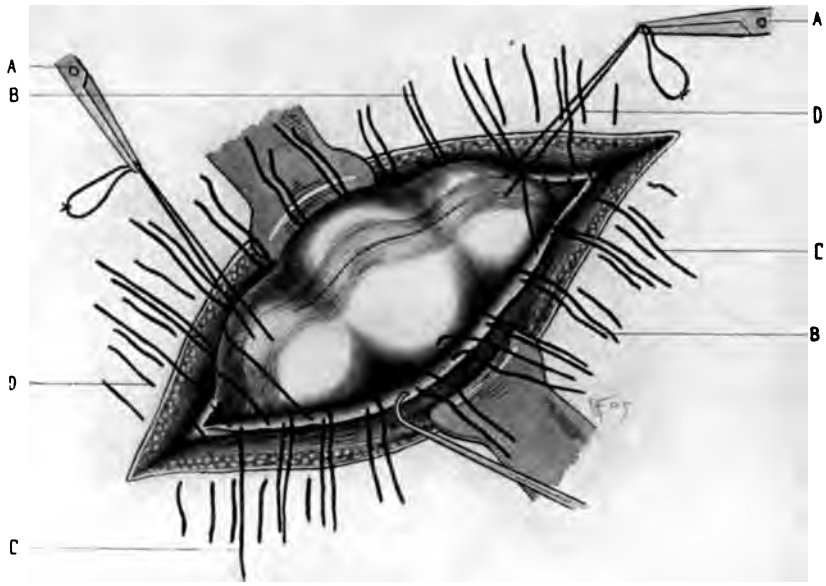

Fig. 432.—Left Inguinal Colostomy—for Temporary Fecal Fistula:—A, A, Temporary ligatures drawing sigmoid flexure of colon into wound; B, B, Sutures uniting peritoneum and lower part of muscular wall of wound, to serous and muscular coats of intestine; C, C, Sutures passing through peritoneum and lower part of muscular wall, on one side; serous and muscular coats of intestine, in center; and peritoneum and lower part of muscular wall, on opposite side; D, D, Sutures passing through entire thickness of muscular wall. Position of future axial incision in colon is shown by dotted lines.

Continuous or interrupted silk or chromic gut sutures are now passed through the serous and muscular coats of the intestine, on the one hand, and the peritoneum and muscle tissue of the abdominal wound, on the other—passing sufficiently far from the free edge of the peritoneum so that some width of peritoneum will be approximated to gut—thus bringing serous surfaces into contact. Preferably the lower line of sutures is passed through the lower longitudinal band—and the upper line, near the mesentery. Any excess of abdominal wound is first closed from either end by interrupted sutures passed as in abdominal section. If haste is unnecessary, the opening is made in two or three days, when the serous surfaces have united. An incision of about 2 cm. ($\frac{3}{4}$ inch) is made into the long axis of the gut—and

the edges of the intestinal wound (all of the coats) are sutured to the skin of the abdominal wound. If haste is necessary, the above is done at once. **(b) Where a permanent artificial anus is intended:**—The knuckle of intestine is drawn well out of the wound, exposing its mesentery. Incise the mesentery, in a line with its vessels, and near the bowel—and insert a short glass rod, or similar object, through this opening—the ends of the glass rod resting on either side of the edges of the wound. If the slit through the mesentery be excessive, the excess is gut-sutured. The two limbs of the knuckle above and below the rod are sutured to each other by gut sutures passing through serous and muscular coats and approximating their mesenteric aspects, thus forming a spur of the walls so brought into apposition.

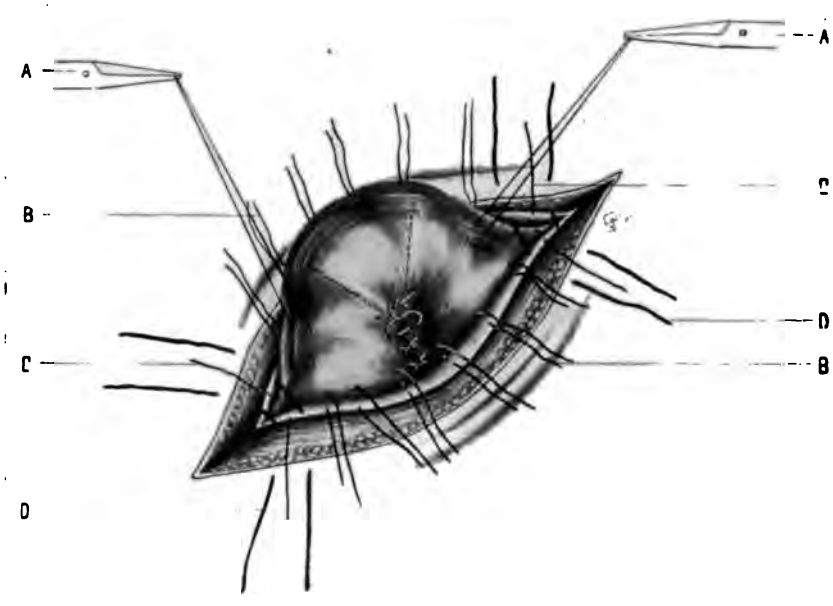

Fig. 433.—Left Inguinal Colostomy—for Permanent Artificial Anus:—A, A, Temporary traction-ligatures drawing sigmoid flexure of colon into wound; B, B, Sutures uniting peritoneum and lower part of muscular wall of wound, to serous and muscular coats of intestine; C, C, Sutures passing through peritoneum and lower part of muscular wall, on one side; serous and muscular coats of intestine, in center; and peritoneum and lower part of muscular wall, on opposite side; D, D, Sutures passing through entire thickness of muscular wall. Position of future excision of triangular piece of colon is shown by dotted line.

(See Fig. 433.) Having first closed in any excess of abdominal wound from either end, by sutures applied as in abdominal section, the protruded knuckle is then sutured into the wound by silk or chromic gut sutures passing through serous and muscular coats of the intestine, on the one hand, and through peritoneum and muscle tissue of the abdominal wound, on the other. If haste be not necessary—wait two or three days until the serous surfaces have united and the peritoneum has been shut off—then seize, with rat-tooth forceps, the prominent knuckle of intestine and cut out transversely, in a line with the rod, a V-shaped segment of gut, with scissors—excising the entire, or nearly the entire, diameter of gut, with the apex of the excised portion ending where the limbs have been sutured together. Let the distal

end of the intestine retract. Suture the margins of the proximal end to the skin of the abdomen. Remove the glass rod in about seven days—and the sutures in about ten. If haste be necessary—the above is done at once.

Comment.—(1) Slight variations occur in the operation as done by Maydl;—the knuckle of intestine is drawn out—the glass rod passed through the mesentery—the limbs of the loop sutured together as above,—following which the steps will differ as to the object sought;—(**a**) If the intestine is to be opened at once—it is stitched to the parietal peritoneum, as described above;—(**b**) If the intestine is not to be opened at once—it is not stitched, but simply gauze is packed around and under the glass rod;—(**c**) If the opening is to be permanent—the bowel is to be divided transversely in from four to six days, through one-third of its diameter—an irrigating tube is then inserted and the intestines washed out—and in two or three weeks later the transverse division is completed—the edges of the proximal gut are sutured to the margins of the skin and the distal end left unsutured—and the rod is then withdrawn;—(**d**) If the opening is to be temporary—the intestine is incised in its long axis—and, when the opening is ready to be dispensed with, the rod is withdrawn and the knuckle of intestine allowed to retract (no suturing to the skin having taken place)—the opening often closing of its own accord. (2) As small an abdominal incision as possible should be made, in order to lessen the chance of hernia. The higher up the abdominal wall the opening is made, the less the chance of hernia. Some surgeons make the incision parallel with the outer third of Poupart's ligament. (3) If the small intestine, mesentery, or omentum present during operation, they are pushed back into the abdomen. (4) If the sigmoid flexure cannot be located readily, it can be found by injecting water through the rectum, while the finger in the wound feels for the enlarging bowel. (5) The use of the rod, or other object, to pierce the mesentery is not absolutely necessary. The mesocolon can be sutured to the edges of the abdominal wound instead. (6) In stitching the intestine into the wound, the stitching is so done as to give the proximal part of the loop ample room, and, at the same time, make pressure upon the distal part, to prevent the passage of intestinal contents into it. (7) Sometimes the parietal peritoneum is drawn sufficiently out to be sutured to the margin of the skin around the wound, the muscle layers not being included—and the intestine is then sutured to this parietal peritoneum. But firmer union is probably secured by the principal method described above. (8) Sometimes (though hardly to be recommended) instead of making a spur, which is often inefficient, the bowel is cut through above the obstruction (when performed for that purpose) and the lower end is closed by inverting the edges of the distal end by a double row of sutures, the outer row, an overhand, continuous suture; the second, a row of Lemberts; and this end is dropped into the abdominal cavity. The edges of the proximal gut are then sutured into the abdominal wound by two tiers of sutures; the lower, of chromic gut, through the serous and muscular coats of the gut (a short distance from the edge), and peritoneum and muscles of the abdominal wound; the marginal, of silk, through all the coats of the gut, and the skin. The method, however, is not indicated when it is desirable to keep the upper end of the distal gut patulous, where drainage below is difficult.

Note.—Right Inguinal Colostomy, or Cæcostomy, is but rarely done. The contents of the ascending colon (from the nearness of the small intestine) are more liquid and less easily controlled through such a fistula or anus. The absence, or shortness, of the mesentery also makes the attachment to

the abdominal wall more difficult. The operation is, practically, done only when the site of the trouble is uncertain, the cæcum at the same time being distended,—or when, in doing a Left Inguinal Colostomy, it is impossible to find the sigmoid colon. When the operation is done at all, it is generally only a temporary fistula which is made, as, when this site is selected, it is usually an operation of emergency only. A Transverse Colostomy is even rarer.

LEFT LUMBAR COLOSTOMY.

Description.—Left Lumbar (Posterior) Colostomy consists in making an opening posteriorly through the loin, over the descending colon—extra-peritoneally. Rarely the opening is made over the ascending colon, in the right loin.

Preparation—Position.—As for median abdominal section.

Position.—Patient lies upon opposite side and near edge of table, with a hard pillow, or support, under the opposite loin, to render prominent the site of operation,—Surgeon on side of operation,—Assistant opposite.

Landmarks.—Position of descending colon—namely, a line extending vertically upward from a point about 1.2 cm. (½ inch) posterior to the center of the iliac crest to the twelfth rib—which line will about correspond with the outer border of the quadratus lumborum.

Incision.—About 7.5 to 10 cm. (3 to 4 inches) long—placed obliquely between the twelfth rib and the crest of the ilium, with its center over the center of the vertical line representing the course of the descending colon—which incision will run in the direction of a line extending from the anterior superior iliac spine to the angle formed by the twelfth rib and the outer border of the erector spinæ muscle, the incision beginning at about the outer border of this muscle. (See Fig. 434.)

Operation.—(**1**) Divide the skin and the thick subcutaneous fatty fascia, clamping all vessels. (**2**) Divide the latissimus dorsi and its aponeurosis in the posterior part of the wound—and the posterior part of the external oblique in the anterior part. (**3**) Divide the internal oblique, exposing the lumbar fascia posteriorly. (**4**) Recognize and protect the twelfth dorsal nerve and accompanying branch of the lumbar artery. (**5**) Divide the lumbar fascia and the transversalis muscle, exposing the anterior margin of the quadratus lumborum (which rarely requires division) in the posterior angle of the wound, and the transversalis fascia. (**6**) Divide the transversalis fascia, from the quadratus lumborum to the anterior angle of the wound, exposing the subperitoneal tissue—avoiding the twelfth nerve on its way from the quadratus lumborum to the transversalis muscle. (**7**) A distended colon may now protrude through the subperitoneal connective tissue into the wound—this areolar fatty tissue, often very thick and fatty, lying around the kidney, being separated by the fingers and forceps, or by a blunt dissector. If the colon does not thus protrude, insert an index-finger through this subperitoneal areolar tissue, while the parts are well retracted behind the lumbar fascia—following, with the back of the finger toward the patient's back, along the anterior surface of the quadratus lumborum, aiming for the angle between the quadratus lumborum and the psoas, toward which angle the posterior surface of the colon presents, lying anterior to the plane of the kidney, the lower portion of which (kidney) is generally felt. The finger which has passed through the subperitoneal areolar tissue and is carefully working behind the peritoneum is aided in its search by rolling the body

over toward the side of operation, while the assistant presses the anterior abdominal wall firmly, so as to aid the colon, by gravity and pressure, to fall, as it were, into the curved index-finger. The colon is generally recognized by the thickness of its wall, by the absence of the peritoneal coat, and sometimes by the posterior longitudinal band. (8) Grasp the non-mesenteric aspect of the colon with the fingers, or special forceps, and bring it out to a level with the surface—no loop being here drawn out of the wound as in the anterior operation. The colon is held in place with forceps, or traction-sutures, or temporarily allowed to fall back into place—while the excess of the abdominal wound is closed from either end—by layer suturing with chromic gut, or by mass-suturing with chromic gut, silk, or silkworm-gut, leaving just space enough for the emergence of the gut. (9) The convex dome of the gut is sutured into the lips of wound—by interrupted sutures

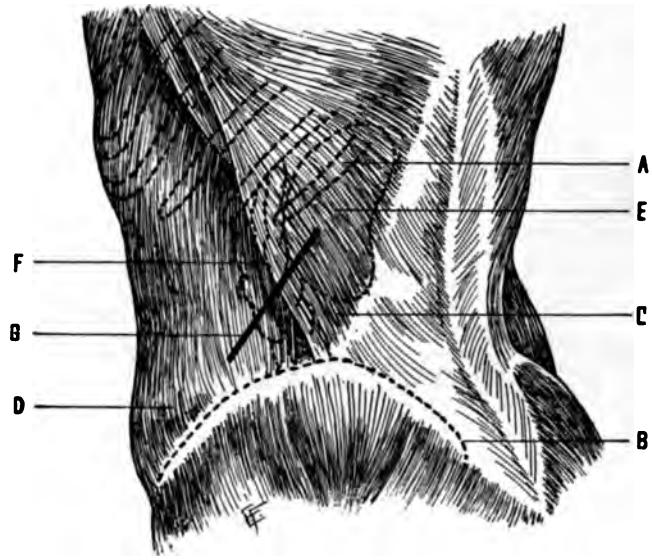

Fig. 434.—LEFT LUMBAR COLOSTOMY:—A, Twelfth rib; B, Iliac crest; C, Latissimus dorsi muscle; D, External oblique muscle; E, Left kidney; F, Descending colon; G, Line of incision for left lumbar colostomy.

of silk passing through the fibrous and muscular coats of the intestine, on the one hand, and the skin of the abdomen, or as near it as possible, on the other. (10) If haste be unnecessary—several days are allowed to pass, for union of intestine to abdominal wound to occur, and then the intestine is incised and the lips of the intestinal wound sutured to the lips of the abdominal wound—by interrupted sutures of silk, or silkworm-gut, passing through all the coats of the bowel, and through the skin of the abdomen, or as near it as possible—the sutures being passed from the skin into the gut (making infection less likely). (11) If haste be necessary—the above incision is made at once. (12) If a temporary fecal fistula be intended—the gut is incised in its longitudinal axis. (13) If a permanent artificial anus be intended—the gut is drawn as far into the wound as possible (which is never as far as in the anterior operation) and divided nearly through—the object being to form a spur as in the anterior operation.

Comment.—(1) The outer border of the erector spinæ is the superficial muscular guide to the colon. The outer border of the quadratus lumborum may be cut to expose the colon if necessary. (2) The operation is difficult in very thick loins—thorough retraction aids the steps. (3) It is important to recognize and open up the transversalis fascia—and not mistake it for the peritoneum. The bulging peritoneum has been mistaken for the colon. The duodenum has been mistaken for the ascending colon in operating on the right side—and the stomach for the descending colon in operating on the left side. The kidneys and small intestines have been mistaken for the colon. The small intestines, when encountered, lie external to the colon. The colon is generally distinguished by its longitudinal bands, anterior, posterior (at the mesocolon, when the mesentery is present), and one internal,—by its greater fixity,—and by its sacculations (often filled with scybala). The descending colon is sometimes congenitally absent. The large intestine may be distended with air or water to aid its recognition. The empty colon is often hard to detect. If all means of detection fail, do a median abdominal

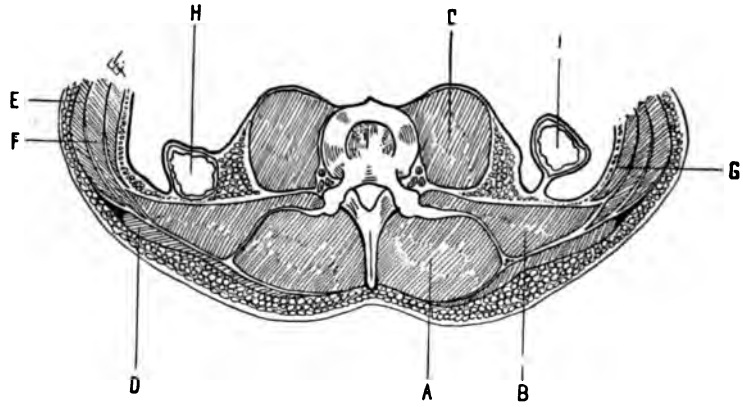

Fig. 435.—Transverse Section of the Posterior Abdominal Wall in the Lumbar Region:—A, Erector spinæ muscle; B, Quadratus lumborum; C, Psoas magnus; D, Latissimus dorsi; E, External oblique; F, Internal oblique; G, Transversalis; H, The descending colon shown in its usual position, and without a mesentery, as usual; I, The ascending colon shown with a mesentery (an exceptional occurrence). (Modified from Gray.)

section—find the bowel—and then complete the lumbar operation. (4) If the peritoneum be accidentally opened, close it by gut suture if possible. If this cannot be done, no harm is generally done by accidentally opening the peritoneum in this locality. Draw the intestine into the wound and fix it there. (5) If the mesocolon be present, the abdominal cavity must be opened, unless the laminæ of the mesentery can be split—which can generally be done. (See Fig. 435.) A branch of the inferior mesenteric artery may guide to a separation of the laminæ. (6) The non-peritoneal surface of the colon is generally thickly covered with fatty areolar tissue—which also intervenes between the colon, in front, and kidney, diaphragmatic crura, and quadratus lumborum, behind. (7) The empty descending colon is apt to tend further toward the median line, behind the border of the quadratus lumborum, than a distended one—so that, in such cases, the normal site of the distended colon is more apt to be occupied by peritoneum, which is consequently, under these circumstances, more apt to be opened. (8)

Owing to the fixity of the colon, it is often hard to get enough of it into the wound to form a spur, in the operation for artificial anus—though enough for a fecal fistula is generally to be gotten. If difficulty be experienced in causing sufficient bowel to protrude, a Paul tube may be tied into the gut, the balance of the wound being closed about it. (9) Right lumbar colostomy may be, but rarely is, performed.

OPERATION FOR THE CLOSURE OF FECAL FISTULA AND ARTIFICIAL ANUS.

Description.—Sometimes occurring alone, and sometimes as a result of the operations just described for the formation of fecal fistula and artificial anus, a more or less permanent fistulous tract between the intestinal canal and the abdominal wall is left. The simplest forms of such fistulous tracts tend to close of their own accord, but the more complicated generally require some operation for their closure. These fistulæ leading to some part of the large or small intestine are generally one of three kinds:—(1) The gut is not bent upon itself to any extent; there is no spur; but little of the intestinal wall is involved; the opening is small; the skin and intestinal mucous membrane are connected by a sinus-like communication (see Fig. 436, A);—(2) The gut is bent somewhat more upon itself; an incomplete spur is present; more of the intestinal wall has been lost; the opening is larger; the intestinal mucous membrane and the abdominal skin are more nearly in contact (see Fig. 436, B); (3) The gut is more acutely bent on itself; a marked spur is present, forming an obstruction to the intestinal passage; the amount of intestinal wall lost may be variable; the condition present generally being an exaggeration of (2) (see Fig. 436, C). The procedure for the closure of the fistulous tract will be modified, therefore, by the various degrees of fistula found and by the extent of the adjacent adhesions.

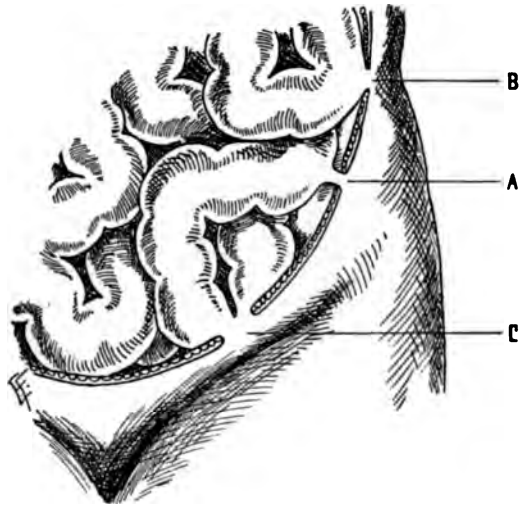

Fig. 436.—Forms of Fecal Fistulæ and Artificial Ani:—A, First form, intestine connected with skin by sinus-like communication; B, Second form, intestine and skin more directly in contact and gut slightly bent on itself; C, Third form, showing formation of marked spur.

Preparation.—Neighboring skin should be gotten as healthy as possible preliminarily. Evacuation of intestinal canal; local irrigation; vicinity of fistula shaved. Just preceding operation, sinus is to be gently scraped and again irrigated—after which it is packed with a small sponge, or with gauze, attached to a piece of silk, the end of which is left out—and the lips of the fistula are then tightly and deeply sutured and the long ends of the

sutures, after tying, are knotted, or grasped by clamp-forceps, and drawn upward.

Position.—Patient supine on edge of table nearer fistula; Surgeon on side of fistula; Assistant opposite.

Landmarks.—Site of fistula and known relation of neighboring parts.

I. Cases in which the operation involves the peritoneal cavity—no extensive adhesions existing—or where it is desired to free existing adhesions before excising the fistula:

Incision.—An elliptical incision is made around the fistulous opening—its long axis will generally be vertical in operating upon fistulæ of the small intestine, and will usually correspond with the long axis of the large gut in operating upon parts of the colon—and the length and breadth of the

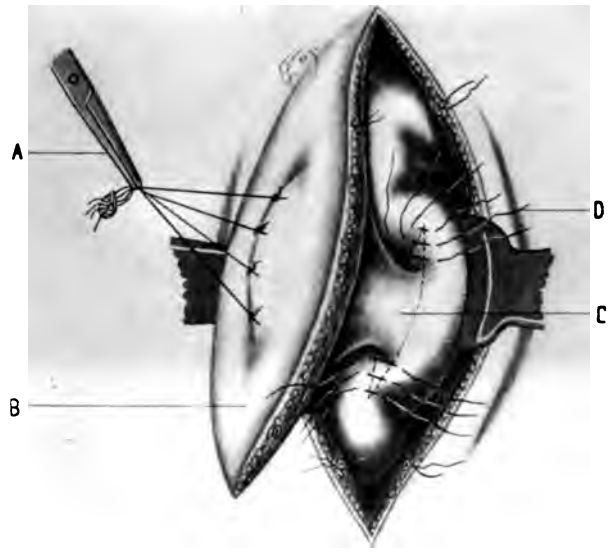

Fig. 437.—Operation for Cure of Fecal Fistula or Artificial Anus:—A, Skin opening of fistula closed by sutures used as traction-sutures; B, Ellipse of abdominal wall to be removed, with its center occupied by external opening of fistula; C, Ellipse of intestine to be removed, including neck of fistulous tract; D, Position of some of the Lembert sutures which will close in entire elliptical opening in intestine after excision of fistulous tract.

ellipse will be planned, as far as possible, to extend beyond the adhesions probably surrounding the sinus.

Operation.—(1) Having sutured the fistulous opening and using the sutures as traction-loops, this incision is carefully deepened on each side—clamping bleeding vessels—and guarding against opening the peritoneum prematurely, or cutting into an adherent coil of intestine. (See Fig. 437.) (2) In passing through the thickness of the abdominal wall, the course of the incision is directed by the sensation and form of the distended fistula and by the left index-finger within the wound. In difficult cases, and especially in devious fistulæ, it may be necessary to introduce a sound, or bougie, through the sinus as a palpable guide. (3) Having deepened the incision, all around, down to the peritoneum, the abdominal cavity is now carefully

opened in the line of the original ellipse. If the ellipse lie without the site of adhesions, no great difficulty will be experienced. If it lie in part over adhesions, a finger introduced through the site leading into the free peritoneal cavity and swept around the sinus will serve for exploration and as a guide to the separation or incision of the adherent portion. If the ellipse lie wholly over adhesions and come down upon these all around, great care is required to recognize the plane of adhesions when reached, and greater care still in separating or dividing them in the line of the ellipse. (4) Having thus reached the intestines, an isolated oval island of tissues (included in the original ellipse and in deepening the ellipse to the intestinal wall) will be evident—free above and continuous with the intestine below—through the center of which the sinus extends. The intestine is carefully freed and drawn out into the abdominal wound, with the oval island of tissues still adherent—and the neighboring parts packed off with gauze. (5) Having pressed away the intestinal contents and clamped the gut above and below the site of the sinus, a small elliptical incision is made in the gut, circumscribing the connection of the sinus with the gut, and having its long axis coincident with that of the gut—and the incision is deepened through the wall of the gut, thus excising an elliptical piece of the intestinal wall, representing the intestinal end of the sinus. The escape of intestinal contents is especially guarded during this excision. (6) The wound of the intestine is at once closed by a double row of sutures—a continuous overhand suture of all the coats, thus bringing together the free edges—followed by interrupted Lemberts of the outer coats. (7) The abdominal wound is closed in the usual manner.

II. Cases in which the operation does not involve the peritoneal cavity—extensive adhesions extending around the sinus, and it being possible to excise the fistula and close the intestinal wound without passing beyond the adhesions:

Incision.—Same in form as above, but less extensive.

Operation.—(1) The operation is conducted as above, except that care is exercised to avoid entering the abdominal cavity, which can be done only when more or less extensive and strong adhesions exist. The sinus is followed down to its intestinal end by cutting directly through all intervening tissues to the intestinal wall, which is then incised in such a way as to elliptically excise the intestinal end of the fistula—guarding against injury to neighboring coils of intestines and viscera. (2) Having excised the sinus without entering the peritoneal cavity, the borders of the wound on a plane with the upper wall of the intestine are inverted and sutured together by interrupted chromic gut or silk sutures, applied after the manner of Lembert's approximating surfaces, which, while not peritoneal, have been left raw from the excision of the sinus. The sinus is closed throughout the rest of its extent by deeply buried chromic gut sutures.

III. In other cases:—

In cases where large and obstinate spurs exist, or where there has been much loss of intestinal wall—which may be found to be the case after having exposed the parts as in the first category of cases mentioned above, a partial enterectomy may be done, followed by one of the methods of entero-enterostomy. Or the necessary calibre of intestine may be gotten by some form of "elbowing," without excision. Or junction of the involved coil of intestine with a neighboring coil may be secured by lateral anastomosis without partial excision of the intestine, after having closed the wound in the intestine left

by excision of the intestinal end of the sinus. Or, where a moderate spur exists, attempts may be made to remove the spur by means of a piece of rubber tubing introduced into the lumen of the gut and held against the spur. Formerly the use of an enterotome, whereby the spur was crushed, was much resorted to.

ENTEROPLASTY.

Description.—By enteroplasty is generally understood a plastic operation carried out for the purpose of increasing the calibre of the intestinal lumen in the case of a strictured gut—without resection of the bowel. The technic of the operation is exactly similar to that of pyloroplasty—an axial incision is made through the strictured portion of the gut and this incision is then sutured in a transverse direction. For description and illustration of the principle, see Pyloroplasty, page 789, and Fig. 473.

Note.—Other methods of increasing the calibre of the narrowed portion of intestine are employed in connection with operations of resection:—Jeannel, after partial enterectomy, cuts the ends of both pieces of intestine obliquely from above downward (the right-hand piece from right to left, and the left-hand piece from left to right)—and then unites their edges by suturing—forming an "elbow," as in the junction of pieces of stove-pipe. Chaput, after performing partial enterectomy, united the ends of the bowels by circular suturing—then made a longitudinal incision through the walls of the united intestines opposite the mesentery and sutured this longitudinal division transversely—employing, in the latter part of the operation, the principle of the usual enteroplastic operation. Chaput, by another method, completely divides the bowel obliquely, from above downward and from side to side—forming two oblique ellipses of the same size, but in opposite directions, at the ends of the intestines—followed by union of the intestinal margins.

COLOPEXY.

BRYANT'S METHOD.

Description.—In this operation some part of the colon is elevated and attached to the abdominal wall by suturing. Colopexy of the transverse colon to the anterior abdominal wall is done in some cases of Enteroptosis. Colopexy of the sigmoid flexure of the colon to the antero-lateral abdominal wall is sometimes done for Prolapsus Recti. This latter operation will be here considered.

Preparation—Position.—As for median abdominal section.

Landmarks.—Outer part of Poupart's ligament.

Incision.—About 7.5 cm. (3 inches)—parallel with and about 2.5 cm. (1 inch) above the outer part of Poupart's ligament—being extended upward if more room be necessary.

Operation.—(1) The above incision is carried down to and through the peritoneum—clamping and tying all bleeding vessels as encountered. (2) After having opened the abdominal cavity, the parietal peritoneum is separated from the edges of the abdominal wound for about 2.5 cm. (1 inch) on each side, the width of separation being somewhat greater above than below—the separated peritoneum thus forming two flaps. (3) The rectum is now pulled well upward, reducing all prolapse—and, at the same time, any adjacent laxity of the colon is pulled down. While the rectum is being drawn firmly

upward, the parietal peritoneal flaps are sutured to the serous and muscular coats of the rectum by quilting and continuous silk sutures. (4) About half a dozen silk sutures are then passed in the following order—through all the layers of the edges of the abdominal wound—through the peritoneal flap of that side—then through the serous and muscular coats of the intestine, passing behind the longitudinal band—out through the peritoneal flap of the opposite side—and then through all the tissues of the corresponding edge of the abdominal wound. These deep sutures are then drawn tight and tied—thus bringing the longitudinal band and a part of the intestinal wall into contact with the abdominal wall—and approximating the borders of the wound so that they grasp the longitudinal band and part of the wall of the gut—and, at the same time, closing the abdominal wound.

RECTOPEXY.

VERNEUIL'S METHOD.

Description.—Rectopexy, or Proctopexy, consists in the suturing of the prolapsed rectum back to its posterior bed.

Preparation.—Bowels emptied; perineum shaved; prolapse replaced.

Position.—Patient in lithotomy position; Surgeon seated in front of perineum; Assistant to one side.

Landmarks.—Anus; tip of coccyx; ischial tuberosities.

Incision.—Two straight incisions of about 2.5 cm. (1 inch) in length are made directly outward from the mid-lateral aspect of the anal orifice (at right angles to the median perineal line). Two other incisions are, later, made from the tip of the coccyx to the outer ends of the two lateral incisions.

Operation.—(1) Deepen the lateral incisions through the skin and external sphincter. (2) Deepen the posterior incisions through skin, fascia, and external sphincter, raising a triangular flap attached at its base to the tissues of the posterior aspect of the anal orifice—and displace this flap forward, and hold it out of the way by retractors or skin sutures. (3) Detach the posterior wall of the rectum, by blunt dissection, from the anus to the tip of the coccyx, and for the width of 5 to 6.5 cm. (2 to 2½ inches). (4) Pass four rather stout silk sutures transversely through the posterior wall of the rectum, going through its outer coats, for as nearly the whole width of the posterior aspect of the rectum as possible, leaving both ends of the sutures free. These sutures are parallel, the highest being opposite the tip of the coccyx, the lowest about 1.5 cm. (⅗ inch) from the anus, and the others equidistant between. (5) Pass a Reverdin needle (or other needle with eye at point) from the skin without to the denuded surface within—the punctures being made about 4 cm. (1½ inches) from the median line on each side, and above the particular thread to be drawn through—the uppermost sutures coming out through the skin on a level with the sacro-coccygeal articulation, and the lowermost opposite the tip of the coccyx. Each end of each suture is then threaded through the eye of the needle, in turn, and thus drawn through the thickness of the posterior pelvic wall. (6) The free ends of these sutures are then tied together over a firm pad of gauze (to avoid burying into and cutting the skin)—either the opposite ends of each suture being tied transversely together—or the ends of the first and second, and of the third and fourth, tied together in a vertical line on either side. Rather strong traction is made during suturing—to approximate and retain the posterior aspect of the denuded rectum in contact with the anterior aspect of the denuded pelvic

wall. (7) Suture the triangular flap back into place— narrowing, at the same time, the anus, by suturing the inner ends of the lateral incisions somewhat further inward than normal—freshening the margins of the anus sufficiently for the purpose (the original incisions may be planned with reference to narrowing the anus).

Comment.—The same object may be accomplished by Tuttle's somewhat similar operation;—and also by Peter's operation of opening the abdomen, narrowing the barrel of the rectum by invaginating a vertical strip of its anterior wall by Lemberts, and then stitching the rectum to the abdominal wall;—as well as by other procedures.

INTERNAL RECTOTOMY.

Description.—Rectotomy, or Proctotomy, consists in the division of the rectum for constriction, obstruction, or the removal of a foreign body. In Internal Rectotomy the rectum is divided from within—and is generally done for stricture of its lower part.

Preparation.—Bowels emptied; anal region shaved; and, at time of operation, gauze packing of rectum above, with end of gauze, or attached silk ligature, held ready for withdrawal.

Position.—Patient in lithotomy position; Surgeon sits opposite perineum; Assistant to one side.

Landmarks.—Anus; known course of rectum.

Operation.—Insert an anal speculum, which, when opened, will expose the site of stricture—introduce a straight, narrow bistoury through the speculum and divide the strictured site in the posterior median line until healthy tissue is reached, cutting backward from above downward—cutting through sphincters if necessary. Any vessels which bleed markedly are tied. The wound is packed—and the gauze withdrawn. Some form of dilator is worn for a time after the operation.

EXTERNAL RECTOTOMY.

Description.—In the operation of External or Posterior Rectotomy, or Proctotomy, the rectum is opened from without and from behind—generally for the removal of foreign bodies, tumors, or the division of strictures—and usually gives a fuller and higher exposure than Internal Rectotomy.

Preparation—Position.—As for Internal Rectotomy.

Landmarks.—Anus; tip of coccyx; known course of rectum.

Incision.—An external incision is made from the tip of the coccyx (or from somewhat below it, according to circumstances) down the median line to and through the anus.

Operation.—(1) The above incision is first made through the superficial parts—and all bleeding controlled. (2) A finger is then placed in the rectum, or a special guide, and upon this the whole thickness of the posterior pelvic wall, from tip of coccyx to anus, is divided. (3) Having completed the division of the rectum and accomplished the special object, the wound is treated as indicated. In cases where the operation has been for the removal of foreign body, the walls of the rectum are to be carefully brought together by suture (chromic gut)—and then the tissues between the rectum and the skin, including the latter, are brought together by silk sutures. Where the

operation has been performed for stricture, the walls of the rectum are, of course, not reunited—a light packing is placed between these to prevent their reunion—and then the tissues intervening between the intestinal wall and the skin, including the latter, are sutured with silk—leaving a temporary opening below that no accumulation of discharge within the extra-intestinal tissues may take place.

EXCISION OF THE RECTUM IN GENERAL.

Rectectomy, or Proctectomy, consists in the excision of the rectum, in whole or in part. It is generally resorted to for malignant disease, in cases where there is little or no involvement of neighboring viscera or lymphatic glands. The operation may be done through the perineum—through the sacrum—through the vagina—by the abdomen—or by the combined abdominal and perineal routes. Proctectomy may be partial or complete.

Partial Proctectomy by the perineal route is generally confined to cases in which the malignant growth is within 10 cm. (4 inches) of the anus—and, in women, in which the anterior rectal wall is not involved higher up than 7.5 cm. (3 inches). With some the indication for the perineal route is a growth within 5 cm. (2 inches) of the anus. Moderately high growths are approached by the sacral route. Very high involvements may be approached by the combined perineal and abdominal routes.

If uninvolved, the sphincters should be preserved—provided their nerve-supply, which reaches them from their lateral aspects, can be retained intact—and subsequently the proximal end of the rectum should be attached to the distal end containing the sphincters.

The division of the sacrum as high as the lower border of the third sacral foramen may be done without serious injury to, or serious functional impairment of, neighboring structures. But division as high as the third sacral foramen has been followed by paralysis of the bladder.

A wide removal of circumanal and circumrectal tissues is indicated in all malignant involvement. If involved, the prostate gland, part of the bladder, or the rectovaginal septum, should be removed.

EXCISION OF THE RECTUM BY THE SACRAL ROUTE

BY PARTIAL EXCISION OF SACRUM—KRASKE'S OPERATION.

Description.—Kraske, having incised through the soft tissues vertically downward from the second sacral spine to the anus and bared the coccyx and left lower part of the sacrum, excised the coccyx—entirely divided the sacrosciatic ligaments and completely excised the left lower portion of the sacrum along a line curving from the left margin of the sacrum (on a level with the third sacral foramen) along the lower border of the third sacral foramen to the left inferior corner of the sacrum—and thus exposed and excised the rectum.

This operation subsequently became the basis of various modifications. Hochenegg, Bardenheuer, and others have extended the line of excision transversely across the entire sacrum on a level with the lower border of the third sacral foramen. Heinecke, Rehn, Rydygier, and others converted the partial excision into an osteoplastic resection of the sacrum and coccyx—by a para-sacral incision just outside of, and parallel with, the left border of the sacrum

and coccyx, followed by a transverse division of the sacrum just below the third sacral foramen—the flap thus formed being temporarily turned aside to the right, hinging upon its partly broken and partly bent tissues—and being subsequently replaced in position.

Preparation.—(1) A preliminary left inguinal colostomy is done by many surgeons some days in advance—insuring greater cleanliness of the part during operation and the avoidance of fecal soiling for some days afterward. It is desirable in the majority of cases. Previous purgation and irrigation of the lower bowel for two or three days immediately preceding operation. (2) At the time of operation, high irrigation and swabbing out of the bowel—and often rectal packing placed high up, above the site of disease. Bladder emptied. Perineum shaved. The sphincter ani is paralyzed by digital distention.

Position.—Patient is held in the knee-chest position by means of upright supports at end of table, being suspended from these from just below the hip-joints, while the chest is supported by a cushion. The right latero-prone, or the exaggerated lithotomy, position may also be used.

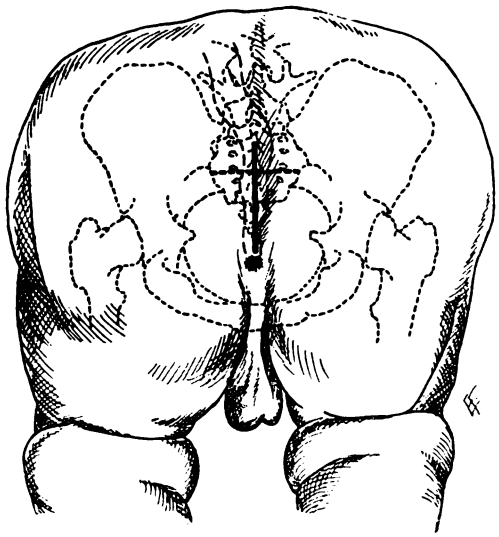

Fig. 438.—Excision of Rectum by the Kraske Operation:—Subject in knee-chest position. Skin-incision shown in median heavy line, from second sacral spine to posterior margin of anus. Bone-section shown in dotted line crossing transversely just below third sacral foramina. Position of rectum shown in dotted outline. The above line is the modification of Hochenegg and Bardenheuer.

Landmarks.—Anus; coccyx; sacral spines; posterior superior and inferior iliac spines; known course of rectum.

Incision.—In the mid-line—from the second sacral spine to the posterior margin of the anus. (See Fig. 438.)

Operation.—(1) The above incision passes directly to the bone over sacrum and coccyx—hemorrhage being controlled by clamp forceps. (2) The overlying soft parts are retracted outward to the left, exposing the left side of the sacrum and coccyx, and from the right side of the coccyx. (3) The gluteus maximus and sacrosciatic ligaments are detached from both sides of the coccyx and from the left side of the sacrum. The coccygei and part of the left pyriformis are also detached. If it be intended to remove the anus, the external sphincter and levator ani are also removed. (4) Pass a periosteal elevator beneath the sacrum (in contact with its anterior surface) and detach the soft parts from the hollow of the bone, and the sacra media vessels and venous plexus along with them. (5) The coccyx and as much of the sacrum as considered necessary are now removed. (See Fig. 439.) To accomplish this the soft parts are strongly retracted to the left and the sacrum is divided with chisel and mallet, or by very strong bone-cutting pliers, or

by Gigli saw—passing, generally, from the left edge of the sacrum on a level with a point just below the left third posterior sacral foramen, curving inward and downward directly through the left fourth posterior sacral foramen to the left lower corner of the sacrum—thus neither harming the anterior division of the third sacral nerve, nor opening the sacral canal. The hemorrhage, which is chiefly from the lateral sacral, middle sacral, and hemorrhoidal

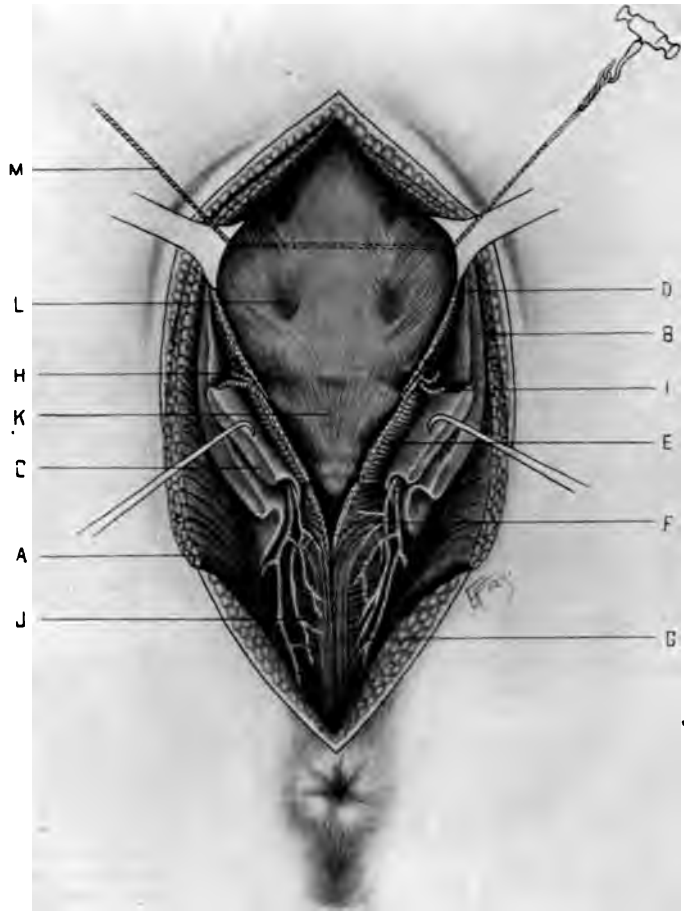

Fig. 439.—Excision of Rectum by Sacral Route—Kraske Operation:—A, Gluteus maximus; B, Great sacrosciatic ligament; C, Lesser sacrosciatic ligament; D, Pyriformis; E, Coccygeus; F, Levator ani; G, External sphincter; H, Sciatic artery; I, Internal pudic artery; J, Branches of internal pudic artery and pudic nerve; K, Coccyx; L, Fourth sacral foramen; M, Gigli saw dividing sacrum just below third sacral foramina.

arteries, and anterior and posterior venous plexus, and the bone, is controlled by pressure until the bone is removed—and subsequently by catch-forceps and ligature. (6) Having thus exposed the pelvic cavity, incise the tissues in the middle line down to and through the levatores ani, until the rectum is reached. (7) The external sphincter and anus are generally left, if the

site of involvement be as much as 2.5 cm. (1 inch) above the former. **(8)** The rectum is now "shelled out" by blunt dissection. This "shelling out" can be readily carried out behind and on the sides. The size of the rectum may prevent the passage of the finger completely around it—and the attachments of the peritoneum and mesorectum will prevent its being drawn downward very far. (See Fig. 440.) **(9)** Having thus isolated the rectum, it should be divided transversely at least 2.5 cm. (1 inch) below the lowest

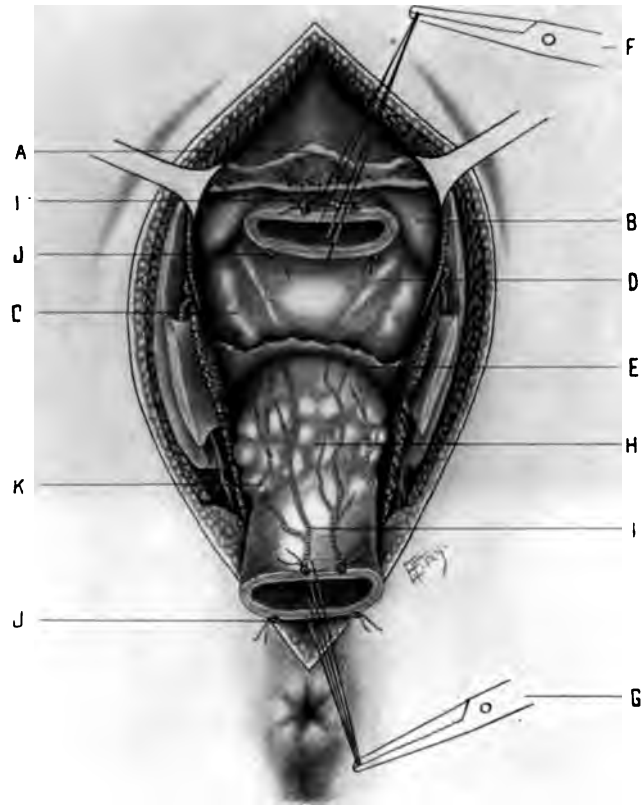

Fig. 449.—Excision of Rectum by Sacral Route (Kraske Operation)—Part of Sacrum and Coccyx Removed and Divided Rectum Turned Down:—Unlettered structures are same as in Fig. 439. A, Section of sacrum below third sacral foramina; B, Peritoneum; C, Vesiculæ seminales; D, Vasa deferentia; E, Recto-vesical layer of pelvic fascia; F, Upper end of severed rectum; G, Lower end of divided rectum retracted downward; H, Cancerous growth of rectum; I, I, Middle sacral artery and branches; J, J, Superior hemorrhoidal arteries; K, Middle hemorrhoidal artery (and same on opposite side).

margin of disease. In order to retain command of the upper end, just prior to dividing the rectum a stout circular ligature may be thrown around it just beneath the involved area—or, simultaneously with the division, sutures may be placed through the cut walls of the upper end. **(10)** The separation of the rectum is now continued by blunt dissection, guided, in the male, by a sound in the bladder, while separating the rectum from the prostate

and bladder—and, in the female, by an assistant's finger in the vagina, in separating the rectum from the vagina—controlling hemorrhage by pressure. (**11**) When the peritoneal reflection upon the anterior aspect of the rectum is reached, if it do not extend too high it may be found possible to protrude this reflection upward with the finger and thus not have to open the peritoneum. If the growth extend above the reflection, the peritoneum must be opened, and is, accordingly, freely incised. (**12**) The mesorectum and presacral areolar tissue now alone hold the rectum—and these are separated and loosened upward by blunt dissection, while the bowel is gently drawn downward. (**13**) Having freed the rectal surfaces for about 2.5 to 5 cm. (1 to 2 inches) above the growth and clamped it at this site, and having packed off the neighboring regions with gauze, it is divided at least 2.5 cm. (1 inch) above the disease—dividing the mesorectum and presacral areolar tissues on the same level. All bleeding is now controlled by clamp forceps and ligature. (**14**) If the peritoneum have been opened during operation, a small wound of the structure is to be at once sutured, with or without drainage, as indicated—a large rent may be partly sutured and partly packed with gauze, or entirely packed. (**15**) Having completed the excision of the diseased portion of rectum, controlled hemorrhage, and repaired any damage done the peritoneum, the ends of the gut are to be treated according to the circumstances of the case and the special views of the operator. Considerable difference of opinion exists as to the management of the ends of the intestine—some of the views being here summarized:—(**A**) If the Sphincters and Anus Have Been Retained;—(**a**) Direct suturing of the divided ends may be done. Kraske sutures the anterior and lateral portions by a double tier of sutures, one through the mucous membrane only, and one through all the coats—while he inverts the posterior portion by a single tier not passing through the mucous membrane. (**b**) The ends may be united by a Murphy button. (**c**) Moulouguet carefully removes the mucous membrane of the lower portion of the rectum (avoiding injury to the external sphincter)—and draws through this lower portion the upper end and sutures its borders to the border of the anus, controlled by its sphincter. (**B**) If the Sphincters and Anus be Sacrificed;—(**a**) The upper end of the divided rectum is sutured into the upper posterior angle of the wound. (**b**) Gersuny twists the upper end of the rectum upon its long axis (to give some difficulty to the fecal passage) if it be long enough, and sutures it into the skin. (**c**) Witzel draws the upper end of the rectum through a short incision just above the free border of the gluteus maximus and sutures its edge to the skin (to gain some muscular control).

Comment.—(**1**) The coccyx alone should be first removed—as that may furnish sufficient room. (**2**) The superior hemorrhoidal vessels (bifurcating from the inferior mesenteric artery in the median line between the layers of the mesorectum) run very near the muscular layer of the intestine, and by cutting in the loose areolar tissue just under the peritoneum these vessels are avoided and the upper rectum easily freed from the wall of the pelvis. The high division of these vessels is apt to be followed by necrosis of the gut. (**3**) In the male, with empty bladder, the rectovesical peritoneal reflection is generally about 7.5 cm. (3 inches) above the anus. A full bladder raises the reflection about 2.5 cm. (1 inch). The tip of the coccyx is below the level of this reflection. (**4**) The peritoneum nearly entirely surrounds the rectum at the level of the third sacral foramen, a distinct mesorectum existing—loose areolar tissue connecting the intestine to the sacrum and coccyx where the peritoneum is absent. (**5**) A truss and pad are worn

where a sacral anus is made. (6) Keen performs a preliminary inguinal colostomy, which is permanent—and closes the lower opening entirely. (7) Fig. 440 represents the complete transverse division of the sacrum.

EXCISION OF THE RECTUM BY THE SACRAL ROUTE.

BY THE REHN-RYDYGIER OSTEOPLASTIC FLAP METHOD.

Description.—See the description given under Kraske's excision of the rectum by the sacral route.

Preparation—Position—Landmarks.—Same as in Kraske's operation, above given.

Incision.—(1) An oblique parasacral incision is first made, beginning opposite the center of the sacrum, passing along just to the outer side of the left border of the sacrum and coccyx to the tip of the coccyx—and thence along the mid-line of the perineum nearly to the anus. (2) A second incision is then carried transversely across the sacrum about 4 cm. (1½ inches) above the sacro-coccygeal articulation. (See Fig. 441.)

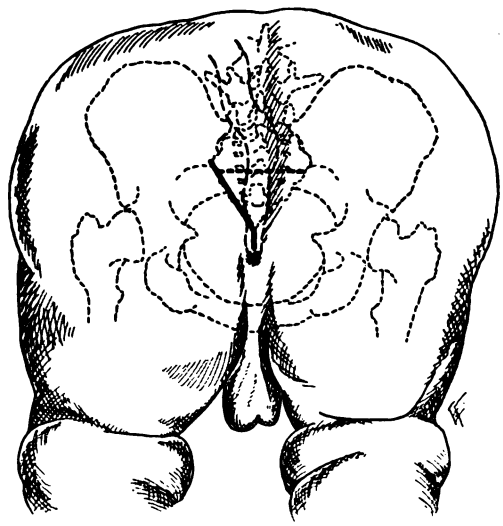

Fig. 441.—OSTEOPLASTIC RESECTION OF RECTUM BY THE REHN-RYDYGIER OPERATION:—Patient in knee-chest position. Rectum shown in outline. Skin-incision in heavy oblique and vertical line. Bone-section in transverse dotted line.

Operation.—(1) The oblique incision passes downward from the posterior superior iliac spine along the outer border of the sacrum and coccyx—the transverse incision passing at once to the sacral bone. All bleeding vessels in the lines of incision are clamped. (2) Expose and divide the gluteus maximus and the greater and lesser sacrosciatic ligaments of the left side, along the oblique incision. (See Fig. 442.) (3) The transverse incision is further deepened until the irregular depressions and elevations of the posterior aspect of the sacrum are exposed in the bed of the transverse wound. (4) By means of a curved elevator and blunt dissector the soft parts in the hollow of the anterior surface of the sacrum are raised from the bone, clearing the anterior surface of the sacrum below the level of the third sacral foramina. (5) The sacrum is now divided transversely just below the third sacral foramina by means of chisel or saw—and the osteo-cutaneous flap thus freed is then prized over to the right, hinging along a line corresponding with the right sacro-coccygeal border—and the posterior aspect of the rectum is thus exposed. All hemorrhage is now controlled by clamp and ligature before proceeding. (6) The subsequent steps of the operation are practically the same as in Kraske's operation (*q. v.*). (7) Where union between the two segments of the rectum can be accomplished at the end of the operation,

this is secured as described under Kraske's operation—followed by the reposition of the bone-flap in place and the holding of it there by the passage of chromic gut sutures through its periosteal and aponeurotic structures—accompanied by temporary gauze drainage. If union of the ends cannot be accomplished, the upper end may be brought down and anchored as low in the wound as possible, by sutures, the wound cavity packed, and no attempt made to suture the bone-flap in place. Granulation then occurs, with some retraction of the flap, but a useful result generally follows. Or, where the growth cannot be all removed, or a greater gap is left between the segments than foreseen, the bone-flap may be entirely detached and

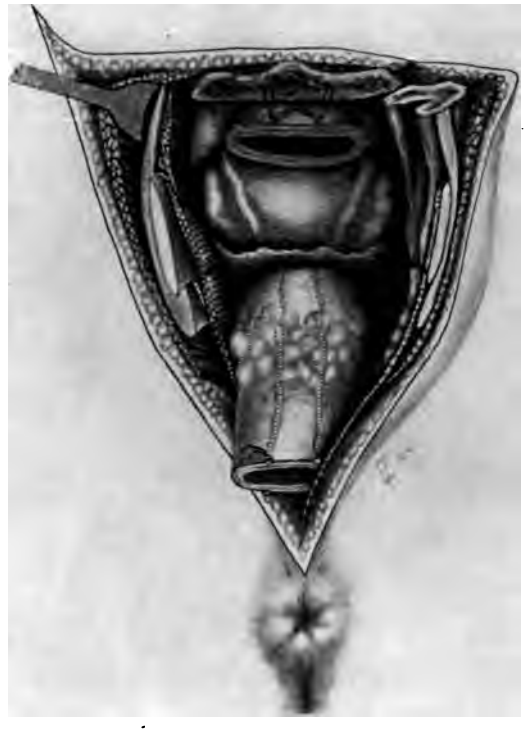

Fig. 442.—Osteoplastic Resection of the Rectum—Rehn-Rydygier Operation:—Showing flap of part of sacrum, coccyx, and overlying soft parts temporarily displaced to right. Unlettered structures are same as in Figs. 439 and 440.

discarded (constituting a sacral excision of the lower portion of the bone) and the upper end of the gut anchored in the upper angle of the external wound—which is then closed throughout the balance of its extent, except at the site where drainage is established.

Comment.—The osteoplastic method of exposing the rectum is preferable where it is possible—but if the flap of bone be in the way of the operation itself, or in the way of the subsequent management of the case, it should be removed—and the operation converted into a partial excision. The temporary bony resection preserves the posterior support of the levatores ani.

It probably does not furnish quite as much room as the method by partial excision; the bone-flap may necrose; there is no room for a sacral anus, where this is indicated, except by total or partial removal of the bone-flap.

EXCISION OF THE LOWER PART OF THE RECTUM BY THE PERINEAL ROUTE.

Description.—The excision of the lower portion of the rectum by the perineal route is usually confined to cases in which the cause of removal is within finger's reach of the anus.

Preparation.—Purgation; irrigation of the lower bowel; rectal packing; bladder emptied; perineum shaved.

Position.—Patient in exaggerated lithotomy position, or in Sims' position. Surgeon standing, or sitting, in front of perineum.

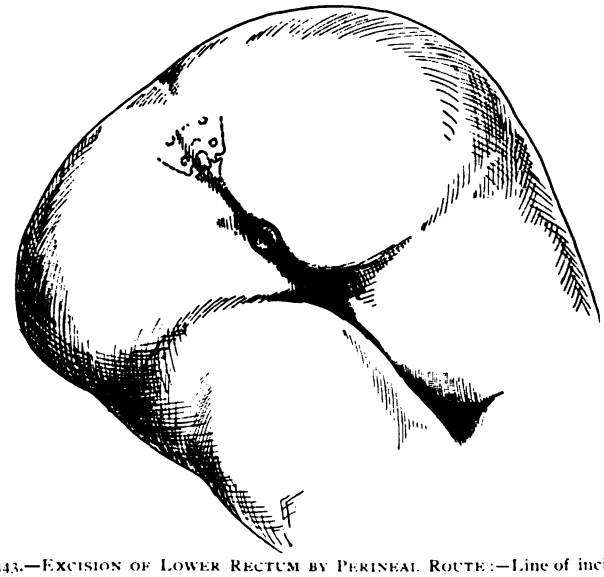

Fig. 443.—Excision of Lower Rectum by Perineal Route:—Line of incision.

Landmarks.—Anus; tip of coccyx; and, later, position of bladder, prostate, vagina, and rectum.

Incision.—Two lateral oval incisions are made—almost, but not quite, meeting in front of the anus—being continued backward around the sides of the anus in the ilio-rectal fossæ to meet behind the anus—and prolonged thence in the mid-line to the tip of the coccyx. (See Fig. 443.)

Operation.—(1) The incision passes directly into the ilio-rectal fossæ—and is followed by blunt dissection (with finger and blunt dissector) of the lower end of the rectum up to the levatores ani—the bleeding being controlled by catch-forceps and gauze-mops upon sponge-holders pressed into the wound. (See Fig. 444.) (2) In the male, guided by the sound in the bladder, the rectum is carefully separated from the bladder, prostate, and urethra, to which it is rather closely adherent. The index-finger of an assistant in the rectum, with thumb toward bladder, aids the surgeon in this separation,

(3) In the female, an assistant's index in the vagina aids the operator in separating the rectum from that organ. (4) Guard against opening the reflection of peritoneum—and, if opened, suture at once, if small—and pack with gauze, if the opening be large. (5) The levatores ani are now divided—and the rectum thus freed everywhere but above. All bleeding vessels are clamped or ligated before beginning the freeing of the rectum. (6) During gentle downward traction of the bowel it is further freed by blunt dissection and scissors. Having clamped the bowel above (to retain control and also

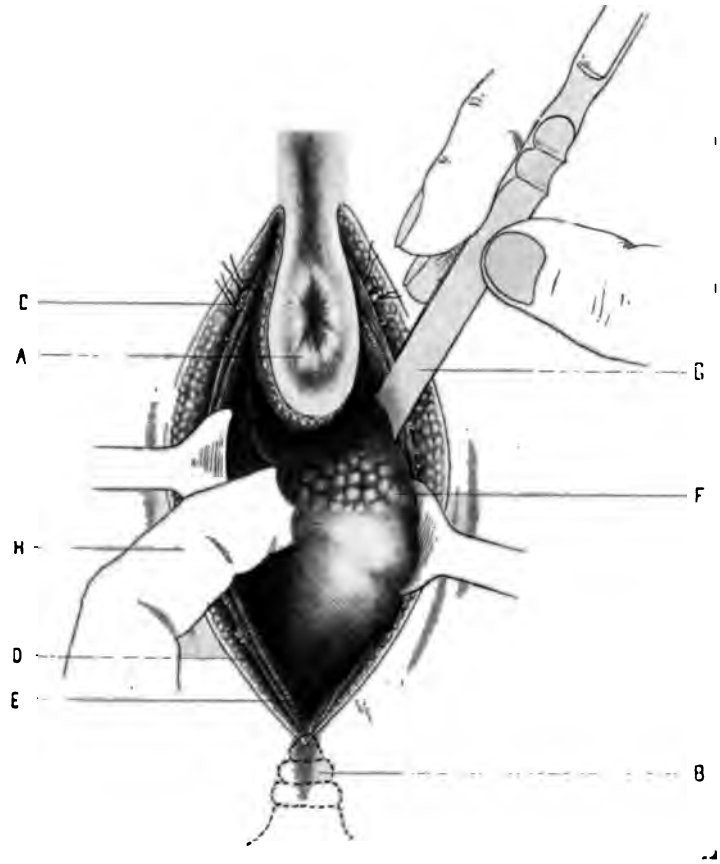

Fig. 444.—Excision of Lower Rectum by Perineal Route:—A, Anus; B, Coccyx; C, Margin of wound, showing transverse perineal vessels anteriorly, and inferior hemorrhodal vessels posteriorly; D, External sphincter; E, Levator ani; F, Rectum being freed by blunt dissector (G) and by traction with finger (H)—(Cancerous growth is shown at toughened portion of rectum).

to avoid soiling), it is divided transversely about 2.5 cm. (1 inch) above and below the growth. Where possible, the sphincters and anus should be preserved. (7) All hemorrhage having been controlled, the question of the management of the ends of the intestine must be decided: —(a) Where the Sphincters and Anus are Left; - The upper end is brought down and sutured to the lower by one of the methods of entero-enterostomy; (b) Where the

Sphincters and Anus are Removed;—The upper end may be displaced backward and sutured between the levatores ani in the position of a subcoccygeal anus—the wound in front being closed by deep and superficial sutures, the deep sutures including the levatores ani so as to form a sphincteric anus.

OPERATION FOR THE CURE OF HEMORRHOIDS BY LIGATION AND EXCISION.

ALLINGHAM'S METHOD.

Description.—Consists in the isolation and freeing of the pile by dissection, until its true pedicle is reached—around which pedicle a ligature is placed and the pile cut off below it. This form of operation is especially indicated in isolated piles, and particularly those of columnar outline.

Preparation.—Purgation; rectal irrigation; circum-anal region shaved; dilatation of anus immediately preceding excision.

Position.—Patient in lithotomy position at end of table; Surgeon seated opposite perineum; Assistant to surgeon's side. Patient may lie upon side, with knees drawn up.

Landmarks.—Anus; hemorrhoidal tumors.

Operation.—(1) For the purpose of dilating the anal orifice, both thumbs, lubricated, are inserted into the bowel, knuckle to knuckle—and, grasping the ischial tuberosities on each side with the fingers, the surgeon carefully and slowly separates the thumbs to the desired extent, consuming about two minutes in the process. (2) Having thoroughly dilated the anal orifice, the interior of the lower rectum is examined with the index-finger, and the number, nature, and position of the hemorrhoids determined. (3) Beginning with those upon the lower, posterior aspect (that bleeding may not obscure the operation), each pile is seized with toothed forceps and drawn downward and away from its attachment, putting this attachment upon gentle stretch. (4) While the pile is thus held, a pair of blunt-pointed scissors (straight or curved, as more convenient) is made to dissect the pile up from the subcutaneous tissue by limited snips, beginning below at the line of mucocutaneous junction and proceeding upward in the long axis of the bowel, until a point is reached where the pile is attached by the normal mucous membrane and by its blood-vessels, which now form its pedicle. Up to this stage but few vessels have been encountered and but little bleeding occurs. (5) While the pile is thus held by an assistant, a friction-knot of chromic gut is thrown around the pedicle of the pile and pushed as high up as possible—this friction-knot is drawn tight and a second knot is added. (6) The hemorrhoid is then cut off, with scissors or knife, just far enough below the ligature to insure its retention. This procedure is repeated upon as many piles as are present. (See Fig. 445, A and B.)

Comment.—(1) Piles are classed as "External," below the pressure of the external sphincter;—"Internal," above the pressure of the external sphincter;—"Interno-external," partly above and partly below the grasp of the external sphincter. (2) The vessels which supply hemorrhoids come from above and run just under the mucous membrane, entering the upper portion of the pile—which facts have a direct bearing upon the manner of partially separating hemorrhoids preparatory to ligation or excision. (3) Where closely placed piles form more or less of a circle around the anus, they are separated by incisions made through the mucous membrane, and then each pile is ligated separately, as above described. (4) It is par-

ticularly important to include no part of the skin within the grasp of the ligature, as much and prolonged pain, from the inclusion of nerve filaments, may follow. Such inclusion is impossible if the ligature be not applied until the pile is freed up to its natural pedicle (5) It is well to suture up with fine catgut the furrows in the submucous tissue left by the snips of the scissors in dissecting the hemorrhoid from its bed. (See Fig. 445, C.)

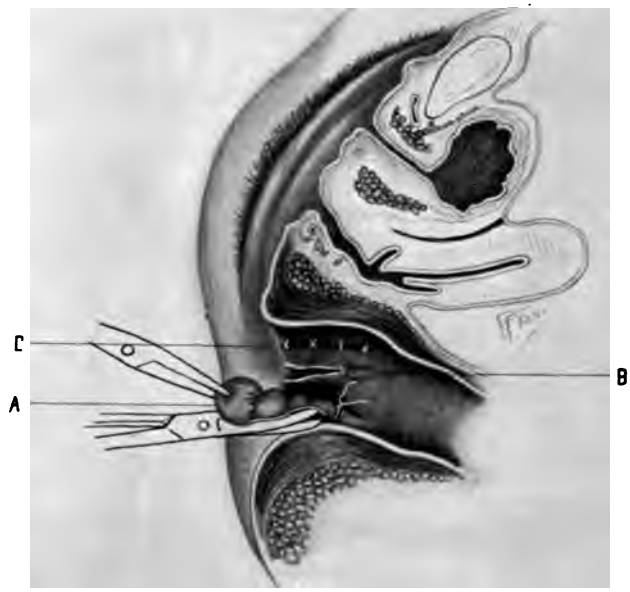

Fig. 445.—Operation for Hemorrhoids by Ligation and Excision:—A, Hemorrhoid excised from its bed and ligature thrown around its pedicle; B, Tract left to granulate after the ordinary operation of removal by ligation and excision; C, Former tract, left after ligation and excision, sutured so as to approximate edges and promote primary union.

OPERATION FOR THE CURE OF HEMORRHOIDS BY EXCISION.

WHITEHEAD'S OPERATION.

Description.—Consists in the excision of the pile-bearing segment of mucous membrane, together with its piles—followed by the immediate suturing of the divided mucous membrane above to the skin below. This form of operation is especially indicated in those cases of hemorrhoids where a circle of large and irregular piles more or less completely surrounds the anal orifice.

Preparation—Position—Landmarks.—As in the operation by ligation above described.

Operation.—(1) Having dilated the anal orifice, as described under the ligature operation, the pile-bearing segment of mucous membrane is seized with forceps and put upon gentle stretch. (See Fig. 446.) (2) While thus held, and beginning at the lowest portion of the circle and proceeding, *pari passu*, up the two sides, the mucous membrane is divided with scissors exactly along the muco-cutaneous line—passing entirely around the circumference of

the anal opening and accurately following in and out along every irregularity of the skin. (3) Working by rapid dissection along the submucous plane with the closed end of blunt scissors, the external sphincter is first exposed and then the beginning of the internal sphincter—and the mucous membrane, with the attached hemorrhoids, separated from their bed of submucous tissue, are drawn down below the skin margin—all restraining points of connective tissue being divided. (4) The mucous membrane just above the hemorrhoids is now cut transversely, a small extent at a time—and the limited part of the mucous membrane thus freed above is immediately stitched with silk to the free border of skin below, which has been divided along the muco-cutaneous line of the primary incision. Following this, another area of mucous membrane is cut free above—and at once sutured

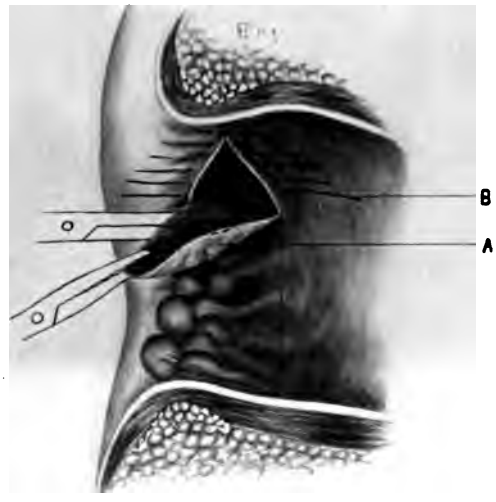

Fig. 446.—WHITEHEAD'S OPERATION FOR HEMORRHOIDS:—A, Pile-bearing segment of mucous membrane being dissected away with scissors, while held upon the stretch with forceps; B, Sutures approximating mucous membrane above, to skin below.

to the skin below—and thus on around the circle—until the circumference of pile-bearing mucous membrane is removed.

Comment.—All bleeding vessels are controlled, by Whitehead, by torsion during these steps. The chief hemorrhage tends to come from the vessels divided in the transverse division of the mucous membrane and pedicle of the pile above—and this bleeding is largely controlled by the immediate suturing of the free border of the mucous membrane to the free margin of the skin. There is no reason why fine catgut ligatures should not be used where considered necessary.

OPERATION FOR THE CURE OF HEMORRHOIDS BY THE CLAMP AND ACTUAL CAUTERY.

Description.—Consists in the cauterizing, at red heat, of the hemorrhoidal growth—while held in the grasp of special clamp-forceps. This

form of operation may be applied to piles in general—but is more especially indicated in simple venous piles of medium size.

Preparation—Position—Landmarks.—As in the ligature method.

Operation.—(1) Having dilated the anus, each pile in turn, or a cluster of piles, is seized with toothed forceps and drawn downward and away from its attachment. (2) Divide the muco-cutaneous border, if there be one, with blunt-pointed scissors or knife (that nerve-filaments may not be included in the grasp of the clamp). (3) Apply the clamp, with the pile still under gentle traction, to the base of the tumor, and in the axis of the gut—the clamp resting in the cut groove at the muco-cutaneous border, if the pile be one having a cutaneous part. The blades are then screwed together sufficiently firmly to thoroughly compress the parts. (4) With a pair of curved scissors, cut away the excess of hemorrhoid which projects above the clamp. Then, with a Paquelin or other cautery at red heat, slowly and thoroughly cauterize the stump of the pile. As the clamp is loosened, follow down the escaping pile-stump with the point of the cautery—seeing that all hemorrhage is controlled. If necessary to make the hemostasis complete, the stump may be again clamped and again cauterized. This process is repeated until all the piles or clusters have been cauterized.

Comment.—Where the piles are in the form of a more or less complete circle surrounding the anus, they should be divided into segments or groups by incision of the mucous membrane prior to clamping and cauterizing. Avoid burning the skin—or detaching the eschars, thereby favoring hemorrhage.

OPERATION FOR THE CURE OF FISTULA-IN-ANO BY INCISION.

Description.—Consists in the laying open of the fistulous tract upon a grooved director—followed by the curettage of the sinus-walls—and light gauze packing of the raw bed to promote healing from the bottom and obliteration of the fistula,—or excision of tract with suture of its bed.

Preparation.—Purgation; rectal irrigation; shaving of circum-anal region; dilatation of the sphincter just before operation, in the more complicated cases.

Position.—Patient in the lithotomy position, with nates over the end of the table; surgeon sitting opposite the perineum.

Landmarks.—Anus; rectum; course of fistula and position of openings determined in advance, if possible.

Operation.—(1) A grooved director is passed through the sinus, from its skin opening—made to traverse its length and emerge through its internal opening within the bowel—and the end of the director is then caused to project through the anus by directing its tip with the left index-finger within the rectum, while its handle is depressed with the right hand. The external and internal openings of the fistula are then in plain view—with the grooved director passing through its entire length. (See Fig. 451, A.) (2) Upon the grooved director a narrow, pointed knife is passed (or a probe-pointed bistoury may be used) with its cutting-edge directed outward—thus incising the fistula throughout its entire course—freeing the grooved director and allowing the parts to recede into their normal positions. (3) The lips of the wound and of the sinus are then separated by the operator's left thumb and index—and, while thus exposed, the entire extent of the fistula should be scraped with a curette, so as to remove its old wall—and then lightly packed with gauze and allowed to heal from the bottom. A T-bandage

keeps the dressing in place. The bowels are usually kept constipated for a few days.

Comment.—(1) Fistulæ-in-ano are generally one of three types;—"Complete"—"Incomplete Internal"—"Incomplete External." In addition, fistulæ may have several openings;—and they may have irregular forms, as, for example, the "horseshoe" type. (See Figs. 447 to 450.) (2) If the grooved director does not pass readily, a probe may first find the way—and the director passed along this—and the probe then withdrawn. (3) If the grooved director, or probe, cannot be made to find an internal communication with the bowel, but nevertheless comes very near the mucous membrane, it may be forced the remaining distance, provided this distance be short. (4) If the end of the director cannot be brought out through the anus, a narrow, probe-pointed bistoury may be passed along it and the director

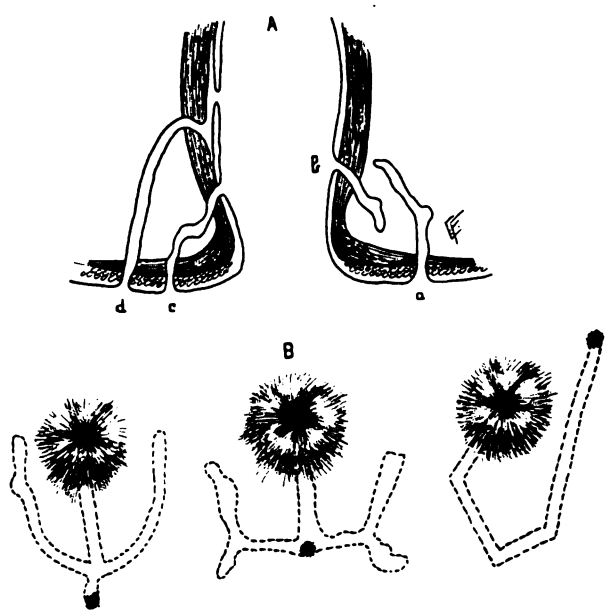

Figs. 447-450.—Forms of Fistulæ-in-ano:—A, Rectum in vertical section; *a*, Incomplete external fistula; *b*, Incomplete internal fistula; *c*, Complete fistula; *d*, Irregular complete fistula. B, Surface view of fistulous tracts, showing various irregular forms of fistulæ and diverticula—their external openings being marked by a star.

withdrawn—and then the end of the probe-pointed bistoury is pressed against the surgeon's left index-finger (or a special piece of wood) introduced within the rectum—and finger and knife simultaneously withdrawn—the knife cutting the intervening soft parts through in its withdrawal. Or one blade of a pair of scissors may be passed along the director and the sinus thus laid open. (5) In incomplete internal fistulæ, the internal opening is found through a speculum—a bent probe passed along the sinus—and an external opening made where thus indicated—after which the operation is completed as in a complete fistula. (6) In incomplete external fistula, if the inner end be very near the mucous membrane, a director is protruded through the sinus into the bowel, forcing its way through the thin barrier—after which the operation is completed as in the complete fistula. If, on the other hand, the inner

opening be not connected with or near the bowel, the entire tract must be laid open from without. (7) If the fistula extend high up along the bowel, judgment must be exercised as to what extent cutting is necessary, and to what extent dilatation and scraping will suffice. (8) In "horseshoe" fistulæ (an external opening on each side of the anus leading to a single internal opening, generally upon the posterior rectal wall) the bowel function is less

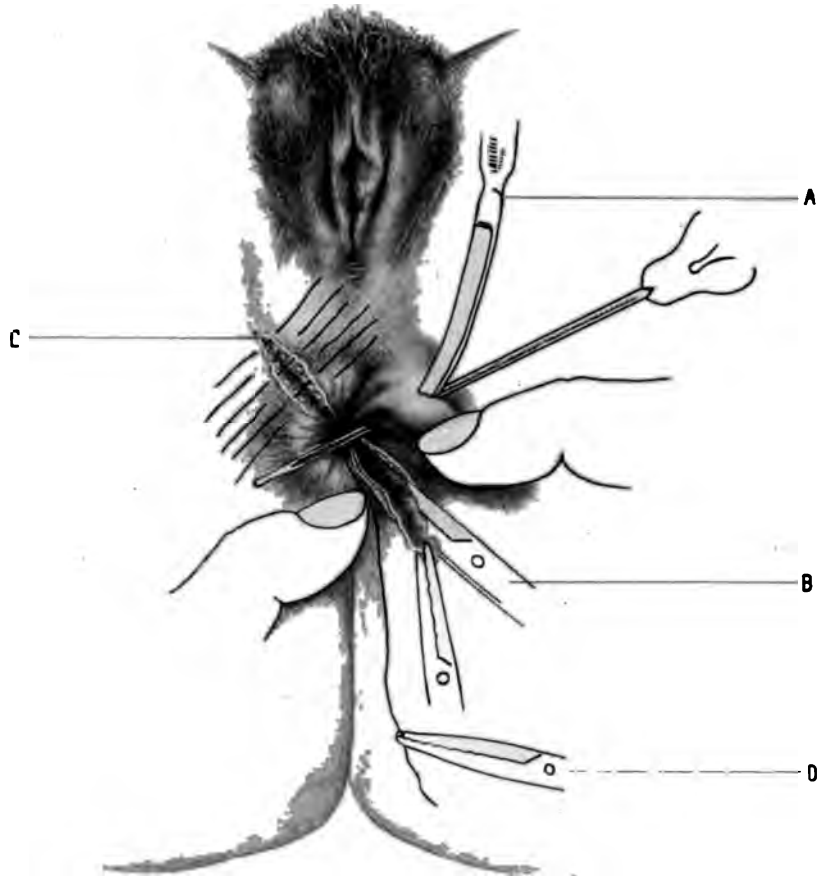

Fig. 451.—Operation for Cure of Fistula-in-ano by Incision and Excision:—A, Bistoury in act of dividing fistula upon grooved director; B, Fistulous tract being excised by curved scissors, while steadied with forceps; C, Suturing of bed of sinus after its excision; D, Ligature attached to gauze tampon in rectum, to control contents.

apt to be interfered with if the sphincter be cut on one side only (and at right angles to the anal orifice) and the opposite part of the fistula be dilated, scraped, and drained from the first side. (9) Search should always be made for secondary fistulæ running off from the main one, and these likewise laid open and curetted—or dilated and scraped. (10) The internal sphincter should not be divided if it can be helped. If it be necessary to incise the

internal sphincter, the division should be at right angles to its fibers at the site of section (that repair may be more complete, and subsequent functioning). And it is preferable not to divide the internal sphincter in more than one place at a time (for the same reasons). (**11**) Whatever hemorrhage occurs, which is generally slight, is ordinarily controlled by gauze packing—but gut-ligaturing may be used where necessary. (**12**) In appropriate cases the entire fistulous tract may be dissected out—and the raw edges thus left be brought together by superficial and deep chromic gut sutures—thus at once obliterating the site of sinus and inviting primary union. This method is preferable to simple incision wherever applicable. (See Fig. 451, B and C.)

VI. THE STOMACH.

SURGICAL ANATOMY.

Description.—Lies in epigastric and left hypochondriac regions—being about five-sixths to left and one-sixth to right of median line;—lying under the liver and diaphragm,—above the jejunum, ileum, and transverse colon (also upon the transverse mesocolon, which intervenes between it and pancreas, abdominal vessels and solar plexus),—and between gall-bladder on right and spleen on left.

Relations.—Anteriorly and superiorly: diaphragm; thoracic wall (anterior portions seventh, eighth, and ninth ribs); left and quadrate lobes of liver; anterior abdominal wall; lesser omentum. **Posteriorly and inferiorly:** diaphragm; crura of diaphragm; aorta and inferior vena cava; first lumbar vertebra; cœliac axis; lesser peritoneal sac; splenic flexure of colon; transverse colon; transverse mesocolon (superior layer); spleen (gastric surface); left kidney and suprarenal capsule; pancreas; splenic vessels; duodenum fourth, or ascending portion); solar plexus. **Right end:** transverse colon; inferior surface of liver. **Left end:** spleen; diaphragm.

Position of Cardiac End (Fundus).—Reaches up to the left sixth chondro-sternal articulation, or fifth rib in mammary line, and to cupola of diaphragm;—slightly above and behind the heart apex;—and 3 to 5 cm. ($1\frac{1}{4}$ to 2 inches) higher than the cardiac orifice of the stomach.

Position of Cardiac Orifice.—Opposite left seventh chondro-sternal articulation, about 2.5 cm. (1 inch) from sternum;—also on level with ninth dorsal spine (left side of eleventh dorsal vertebra). Lies from 2 to 3 cm. ($\frac{3}{4}$ to $1\frac{1}{4}$ inches) below the esophageal opening, and about 7.5 cm. (3 inches) from the left extremity of the stomach,—and 11 cm. ($4\frac{1}{4}$ inches) from the anterior abdominal wall.

Position of Pylorus.—On level with bony ends of seventh ribs (which are 5 to 7.5 cm., or 2 to 3 inches, below the sterno-xiphoid joint), lying to right of median line and nearer the surface than the cardiac end;—also on level with twelfth dorsal spine (upper border of first lumbar vertebra).

Fixation Points and Ligaments of Stomach.—Bound to diaphragm by esophagus;—bound to vertebral column by duodenum;—ligamentum phrenico-gastricum connects cardia to diaphragm;—gastro-hepatic omentum (lesser omentum) connects lesser curvature to liver;—ligamentum hepato-duodenale connects pylorus and duodenum to liver;—gastro-splenic omentum binds greater end of stomach to spleen;—great omentum binds the stomach only when itself is bound.

Peritoneal Coverings.—Everywhere—except along the upper and lower curvatures, and upon the triangular areas at either end.

Arteries.—Gastric; pyloric and right gastro-epiploic branches of hepatic; left gastro-epiploic and vasa brevia of splenic.

Veins.—Coronary and pyloric, emptying into portal vein; right gastro-epiploic, emptying into superior mesenteric; left gastro-epiploic, emptying into splenic.

Nerves.—Right vagus (posterior surface); left vagus (anterior surface); solar plexus of sympathetic system.

Lymphatic Glands.—Along greater and lesser curvatures—and at pyloric and cardiac ends.

SURFACE FORM AND LANDMARKS.

Stomach when empty—lies far back in the abdominal cavity, beneath left lobe of liver and in front of pancreas.

In moderate distention—Cardiac end lies beneath left seventh chondro-sternal articulation, about 2.5 cm. (1 inch) beyond the sternum. Pyloric end lies opposite a point near end of eighth right chondro-costal articulation.

Borders (curvatures) of stomach are represented approximately by curves of the characteristic contour between the points just given—the greater curvature reaching at first to the left, then downward to the infracostal line. The lesser curvature crosses the vertebral column on a level with the first lumbar vertebra. The greater curvature crosses the epigastrium on a line connecting the ninth and tenth costal cartilages—which is about two finger-breadths above the umbilicus.

Gastric fossa—a triangular area of about 40 square centimeters (15½ inches) of the anterior wall of the stomach where it lies in direct contact with the abdominal wall—bounded, below, by the transverse colon; above and to left, by seventh, eighth, and ninth costal cartilages; and above and to right, by the anterior border of the liver.

GENERAL SURGICAL CONSIDERATIONS IN OPERATIONS UPON THE STOMACH.

Stomach may be recognized by its relation to the inferior surface of the liver—by its continuity with the anterior layer of the gastro-hepatic omentum—by its thick and stiff wall, as determined by pinching it up between the fingers—by the direction of its vessels—and by its pinkish-white color and absolute opacity. The stomach and transverse colon have been mistaken for each other. The transverse colon should be displaced downward and the liver upward—revealing the stomach between them. If not otherwise recognizable, follow back the under surface of the liver to the portal fissure, with the index-finger—thence downward along the gastro-hepatic omentum to the stomach.

Anterior gastric wall lies in the greater peritoneal cavity—and its posterior wall in the lesser cavity.

Superior wall of the transverse colon lies in the lesser peritoneal cavity—and its inferior wall in the greater cavity.

Mesentery descends downward and forward from under the back part of the transverse mesocolon. The omentum major descends from the greater curvature of the stomach and inferior aspect of the transverse colon—and

may contain a cavity and be continuous with the omentum minor above the transverse colon—but its component layers are more generally united. The omentum can be more conveniently displaced upward and to the left.

Note.—Other general surgical considerations will be mentioned under special classes of gastric operations.

INSTRUMENTS.

Scalpels; straight and blunt-pointed bistouries; scissors, curved and straight; dissecting and toothed forceps; tenacula; artery-clamp forceps; various retractors; large gauze pads; broad spatulæ; intestinal clamps; stomach clamps; Murphy button; sponge-holders; volsella; stomach-tube; rubber tubing (for gastrostomies); needles, curved and straight; needle-holders; sutures, silk and gut; ligatures, silk and gut; ligature-carrier, wound-hooks.

INTRODUCTION OF STOMACH-TUBE.

Description.—The passage of a hollow tube down the esophagus and into the stomach—for the purpose of removing fluid from, or injecting fluid into, the stomach.

Position.—Patient sits upright in chair or in bed—head thrown backward (preferably steadied by an assistant)—mouth gagged (preferably, but not necessarily)—napkin placed over tongue to enable it to be more easily grasped; —Surgeon stands in front.

Operation.—The surgeon depresses the base of the tongue with the left index-finger, and, at the same time, draws it forward—this finger thus also guarding the larynx. The tube, previously warmed and lubricated, and held in the fingers of the right hand, is guided along until it impinges upon the posterior wall of the pharynx, when it is directed downward. The esophagus once entered, the tube is gently pressed further downward, aided by the act of swallowing, until it has entered the stomach.

Comment.—In the average adult, the distance from the upper incisor teeth to the superior end of the esophagus is given as 14 cm. (5½ inches);—from the same point to the arch of the aorta, as 23 cm. (9 inches);—and from the same point to the diaphragmatic opening, as 37 cm. (14½ inches). Pouches and diverticula of the esophagus are to be avoided.

GASTROTOMY

BY MEDIAN INCISION.

Description.—Consists in the temporary opening of the stomach by incision, followed by its closure at the same operation. Generally resorted to for removal of foreign bodies, for exploration, or for treatment of surgical conditions of the stomach, pylorus, or esophagus (such as gastric ulcer, dilatation of the esophageal or pyloric orifice, dilatation of the esophagus, etc.). The opening may be made in the median line, or below and parallel with the left costal arch. As far as possible, transverse division of muscles and injury to nerves should be avoided.

Preparation.—Stomach washed out.

Position.—Patient supine; Surgeon to patient's right, cutting from above downward; Assistant opposite.

Landmarks.—Linea alba; xiphoid cartilage; umbilicus.

Incision.—In the median line—its center being about opposite the space between the eighth and ninth costal cartilages—and extending to or toward the tip of the xiphoid cartilage above, and to or toward the umbilicus below, as far as the circumstances of the case require—generally being from 5 to 10 cm. (2 to 4 inches) long. (Fig. 452, A.)

Operation.—(1) The steps of the operation, up to entering the peritoneal cavity, are exactly similar to those for median abdominal section (see page 631). (2) The edges of the abdominal wound are now well retracted and the stomach sought—the steps for its recognition being given under General Surgical Considerations. While searching for the stomach, which is often not easily located, temporary silk sutures, or traction-ligatures, may be

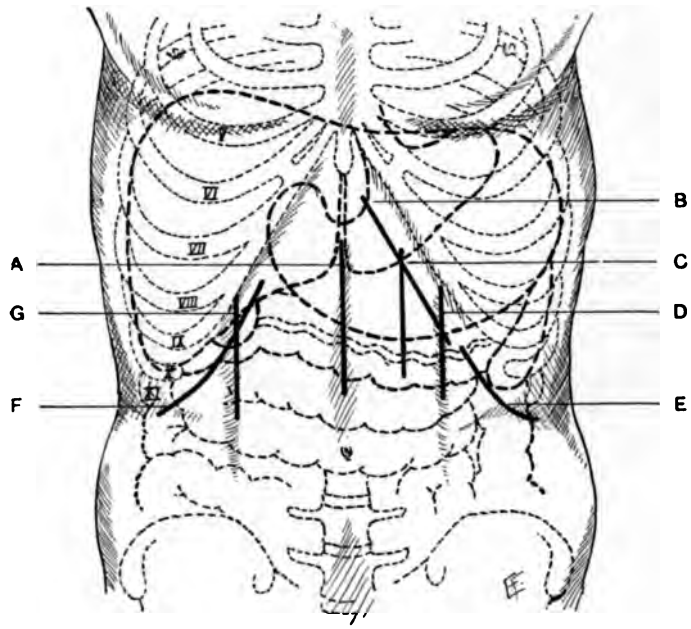

Fig. 452.—Incisions for Exposing Stomach, Liver, Gall-bladder, and Spleen:—A, Median, for stomach, liver, or spleen; B, Oblique subcostal, for stomach; C, Vertical over outer third of left rectus, for stomach; D, Vertical subcostal in left linea semilunaris, for spleen; E, Oblique subcostal, for spleen; F, Oblique subcostal, for liver and gall-bladder; G, Vertical subcostal in right linea semilunaris, for liver and gall-bladder. (Modified from Gray.)

placed through the entire thickness of each abdominal lip—partly to serve as retractors, and partly to prevent the separation of the peritoneum from the abdominal wall. (3) Having located the stomach, that portion of its anterior wall into which the incision is to be made must be isolated and drawn out of the wound by means of the fingers or special traction-forceps, the general peritoneal cavity being packed off with gauze. The site of the opening into the stomach will depend largely upon the site of the foreign body, or upon the special object of the operation. (4) An assistant grasps the anterior stomach-wall toward either side of the retracted abdominal wound, between his thumbs and fingers, steadying and spreading out that surface—or temporary silk traction-sutures may be passed, with curved

needle, into the stomach-wall, without entering its cavity—thus exposing an area of about 5 to 7.5 cm. (2 to 3 inches) of the anterior stomach-wall. (5) This area having been put upon the stretch, an opening of about 3.7 to 5 cm. (1½ to 2 inches) is made in the vertical axis of the stomach, parallel with the blood-vessels—or it may be made parallel with the long axis, avoiding large vessels. This opening may be made by a quick, controlled stab of a narrow, sharp bistoury, penetrating all the coats, and then enlarging with blunt-pointed bistoury—or it can be more deliberately made by a pair of scissors, picking up a fold of stomach-wall and cutting through at right angles to the fold. (6) Two temporary traction-sutures are at once placed in the opposite lips of the stomach wound, to hold them in control, and to enable the interior of the stomach to be exposed by retraction of its walls. The stomach opening may be enlarged if necessary. Clamp and twist all bleeding vessels, carefully isolating and ligating with gut any requiring ligature. If indicated, the stomach may be washed out, thoroughly protecting the abdominal cavity from soiling. (7) The object of the operation is now accomplished. The stomach-wall is then sutured in the manner described under Gastrorrhaphy, page 765,—with a tier of sutures through the mucous coat, and an overlying tier of Lemberts through the outer coats—using, preferably, fine chromic gut. The stomach is then dropped back into place and the abdomen closed in the usual fashion.

Comment.—Where the cardiac end of the stomach is the special site sought, it is more conveniently reached by an oblique subcostal incision (*q. v.*). The above incision is the best for the pyloric end, and for all other portions of the stomach except the cardiac end—and for general exploration and most foreign bodies.

GASTROTOMY

BY OBLIQUE SUBCOSTAL INCISION.

Description.—The stomach is opened by an incision parallel with and below the left costal arch—which more conveniently exposes the cardiac end of the stomach and the cardiac orifice of the esophagus.

Preparation—Position.—As for Median Gastrotomy.

Landmarks.—Xiphoid cartilage; left costal arch.

Incision.—Begins near the tip of the xiphoid cartilage and extends thence downward and outward, parallel with and about 2.5 to 3.7 cm. (1 to 1½ inches) to the inner side of the left costal arch, ending about opposite the anterior end of the ninth rib,—generally extending for a distance of 5 to 7.5 cm. (2 to 3 inches), varying with the thickness of the abdominal wall and other circumstances. (Fig. 452, B.)

Operation.—(1) Incise through skin and fascia, clamping all bleeding vessels. The incision will pass through the fibers of the external oblique at about a right angle to its fibers,—will pass between the fibers of the internal oblique,—and will divide those of the transversalis transversely to their course,—but will pass more or less parallel with the seventh and eighth nerves, which, if possible, should be recognized and drawn aside. (2) The peritoneum is opened in the line of the original incision—the stomach is recognized—isolated—and drawn into the wound, the general peritoneal cavity being well packed off—and its anterior wall is opened in the same general way as described in Median Gastrotomy, and in the special site selected. (3) The object of the operation having been accomplished, the stomach-wall and the abdominal wound are closed in the manner just described.

Comment.—(1) The above operation is very similar to that of Gastrostomy by the same incision. (2) Large, irregular, impacted bodies are sometimes removed by incisions made directly over them and giving access by the nearest route.

GASTRORRHAPHY.

Description.—Suturing of the stomach-wall. Generally resorted to for wounds, closure after operations, ulcers, etc. (Sometimes gastrorrhaphy is unadvisedly used synonymously with gastroplication.)

Preparation—Position—Landmarks—Incision.—As for gastrotomy by median incision.

Operation.—(1) The peritoneal cavity having been opened, hemorrhage controlled, and the wound retracted, the stomach is exposed and brought

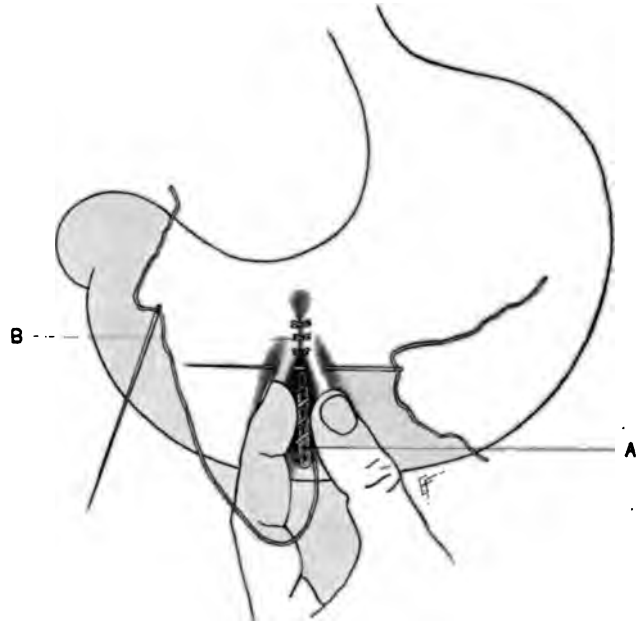

Fig. 453.—GASTRORRHAPHY:—A, Line of overhand continuous suturing through all coats; B, Interrupted Lembert sutures through outer coats.

forward. (2) The area being packed off with gauze, the site of the operation is conveniently held by an assistant. (3) The mucous membrane is first sutured with continuous sutures of fine silk or gut—by means of a curved needle held in a holder in the right hand, while picking up the mucous membrane with forceps in the left. (4) A second line of interrupted Lembert sutures of fine chromic gut is now applied, passing through the serous and muscular coats of both lips of the wound, and thus bringing serous surfaces into contact. (5) The stomach is then returned to its place—and the abdomen sutured as usual.

Comment.—(1) Chromic gut may be used throughout. (2) The first

tier of sutures may consist of an overhand stitching through the entire thickness of all the coats, applied continuously—followed by interrupted Lembert sutures passing through the serous and muscular coats and burying in the first tier. (Fig. 453.) (3) Sometimes three tiers are applied—a continuous stitch through the mucous coat—an interrupted or continuous through the muscular—and an interrupted through the serous. (4) In cases of suturing for gastric ulcer—(a) the edges (in simple cases) are merely invaginated by sutures, first of the mucous membrane, then of the serous and muscular coats;—(b) Or the ulcer may be excised (in hard, thick walls, or in large ulcers) elliptically, the edges of the ellipse being united by the two tiers just described. (5) All lines of gastric suturing may be reinforced by omental grafts sutured over the suture-line.

GASTROSTOMY IN GENERAL.

Description.—By gastrostomy is meant the establishment of a more or less permanent fistulous opening in some part of the anterior wall of the stomach, for the purpose of alimentation or surgical treatment—the stomach generally being attached by suture to the anterior abdominal wall just preceding or following the incision of its wall. The operation of Gastrostomy may be done in one or in two stages. Where haste is a consideration, the opening must be made into the stomach as soon as the latter is attached to the abdominal wall. Where haste is unnecessary, the stomach is first attached to the opening in the anterior abdominal wall—from three to five days given for union to take place, shutting off the peritoneal cavity—and then the stomach is opened. In such cases as those in which the operation is done for inoperable cancer, the gastrostomy is meant to be permanent. Where the operation is done for temporary cause, the fistula is expected to subsequently heal of its own accord (which is generally the case), or a special operation is done later for its closure.

Preparation of Patient.—The stomach is washed out; the site of operation is shaved; the bowels are emptied.

Position during Operation.—Supine, at the side of table, with abdominal parietes relaxed by slight elevation of the shoulders and slight flexion of the hips; Surgeon to right in operating in median line, and to left in the subcostal operation; Assistant opposite.

Division of Abdominal Parietes.—Muscles should be divided in their cleavage line, in so far as this is possible—and the abdominal nerves should be spared, as far as practicable. A disadvantage of all oblique incisions parallel with and just below the left costal arch is the difficulty of making an intramuscular separation of the fibers. Considerable differences of statement exist among the writings of surgeons as to the placing of the skin incision, and as to the manner of dividing, dealing with, and suturing the subjacent structures in the descriptions of even the same operation of Gastrostomy.

Form of Artificial Canal.—As to regurgitation of stomach contents, the longer, more indirect, and more valvular the canal between the stomach and abdominal openings, the greater the control over the gastric contents. Immediately after operation, rubber tubes for feeding are passed down the artificial fistula—but after the first few days these tubes are introduced only at times of feeding—while in some cases the tubes must be constantly worn, only being removed for cleansing.

Comparison of Methods.—Ssabanajew-Franck's method, performed through the separated fibers of the rectus, is probably the best for a permanent fistula, especially in a lax stomach. Kader's method is probably the best for small or adherent stomachs. Marwedel's method is probably the best for the rapidity of healing of the fistula. And Howse's method is probably the most quickly done.

GASTROSTOMY

BY SSABANAJEW-FRANCK'S METHOD.

Description.—A cone of stomach is drawn through the separated left rectus muscle—carried beneath a bridge-work of skin—and its apex made to open upon the cutaneous surface just above the left costal arch. The stomach is exposed through an oblique skin incision approximately parallel with the left costal arch—with a vertical separation of the fibers of the outer part of the left rectus muscle—which, at the end of the operation, are sutured about the base of the cone.

Preparation—Position.—See General Surgical Considerations.

Landmarks.—Median line; linea semilunaris; left costal arch.

Incisions.—Primary incision—oblique, about 6 to 8 cm. (2½ to 3 inches) in length, is made over the outer third of the left rectus muscle, beginning near the median line and passing downward and outward somewhat more vertically than transversely, though approximately parallel with and about 2.5 to 4 cm. (1 to 1½ inches) from the left costal arch. Secondary incision (made later in the operation)—about 2 cm. (¾ inch) in length, is made through the skin and fascia about 2.5 cm. (1 inch) above the costal cartilages and approximately parallel with the original incision.

Operation.—(**1**) Incise skin and fascia in the above line—clamping bleeding vessels—and retracting the lips of the wound. (**2**) Expose the rectus muscle—divide the anterior layer of the rectal sheath—separate the fibers of the outer part of the rectus muscle vertically by blunt dissection in their cleavage line—divide the posterior layer of the sheath,—and divide the transversalis fascia, subperitoneal areolar tissue, and peritoneum—preserving, throughout, the integrity of the muscles and nerves as much as possible, and retracting the structures as divided. (Figs. 454 and 455.) (**3**) Draw a long cone of the anterior wall of the stomach through the abdominal wound, by means of a silk traction-ligature passing through the serous and muscular coats—the apex of the cone being represented by a part of the stomach-wall nearer the greater than the lesser curvature, and nearer the cardiac than the pyloric end—calculating that sufficient length of cone be drawn out to pass, without tension, under a bridge-work of skin about 5 cm. (2 inches) wide. (**4**) The serous coat of the stomach forming the base of the cone, is now sutured to the peritoneal and fascial edges of the wound by four gut sutures. The serous and muscular coats of the stomach are then attached throughout to the posterior layer of the rectal sheath by interrupted or continuous gut sutures (preferably chromic), avoiding the danger of constriction. (**5**) The secondary incision is now made through the skin and fascia in the site indicated (see Incisions)—passing only into the connective tissue plane. (**6**) By blunt dissection from the larger to the smaller wound, the two are connected and the intervening bridge-work of skin thus undermined along the fascial plane. (**7**) A pair of forceps is passed through the smaller opening into the larger—grasps the silk traction ligature and draws the cone of the

stomach into the smaller, upper wound, over the edge of the lower costal cartilages—where it is held in place by four silk sutures. These four sutures are passed through all the coats of the stomach, on the one side, and through the skin and fascia, on the other—if the apex of the cone is to be opened at once. But if the opening is to be deferred, the sutures pass through only the serous and muscular coats of the stomach. The small incision is now sutured at either end, leaving a sufficient opening in the center for the passage of the cone. (8) The separated edges of the rectus and its sheath are now sutured with interrupted chromic gut, from either end toward the center, leaving a sufficient opening to guard against dangerous constriction of the base of the cone, while, at the same time, approaching the base nearly enough to form a muscular circle about it. (9) The skin wound is then closed throughout with subcuticular silkworm-gut sutures—or other form of suturing.

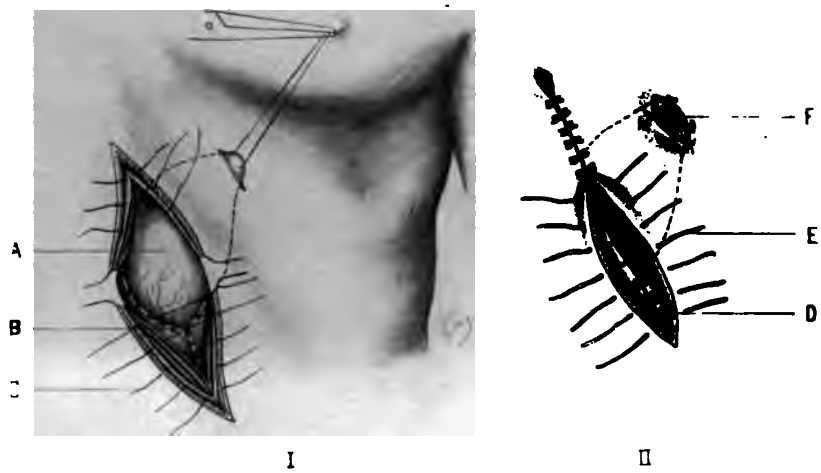

Figs. 454 and 455.—GASTROSTOMY, SSABANAJEW-FRANCK'S METHOD:—I. Cone of stomach drawn out of abdominal wound, over costal arch, and through opening in skin:—A, Stomach-cone; B, Posterior layer of rectal sheath, together with subserous and transversalis fasciæ and peritoneum sutured to serous and muscular coats of stomach around base of cone; C, Sutures carried through anterior rectal sheath and rectus ready to approximate rectus muscle around cone of stomach. II. Completion of wound-suturing:—D, Sutures through rectus and anterior rectal sheath tightened, so as to embrace stomach-cone; E, Sutures through skin and fascia; F, Apex of cone incised and sutured into skin.

(10) The apex of the cone is incised at once, in cases of emergency—otherwise the opening is deferred for two or three days.

Comment.—(1) In the original Ssabanajew-Franck operation, the incision was carried more obliquely and more nearly parallel with the costal arches—and with less regard for the preservation of muscles and nerves by intramuscular separation. (2) Surgeons differ as to the direction of incising the posterior layer of the rectal sheath and the subjacent structures. (3) This operation requires a very lax stomach, capable of furnishing a rather long cone. The resulting fistula is more apt to be difficult to close than is the case in some of the other methods of Gastrostomy. (4) The efficiency of the operation depends upon the valve like nature of the opening over the edge of the costal cartilages—the length of the cone—the muscular action

of the rectus—the double change of direction of the gastric fistula (at first passing through the rectus, and then coming out at the skin wound)—and upon the obliquity of the fistulous canal. (5) The deferring of making the opening into the stomach until all the cone-burying sutures are placed and tied, prevents regurgitation and soiling of the wound in cases in which the stomach must be opened at once.

Other Gastrostomies Resembling Ssabanajew-Franck's Method in General Principle.—

Albert's Gastrostomy.—Similar in all important essentials to Ssabanajew-Franck's operation, with the following exceptions;—(1) The primary incision begins 2.5 cm. (1 inch) below the margin of the ribs and passes almost vertically downward over the outer part of the rectus muscle (tending to be more vertical than oblique as in Ssabanajew-Franck's). (2) The secondary incision is made more directly over (than to one side of) the primary incision, and is placed somewhat nearer the costal margin. (3) The stomach is bent more nearly directly upward—rather than upward and outward.

Hahn's Modification of Ssabanajew-Franck's Gastrostomy.—Resembles, in general principle, Ssabanajew-Franck's method—the chief difference being that the cone of stomach is brought directly up through the eighth intercostal space. (1) The primary incision (Fenger's incision) is about 7.5 cm. (3 inches) long—placed to the left of the left rectus muscle—2.5 cm. (1 inch) from, and parallel with, the left costal arch. The secondary incision is made later—at the anterior end of the eighth left intercostal space, parallel with the ribs—and about 2.5 cm. (1 inch) long. (2) Incise skin and fascia in line of primary incision—incise external oblique at right angle to fibers—separate internal oblique in cleavage line—divide transversalis transversely to cleavage line—and transversalis fascia, subserous areolar tissue, and peritoneum in same line—draw out long cone of stomach, as in Ssabanajew-Franck's operation—suture serous coat of stomach to parietal peritoneum and fascial edges of abdominal wound—make secondary incision in given line—closed, pointed forceps are passed through the anterior end of the left eighth intercostal space and made to work their way through the intervening tissues, hugging the posterior aspect of the costal cartilages and guided by the finger in the abdominal wound—the silk traction-suture is grasped by the forceps and the cone of stomach drawn through the eighth intercostal space—the operation being completed as in the regular Ssabanajew-Franck's method. The danger of injuring the pleural cavity and the costal cartilages, together with the fact of there being no special advantage over the regular operation, are to be considered in undertaking this modification.

GASTROSTOMY

BY WITZEL'S METHOD.

Description.—The stomach is approached by an oblique incision below the left costal arch, passing through skin and fascia—with vertical separation of the anterior rectal sheath and fibers in their cleavage line—division of the posterior layer of the rectal sheath—and vertical division of the peritoneum. A rubber tube is then buried in a long, oblique canal in the anterior stomach-wall, formed by a process of suturing—following which, the stomach-wall is sutured to the parietal peritoneum and edges of the posterior layer of the rectal sheath—and the abdominal wound closed over all.

Preparation—Position.—See General Surgical Considerations.

Landmarks.—Median line; linea semilunaris; left costal arch.

Incision.—Oblique, parallel with and 2.5 to 4 cm. (1 to 1½ inches) from the left costal arch—beginning near the median line and passing downward and outward for about 7.5 cm. (3 inches).

Operation.—(1) Incise skin and fascia in above line—clamp vessels—and retract lips of wound. (2) Expose the rectus muscle—divide the anterior layer of its sheath—and separate the fibers of the rectus muscle vertically, in their cleavage line, by blunt dissection. (Figs. 456–458.) (3) Divide the posterior layer of the rectal sheath. (4) Divide the transversalis fascia, subserous areolar tissue, and peritoneum vertically. (5) Retract the parts well—and draw the portion of the anterior stomach-wall which is to be dealt with well into the wound. (6) A velvet-eyed rubber tube is now laid against the anterior wall of the stomach, generally in such a position as to correspond with the outer wound, with the blunt end of the tube toward the cardiac end

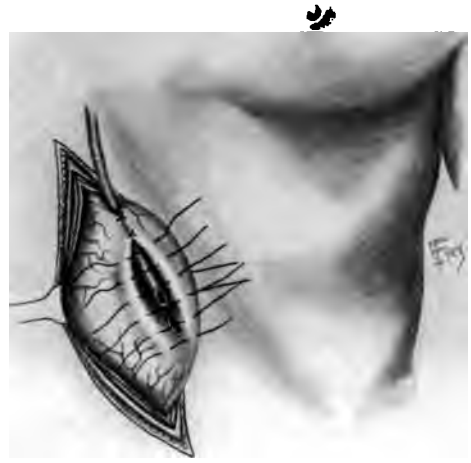

Fig. 456.—GASTROSTOMY, WITZEL'S METHOD:—I. Cone of stomach drawn through separated rectal fibers—showing Lembert sutures placed ready to bury tube, which is about to enter stomach through incision in its wall.

of the stomach and the opposite end directed toward the lesser curvature. About 5 to 7.5 cm. (2 to 3 inches) of this tube is now buried in the anterior stomach-wall by Lembert gut sutures, placed about 5 mm. ($\frac{3}{16}$ inch) apart, and extending at least 1.3 cm. (½ inch) beyond the point at which the tube is to enter the stomach, and so placed as to avoid the larger vessels. All the sutures are now tied, thus burying in the tube—except the three or four at the lower end of the tube. (7) The stomach-wall is then held in such a way as to render the site of entrance of the tube into the stomach prominent, and, at the same time, so as to separate the opposite (posterior) stomach-wall—and with a narrow, sharp-pointed bistoury, a quick, controlled stab is made through all the layers of the anterior stomach-wall, guarding against wounding the opposite (posterior) wall—the opening being made just beneath the tip of the tube, which is temporarily withdrawn about 6 mm. (¼ inch) for that purpose and just before the stab is made. Immediately upon the completion

of the stab-wound, which should be a little less in extent than the caliber of the tube, the end of the tube is thrust through the opening and into the cavity of the stomach—and the already placed sutures, which were temporarily left untied at the lower end of the tube, are at once tied—thereby preventing any regurgitation of the stomach contents. (8) The stomach is now allowed to fall back into the abdominal cavity sufficiently to leave only the site of the anterior stomach-wall represented by the buried tube in contact with the edges of the abdominal wound—and even this area is so adjusted as to cause the site of the buried tube to be surrounded by the edges of the abdominal wound in the form of as narrow an ellipse as possible. (9) The serous and muscular coats of the stomach are now united by interrupted gut sutures to the parietal

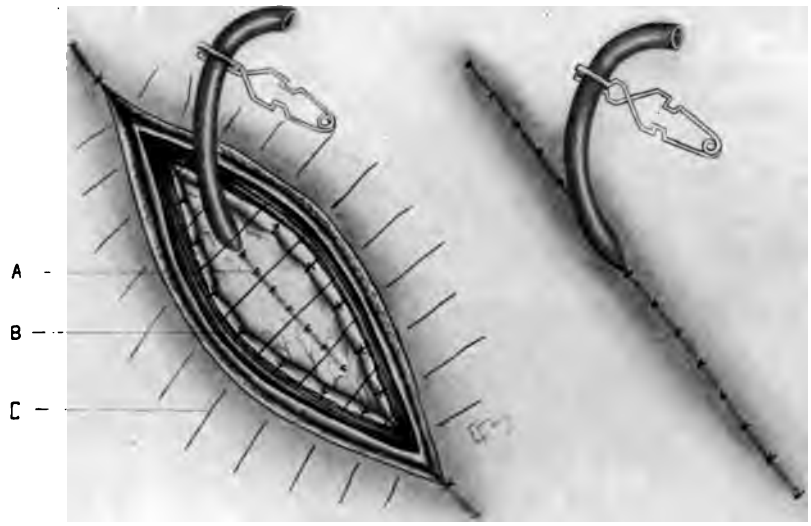

Figs. 457 and 458.—GASTROSTOMY, WITZEL'S METHOD:—II. Manner of placing sutures; A, Tube buried in by two parallel folds of stomach-wall united by tying of interrupted Lemberts shown in I; B, Interrupted sutures passing through serous and muscular coats of stomach, and through parietal peritoneum, posterior rectal sheath, and lower plane of rectus; C, Interrupted sutures through skin, fascia, anterior rectal sheath, and major part of rectus. III. Final position of tube—seen emerging from completely sutured wound.

peritoneum and lower lip of wound along this narrow ellipse. (10) The edges of the abdominal wound are then united—first with chromic gut interrupted sutures passing through the entire thickness of the opposite lips of the separated rectus muscle, together with the edges of its sheath, but not involving the already sutured peritoneum,—followed by interrupted or continuous silk suturing of the skin and fascia—or subcuticular suturing. Or skin, fascia, and rectus may be sutured in one tier. The rubber tube will emerge between the two or three upper sutures. (11) The rubber tubing is held in position by a silk suture passing through the outer part of its wall and attached to the skin. The tube is left in for three or four days—and then inserted only for feeding.

Comment.—(1) The site of incision sometimes differs from that above given—and the fibers of the rectus are sometimes cut instead of separated—but all muscular structures should be separated, and nerves retracted, as far as these may be done. (2) Fenger's incision is sometimes used—about 7.5 cm. (3 inches) in length and placed to the left of the rectus, and 2.5 cm. (1 inch) from and parallel with the left costal arch. (3) Before the stomach is dropped back into the abdomen, three gut sutures may be inserted through its serous and muscular coats, each threaded with a needle at either end—and after the stomach has receded into its normal position, these needles are made to pierce the edges of the abdominal wound, from within—and the stomach thus drawn up to the edges of the abdominal opening. (4) By postponing the opening into the stomach until all the sutures are placed and most are tied, the leakage is minimized. (5) Regurgitation is prevented by the constriction of the separated fibers of the rectus—by the long, oblique canal—and by the short artificial cone created by the manner of suturing, and which projects into the stomach. (6) Operators differ as to the direction in which they divide the layers of the rectal sheath and subjacent structures.

GASTROSTOMY

BY MARWEDEL'S METHOD.

Description.—This operation resembles Witzel's in most of its essentials—except that the tube is buried between the mucous coat, on the one hand, and the serous and muscular coats, on the other—and that the parietal peri-



Fig. 459.—GASTROSTOMY, MARWEDEL'S METHOD:—I. Anchoring of stomach and splitting of stomach-wall; A, Parietal peritoneum sutured into lower part of lips of abdominal wound; B, Stomach sutured to parietal peritoneum and lower plane of abdominal wound; D, Sutures through serous and muscular coats of stomach; D, Tube about to be buried in stomach-wall.

toneum is sutured to the skin before the stomach-wall is attached to the edges of the abdominal incision.

Preparation—Position.—See General Surgical Considerations.

Landmarks.—As in Witzel's operation.

Incision.—Oblique incision about 6 to 7.5 cm. (2½ to 3 inches) in length—made over the left rectus muscle—beginning near the median line and passing downward and outward somewhat more vertically than horizontally, though approximately parallel with and about 2.5 cm. to 4 cm. (1 to 1½ inches) from the left costal arch.

Operation.—(1) Incise skin and fascia—clamp bleeding vessels—and retract the lips of the wound. (2) Expose the rectus muscle—divide the anterior layer of the rectal sheath vertically, nearer its outer part—separate the fibers of the rectus vertically in their line of cleavage, by blunt dissection—divide the posterior layer of the rectal sheath vertically—and the transversalis fascia, subserous areolar tissue, and peritoneum in the same line. (3) The parietal peritoneum is now drawn out and sutured with interrupted gut to the skin at the margin of the abdominal wound. (See Comment.) (4) The anterior stomach-wall is then drawn out and sutured to the parietal peritoneum

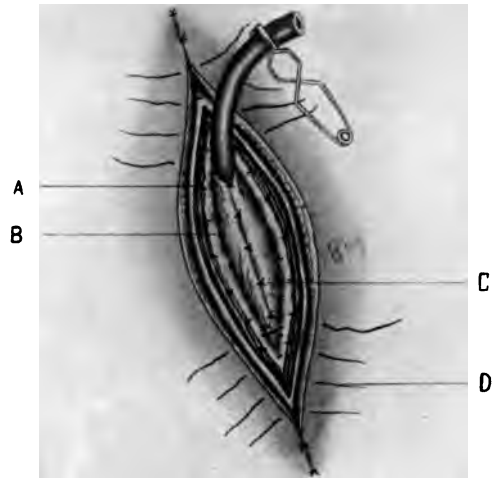

Fig. 460.—GASTROSTOMY, MARWEDEL'S METHOD:—II. Burying of tube and closure of wound; A, Sutures uniting peritoneum to lower plane of abdominal wound; B, Sutures uniting stomach to peritoneum and lower plane of wound; C, Sutures burying tube between mucous coat below, and serous and muscular above; D, Sutures through skin, fascia, anterior rectal sheath, and upper part of rectus.

at the margins of the abdominal wound, in the form of a narrow ellipse. (Fig. 459.) (5) For a distance of about 5 cm. (2 inches) and about parallel with the line of skin incision, the serous and muscular coats are incised, carefully guarding against cutting through the mucous coat. The serous and muscular coats are then dissected from the mucosa to either side for a short distance. A rubber tube is now laid between the split coats of the stomach, which are then sutured over it with fine gut. (Fig. 460.) The sutures at the lower end extend 1.2 cm. (½ inch) beyond the intended opening and are placed but not tied. When all the rest are tied, an opening is made through the mucous coat in the same manner as in Ssabanajew-Franck's operation—immediately following which, the tube is thrust into the stomach and the lower sutures at once tied. (6) The margins of the abdominal wound are then sutured together with interrupted silk or silkworm-gut.

Comment.—(1) It would seem better to attach the parietal peritoneum to the lower edge of the abdominal wound (rather than to the skin)—and the stomach to the peritoneum thus attached—then the edges of the split rectus can be brought into direct contact, in finally closing the abdominal cavity. (2) Fenger's oblique subcostal incision is often used—about 7.5 cm. (3 inches) in length, placed to the left of the rectus and about 2.5 cm. (1 inch) below and parallel with the left costal arch. The operation may also be done in the median line. (3) The tube may be buried in the stomach-wall before the latter is sutured to the edges of the abdominal wound—which is sometimes more convenient. (4) Surgeons differ considerably upon the incision and subsequent steps of the operation.

GASTROSTOMY

BY KADER'S METHOD.

Description.—This is a modification of Witzel's operation, and consists in the insertion of a tube into the stomach at a right angle to its surface—and, by means of two tiers of Lembert interrupted sutures, two parallel folds are made in the anterior stomach-wall, thus invaginating the stomach-wall and burying in the tube. The stomach is reached through the vertically separated fibers of the rectus.

Fig. 461.—GASTROSTOMY, KADER'S METHOD:—I. Burying tube perpendicularly within stomach; A, Lower tier of sutures approximating lower ridges of stomach-wall; B, Upper tier of sutures approximating upper ridges of stomach-wall. Both tiers are partly tied. Note—Through error, the abdominal incision is represented oblique—but should be vertical, as shown in II, Fig. 462.

Preparation—Position.—See General Surgical Considerations.

Landmarks.—Linea alba; linea semilunaris; left costal arch.

Incision.—Vertical incision over the left rectus muscle, beginning about 2.5 cm. (1 inch) below the costal cartilages and extending downward 6 to 7.5 cm. (2½ to 3 inches). (Fig. 452, C.)

Operation.—(1) Incise skin and fascia in the above line—clamp bleeding

vessels—retract margins of the wound, exposing the sheath of the rectus. (2) Divide the outer sheath of the rectus vertically. Separate the fibers of the rectus by blunt dissection in their cleavage line. (3) Divide vertically the posterior sheath of the rectus, transversalis fascia, subserous areolar tissue, and peritoneum. (4) Isolate and draw into the wound a fold of the anterior stomach-wall—packing off the peritoneal cavity with gauze. (Fig. 461.) (5) Having selected an appropriate site, and while the stomach is properly held by an assistant so as to avoid injury to the opposite (posterior) wall, an opening somewhat smaller than the caliber of the tube is made by a quick, controlled stab with a narrow, sharp-pointed bistoury. Having seen that no serious hemorrhage follows the stab wound, a rubber tube is immediately inserted into the stomach cavity through this opening and sutured to the edge of the stomach wound with two gut sutures passing into but not through the wall of the tube. (6) While the tube is held perpendicular to

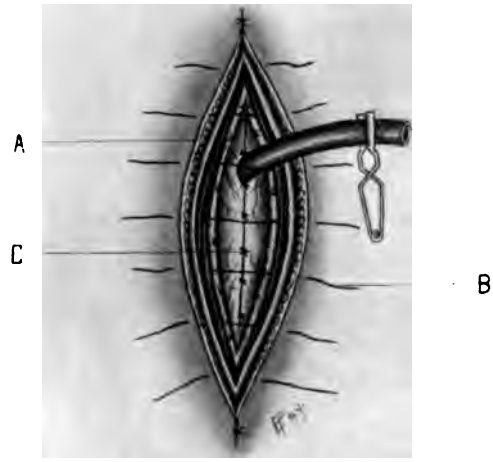

Fig. 462.—GASTROSTOMY, KADER'S METHOD:—II. Anchoring of stomach and closure of wound; A, Suture uniting serous and muscular coats of stomach to parietal peritoneum and margins of wound; B, Sutures passing through skin, fascia, anterior rectal sheath, and rectus; C, Tier of sutures burying in tube.

the stomach-wall at its point of entrance, two chromic gut Lembert sutures, about 1.2 cm. (½ inch) apart, are so passed through the serous and muscular coats of the stomach, on either side of the tube, as to raise a fold or pleat of stomach-wall about 7.5 cm. (3 inches) long and 1.2 cm. (½ inch) high. These deep occlusion sutures are then tied—the included tissues infolding into the stomach in the form of a funnel-shaped projection. A second tier, superficial occlusion sutures, is similarly placed, at the same distances apart, above the first, which are, in turn, thus buried in by the second, forming a second fold. The sutures of the second tier are temporarily left long, to aid in the subsequent manipulation of the stomach. (7) The general peritoneal cavity is shut off by stitching the serous and muscular coats of the stomach, on the one hand, to the parietal peritoneum and edges of the divided posterior sheath of the rectus; on the other—holding the stomach by means of the temporarily left occlusion sutures. (Fig. 462.) (8) The

separated edges of the rectus are sutured with interrupted chromic gut sutures —and the anterior sheath of the rectus with a similar separate line of sutures— both being closely approximated to the tube. The skin is closed by interrupted silkworm-gut sutures.

Comment.—(1) This operation is more generally applicable than Witzel's, of which it is a modification, because of requiring less amount of movable stomach-wall—and because it may be used through any kind of incision exposing the stomach. (2) The folds or pleats are made transverse when the opening is to be temporary—and perpendicular when the opening is to be permanent. (3) Where the stomach is so small, or so bound down, as to make it impossible to bring it well into the wound, the pleating may be made and the tube buried with the stomach *in situ*. (4) The efficiency of the method depends chiefly upon the valvular invagination of the stomach-wall. The sides of the infolded funnel soon become adherent, leaving only the tubular tract patulous. (5) As in most Gastrostomies, surgeons vary as to the exact placing of the external incision and the manner of dividing, dealing with, and suturing the subjacent layers. (6) A somewhat similar method (Abbe and Stamm) consists in thrusting a tube, through a previously made opening, perpendicularly into the anterior stomach-wall—then surrounding it by a circular purse-string suture about 1.2 cm. (½ inch) from the catheter, which is then tied, gut being used—then a second purse-string suture about 2.5 cm. (1 inch) from the first, which is tied similarly—and a third—the stomach being attached to the abdominal wall as above.

Note.—Other forms of Gastrostomy might be mentioned—some representing older, some more modern methods—such as Howse's; Greig Smith's modification of Howse's; E. J. Senn's; Andrew's; Von Hacker's; and others' —but those above described in detail sufficiently cover the best modern methods.

GASTRO-ENTEROSTOMY IN GENERAL.

By Gastro-enterostomy is meant the establishment of an anastomotic opening between the stomach and some part of the small intestine—the name of the operation being further designated by the part of the intestine anastomosed—for example, gastro-duodenostomy, gastro-jejunostomy, gastro-ileostomy. The object of the operation is generally to obtain the complete emptying and rest of the stomach—or to furnish egress from it in cases of obstinate obstruction at or near the pyloric end—or in cases of excision of the intestine near the pylorus.

The nearer to the stomach the portion of intestine anastomosed, the greater will be the length of small intestine left for absorption. That portion of the stomach between the pyloric end and the site of the intestine anastomosed with the stomach becomes partially thrown out of circuit ("short-circuited") in proportion as it continues or not to transmit intestinal contents, and henceforth performs more or less limited function—the bulk of the stomach contents traveling by the new route, while the small amount which escapes through the pylorus still goes by the old route.

The flow of the stomach contents is usually from the cardiac to the pyloric and along the greater curvature, nearer which the anastomosis is generally made—and usually from the pyloric to cardiac end along the lesser curvature. It is always desirable to so approximate a coil of intestine to the stomach that the flow in both viscera may be in a normal direction—which is generally

accomplished by giving the coil of intestine a half-turn just before making the anastomosis.

In order to avoid regurgitation into the stomach of intestinal contents, including bile, many surgeons, after completing the gastro-enterostomy, perform a jejuno-jejunostomy (between the proximal and distal limbs of the jejunum)—the Jaboulay-Braun operation (see page 781).

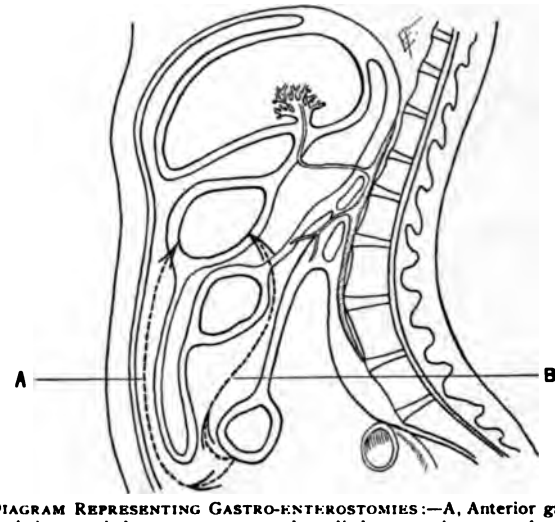

Fig. 463.—DIAGRAM REPRESENTING GASTRO-ENTEROSTOMIES:—A, Anterior gastro-enterostomy—small intestine being carried over omentum and applied to anterior stomach-wall; B, Posterior gastro-enterostomy—small intestine being carried through an opening made in transverse mesocolon and applied to posterior stomach-wall. (Modified from Gray.)

The intestine may be anastomosed to the anterior or to the posterior wall of the stomach—constituting Anterior or Posterior Gastro-enterostomy. The latter operation is preferable—the reasons for which being given under Comment upon the two operations, pages 780 and 785. (Fig. 463.)

ANTERIOR GASTRO-ENTEROSTOMY

BY SIMPLE SUTURING—WÖLFLER'S OPERATION.

Description.—In this operation some part of the small intestine is carried up in front of the great omentum and transverse colon and united by some method of suturing, without the aid of one of the mechanical devices, to the anterior wall of the stomach, nearer its greater curvature. (Fig. 463, A.) The nearest part of the small intestine to the pyloric end of the stomach which is available, which will generally be the jejunum, is the portion usually selected for the anastomosis—constituting gastro-jejunostomy.

Preparation.—The stomach is washed out; the site of the operation is shaved; the bowels are emptied by purgation.

Position.—Patient supine, at side of table, with abdominal parietes relaxed by slight elevation of the shoulders and slight flexion of the hips; Surgeon to the right; Assistant opposite.

Landmarks.—Linea alba; xiphoid cartilage; umbilicus.

Incision.—In median line, from just below xiphoid cartilage to umbilicus—and beyond, if necessary (Fig. 452, A).

Operation.—(1) Is conducted as a median abdominal section up to the exposure of the abdominal cavity. (2) The beginning of the jejunum is now sought—and is most readily found by temporarily displacing the great omentum upward and to the left, and the transverse colon and mesocolon upward and to the right—and by following down the under surface of the mesocolon to its base, from left to right, as the finger passes beneath the ligament of Treitz, a loop of small intestine is encountered, which is the commencement of the jejunum. (Fig. 464.) This is now followed down several inches until a convenient distance for anastomosis, without tension, to the anterior stomach-wall is secured—which is generally about 40 to 50 cm. (16 to 20 inches). (3) This site of jejunum being held by an assistant, the transverse mesocolon and great omentum are now allowed to drop back into place—the jejunum being brought down, around and in front of them—

Fig. 464.—Manner of Locating Beginning of Jejunum:—A, Great omentum displaced upward and to left; B, Transverse colon and mesocolon displaced upward and to right; C, Commencement of jejunum emerging from beneath ligament of Treitz; D, Incision in mesocolon through which jejunum is to be carried into the cavity of the lesser omentum and approximated to posterior stomach-wall.

seeing that sufficient length of intestine for this course is allowed. Then to cause the flow in the intestinal canal to correspond with the gastric flow (from left to right) the loop of jejunum is given a half-turn (Rockwitz's modification) and is thus approximated to the anterior wall of the stomach, near its greater curvature. (Fig. 465.) It is important that this approximation should be accomplished without undue twisting and tension of the intestine, or other marked disarrangement of normal relations of the parts concerned. (4) When all is in readiness for suturing, the proposed site of anastomosis of the anterior stomach-wall and the corresponding portion of the jejunum should be drawn somewhat out of the abdominal cavity for the greater convenience of manipulation. An assistant holds the antimesenteric border of the jejunum in easy contact with the lower anterior surface of the stomach-wall, near the great curvature—holding the stomach so as

to exclude, as much as possible, an outflow of its contents when incised—the intestines being squeezed empty and clamped. (5) With a long, straight needle, threaded with chromic gut, or silk, a line of continuous suturing, passing through serous and muscular coats of the intestine, on the one hand, and the same coats of the stomach, on the other, is carried along what will form the posterior line of union, the needle being inserted at close intervals—the suture left hanging long at both ends, with the needle at one end, and knotted at the other—and the suturing having extended in a slightly elliptical

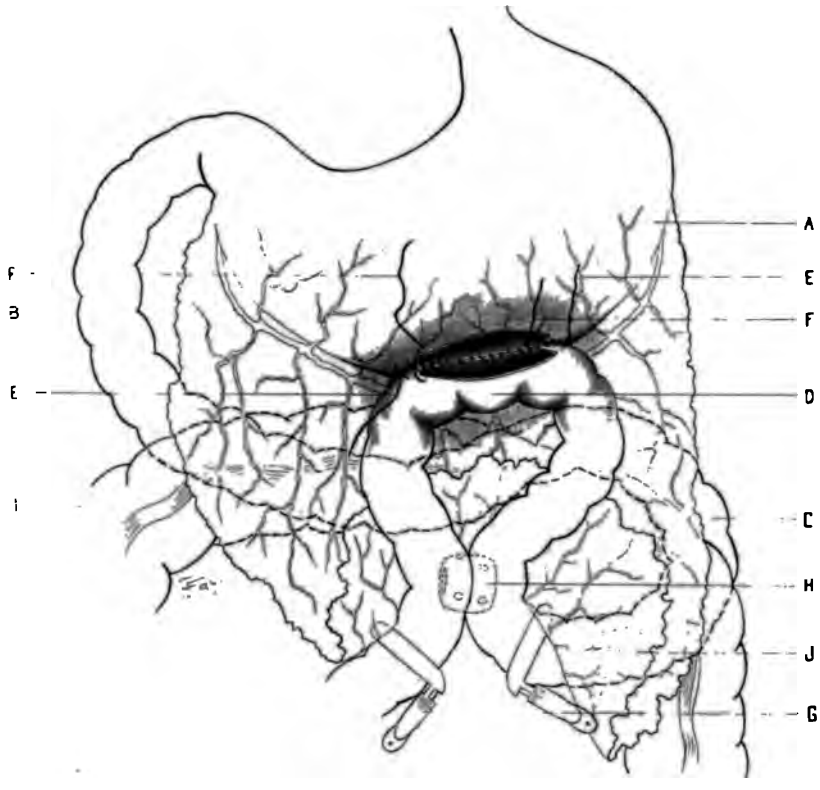

Fig. 468.—ANTERIOR GASTRO-ENTEROSTOMY:—A, Stomach; B, Duodenum; C, Jejunum, after emerging from ligament of Treitz; D, Coil of jejunum given a half-turn and applied to lower aspect of anterior stomach-wall; E, E, Outer tier of continuous Lembert suturing; F, F, Inner tier of continuous overhand suturing approximating edges of opening in stomach and intestine; G, Intestinal clamps; H, Entero-enterostomy by Murphy button; I, Transverse colon; J, Omentum folded back by up-lifted jejunum.

direction, beginning and ending about 1.2 cm. (½ inch) beyond the ends of the future incision through the two opposed walls. (6) With a sharp-pointed bistoury, a quick, controlled stab is made into the stomach, in its long axis, and then into the intestine, in its long axis, in the indicated sites, and so planned that the incisions will fall immediately opposite each other and be of the same size—the incisions being made while both stomach and intestine are so held by an assistant as to present their proper surfaces, and,

at the same time, the opposite walls are held apart so as not to be also penetrated by the knife stab. One blade of a pair of sharp-pointed scissors is now introduced, and both incisions lengthened in the long axes of both viscera to the extent of about 5 to 6.5 cm. (2 to 2½ inches)—until within about 1.2 cm. (½ inch) of either end of the posterior line of suturing. These incisions into the stomach and intestine, made immediately opposite each other, should be from 5 to 8 mm. (¼ to ⅓ inch) from the suture-line. Soiling of the adjacent structures with the outflow of stomach and intestinal contents should be prevented as much as possible with gauze packing. All bleeding should be controlled by clamping and twisting—and is further controlled by suturing—and by gut ligature if necessary. (7) Immediately following these incisions, the margins of the intestinal incision are united to the margins of the stomach incision by continuous suturing with silk or chromic gut, passed with a curved needle held in a holder, the sutures passing through all the coats of both stomach and intestine, the edges of the incision being so held as to enable them to be whipped together by an overhand stitch. (8) The threaded end of the original continuous gut or silk suture is now taken up and the line of suturing continued from the end where it was temporarily discontinued, on around now in front of the line of incisions into stomach and intestine, in the same slightly elliptical outline as upon the posterior aspect, and passing about 8 to 12 mm. (⅓ to ½ inch) from the line of incision into the lumina of the viscera—until the suturing reaches the opposite end, when the free end of the suture is tied to the end originally left long after knotting. Thus the inside line of sutures, chiefly for strength, is reinforced by this secondary line uniting the muscular and serous coats, and thus shutting off any leakage which might escape through the suturing of the margins alone. The stomach and intestine must be so manipulated during the various stages of the suturing as to present the site to the surgeon most advantageously. (9) A third line of interrupted gut Lemberts may be now applied, burying in the other two, if thought necessary—but is rarely needed. (10) The viscera are now dropped back into the peritoneal cavity and the abdominal wound closed as usual. See, under Comment, reference to intestinal anastomosis as an accompaniment of gastro-enterostomy.

Comment.—(1) The chief objections to the anterior method of gastro-enterostomy are—that the transverse colon is apt to be compressed by the small intestine resting and dragging upon it;—that the two intestinal arms descending from the stomach are apt, by gravity and traction, to become parallel, and a spur-formation thereby occur at the stomach opening, by converting the original curve at their point of meeting into an angularity;—and that regurgitation of intestinal contents, including bile, into the stomach is more frequent after the anterior operation. Therefore various suggestions have been made to overcome the above disadvantages—such as valvular forms of anastomoses,—multiple intestinal anastomoses, or a single intestinal anastomosis, to carry off the contents of the proximal end of the intestine, including bile,—and, probably best of all, posterior gastro-enterostomy. (2) In all forms of gastro-enterostomy, but especially in the anterior operations, it is advisable, after completing the gastro-enterostomy proper, to form an intestinal anastomosis, a jejuno-jejunostomy, at the site and in the manner described in connection with the following operation (page 781). (3) In the operation just described, wherever the continuous suture is used, it is well to tie it at several points (without intermitting the stitch) rather than at one only—to do away with any possibility of the suture acting as a "draw-string" and constricting the opening.

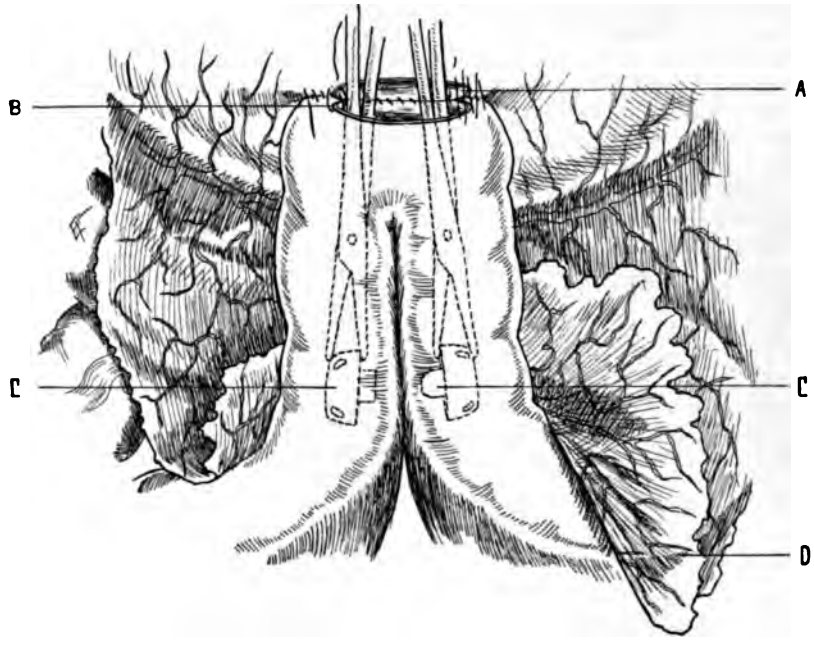

Fig. 466.—ANTERIOR GASTRO-ENTEROSTOMY, FOLLOWED BY ENTERO-ENTEROSTOMY BY GALLET'S METHOD OF INTRODUCING WEIR'S MODIFICATION OF THE MURPHY BUTTON:—A, Stomach opening; B, Intestinal opening; C, C, Manner of applying the buttons from within parallel limbs of jejunum; D, Omentum folded back over a reversed coil of jejunum.

ANTERIOR GASTRO-ENTEROSTOMY BY THE MURPHY BUTTON;

FOLLOWED BY SINGLE OR MULTIPLE INTESTINAL ANASTOMOSIS BY THE JABOULAY-BRAUN METHOD.

Description.—Consists, first, in performing an anterior gastro-enterostomy, by bringing the highest available part of the jejunum up in front of the great omentum and transverse colon and uniting it to the anterior wall of the stomach, nearer its greater curvature, by means of the Murphy button. For the reasons explained under Comment in the last operation, the two arms of the loop of jejunum are then anastomosed, either by the Murphy button or by simple suturing—constituting single intestinal anastomosis,—or, in addition to the anastomosis thus formed, one or more other anastomoses may be made between adjacent coils of intestine, if the need for these be indicated.

Preparation—Position—Landmarks—Incision.—As in the operation just described.

Operation.—(1) All the steps of the gastro-enterostomy are precisely similar to those described under anterior gastro-enterostomy by simple suture, up to the point of making the anastomosis—which, in the present case, is accomplished by means of the Murphy button. The male half of the button is inserted into a convenient, relatively non-vascular part of the anterior wall of the stomach, near the greater curvature and about at its center. The insertion of the half button into the stomach is accomplished exactly as described under entero-enterostomy by the Murphy button (page 703)—the

incision into the stomach-wall being in its long axis, and all bleeding being controlled by twisting or ligature before proceeding. The female half of the button is then inserted into the antimesenteric aspect of the loop of jejunum—also in the same manner as described in entero-enterostomy by the Murphy button. When all is in readiness, the two halves of the button are approximated in the usual manner. If thought necessary, the button anastomosis may be reinforced by a few interrupted Lemberts. (**2**) The anastomosis between the antimesenteric aspect of the limbs of the jejunum, several inches below the stomach, is now accomplished in one of the following ways:—(**a**) By Gallet's method of introducing Weir's modification of the Murphy button:—When the incision is made into the knuckle of jejunum to be anastomosed to the anterior stomach-wall, and before that anastomosis is done, the male half of the button, with the end of its cylinder beveled and sharpened,

Fig. 467.—GASTRO-ENTEROSTOMY, FOLLOWED BY ENTERO-ENTEROSTOMY:—By means of buttons dropped into parallel limbs of jejunum, and then approximated through incisions made over their cylinders. (Hartley's method.)

as modified by Weir, is introduced down the proximal limb of the jejunum, in the grasp of a pair of forceps, the handle of the forceps being steadied by an assistant,—and the female button, similarly grasped, is introduced down the distal limb of the jejunum—and while thus held, the two halves of the button are approximated and pressed home, the cutting cylinder of the male button cutting its way through intervening intestinal wall of the proximal and distal limbs of the gut and finding its way into the female cylinder. No reinforcing suture is necessary—though may be applied if desired. The forceps are now withdrawn from the opening in the knuckle of intestine, and the anastomosis between stomach and intestine completed. (Fig. 466.) (**b**) By Hartley's method:—the ordinary Murphy buttons are used—the male button being dropped through the incision at the knuckle of intestine into the proximal, and the female button into the distal limb.

The gastro-intestinal anastomosis is then completed—after which each button is grasped and, while so held as to bring their cylinders into contact with the antimesenteric aspect of the jejunum, at the indicated site, two small incisions are made at right angles through the intestinal wall, which has been stretched like a drum-head over the ends of the cylinders—the surgeon steadying one button with the fingers of his left hand, and an assistant steadying the other. The buttons are then pressed together in the usual fashion—no reinforcing suturing being ordinarily used. (Fig. 467.) (c) The Murphy buttons may be used to make the intestinal anastomosis in the ordinary manner—as described in entero-enterostomy by lateral anastomosis (page 708). (d) The intestinal anastomosis may also be made by simple suturing. (3) The stomach and intestines having been dropped back into place, the abdomen is closed as in median abdominal section.

Comment.—If it be thought advisable, in addition, to anastomose adjacent coils of intestine, in order to increase the freedom of passage of intestinal contents, one or more anastomoses may be made where indicated—the operation becoming an entero-enterostomy by lateral anastomosis, and one of the methods described under that head may be used—the Murphy button being the means usually employed.

POSTERIOR GASTRO-ENTEROSTOMY

BY VON HACKER'S METHOD.

Description.—In this operation some part of the small intestine as near as possible to the stomach (generally the upper part of the jejunum) is carried through an artificial opening made for the purpose in the transverse mesocolon, and anastomosed with the posterior wall of the stomach. (Fig. 463, B.)

Preparation—Position—Landmarks.—As in the anterior operation.

Incision.—In the median line—beginning about 5 cm. (2 inches) below the ensiform cartilage and extending below the umbilicus.

Operation.—(1) Expose the peritoneal cavity, as in median abdominal section. (2) Lift the great omentum upward and to the left, and the transverse colon upward and to the right, displacing them over the stomach. (3) Isolate and draw out the beginning of the jejunum, as described in anterior gastro-enterostomy. (4) An assistant, standing above the stomach and to one side, so grasps the stomach that both his thumbs press its anterior and his fingers its posterior surface—then by pronating his forearms, the posterior surface is protruded downward and forward prominently toward the surgeon, the transverse mesocolon intervening. (5) Separate the fibers of the transverse mesocolon by blunt dissection in the direction of its vessels, and opposite the site of the future anastomosis—thus opening into the cavity of the lesser omentum. (Fig. 468.) (6) The assistant, continuing to press upon the stomach as above, causes its posterior wall to bulge through the artificial slit in the transverse mesocolon—until it presents in the cavity of the great omentum. The edges of this slit in the mesocolon are immediately sutured to the stomach, leaving an oval area of posterior stomach-wall of sufficient size, the sutures passing through the entire thickness of transverse mesocolon and through serous and muscular coats of the stomach. (7) A convenient coil of jejunum, so selected as to avoid tension and kinking, is now approximated to the posterior gastric wall—its contents having been pushed away for several inches on either side and the gut clamped—the

assistant holding the stomach likewise keeping its contents away from the site as far as possible. The coil of jejunum should be so approximated to the stomach as to make the flow of contents from the latter correspond with that in the intestine. While the need of giving it a half-turn is not so pressingly necessary as in the anterior gastro-enterostomy, because of the more favorable relations of the parts at the site of the posterior operation, it is, however, generally best to resort to this manœuvre. (8) While the jejunum is held in

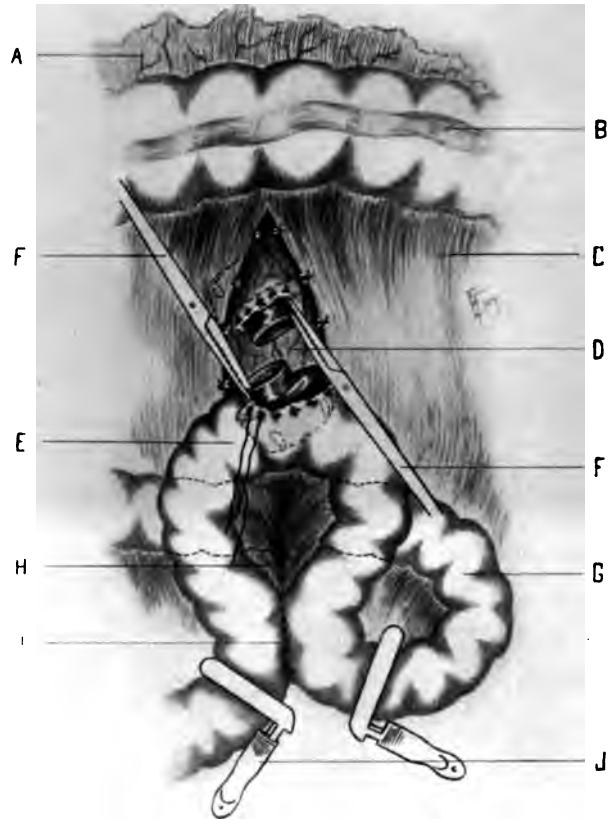

Fig. 408.—POSTERIOR GASTRO-ENTEROSTOMY:—A and B, Great omentum and transverse colon turned upward; C, Transverse mesocolon with edges of its incised wall sutured to posterior stomach-wall; D, Posterior stomach-wall with a halt-button inserted; E, Coil of jejunum, with a halt-button inserted; F, F, Forceps holding buttons; G, Coil of jejunum, just beyond ligament of Treitz, given a halt-turn; H, Mesentery of jejunum; I, Entero-enterostomy by simple suturing; J, Intestinal clamps.

contact with the posterior stomach-wall (both being drawn as far out of the abdominal cavity as feasible) the surfaces are sutured together exactly as in the anterior gastro-enterostomy—first the line of continuous chromic gut suturing is applied posteriorly, extending about 1.2 cm. (½ inch) beyond the ends of the incisions, slightly elliptically—carried by a long, straight needle—following the directions given in section 5 of Wölfler's Anterior Gastro-enterostomy. Sections (9), (10), (11), and (12) of the Posterior Gastro-enterostomy

are performed exactly as are the corresponding steps in the Anterior Gastro-enterostomy—where they are found described under sections 6, 7, 8, and 9. (13) The viscera are now returned to the abdominal cavity and the wound closed as usual.

Comment.—(1) In the posterior operation, the opening in the stomach is made with a slight obliquity from left to right and from above downward—the intestine being incised in its long axis, as in the anterior operation. (2) The suturing of the split transverse mesocolon to the stomach lessens the chance of the intestine slipping through the opening—and also lessens traction of the transverse mesocolon on the small intestine. (3) The application of the sutures is somewhat more difficult in the posterior operation. In placing the continuous suture, it is well to tie it at intervals, without interrupting its continuity—to prevent its acting as a draw-string. There is also probably greater danger of twisting of the intestines subsequently—owing to the passage through the slit in the mesocolon. (4) While a single intestinal anastomosis is generally advisable, some surgeons perform multiple intestinal anastomoses—to further prevent regurgitation of intestinal contents. Some surgeons also narrow the calibre of the proximal portion of the small intestine, by Lemberts through the serous and muscular coats transversely, thus infolding the walls as a rosette. (5) The various disadvantages of the anterior operation are, however, largely overcome—and some of them entirely overcome. The direction of the flow and the position of the parts are more natural.

POSTERIOR GASTRO-ENTEROSTOMY

BY THE MURPHY BUTTON.

Description.—Consists in anastomosing the jejunum to the posterior stomach-wall by means of the Murphy button—the manner of exposing the parts being the same as in Von Hacker's Posterior Gastro-enterostomy—and the manner of applying the button being identical with its application in the operation of Anterior Gastro-enterostomy by the Murphy button. See pages 783 and 781. (Also see Fig. 468.)

Where a single or multiple intestinal anastomosis is done in connection with the operation of Gastro-enterostomy, it may be performed in one of the several manners mentioned upon page 782.

Note.—There are several other methods of performing both Anterior and Posterior Gastro-enterostomy—but those above described are considered among the best modern methods.

GASTROGASTROSTOMY

BY WÖLFLER'S OPERATION.

Description.—The operation of Gastrogastrostomy consists in the anastomosis of the two pouches of an hour-glass contraction of the stomach, for the purpose of making a common cavity. Wölfler's method of operating is probably more applicable to a symmetrically deformed hour-glass contraction, where the two pouches are approximately of the same size and the intervening connection fairly large.

Preparation—Position.—Gastrostomy in General, page 765.

Landmarks.—As for median abdominal section.

Incision.—In the median line—from the tip of the xiphoid cartilage to about 7.5 cm. (3 inches) below the umbilicus.

Operation.—(1) Having exposed the abdominal cavity, the deformed stomach is brought as well into the wound as possible—the portion intervening between the two pouches being apt to be bound down to the pancreas and gastro-hepatic ligament. (2) Having packed off the adjacent regions with gauze, the assistant holds first one and then the other gastric pouch conveniently to the surgeon. (3) Oval incisions (thus excising elliptical portions) are made upon those aspects of the two pouches which face each other—near their lower borders, so as to re-establish a greater curvature. (Figs. 469 and 470.) These openings are about 7 cm. (2¾ inches) long and pass through all the coats of the stomach. Bleeding vessels are clamped and gut-ligatured. The pouches are so held as to minimize the escape of intestinal contents. (4) An assistant now approximates the two openings while the Wölfler (which are practically the same as the Czerny-Lembert) sutures are

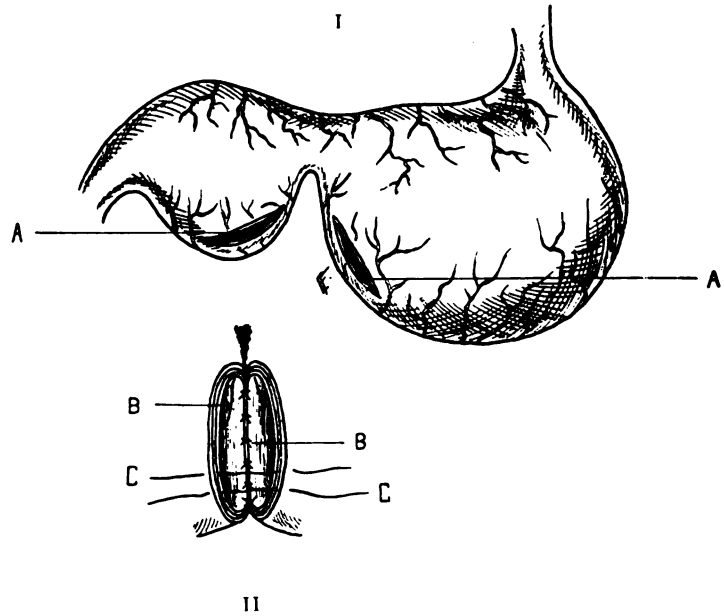

Figs. 469 and 470.—GASTROGASTROSTOMY (WÖLFLER'S OPERATION):—I. A, A, Incisions in the two pouches of an hour-glass contraction of the stomach. II. Manner of applying sutures; B, B, Wölfler's sutures through the mucous coat; C, C, Sutures through the outer coats.

applied—along the posterior aspects first (Fig. 384). Along the posterior borders the sutures are first passed through the serous and muscular coats, each knot being turned outward as tied, being pushed outward with a probe if necessary (so as not to serve as a capillary drain from the stomach). Then the mucous membrane is sutured along the posterior aspect—and then on around both sides and front—all knots being turned inward toward the lumen. Then the outlying line of sutures through the serous and muscular coats, which had been applied posteriorly only, is now continued on around the sides and in front—thus completing the double line of suturing. (5) The stomach is now returned to its position and the abdomen closed.

Comment.—(1) The openings are so calculated that they will correspond with the greater curvature of the stomach—and increase this when the two

halves of the stomach are united. (2) In some cases of non-symmetrical hour-glass contraction of the stomach, the pyloric pouch is bent over upon a vertical axis and sutured along an elliptical outline to the cardiac pouch—an opening is then made in the pyloric pouch, and through this an incision is made through the two walls which have been sutured together and which now intervene between the two pouches—the margins of this incision through the double walls is then whipped over with a button-hole stitch—and then the original incision in the pyloric pouch is closed by sutures—and the abdomen, which has been opened by an incision from the tip of the xiphoid cartilage down the median line two-thirds of the way to the umbilicus, and thence rounding outward and upward to the left costal arch, is closed—constituting Watson's operation.

GASTROPLICATION.

WEIR'S MODIFICATION OF BIRCHER'S OPERATION.

Description.—Gastroplication consists in the reduction of the size of a chronically dilated stomach by invaginating a fold of the stomach-wall into

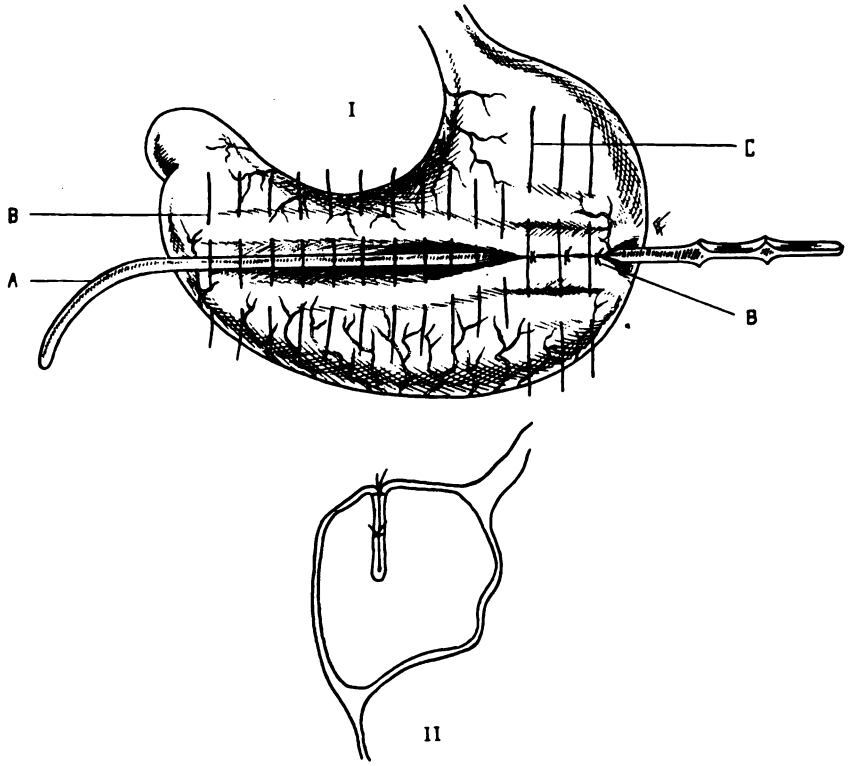

Figs. 471 and 472.—GASTROPLICATION (WEIR'S MODIFICATION OF BIRCHER'S OPERATION):—I. A, Sound infolding anterior stomach-wall; B, B, First tier of Lembert sutures burying in sound; C, Second tier of sutures ready to bury in sound for second time, when latter is placed upon first tier. II. Sectional view of stomach after the two tiers have been tied.

the lumen of the stomach, with suturing together of the walls of the infolded portion.

Preparation—Position—Landmarks.—As for median abdominal section.

Incision.—In the median line—from below the ensiform cartilage, nearly or quite to the umbilicus.

Operation.—(1) Expose the abdominal cavity by the usual steps of the median abdominal section—control hemorrhage—retract the edges of the wound—well expose the anterior surface of the stomach and lift it as far forward into the wound as possible, separating by blunt dissection all minor adhesions. (2) In a direction parallel with the long axis of the stomach, and midway between the greater and lesser curvatures, depression of the anterior surface of the stomach is made with a sound, causing parallel longitudinal ridges to form on either side of the sound. (Figs. 471 and 472.) (3) These ridges of anterior stomach-wall are now united with interrupted silk sutures, passing through serous and muscular coats of each ridge, and extending for 15 to 20 cm. (6 to 8 inches). (4) The sound is now withdrawn and reapplied over the first line of sutures, and parallel with it—similarly depressing them—and similarly causing two secondary parallel longitudinal folds of anterior stomach-wall to rise up on each side of the sound. These secondary folds are similarly sutured. Whether a third tier is placed, will depend upon the size of the stomach—the process being continued, in some cases, until the greater and lesser curvatures meet. (5) The stomach is then allowed to recede into position—and the abdomen is closed.

Comment.—Bircher did not suture the two walls of the fold together, but left a dead space—Weir's suturing of these folds into apposition constitutes his modification. Chromic gut may be substituted for silk.

GASTROPEXY.

Description.—Consists in the suturing of a prolapsed or displaced stomach to some fixed point of support. The condition of the stomach is termed gastroptosis—and as this condition is frequently associated with a general enteroptosis (Glénard's disease) of the abdominal viscera, suturing into a more fixed position of other viscera than simply the stomach is generally indicated. The viscera usually sutured to the anterior abdominal wall are the stomach, liver, and transverse colon.

Preparation—Position—Landmarks.—As for median abdominal section.

Incision.—In the median line, from just below the xiphoid cartilage to or below the umbilicus.

Operation.—(1) Expose the abdominal cavity—control hemorrhage—retract margins of wound—isolate the stomach and other displaced organs. (2) The following steps have been resorted to:—(a) Treves, in whose case the liver was also involved, passed three stout silk sutures—one through the edge of the liver to the round ligament—and two from the falciform ligament and round ligament to the fibrous tissue of the abdominal parietes near the ensiform cartilage. (b) Duret passed a continuous suture through the serous and muscular coats of the anterior wall of the stomach, on the one hand, and through the undivided parietal peritoneum on a level with the fold around the round ligament of the liver, on the other. (c) Rovsing placed three silk ligatures between the anterior wall of the stomach and the parietal peritoneum. (d) Davis, in one case, sutured, with silk, the lesser curvature of the stomach to the parietal peritoneum near the xiphoid cartilage.

In another case, he did the same operation, together with gastroplication. (e) Beyea shortened the gastro-hepatic omentum with eight or ten interrupted sutures. (f) Depage operated by lessening the capacity of the abdominal cavity by removing a T-shaped segment of the abdominal wall.

GASTROLYSIS.

Description.—Consists in division of gastric peritoneal adhesions from neighboring structures. The adhesions are met incidentally, in the course of other operations.

The region of adhesions having been well exposed in the course of some primary operation, the adhesions are dealt with according to their nature:—(1) Slight, flat adhesions may be separated by finger or blunt dissection;—(2) Cord-like or ribbon-like adhesions are divided between double ligatures;—(3) Extensive, firm adhesions often require partial excision of the wall of the stomach, or that of the neighboring organ—with repair of the denuded surface, or excised area, by suturing, omental grafting, etc.

Note.—See the section upon Peritoneal Adhesions, page 649.

GASTROPLASTY.

Description.—An operation for widening the opening between the two pouches of an hour-glass contraction of the stomach—similar in principle and application to Pyloroplasty.

The stomach is exposed by median abdominal section—after which the narrowed portion between the two pouches is brought into the field—and the same operation is there done which will be described below under Pyloroplasty.

PYLOROPLASTY.

THE HEINEKE-MIKULICZ OPERATION.

Description.—Consists in an increasing of the caliber of the pyloric orifice of the stomach, by means of a horizontal incision through its anterior wall, corresponding with the site of stricture, followed by a vertical suturing of the wound. Chiefly resorted to in non-malignant stricture of the pylorus.

Preparation—Position.—As for Gastrostomy.

Landmarks.—Linea alba—for median incision;—right rectus—for incision through rectus.

Incision.—(1) Incision is generally made in the median line, beginning a short distance below the xiphoid cartilage and extending nearly to, or beyond, the umbilicus. (2) A better approach to the site itself, though with more injury to the abdominal wall, is accomplished by a vertical incision through the outer third of the right rectus muscle. The median incision will be used in the operation which follows.

Operation.—(1) The abdominal cavity having been opened—hemorrhage is controlled—and the edges of the wound, especially on the right side, are well retracted. (2) The pylorus is isolated (any slight adhesions being separated by blunt dissection) and brought into the abdominal wound as well as possible. Neighboring regions are well guarded by gauze packing. (3) Incise longitudinally through the anterior wall of the pylorus, beginning over the gastric aspect and ending over the duodenal aspect of the pylorus,

and extending along midway between the superior and inferior borders of the pylorus—through all the coats. (Fig. 473.) The incision, at first, is about 2 cm. ($\frac{3}{4}$ inch) long. The right index-finger is then inserted through this opening and passed on into the pylorus, to determine the degree of constriction and the thickness of the wall, by palpation between the internal finger and external thumb. The incision is now continued through the strictured portion on into the healthy duodenum and stomach—and is generally about 5 cm. (2 inches) long. (4) By means of wound-hooks, or silk

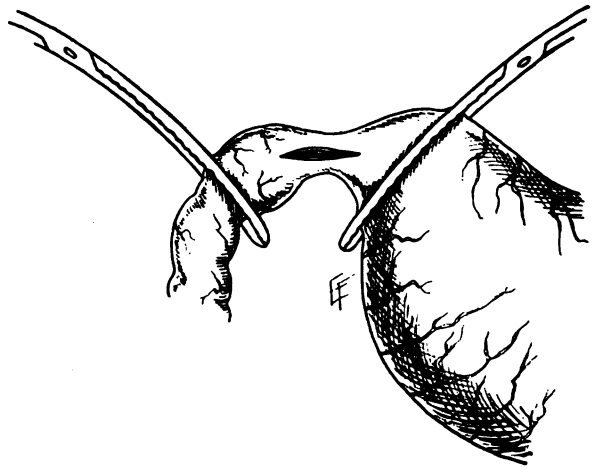

Fig. 473.—PYLOROPLASTY:—I. Longitudinal incision in anterior aspect of constricted pylorus—which is shown clamped off proximally and distally.

Figs. 474 and 475.—PYLOROPLASTY:—II. Longitudinal incision converted into transverse wound by suturing; A, Tier of sutures through all coats; B, Tier of sutures through serous and muscular coats. III. Showing the site sutured.

retractors, inserted at the center of either side of each lip, draw upon the margins until the longitudinal wound first becomes diamond-shaped, and then transverse—and while held in this last position the sutures are applied. (5) The mucous membrane may be first sutured with continuous silk suturing, or sutures may pass through all the coats. (Figs. 474 and 475.) Interrupted silk Lembert sutures are then introduced through serous and muscular coats. If indicated, a third continuous Lembert suture may be applied. (6) The

parts are then thoroughly cleaned and dropped back into position—and the abdomen closed in the usual manner.

Comment.—(1) In a very dense, thick wall, a small diamond-shaped excision may be made—to aid in the approximation of the two edges. (2) Suturing may be done as above, but over an absorbable tube. (3) The site of operation should be clamped on both sides.

DIVULSION OF PYLORIC ORIFICE OF STOMACH.

LORETA'S OPERATION.

Description.—The cavity of the stomach having been entered by gastrotomy, the constricted pyloric orifice is dilated either by finger or instrument. Chiefly resorted to in non-malignant stricture.

Preparation—Position—Landmarks—Incision.—As for Gastrotomy by median incision.

Operation.—(1) Median abdominal section is done—and the abdominal walls retracted. (2) The pylorus is isolated and brought as well into the wound as possible—exactly as in Pyloroplasty. The region is well packed off with gauze. (3) Incise the anterior stomach-wall vertically, at a distance of about 5 cm. (2 inches) from the pylorus, and midway between the upper and lower curvatures—at first, to an extent only sufficient to admit the index-finger snugly. (4) The right index-finger is immediately inserted through the opening and is made to slowly work its way through the pyloric stricture—while the region is steadied from without by the left hand. Should the stricture be found too tight for the tip of the finger, a dilating instrument may be used first—to be followed by the finger. When the stricture is enlarged sufficiently to accommodate one finger, the stomach wound is enlarged with a blunt bistoury, without withdrawing the first finger, and the middle finger introduced alongside of it. The fingers in the stomach wound prevent any considerable hemorrhage—the vertical direction of the gastric incision also aiding in this respect. Even a third finger may be introduced. (5) The object having been accomplished—the fingers are withdrawn—and the hemorrhage from the stomach wound is controlled by clamping and twisting, or by gut-ligaturing. (6) The wound in the stomach is then sutured in the ordinary manner—or as in Pyloroplasty. (7) The abdominal wound is closed in the usual fashion.

Comment.—(1) Incision into the stomach may be parallel with its length and just to the left of the pylorus—as in Pyloroplasty. (2) Loreta inserted both index-fingers and stretched in opposite directions. (3) In Hahn's operation, no opening is made into the stomach—the neighboring stomach-wall is simply invaginated into the pylorus upon the end of the finger.

DILATATION OF CARDIAC ORIFICE OF STOMACH.

See under Retrograde Dilatation of Esophagus, page 562.

PYLORECTOMY

IN GENERAL.

Pylorectomy consists in the excision of the pylorus, together with as much of the stomach and duodenum as may be necessary. Generally resorted to in cases of malignant growth of the pyloric end of the stomach. The operation

is sometimes called partial gastrectomy, especially where a considerable portion of the stomach is removed.

After all pylorectomies an additional operation is always necessary, uniting the lower intestinal tract with the stomach. The cut end of the duodenum is the part generally united to some part of the stomach—though the cut end of the duodenum may be closed by suture and the jejunum united. The anastomosis may be by simple suturing or by some form of mechanical device.

PYLORECTOMY FOLLOWED BY POSTERIOR GASTRO-DUODENOSTOMY.

BY KOCHER'S METHOD.

Description.—This operation consists in the excision of the pylorus, with as much of the adjacent stomach and duodenum as indicated—followed

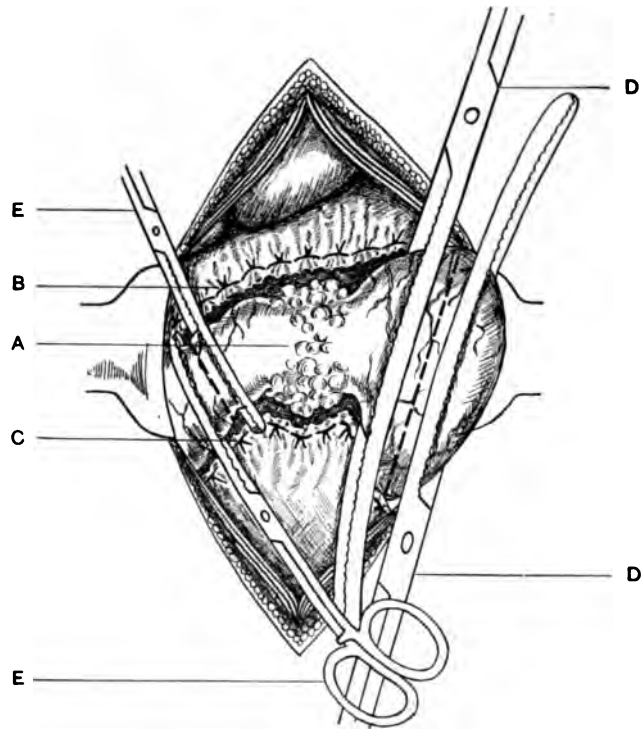

Fig. 476.—PYLORECTOMY, FOLLOWED BY POSTERIOR GASTRO-DUODENOSTOMY (KOCHER'S OPERATION):—A, Pylorus, with involved malignant growth to be removed; B, Lesser omentum ligated off; C, Greater omentum ligated off; D, D, Clamps placed on either side of line of future incision through stomach; E, E, Clamps similarly placed upon duodenum. (Modified from Kocher.)

by a complete closure, by invaginating and suturing, of the pyloric end of the stomach—and an approximation of the cut end of the duodenum to the posterior aspect of the stomach near its excised end.

Preparation—Position—Landmarks.—As for Gastrotomy by median incision.

Incision.—About 10 to 15 cm. (4 to 6 inches) in length—beginning a short distance below the ensiform cartilage, and extending as far as necessary below the umbilicus, in the median line.

Operation.—(1) Perform ordinary median abdominal section—excise the umbilicus—control hemorrhage—retract lips of wound. Bring into the wound the involved parts, lifting them as far out of the abdominal cavity as possible. (2) Ligate off the lesser and greater omenta for an extent corresponding to the area involved and sever with scissors from the stomach and duodenum, near the visceral borders. Ligate all bleeding vessels with gut. Isolate the parts from which the omenta have been separated—and protect, with gauze packing, the underlying and adjacent parts from the

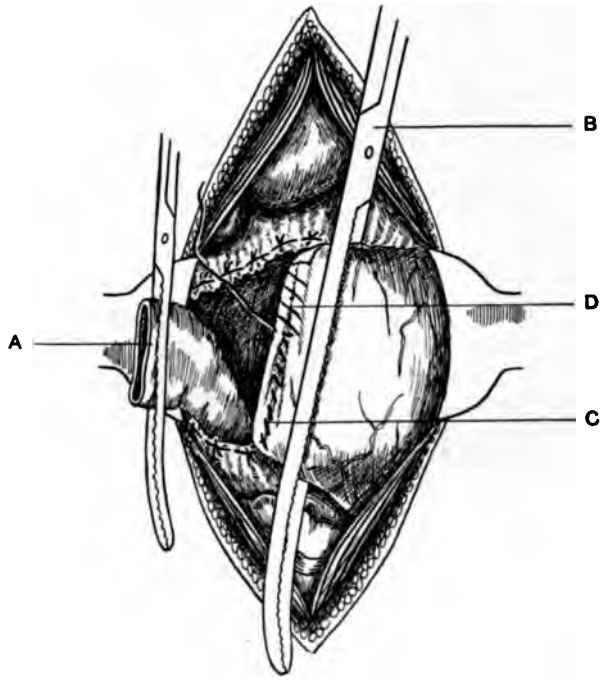

Fig. 477.—PYLORECTOMY, FOLLOWED BY POSTERIOR GASTRO-DUODENOSTOMY (KOCHER'S OPERATION):—II. A, Clamped duodenum turned to one side; B, Clamped stomach steadied by clamps during suturing; C, Suture of all coats of stomach; D, Continuous Lembert sutures of outer coats. (Modified from Kocher.)

stomach and intestinal contents. (Fig. 476.) (3) A clamp is placed upon the duodenum just distal to the part to be removed—and a second clamp about 2.5 cm. (1 inch) still distal to the first, and parallel with it, the handles of the clamps lying in opposite directions. Two clamps are now placed across the pyloric end of the stomach, in the same line, on the cardiac side of the growth —one being placed from the lesser and one from the greater curvatures, their ends overlapping. (4) The duodenum is now cut through between its two clamp—the edges of the distal end being disinfected with 1 : 1000 bichloride, and turned over the right edge of the wound—and the proximal end wrapped in gauze and lifted out of the wound. (5) An assistant, using his forefingers and thumbs (or first and second fingers) as a second pair of

clamps, seizes the stomach from above and below, a short distance to the cardiac side of the stomach clamps—and compresses the stomach firmly, gauze being placed to catch any leakage from the stomach. The stomach is now cut through between the two stomach clamps—and the growth removed—and all bleeding vessels ligated with gut. (6) The cut edges of the stomach are now first sutured with continuous silk suture, passing through all three coats in an overhand, or whipping fashion—approximating the anterior and posterior walls. All projecting mucous membrane is disinfected with bichloride. This line of primary suturing is then invaginated by a second line of continuous silk Lembert sutures of serous and muscular coats —thus burying in the first line and extending a short distance beyond its ends.

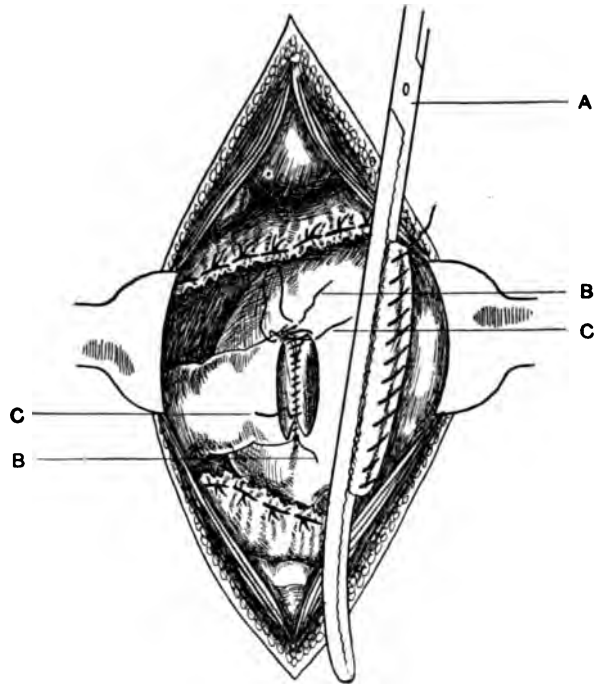

Fig. 478.—PYLORECTOMY, FOLLOWED BY POSTERIOR GASTRO-DUODENOSTOMY (KOCHER'S OPERATION):—III. A, Clamp holding stomach forward while duodenum is being sutured to its posterior aspect; B, B, Line of continuous Lembert sutures uniting outer coats of stomach and duodenum; C, C, Line of continuous overhand sutures through all coats, uniting their edges. (Modified from Kocher.)

(Fig. 477.) (7) The assistant, holding the stomach in both hands, so manipulates it as to direct its posterior wall to the front and to the right, compressing the duodenum between the stomach and right edge of the abdominal wound and thus closing the lumen of the gut. While the stomach is thus held, the posterior aspect of the duodenum (still in the grasp of the forceps) is applied to the posterior wall of the stomach (the serous surfaces of both being in contact). (Fig. 478.) (8) A continuous posterior serous suture of silk is now placed between the serous and muscular coats of the posterior wall of the stomach and the posterior aspect of the duodenum thus approximated, from the upper to the lower border of the intestine—both ends of the suture being left long after knotting, and the needle threaded to the lower one.

These sutures in the intestine are placed sufficiently far from its extreme end to leave the circumference of the extreme end of the gut free for suturing to the stomach opening. The hitherto retained forceps are unclamped from the duodenum—(unless a pair should be kept on further down)—and whatever leakage occurs is caught upon gauze—the lumen of the gut is then disinfected—and the vessels are gut-ligatured. (9) The posterior stomach-wall is now incised vertically about 1.2 cm. (½ inch) from the posterior serous suture just inserted, and for a distance equal to the breadth of the duodenum. Bleeding vessels are gut-ligatured. (10) A continuous silk ligature is now passed, upon curved needle in holder, uniting the edges of the cut end of the duodenum to the edges of the stomach opening, passing through all the coats of both viscera, around the entire circumference. This line of suturing is chiefly for strength. If preferred, two rows may be used—one of the mucous membrane—and one of the serous and muscular coats. (11) Taking up now the still threaded end of the posterior serous suture, that line of continuous suturing is continued around the anterior aspect, forming the anterior serous suture, passing through the serous and muscular coats of the intestine and stomach, until the surfaces throughout the entire circumference are approximated, and is then tied to the opposite free end of the suture. (12) The parts are then thoroughly cleaned and disinfected and dropped back into place. (13) Prior to the return of the parts to the abdomen, the free edges of the lesser and greater omenta should be gut-ligatured to the upper and lower margins, respectively, of stomach and intestine at the site of operation. (14) The abdominal wound is then closed as in ordinary median abdominal section.

Comment.—(1) The omenta can be ligated off conveniently with Cleveland's ligature-carrier, or an aneurism-needle. (2) The division of the stomach and intestines is usually made with scissors. (3) A rather long abdominal wound may be needed to enable sufficient lateral displacement to the right to expose the gastroduodenal site sufficiently for the necessary technique, upon the accuracy of the details of which so much depends. (4) The Murphy button may be used for the approximation, after the excision of the growth by the above method. (5) A second pair of stomach clamps may be used instead of the fingers of an assistant.

PYLORECTOMY FOLLOWED BY END-TO-END GASTRO-ENTEROSTOMY.

BILLROTH'S OPERATION.

Description.—Following the excision of the pylorus, together with the adjacent involved portions of the stomach and duodenum, the large opening left in the pyloric end of the stomach having been lessened by suturing to the size of the lumen of the duodenum, the two viscera are anastomosed by simple suturing, end to end.

Preparation—Position.—As for Gastrotomy.

Landmarks.—Right rectus muscle.

Incision.—Vertical, in the outer third of the right rectus, beginning a short distance beneath the costal arch and extending downward to or below the level of the umbilicus. Various incisions have been used;—A median incision, which does not so readily expose the parts;—An obliquely transverse incision 10 to 12.5 cm. (4 to 5 inches) long, having one-third of its length to the left, and two-thirds to the right of the linea alba, and crossing that line obliquely downward from left to right, between the xiphoid cartilage and

umbilicus, Billroth's original line, which necessitates much transverse division of muscle, though better exposing the parts.

Operation.—(1) Expose the peritoneal cavity in the usual manner of abdominal section by vertical incision through the outer third of the rectus muscle—control hemorrhage and retract the margins of the wound. (2) The site of the operation is carefully located and packed off with gauze—slight adhesions being broken down by blunt dissection—and the parts brought as well forward into the wound as possible. (3) The lesser and greater omenta are ligated off along the area corresponding with the parts to be removed—by gut-ligature carried by an aneurism-needle, or Cleveland ligature-carrier—along the upper and lower borders of the pyloric end of the stomach and duodenum. (4) As soon as freed from omental attachment, the contiguous portions of the stomach and intestine are to be packed off with especial care from the general cavity and adjacent structures with gauze. Two clamps are now placed upon the duodenum, parallel with and about 2 cm. (¾ inches) apart, on

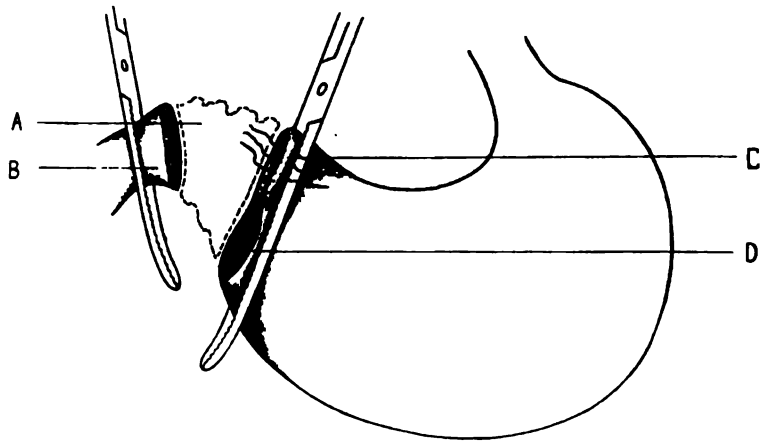

Fig. 479. PYLORECTOMY (BILLROTH'S OPERATION):—I. A, Malignant pylorus excised; B, Free end of duodenum; C, Portion of stomach-opening in excess being closed by interrupted sutures of all coats, followed by interrupted Lemberts of the outer coats; D, Remaining portion of stomach-opening to be sutured to the duodenum.

either side of the line to be incised. Two are similarly placed upon the stomach about 2.5 cm. (1 inch) apart. The lines of incision are so calculated that they will be parallel. (5) The duodenum is first divided between the clamps, with scissors. All leakage is carefully caught and the interior of the free end of the gut cleaned. The stomach is then similarly dealt with The excised portion is now removed. The free ends of the stomach and intestine are brought well forward and abundant packing placed posteriorly. The clamps are retained as convenient means of aiding in the manipulation of the parts. (6) In order to provide a lumen of stomach at the pyloric end which will correspond with that of the duodenum, all that portion of the cut edges of the stomach in excess of the required lumen is closed. This is done by a continuous overhand silk suture including all the coats of both edges of the stomach. It begins at the lesser curvature and is carried downward the required distance—leaving unsutured, next to the greater curvature, a lumen of stomach which will corre-

spond in size with the opposite lumen of duodenum. A line of continuous or interrupted chromic gut Lembert sutures immediately buries in this first line of silk suturing, passing through the serous and muscular coats of the stomach, on either side of the first suture line and thus invaginating it. (Fig. 479.) (7) The free edges of the openings in the duodenum and stomach are then approximated by an assistant who holds them in apposition by means of the clamps. By means of a continuous or interrupted silk suture including all the coats of intestine and stomach, the duodenum is sutured to the remaining opening in the stomach—the parts being so turned, as the suturing progresses, as to present the entire circumference. This line of sutures is chiefly for strength. (8) The line of continuous circular suturing just applied is immediately followed by a second tier of interrupted silk Lembert sutures passing through serous and muscular coats of both viscera, thereby burying in by invagination the first tier. This second line of suturing is chiefly for occlusion. (Fig. 480.) (9) The clamps being relaxed and all parts being thoroughly

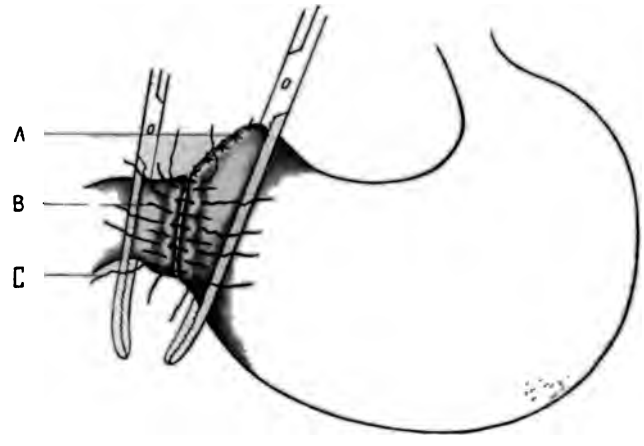

Fig. 480.—PYLORECTOMY (BILLROTH'S OPERATION):—II. A, Upper portion of stomach-opening sutured; B, Interrupted sutures of all coats uniting duodenum to lower portion of stomach-opening; C, Interrupted Lemberts uniting outer coats. The greater curvature of stomach is here restored.

cleansed, the lesser and greater omenta, which had been previously ligated and detached, are now resutured with gut to the upper and lower borders of the attached stomach and duodenum. (10) The parts are then dropped back into place and the abdomen closed.

Comment.—(1) The above is the description of Billroth's operation in the main—the line of incision, the manipulation of the parts, and especially the method of suturing being simplified. (2) If indicated, after excision of the pyloric end of the stomach, the large opening may be closed to fit the duodenum by being sutured partly from the lesser curvature downward and partly from the greater curvature upward. Again, the junction may be made continuous with the lesser curvature—though the stomach is better emptied when made continuous with the greater curvature. (3) Murphy's button may be used in accomplishing the approximation. Still other forms of operation are the following;—Pylorectomy with gastro duodenostomy by union of the stomach and duodenum over decalcified bone tube;—Pylorectomy with posterior gastro-

jejunostomy by means of Murphy's button;—Posterior gastro-jejunostomy at first sitting, followed by pylorectomy at second sitting (Czerny);—Pylorectomy with gastro-duodenostomy by Senn's plates;—Pylorectomy with gastro-jejunostomy by Maunsell's method.

PARTIAL GASTRECTOMY, FOLLOWED BY GASTRO-JEJUNOSTOMY, TOGETHER WITH CLOSURE OF DUODENUM AND JEJUNO-JEJUNOSTOMY.

Description.—This operation is practically similar to Kocher's Pylorectomy followed by Posterior Gastro-jejunostomy—except that a larger portion of the stomach than simply the pylorus is removed. In the following operation the distal half (pyloric) of the stomach will be excised. The end of the duodenum is then closed—a convenient loop of the jejunum is approximated to the posterior wall of the stomach—and a jejuno-jejunostomy is made a short distance below the gastro-jejunostomy. This operation is indicated in those cases where it is necessary to remove more stomach than simply the pylorus, and not so much as the whole stomach.

Preparation—Position—Landmarks.—As for median abdominal section.

Incision.—In the median line—from the ensiform cartilage to or below the umbilicus.

Operation.—(1) Open the abdominal cavity—control hemorrhage—retract wound—and bring stomach and duodenum as well forward as possible. (2) The lesser and great omenta are ligated off with chromic gut close to the stomach and duodenum and corresponding with the area to be removed—going somewhat beyond in either direction. Gauze packing is then placed beneath and behind these structures. (3) Two long stomach clamps (preferably of the Kocher type) are placed parallel with each other and about 2.5 cm. (1 inch) apart, with handles in opposite directions, upon the stomach—and two upon the duodenum—thus isolating the involved area, but being placed well beyond that area. (4) The duodenum is now divided with scissors between its two pairs of clamps—all leakage being caught in gauze. The diseased end is wrapped in gauze—and the lumen of the sound end, held between the clamp, is dried and also wrapped in gauze. (5) The stomach is similarly divided between its clamps and similarly treated. (6) The edges of the stomach wound, still held by the clamp, are closed by a continuous silk suture including all coats. (7) The edges of the duodenal wound are sutured in the same manner. (8) The first row of continuous silk sutures in the stomach is now buried by interrupted Lemberts of chromic gut, thus invaginating it into the lumen of the stomach. (9) The first continuous row of sutures in the duodenum is similarly invaginated into the lumen of the gut by a row of interrupted chromic gut Lembert sutures. (10) A loop of the jejunum, as near to the stomach as convenient, is now anastomosed with the posterior gastric wall near its greater curvature—exactly as is done in Posterior Gastro-jejunostomy by Von Hacker's method (page 783). (11) A short distance below the gastro-jejunostomy an anastomosis between two convenient loops of jejunum is performed (Jejuno-jejunostomy—Braun's operation), which is done largely to prevent regurgitation into the stomach and stagnation of food and bile in the duodenum. (12) The severed omenta are sutured into as normal a position as possible. (13) The viscera are returned to place—and the abdomen closed.

TOTAL GASTRECTOMY.

Description.—Consists in the total removal of the stomach. Following the removal of the stomach, anastomosis is at once made between the esophagus and some part of the small intestine. When circumstances permit of sufficiently easy approximation of the cut end of the duodenum to the cut end of the esophagus, esophago-duodenostomy is performed. Where this is impossible, the free end of the duodenum is closed, and a loop of the jejunum is anastomosed with the esophagus, constituting esophago-jejunostomy.

Preparation—Position—Landmarks.—As for Gastrotomy by median incision.

Incision.—In the median line, from the xiphoid cartilage to or below the umbilicus.

Operation.—(1) Expose the peritoneal cavity—control hemorrhage—retract the wound. (2) The stomach and duodenum are brought to view—adhesions, if any, being separated by blunt dissection, or divided between double ligatures—and these viscera are then brought as well forward as possible. (3) The lesser (gastro-hepatic) omentum is ligated off with silk near the duodenum and lesser curvature of the stomach—beginning at the duodenum and extending toward the esophagus. When 8 to 10 cm. (3 or 4 inches) have been thus ligated, the greater omentum is similarly ligated off, beginning at the duodenum and following along the greater curvature. After 8 to 10 cm. (3 or 4 inches) of this omentum is ligated, the ligaturing is interrupted here and resumed along the lesser omentum—and thus alternating upon the two omenta, manipulating and rotating the stomach as indicated, both omenta are entirely tied off. (4) The duodenum is now clamped off with two parallel clamps and divided between them—the adjacent regions having been packed off with gauze. Both free ends are also well protected with gauze (the duodenum being well cleansed)—the clamps being left *in situ*. (5) The gastro-splenic omentum is ligated off and divided—and also the gastro-phrenic omentum. (6) While some tension is being exercised upon the stomach to draw the esophagus downward, a clamp is placed upon the esophagus as high up as possible. Another esophageal clamp is placed just below the site at which division is to be made. The esophageal end of the stomach is then divided between the clamps, the freed ends being treated as above described, the esophageal end being particularly cleansed and protected. (7) An attempt is then made to approximate the duodenum and esophagus, and if the ends come together without too much tension, they are at once united. If the esophageal end of the stomach (especially when much of the cardiac end is left) be too large, it is sutured down to fit the duodenum (as described under Pylorectomy). In Schlatter's operation, the duodenum was sutured to the esophagus in the following manner;—the mucous membrane of the esophagus was united to that of the duodenum by continuous silk suture;—the serous and muscular coats of each viscus were then united by continuous suture; and both of these were followed by a row of Lembert sutures. The clamps are then removed. (8) If the duodenum cannot be made to easily reach the esophagus, the duodenum is closed at its free end and the nearest coil of jejunum is anastomosed to the esophagus (esophago-jejunostomy)—followed, if thought best, by an anastomosis of the two coils of jejunum lower down (jejuno-jejunostomy). (9) The omenta are sutured into as nearly a normal position as possible. (10) The viscera are replaced and the abdomen closed.

Comment.—(1) In tying off the great omentum, pass a finger behind to avoid tying off the mesocolon—which has been done by the best surgeons. (2)

It is well to leave as much of the cardiac end of the stomach as possible—to increase the ease of approximating the duodenum—excess of cardiac end being sutured down to fit the duodenum, as in gastro-duodenostomy. (3) Displacement of the left lobe of the liver, temporarily, aids in giving room. (4) As the esophagus is more brittle than the stomach, it is well, where possible, to leave enough of the latter for suturing to the duodenum. (5) Brigham, not having sufficient room for simple suturing, united duodenum and esophagus with No. 3 Murphy button, without any subsequent suturing. (6) Delatour used temporary abdominal drainage.

OPERATION FOR GASTRIC ULCER.

Description.—The nature of the operation will depend upon the nature and position of the ulcer. According to Welch, the most frequent sites of gastric ulcers are as follows;—Upon the lesser curvature, 36 per cent.; posterior wall, 29 per cent.; pylorus, 12 per cent.; anterior stomach-wall, 8 per cent.; cardiac end, 6 per cent.; fundus, 3 per cent.; greater curvature, 3 per cent. According to Brinton, 2 per cent. of those which occur on the posterior wall perforate—85 per cent. of those on the anterior wall—40 per cent. of those on the cardia—and 10 per cent. of those at the pylorus.

Preparation—Position—Landmarks—Incision.—As for Gastrotomy by median abdominal section.

Operation for Perforated Gastric Ulcer.—Having exposed and brought into the field, by median abdominal section, the stomach, and located the ulcer, its treatment will depend upon the local conditions found;—(a) Where the walls are pliable and the ulcer small;—Invert the edges of the ulcer with interrupted Lembert or Halsted sutures, without excision of its margins. (b) Where the gastric walls are rigid and thick:—Excise the ulcer elliptically—unite the mucous membrane by continuous silk suture—then the serous and muscular coats with interrupted silk sutures. (c) Where the edges of the ulcer cannot be brought together:—One of the following methods may be used; Patch with omental graft; Plug with omentum, sewing it in; Suture to a neighboring structure; Suture to the abdominal wound and drain; Perform gastro-enterostomy, uniting the incised intestine with the ulcerated stomach-opening (after excising the edges of the latter); Drain the ulcer through the abdominal wound, packing with gauze to make sinus between abdominal wound and ulcer.

Comment.—Non-perforating ulcer may also be treated by excision and gastrorrhaphy. Also see Enterorrhaphy for Wounds of the Intestine, page 670.

VII. THE LIVER.

SURGICAL ANATOMY.

Description.—Presents three surfaces (superior, or phrenic;—inferior, or visceral;—posterior);—two extremities (right and left);—one border (anterior). Its average measurements are transversely, 28 cm. (11 inches)—antero-posteriorly, 20 cm. (8 inches)—vertically, 6 cm. (2½ inches).

Position.—Occupies parts of right hypochondriac, epigastric, and left hypochondriac regions;—situated below diaphragm—above stomach, duodenum, transverse colon, and small intestine—and in front of right false ribs (tenth, eleventh, and twelfth).

Fissures.—Left longitudinal fissure:—Anterior part forms umbilical fissure (for umbilical vein in fetus, and for its remains, the round ligament, in adult);—Posterior part forms fissure of ductus venosus. **Right longitudinal fissure:**—Anterior part, forms fossa for gall-bladder;—Posterior part, fossa for vena cava. **Transverse fissure:**—Transmits hepatic artery, portal vein, hepatic duct, nerves, lymphatics, and connective tissue.

Lobes.—Right, Left, Quadrate, Caudate, Spigelian.

Ligaments and Fixations of Liver.—(1) **Coronary:**—from posterior surface of liver to diaphragm. Formed of two layers of reflected parietal peritoneum. (2) **Right lateral ligament:**—from right lobe of liver to back of diaphragm. Lateral continuation of coronary ligament. (3) **Left lateral ligament:**—from left lobe of liver to diaphragm anterior to esophagus. Lateral continuation of coronary ligament. *Note:*—Middle portion of coronary ligament has its anterior layer furnished by greater peritoneal sac, its posterior layer by lesser sac; Right lateral ligament has both layers from greater sac; Left lateral ligament has both layers from greater sac. (4) **Longitudinal (broad or suspensory) ligament:**—Passes antero-posteriorly upon upper and anterior portion of liver. Posteriorly and superiorly it is connected with the coronary ligament. Anteriorly and superiorly it is connected with the posterior sheath of the right rectus muscle, up to the umbilicus—and thence to under surface of diaphragm, diverging to either side. Free anterior margin extends from interlobular notch to transverse fissure—containing round ligament (remains of fetal umbilical vein). Inferiorly it extends along the superior surface of the liver, from before backward. Formed by portions of peritoneum covering superior surface of liver—one layer passing over left lobe, the other over right, and meeting at longitudinal ligament. (5) **Round ligament:**—Remains of umbilical vein—in free margin of longitudinal ligament, extending from left longitudinal fissure to umbilicus. (6) **Lesser omentum (Gastro-hepatic omentum):**—may be considered a ligament of liver, consisting of following parts;—(**a**) Lig. Hepato-gastricum—from borders of transverse fissure to upper curvature of stomach;—(**b**) Lig. Hepato-duodenale—that part embracing superior curvature of duodenum, and enclosing following structures; common bile-duct, portal vein, hepatic artery, lymphatics and nerves;—(**c**) Lig. Hepato-colicum—that part passing over duodenum to transverse colon;—(**d**) Lig. Hepato-renale—that part from inferior surface of right lobe of liver (near gall-bladder and vena cava, and posterior to foramen of Winslow), to upper surface of right kidney;—(**e**) Lig. Cystico-duodenale—that part from gall-bladder to duodenum. *Note:*—Fusion of upper surface of liver to diaphragm forms a strong fixation of liver.

Peritoneal Covering.—Only portions of liver uncovered by peritoneum are; transverse fissure, fossa of gall-bladder, and postero-superior aspect of right lobe (where fused to diaphragm).

Relations.—(1) **Antero-posteriorly:**—diaphragm (whole of right arch and part of left—which separates liver from right and left lungs and pericardium); abdominal wall; six or seven lower right ribs (seventh to eleventh, according to Morris); fifth to ninth right costal cartilages (sixth to ninth, according to Morris). (2) **Inferiorly:**—stomach (cardiac and pyloric ends, lesser curvature, and part of anterior surface); duodenum (superior curve and descending parts); gall-bladder and cystic duct; portal vessels; right kidney and capsule; colon (hepatic flexion). (3) **Posteriorly:**—diaphragm and crura; tenth and eleventh dorsal vertebræ; tenth and eleventh ribs; esophagus; aorta; vena cava; right suprarenal capsule; thoracic duct.

Vessels of Liver.—Hepatic artery (of cœliac axis), artery of supply;

Portal vein, bringing blood from stomach, intestines, pancreas, and spleen; Hepatic veins, emptying blood of liver into vena cava; Hepatic duct, formed at transverse fissure.

Lymphatics.—Deep set; accompany portal vein, hepatic artery, and duct and join superficial set. Superficial set; empty into (**a**) mediastinal glands; (**b**) sometimes into thoracic duct; (**c**) glands of small omentum; (**d**) lumbar glands; (**e**) glands of esophagus and lesser curvature of stomach.

Nerves.—From left pneumogastric and cœliac plexus.

Structures at Transverse Fissure.—(**a**) Hepatic artery, portal vein, and numerous nerves enter:—(**b**) Hepatic duct and some lymphatics leave:—*Note:* the hepatic veins do not emerge here, but pass backward into the vena cava.

Order of Structures at Transverse Fissure.—From before backward; hepatic duct, hepatic artery, portal vein.

Order of Structures in Gastro-hepatic Omentum.—Common bile-duct, to right; hepatic artery, to left; portal vein, behind and between other two.

SURFACE FORM AND LANDMARKS.

The liver occupies parts of right hypochondriac, epigastric, and left hypochondriac regions—filling all of right and part of left diaphragmatic arches—the diaphragm forming dome of cavity in which liver rests and passing down laterally between ribs and liver.

Upper limit of right lobe—is along line from right fifth chondro-sternal articulation extending horizontally outward to a point about 2.5 cm. (1 inch) below the right nipple—thence downward to seventh rib at lateral aspect of chest.

Upper limit of left lobe—along line from right fifth chondro-sternal articulation extending across sternum slightly downward to a point about 5 cm. (2 inches) to left of gladiolus, on a level with left sixth costal cartilage.

Lower limit of right margin—corresponds with line passing from behind forward about 1.2 cm. (½ inch) below the lower margin of the right thorax to right ninth costal cartilage—thence obliquely across the subcostal angle to left eighth costal cartilage.

Lower limit of left margin—represented by a curved line, with outward convexity, from left eighth costal cartilage to a point 5 cm. (2 inches) to left of gladiolus and on a level with left sixth costal cartilage.

Lower border of liver in middle line—about half-way between xiphoid cartilage and umbilicus.

Convex surface of liver, on right side—corresponds with seventh to eleventh ribs, inclusive—and, in front, with ensiform cartilage and sixth to ninth costal cartilages, inclusive.

Heart descends to left fifth interspace. Right lung descends to superior margin of sixth rib, in the nipple-line.

Note.—Authorities differ considerably upon the relations of the liver to the thoracic wall.

GENERAL SURGICAL CONSIDERATIONS.

The liver may be approached either through the abdominal cavity, the more usual route—constituting a transperitoneal operation;—or through the thoracic cavity—in which latter case the operation may be either transpleural or subpleural, while, at the same time, intrathoracic.

While desirable that all incisions should be in intramuscular cleavage lines

as far as possible, yet, as hernia of the upper abdominal wall is less frequent than of the lower, incisions about the liver and gall-bladder, therefore, often violate this desirable rule.

The two most general methods of transperitoneal approach are the following:—(**a**) By incision parallel with and about 1.2 to 2 cm. ($\frac{1}{2}$ to $\frac{3}{4}$ inches) below the right costal arch, with its center over the indicated site;—(**b**) By incision in the right linea semilunaris (which runs down from the ninth rib to the pubic spine)—or further outward, from the tenth costal cartilage—passing from the lower border of the right costal arch as far down as necessary.

Oblique subcostal incision:—gives better approach to the subhepatic space —and especially to the right end of the liver. It may be extended upward or downward obliquely, parallel with the costal arch. It will cross the external oblique and transversalis at a right angle, and about coincide with the fibers of the internal oblique. It affords a somewhat better chance to preserve some of the abdominal nerves.

Anterior vertical incision:—gives best access to gall-bladder and ducts—together with a very good exposure of the liver. A vertical incision in the right linea semilunaris—or more externally, from the tenth costal cartilage—can be increased directly downward to give room. Its lower end may also be extended transversely, or obliquely, toward the median line—giving an angular flap. A continuation of the original incision gives a very extensive approach to the abdominal cavity—and even the pelvis. The simple vertical incision will cross the external and internal oblique muscles obliquely, and the transversalis at a right angle—and will cross the abdominal nerves at a right angle.

In operating to expose the liver, it will often be found, when the liver is reached, that its serous surface is adherent to the parietal peritoneum—and, therefore, that its substance can be entered without involving the general peritoneal cavity.

As adjuncts to the satisfactory exposure of these sites, the following manœuvres are helpful:—(**a**) the reversed Trendelenburg position—(**b**) firm upward traction upon the liver and right costal arch—(**c**) passage of the left index through the foramen of Winslow and the left thumb over the lesser omentum, thus embracing that structure between the digits.

When the round ligament is encountered descending to the umbilicus and is severed, it should be sutured at the end of the operation.

Standing, the lower border of the liver is about 1.2 to 2.3 cm. ($\frac{1}{2}$ to $\frac{1}{2}$ inch) below the costal cartilages;—reclining, the lower border recedes until about 2.5 cm. (1 inch) above the lower costal cartilages. This change in position, and change during respiration, must, therefore, be allowed for in suturing the liver to the parietes.

Anteriorly, the gastro-diaphragmatic sinus (between the lower edge of the pleura and the diaphragm) makes it possible to reach and pierce the diaphragm more easily and without involving the pleura, in operating intrathoracically,—therefore the subpleural operation is more generally done anteriorly or anterolaterally. This sinus is absent posteriorly, and an incision here would pass through the pleura (if that structure were not raised from the course of incision by blunt separation)—hence the posterior operation is generally transpleural.

In the transpleural operation, where the two layers of pleuræ cannot be sutured *in situ*—the parietal pleura is incised—its edges are grasped with forceps, or traction-sutures (to keep them from receding out of the way)—then the visceral peritoneum is incised—and the edges of the parietal and visceral peritoneum are whipped together by an overhand stitch.

INSTRUMENTS USED IN OPERATIONS UPON LIVER AND GALL-BLADDER.

Scalpels; bistouries; scissors, curved and straight; forceps, dissecting and toothed; artery-clamp forceps; clamp-forceps for adhesions; retractors, various; broad spatulæ; grooved director; tenaculum; costotome; blunt dissector; intestinal clamps; forceps for removing calculi; forceps for crushing calculi; Halsted's hammer; lithotomy scoop (small); lithotomy forceps (small); needles for needling stones; cholelithotomy forceps and scoop; sponge-holders; gauze pads with tails; intestinal and other needles; silk, gut, and silkworm-gut; drainage-tubing, glass-drains, gauze-drains; exploratory cannula and trocar, or exploratory needle; intestinal instruments; Murphy button (special); probe.

EXPLORATORY PUNCTURE OF LIVER.

Description.—Resorted to for withdrawal of fluid for diagnostic purposes—generally pus or hydatid. An operation involving some danger. The site of puncture is generally determined by some physical sign, such as tumor or other indication—and the puncture is made by the safest and most direct route into the site.

Preparation.—Site asepticized.

Position.—Such as to best expose the region.

Landmarks.—Anatomical outline of liver; physical signs.

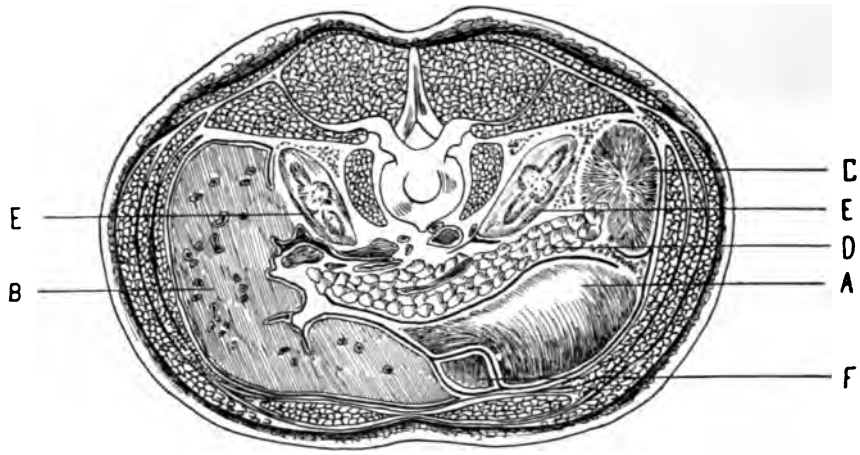

Fig. 481.—Relative Relation of Abdominal Viscera on Level with Lowest Part of Costal Arch (5 cm., or 2 inches, above umbilicus; on a level with second lumbar vertebra):—A, Stomach; B, Liver; C, Spleen; D, Pancreas; E, E, Kidneys; F, Transverse colon. (Modified from Rüdinger.)

Operation.—The exploration is usually made with the needle of an exploratory syringe. The depth of puncture is to be guarded by the right index on the barrel of the needle—and to be largely determined in advance by the estimated thickness of the abdominal or thoracic wall and intervening liver substance at the site to be punctured. If no physical sign guiding to the seat of exploration exist, puncture may be made in several sites:—(1) Laterally,

in the ninth, tenth, or eleventh intercostal space, in the mid-axillary line—the most general position—and the tenth space being the one most frequently used;—(2) Anteriorly, in the subcostal angle, over the known region of the liver (on anatomical grounds)—in the space bounded, above, by the costal arches, and, below, by a line from the right ninth costal cartilage to the left eighth costal cartilage. In abnormal cases, the liver may, of course, be looked for considerably lower than usual;—(3) Posteriorly, in the tenth intercostal space on the right. The liver is in relation, posteriorly, with the tenth and eleventh ribs—and the pleura comes down to the twelfth, or lower—hence the pleura would be pierced if not displaced;—(4) Transthoracic—preferably subpleural—rarely transpleural. See subpleural and transpleural hepatotomy, pages 810 and 812;—(5) Below the free border of the ribs—where the liver dulness extends below;—(6) At any point from which liver substance can be reached with minimum risk and danger—the guides being anatomical and physical. Upon the withdrawal of the needle the puncture-wound is generally sealed with sterile gauze and collodion. (See Fig. 481.)

Comment.—(1) Wounding of the lung should be avoided—and also piercing of the pleura or diaphragm, unless specially indicated. (2) The diaphragm would be penetrated by any puncture above the lower border of the ribs or costal arch. The pleura would be penetrated by any puncture above the eighth right rib in the nipple-line—the ninth right rib in the mid-axillary line—(the tenth left rib in the same line)—and the twelfth right rib in the posterior scapular line. The lung would be penetrated by any puncture above the sixth costo-sternal articulation in front—the sixth right rib in the nipple-line—the eighth right rib at the mid-axillary line—and the right twelfth rib in the scapular line.

HEPATOTOMY IN GENERAL.

(1) Hepatotomy consists in an incision of the liver—and is generally resorted to for abscess, hydatid cyst, or other tumor. The site of the incision is usually determined in advance—by the presence of a tumor, or as a result of an exploratory puncture. (2) The liver may be exposed by the transperitoneal, subpleural, or transpleural routes—and each of these routes may be followed from the anterior, lateral, or posterior aspects of the thoracico-abdominal wall—though each method of approach usually has a site of preference. (3) The selection of the site and method of operation will depend upon the location of the abscess, or other condition—as to its accessibility, importance of contiguous organs, and possibility of drainage. (4) The choice of incision for approaching the liver transperitoneally will generally lie between the oblique subcostal and vertical subcostal incisions—each having its advantages (see General Surgical Considerations). It is to be remembered that abscesses, hydatids, tumors, etc., often project downward considerably below the ribs. It is also to be remembered that, after incision of such sacs and emptying of their contents, there is a tendency for the portion of involved liver to regain its normal position—and that, therefore, in calculating to suture such parts to the abdominal wall for drainage, calculation must be made that the stitching will not draw the part too far out of its natural position. (5) Where no guide exists, the anterior or antero-lateral subcostal transperitoneal route is generally chosen, as, in abscess, pus is usually in the more anterior part of the right lobe. But after exposure of the liver, if, by exploratory syringe, or otherwise, pus be found in a locality more conveniently reached and drained from another external incision, the first incision may be closed and a second made in the in-

dicated position. (6) The different incisions described in the following pages are given to cover the various sites in which the liver may be exposed—and apply as much to the exposure of the liver for other purposes as for incision of that viscus. In the case of pus or hydatids the site of operation will generally have been indicated by a preliminary exploratory puncture. (7) The operation of exposure of the liver may be done in one or in two stages. In operating in one stage, the liver is exposed and the organ is cut into at once—after safeguarding the general peritoneal cavity by suturing the parietal peritoneum to the surface of the liver, or by gauze packing,—or, in transthoracic operations, after protecting the pleural cavity on the same principles. In operating in two stages, the liver is first exposed and the wound then packed with gauze for two or three days, until the peritoneal surface of the liver adheres to the wound (the union being reinforced and aided by sutures, in some cases)—and then the organ is incised. (8) In operating transthoracically, if the pleura be wounded, it should be immediately sutured—with a purse-string suture, if possible, thus drawing the edges together. (9) The subpleural method is generally impossible if adhesions exist—but then, also, the pleural cavity is apt to be shut off—so that it is not opened up even if one passes through its layers. (10) The posterior superior aspect of the right lobe of the liver is fused to the diaphragm (there being no peritoneum here)—hence the diaphragm may be immediately incised in this locality, without waiting for adhesions. An abscess here would be subphrenic and extraperitoneal. (11) If the transpleural method of approaching the liver be adopted, the same principles should be adhered to as in operating transperitoneally—either suture the two opposed pleuræ together and incise through them at once—or press the two pleural surfaces into contact with gauze packing for two or three days, until adhesions occur—and then incise through them. (12) It is preferable to pass beneath the pleura rather than through it—and if they must be incised at once, it is preferable to suture the parietal and visceral layers together preparatory to going through them. The operation of suturing the pleuræ, however, is quite difficult—and the suturing is apt to tear away—or allow of leakage. (13) In cutting into the liver the incisions should be made in straight lines radiating from the direction of the center toward the periphery. (14) Bleeding from deep incisions may be controlled by ligature *en masse*, with interlocked stitches—as described under partial excision of the liver.

ANTERIOR SUBCOSTAL TRANSPERITONEAL HEPATOTOMY

BY ANTERIOR OBLIQUE INCISION PARALLEL WITH COSTAL ARCH.

Description.—The liver is exposed along the right costal arch, by an incision which parallels that arch and is placed 1.3 to 2 cm. (½ to ¾ inch) below it. Resorted to where the more central portion of the anterior aspect of the liver and gall-bladder region is to be exposed.

Preparation—Position.—As for abdominal section.

Landmarks.—Right costal arch.

Incision.—Parallel with and from 1.3 to 2 cm. (½ to ¾ inch) below the right costal arch—beginning near the right linea semilunaris (which runs downward from the ninth rib to the spine of the pubis)—and extends as far downward and outward, below the costal arch, as considered necessary—even to the extent of 12.5 to 15 cm. (5 to 6 inches). (Fig. 452, F.)

Operation.—(1) Incise skin—fascia—external oblique (transversely)—internal oblique (in cleavage line). Superior epigastric artery may be cut at

inner end of incision, if the inner end reaches the outer border of the rectal sheath—if so, it is ligated. The abdominal nerves lie between the internal oblique and transversalis, crossing the line of incision, and an attempt should be made to draw them aside if encountered. The transversalis muscle is then divided obliquely to its fibers. In long incisions, much division of muscles and nerves must occur. In short incisions, much displacement in intramuscular cleavage lines and saving of nerves may be accomplished (Fig. 482). (2) Divide the transversalis fascia, subperitoneal areolar tissue, and peritoneum in the original line—and retract the wound well. (3) Adhesions are looked for as soon as the abdomen is opened. If encountered, intervening between the seat of pus, or hydatid fluid, and the abdominal wall, they are carefully preserved—that they may serve as a protection to the general peritoneal cavity in opening these collections of fluid. If the object be the exposure of the liver

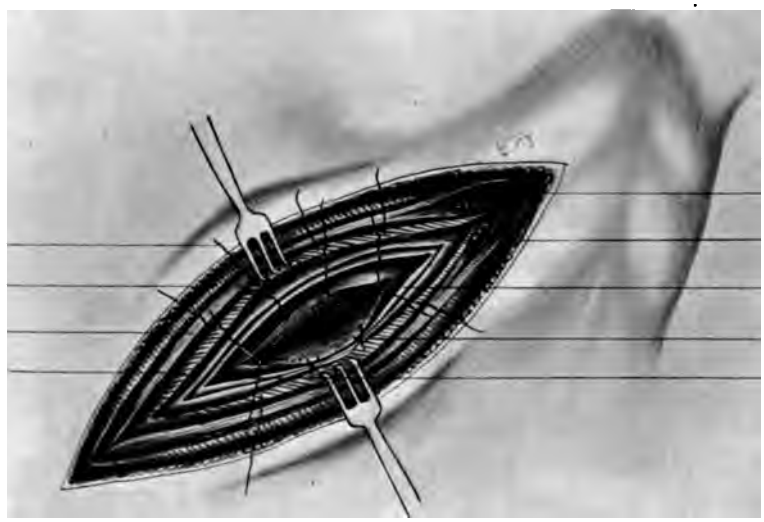

Fig. 482.—Exposure of Liver, and Hepatotomy, by Anterior Oblique Subcostal Incision:—A, External oblique; B, Internal oblique; C, Transversalis; D, Outer border of right rectus incised, showing superior epigastric vessels between muscle and posterior sheath; E, Transversalis fascia and subserous areolar tissue; F, Peritoneum; G, Surface of liver; H, Suture through lip of liver wound, peritoneum, transversalis fascia, subserous areolar tissue, and transversalis; I, Same tightened, approximating lip of liver wound to lower plane of abdominal wound.

on other grounds, the adhesions are separated by blunt dissection, or are divided between ligatures. (4) The liver having been exposed, the operation may be concluded in a single stage, or in two stages:—(**A**) In One Stage;—Where (in pus and hydatid cases) adhesions of parietal peritoneum to hepatic peritoneum have occurred, the incision may be made directly into the liver substance. Where no such adhesions exist, one of two courses may be pursued;—(**a**) The lips of the abdominal wound may be applied to and pressed around the site of the liver to be opened, by the fingers of an assistant and by packing—the tensity of the abscess wall is then lessened (to avoid a gush of pus) by the withdrawal of some of its contents with a syringe—a narrow bistoury is inserted into the abscess and its walls incised—the contents are directed out without escaping into the abdomen—and as soon as the cavity is partly empty,

the edges of the abscess wall, including Glisson's capsule, are seized with special forceps and drawn up into the wound and everted, while the balance of its contents is emptied—the borders of the abscess cavity are then stitched to the edges of the abdominal wound at its lower plane (that is, to the parietal peritoneum, subserous areolar tissue, transversalis fascia, and possibly into the edge of the muscle tissue) with continuous or interrupted silk or chromic gut sutures—closing in either end of the abdominal wound in the usual way—leaving room for the exit of tube or gauze drain. Or, pursuing a second course—(**b**) Before opening the peritoneum, and after recognizing that the parietal and hepatic peritoneal surfaces are not adherent, the parietal peritoneum (by slight outward separation of the extraperitoneal parts of both lips of the wound) may be stitched, with curved needle, to the hepatic surface over an elliptical area, with continuous silk or chromic gut—surrounding and further protecting the area by gauze packing—and then incision is made simultaneously through parietal and visceral peritoneum into the liver—drainage being established and the wound treated as in (a). (**B**) In Two Stages;—This method is practised only where no adhesions are found—and when no haste exists. The parietal peritoneum is united to the serous surface of the liver in one of the two above ways—the gauze packing being preferable to the stitching (or both may be used together)—the wound being packed with gauze, pressing the serous surfaces together for two or three days—after which the incision is made and the operation completed as in (a) above.

Comment.—Where the abscess, or other cavity, is incised before the abdominal wall is sutured to the liver, the suturing of the margin of the cavity to the abdominal wound is aided by inserting the left index-finger into the cavity and hooking it forward—thus holding it in contact with the abdominal wall while the sutures are being placed and tied.

EXPOSURE OF LIVER BY ANTERIOR SUBCOSTAL TRANS-PERITONEAL ROUTE

BY ANTERIOR VERTICAL INCISION THROUGH RIGHT LINEA SEMILUNARIS.

Description.—A free exposure is thus given—which may be lengthened so as to give access to both peritoneal and pelvic cavities. See General Surgical Considerations. The incision may also be placed to the outer side of the right semilunar line.

Preparation—Position.—As for abdominal section.

Landmarks.—Right Linea Semilunaris (which extends from the ninth right costal cartilage to the pubic spine, passing within 7.5 cm. [3 inches] of the umbilicus); right costal arch.

Incision.—Vertically downward in the right semilunar line, beginning at the right ninth costal cartilage and extending as far as necessary (Fig. 452, G).

Operation.—Incise skin—fascia—external oblique (obliquely)—internal oblique (obliquely)—abdominal nerves between internal oblique and transversalis are almost necessarily divided (except in very short incisions they may sometimes be displaced)—transversalis muscles (transversely)—transversalis fascia, subserous areolar tissue and peritoneum—entering the abdomen in the original line. All hemorrhage is controlled—the lips of the wound retracted—and the liver exposed.

EXPOSURE OF LIVER BY LATERAL SUBCOSTAL TRANS-PERITONEAL ROUTE

BY LATERAL HORIZONTALLY CURVED INCISION BELOW RIGHT TWELFTH RIB.

Description.—The general features of the operation are the same as by the anterior oblique subcostal incision—the steps of the operation differing only in so far as determined by anatomical circumstances. Chiefly applicable where the lower lateral aspect of the liver is to be exposed.

Preparation.—As for abdominal section.

Position.—Patient rests upon opposite side, with cushion under the sound side to round out the involved side; Surgeon may stand behind or in front of patient; Assistant opposite.

Landmarks.—Right twelfth rib, in the mid-axillary region.

Incision.—Parallel with and about 1.3 to 2 cm. (½ to ¾ inch) below the right twelfth rib, with its center about opposite the mid-axillary line.

Operation.—Incise skin—fascia—external oblique (obliquely)—latissimus dorsi (transversely, if the incision extend that far backward)—internal oblique (obliquely)—the nerves between the internal oblique and transversalis being guarded as well as possible—transversalis muscle (in cleavage line)—transversalis fascia, subserous areolar tissue, and peritoneum in the original line. All hemorrhage is controlled—the wound retracted—and the liver brought into the field.

Comment.—Unless the liver be enlarged, but small part of its lower border is accessible through this incision—except by the strong upward retraction of the twelfth rib, and the downward retraction of the lower lip of the wound.

EXPOSURE OF LIVER BY INTERCOSTAL SUBPLEURAL ROUTE

BY INTERCOSTAL INCISION BELOW LEVEL OF PLEURA.

Description.—This incision, which is made in an intercostal space below the level of the pleura, rarely gives sufficient room—and is indicated only in cases where abscess or fluid point here and adhesions have, in all probability, protected surrounding regions. In the following description the operation site will be supposed to be in the right tenth interspace, in the mid-axillary line.

Preparation—Position.—As for intercostal thoracotomy (see page 601).

Landmarks.—Right tenth and eleventh ribs, in the mid-axillary line.

Incision.—Midway between lower border of the right tenth and the upper border of the right eleventh rib—in the mid-axillary region.

Operation.—The steps of the operation are the same, practically, as those for Intercostal Thoracotomy (*q. v.*, page 601)—with the exception that in the present instance the incision is made below the level of the pleura. As an operation, owing to the small amount of room which it affords, it is indicated only in those cases in which the liver is supposed to be adherent to the diaphragm opposite the site of incision (either naturally or by pathological process). If during operation it be found that the liver be not adherent to the diaphragm, parts of one or two ribs should be excised—and the operation be completed as given in the following description.

Comment.—The operation is distinctly inferior to the following method.

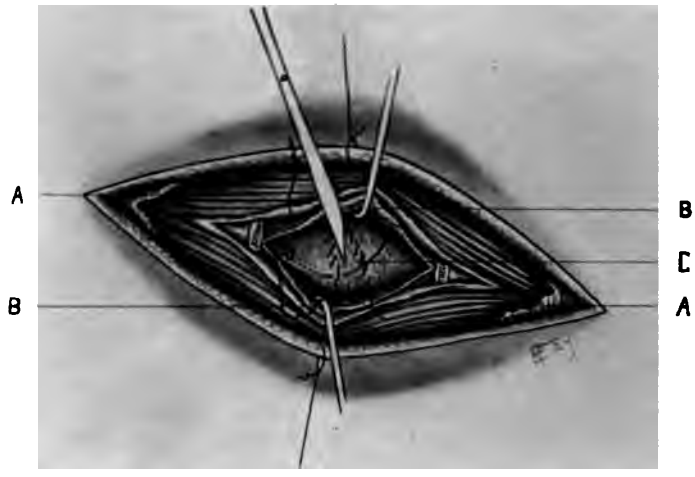

Fig. 483. EXPOSURE OF LIVER BY SUBPLEURAL ROUTE, BY PARTIAL EXCISION OF A RIB BELOW LEVEL OF PLEURA:—A, A, Thoracic muscles; B, B, Anterior and posterior layers of rib periosteum retracted after excising part of rib, both divided longitudinally, and endothoracic fascia seen upon under surface of latter; C, Diaphragm being sutured to convex surface of liver and incised within area elliptically sutured.

EXPOSURE OF LIVER BY SUBPLEURAL ROUTE

BY PARTIAL EXCISION OF ONE OR MORE RIBS BELOW THE LEVEL OF PLEURA.

Description.—The liver is here approached transthoracically, but the incision being placed below the normal level of the pleura, the pleura is not, ordinarily, brought into the field of operation. In the following account, part of the right eleventh rib in the mid-axillary line will be removed.

Preparation Position.—As for Thoracotomy by the partial excision of a rib.

Landmarks. The special rib nearest the site to be exposed.

Incision Operation. As for the Partial Subperiosteal Excision of a Rib (see page 447)—up to the point of the removal of the rib. The posterior layer of periosteum, forming the bed in which the rib has lain, is then incised in its center, in its long axis. If more room be required than furnished by the partial excision of one rib, two or more ribs are excised in part (see page 603). Having passed through the thoracic wall, the diaphragm is exposed and incised in a line corresponding with the direction of its muscle-fibers at the site incised. The edges of the diaphragmatic wound are sutured to the convex surface of the liver, if not already adherent. If adhesions be present, or if haste be necessary, the liver is incised at once. If haste be unnecessary, and no adhesions be present, the wound, after the above suturing, is packed with gauze for two or three days, until adhesions form—and the organ then incised (Fig. 483).

EXPOSURE OF LIVER BY SUBPLEURAL ROUTE

BY PARTIAL EXCISION OF ONE OR MORE RIBS OPPOSITE THE PLEURA

Description. Parts of one or more ribs are excised subperiosteally above the level of the pleura; the pleura is exposed and opened—and is carefully

separated from the thoracic wall and diaphragm and displaced upward—the diaphragm being thus exposed and the liver entered through its substance. In the following account, parts of the seventh and eighth right ribs in the antero-lateral aspect of the chest will be removed.

Preparation—Position.—As for Thoracotomy.

Landmarks.—The rib or ribs overlying the involved site.

Incision—Operation.—(1) The operation is conducted as a Partial Subperiosteal Excision of one or more Ribs (see page 447)—up to the removal of the rib. The Subperiosteal bed of the rib is very carefully incised in the center of its long axis—cautiously recognizing but not incising the costal pleura—which is to be preserved with the greatest care from the smallest cut or tear (on account of the respiratory complications often arising from the entrance of air into the pleura, with the possible collapse of the lung, and the possible infection

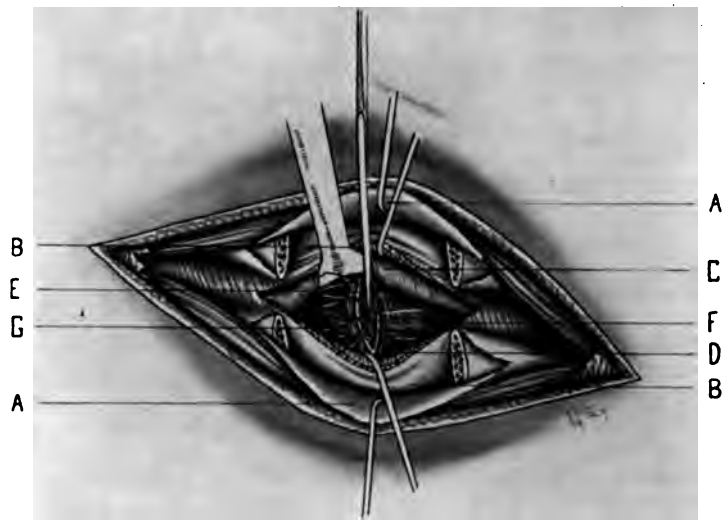

Fig. 484.—Exposure of Liver by Subpleural Route, by Partial Excision of Parts of Two Ribs Opposite the Pleura:—A, A, Upper layer of periosteum and thoracic muscles retracted; B, B, Lower layer of periosteum and intercostal muscles retracted; C, Pleura detached and retracted upward; D, Diaphragm incised; E, Incised margin of parietal pleura; F, Convex surface of liver; G, Sutures uniting edges of diaphragm and parietal peritoneum to surface of liver.

of the pleura). (2) The costal pleura is carefully detached by blunt dissection, largely aided by the back of the surgeon's fingers—first detaching it from the ribs, until its lowest thin edge is reached—then from the upper surface of the diaphragm—and finally displacing it upward and retaining it there by blunt, rounded retractor, or gauze packing. Thus the upper surface of the diaphragm, as far inward as necessary, is freely exposed—with the upper convex surface of the liver immediately below it (Fig. 484). (3) The operation is now completed in one or in two stages:—(a) In One Stage;—The diaphragm is incised over the site of fluid—the edges of the diaphragmatic wound are slightly separated—and these edges are sutured with chromic gut (by means of a curved needle in a holder) to the upper surface of the liver, in the form of an ellipse. If adhesions be present between liver and diaphragm, this suturing is unnecessary. In addition (to either suturing or adhesions), gauze is packed around

the region, further guarding against infection. To relieve the tension part the contents of the cavity is first aspirated. The liver is then incised a drained. The wound is closed up to the site of drainage—so suturing t parts that the thoracic cavity is shut off and the pleura prevented from comi into the region of the wound. (**b**) In Two Stages;—The diaphragm sutured as above to the liver and the wound packed—and, after two or thi days, when adhesions have occurred, the liver is incised and drained—and t wound treated with the same precautions as just given.

Comment.—(**1**) Parts of at least two ribs should generally be excised—give the necessary room to meet the difficulties which are apt to arise in t progress of the operation. (**2**) Where, from the position of the opening it possible to do so, it is well to unite the edges of the diaphragm to the edges the thoracic wound—thus giving freer drainage and better protection of t neighboring parts from infection.

EXPOSURE OF LIVER BY TRANSPLEURAL ROUTE

BY PARTIAL EXCISION OF ONE OR MORE RIBS OPPOSITE THE PLEURA.

Description.—Following the subperiosteal excision of parts of one more ribs, no attempt is made to avoid the pleura, but care is taken not to op it prematurely. After entering the thoracic cavity, in the same manner as the last operation, the costal and diaphragmatic pleuræ are recognized—th surfaces are then sutured together in the form of a circle or an ellipse—and opening is made through their united surfaces—at once if necessary,—aft two or three days if haste be unnecessary. Thus an attempt is made to pi vent the invasion and infection of their cavity. The operation is inferior to t subpleural method, which should always be practised if possible—reserving t method just described for those cases in which the pleura cannot be thus sep rated and pushed above the seat of operation. In the following account pa of the seventh and eighth right ribs will be excised in the antero-lateral aspe of the chest.

Preparation—Position—Landmarks—Incision.—As in the operati last described.

Operation.—Same as in the above operation—except that when the pleu is exposed, instead of detaching and displacing it upward, the costal and di phragmatic pleuræ are sutured together in an elliptical or circular outlir with continuous suture of silk or fine chromic gut carried upon a curved nee in a holder—carefully guarding against opening the pleural cavity in the pr cess of manipulation—it being very difficult to prevent the tearing out of t pleural stitches. The operation may now be concluded in one or in tv stages:—(**a**) In One Stage;—Through the center of the area thus sutured, t two pleuræ are incised—through this incision the diaphragm is exposed—t margins of the pleuræ are now sutured as one layer to the diaphragm, over elliptical area, with continuous suture of silk or fine chromic gut, carried up a fully curved needle in a holder—the surrounding area is packed off wi gauze, in addition—the diaphragm is incised—and the edges of the diaphrag are stitched, in turn, to the liver with chromic gut—after which, the tension the abscess is partly relieved by aspiration—the liver then being incised—drai age established and the wound partly closed. (**b**) In Two Stages;—Same in the single-stage method—except that after suturing the double layer pleura together, and, at the same time, to the diaphragm, in the form of a cir or ellipse—the area is packed with gauze for two or three days—after which t

operation is completed as above. In such cases, the diaphragm will usually be found adherent to the liver (when the operation falls over the peritoneal aspect of the liver). If, however, upon exposing the liver through the diaphragm, no adhesions are found, the margins of the diaphragmatic wound can be stitched to the liver surface—the wound packed and two or three days longer waited, if haste be unnecessary.

Comment.—(1) If the two pleuræ cannot be sutured, and time be available, incise the parietal pleura—pack the wound for a few days, until the two pleuræ have united around the margins—then incise the visceral pleura and diaphragm—similarly stitching the diaphragm to the liver for a few days, if desired. (2) If the situation of the wound make it possible, it is well to suture the edges of the diaphragmatic and thoracic wounds together.

EXPOSURE OF LIVER BY CHONDRO-PLASTIC RESECTION OF RIGHT COSTAL ARCH

BY ANTERIOR OBLIQUE SUBCOSTAL INCISION.

Description.—Where the operation site is encumbered by the bony or cartilaginous thoracic wall, the area may be more satisfactorily exposed by temporarily resecting the right costal cartilage forming the costo-chondral arch—turning it outward—and back into place at the end of the operation. The amount of costal arch to be temporarily resected will depend upon the needs of the special case. Especially is this step sometimes called for in gall-duct surgery.

Preparation—Position—Landmarks—Incision.—As for exposure of liver by anterior oblique subcostal incision.

Operation.—If, in the course of exposure of the liver by the anterior oblique subcostal incision, insufficient room is afforded, the upper margin of the wound is retracted—after extending the original incision in either or both directions, as indicated—and dissected backward sufficiently far to expose the right costal arch—which is then divided with a costotome, above and below, including an extent of from 5 to 10 cm. (2 to 4 inches)—and partially bent, partially broken backward upon itself—thus more freely exposing the liver. At the end of the operation, the costo-chondral margin is then turned back into place—and sutured at either end, if necessary.

HEPATORRHAPHY.

Description.—Suturing of the liver substance. Generally done in the case of wounds of the liver—and in the approximation of the cut surfaces after partial excisions. The liver may be exposed by any of the above operations, according to the circumstances of the case—preference being given to the simplest route.

Preparation—Position—Landmarks—Incision.—As for Hepatotomy (page 806).

Operation.—Having exposed the liver in one of the usual methods—and an assistant having brought the involved region of the organ well into the field—interrupted chromic gut sutures, carried upon a large, fully-curved Hagedorn, or other, needle, are carried through the opposed edges of the wound. Two tiers of sutures are, ordinarily, indicated—coarser gut carried more deeply and further from the edges—and finer gut more superficially and

the region, further guarding against infection. To relieve the tension part of the contents of the cavity is first aspirated. The liver is then incised and drained. The wound is closed up to the site of drainage—so suturing the parts that the thoracic cavity is shut off and the pleura prevented from coming into the region of the wound. (**b**) In Two Stages;—The diaphragm is sutured as above to the liver and the wound packed—and, after two or three days, when adhesions have occurred, the liver is incised and drained—and the wound treated with the same precautions as just given.

Comment.—(**1**) Parts of at least two ribs should generally be excised—to give the necessary room to meet the difficulties which are apt to arise in the progress of the operation. (**2**) Where, from the position of the opening it is possible to do so, it is well to unite the edges of the diaphragm to the edges of the thoracic wound—thus giving freer drainage and better protection of the neighboring parts from infection.

EXPOSURE OF LIVER BY TRANSPLEURAL ROUTE

BY PARTIAL EXCISION OF ONE OR MORE RIBS OPPOSITE THE PLEURA.

Description.—Following the subperiosteal excision of parts of one or more ribs, no attempt is made to avoid the pleura, but care is taken not to open it prematurely. After entering the thoracic cavity, in the same manner as in the last operation, the costal and diaphragmatic pleuræ are recognized—their surfaces are then sutured together in the form of a circle or an ellipse—and an opening is made through their united surfaces—at once if necessary,—after two or three days if haste be unnecessary. Thus an attempt is made to prevent the invasion and infection of their cavity. The operation is inferior to the subpleural method, which should always be practised if possible—reserving the method just described for those cases in which the pleura cannot be thus separated and pushed above the seat of operation. In the following account parts of the seventh and eighth right ribs will be excised in the antero-lateral aspect of the chest.

Preparation—Position—Landmarks—Incision.—As in the operation last described.

Operation.—Same as in the above operation—except that when the pleura is exposed, instead of detaching and displacing it upward, the costal and diaphragmatic pleuræ are sutured together in an elliptical or circular outline, with continuous suture of silk or fine chromic gut carried upon a curved needle in a holder—carefully guarding against opening the pleural cavity in the process of manipulation—it being very difficult to prevent the tearing out of the pleural stitches. The operation may now be concluded in one or in two stages:—(**a**) In One Stage;—Through the center of the area thus sutured, the two pleuræ are incised—through this incision the diaphragm is exposed—the margins of the pleuræ are now sutured as one layer to the diaphragm, over an elliptical area, with continuous suture of silk or fine chromic gut, carried upon a fully curved needle in a holder—the surrounding area is packed off with gauze, in addition—the diaphragm is incised—and the edges of the diaphragm are stitched, in turn, to the liver with chromic gut—after which, the tension of the abscess is partly relieved by aspiration—the liver then being incised—drainage established and the wound partly closed. (**b**) In Two Stages;—Same as in the single-stage method—except that after suturing the double layer of pleura together, and, at the same time, to the diaphragm, in the form of a circle or ellipse—the area is packed with gauze for two or three days—after which the

operation is completed as above. In such cases, the diaphragm will usually be found adherent to the liver (when the operation falls over the peritoneal aspect of the liver). If, however, upon exposing the liver through the diaphragm, no adhesions are found, the margins of the diaphragmatic wound can be stitched to the liver surface—the wound packed and two or three days longer waited, if haste be unnecessary.

Comment.—(1) If the two pleuræ cannot be sutured, and time be available, incise the parietal pleura—pack the wound for a few days, until the two pleuræ have united around the margins—then incise the visceral pleura and diaphragm—similarly stitching the diaphragm to the liver for a few days, if desired. (2) If the situation of the wound make it possible, it is well to suture the edges of the diaphragmatic and thoracic wounds together.

EXPOSURE OF LIVER BY CHONDRO-PLASTIC RESECTION OF RIGHT COSTAL ARCH

BY ANTERIOR OBLIQUE SUBCOSTAL INCISION.

Description.—Where the operation site is encumbered by the bony or cartilaginous thoracic wall, the area may be more satisfactorily exposed by temporarily resecting the right costal cartilage forming the costo-chondral arch—turning it outward—and back into place at the end of the operation. The amount of costal arch to be temporarily resected will depend upon the needs of the special case. Especially is this step sometimes called for in gall-duct surgery.

Preparation—Position—Landmarks—Incision.—As for exposure of liver by anterior oblique subcostal incision.

Operation.—If, in the course of exposure of the liver by the anterior oblique subcostal incision, insufficient room is afforded, the upper margin of the wound is retracted—after extending the original incision in either or both directions, as indicated—and dissected backward sufficiently far to expose the right costal arch—which is then divided with a costotome, above and below, including an extent of from 5 to 10 cm. (2 to 4 inches)—and partially bent, partially broken backward upon itself—thus more freely exposing the liver. At the end of the operation, the costo-chondral margin is then turned back into place—and sutured at either end, if necessary.

HEPATORRHAPHY.

Description.—Suturing of the liver substance. Generally done in the case of wounds of the liver—and in the approximation of the cut surfaces after partial excisions. The liver may be exposed by any of the above operations, according to the circumstances of the case—preference being given to the simplest route.

Preparation—Position—Landmarks—Incision.—As for Hepatotomy (page 806).

Operation.—Having exposed the liver in one of the usual methods—and an assistant having brought the involved region of the organ well into the field—interrupted chromic gut sutures, carried upon a large, fully-curved Hagedorn, or other, needle, are carried through the opposed edges of the wound. Two tiers of sutures are, ordinarily, indicated—coarser gut carried more deeply and further from the edges—and finer gut more superficially and

nearer the edges. The deeper sutures are first tied—then the superficial,—after which the liver is dropped back into place—and the abdomen closed—unless special cause for drainage exist. (See Fig. 485.)

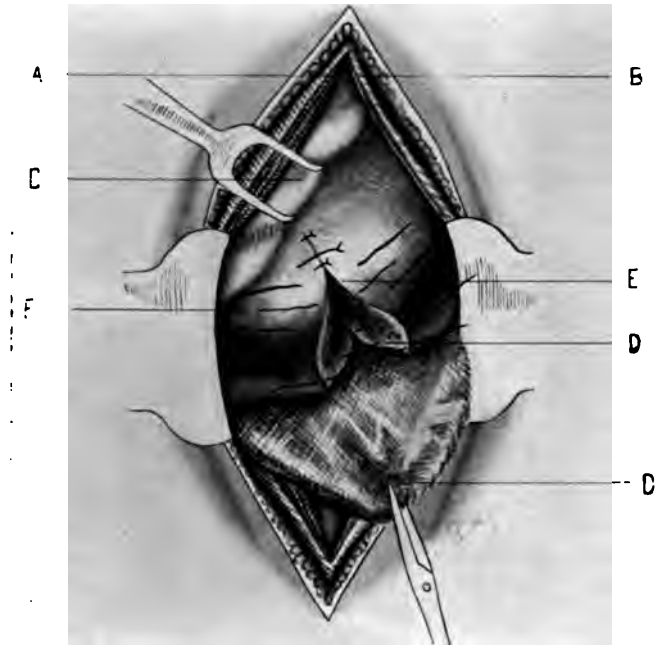

Fig. 485.—Partial Hepatectomy, followed by Hepatorrhaphy:—A, Incised external oblique, internal oblique, and transversalis; B, Incised outer border of rectal sheath; C, Costal arch retracted from liver; D (lower D), Gauze pad packed under liver; E, Borders of liver-wound after excision of wedge; F, Superficial sutures through liver substance; D (upper D), Deep sutures.

HEPATOPEXY.

Description.—Operation of suturing the liver, in whole or in part, to the abdominal wall, or neighboring structures. Resorted to for partial or complete hepatoptosis.

Preparation- Position--Landmarks—Incision.—As for Hepatotomy by anterior oblique subcostal incision.

Operation.—The prolapsed liver having been exposed, the part involved in the prolapse, or the whole liver, if involved in its entirety, is brought into its normal position—and is then sutured with coarse chromic gut, kangaroo-tendon, or silk, to the posterior surface of the anterior abdominal wall. It may also be sutured to the round ligament—to the cartilages of the ribs—or to the general abdominal wall. The sutures are carried deeply into the liver substance with a large, fully curved needle.

PARTIAL HEPATECTOMY.

Description.—Excision of a limited portion of the liver substance. Generally done in the removal of growths.

Preparation—Position—Landmarks—Incision.—As for Hepatotomy by one of the transperitoneal routes—and preferably by an incision parallel with and just below the ribs.

Operation.—(1) The abdomen is opened—and the involved portion of the liver is brought as far forward into the wound as possible. (2) Circumscribe the growth, or part to be removed, by an elliptical incision—the elliptical outline representing the base of a wedge, the sides of which come together within the liver beyond the part to be removed. The ellipse, where possible, is made with its long axis radiating from the center of the liver toward the periphery, and so placed as to avoid the chief hepatic vessels. This area is excised by cutting down along the outline of the incision, the knife traveling at a right angle to the surface—hemorrhage being controlled by pressure and by ligature with chromic gut. (Also see Comment.) (3) The sides of the wound are then brought together by deep and superficial chromic gut sutures—placed and tied as described under Hepatorrhaphy (page 813). (4) Unless drainage be specially indicated, the liver is dropped back into place and the abdomen closed—particularly if the surfaces of the wound be satisfactorily approximated and hemorrhage be entirely controlled (Fig. 485).

Comment.—(1) If the area to be excised is first surrounded by a deeply placed, interlocking chromic gut ligature, hemorrhage is more thoroughly controlled. These ligatures are then drawn tightly enough to cut through the liver substance and bind the vessels before these are cut. (2) Also a heavy ligature may be placed through the liver, surrounding the part to be removed, which is thus tied off in sections—the ligatures being tightened and the part removed with the knife or cautery.

VIII. THE GALL-BLADDER.

SURGICAL ANATOMY.

Description and Position.—Bound to fossa of gall-bladder, upon under surface of liver, by connective tissue and vessels, lying between the right and quadrate lobes—its fundus reaching the abdominal wall anteriorly—and its neck extending to the transverse fissure posteriorly. Its fundus and inferior and lateral aspects are covered with peritoneum reflected from the liver. It sometimes has a mesentery. Its neck points backward and upward, toward the transverse fissure of liver,—its fundus points downward and forward toward the anterior border of liver. Its length is from 7 to 10 cm. ($2\frac{3}{4}$ to 4 inches)—the width of its fundus is from 2.5 to 3 cm. (1 to $1\frac{3}{16}$ inches)—and it holds about 20 c.c.

Relations.—**Superiorly**;—fossa of gall-bladder;—**Inferiorly**;—duodenum (first and second parts); pyloric end of stomach (sometimes); colon (hepatic flexion and commencement of transverse portion);—**Anteriorly**;—abdominal wall; ninth costal cartilage.

Arteries.—Cystic, from right branch of hepatic.

Veins.—Cystic (two) emptying into right branch of vena portæ; others emptying into liver.

Lymphatics.—Run into a gland at its neck.

Nerves.—Supplied by cœliac plexus.

Fixations.—Connective tissue; vessels; peritoneum reflected over under surface of liver; cysto-duodenal ligament (a fold of peritoneum extending from neck of gall-bladder to duodenum).

SURFACE FORM AND LANDMARKS.

The fundus of the gall-bladder projects outward beyond the anterior border of the liver, in the incisura vesicalis—generally resting upon the transverse colon—and coming into contact with the anterior abdominal wall close to the outer border of the right rectus muscle. Authorities differ as to the exact point of contact with the abdominal wall, in relation with the costochondral structures;—according to Morris, the fundus lies opposite the cartilage of the right ninth or tenth rib;—according to Gray, opposite the inferior border of the right ninth costal cartilage;—and according to Treves, below the inner end of the right tenth costal cartilage.

GENERAL SURGICAL CONSIDERATIONS.

(1) The gall-bladder is in relation with the first and second portions of the duodenum, with the hepatic flexure and commencement of the transverse colon, and sometimes with the pylorus. Therefore the gall-bladder could generally be united with either duodenum or colon—but if united to the colon, the function of the bile in the small intestines would be lost—hence the duodenum is the usual site of anastomosis. (2) In examining the gall-bladder and ducts, first pass the left index over these structures, to gain an idea of their size and contents—then let the left index slip through the foramen of Winslow—in which position the left thumb will grasp the ligamentum hepato-duodenale (the right margin of the gastro-hepatic omentum) and press it against the left index—and thus the ducts can be palpated between thumb and index, upward and downward. (3) By drawing upon the gall-bladder, the gall-ducts are rendered more tense and evident. (4) The pedicle of the gall-bladder consists of cystic duct, artery, and veins.

INSTRUMENTS USED IN GALL-BLADDER OPERATIONS.

Mentioned under Instruments used in operations upon the Liver (page 804).

CHOLECYSTOTOMY

BY OBLIQUE SUBCOSTAL INCISION.

Description.—Incision of gall-bladder for removal of its contents—followed by closure at same operation. Usually resorted to for removal of gall-stones in healthy gall-bladder and with unobstructed ducts. The gall-bladder may be exposed by an oblique or vertical subcostal incision—the former generally being accomplished with less damage to the abdominal wall.

Landmarks.—Site of fundus of gall-bladder (opposite lower border of right ninth costal cartilage).

Preparation—Position—Incision—Operation.—Same as for the exposure of the liver by the anterior oblique incision parallel with the costal arch. The gall-bladder is brought into the field—and incised with a sharp knife or scissors—the apex of the fundus (that portion normally in contact with the anterior abdominal wall) being opened in the long axis of the body. Having accomplished the object of the operation, which is generally the freeing of fluid or removal of gall-stones, the bladder is to be closed by two tiers of sutures, introduced with a curved needle held in a holder—the first tier consisting of

fine interrupted gut sutures passing through mucosa and muscularis—and these buried in by a second row of interrupted Lemberts of fine gut (chromic) passing through serosa and muscularis. The gall-bladder is then dropped into place and the abdomen closed—unless it be indicated to temporarily drain from the sutured gall-bladder to the outer wound.

CHOLECYSTOSTOMY

BY OBLIQUE OR VERTICAL SUBCOSTAL INCISION.

Description.—Incision of gall-bladder, followed by suturing of the opened bladder into the abdominal wound for a shorter or longer time. Generally resorted to in cases of gall-stones, or in suppuration. The operation may be done in one or in two stages—in the former case, the gall-bladder is opened at once—in the latter, it is first sutured to the abdominal wall and not opened until after adhesions have formed.

Preparation.—As for median abdominal section.

Position.—As for median abdominal section—or, better, the reversed Trendelenburg position.

Landmarks.—Lower border of tip of right ninth costal cartilage; costal arch; right linea semilunaris.

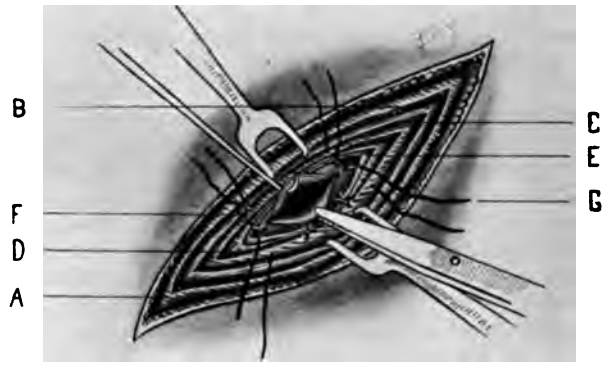

Fig. 486.—CHOLECYSTOSTOMY BY OBLIQUE SUBCOSTAL INCISION:—A, External oblique; B, Internal oblique; C, Transversalis; D, Subserous areolar tissue and transversalis fascia; E, Peritoneum; F, Gall-bladder, its fundus being drawn out of abdominal wound; G, Sutures through transversalis and subserous fasciæ, and through serous and muscular coats of gall-bladder.

Incision.—Oblique or vertical subcostal incision, as for exposure of the liver (see pages 806 and 808, and also General Surgical Considerations in Operations upon the Liver, page 802).

Operation.—Having opened the abdomen by the chosen incision, hemorrhage is controlled, the wound is retracted, and the gall-bladder located. If any adhesions are found, these are separated by blunt dissection, or tied off—and the bladder brought as far out into the abdominal wound as possible (Fig. 486). If much intravesical tension exist, this should be lessened preliminarily by the aspiration of part of the fluid. The operation may now be concluded in one or in two stages;—(**A**) In One Stage:—(**a**) Having partially emptied the gall-bladder by aspiration, and after having packed off the vicinity

with gauze, the bladder is seized with special forceps, a pair in each hand of an assistant—or by two traction-loops passing through the serous and muscular coats—and while thus held as far out of the wound as possible, the fundus of the bladder is incised vertically between the forceps or traction-loops, provision being made for the catching of the fluid. (**b**) Having opened the gall-bladder, and while holding the lips of the bladder wound apart, insert a finger, or special instrument, and pass it down to the cystic duct to examine the contents—removing with special forceps or scoop any calculi found—followed by irrigation or cleansing of the bladder. (**c**) The cystic, hepatic, and common ducts are then carefully palpated. (**d**) In completing the operation, the packing is removed and the excess of abdominal wound is closed in from either end toward the center, in the ordinary manner, leaving a sufficient opening midway between the ends, or in the most convenient site for approximating the bladder. The margins of the gall-bladder are now sutured into the lower edge of the abdominal wound left after the partial closure of the ends of the abdominal incision—in such a way that all the coats of the gall-bladder are sutured to the lower layers of the abdominal wound with fine interrupted chromic gut—so that serous surfaces are approximated, but so that the edges of the gall-bladder wound do not reach to the skin. Or, where sufficient room for manipulation exists, it is better to use two tiers of sutures—the first row of fine gut sutures passing through serous and part of muscular coats of the gall-bladder, on the one hand, and through the parietal peritoneum, on the other,—followed by a second tier suturing all the coats of the gall-bladder to the aponeurotic layer of the abdominal wound. (**e**) A drainage-tube is then generally conducted through the abdominal wound down to the cystic duct. (**B**) In Two Stages;—(**a**) Having closed in the excess of abdominal wound from either end, the fundus of the gall-bladder is sutured into the remaining opened portion of the abdominal wound by interrupted silk or fine chromic gut sutures—passing through the serous and muscular coats of the gall-bladder, on the one hand, and through the parietal peritoneum and the lower layers of the abdominal wound, on the other. (**b**) When adhesions have formed in two or three days, the fundus is incised—as in the single-stage operation.

Comment.—(**A**) In Operating in One Stage;—(**a**) The gall-bladder may be tied with a purse-string around a glass flanged tube, which is then brought out of the abdominal wound. Or a Murphy button-tube, with long cylinder, may be used. The tube or button tied in sloughs out in a few days, by which time adhesions have shut off the cavity. (**b**) Where the gall-bladder is small and contracted, so as not to reach the abdominal wound, the parietal peritoneum may be peeled back from the edges of the abdominal wound and sutured around the wound in the fundus of the gall-bladder. (**B**) In General;—(**a**) It may be possible, by the oblique subcostal incision, to expose the gall-bladder through an intermuscular separation of the external oblique, internal oblique, and transversalis muscles, in the triangular space bounded by the eighth nerve running along the costal arch, the ninth nerve running transversely inward from the level of the lower border of the ninth costal cartilage, and the linea semilunaris. (**b**) Adhesions may have to be separated before the gall-bladder can be brought forward. (**c**) Avoid stitching the gall-bladder to the skin, as such fistulæ are hard to cure. (**d**) Sometimes stones discovered in the ducts can be milked back into the gall-bladder and thence removed. (**e**) In the two-stage operation, the examination of the interior of the bladder and of the ducts is not so satisfactory as in the single-stage operation—nor the removal of stones, if found, so easy.

CHOLECYSTENDYSIS

BY OBLIQUE OR VERTICAL SUBCOSTAL INCISION.

Description.—This operation consists in doing, first, an ordinary Cholecystotomy, after which the steps of the procedure in view are carried out—followed by the closure of the gall-bladder by suture—after which the fundus of the gall-bladder is anchored by suture to the abdominal incision, which is closed over it. Indicated in cases where no obstruction in the ducts exists, and where the opening into the gall-bladder is small and the parts healthy.

The operation throughout is that of a Cholecystotomy—with the addition that, in the act of closing the abdominal wound, the fundus of the gall-bladder, at the site of the incision into the bladder, is sutured in contact with the intra-abdominal aspect of the abdominal wound—in such a position that should it become necessary to open the wound for drainage, or other purpose, the abdominal wound and the bladder wound would lie in the same line.

Comment.—Some drop the gall-bladder back into the abdomen without attachment to the abdominal wall—which would constitute the operation a Cholecystotomy,—while others sometimes do not entirely close the abdominal wound immediately—which would constitute a temporary Cholecystostomy. In suturing the gall-bladder fine gut is preferable, especially where the sutures enter the cavity of the bladder, thus avoiding the retention of unabsorbable sutures, which might become foci of calculous formation.

CHOLECYSTENTEROSTOMY

BY THE MURPHY BUTTON.

Description.—By Cholecystenterostomy is meant the establishment of a communication between the gall-bladder and the small or the large intestine. Preferably the union is made with the duodenum (Cholecysto-duodenostomy), —next, with the upper jejunum (Cholecysto-jejunostomy),—and if these be not easily brought into apposition (because of adhesions, or other conditions), the junction is made with the hepatic flexure of the colon (Cholecysto-colostomy). Union may be accomplished by some mechanical device, of which Murphy's special gall-bladder button is probably the best—or it may be accomplished by simple suturing. The operation is indicated in unremovable obstruction of the cystic or common ducts, in chronic cholecystitis, and in persistent fistulæ following cholecystostomy.

Preparation—Position—Landmarks.—As for Cholecystotomy.

Incision.—A vertical subcostal incision is generally to be preferred. If a tumor exist, the incision is placed over it—if not, it is placed in the right semilunar line, or just to the outer side of it.

Operation.—The steps of the operation are not essentially different from Entero-enterostomy by the Murphy button. (1) The abdomen having been opened, the gall-bladder and duodenum are exposed—and trial is made to ascertain that both structures can be brought into the field and approximated without too great tension. The field is then packed off with gauze. If the bladder be very much distended, the distention is lessened by partial aspiration, that the contents may not be thrown out over the neighboring parts on incising the viscus. (2) The regular purse-string suture (see Fig. 487) is then introduced through all the coats of the gall-bladder, calculating to so place it upon the prominent fundus, or the inferior surface of the gall-bladder, as to make the best approximation with the duodenum, without tension. The bladder-

wall is then incised between the lines of the purse-string suture for a distance equal to two-thirds of the diameter of the special button. The male button, grasped in the usual manner, is insinuated into the opening in the gall-bladder and the walls of that viscus drawn about the cylinder of the button and tied. (3) The female button is similarly introduced into the free aspect of the duodenum and tied. (4) The halves of the button are pressed together—thus completing the cholecysto-duodenostomy. If reinforcing Lembert sutures are considered necessary, they are applied. (5) Unless special cause for drainage exists, the abdomen is closed as after ordinary abdominal section.

Fig. 487.—CHOLECYSTENTEROSTOMY BY THE MURPHY BUTTON:—A, Male button within gall-bladder; B, Female button within duodenum.

Comment.—(1) Union of the gall-bladder to portions of the intestine between the usual site of anastomosis (duodenum, or upper part of jejunum) and the hepatic flexure of the colon, is more apt to be followed by volvulus. (2) Prior to completing the anastomosis, the interior of the gall-bladder should be examined for calculi, and the ducts palpated. (3) The contents of the duodenum should be pressed away from the site of anastomosis and controlled by double clamps during the operation. (4) If more convenient, the smaller female button may be placed in the gall bladder.

CHOLECYSTENTEROSTOMY

BY SIMPLE SUTURING.

Description.—The operation is the same as Cholecystenterostomy by the Murphy button, except that no artificial device is used in accomplishing the union other than simple suturing.

Preparation—Position—Landmarks—Incision—Operation.—Are, in the main, the same as those just described. Having brought the gall-bladder and intestine (preferably the duodenum) into convenient position for manipulation, the two viscera are united in exactly the same manner as in Entero-enterostomy by lateral anastomosis (see Fig. 683). A posterior row of continuous Lembert sutures is introduced through the serous and muscular coats of the two viscera, along their posterior aspects, leaving the threads long at both ends. The two organs are then incised—and the lips of the incision whipped together by an overhand continuous suture of all the coats—after which, the line of continuous Lembert suturing is carried around the anterior aspect of the wound. The opening made in the gall-bladder and intestine is from 1.2 to 2 cm. (½ to ¾ inch) long. The parts are returned to the abdomen, which is closed in the usual manner.

Comment.—(1) The above method of suturing is simpler than to first make the incision and suture together the mucous coats alone—followed by suturing of muscular and serous coats. (2) Sometimes, though rarely, union by simple suturing is done in two, or even in three stages;—(a) In Two Stages;—The gall-bladder and intestine are sutured together by continuous sutures of serous and muscular coats, approximating an area of each equal to about 2.5 by 3.7 cm. (1 by 1½ inches). These viscera are then sutured to the bottom of the abdominal wound and the wound packed for several days. An incision is then made through the intestine—and through this an incision is made through the adherent walls of gall-bladder and intestine. The incised wound in the intestine is then closed—and the abdominal wound also closed. (b) In Three Stages;—The gall-bladder and intestine are sutured together, as in the above. The gall-bladder is then incised and its edges sutured into the abdominal wound (after closing the excess of abdominal wound from the ends). After several days the adherent wall between gall-bladder and intestine is incised through the fistula—which fistula is then allowed to close, or is closed by a plastic operation.

CHOLECYSTO-LITHOTRITY.

Description.—Consists in the exposure of the gall-bladder and crushing of the calculi from the outside, as they lie within the gall-bladder—by means of the fingers or special forceps with protected blades—and manipulating the fragments on into the cystic duct. The operation is sometimes applicable in cases of soft and friable stones. Fragments of hard stones are apt to wound the gall-bladder. Small stones may sometimes be pushed or worked on out of the gall-bladder into the cystic and common duct without being broken.

The steps of the operation are the same as those for Cholecystotomy, up to the point of exposing the gall-bladder—after which it is a process of palpation and manipulation with the fingers, or special protected forceps.

CHOLECYSTECTOMY.

Description.—The total excision of the gall-bladder. Indicated when the gall-bladder or the cystic duct is considerably changed by disease, or where contracted and deep-lying, making difficult the approximation of the gall-bladder to the abdominal wall (cholecystotomy); and where the hepatic and common bile-ducts are patulous.

Preparation—Position—Landmarks—Incision.—As for Cholecystotomy by vertical subcostal incision.

wall is then incised between the lines of the purse-string suture for a distance equal to two-thirds of the diameter of the special button. The male button, grasped in the usual manner, is insinuated into the opening in the gall-bladder and the walls of that viscus drawn about the cylinder of the button and tied. (3) The female button is similarly introduced into the free aspect of the duodenum and tied. (4) The halves of the button are pressed together—thus completing the cholecysto-duodenostomy. If reinforcing Lembert sutures are considered necessary, they are applied. (5) Unless special cause for drainage exists, the abdomen is closed as after ordinary abdominal section.

Fig. 487.—Cholecystenterostomy by the Murphy Button:—A, Male button within gall bladder; B, Female button within duodenum.

Comment.—(1) Union of the gall bladder to portions of the intestine between the usual site of anastomosis (duodenum, or upper part of jejunum) and the hepatic flexure of the colon, is more apt to be followed by volvulus. (2) Prior to completing the anastomosis, the interior of the gall-bladder should be examined for calculi, and the ducts palpated. (3) The contents of the duodenum should be pressed away from the site of anastomosis and controlled by double clamps during the operation. (4) If more convenient, the smaller female button may be placed in the gall bladder.

CHOLECYSTENTEROSTOMY

BY SIMPLE SUTURING.

Description.—The operation is the same as Cholecystenterostomy by the Murphy button, except that no artificial device is used in accomplishing the union other than simple suturing.

Preparation—Position—Landmarks—Incision—Operation.—Are, in the main, the same as those just described. Having brought the gall-bladder and intestine (preferably the duodenum) into convenient position for manipulation, the two viscera are united in exactly the same manner as in Entero-enterostomy by lateral anastomosis (see Fig. 683). A posterior row of continuous Lembert sutures is introduced through the serous and muscular coats of the two viscera, along their posterior aspects, leaving the threads long at both ends. The two organs are then incised—and the lips of the incision whipped together by an overhand continuous suture of all the coats—after which, the line of continuous Lembert suturing is carried around the anterior aspect of the wound. The opening made in the gall-bladder and intestine is from 1.2 to 2 cm. (½ to ¾ inch) long. The parts are returned to the abdomen, which is closed in the usual manner.

Comment.—(1) The above method of suturing is simpler than to first make the incision and suture together the mucous coats alone—followed by suturing of muscular and serous coats. (2) Sometimes, though rarely, union by simple suturing is done in two, or even in three stages;—(a) In Two Stages;—The gall-bladder and intestine are sutured together by continuous sutures of serous and muscular coats, approximating an area of each equal to about 2.5 by 3.7 cm. (1 by 1½ inches). These viscera are then sutured to the bottom of the abdominal wound and the wound packed for several days. An incision is then made through the intestine—and through this an incision is made through the adherent walls of gall-bladder and intestine. The incised wound in the intestine is then closed—and the abdominal wound also closed. (b) In Three Stages;—The gall-bladder and intestine are sutured together, as in the above. The gall-bladder is then incised and its edges sutured into the abdominal wound (after closing the excess of abdominal wound from the ends). After several days the adherent wall between gall-bladder and intestine is incised through the fistula—which fistula is then allowed to close, or is closed by a plastic operation.

CHOLECYSTO-LITHOTRITY.

Description.—Consists in the exposure of the gall-bladder and crushing of the calculi from the outside, as they lie within the gall-bladder—by means of the fingers or special forceps with protected blades—and manipulating the fragments on into the cystic duct. The operation is sometimes applicable in cases of soft and friable stones. Fragments of hard stones are apt to wound the gall-bladder. Small stones may sometimes be pushed or worked on out of the gall-bladder into the cystic and common duct without being broken.

The steps of the operation are the same as those for Cholecystotomy, up to the point of exposing the gall-bladder—after which it is a process of palpation and manipulation with the fingers, or special protected forceps.

CHOLECYSTECTOMY.

Description.—The total excision of the gall-bladder. Indicated when the gall-bladder or the cystic duct is considerably changed by disease, or where contracted and deep-lying, making difficult the approximation of the gall-bladder to the abdominal wall (cholecystotomy); and where the hepatic and common bile-ducts are patulous.

Preparation—Position—Landmarks—Incision.—As for Cholecystotomy by vertical subcostal incision.

Operation.—(1) Having exposed the subhepatic region by thorough retraction, aided by the reversed Trendelenburg position, and packed off the neighboring vicinity with gauze, the gall-bladder is isolated (Fig. 488). (2) The peritoneum binding the gall-bladder to its fossa is incised over the prominent inferior surface of the gall-bladder—either in one straight line in the long axis of the bladder, from fundus to cystic duct—or in the form of an ellipse (especially where the bladder is large), the two limbs meeting at the fundus and cystic duct. (3) This incision having passed simply through the serous covering into the underlying connective tissue, the peritoneum is separated from the gall-bladder by blunt dissection, from fundus to neck, and

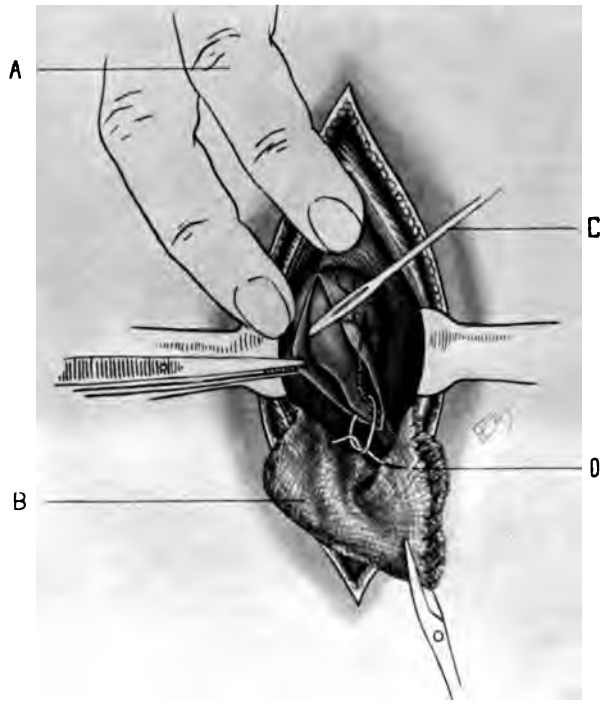

Fig. 488.—Cholecystectomy by Vertical Subcostal Incision:—A, Liver displaced upward, exposing fossa of gall-bladder; B, Gauze pad protecting neighboring structures; C, Longitudinally incised peritoneum over gall-bladder being separated from the bladder by blunt dissection; D, Ligature placed around pedicle of gall-bladder.

throughout its width, and retracted to either side. Having dissected and peeled back the peritoneal covering, the gall-bladder itself is then dissected, or shelled out, by blunt dissection from its fossa and freed to its pedicle—working with curved blunt scissors and a blunt dissector, and keeping strictly in the connective tissue plane. The pedicle, formed by the cystic duct and vessels, is well isolated, doubly ligated with chromic gut, and divided between the ligatures, the adjacent structures having been protected with gauze packing. The end of the divided duct may be immediately cauterized. (4) The divided peritoneum, which has been separated and retracted in the form of two flaps,

is now sutured with gut over the fossa of the gall-bladder. (5) The abdomen is closed—generally without drainage.

Comment.—(1) It may be necessary to separate adhesions by blunt dissection, or by division between ligature. (2) If much distended, the gall-bladder should be first partially emptied by aspiration through a fine needle—the needle wound being subsequently puckered together with a purse-string ligature before manipulating the bladder. (3) Avoid the inclusion of the hepatic and common ducts. (4) The abdominal wound may be closed in part only, leaving a temporary drain.

IX. THE GALL-DUCTS.

SURGICAL ANATOMY.

Hepatic Duct.—Formed by right and left bile-ducts uniting generally at their emergence from the liver. Length from 3 to 5 cm. ($1\frac{1}{4}$ to 2 inches). Diameter, about 4 mm. (nearly $\frac{3}{16}$ inch). Passes downward in right border of gastro-hepatic omentum, having vena cava behind and hepatic artery to left. Unites with cystic duct to form common bile-duct.

Cystic Duct.—Begins at neck of gall-bladder—is directed slightly to left—and ends at its junction with hepatic duct at an acute angle, to form common bile-duct. Length, 2.5 to 4 cm. (1 to $1\frac{1}{2}$ inches). Passes downward, backward, and to left in gastro-hepatic omentum—having hepatic artery to left and portal vein behind.

Common Bile-duct.—Formed by union of hepatic and cystic ducts. Length, about 7.5 cm. (3 inches), dependent upon site of union of cystic and hepatic ducts. Diameter, about 6 mm. (nearly $\frac{1}{4}$ inch). Its course and relations are the following;—continuing the direction of hepatic duct, it passes downward and backward in hepato-duodenal portion of gastro-hepatic ligament, having hepatic artery and its gastro-duodenal branch to left, and portal vein behind and between—enters right pancreatico-gastric fold behind first portion of duodenum (superior curve), then passes between second portion of duodenum (descending part) and head of pancreas—and ends by entering posterior and inner wall of descending portion of duodenum (being crossed on the way by the pancreatico-duodenal artery), running obliquely for about 2 cm. ($\frac{3}{4}$ inch) through its walls and opening upon a papilla of mucous membrane about 10 cm. (4 inches) from the pylorus. The pancreatic duct joins the common bile-duct just before its termination.

SURFACE FORM AND LANDMARKS. INSTRUMENTS.

See these headings under the Liver and Gall-bladder.

GENERAL SURGICAL CONSIDERATIONS.

The common bile-duct lies in the hepato-duodenal ligament, near its right free margin—in the free border which constitutes the fold at the entrance of the foramen of Winslow—the hepatic artery lying nearby to its left—and the vena porta behind and between the common duct and hepatic artery—owing to which important relations, the ducts should be fully exposed before being opened. (See Fig. 489.)

Where more than usual room is required, resection of the right costal arch may be performed.

No suture should be used which will come within the lumen of any of the ducts—for fear of forming the nucleus of calculi.

The exact nature of the operation to be done is frequently not known until the gall-bladder and ducts are exposed and examined

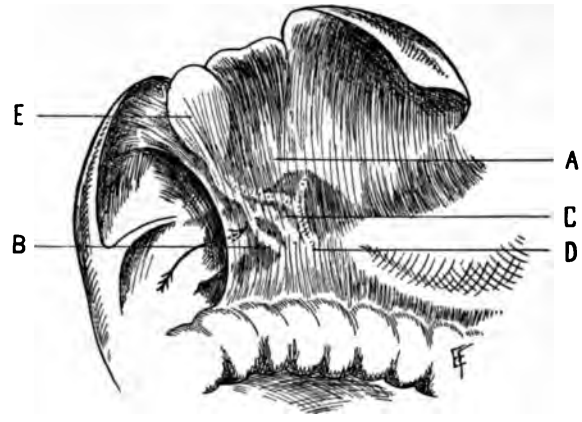

Fig. 489.—HEPATO-DUODENAL LIGAMENT AND CONTAINED STRUCTURES:—A, Ligamentum hepato-duodenale; B, Common bile-duct; G, Vena portæ; D, Hepatic artery; E, Gall-bladder; F, Arrow within foramen of Winslow.

CHOLEDOCHOTOMY.

Description.—Incision of common bile-duct for removal of gall-stone. Often less correctly used in connection with incision of the other biliary ducts.

Preparation—Position—Landmarks.—As for exposure of liver or gall-bladder by an oblique or vertical subcostal incision.

Incision.—The site of operation is often reached in the course of some other operation about the liver or gall-passages. Where especially planned for the removal of a stone in the common duct, a vertical incision may be made along the outer border of the right rectus, ending about 5 cm. (2 inches) above the level of the umbilicus. A curved incision may also be used—from just below the outer aspect of the ensiform cartilage, thence parallel with and about 1.2 cm. (½ inch) from the costal arch to a point about 1.2 cm. (½ inch) above the end of the eleventh rib. In either of these incisions only the ninth nerve need be divided. Fenger gives a vertical incision, combined, if necessary, with a transverse addition.

Operation.—(1) The abdomen having been opened—the liver retracted well upward—the intestines depressed (or having fallen away in the reversed Trendelenburg position)—the gall-bladder is exposed. (2) The bladder is then first palpated for calculi—and the cystic and hepatic ducts are followed down until the common duct is reached—manipulating in the manner described below. (3) All adhesions present should be broken down by blunt dissection, or divided between chromic gut ligatures. These adhesions are apt to be found between gall-bladder, stomach, transverse colon, great omentum, and duodenum. The entire area should be packed off with gauze. (4) After tracing down the cystic duct, expose the anterior surface of the hepato-duo-

denal ligament down to the duodenum—demonstrate the free border of the ligamentum hepato-duodenale to the right—insert the left index-finger into the foramen of Winslow (with pulp of finger forward) and left thumb upon the anterior surface of this ligament—follow its structure downward to the duodenum, having, between the fingers, the common duct to the right, the hepatic artery to the left, and the vena portæ on a plane posterior to and between the other two. (**5**) Having located the stone by the above method of palpation, especially guard against its slipping into the hepatic duct from between the thumb and index—by pressing it forward against the anterior wall of the duct and steadying it in that position. (**6**) Incise the duct in its long axis, directly over the stone, for a distance of from 1 to 3 cm. ($\frac{1}{3}$ to $1\frac{1}{4}$ inches) as indicated (Fig. 490). The escape of bile is caught in gauze—and the presenting calculus

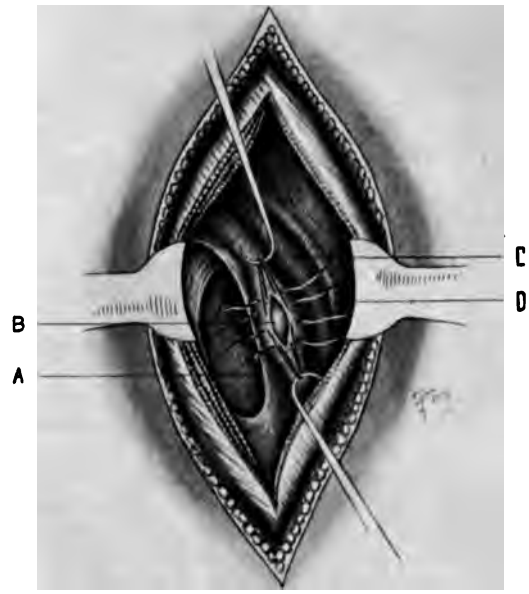

Fig. 490.—Choledochotomy and Choledochorrhaphy, by Vertical Subcostal Incision in Right Linea Semilunaris:—A, Foramen of Winslow, leading behind hepato-duodenal ligament; B, Distended common bile-duct incised over a calculus. Lembert interrupted sutures are shown placed ready to be tied after extraction of stone; C, Position of vena portæ; D, Position of hepatic artery.

removed with special forceps or scoop. Having removed the stone, the common duct should be examined for other stones—by means of the finger or probe—and from the duodenum to and into the cystic and hepatic ducts. (**7**) Having extracted the stone, the wound in the duct is to be closed—either by simple suturing—or by suturing aided by some such mechanical device as one of Halsted's hammers (which are of various sizes). (**a**) Closure Aided by Halsted's Hammer;—Preliminary to the incision, two traction-sutures are inserted on either side of the line of the future incision, through the outer coats of the duct—for the purpose of aiding the manipulation. Having evacuated the duct and examined its cavity for other calculi, Halsted's hammer is introduced by insinuating its longer arm into the incised wound—the hammer

portion distending the duct and rendering it easier to suture its walls over the round, firm form—which also obstructs the flow of bile during the operation. (Fig. 491.) The opening is finally closed either by Halsted's mattress sutures passed through the outer coats of the duct,—or two rows of ordinary sutures may be used—an inner row of interrupted gut sutures through the muscular and external coats, without penetrating the mucous membrane—and an outer row of interrupted silk sutures through the serous surfaces. The peritoneum covering the anterior aspect of the hepato-duodenal ligament is included in the suturing. (**b**) Closure by Simple Suturing;—Having incised the duct over the stone, before the stone is removed the first row of sutures, inserted upon a small, fully curved needle through the muscular and external coats, is passed while the stone is still *in situ* (using the stone as a distender of the gut)—these stitches are then held apart and the stone is withdrawn between them—after which the first row is tied and an outer row of interrupted silk sutures is passed through the serous surfaces, as above described (Fig. 490). (**8**) In completing the operation, a rubber drainage-tube may be carried down to the wound in the duct, and this surrounded by gauze—the abdominal wound being closed except where the drainage comes out.

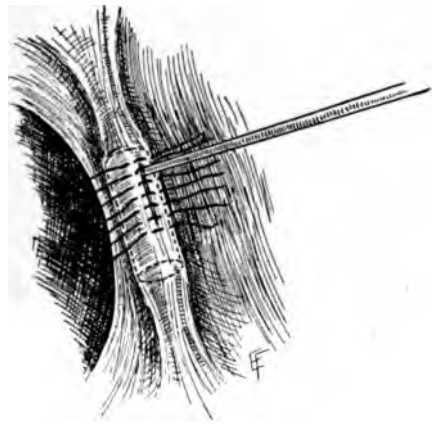

Fig. 491.—CHOLEDOCHORRHAPHY, AIDED BY HALSTED'S HAMMER:—The hammer is shown *in situ* during placing of sutures—and is withdrawn prior to tightening last of the sutures.

Comment.—(**1**) If distended, the gall-bladder or duct should first be partly aspirated. (**2**) Where choledochotomy with suture of the duct is done, cholecystostomy is frequently done at the same time, to relieve the tension upon the stitches and as a drain. (**3**) It is easier to suture a thickened duct, and harder to suture a thin one. If it be impossible to suture the duct, insert a small rubber drainage-tube into the opened duct and pack around it with gauze. (**4**) If the stone can be shifted, it is better to shift it nearer the duodenum before incising the duct—as there is less danger of wounding the vena portæ. (**5**) After incising the duct, it may be necessary to crush the stone *in situ* by inserting special crushing forceps through the wound in the duct and then removing the debris with scoop or forceps. (**6**) If possible, ascertain with the probe whether duct into the duodenum is patulous.

CHOLELITHOTRITY.

Description.—Exposure of the gall-ducts (cystic, hepatic, or common)—the crushing of the contained calculi *in situ*, without opening the duct—and the pressing onward of the fragments toward the duodenum. Instead of crushing, the calculi may be broken up by a needle inserted through the walls of the duct (Tait's method of "needling"). As applied to the common duct, the operation is called choledocho-lithotrity—in which duct the calculus is found more frequently than in cystic or hepatic ducts. Cholelithotrity is understood to refer to the operation in its application to any of the three ducts.

Preparation—Position—Landmarks—Incision.—As for Choledochotomy.

Operation.—The region of operation is exposed exactly as in the description immediately preceding. The gall-bladder and ducts, especially the common duct, are palpated by the same process of manipulation as there described. When the calculus is located, an attempt is made to crush it with the fingers, or special protected forceps, and then to manipulate the fragments onward into the duodenum—pushing them on if possible—crushing them only if absolutely necessary. Guard against the escape of the stone from the cystic into the hepatic duct, and thence into the right or left hepatic ducts out of reach. The abdomen is closed without drainage if no great harm is thought to have been done in the manipulation—otherwise temporary drainage is used.

X. THE SPLEEN.

SURGICAL ANATOMY.

Description and Situation.—Situated chiefly in left hypochondriac region—lying above left kidney and splenic flexure of colon—between concavity of diaphragm to left and behind, and fundus of stomach to right and in front—corresponding, in axillary line, with ninth, tenth, and eleventh left ribs. It lies obliquely from above downward and from within outward. Its length is about 12 cm. (4¾ inches)—breadth, 8 cm. (3¼ inches)—thickness, 3 cm. (1¼ inches). The peritoneum entirely surrounds the spleen except at its hilum—which is at the center of the internal surface (between the renal and gastric portions of internal surface) through which the arteries and nerves enter and the veins and lymphatics emerge. Its pedicle is formed by the reflection of peritoneum over the vessels at the hilum. The diaphragm separates all parts of the normal spleen from the parietes. The spleen may be absent, or there may be from one to twenty more or less rudimentary spleens present.

Surfaces and Borders.—Phrenic surface; lies beneath left ninth, tenth, and eleventh ribs—peritoneum, diaphragm, portions of left pleura and lung, the costo-phrenic sinus (and sometimes left lobe of liver) intervening. **Renal part of internal surface;** touches superior and external part of left kidney, and generally the suprarenal capsule. **Gastric part of internal surface;** in contact with posterior wall of a filled stomach. **Basal surface** (lower outer end); in contact with splenic flexure of colon and phreno-colic ligament (and often with tail of pancreas). **Anterior margin;** situated between diaphragm and stomach. **Posterior border;** between diaphragm and left kidney. **Superior end;** on level with tenth dorsal vertebra, approaching within 2 to 3 cm. (¾ to 1¼ inches) of spinal column. Reaches to level of ninth dorsal spine. **Inferior end;** limited anteriorly by costo-clavicular line (connecting left sterno-clavicular articulation with anterior end of eleventh rib). Reaches to level of first lumbar spine.

Relations.—Externally and Superiorly; peritoneum; diaphragm; left ninth, tenth, and eleventh ribs; costo-phrenic sinus; left lung and pleura; posterior thoracic muscles. **Inferiorly;** splenic flexure of colon; phreno-colic ligament; tail of pancreas (sometimes). **Internally;** stomach (posterior surface of fundus); left kidney and capsule; tail of pancreas; spinal column (sometimes).

Relations of Spleen to Thoracic Cavity.—Upper third of spleen is

covered by left lung,—middle third is in contact with left costo-phrenic sinus,—lower third passes below lower pleural limit and costal origin of diaphragm.

Ligaments and Fixations of Spleen.—Gastro-splenic omentum—from hilum to fundus of stomach. Phreno-splenic ligament—from upper end of spleen to diaphragm. Spleno-renal ligament—formed partly by greater and lesser peritoneal sacs—contains the splenic vessels. Phreno-colic ligament—affords support, though not connected with spleen. Pancreatico-splenic ligament—present when tail of pancreas does not reach spleen. Spleno-colic ligament—from basal aspect of spleen to colon (sometimes present).

Arteries.—Splenic.

Veins.—Splenic.

Lymphatics.—Empty into glands at hilum.

Nerves.—From cœliac plexus and right pneumogastric.

SURFACE FORM AND LANDMARKS.

Upper end of spleen lies opposite level of ninth dorsal spine—lower end opposite level of first lumbar spine. The inner border comes within 3.8 to 5 cm. (1½ to 2 inches) of the median plane of the body. The outer border lies just posterior to the mid-axillary line—not coming further forward than a line joining the left sterno-clavicular articulation and the anterior end of the eleventh rib. The spleen corresponds with the ninth, tenth, and eleventh left ribs—separated from them by the diaphragm and, in its upper part, also by the lung. Its long axis about corresponds with the line of the left tenth rib. It slightly overlaps the outer border of the left kidney below.

GENERAL SURGICAL CONSIDERATIONS.

The spleen may be exposed in several ways—by oblique subcostal incision parallel with costal arch; by vertical incision in left linea semilunaris; by vertical incision to left of left linea semilunaris; by median abdominal incision; by intercostal incision; by partial excision of one or more ribs, followed by subpleural or transpleural exposure of spleen. If more room be needed, any of the vertical incisions may be increased by a transverse or curved incision extending toward flank or median line, from the lower part of the vertical incision. Where an abdominal incision is first made for pure exploratory purposes, the median abdominal incision is probably best. There is general similarity in the technic of hepatic and splenic operations.

INSTRUMENTS.

See those used in operating upon the Liver.

EXPLORATORY PUNCTURE OF SPLEEN.

Exploratory puncture of the spleen is made in the same general manner, and with the same general precautions, as is exploratory puncture of the liver (see page 804). As in the case of the liver, exploratory puncture of the spleen is rarely warrantable, owing to the risks of sepsis and hemorrhage—and should not be used except in the case of tumors, which are almost certainly adherent to the abdominal wall, thus shutting off the general peritoneal cavity—and

especially in those projecting below the ribs. The site of the tumor and the general relations given under Surgical Anatomy will serve as the guide for the site of puncture—the puncture itself being made exactly as it is in the case of the liver.

SPLENOTOMY

BY OBLIQUE SUBCOSTAL INCISION.

Description.—Incision of the spleen—by an incision just below and parallel with the left costal arch. The spleen may be exposed by any of the incisions mentioned under General Surgical Considerations—one of the first three being preferable. The operation may be done in one stage—or in two stages (after adhesions have formed).

Preparation—Position.—As for Median Abdominal Section.

Landmarks.—Lower border of left costal arch; left linea semilunaris; position of tumor, if any.

Incision.—Oblique incision parallel with and about 1.3 cm. (½ inch) below left costal arch, with its center over the site of spleen (the inner border of which comes to within 4 to 5 cm. [1½ to 2 inches] of the median plane—and whose outer border extends just posteriorly to the mid-axillary line).

Operation.—(1) Having opened the abdomen in the same manner as in Hepatotomy by the same incision, the spleen is isolated and brought into the wound as far as possible and the neighboring field packed off with gauze. In dealing with fluid collections within the spleen substance, the tension should be lessened by partial aspiration of the contents preliminarily to incision of the viscus, after the organ is brought into the wound. (2) The operation may be completed in one or in two stages;—(a) In One Stage:—Having been brought as near the surface of the wound as possible, and after packing off the vicinity as securely as possible, the spleen is incised in the same general manner and with the same precautions as in the case of the liver (see page 806). In the case of a fluid collection, the edges of the pus or cyst cavity are then seized and brought forward and sutured into the lower plane of the abdominal wound (which is closed in from either end for a part of the distance)—the sutures passing through spleen substance and capsule at some distance from the wound in the viscus, on the one hand, and through parietal peritoneum and part of the thickness of the lower plane of the lips of the abdominal wound, on the other—thus approximating the peritoneum of the spleen and the peritoneum of the abdominal wall all around. (b) In Two Stages;—The spleen is brought into the wound and the parietal peritoneum and edges of the abdominal wound are stitched in an elliptical manner to the serous surface and to the substance of the spleen—the wound of the abdomen, which is partly closed from one or both ends, is then packed with gauze and two or three days given for union—after which the spleen is incised. All incisions into spleen substance are planned so as to avoid, as far as possible, the large vessels of the viscus. (3) Where the spleen has been incised for exploration simply, and nothing has been found, splenorrhaphy is done and the abdomen closed.

EXPOSURE OF SPLEEN BY SUBPLEURAL ROUTE

BY PARTIAL EXCISION OF ONE OR TWO RIBS.

Description.—For the general description, see the corresponding operation upon the liver. The ribs chosen are usually the tenth and eleventh

(and the former when only one rib is excised)—the site of excision lying midway between a point about 4 to 5 cm. (1½ to 2 inches) from the median plane, and a point just posterior to the mid-axillary line. The steps of the operation are the same as those for the subpleural exposure of the liver by the partial excision of one or more ribs (see page 810).

SPLENORRHAPHY.

Description.—Suturing of the spleen. Generally resorted to for incised and lacerated wounds, and for approximating surfaces after partial splenectomy. The route of approach is often determined by a pre-existing wound or operation—if not, the oblique subcostal incision parallel with the left costal arch gives the best exposure. For the method of approaching the spleen, therefore, see Partial Splenectomy by Oblique Subcostal Incision parallel with the Ribs, page 831. For the details of the operation, after exposing the organ, see Hepatorrhaphy, page 813, the technic being practically the same.

SPLENOPEXY.

Description.—By Splenopexy is meant the fixation, generally by means of suturing, of a displaced spleen back to its original site, or to another site. Indicated in "wandering" spleen (Splenoptosis).

Preparation—Position—Landmarks.—As for Partial or Total Splenectomy, according to the incision adopted.

Incision.—The organ may be approached by a vertical incision in the left linea semilunaris; by an oblique subcostal incision; or by a median vertical incision. The first incision given provides the most convenient approach to the parts involved. The median incision has been used by Rydygier, who introduced the operation.

Operation.—Having opened the abdomen, isolated and exposed the displaced spleen, its position, its environments, and the laxity of its ligaments are studied, and a site for its fixation decided upon. (**a**) Rydygier, having opened the abdomen in the median line, elevated the spleen to a proper height—then detached from the parietes sufficient peritoneum to form a pocket—dividing the parietal peritoneum with a transverse upward convexity, detaching it downward from the abdominal wall. The lower half of the spleen was then placed in this pocket—the parietal peritoneum was sutured to the underlying tissues along the lowest line of separation (to prevent further separation)—and the free border of the parietal peritoneum was attached to the gastro-splenic omentum above. (**b**) Bardenhauer entered the abdominal cavity by a somewhat rectangular incision, made by a vertical incision extending from the ribs to the superior iliac crest, the upper line of which was extended transversely forward along the inferior border of the tenth rib. The flap thus included was detached downward to but not through the peritoneum and turned inward—the peritoneum was then incised sufficiently to enable the spleen to be drawn through edgewise. A strong purse-string suture of silk, previously placed around the margin of the peritoneal opening, was then drawn so as to pucker it around the pedicle but not constrict it. A suspensory silk suture was passed under the end of the spleen and over the tenth rib as a sling. Other sutures were passed where indicated. The spleen was thus practically extraperitoneally placed. The abdomen is closed without drainage.

PARTIAL SPLENECTOMY

BY SUBCOSTAL INCISION PARALLEL WITH RIBS.

Description.—Excision of part of spleen. Generally done for removal of tumor involving a portion of the organ.

Preparation—Position.—As for median abdominal section.

Landmarks.—Lower border of left costal arch—or modified by the position of a tumor, if one be present.

Incision.—Obliquely curved incision parallel with and about 1.2 cm. (½ inch) below the left costal arch, with its center over the site of the spleen (whose inner border extends to within 4 or 5 cm. [1½ or 2 inches] of the median plane, and whose outer border extends just posteriorly to the mid-axillary line), —or, if a tumor be present, directly over the tumor.

Operation.—(1) Having incised the skin and fascia; the external oblique transversely; separated the internal oblique in the cleavage line; retracted what nerves could be spared; divided the transversalis obliquely; and the transversalis fascia, subserous areolar tissue, and peritoneum in the line of the original wound, the abdominal cavity is opened. (2) Having retracted the wound and brought the spleen as far into the opening as possible, the area of the spleen to be removed, including the tumor, if any, is now to be surrounded in sections by interlocking silk or chromic gut ligatures and tightened—or other form of ligature which will compress the entire area to be circumscribed and removed. When the entire portion to be removed has been thus circumscribed by a compressing ligature, the tied-off area is excised with curved scissors, or by the actual cautery—further ligating any portions requiring ligature. Where the area to be removed has any ligamentous attachments corresponding to it, or adhesions connected with it, these are first tied off and divided between ligatures. (3) Where possible, the surfaces left by the partial excision should be approximated by deeply placed sutures. See Splenorrhaphy, page 830. The spleen is then dropped back into place—and the abdomen generally closed without drainage.

Comment.—Where the tumor or tumors are small, small wedge-shaped masses may be removed and the edges approximated by deeply placed sutures, which both coapt the surfaces and control the hemorrhage—thus obviating any previous ligation of the spleen substance.

TOTAL SPLENECTOMY

BY VERTICAL INCISION IN LEFT LINEA SEMILUNARIS.

Description.—Excisions of entire spleen. Resorted to in some cases of movable spleen, injury of the organ, simple hypertrophy and in some tumors.

Preparation.—As for Median Abdominal Section.

Position.—As for Median Abdominal Section—the position of the surgeon to the right of the patient giving better access to and control of the pedicle.

Landmarks.—Left linea semilunaris.

Incision.—Vertical incision in left linea semilunaris, beginning near the left costal arch and extending downward as far as necessary. (Such an incision will divide the ninth nerve transversely on a line with the lower border of the ninth rib.) The spleen may also be exposed by one of the incisions given under General Surgical Considerations.

Operation.—(1) Having incised abdominal wall and opened the peritoneal cavity and retracted the lips of the wound, the spleen is located and brought as

prominently forward as possible. If any adhesions be found between the spleen and neighboring viscera, or the abdominal wall, these are separated by blunt dissection, or divided between double ligatures—carefully avoiding injury to the spleen. (2) Freeing Splenic attachments (ligaments) and Enucleation of the Spleen;—The phreno-splenic ligament is best reached and freed, as suggested by Jonnesco, by covering the spleen with a square of gauze, to avoid slipping of fingers, and then depressing the spleen downward and to the right, while an assistant draws the left lower edge of the abdominal wound to the left—thus exposing the bed of the spleen and vault of the diaphragm and the phreno-splenic ligament, which latter is divided between double ligatures. (3) Following this, the remaining ligaments and attachments of the spleen to its bed are freed, commencing at its lower aspect. The spleen is then enucleated and delivered through the abdominal wound. The gastro-splenic ligament is the omentum surrounding the pedicle, and therefore a part of the pedicle—and is treated in ligating the pedicle. (4) Ligation and Division of the Pedicle;—The spleen having been delivered, is then turned toward its left and made to rest upon its convexity, thus exposing its pedicle. The constituent vessels of the pedicle, beginning with the most important, should all be separated and each doubly ligated and divided between the two ligatures, which should be of strong silk. This is the most important step of the operation. Separate ligation is better than ligation *en masse*, or in two or three divisions or groups of vessels—though the latter may be done in cases of haste or other need. Traction upon the constituents of the pedicle, which are easily ruptured, is to be avoided. Adherence of the splenic artery and vein to the tail of the pancreas often adds to the difficulty of isolation and separate ligature of these vessels. (5) Hemostasis of the Splenic Bed;—Having removed the spleen, its bed is carefully examined—and every bleeding point ligated with chromic gut. Especially examine the pillar of the diaphragm, where the phreno-splenic ligament has been divided—after drawing the stomach and intestines to the right. Limited bleeding surfaces may be controlled by suturing peritoneum over them, where possible. (6) The abdominal wound is closed—unless drainage be specially indicated, or there should be uncertainty as to the hemostasis. Full elastic dressings are applied so as to compress the region formerly occupied by the spleen.

Comment.—(1) It is better to ligate the pedicle at once—than to clamp first and then ligate. (2) Some surgeons, especially in very large spleens, prefer to ligate the pedicle first, with the spleen *in situ*—then draw the spleen down and tie off the gastro-splenic omentum—then deliver the spleen. (3) The vessels are often enormously enlarged—and the veins are often especially thin. (4) Tie the arteries first—then the veins—as less blood is thus lost. (5) See that ligatures, in tying off the pedicle, pass between rather than through the vessels—passing through connective tissue between the vessels. (6) Some surgeons advise first clamping and separating the gastro-splenic ligament—in order to enable the spleen to be lifted up and the pedicle better exposed (J. Wesley Bovee—but adds that this is often impossible in marked hypertrophy—in which cases the vessels are ligated in the order encountered). (7) Some surgeons, in dealing with less accessible pedicles, transfix the entire splenic omentum with double ligature, tying each half separately—then subsequently surround the entire pedicle with another single ligature. (8) After exposing the spleen, the hand should be passed between it and the diaphragm and its surface examined—as well as its other aspects, as far as possible. Very extensive and firm adhesions would contraindicate the continuance of the operation. There may be visceral, parietal, and omental adhesions. If much

damage be done in separating adhesions, temporary drainage is indicated. (9) Practise no traction upon the pedicle, both because of the friable vessels and because of the general bad symptoms which are apt to supervene from pressure upon the splenic plexus (from the solar plexus). Relax the pedicle before tightening each ligature. (10) Treatment of the pedicle comes first in importance and treatment of adhesion second. Hemorrhage is the chief danger. (11) If secondary hemorrhage be feared, suture the pedicle to the abdominal wall.

XI. THE PANCREAS.

SURGICAL ANATOMY.

Description.—The pancreas lies transversely across the posterior abdominal wall, the large vessels intervening between it and the wall—being on a level with the second lumbar vertebra (and sometimes with the first or third)—lying in the epigastric and left hypochondriac regions—having the stomach in front, duodenum to the right, and spleen to the left—and the aorta, vena cava, cœliac plexus, thoracic duct, and diaphragmatic crura behind. It lies behind the posterior wall of the lesser omental cavity and is between the laminæ of the mesocolon of the transverse colon. The head of the pancreas is surrounded by the loop of the duodenum. The tail of the pancreas is in contact with the interno-inferior aspect of the spleen. Peritoneum covers the pancreas except upon its posterior surface. The viscus is 15 to 16 cm. (about 6 inches) in length—3 to 4 cm. ($1\frac{1}{4}$ to $1\frac{1}{2}$ inches) in width—and 15 to 18 mm. (about $\frac{1}{2}$ inch) in thickness.

Relations.—Anteriorly; Upper layer of transverse mesocolon; lesser peritoneal sac; transverse colon; gastro-duodenal and pancreatico-duodenal arteries; stomach (posterior surface). **Posteriorly;** second (sometimes third or first) lumbar vertebra; crura of diaphragm; aorta and right and left renal arteries and superior mesenteric artery; inferior vena cava, superior and inferior mesenteric, splenic, and right and left renal veins; vena portæ; cœliac plexus; thoracic duct (origin); ductus communis choledochus and pancreatic duct; left kidney (and sometimes its capsule). **Superiorly;** Duodenum (first part); liver; hepatic and splenic arteries and cœliac axis; solar plexus. **Inferiorly;** Duodenum, third (preaortic) and fourth (ascending) parts; duodeno-jejunal angle; jejunum; transverse colon; transverse mesocolon (inferior layer); superior mesenteric artery and vein; inferior mesenteric vein; mesentery. **Right end;** Loop of duodenum. **Left end;** Interno-inferior aspect of spleen.

Fixations.—Held in place by its peritoneal investment and by adjacent viscera and structures to which attached.

Pancreatic Duct (Canal of Wirsung).—Begins at left end, or tail, of pancreas—runs thence toward the head of the organ, passing nearer its posterior than anterior aspects—after passing the neck, it turns downward, backward, and to right, in the head of the viscus, and runs to the left side of the common bile-duct—entering the duodenal wall together and parallel with the ductus communis choledochus—uniting with the latter while running obliquely in the walls of the duodenum—and emptying by a common opening with it upon a papilla of mucous membrane about 10 cm. (4 inches) from the pylorus—the opening being covered by a fold of mucous membrane from above. The pancreatic duct is recognized by its white color and its relation to the pancreatica magna artery. Its diameter, near its termination, is between 2 and 3 mm. (about $\frac{1}{9}$ inch). The Duct of the Lesser Pancreas (Duct of San-

torini) may join the Canal of Wirsung near its termination—or may empty into the duodenum by a separate mouth.

Arteries.—Pancreaticæ parvæ and pancreatica magna from splenic artery; pancreatico-duodenalis superior from gastro-duodenalis of hepatic; pancreatico-duodenalis inferior from superior mesenteric.

Veins.—Accompany the above arteries, emptying into splenic and superior mesenteric veins.

Lymphatics.—End in two glands upon superior mesenteric artery.

Nerves.—From solar plexus.

SURFACE FORM AND LANDMARKS.

The pancreas lies obliquely behind the stomach—crossing the spine opposite the second (or sometimes the first or third) lumbar vertebra. Anteriorly, it lies transversely about 7.5 cm. (3 inches) above the umbilicus.

GENERAL SURGICAL CONSIDERATIONS.

General Considerations.—(1) Surgery of the Pancreas is limited to operations for cysts (which is the most frequent operation done upon the viscus), removal of small tumors, abscess, hemorrhage, localized necrosis, calculi, "annular pancreas," and for the removal of parts of the organ. (2) Anatomically, complete pancreatectomy is very difficult. (3) Surgically, complete removal with subsequent life has been proved with animals—but not with man. Rapidly fatal diabetes follows complete removal of the organ. (4) Cysts may be incised or excised. In incision, the cyst-wall should be sutured to the abdominal wall (marsupialization)—for drainage, and to prevent pancreatic juice from getting into the abdominal cavity. (5) Pancreatic juice in the abdominal cavity is apt to excite peritonitis. (6) If the pancreatic opening into the duodenum be cut off, a new route must be made, or a pancreatic fistula must be established. (7) Suturing material should not be left in the pancreatic ducts, as such material may form the nuclei of calculi. (8) Wounds of the pancreatic canals should be closed by suture. (9) Always ligate before excising a portion of the pancreas—in order to prevent the escape of pancreatic juice into the peritoneal cavity. (10) Extirpation of the tail and part of the body, or of limited portions of the head, may be done. The tail of the organ is the part most safely operated upon. In operating upon the head, it is necessary to spare the canal of Wirsung, or the duct of Santorini. In removing the whole head of the pancreas, there is no way to restore the flow of pancreatic juice into the intestines.

Routes of Approaching the Pancreas.—(1) **Gastrocolic**;—by incising the anterior layers of the gastrocolic omentum between the greater curvature of the stomach and the transverse colon, and thus entering the lesser omental cavity. This is the route to be preferred—and is made by a transperitoneal median incision above the umbilicus. (2) **Transmesocolic**;—by incising the inferior layer of the mesocolon. This route may be used when the tumor lies between the laminæ of the mesocolon—and is made by a transperitoneal median incision above the umbilicus. (3) **Epigastric**;—by cutting through the gastrohepatic omentum. This approach may be used when the tumor presents above the lower curvature of the stomach, as less frequently happens —and is made by transperitoneal median incision above the umbilicus. (4)

Lumbar;—by incising as for exposure of the kidney. Sometimes done for tumors of the tail of the pancreas—and is made by an extraperitoneal incision as for exposure of the left kidney—or below and along the twelfth rib. (See Fig. 492.)

Methods of Drainage of Pancreatic Cavities.—(1) If pus have collected in the bursa omentalis, incise in the median line, from the ensiform cartilage downward, and cut through the gastrohepatic omentum—after, if possible, first suturing that omentum to the abdominal wall. (2) If pus be in the bursa omentalis and extend along the pancreas, resort to Leith's lumbar drainage mentioned below. (3) Lumbar drainage is sometimes necessary where anterior drainage cannot be secured—in such cases Leith suggests a lumbar incision made under the left twelfth rib. Through this the finger is inserted by the upper border of the quadratus lumborum, locating the left kidney and its vessels. The tail of the pancreas and the posterior and external wall of the bursa omentalis are placed above and just internal to the renal vessels. The lesser peritoneal cavity can be here entered either through the mesocolon or through the posterior layer of the peritoneum. (4) If pus be retroperitoneal—make a lumbar incision as for exposure of the left kidney and reach the site extraperitoneally.

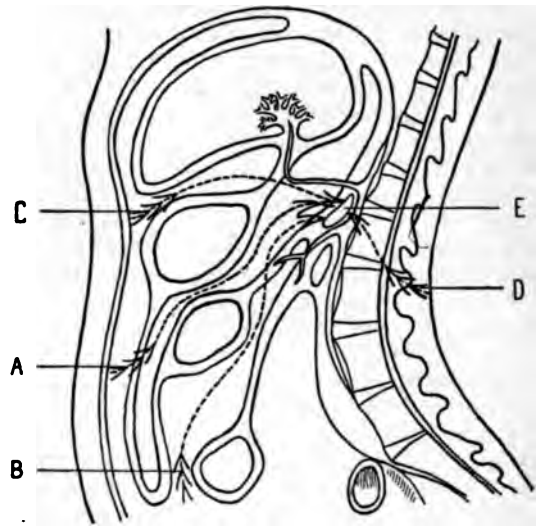

Fig. 492.—Illustrating Routes of Approach to Pancreas:—A, Gastro-colic; B, Trans-mesocolic; C, Trans-gastrohepatico-omental (epigastric); D, Lumbar; E, Pancreas. (Modified from Gray.)

INSTRUMENTS.

See those given under the Liver (page 804).

PANCREATOTOMY

BY GASTROCOLIC ROUTE.

Description.—Incision of the pancreas. Generally resorted to for cyst or abscess of that organ. The method of approach is generally one of the first three given under General Surgical Considerations—and is usually the one above mentioned. In the case of a cyst of the pancreas, its walls may be excised, or, as is more generally done, sutured to the abdominal wall and drained.

Preparation—Position—Landmarks.—As for Median Abdominal Section.

Incision.—In median line, with its center opposite the lower border of the stomach—which is about 4 cm. (1½ inches) above the umbilicus. Where a tumor is evident, the incision is usually placed directly over it.

Operation.—(1) Having opened the abdomen as in median section, the gastrocolic omentum is exposed. (2) Having displaced the stomach upward and the transverse colon downward, the gastrocolic omentum is incised vertically, between the lower border of the stomach and the upper border of the colon—thus reaching the lesser peritoneal cavity. (3) Having controlled all hemorrhage, the pancreas is reached through the opening in the omentum and drawn forward into the wound—packing off the vicinity with gauze. (4) If haste be necessary, the operation is completed in one stage, the cyst being incised and its edges sutured into the lower plane of the abdominal wound, having been brought through the rent in the gastrocolic omentum, which is sutured around the opening in the pancreas as well as possible. (5) If haste be unnecessary, the operation is concluded in two stages—the first step being similar to the one just described—the second step, the incision of the viscus, being performed two or three days later, after adhesions have formed and the general peritoneal cavity has been shut off. (6) In any event, therefore, drainage is temporarily provided for through the abdominal incision, which is usually accomplished by drainage-tube and gauze packing.

Comment.—(1) Adhesions are apt to be found in such cases, and should be separated by blunt dissection, or divided between chromic ligatures, before attempting to expose the pancreas in the wound. (2) In distended cysts or abscesses, partial aspiration should first be done to lessen tension. (3) In some cases adhesions are found walling off the general peritoneal cavity—so that it is possible to incise directly through the abdominal wall and gastrocolic omentum into the pus or fluid cavity. (4) In exceptional cases cysts may be excised in the same manner as small tumors.

PARTIAL PANCREATECTOMY

BY GASTROCOLIC ROUTE.

Description.—Excision of part of the pancreas. Generally performed in connection with removal of a tumor involving a portion of the organ.

Preparation—Position—Landmarks—Incision.—As for Pancreatotomy.

Operation.—The pancreas is exposed in precisely the same manner as for Pancreatotomy. The tumor in the organ is sought and brought as well forward as possible. Chromic gut ligatures are then placed deeply around the mass to be removed, so as to completely circumscribe it—thus preventing both hemorrhage and the escape of pancreatic fluid. This having been done, the tumor is excised with curved, blunt-pointed scissors, aided by blunt dissection. If a marked cavity is left, and it is possible to do so, the walls of the cavity are approximated by deep chromic gut sutures. Drainage is then established between the site of the operation and the abdominal wound—and the remainder of the abdominal incision closed.

XII. THE KIDNEYS.

SURGICAL ANATOMY.

Description.—Each kidney lies partly in the hypochondriac, lumbar, epigastric, and umbilical regions—abutting upon the confines of each—resting upon the lower part of the diaphragm and areolar fatty tissue covering the quadratus lumborum and psoas magnus—and placed behind the peritoneum. They lie embedded in abundant fatty areolar tissue, more abundant posteriorly than anteriorly—constituting the fatty areolar capsule. The right kidney generally (though not always) lies about 7 mm. to 1.3 cm. ($\frac{1}{3}$ to $\frac{1}{2}$ inch) lower than the left (owing to the presence of the liver upon the right). Vertically, the kidneys correspond to the space between the upper border of the twelfth dorsal and the first and second (and sometimes the upper half of the third) lumbar vertebræ—and to the eleventh and twelfth ribs and transverse processes of the first and second lumbar vertebræ—the left kidney generally reaching to the upper border of the eleventh rib—and the right kidney generally reaching to the lower border of the eleventh rib. Outer borders of the kidneys lie from 9 to 10 cm. ($3\frac{1}{2}$ to 4 inches) external to the lumbar spines. The superior poles of the kidneys lie about 5 cm. (2 inches), and the inferior poles from 6.3 to 7.6 cm. ($2\frac{1}{2}$ to 3 inches), from the median line. Inner border of right kidney lies close to the vena cava—the inner border of the left kidney lies within 2.5 cm. or more (1 inch or more) of the aorta. The kidneys average 10 to 12 cm. (4 to $4\frac{3}{4}$ inches) in length—2.8 cm. ($1\frac{1}{8}$ inches) in thickness—6.3 cm. ($2\frac{1}{2}$ inches) in breadth—and weigh about $4\frac{1}{2}$ ounces. There may be an irregularity from the normal in the form, size, number, position, and mobility of the kidneys.

Peritoneal Relations of the Kidneys.—

Posterior surfaces of both kidneys are uncovered by peritoneum. Upon the anterior surface of the right kidney—the hepatic and mesocolic areas are peritoneal—and the areas of the duodenum and transverse colon are non-peritoneal. Upon the anterior surface of the left kidney—the gastric area is peritoneal—the pancreatic area is non-peritoneal—the outer part of the colic area is non-peritoneal, and the inner part of the colic area is peritoneal.

Fixations.—(1) Fatty areolar tissue, or capsule—in which the kidneys are embedded—derived from parietal subperitoneal fascia—and separates them from the diaphragm and from the anterior lamella of the lumbar fascia covering the quadratus lumborum and psoas muscles. (2) Vessels, nerves, and connective tissue form the pedicle. (3) Partial covering of peritoneum upon their anterior surfaces and borders.

Relations.—Anterior Surface—(a) Right Kidney;—Liver (right lobe)—peritoneum intervening; ascending colon and hepatic flexure; duodenum (descending part); suprarenal capsule (to slight extent). **(b)** Left Kidney;—Stomach (fundus)—peritoneum of lesser sac intervening; pancreas (tail); splenic artery and vein; splenic flexure of colon and upper part of descending colon; duodenum (ascending part); suprarenal capsule (to slight extent). **Posterior Surface**—(Both Kidneys)—Areolar fatty tissue, separating the kidneys from diaphragm and quadratus lumborum and psoas muscles; posterior abdominal wall, corresponding to eleventh and twelfth ribs and transverse processes of first and second lumbar vertebræ; diaphragm (areolar tissue intervening); anterior layer of posterior aponeurosis of transversalis (*i. e.*, anterior layer of lumbar fascia), separating kidney from quadratus lumborum; psoas; diaphragmatic, transversalis and iliac fascia lining dia-

phragm, transversalis and iliacus; twelfth dorsal, ilio-hypogastric and ilio-inguinal nerves; anterior divisions of first and second lumbar arteries and veins. The nerves and vessels just mentioned all pass downward and outward anteriorly to the quadratus lumborum and pierce the transversalis beyond the external border of the quadratus. *Note.*—The left kidney is in contact with a larger area of diaphragm than the right—and the amount of diaphragm in contact may be increased on both sides when the arcuate ligaments are attached to the tips of the transverse processes of the second lumbar vertebra. **External border**—(**a**) Right Kidney; liver (upper two-thirds); ascending colon (lower third). (**b**) Left Kidney; spleen (above); descending colon (below). **Internal border**—(**a**) Right Kidney; near vena cava; structures of hilum (*q. v.*). (**b**) Left Kidney; 2.5 cm. or more (1 inch or more) from aorta; structures of hilum (*q. v.*). **Superior extremity**—(Both Kidneys)—Suprarenal capsule—which encroaches also upon the anterior and internal border and is bound to the kidney by the connective tissue of the subperitoneal fascia. **Inferiorly**—(Both Kidneys)—come within about 5 cm. (2 inches) of the crest of the ilium.

Relations of the Pleuræ.—The pleuræ are in proximity to, but not in relation with, the kidneys. The lower limit of the pleura extends nearly

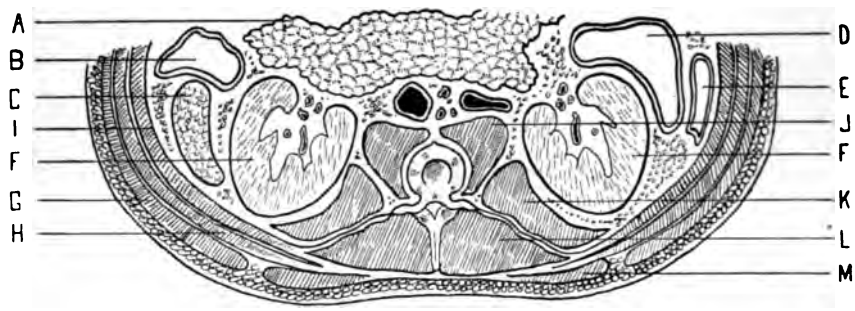

Fig. 493.—Horizontal Section through Upper Lumbar Region:—A, Pancreas; B, Descending colon; C, Spleen; D, Ascending colon; E, Small intestine; F, F, Kidneys; G, External oblique; H, Internal oblique; I, Transversalis; J, Psoas magnus; K, Quadratus lumborum; L, Erector spinæ; M, Latissimus dorsi. (Modified from Esmarch.)

horizontally outward from the lower margin of the twelfth dorsal vertebra—crossing the twelfth rib close to its neck—and crossing the eleventh rib about 5 cm. (2 inches) beyond (external to) its neck.

Relation of Structures within the Sinus of the Kidney.—(**A**) Structures;—Branches forming renal artery; branches forming renal vein; lymphatic vessels and glands; plexus of nerves; ureter; areolar fatty tissue. (**B**) Order of Structures from Before Backward;—(**a**) Right Kidney—vein, artery, ureter:—(**b**) Left Kidney—vein, artery, ureter. (**C**) Order of Structures from Above Downward;—(**a**) Right Kidney—vein, artery, ureter:—(**b**) Left Kidney—artery, vein, ureter.

Arteries.—Renal, suprarenal, spermatic, and lumbar—all from aorta.

Veins.—Renal. Right vein empties directly into vena cava. Left vein receives left spermatic (or left ovarian), left inferior phrenic, and sometimes left suprarenal before emptying into vena cava.

Nerves.—From solar and aortic plexuses, semilunar ganglia, splanchnics, and pneumogastrics.

Lymphatics.—Superior and deep sets—emptying into lumbar glands.

Description of Lumbar Fascia.—Consists of three layers, which ensheathe erector spinæ and quadratus lumborum muscles. (1) **Posterior or superficial layer**:—Layer through which latissimus dorsi, and serratus posticus inferior beneath it, are connected to the vertebral spines (same thing as aponeurosis of those muscles). Latissimus dorsi is connected with it most posteriorly—serratus posticus inferior, lying beneath latissimus dorsi, is connected with its upper part anteriorly to latissimus dorsi—and beyond the line along which these two muscles are connected with it (*i. e.*, after these two muscles are free of it) it gives origin to the posterior part of the internal oblique—and then passes on (after internal oblique is free of it) to merge with middle layer—thus binding down posterior aspect of erector spinæ. It is continuous with the vertebral aponeurosis. (2) **Middle layer**:—Arises from tips of lumbar transverse processes—runs outward between quadratus lumborum in front and erector spinæ behind, to fleshy part of transversalis muscle —forming posterior aponeurosis of transversalis. It is joined at outer border of erector spinæ by posterior layer—and at outer border of quadratus lumborum by anterior layer. It is attached, above, to lower margin of last rib—and, below, to ilio-lumbar ligament and adjacent iliac crest. (3) **Anterior layer**:—attached to front of lumbar transverse processes at inner border of quadratus lumborum—covering anterior surface of quadratus lumborum to its outer border, where it becomes united with middle layer and becomes the transversalis fascia. Attached above (forming ligamentum arcuatum externum) to front of transverse processes of first (or second) lumbar vertebra and apex of last rib, and, below, to ilio-lumbar ligament and iliac crest (Fig. 493).

SURFACE FORM AND LANDMARKS.

(1) A horizontal line through the umbilicus will be below the lower border of each kidney—about 2.5 cm. (1 inch) below the right kidney, and 4 cm. (1½ inches) below the left (Quain). According to Treves, such a line will intersect the lower portion of the right kidney, and pass below the left. (2) A vertical line from the middle of Poupart's ligament upward to the costal arch will have one-third of the kidney to its outer, and two-thirds of the kidney to its inner side. (3) Posteriorly, the kidney lies within a parallelogram included within the four following lines: (a) Line parallel with and 2.5 cm. (1 inch) external to the spine, from the lower border of the tip of the eleventh dorsal spine to the center of the tip of the third lumbar spine,—(b) Line drawn outward for 7 cm. (2¾ inches) at a right angle to, and from the upper end of line "a,"—(c) Line drawn outward for 7 cm. (2¾ inches) at a right angle to, and from the lower end of line "a,"—(d) Line parallel with line "a," between the outer ends of lines "b" and "c." (4) The right kidney is generally from 1.3 to 2 cm. (½ to ¾ inch) lower than the left,—and will lie that far below the measurements given in (3) above. (5) The upper border of the kidney lies upon a level with the eleventh intercostal space and with the eleventh or twelfth dorsal spine—the right kidney lying somewhat lower. (6) The twelfth ribs divide the kidneys, approximately, into a superior and an inferior half. (7) The lower border of the kidney about corresponds with the center of the spinous process of the third lumbar vertebra. (8) The kidneys are accessible to pressure in the triangle formed by the lower border of the twelfth rib above, and the outer border of the erector spinæ internally. (9) The axes of the kidneys are oblique—from above and within, downward and outward. (10) The superior pole of the kidney is about 5 cm. (2 inches) from the median plane. (11) The hilum of the kidney lies about 5 cm. (2 inches) from the

median plane, on a level with the first or second lumbar spine, or opposite the interval between them. (**12**) The inferior pole of the kidney lies about 6.3 to 7.5 cm. (2½ to 3 inches) from the middle line. (**13**) The inner border of the upper part of the kidney lies about 2.5 cm. (1 inch) external to the middle line of the body. The inner border lies upon the external border of the psoas—the rest of the kidney lying upon the lumbar fascia covering the quadratus lumborum. (**14**) The outer border of the lower part of the kidneys is about 9.5 cm. (3¾ inches) from the middle line. The external border lies from 2 to 3 cm. (¾ to 1¼ inches) to the outer side of the external border of the quadratus lum-

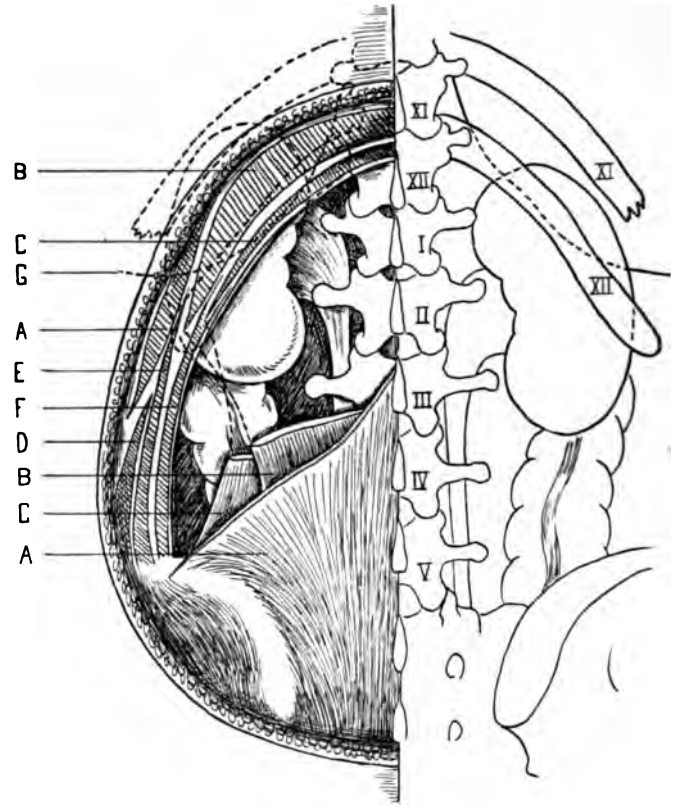

Fig. 494.—Relations of Kidneys to Vertebræ, Ribs, Pleuræ, and Overlying Muscles: —A, A, Latissimus dorsi; B, B, Erector spinæ; C, C, Quadratus lumborum; D, External oblique, E, Internal oblique; F, Transversalis; G, Lower limit of pleura. Ascending colon is seen on the right, the descending on the left. (Modified from Gray, and from Esmarch and Kowalzig.)

borum muscle. (**15**) The ureter expands into the pelvis of the kidney opposite the lower half of the kidney. (**16**) Both kidneys rest upon the lower portion of the arch of the diaphragm (as it comes downward between the kidneys and the twelfth ribs), quadratus lumborum, anterior layer of lumbar fascia, and psoas muscle. (**17**) The external border of the erector spinæ is the superficial guide to the kidney—and the quadratus lumborum the deep guide, —the former muscle marking the twelfth rib about 6.3 cm. (2½ inches) from the median line—and the latter being attached to the inner half of the twelfth rib (Fig. 494).

GENERAL SURGICAL CONSIDERATIONS.

Preparation.—Bowels and bladder emptied—part shaved.

Position.—In operating extraperitoneally, the patient lies upon the sound side, near the edge of the table, with a firm cushion or support under the opposite loin, to round out and make prominent the side of the operation and increase the interval between the twelfth rib and the iliac crest. The surgeon stands at the patient's back, cutting from above downward on the right side, and in the reverse, or in the same direction, on the left. The assistant stands opposite. In operating transperitoneally, the position is the same as for median abdominal section.

Approach to the kidney may be by the extraperitoneal or transperitoneal route—preferably the former.

Always ascertain that the opposite kidney is present before removing a kidney.

An incision to expose the kidney may go, with safety, to the lower border of the twelfth rib. If the eleventh be the last rib, the pleura would be endangered if that rib were taken for the twelfth. If the thirteenth rib be present, the operation area would be contracted.

Do not take for granted that the last rib is the twelfth rib—else the pleura may be wounded. Always count the ribs from above.

The pleuræ may reach lower where the arcuate ligaments are attached to the second lumbar vertebra.

If necessary to better expose the kidney, the twelfth rib may be excised subperiosteally, in whole or in part.

Hemorrhage in kidney operations is often great. It may be controlled:—by compression of the pedicle by the fingers, or a special forceps temporarily applied,—by gauze-pressure of the bleeding surface,—by hot douching. Suturing of bleeding surfaces in contact also controls hemorrhage. In bisection of the healthy kidney, pressure of the pedicle is necessary. Diseased kidney bleeds less than healthy kidney substance.

The right renal vein is generally much shorter than the left—a fact to be remembered in handling the pedicle of the right kidney.

Gut is preferable to silk throughout in kidney surgery—as being absorbable—and less apt to form the nuclei of calculi.

INSTRUMENTS.

Scalpels; bistouries; scissors, various; forceps, dissecting, toothed, and dressing; blunt dissector; probe; sound; grooved director; tenacula; exploratory syringe and needle; needle in handle, for exploration; periosteotomes; costotome; pedicle forceps; special stone scoops and forceps; stone-searcher; aneurism-needles; artery-clamp forceps; dilators; ureteral buttons; needle-holder; needles, straight and curved; sutures and ligatures, of chromic and plain gut, kangaroo tendon, and silk; ligature-carriers; long tenotome; drainage-tubes; gauze; blunt hooks; clamps, various; retractors.

RETROPERITONEAL EXPOSURE OF THE KIDNEY

BY OBLIQUE LUMBAR INCISION.

Description.—The most generally applicable method of exposing the kidney, for whatever purpose indicated. The incision admits of being ex-

tended upward over the twelfth or eleventh rib, exposing them for partial excision, if necessary—as well as downward toward the anterior superior iliac spine, and onward and downward just above and parallel with Poupart's ligament, exposing, if need be, the entire length of the ureter—the parts being exposed throughout, extraperitoneally.

Preparation—Position.—See General Surgical Considerations.

Landmarks.—Twelfth rib; outer border of erector spinæ; iliac crest; Poupart's ligament.

Incision.—Begins in the triangle made by the lower border of the twelfth rib and the outer border of the erector spinæ—at a point about 1.3 cm. (½ inch) below the twelfth rib, and just to the outer border of the erector spinæ (which crosses the twelfth rib about 6.3 cm. [2½ inches] from the median line)—passes thence obliquely downward and forward in the direction of the anterior superior

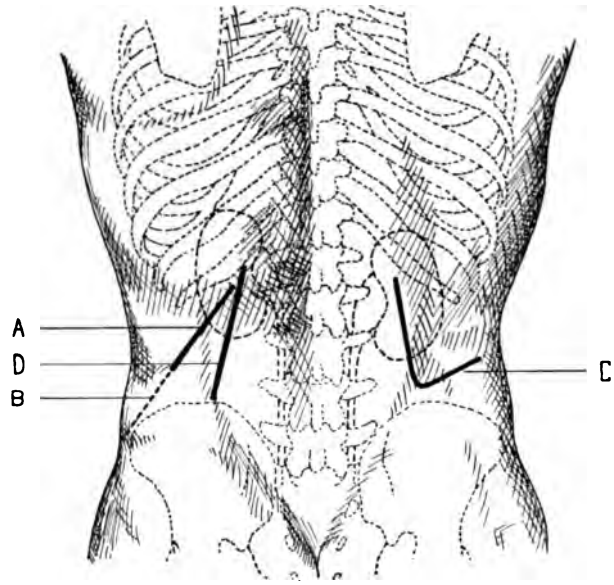

Fig. 495.—Incision for Exposure of Kidneys by the Lumbar Route:—A, Retroperitoneal exposure by oblique lumbar incision; B, Continuation of this incision where additional room is required; C, Retroperitoneal exposure by Koenig's angular lumbo-abdominal incision; D, Incision in Edebohls's operation of nephropexy.

iliac spine, generally at first for 7.5 to 10 cm. (3 to 4 inches)—and may be subsequently extended both upward and downward as mentioned. When so continued downward, it passes to within 2 to 2.5 cm. (¾ to 1 inch) of the anterior superior iliac spine, and thence turns downward and inward parallel with and about the same distance above Poupart's ligament (Fig. 495, A and B, and Fig. 496).

Operation.—(1) Incise skin and superficial fascia, exposing the posterior layer of the lumbar fascia, the anterior part of the latissimus dorsi and the posterior part of the external oblique. Continuing the incision in the original line, the anterior portion of the latissimus dorsi will be incised transversely to its fibers. The upper part of the serratus posticus inferior will be incised transversely beneath it. The posterior border of the external oblique will be

divided, and, if the incision be continued far toward the iliac crest, the knife will pass into the intermuscular cleavage line of this muscle (Fig. 497). (2) The outer border of the erector spinæ is exposed, but its sheath is not opened. The internal oblique is incised nearly at a right angle to its course. The posterior aponeurosis of the transversalis muscle (fascia lumborum) is divided also to the full length of the wound. Between the internal oblique and transversalis, branches of the last dorsal nerve and last intercostal artery may be encountered passing downward and forward near the twelfth rib—and branches of the first lumbar nerve and last lumbar artery near the iliac crest. The nerves are retracted wherever possible. The arteries are ligated with gut. All the parts are retracted as divided. (3) The outer border of the quadratus lumborum muscle and the anterior layer of the fascia lumborum are now encountered. The latter is incised to the limit of the wound. The outer border of the former is retracted—or may be incised if necessary. This divided layer is also retracted. (4) The fascia transversalis is thus exposed, and is similarly divided —when the entire depth of the wound is well retracted on each side. (5) The fatty areolar capsule of the kidney is now exposed, retroperitoneally—and is opened up, partly by careful incision, and partly by blunt dissection of the perirenal tissue—while an assistant, by pressure upon the abdominal wall, thrusts the kidney into the lumbar wound—thus exposing the surface of the organ. (6) The special object of the operation is now accomplished—and the wound treated as indicated.

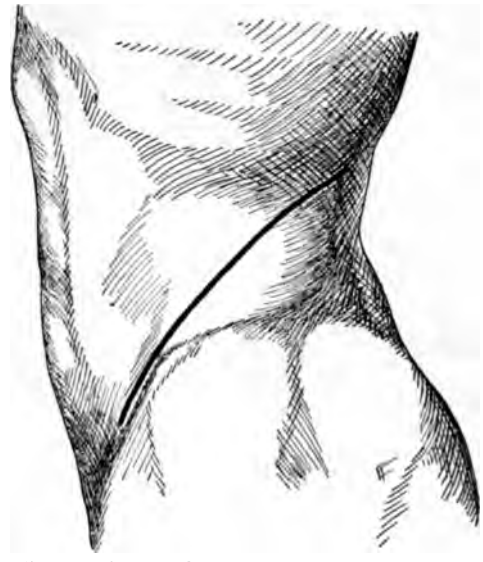

Fig. 496.—Oblique Lumbo-abdominal Incision:—For exposure of kidney and ureter.

Comment. — (1) There is more chance to separate, rather than divide, some of the muscle-fibers in this incision, if it become necessary to extend it, than in most of the other incisions. (2) In exploratory incisions, and in limited operations upon the kidney, it is generally only necessary to divide the skin, superficial fascia, lumbar fascia, latissimus dorsi, and serratus posticus inferior over a distance between the anterior border of the erector spinæ and the posterior edges of the external and internal oblique muscles. (3) In thick loins, longer incisions are necessary. (4) Where the kidney does not extend down as far as usual, the incision may be extended well over the twelfth rib (but see Surgical Anatomy). (5) Guard against opening the pleura, which is only separated by a comparatively thin layer of fibrous tissue from the renal fatty tissue at the costo-lumbar hiatus of the diaphragm. (6) Proximity of the kidney is sometimes noticed, in approaching from behind, by the finer texture of the fatty areolar tissue near it. (7) Avoid the colon, which sometimes pushes its way into the wound. (8) If, in the course of operation, more room be needed, the incision may be extended in one of three directions;—(a) backward, dividing, if necessary, the anterior border of the erector spinæ:—(b) up-

tended upward over the twelfth or eleventh rib, exposing them for partial excision, if necessary—as well as downward toward the anterior superior iliac spine, and onward and downward just above and parallel with Poupart's ligament, exposing, if need be, the entire length of the ureter—the parts being exposed throughout, extraperitoneally.

Preparation—Position.—See General Surgical Considerations.

Landmarks.—Twelfth rib; outer border of erector spinæ; iliac crest; Poupart's ligament.

Incision.—Begins in the triangle made by the lower border of the twelfth rib and the outer border of the erector spinæ—at a point about 1.3 cm. (½ inch) below the twelfth rib, and just to the outer border of the erector spinæ (which crosses the twelfth rib about 6.3 cm. [2½ inches] from the median line)—passes thence obliquely downward and forward in the direction of the anterior superior

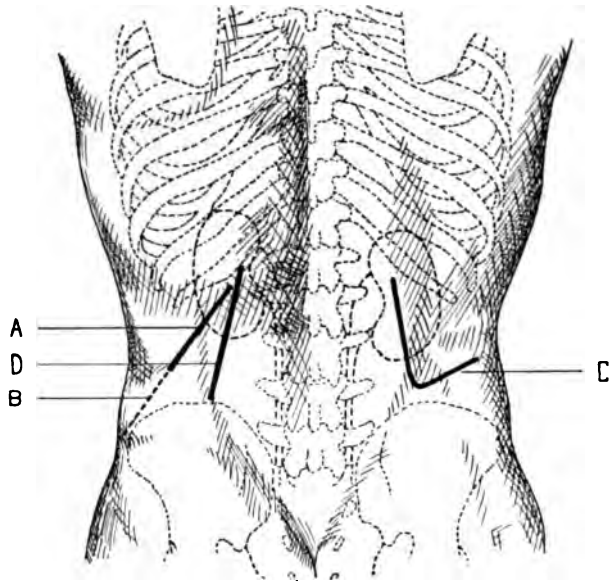

Fig. 495.—Incision for Exposure of Kidneys by the Lumbar Route:—A. Retroperitoneal exposure by oblique lumbar incision; B, Continuation of this incision where additional room is required; C, Retroperitoneal exposure by Koenig's angular lumbo-abdominal incision; D, Incision in Edebohls's operation of nephropexy.

iliac spine, generally at first for 7.5 to 10 cm. (3 to 4 inches)—and may be subsequently extended both upward and downward as mentioned. When so continued downward, it passes to within 2 to 2.5 cm. (¾ to 1 inch) of the anterior superior iliac spine, and thence turns downward and inward parallel with and about the same distance above Poupart's ligament (Fig. 495, A and B, and Fig. 496).

Operation.—(1) Incise skin and superficial fascia, exposing the posterior layer of the lumbar fascia, the anterior part of the latissimus dorsi and the posterior part of the external oblique. Continuing the incision in the original line, the anterior portion of the latissimus dorsi will be incised transversely to its fibers. The upper part of the serratus posticus inferior will be incised transversely beneath it. The posterior border of the external oblique will be

divided, and, if the incision be continued far toward the iliac crest, the knife will pass into the intermuscular cleavage line of this muscle (Fig. 497). (2) The outer border of the erector spinæ is exposed, but its sheath is not opened. The internal oblique is incised nearly at a right angle to its course. The posterior aponeurosis of the transversalis muscle (fascia lumborum) is divided also to the full length of the wound. Between the internal oblique and transversalis, branches of the last dorsal nerve and last intercostal artery may be encountered passing downward and forward near the twelfth rib—and branches of the first lumbar nerve and last lumbar artery near the iliac crest. The nerves are retracted wherever possible. The arteries are ligated with gut. All the parts are retracted as divided. (3) The outer border of the quadratus lumborum muscle and the anterior layer of the fascia lumborum are now encountered. The latter is incised to the limit of the wound. The outer border of the former is retracted—or may be incised if necessary. This divided layer is also retracted. (4) The fascia transversalis is thus exposed, and is similarly divided —when the entire depth of the wound is well retracted on each side. (5) The fatty areolar capsule of the kidney is now exposed, retroperitoneally—and is opened up, partly by careful incision, and partly by blunt dissection of the perirenal tissue—while an assistant, by pressure upon the abdominal wall, thrusts the kidney into the lumbar wound—thus exposing the surface of the organ. (6) The special object of the operation is now accomplished—and the wound treated as indicated.

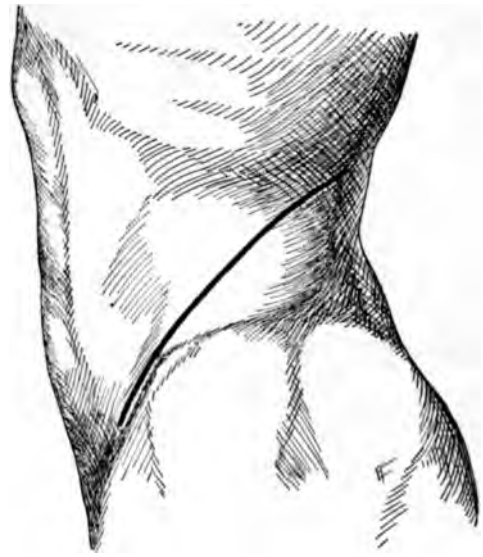

Fig. 496.—Oblique Lumbo-abdominal Incision:—For exposure of kidney and ureter.

Comment. — (1) There is more chance to separate, rather than divide, some of the muscle-fibers in this incision, if it become necessary to extend it, than in most of the other incisions. (2) In exploratory incisions, and in limited operations upon the kidney, it is generally only necessary to divide the skin, superficial fascia, lumbar fascia, latissimus dorsi, and serratus posticus inferior over a distance between the anterior border of the erector spinæ and the posterior edges of the external and internal oblique muscles. (3) In thick loins, longer incisions are necessary. (4) Where the kidney does not extend down as far as usual, the incision may be extended well over the twelfth rib (but see Surgical Anatomy). (5) Guard against opening the pleura, which is only separated by a comparatively thin layer of fibrous tissue from the renal fatty tissue at the costo-lumbar hiatus of the diaphragm. (6) Proximity of the kidney is sometimes noticed, in approaching from behind, by the finer texture of the fatty areolar tissue near it. (7) Avoid the colon, which sometimes pushes its way into the wound. (8) If, in the course of operation, more room be needed, the incision may be extended in one of three directions;—(a) backward, dividing, if necessary, the anterior border of the erector spinæ:—(b) up-

ward and backward over the twelfth rib, which may be partially excised:—**(c)** downward and forward toward the anterior superior iliac spine, and thence parallel with and about 2.5 cm. (1 inch) above Poupart's ligament. **(9)** If it be desired to examine the opposite kidney during operation (which should always be done before removing a kidney, except where that ground has been preliminarily covered by vesical catheterization of the opposite ureter), Kocher resorts to the following technic;—he divides the transversalis muscle sufficiently

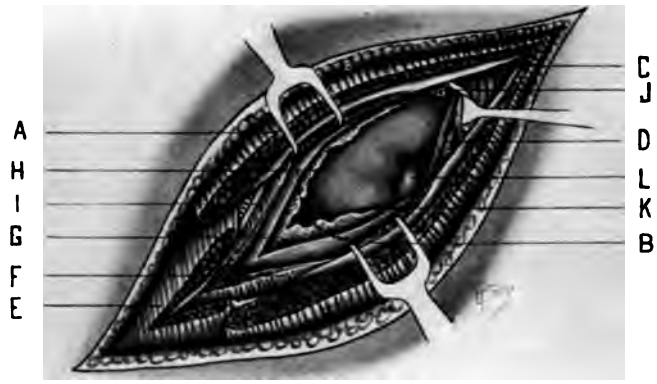

Fig. 497.—Retroperitoneal Exposure of Kidney by Oblique Lumbar Incision:—A, Latissimus dorsi; B, Serratus posticus inferior; C, Erector spinæ; D, Quadratus lumborum; E, External oblique; F, Internal oblique; G, Transversalis aponeurosis; H, Fatty areolar tissue; I, Intercostal nerve and artery; J, Last dorsal nerve and lumbar artery; K, Kidney; L, Pelvis of kidney.

far forward to expose the reflection of the peritoneum on to the colon, near the posterior axillary line—then he opens the peritoneum and passes his hand through the opening and around to the opposite kidney—the inferior surface of the liver and gall-bladder being thus palpable also. After accomplishing the examination, the opening in the peritoneum is sutured and the operation continued. **(10)** By keeping close to the outer edge of the quadratus lumborum muscle, there is minimum danger of wounding the peritoneum.

RETROPERITONEAL EXPOSURE OF THE KIDNEY

BY KOENIG'S ANGULAR LUMBO-ABDOMINAL INCISION.

Description.—A retroperitoneal exposure of the kidney where an especially large amount of room is required.

Preparation Position.—See Surgical Considerations.

Landmarks.—Twelfth rib; outer border of erector spinæ; iliac crest; umbilicus.

Incision.—Begins about 2 cm. (¾ inch) below the twelfth rib, at the outer border of the erector spinæ—passes almost vertically downward (having slight outward tendency) along the outer border of the erector spinæ, to just above the iliac crest—thence curves forward and upward and passes in a straight line toward the umbilicus, stopping at the outer border of the rectus (Fig. 495, C).

Operation.—**(1)** Incise, in the vertical portion of the incision, the skin, superficial fascia, posterior layer of the lumbar fascia, latissimus dorsi, serratus

posticus inferior, middle layer of lumbar fascia, quadratus lumborum, anterior layer of lumbar fascia, and subperitoneal fatty areolar tissue. The vessels and nerves encountered in this portion of the incision are the same as those in the oblique lumbar incision. (2) The lips of this wound are retracted —the fingers are inserted and the peritoneum detached and pushed ahead in advance of the oblique part of the wound, as it is being made. (3) The oblique portion of the incision is now carried out, dividing the skin, superficial fascia, latissimus dorsi, external oblique, internal oblique, transversalis, transversalis fascia, and subperitoneal areolar tissue. All nerves encountered are preserved, by retraction, as far as it is possible. The peritoneum is carefully detached and held out of the way ahead of the incision until its end is reached. (4) The perirenal fatty areolar tissue is now opened up and the kidney exposed. (5) The special operation is accomplished—and the wound treated accordingly.

Comment.—This operation gives abundant room, and is retroperitoneal—but is very extensive, and a weakened abdominal wall is apt to follow.

RETROPERITONEAL EXPOSURE OF THE KIDNEY

BY THE LUMBAR INTRAMUSCULAR METHOD.

Description.—A retroperitoneal exposure of the kidney in the intramuscular cleavage line and without severing important nerves and vessels. Chiefly for diagnostic purposes—and such steps as can be carried out through a limited space. The principle involved is the same as that in McBurney's intramuscular operation.

Preparation—Position.—See General Surgical Considerations.

Landmarks.—Tip of twelfth rib; anterior superior iliac spine.

Incision.—Begins just internal to the anterior superior iliac spine—and passes upward and backward, in the cleavage line of the external oblique, to the tip of the twelfth rib.

Operation.—Incise skin and superficial fascia—expose external oblique and separate its fibers in their cleavage line, throughout the entire length of the wound, from the anterior superior iliac spine to the tip of the twelfth rib—retract the separated fibers forward and upward, and backward and downward—expose the internal oblique, running almost directly across the external oblique, and separate its fibers similarly, along as much of the line as possible, from the ninth costal cartilage toward the posterior superior iliac spine, and retract the separated fibers forward and downward, and backward and upward—expose the transversalis and separate its fibers similarly, and retract the separated fibers upward and downward—divide the transversalis fascia—then the subperitoneal connective tissue—open up the perirenal fatty areolar tissue —retract the walls of the wound well—and expose the kidney.

TRANSPERITONEAL EXPOSURE OF THE KIDNEY

BY VERTICAL INCISION IN THE LINEA SEMILUNARIS – LANGENBUCH'S OPERATION.

Description.—An anterior transperitoneal exposure, with division of the mesocolon over the kidney. Chiefly indicated in large tumors—in narrow, deformed lumbar regions—in thick lumbar regions—where much room is required—and as furnishing an easy approach and examination of both kidneys

ward and backward over the twelfth rib, which may be partially excised:—**(c)** downward and forward toward the anterior superior iliac spine, and thence parallel with and about 2.5 cm. (1 inch) above Poupart's ligament. **(9)** If it be desired to examine the opposite kidney during operation (which should always be done before removing a kidney, except where that ground has been preliminarily covered by vesical catheterization of the opposite ureter), Kocher resorts to the following technic;—he divides the transversalis muscle sufficiently

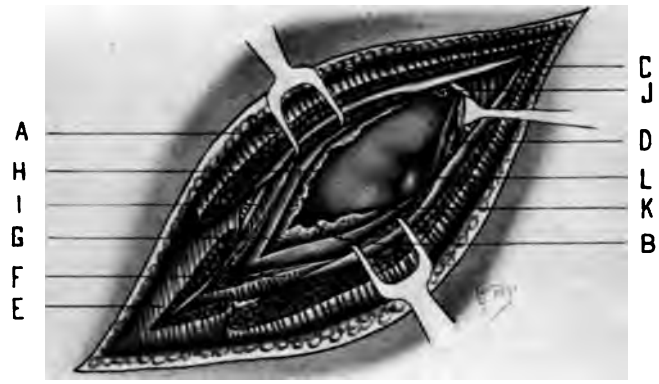

Fig. 497.—RETROPERITONEAL EXPOSURE OF KIDNEY BY OBLIQUE LUMBAR INCISION:—A, Latissimus dorsi; B, Serratus posticus inferior; C, Erector spinæ; D, Quadratus lumborum; E, External oblique; F, Internal oblique; G, Transversalis aponeurosis; H, Fatty areolar tissue; I, Intercostal nerve and artery; J, Last dorsal nerve and lumbar artery; K, Kidney; L, Pelvis of kidney.

far forward to expose the reflection of the peritoneum on to the colon, near the posterior axillary line—then he opens the peritoneum and passes his hand through the opening and around to the opposite kidney—the inferior surface of the liver and gall-bladder being thus palpable also. After accomplishing the examination, the opening in the peritoneum is sutured and the operation continued. **(10)** By keeping close to the outer edge of the quadratus lumborum muscle, there is minimum danger of wounding the peritoneum.

RETROPERITONEAL EXPOSURE OF THE KIDNEY

BY KOENIG'S ANGULAR LUMBO-ABDOMINAL INCISION.

Description.—A retroperitoneal exposure of the kidney where an especially large amount of room is required.

Preparation—Position.—See Surgical Considerations.

Landmarks.—Twelfth rib; outer border of erector spinæ; iliac crest; umbilicus.

Incision.—Begins about 2 cm. (¾ inch) below the twelfth rib, at the outer border of the erector spinæ—passes almost vertically downward (having slight outward tendency) along the outer border of the erector spinæ, to just above the iliac crest—thence curves forward and upward and passes in a straight line toward the umbilicus, stopping at the outer border of the rectus (Fig. 495, C).

Operation. (1) Incise, in the vertical portion of the incision, the skin, superficial fascia, posterior layer of the lumbar fascia, latissimus dorsi, serratus

posticus inferior, middle layer of lumbar fascia, quadratus lumborum, anterior layer of lumbar fascia, and subperitoneal fatty areolar tissue. The vessels and nerves encountered in this portion of the incision are the same as those in the oblique lumbar incision. (2) The lips of this wound are retracted —the fingers are inserted and the peritoneum detached and pushed ahead in advance of the oblique part of the wound, as it is being made. (3) The oblique portion of the incision is now carried out, dividing the skin, superficial fascia, latissimus dorsi, external oblique, internal oblique, transversalis, transversalis fascia, and subperitoneal areolar tissue. All nerves encountered are preserved, by retraction, as far as it is possible. The peritoneum is carefully detached and held out of the way ahead of the incision until its end is reached. (4) The perirenal fatty areolar tissue is now opened up and the kidney exposed. (5) The special operation is accomplished—and the wound treated accordingly.

Comment.—This operation gives abundant room, and is retroperitoneal—but is very extensive, and a weakened abdominal wall is apt to follow.

RETROPERITONEAL EXPOSURE OF THE KIDNEY

BY THE LUMBAR INTRAMUSCULAR METHOD.

Description.—A retroperitoneal exposure of the kidney in the intramuscular cleavage line and without severing important nerves and vessels. Chiefly for diagnostic purposes—and such steps as can be carried out through a limited space. The principle involved is the same as that in McBurney's intramuscular operation.

Preparation—Position.—See General Surgical Considerations.

Landmarks.—Tip of twelfth rib; anterior superior iliac spine.

Incision.—Begins just internal to the anterior superior iliac spine—and passes upward and backward, in the cleavage line of the external oblique, to the tip of the twelfth rib.

Operation.—Incise skin and superficial fascia—expose external oblique and separate its fibers in their cleavage line, throughout the entire length of the wound, from the anterior superior iliac spine to the tip of the twelfth rib—retract the separated fibers forward and upward, and backward and downward—expose the internal oblique, running almost directly across the external oblique, and separate its fibers similarly, along as much of the line as possible. from the ninth costal cartilage toward the posterior superior iliac spine, and retract the separated fibers forward and downward, and backward and upward—expose the transversalis and separate its fibers similarly, and retract the separated fibers upward and downward—divide the transversalis fascia—then the subperitoneal connective tissue—open up the perirenal fatty areolar tissue —retract the walls of the wound well—and expose the kidney.

TRANSPERITONEAL EXPOSURE OF THE KIDNEY

BY VERTICAL INCISION IN THE LINEA SEMILUNARIS – LANGENBUCH'S OPERATION.

Description.—An anterior transperitoneal exposure, with division of the mesocolon over the kidney. Chiefly indicated in large tumors—in narrow, deformed lumbar regions—in thick lumbar regions—where much room is required—and as furnishing an easy approach and examination of both kidneys

and ureters. Incision over the linea semilunaris gives a more direct route than incision in the median line.

Preparation—Position.—As for median abdominal section.

Landmarks.—Linea semilunaris; costal arch.

Incision.—Begins just below the border of the ribs, in the linea semilunaris of the affected side, and extends vertically downward in that line for 10 or 12.5 cm. (4 or 5 inches)—the incision having its center about opposite the umbilicus.

Operation.—(1) The abdominal cavity is opened in the usual way and the wound well retracted. The small intestines are held out of the way by gauze pads and special retractors. The hand is introduced and the condition of both kidneys examined. (2) The colon is displaced toward the median line

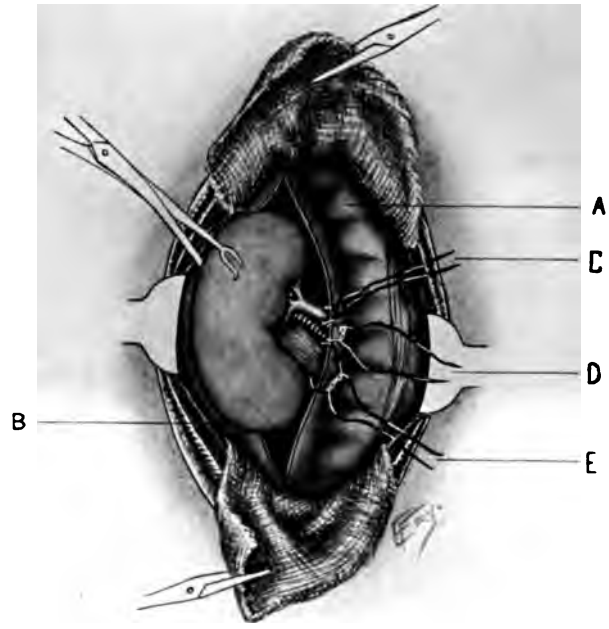

Fig. 498.—Transperitoneal Exposure of Kidney, by Vertical Incision in Linea Semilunaris (Langenbuch's Operation):—A, Ascending colon displaced toward median line; B, Outer layer of mesocolon incised over kidney; C, Ligature around renal vein; D, Ligature of renal artery; E, Ligature of ureter.

and the outer layer of the mesocolon is incised in a vertical direction over the site of the kidney—thus avoiding the vessels to the colon (Fig. 498). (3) The fingers of the surgeon are passed through this incision in the mesocolon down upon the kidney—the posterior surface of which is then freed and exposed, as it lies in its fatty areolar bed. (4) The special steps of the operation are then concluded—and the abdomen closed. For the details of total nephrectomy by the abdominal route, see page 860.

Comment. (1) Where drainage is necessary in connection with the anterior transperitoneal operation, a counter-opening is made in the loin—the incision being made from without upon a sound pressing against the lumbar wall from within. (2) Where it is necessary, in the anterior operation, to fix

a diseased ureter into the lumbar skin, an incision is made by cutting from without upon a pair of forceps introduced from within, near the outer edge of the quadratus lumborum. (3) Before closing the abdomen, the incised wound in the mesocolon is sutured with gut.

TRANSPERITONEAL EXPOSURE OF THE KIDNEY

BY MEDIAN ABDOMINAL SECTION.

Description.—Exposure of the kidney by an incision in the median line. Practically the same as exposure by vertical incision in the linea semilunaris, except for the position of the incision—the operation last described giving the most direct access to the kidney.

Preparation—Position—Landmarks—Incision.—As in median abdominal section.

Operation.—Essentially the same as in exposure by the vertical incision in the linea semilunaris. Having displaced the intestines to the opposite side, the mesocolon is divided over the kidney. The lateral layer of the mesocolon is preferably divided. If circumstances make this inconvenient, the median layer of the mesocolon is divided. Having passed through the opening in the mesocolon, the kidney is isolated and exposed—its anterior surface, lateral borders, upper and lower poles, posterior surface, and pelvis being made accessible. Having accomplished the object of the operation, the incision in the mesocolon is sutured—and the abdomen closed.

Comment.—Wherever the fatty areolar capsule has been opened up very extensively in exposing the proper capsule of the kidney, at the close of the operation the fatty areolar connective tissue is sutured about the kidney again —and, if necessary, anchored, by a chromic gut stitch or two, to the neighboring structures.

EXPOSURE OF THE KIDNEY BY THE COMBINED ABDOMINO-LUMBAR OPERATION

BY ANTERIOR TRANSPERITONEAL AND POSTERIOR RETROPERITONEAL INCISIONS.

Description.—Consists of one of the anterior transperitoneal operations combined with one of the posterior retroperitoneal operations. Generally resorted to where it is wished to make a previous examination of the abdominal cavity, chiefly for diagnostic purposes connected with both kidneys and ureters —or where a large tumor is to be removed. The intra-abdominal operation is first performed. Guided by one hand within the peritoneal cavity, the kidney can be exposed through a smaller lumbar wound, and with greater ease, and with less danger of wounding the colon and peritoneum. The great objection, however, is the double operation—and the involvement of the peritoneal cavity.

Preparation.—As for both the abdominal and lumbar operations.

Position.—Patient is supine during the anterior operation, and partly upon the side during the lumbar incision. The surgeon's position changes with the steps of the operation.

Landmarks.—Those of both the abdominal and lumbar operations.

Incision.—The incisions usually adopted are, for the anterior operation, Langenbuch's vertical incision in the linea semilunaris—and, for the posterior operation, the oblique lumbar incision. See the descriptions of these incisions, pages 845 and 841.

Operation.—The abdominal operation is first done—the examination made—and then, guided by the left hand within the abdomen, the lumbar incision is made and the operation completed extraperitoneally, accomplishing the special object sought through the posterior wound, as a rule—after which, the abdomen is closed. The posterior wound is either entirely closed—or partially closed and drained, as indicated.

EXPLORATORY PUNCTURE OF THE KIDNEY.

Description.—Exploration of the kidney by solid needle for calculus—or by hollow needle and syringe for pus or other fluid. Two forms of puncture may be made—(**a**) Puncture from Without; the puncture is here made through unbroken skin, or, in the case of a large needle, after incising the skin alone;—the needle-puncture is made on anatomical grounds, and is made below the level of the pleura (see pages 599 and 838). (See Comment.) (**b**) Puncture after exposure of the Kidney—which will be here described. In the latter case the exposure is usually made through the oblique lumbar incision.

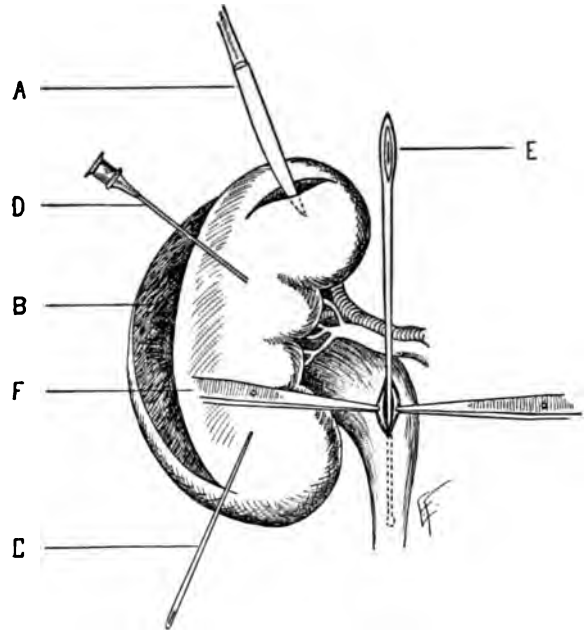

Fig. 499.—Exploratory Incision and Puncture of Kidney and Pelvis:—A, Nephrotomy; B, Bisection of kidney; C, Exploratory puncture of kidney substance with solid needle; D, Exploratory puncture with aspiratory needle; E, Sound passed through pelvis of kidney to explore ureter; F, Forceps holding apart lips of pyelotomy wound.

Preparation—Position—Landmarks—Incision.—As for exposure of the kidney by an oblique lumbar incision.

Operation.—Having exposed and incised the perirenal fatty tissue, the kidney surface (the proper capsule) is exposed over as large an area as considered necessary, by a blunt dissector and the finger. The kidney is then steadied by the fingers of the operator's left hand—while a needle, held between the right index and thumb (remembering the dimensions of the kidney), is thrust into the viscus—always being introduced in a straight line, and thrust from its point of entrance toward the hilum—being introduced, preferably, from the convex border—next, in the sides—and, last, at the hilum. A needle may be thus introduced a dozen or more times—always being withdrawn and re-entered before being made to travel in a new direction. The operation will be concluded according to the result of the puncture. (Fig. 499.)

Comment.—Transperitoneal puncture should never be made—it is both unsafe and uncertain. Extraperitoneal lumbar puncture is not so dangerous—and, when made through the unbroken skin, while not so unsafe as transperitoneal puncture, it is quite uncertain. The most advisable form of puncture is first to expose the kidney deliberately, and then to puncture.

NEPHROTOMY.

Description.—Incision of the kidney substance for the removal of calculi or tumors, or for the evacuation of pus or other fluid from the kidney proper, calices or pelvis—or for nephralgia. The kidney may be exposed by any of the incisions given—the oblique lumbar incision being probably the best.

Preparation—Position—Landmarks—Incision.—As for exposure of the kidney by the oblique lumbar incision.

Operation.—(1) Having exposed the kidney and brought it into the field, by counter-pressure from in front, and by drawing it down from under the rib the site of the calculus or fluid is discovered by the introduction of the solid or hollow needle, after the manner described under Puncture of the Kidney. (2) Having located the object, an incision is made down upon it exactly as described under Nephro-lithotomy (page 850), stone being the most usual indication for Nephrotomy. (3) Following the operation for stone, the kidney wound is treated as under Nephro-lithotomy. (4) Following the operation for pus or fluid, drainage is carried down into the cavity of pus or fluid—after, where it is possible, the lips of the cavity have been brought up and sutured to the deeper structures of the abdominal wound—or the cavity may be partly closed around a drainage-tube going to its bottom. (5) Where the kidney has been cut into and no cause for drainage is found, the kidney substance is brought together by alternate deep and superficial catgut sutures. (6) The fatty areolar capsule is also closed by deep buried gut sutures in all such cases. (7) The lumbar wound is sutured in part, leaving room for drainage—or entirely, as indicated. (Fig. 499.)

Comment.—(1) Where hemorrhage is severe on cutting into the kidney, it may be controlled by compressing the pedicle (which should have been demonstrated in advance) between the fingers or special clamps—or by gauze packing. Hemorrhage from a healthy kidney is often enormous—while it is generally much less from a diseased one. (2) Incision along the convex border of the kidney is always preferable. It is better to remove a calculus in the pelvis of the kidney through an incision from the convex border than by an incision directly into the pelvis—fistula being more apt to follow incision of the pelvis. (3) Where all is favorable, complete suturing of the kidney substance should be done after the removal of a stone. (4) Splitting of the capsule alone may be done in Nephralgia. (5) It is often hard to find the pelvis in the normal kidney, even after incising from the convex border. (6) After nephrotomy for pus, always unite the margins of the cavity to the structures in the lower part of the wound, if possible—to avoid, if possible, infection of the perirenal tissue. (7) In unhealthy or suspicious cases, drainage is established down to the kidney—or, if indicated, into not only the kidney itself, but even into the pelvis—with gauze or tube, preferably gauze packed into the pelvis and calices.

Bisection of Kidney.—In cases where limited incisions into the kidney substance will not suffice, it is sometimes necessary to lay the kidney widely open—splitting it into two halves flat-wise, or "bisecting" it. An incision is

made in the middle line of the convex border, from the upper to the lower pole —passing straight into the pelvis—thus dividing the fewest vessels and uriniferous tubules. The narrow calices are dilated with the tip of the finger or a pair of forceps—a probe is passed thence into the pelvis—and a bougie may be passed down the ureter even into the bladder. Having accomplished the object of the exploration, and, in suitable cases, having corrected the condition, the bisected kidney is sutured with alternate deep and superficial catgut sutures—the deep ones passing through the entire thickness of the kidney. (Fig. 500.)

PYELOTOMY.

Description.—Pyelotomy, or Pelviotomy, consists in the incision of the pelvis of the kidney. Generally resorted to for calculus, or for exploration. Usually done by the oblique lumbar incision. Pelvio-lithotomy, or Pyelo-lithotomy, is the same operation done especially for the removal of stone from the pelvis of the kidney.

Preparation—Position—Landmarks—Incision.—As for exposure of the kidney by an oblique lumbar incision.

Operation.—Having incised and freed the fatty capsule and exposed the kidney by blunt dissection, the organ is brought forward and steadied—as far out into the wound as possible. A longitudinal incision (in the course of the pelvis) is made through the posterior wall of the pelvis. Scarcely any hemorrhage follows incision of the pelvis, as a rule—in contradistinction to the rather free hemorrhage which nearly always at first follows incision of the kidney parenchyma. Insert two temporary silk traction-sutures into the wound-lips of the pelvis. Into the opening thus made and held apart by the traction-sutures, a special sound, or the finger, is introduced and an examination made for the object suspected—both in the calices above, and in the ureter below. Having accomplished the object of the operation (which is often the removal of a calculus) the wound in the pelvis, in clean cases, is closed by interrupted or continuous sutures, applied like the Lembert suturing, through all the coats of the pelvis except the mucous. For fear of leakage, drainage is generally established down to the pelvis. In infected cases, free drainage is established to and even into the pelvis—in the latter case, omitting the suturing of the entire pelvis-wound. The lumbar wound is closed up to the exit of the drain. (Fig. 499, E.)

Comment.—(1) While incision into the pelvis is followed by little or no hemorrhage, and admits of probing the ureter, it gives no access to the kidney parenchyma—and but imperfect access to the calices—and is more apt to be followed by urinary fistula. (2) After Pyelotomy, in order to avoid urinary fistula, especial care should be taken to see that the ureter is patulous—if it be not patulous, the obstacle should be removed—or an ureterostomy, or other operation, be done. (3) The calix, or the site of the lodged stone, may have to be dilated with special forceps before it can be loosened and removed.

NEPHRO-LITHOTOMY.

Description.—Incision of the kidney for the removal of stone. The operation consists, practically, of a Nephrotomy—and is generally done through the oblique lumbar incision.

Preparation—Position—Landmarks—Incision.—As for exposure of kidney by oblique lumbar incision.

Operation.—(1) Having located the kidney and pressed (by counter-pressure) and drawn it into the wound, divide the fatty areolar tissue and expose the surface of the organ. (2) Insinuate the index-finger (of that hand corresponding with the kidney involved) beneath the fatty capsule, through the freeing incision, and feel the organ by palpating it between thumb and index, counter-pressure being maintained the while. If the stone be palpated, steps for its removal may be at once undertaken. (3) If the stone be not detected by palpation, several means of investigation are available; (a) While the kidney is steadied, a small, long, solid needle may be thrust in various directions, entered at the external border and thrust toward the hilum—being withdrawn between each thrust. This is the simplest and best instrumental exploration. (b) A special sound may be passed through an incision made in one of the lowest calices and the pelvis of the kidney thus examined, or a finger may be introduced. Chiefly indicated when a stone is impacted there and is not removable from the external border of the kidney. (c) An incision along the convex border of the kidney, lengthwise of the kidney, may be made—passing as far into the substance of the organ as indicated, even into the calices. *Note*—Methods "a" and "c" are to be preferred to opening the pelvis of the kidney, which is apt to be followed by fistula. (4) When located, the stone is cut down upon by the most direct route, by a straight incision from the cortex toward the hilum—and, when reached, the calculus is removed by the finger alone, or aided by special scoop or forceps—or may be broken and removed in pieces. (5) Having removed the calculus, and cleansed by douching or gauze-sponging, as indicated, the site occupied by the stone, the wound in the kidney, in clean cases, should be repaired by fine catgut (see Nephrorrhaphy), and temporary drainage down to the kidney established. If purulent conditions be present, the kidney wound should not be entirely sutured—and drainage to, or into, the pus cavity be instituted.

Comment.—(1) Following free incision of the kidney substance, considerable hemorrhage is apt to occur at first, but is generally capable of speedy arrest by gauze pressure, or hot douching—or, these failing, by compression of the pedicle. (2) Incisions into the kidney substance should be made in a straight line toward the hilum (centering toward the hilum like the spokes of a wheel). (3) To aid in examining the pelvis of the kidney, turn the external border of the kidney upward and forward. (4) In manipulating near the anterior wall of the kidney, take care lest the peritoneal cavity be entered. (5) Where the kidney has been exposed by an anterior incision (transperitoneal) and drainage is necessary, a posterior counter-opening should be made by cutting from without down upon some instrument pressed against the lumbar wall from within. The peritoneum is then closed over the anterior aspect of the kidney, and the posterior wound, with drainage, is left open. These remarks just made apply to the sometimes indicated removal by a posterior incision of a stone which has been discovered by an anterior operation.

NEPHRORRHAPHY.

Description.—Suturing of the kidney substance—here used in connection with suturing kidney wounds, either accidental or those made in the course of an operation. The kidney is exposed either by enlarging the original wound—or, if deliberately exposed, generally by the oblique lumbar incision. Every Nephropexy involves nephrorrhaphy—but not vice versa. See Nephropexy, page 852.

Operation.—Having exposed the kidney and brought it into convenient position for manipulation, the edges of the wound are brought together and sutured with catgut, carried upon a fully curved needle held in a needle-holder. Interrupted sutures are generally more satisfactory than continuous sutures. Where the wound is superficial, a single row of sutures, all of the same depth, suffices. Where the wound is more extensive, it is well to put in a double row—a deeper row outlying the more superficial row,—or a single row may be used, putting in each alternate suture a deep one. Ordinary suture may be used—either interrupted or continuous—or the Halsted quilt suture may be used, especially where much loss of kidney substance has occurred. (Fig. 500.)

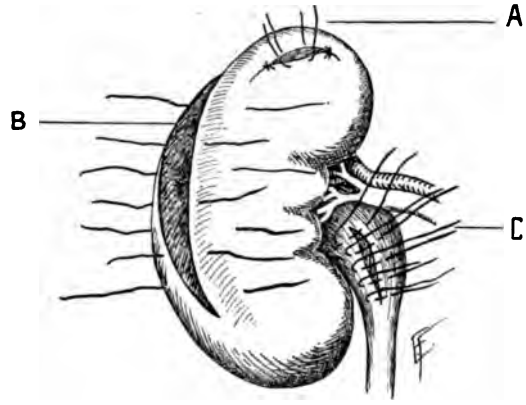

Fig. 500.—NEPHRORRHAPHY AND PYELORRHAPHY:—A, Small nephrotomy wound closed with superficial sutures; B, Long and deep nephrotomy wound closed with alternate superficial and deep sutures; C, Pyelotomy wound closed with Lembert sutures.

NEPHROPEXY

BY SUTURING SPLIT AND EVERTED PROPER CAPSULE OF KIDNEY TO LUMBAR WALL—EDEBOHLS'S OPERATION.

Description.—The fibrous capsule of the kidney is split along the convexity of the organ and peeled back toward the pelvis, on both aspects, for about half-way—after which, chromic gut sutures are passed through both the detached and undetached portions of this capsule, and through the lips of the lumbar wound. When these sutures are tightened and tied, they approximate the partly decapsulated kidney to the raw portions of the lumbar wound.

Position.—Patient lies prone upon Edebohls's kidney air-cushion—which, pressing against the abdomen, aids in bringing the kidney prominently into the wound. Surgeon stands on left side in operating upon left kidney, cutting from above downward—and on right side in operating upon right kidney, cutting from below upward (or stands on opposite side of body, cutting from above downward). Assistant stands upon the opposite side of the body.

Landmarks.—Twelfth rib; iliac crest; outer border of erector spinæ muscle; anatomical relations of kidney.

Incision.—Straight incision along the external border of the erector spinæ muscle, passing from the inferior border of the twelfth rib to the iliac crest. Where the space between rib and ilium is very narrow, this incision may begin at the same point but run more obliquely and reach the ilium further to the outer side of the erector spinæ. (Fig. 495, D.)

Operation.—(1) Incise skin and fascia. Recognize the latissimus dorsi and separate its fibers in their cleavage line—beginning the separation over the outer aspect of the erector spinæ and continuing it upward and outward. The sheath of the erector spinæ is not opened. (2) Divide the transversalis fascia,

exposing the perirenal fatty areolar tissue. If the ilio-hypogastric nerve cannot be retracted to one side, it is cut and subsequently sutured with gut, after the kidney has been sutured into place. (3) The sheath of the quadratus lumborum is incised from the twelfth rib to the iliac crest, along the anterior surface of its lateral border—exposing, by the retraction of its incised edges, considerable raw muscle. (4) The kidney is now freed by blunt dissection, aided by clips of curved, blunt scissors, if necessary—and is delivered upon the back, surrounded by its fatty capsule—which delivery is aided by rolling the patient up and down upon the air-pillow. The size of the opening in the abdominal parietes may be increased, if need be. (5) Dissect away the entire fatty capsule from the proper fibrous capsule of the kidney. (6) Any exploration of the kidney by palpation, *x*-raying, or instrumental means may now be done - and any measure carried out that may be indicated. (7) At this stage,

Fig. 501.—NEPHROPEXY—Edebohls's Operation:—I, Placing fixation or suspension sutures—the kidney is shown delivered through lumbar wound—the proper capsule split and stripped back halfway—and the four fixation sutures passed through reflected and attached portions of proper capsule, and not penetrating kidney substance. (Modified from Edebohls.)

if the removal of the appendix vermiformis be indicated—which the author of the operation considers to be so in a certain percentage of cases—the peritoneum is opened external to the kidney, and to the outer side of the ascending colon—part of the ascending colon is drawn out and one of its longitudinal bands is followed down to the cæcum and the appendix thus located at the termination of the muscular band—after which the appendix is delivered into the wound (the kidney having been temporarily replaced)—and is either inverted entire into the cæcum, after ligating the meso-appendix, or excised and the stump treated according to the operator's individual ideas. (8) Following the replacing of the intestines, the author of the operation—who considers that there is an association, in a certain percentage of cases, between nephroptosis and disease of the bile-passages—explores, by palpation, the gall-bladder,

cystic and common ducts, inferior aspect of liver, and the pyloric end of the stomach, through the lumbar wound. (9) The peritoneal wound is then closed and the kidney again delivered through the lumbar wound, in preparation for anchorage. Where the peritoneum has not been opened, the kidney remains delivered, as described under (4), from the time of its first exposure. (10) Incise the proper capsule of the kidney at the center of its convex border, carefully avoiding entering the kidney substance. Pass a grooved director between the fibrous capsule and kidney proper, first toward the upper pole, and then toward the lower pole, to and half-way around both poles. The fibrous capsule is then separated from the kidney by blunt dissection, from the line of incision, peeling it off (as the skin from an orange) on both sides toward the pelvis—until practically one-half of the kidney is denuded—the detached por-

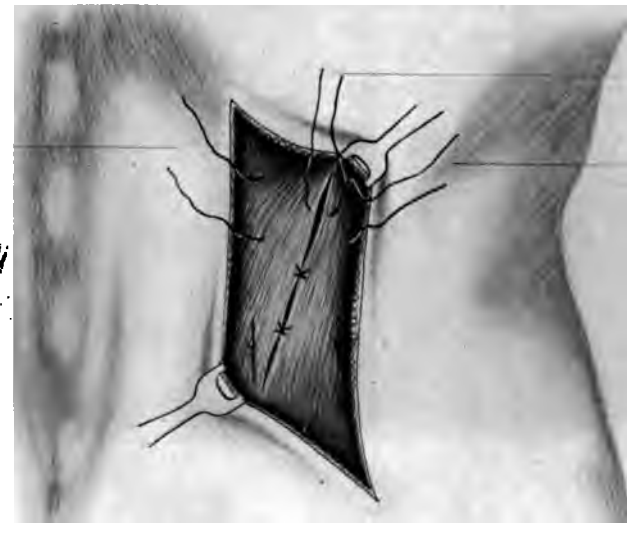

Fig. 502.—NEPHROPEXY—Edebohls's Operation: —II, Anchoring kidney and closing lumbar wound: —the skin wound is shown retracted, and the kidney has been returned within abdominal wound. A, A, Two upper buried fixation sutures, untied. The two lower fixation sutures are tied. B, Untied buried suture uniting lips of lumbar wound in cleavage line of latissimus dorsi. Similar sutures below are tied. (Modified from Edebohls.)

tion remaining continuous with the undetached portion, and turned back upon the latter as the lapel of a coat. If the proper capsule appear excessive, a portion may be excised (Fig. 501). (11) Four forty-day chromic gut fixation or suspension sutures are now introduced through both that portion of the proper capsule which has been detached and reflected, and through the still adherent portion—the passage of the sutures occurring near the line of reflection and being accomplished as shown in Fig. 501,—two being placed upon the anterior and two upon the posterior aspect of the kidney, at the center of the upper and lower halves on each side. A straight Hagedorn needle is used—the suture is carried from within outward entirely through the reflected proper capsule, near the line of reflection, travels transversely to the axis of the kidney and enters the attached portion of the proper capsule (directly opposite its point of emer-

gence from the detached portion) and pierces it from without inward, just beyond the line of reflection—thence the Hagedorn needle travels, flatwise, entirely between the proper capsule and the kidney substance, parallel with and just below the line of reflection, for 2 or 3 cm. ($\frac{3}{4}$ to $1\frac{1}{4}$ inches)—thence emerges through the attached capsule from within outward—and, traveling transversely to the axis of the kidney, passes through the reflected proper capsule from without inward, parallel with the companion limb of the suture. (**12**) Having placed all four sutures, the kidney, with the eight suture ends hanging free, is returned within the body. Each suture is now passed through the entire lumbar wall, from within outward—either by threading a needle upon each and penetrating the wall from within outward, or by passing a Reverdin needle through the abdominal parietes from without and drawing the sutures through from within. The four inner sutures will thus pierce the lumbar wall on the inner side of the incision, and at a distance from each other equivalent to the distances apart at which they penetrate the proper capsule—and will pass through the retracted sheath of the quadratus lumborum near its edge, through the quadratus muscle, and through the erector spinæ. The four outer sutures will pierce the lumbar wall on the outer side of the incision, at the same distance from each other as those of the opposite side, and each at a distance from its companion suture of the opposite side equivalent to the antero-posterior thickness of the kidney—and will pass through the transversalis fascia and the latissimus dorsi muscle. The highest sutures pass through immediately below the last rib. These eight sutures are, at first, left untied. (**13**) The incision in the lumbar wall is now closed, in the cleavage line of the latissimus dorsi, by from four to six deeply buried interrupted sutures of forty-day chromic gut, in such a manner as to turn the raw surface of the quadratus lumborum muscle toward the kidney. This is accomplished by suturing the latissimus dorsi and lumbar fascia, composing the external margin of the wound—to the latissimus dorsi, the sheath of the erector spinæ, and the external margin of the incised sheath of the quadratus lumborum, composing the inner margin of the wound (Fig. 502). (**14**) The eight free suspension or fixation sutures are now drawn taut, thus snugly approximating the decapsulated convex surface of the kidney into contact with the raw substance of the quadratus lumborum, from rib to ilium

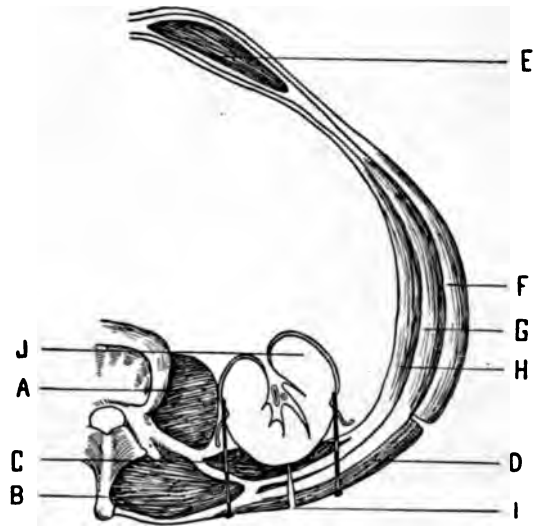

Fig. 503.—NEPHROPEXY—Edebohls's Operation:—III, Cross-section of region of operation. A, Psoas magnus; B, Erector spinæ; C, Quadratus lumborum; D, Latissimus dorsi; E, Rectus abdominis; F, External oblique; G, Internal oblique; H, Transversalis; I, Lumbar incision exposing kidney; J, The decapsulated convexity of kidney is shown approximated to raw substance of quadratus lumborum by the fixation-sutures seen passing through both the detached and adherent portions of proper kidney capsule. (Modified from Edebohls.)

—and are then tied (Fig. 503). (15) The skin and fascia are then closed in the line of the original incision, with a subcuticular suture—and a broad lumbar dressing applied.

NEPHROPEXY

BY SUTURING SPLIT PROPER CAPSULE AND PARENCHYMA OF KIDNEY TO LUMBAR WALL, BY OBLIQUE LUMBAR INCISION—TUFFIER'S OPERATION.

Description.—Anchoring of an abnormally movable kidney into its own or another adjacent site—by suturing of the parenchyma and partially stripped fibrous capsule to the lumbar wall or lower ribs. The kidney may be exposed through any of the posterior incisions recently described—but is generally exposed through the oblique lumbar incision.

Preparation—Position—Landmarks—Incision.—As for exposure of the kidney by an oblique lumbar incision.

Operation.—(1) Having exposed the kidney and brought it well into the wound, partly by pressure from the abdomen, and partly by drawing the organ downward and backward from under the rib (or simply backward, where already much displaced and loosened from its natural position), the fatty areolar capsule is divided and partly turned backward, exposing the kidney and its proper fibrous capsule. (2) Trim away any excess of fatty capsule. Incise the proper fibrous capsule of the kidney along its mid-posterior aspect, in the long axis of the kidney and for its entire length—adding a cross-cut, at right angles, at either end of the vertical incision, of about 2.5 cm. (1 inch) in length, half of its length being on either side of the vertical cut. Peel back the fibrous capsule thus liberated for about 1.3 cm. (½ inch) on either side of the median incision. Pass from four to six chromic gut or kangaroo tendon sutures, in a curved needle, held in a holder, so as to include, on one side, the deeper structures in one lip of the lumbar wound (but not the entire thickness of the lumbar wound), the transversalis fascia, fatty capsule, reflected portion of fibrous capsule, part of unreflected portion of fibrous capsule, and about 1.3 cm. (½ inch) of kidney substance, —emerging from the kidney substance on the opposite side, it takes up, in reverse order, part of the unreflected portion of the kidney capsule, reflected portion of the proper capsule, fatty capsule, transversalis fascia and deeper structures in the opposite lip of the lumbar wound (Fig. 504). These are tied as buried sutures, simultaneously drawing the kidney up to the lumbar fascia, posterior abdominal wall, and borders of the wound, and, at the same time, approximating the deeper parts of the lips of the wound. Care is taken to draw the kidney up to and under the lips of the wound and in contact with as much raw surface as possible—but not into and between the wound. It is also essential to see that the reflected most, to of the proper capsule remains spread out with its raw surface upper portion add to the extent of raw surface for adhesion. (3) The upper depth and

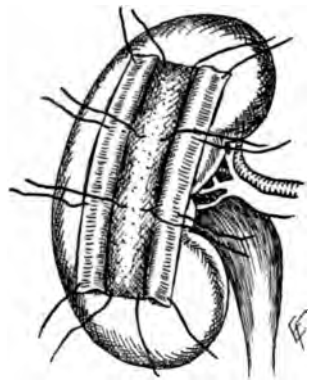

Fig. 504.—NEPHROPEXY BY SUTURE OF SPLIT CAPSULE AND KIDNEY PARENCHYMA:—Sutures are seen penetrating kidney substance and split capsule, which latter has been turned back on either side. The outer limbs of the sutures are ready to be carried through site of abdominal wall, or other site, to which kidney will be approximated by tightening the sutures. Tuffier's method.

skin margins of the wound are then closed with interrupted sutures of silk or chromic gut.

Comment.—(1) This may be regarded as one of the best methods of Nephropexy—granulations of the raw surface of the kidney and capsule form stronger adhesions than when the kidney is not partly stripped. And stronger union is formed than when the stripped capsule alone is sutured into the wound (instead of the stripped capsule and kidney substance). (2) The split fibrous capsule is sometimes also sutured to the periosteum of the twelfth rib. (3) In some cases gauze packing is used down to the kidney in the center of the wound, to strengthen adhesion by granulation. (4) Avoid including nerves in suturing of the kidney to the lumbar wall. (5) Deep drainage may be temporarily used—but is generally not indicated.

NEPHROPEXY

BY SIMPLE SUTURING.

Description.—Here neither the fatty nor the fibrous capsule of the kidney is split—one or both of these structures being sutured to some neighboring structure. See, further, "Description" of the last operation. The kidney may be exposed by any of the incisions given—the oblique lumbar incision being preferable

Preparation—Position—Landmarks—Incision.—As for exposure of kidney by oblique lumbar incision.

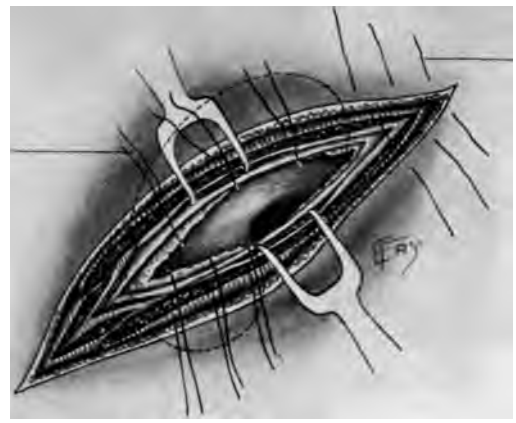

Fig. 505.—NEPHROPEXY BY SIMPLE SUTURING:—A, Sutures passing through lower portion of lips of wound, perirenal fatty areolar tissue, and kidney substance, ready to bind kidney to and into lower plane of wound; B, Sutures passing through skin and upper portion of lips of wound. The structures are the same as those enumerated in Fig. 497.

Operation.—Having exposed the kidney as in the last operation, the displaced organ may be treated in one of several ways; (**a**) By Suturing of the Unopened Fatty Capsule;—Excess of fatty areolar capsule is trimmed away, and the remaining shortened capsule is stitched into the lower plane of the lumbar wound by four to six interrupted chromic gut or kangaroo tendon sutures—the upper layers of the lumbar wound being closed as in the last operation (Fig. 505). (**b**) By Suturing of the Parenchyma, together with the un-

stripped Fatty and Fibrous Capsules;—Having shortened the excess of fatty capsule, if necessary (by excising a portion), three or four kangaroo tendon or chromic gut sutures are passed, with fully curved needle, dipping about 1.3 cm. (½ inch) into the kidney substance, and taking up about 2 cm. (¾ inch) in width of the kidney, into the posterior aspect of the kidney, in a horizontal direction—the sutures passing through the muscles of the wound, transversalis fascia, fatty capsule, fibrous capsule, and the above amount of kidney. These are buried sutures. The upper layers of the wound are separately sutured by interrupted sutures. The fatty capsule is thus sutured between the lips of the wound.

Comment.—(1) The above operation is inferior to splitting the fibrous capsule. (2) Sometimes the fatty and fibrous capsules, without including the kidney, are sutured to the lumbar wound. (3) Sometimes the fibrous capsule is exposed and sutured to the periosteum of the twelfth rib.

TOTAL NEPHRECTOMY

BY OBLIQUE LUMBAR INCISION.

Description.—Excision of one entire kidney. Generally indicated in tumor, extensive suppuration, tuberculosis, fistula. No kidney should be removed until the presence of an opposite, and, if possible, healthy one is ascertained (by vesical catheterization of its ureter—or by actual palpation by hand in the abdominal or lumbar wound). The kidney may be removed by several routes—lumbar nephrectomy—abdominal nephrectomy. The lumbar route is to be preferred—and of the lumbar incisions, the oblique lumbar is the best, being especially capable of extension in either direction to give the necessary room.

Preparation—Position—Landmarks—Incision.—As for exposure of kidney by oblique lumbar incision.

Operation.—(1) The perirenal adipose tissue having been exposed and separated from the kidney by blunt dissection—the kidney being enucleated, as it were, by the finger—the kidney itself is brought well into the wound, partly by abdominal pressure from in front, and partly by traction, while the lips of the wound are drawn well apart (Fig. 506). (2) The pedicle is carefully isolated and freed by blunt dissection—and the kidney is then delivered outside of the wound if possible—especially avoiding traction and twisting of the structures of the pedicle during delivery. (3) The pedicle should be tied with strong silk carried upon a blunt aneurism-needle. Where possible, the artery and vein should be tied separately, and, preferably, prior to their division into branches—the artery being tied first. If not easily differentiated and isolated, the artery and vein may be tied *en masse*—or in several bundles, regardless of whether arteries or veins. If possible, all the structures should be doubly ligated—and the structures forming the pedicle should be relaxed during the placing of ligatures. The ureter should always be tied separately. The pedicle is then severed between the double ligatures, or between kidney and single ligatures. (4) If healthy, the proximal end of the ureter should be cauterized and dropped back into the wound. If unhealthy, it should be attached into the wound and drained. (5) In healthy, clean cases the entire pedicle is dropped back into the abdomen and the wound closed. In suspicious cases, the pedicle is anchored into the wound and drained.

Comment.—(1) Guard the vena cava, which has been wounded in the operation upon the right side. (2) Sometimes the fatty capsule as well as the

kidney must be removed—necessitating the removal of the entire mass from the surrounding tissues. (3) The peritoneal cavity is often opened. If the rent be small, it is closed with ordinary continuous or purse-string suture of gut. If too large to suture, it is packed with gauze. (4) The pleural cavity may be opened in working near the twelfth rib—and should be immediately sutured with continuous or purse-string gut suture. (5) The colon may be wounded.

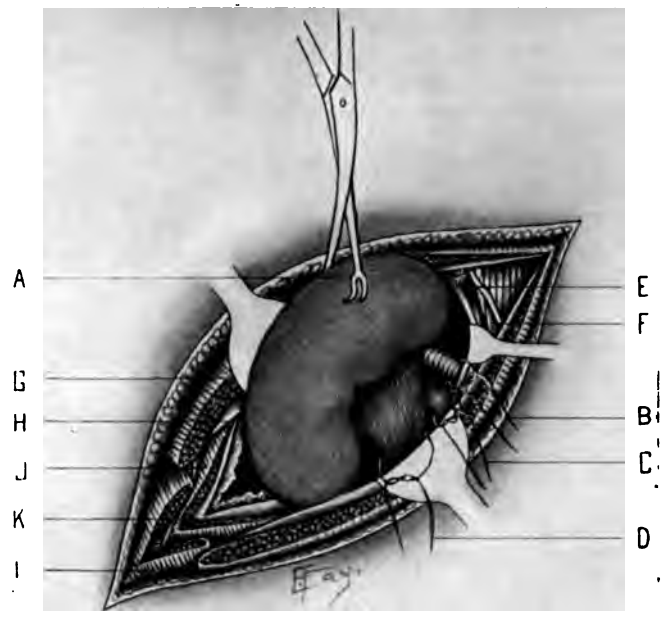

Fig. 506.—Total Nephrectomy by Oblique Lumbar Incision:—A, Kidney brought out of wound in grasp of vulsellum; B, Ligature of renal artery; C, Ligature of renal vein; D, Ligature of ureter; E, Quadratus lumborum muscle and last dorsal nerve and lumbar artery; F, Erector spinæ muscle; G, Serratus posticus inferior; I, External oblique; J, Internal oblique muscle, and intercostal nerve and artery; K, Transversalis aponeurosis.

Treat as wounds of intestine elsewhere. (6) Nephrectomy by morcellement (piecemeal) is sometimes done. (7) If the pedicle have not been doubly ligated, it should be clamped near the kidney before division.

PARTIAL NEPHRECTOMY

BY OBLIQUE LUMBAR INCISION.

Description.—Removal of part of a kidney. May be done in removal of growths—or in badly lacerated wounds. Generally done by the lumbar operation—unless occurring in the course of some other operation.

Operation.—(a) In the deliberate removal of a portion of the kidney, a wedge-shaped piece should be taken out, if possible—so that the sides of the kidney wound, left after the removal of the wedge, could be brought into fairly accurate apposition and sutured by alternate deep and superficial sutures of gut. (b) In extensive lacerations, leaving irregularities of surface, the raw surfaces are to be brought into contact and sutured in the best manner pos-

sible—by deep and superficial gut sutures. The wound of the abdominal wall is treated upon general principles.

SUBCAPSULAR NEPHRECTOMY.

Description.—Where a dense, perirenal capsular mass surrounds the kidney and is firmly adherent to the peritoneum, colon, vena cava, diaphragm, and other structures—so that damage to these structures would likely result in attempting to separate such a capsule, this fatty areolar capsule is incised and the incision carried also through the proper fibrous capsule of the kidney—which is then peeled back to, and, if possible, into the pedicle—which is then ligated or clamped, and the kidney removed. The cavity of the capsule is then curetted (where indicated) and packed—the abdominal-wall wound being closed up to the packing. The best approach in such cases is by the oblique lumbar incision.

TOTAL NEPHRECTOMY

BY ANTERIOR TRANSPERITONEAL OPERATION.

Description.—Removal of an entire kidney through an anterior transperitoneal route—the incision being made in either the median or linea semilunaris region, the latter giving the more direct approach.

Preparation—Position—Landmarks—Incision.—As for exposure of kidney by vertical incision in linea semilunaris.

Operation.—(1) Having opened the abdomen as in the operation above indicated, both kidneys and ureters are examined by the hand introduced into the cavity. (2) Displace the colon toward the median line and incise the outer layer of the mesocolon in a vertical direction. This division of the posterior peritoneum will be upon either the lateral or median aspect of the mesocolon, as determined by its position on the anterior surface of the kidney. The vessels of the colon are less interfered with if the peritoneum be divided upon the outer side of the mesocolon. (3) The fingers are now passed through this incision down upon the kidney—the perirenal fat is incised and the kidney enucleated by blunt dissection. The pedicle is first to be cleared—by stripping off the peritoneum toward the aorta. The vessels are then ligated with silk passed by means of an aneurism-needle—tying, preferably, the artery first, then the veins. If room be sufficient, double ligatures should be used, providing for division between them,—if not, the pedicle may be clamped near the kidney (instead of the second ligature). (4) The pedicle is now divided between the two sets of ligatures—or between the clamp and ligatures. The ureter should be separately doubly ligatured and similarly divided. The ligatured stump, with or without cauterization, as indicated, is returned to the abdomen. (5) The kidney is then further enucleated from its perirenal fatty areolar tissue and removed. All bleeding vessels are gut-ligatured. (6) If drainage be indicated, it is established through the lumbar region by a counter-opening made upon some instrument thrust backward from within and cut upon from without. (7) The incised mesocolon is sutured with gut. (8) The abdominal wound is closed in the general manner.

Comment.—(1) The kidney should be systematically exposed, after incising the fatty capsule—first the anterior surface, then the lateral borders, the poles, and the posterior surface. (2) Where anterior drainage must be established, the edges of the incision in the posterior peritoneum are sutured to

the edges of the incision in the parietal peritoneum, thus shutting off the general cavity. Posterior drainage, however, is always preferable. (3) Suspicious ureters must be brought out into a posterior lumbar wound made as a counter-opening. (4) Avoid injury to the nutrient arteries of the inner layer of the mesocolon. (5) The operation is practically the same whether done through a vertical incision in the linea semilunaris or through a median incision.

XIII. THE URETERS.

SURGICAL ANATOMY.

Description.—Fibro-elastic tubes of about 3 to 4 mm. ($\frac{1}{8}$ to nearly $\frac{3}{16}$ inch) in diameter—flattened from before backward—with walls of about 1 mm. ($\frac{1}{25}$ inch) in thickness. They consist of outer, fibrous—middle, muscular—and inner, mucous coats. They have an average length, in the male, of about 30.5 cm. (12 inches)—extremes being from 25.5 to 40.5 cm. (10 to 16 inches). They are about 7.5 cm. (3 inches) apart at their beginning—about 5 cm. (2 inches) apart near the sacro-iliac joint—about 3.2 cm. ($1\frac{1}{4}$ inches) apart at entrance to bladder—and about 2 to 2.5 cm. ($\frac{3}{4}$ to 1 inch) apart at their bladder-mouths. The ureters begin in the funnel-shaped pelvis of the kidney, opposite the spinous process of the first lumbar vertebra—and run downward through a sort of lymph-space between the laminæ of the subperitoneal connective tissue, downward and inward through the lumbar and pelvic regions—ending in the base of the bladder. The genitocrural nerve is in close relation with the ureter. There are three sites at which the ureter is narrower than elsewhere,—between 4 and 5 cm. ($1\frac{1}{2}$ and 2 inches) from the pelvis of the kidney—crossing of iliac artery—and at junction of pelvic and vesical portions.

Course and Relations.—(1) **Abdominal portion: Male and Female:**—(a) Right Ureter,—Runs downward and slightly inward, from pelvis of kidney to promontory of sacrum, where it crosses either common or external iliac artery. Rests (posteriorly) upon psoas muscle and fascia, genitocrural nerve, common or external iliac artery. Covered (anteriorly) by peritoneum, spermatic and colic vessels, and ileum. Internally lies inferior vena cava, near ureter. (b) Left Ureter,—Runs downward and slightly inward, from pelvis of kidney to promontory of sacrum, where it crosses either common or external iliac artery (same course as right ureter). Rests (posteriorly) upon psoas muscle and fascia, genitocrural nerve, common or external iliac artery (same posterior relations as right). Covered (anteriorly) by peritoneum, spermatic and colic vessels, and sigmoid colon. Internally lies abdominal aorta, being 2.5 cm. (1 inch) from ureter above, and 1.3 cm. ($\frac{1}{2}$ inch) below, near bifurcation. (2) **Pelvic portion: Both sexes: Both sides;**—Runs downward in front of sacro-iliac joint—passes upon obturator internus and its fascia, lying inferiorly and internally to psoas—enters posterior false ligament of bladder (rectovesical fold, in male—uterovesical fold, in female) below the obliterated hypogastric artery—hence its course differs in the two sexes:—(a) **Male: Both sides;**—It is here crossed above and to inner side by vas deferens, which intervenes between it and bladder—and, just before entering bladder, it passes beneath the free extremity of the vesiculæ seminales. The two ureters are about 5 cm. (2 inches) apart at base of bladder, and about 4 cm. ($1\frac{1}{2}$ inches) posterior to the prostate gland. (b) **Female: Both sides;**—It passes down parallel with the cervix uteri and upper part of vagina—lying about 5 mm. ($\frac{1}{5}$ inch) external to cervix opposite os internum—running posteriorly to uterine artery, through

the uterine venous plexus, and below the broad ligament—crossing the vagina opposite its upper third, to the vesicovaginal interspace, and entering the bladder opposite the center of the vagina. (c) **Intravesical portion: Both sexes: Both sides;**—Entering the bladder 4 to 5 cm. (1½ to 2 inches) apart, the ureters pass obliquely downward and inward through its wall, emerging upon the mucous membrane about 2 cm. (¾ inch) apart, and about the same distance posterior to the meatus urinarius internus.

Arteries.—From renal, spermatic, internal iliac, and inferior vesical.

Veins.—End in corresponding trunks.

Lymphatics.—Empty into pelvic and lumbar glands and into receptaculum chyli.

Nerves.—From spermatic, renal, and hypogastric plexuses.

SURFACE FORM AND LANDMARKS.

As the ureters are about 7.5 cm. (3 inches) apart at their commencement at the pelves of the kidneys, opposite the first lumbar spinous process, the beginning of each ureter will lie about 4 cm. (1½ inches) external to the line of the spinous processes, on a level with the spinous process of the first lumbar vertebra. And they lie about 5 cm. (2 inches) apart near the sacro-iliac articulation —or about 2.5 cm. (1 inch) from the median line.

Anteriorly, the line of the ureters, from the kidneys to the brim of the pelvis, may be gotten, approximately, by drawing a line vertically upward from the junction of the inner and middle thirds of Poupart's ligament. And the position of the crossing of the ureters over the brim of the pelvis may be approximately represented by the intersection of a vertical line extending upward from the spine of the pubis, with a horizontal line between the anterior superior iliac spines.

GENERAL SURGICAL CONSIDERATIONS.

(1) The ureter is so intimately adherent to the peritoneum that when the peritoneum is stript up, the ureter is almost always reflected along with that membrane and adherent to it. (2) In all suturing about the ureter, an attempt should be made not to include the mucous membrane—though, practically, this may often be done unintentionally. The fibrous and part of the muscular coats should be taken up by the stitch. (3) Fine silk is the suture material generally used—it being difficult to manipulate gut, or to get it fine enough. (4) There is a tendency to narrowing at the site of suture, especially after transverse division. (5) Extra-pelvic portions of the ureter should be approached retroperitoneally—except where the cause for the operation upon the ureter arises, or is discovered, during an intra-abdominal operation. (6) Intra-pelvic portion of the ureter is accessible by incision through the abdominal wall, bladder, rectum, vagina, perineum, or by sacral resection. (7) Longitudinal wounds of the ureter heal better than transverse ones. (8) Drainage is indicated in all cases where infection is present or suspected, or where the technic is uncertain. (9) In retroperitoneal operations, suture is not absolutely necessary, provided drainage be established down to the wound. (10) Whenever the ureter is opened intraperitoneally, the peritoneum or omentum should be sutured over the wound, so as to make it extraperitoneal. (11) Where the ureter has been divided and must be transplanted, implantation into the bladder is the most desirable. (12) Where the ureter has been

completely divided transversely, it should be repaired by uretero-ureterostomy, if possible. (**13**) Where the division is near the kidney, and uretero-ureterostomy cannot be performed, it should be implanted into the pelvis of the kidney. If the division be low down, it should be implanted into the bladder. (**14**) If such an extent of ureter be lost that uretero-ureterostomy cannot be done—or the end cannot be implanted into the pelvis of the kidney or into the bladder, implantation into the bowel or skin should be done. (**15**) Longitudinal wounds of the ureter generally heal without suture, if retroperitoneal drainage be provided. (**16**) Where it is possible, any operation should be protected by peritoneum—in one of two ways:—(**a**) Lift the ureter up out of its bed, at the site of operation, into the peritoneal cavity—and draw the peritoneum around the ureter from both sides, so stitching the serous membrane as to form a tube through which the ureter runs, practically excluding it from the general peritoneal cavity. The suturing should, however, be lightly and carefully done, forming a loose tube, so as to avoid subsequent contraction. This is probably the better method. (**b**) The site of operation upon the ureter may be surrounded by a detached piece of omentum lightly sutured to the ureter. (**17**) The ureter has been separated for as much as 8.3 cm. (3¼ inches) from its attachments without gangrene—owing to the long artery which accompanies it and is intimately connected with it. (**18**) The ureter may be lengthened 2.5 cm. (1 inch) or more, by steady, gentle traction. (**19**) When a gap in ureter at the lower end cannot be bridged by stretching, a vesical diverticulum can sometimes be turned up to meet the end of the ureter. (**20**) Uretero-ureterostomy is generally practicable except in the lower 2.5 cm. (1 inch) in the male, and the lower 5 cm. (2 inches) in the female. (**21**) In severed ureter, the best course is uretero-ureterostomy by, probably, Van Hook's method—and the next best, uretero-cystostomy (v. i.). (**22**) Normal urine is not injurious to the peritoneal cavity, but it is well not to let it come in contact if it can be helped.

INSTRUMENTS.

See instruments used in operating upon the Kidneys. Also the following special instruments:—Very fine needles, curved, straight, and plain cambric needles; fine silk; fine catgut; fine forceps; fine scissors; small needle-holders; ureteral sound; ureteral catheters; cystoscope; electric illumination; urine evacuator; instruments for segregation of urines.

EXPOSURE OF THE URETER.

Description.—The exposure of the ureter may be made deliberately—or may be done in the course of some other operation. Most of the operations for exposure of the kidney generally also admit of exposure of more or less of the ureter.

Abdominal portion of the ureter is best exposed by the oblique lumbar incision used in exposing the kidney, extending from just below the twelfth rib, at the angle of junction of the lower border of the twelfth rib and the outer border of the erector spinæ muscle—and passing thence obliquely downward toward, and to within 2.5 cm. (1 inch) of, the anterior superior iliac spine—and thence downward and parallel with and 2.5 cm. (1 inch) above Poupart's ligament, to about its center. This incision will enable the upper three-fourths of the ureter to be freely exposed, and will allow of access to the entire ureter, from kidney to bladder—though, of course, not so free access to the lower one-fourth.

It is a possible thing to thus expose the entire ureter extraperitoneally. This exposure should be the one of preference for the upper three-fourths of the ureter (and may be resorted to for even the entire ureter)—except when the ureter is exposed in the course of abdominal section.

Pelvic portion of the ureter is readily accessible through the lower median abdominal incision—followed by retraction of the intestines (especially aided by the Trendelenburg position)—and division of the peritoneum over the course of the ureter. The intrapelvic portion may also be exposed by incision through the bladder, vagina, rectum, male perineum, or by sacral resection.

Intravesical portion of the ureter may be exposed through a cystotomy wound (incision of the bladder)—generally by the suprapubic route.

URETEROTOMY.

Description.—Incision of the ureter. Generally done for the removal of calculi—in which case the operation may be called uretero-lithotomy. Calculi may be lodged at either the upper or lower end of the ureter, or in the middle—usually at one of the two ends. Ureterotomy may be extraperitoneal or transperitoneal (intraperitoneal)—when the ureter is approached, respectively, behind the peritoneum, or through the abdominal cavity. Extraperitoneal ureterotomy is always preferable. Where the site of the ureterotomy is only determined in the course of an operation performed through one of the regular incisions, the ureterotomy will be extraperitoneal or intraperitoneal, according to circumstances. Even when the ureterotomy is done intraperitoneally, however, the site of the ureterotomy, in concluding the operation, should be as thoroughly shut off (walled off) by suturing of peritoneum around the site, as possible. Extraperitoneal ureterotomy is usually done through the oblique lumbar incision, extended as far forward and downward as necessary. Transperitoneal ureterotomy is generally done through a median abdominal incision, or one in the linea semilunaris.

Preparation—Position—Landmarks—Incision.—As for exposure of the kidney by either an oblique lumbar or an anterior abdominal incision.

Operation.—(**a**) In the Extraperitoneal Operation—the ureter—which has generally been found by tracing downward from the pelvis of the kidney—is exposed and divided longitudinally to the necessary extent—over the calculus, if the operation be done for that purpose—the ureter having been steadied and carefully incised with a small, sharp knife, aided by fine forceps—after which the calculus is removed by scoop or forceps. The wound in the ureter, in favorable cases, should be closed with fine silk sutures, passing through the fibrous and muscular coats. Temporary drainage should be employed, in case of leakage—the lumbar wound being closed elsewhere. (**b**) In the Transperitoneal Operation—the ureter is exposed—the peritoneum divided longitudinally over it—the ureter incised in its long axis—and the object of the operation accomplished (usually the removal of a stone). The incised ureter is generally sutured, as in the extraperitoneal operation—and the peritoneum is then sutured about the wound in the ureter so as to render it as extraperitoneal as possible. Prior to suturing the peritoneum over the ureteral wound, a posterior counter-opening is made, and drainage established through this—the abdominal cavity being then closed.

Comment.—Calculi lodged at the lower end of the ureter may sometimes be removed through the bladder, rectum, or vagina, with or without dilating the mouth of the ureter.

URETERORRHAPHY.

Description.—Suturing of the ureter. Generally done for repair of wounds, or following the incision after ureterotomy for calculi. Many of the wounds are accidentally made by the surgeon in the course of other operations.

Varieties of Wounds.—Longitudinal—Oblique, incomplete—Oblique, complete—Transverse, incomplete—Transverse, complete.

Preparation—Position—Landmarks—Incision.—As for Exposure of Ureter.

Operation.—Suturing is generally done with fine silk, or with very fine catgut—carried upon a fine, curved needle, held in a needle-holder. The edges of the wound are brought together by interrupted sutures, generally introduced in the Lembert fashion—passing through the fibrous and part of the muscular coats—but carefully avoiding the penetration of the mucous coat—union taking place by growth of the connective tissue of the apposed surfaces, which is rendered raw in exposing the ureter. The following summary suggests the appropriate methods for dealing with the various sorts of wounds of the ureter:—(1) **Longitudinal wounds;** (a) Close by fine silk (or fine chromic gut) Lembert sutures. Reinforce, if possible, by folding or stitching over the suture-line a fold of peritoneum, or an omental graft. (b) Or excise the piece and do an end-to-end ureteral anastomosis. (2) **Oblique wounds, incomplete;** (a) Same as above (1). (b) Or complete the oblique division and treat as a complete oblique division (v. i.). (3) **Transverse wounds, incomplete;** (a) Lembert sutures. (b) Divide the upper lip of the wound in its center longitudinally upward a short distance. Similarly divide the lower lip of the wound in its center longitudinally downward a short distance. Round off the four corners thus formed with scissors—and suture the borders as in "elbowing" the intestines. (c) Having divided and incised as just described, suture as in the operation of pyloroplasty (see Fig. 789). (d) Or complete the transverse division and do an end-to-end anastomosis. (4) **Oblique wounds, complete;** (a) Oblique end-to-end anastomosis. (5) **Transverse wounds, complete;** (a) Transverse end-to-end anastomosis.

URETERO-URETERAL ANASTOMOSIS (URETERO-URETEROSTOMY).

Description.—Junction, or "splicing," of ends of ureter—by suturing alone—or by suturing aided by supports. Indicated in wounds accompanied by no loss, or very little loss, of substance.

Preparation—Position—Landmarks—Incision.—As for exposure of ureter. Or, as is usually the case, the ureter may be exposed in the course of some other operation.

Operation.—Having exposed the ureter, uretero-ureterostomy may be accomplished in one of several ways:—

(1) **Transverse End-to-end Uretero-ureterostomy by Suturing, without Support** (Schopf, Cushing, and others):—(a) The ends are brought together and the walls are sutured with fine silk in small, fully curved needle, held in holder—the sutures passing through the free edges of the fibrous and muscular coats of the divided ends (Fig. 507). (b) Or Van Hook's method of anastomosing after incomplete transverse division may be used. Make a longitudinal incision extending from the center of each lip of the transverse wound upward and downward, each for a distance equal to the transverse diameter of the ureter. The sharp angles are then rounded off—and the lips

of the wound are then sutured longitudinally, so as to widen the site of suture and avoid subsequent stricture. This is, practically, an ureteroplasty.

(2) **Transverse End-to-end Uretero-ureterostomy by Suturing, with Support** (Tauffer):—The divided ends are brought together over an ureteral catheter or bougie—and are then sutured as in the above method—after which the catheter is withdrawn through an incision made in the ureter opposite the distal end of the catheter—and the longitudinal wound thus made for its withdrawal, is sutured up as a simple longitudinal wound. (Fig. 508.)

(3) **Oblique End-to-end Uretero-ureterostomy by Suturing, without Support** (Bovée):—To lessen tendency to contraction, the ends are divided obliquely—then dilated with special forceps for about 2.5 cm. (1 inch)—then approximated—and sutured with fine silk in fully curved needle, through

Fig. 507.—Ureterorrhaphy without Support:—The obliquely divided ureter is seen sutured with interrupted Lembert sutures passed through the outer coats.

fibrous and muscular coats only—the sutures used being alternating rectangular and interrupted. The peritoneum is then so adjusted as to exclude the sutured ureter from the peritoneal cavity.

(4) **Uretero-ureterostomy by End-into-end Invagination, with Support, without Splitting** (Markoe):—This method was resorted to in division of the ureter near the bladder. Two traction-sutures, each threaded upon two needles, are passed through the proximal ureter near its free end, from within outward and nearly 2 mm. (about $\frac{1}{16}$ inch) apart. The needles are then made to draw the traction-sutures through the wall of the distal ureter, entering in the same relative position and at the same distance apart, passing from within outward. An ureteral catheter is then passed through the distal ureter into the bladder and out of the meatus, being caught by forceps passed

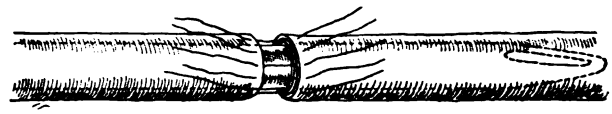

Fig. 508.—Ureterorrhaphy with Support:—Ureteral catheter is seen within the ureter, over which interrupted sutures are passed through the outer coats of the ureter.

through the female meatus (or might be passed from the urethra, by means of a cystoscope, in the case of a male)—the opposite end of the catheter passing into the distal ureter. Over this the proximal ureter is invaginated into the distal, by the traction-sutures—which are then tied. Reinforcing circular suturing is used at the line of junction, passing through all the coats of the distal and through the fibrous and muscular coats of the proximal portions.

(5) **Uretero-ureterostomy by End-into-end Invagination, without Support, without Splitting** (Poggi):—Dilate the distal end with special forceps—place one (or two) pair of traction-sutures through the proximal end—two needles upon single thread, introduced nearly 2 mm. (about $\frac{1}{16}$ inch) apart, in the same horizontal plane, and about 3 mm. ($\frac{1}{8}$ inch) from within the lower end of the proximal portion of the ureter—brought out—and the needles passed from within outward in the distal end, the same distance apart and about 7 mm.

to 1.3 cm. ($\frac{1}{3}$ to $\frac{1}{2}$ inch) from the free end, and opposite the points of penetration above. The proximal end is then invaginated into the distal by traction, and the sutures tied. This invagination is then reinforced by a continuous or interrupted suture applied around the line of union, including all the coats of the distal and the fibrous and muscular coats of the proximal segments.

(6) **Uretero-ureterostomy by End-into-end Invagination, without Support, with Splitting** (Robson, Winslow):—Slit the upper distal end longitudinally—place one or two pairs of traction-sutures as above and invaginate in the same manner—followed by suturing the slit in the distal end over the proximal end. If necessary, reinforce with circular suturing, as above.

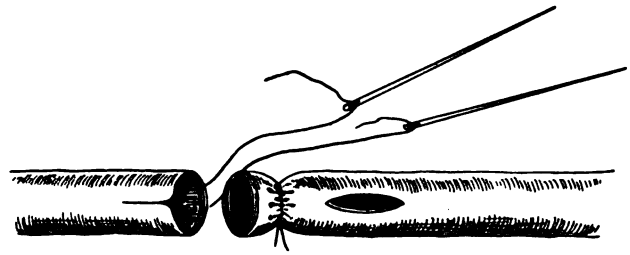

Fig. 509.—URETERO-URETEROSTOMY, BY VAN HOOK'S METHOD:—I, First step. (Modified from Van Hook.)

(7) **Uretero-ureterostomy by Lateral (End-into-side) Implantation** (Van Hook):—Ligate the distal part of the ureter circularly, about 3 to 6 mm. ($\frac{1}{8}$ to $\frac{1}{4}$ inch) from its free end, with silk or gut (Fig. 509). Commencing about 6 mm. ($\frac{1}{4}$ inch) below this ligature, make a longitudinal incision through all the coats of the distal ureter for a distance equal to the diameter of the ureter—with fine, narrow knife, or sharp-pointed scissors. Make a longitudinal incision in the proximal ureter, from the margin of the free end upward for about 6 mm. ($\frac{1}{4}$ inch). A traction suture of fine catgut, upon two needles, is passed just as in the invagination method—about 3 mm. ($\frac{1}{8}$ inch) from the free

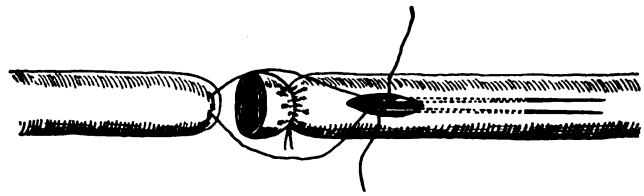

Fig. 510.—URETERO-URETEROSTOMY, BY VAN HOOK'S METHOD:—II, Second step. (Modified from Van Hook.)

end, and from nearly 2 mm. to 3 mm. ($\frac{1}{16}$ to $\frac{1}{8}$ inch) apart, and upon the lateral aspect opposite to the vertical slit (Fig. 510). Pass the points of both needles through the slit into the distal ureter, and thence for about 1.3 cm. ($\frac{1}{2}$ inch) below its lower end—thence penetrate the wall of the distal ureter outward, upon the same aspect of the ureter as the slit, and both needles held at the same horizontal level (side by side—not one over the other). Unthreading the needles, draw (invaginate) the proximal into the distal ureter, until the slit in the proximal is well within the slit in the distal—and then tie the sutures. Complete the union by suturing the edges of the vertical incision around the

proximal, the sutures passing through the fibrous and muscular coats (Fig 511). Further protect the site by peritoneum folded around it, if the operation be intraperitoneal. *Note*—Where the proximal end (from distention or other cause) is too large to go into the distal, it may be narrowed by placing and tying two or more sutures in its free end. Both ends of these "narrowing sutures" are then threaded—and all six needles passed into the slit, in pairs, as in Van Hook's operation, and the threads tied.

Comment.—(1) In the operations of invagination, instead of introducing the traction-sutures through all the coats of the proximal end, it would be better to introduce a single needle on a thread, from without through the fibrous and muscular coats alone—then, keeping the needle on the original end, thread another needle on the other end, and proceed as is ordinarily done. Thus no capillary thread passes into the lumen of the proximal portion—and the ap-

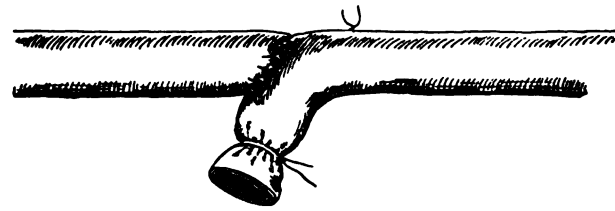

Fig. 511.—URETERO-URETEROSTOMY, BY VAN HOOK'S METHOD:—III, Third step. (Modified from Van Hook.)

proximated outer wall of the proximal portion to the inner wall of the distal portion blocks off the wall of the distal ureter. (2) In some cases the kidney has been lowered somewhat from its original site, in order to furnish additional length for uretero-ureteral anastomosis.

Comparison of Methods of Uretero-ureterostomy.—Van Hook's Lateral Implantation method is probably the best for all-around use. End-to-end anastomosis is more apt to be followed by leakage. End-into-end anastomosis is less apt to be followed by leakage and stricture. In end-into-end anastomosis about 2.5 cm. (1 inch) of ureter is taken up. In end-in-side implantation about 4 cm. (1½ inches) of the ureter is consumed.

IMPLANTATION OF URETER, IN GENERAL.

After division of the ureter, or after excision of a part of the ureter (by accident or other cause), the lower end of the proximal portion of the ureter may be implanted, or "grafted," into the bladder, large intestine (cæcum, sigmoid, or rectum), vagina, opposite ureter, pelvis of opposite kidney, upper portion of the distal end of the same side (which is really uretero-ureterostomy), or into the skin.

When a simple division has taken place, without loss of substance, a simple implantation, or anastomosis of the proximal into the distal end (uretero-ureterostomy), is best.

Where a loss of some extent of ureter has occurred, a uretero-ureterostomy is still the best course, where it is possible to approximate the ends without too great tension. Where the loss is too great for this, an implantation into some other structure is necessary.

The most usual sites (in order of preference) into which the proximal end of the ureter is implanted are—bladder, large intestine (rectum), and skin.

The distal end is ligated and left *in situ*—some surgeons first cauterizing the stump.

As many of the ureteral implantations are done for accidents to the ureter occurring during other operations, the parts are usually already exposed—requiring none or but little more dissection to fully expose them.

IMPLANTATION OF URETER INTO BLADDER—(URETERO-CYSTOSTOMY).

Description.—Implantation of ureter into male or female bladder. In Uretero-cystostomy the implantation itself may be intraperitoneal or extraperitoneal. Where possible, the extraperitoneal implantation is preferable to the intraperitoneal implantation—although when the latter is done, the operation-site should be so walled off by peritoneum as to practically amount to an extraperitoneal implantation. As to the manner of exposing the ureter, this is done generally by an intraperitoneal operation. It is sometimes done through an extraperitoneal route, as, for example, in performing a suprapubic cystotomy, followed by exposure of the ureter by cutting through the base of the bladder. It may also be exposed extraperitoneally through the vagina. In



Figs. 512-514.—URETERO-CYSTOSTOMY:—I, Cut end of ureter is shown grasped in forceps and protruded into bladder through incision in wall of latter. II, Sutures are passed through outer coats of bladder and ureter. III, Ureter is shown sutured into bladder. The peritoneum is incised over ureter in I.

the following description it will be supposed that the ureter is to be severed near its vesical end.

Preparation—Position—Landmarks—Incision.—As for median abdominal section below the umbilicus.

Operation.—(1) Having performed a lower median abdominal section, with the patient in the Trendelenburg position, displace the intestines toward the diaphragm and to the opposite side—isolating the ureter and tracing it to the bladder. (2) Incise the posterior peritoneum over the site of the intended division of the ureter. Having freed the peritoneum and connective tissue from the ureter by blunt dissection, divide the ureter transversely. Ligate the distal end of the ureter and return it to its site (Figs. 512 and 514). (3) Make an incision through all the walls of the bladder, as nearly the normal site as

ous or interrupted catgut, the edges of the opening through the submucous and mucous coats left by the flap, continuing the suturing upward a little beyond the base of the flap, and beneath the ureters, until the furrow caused by approxi-

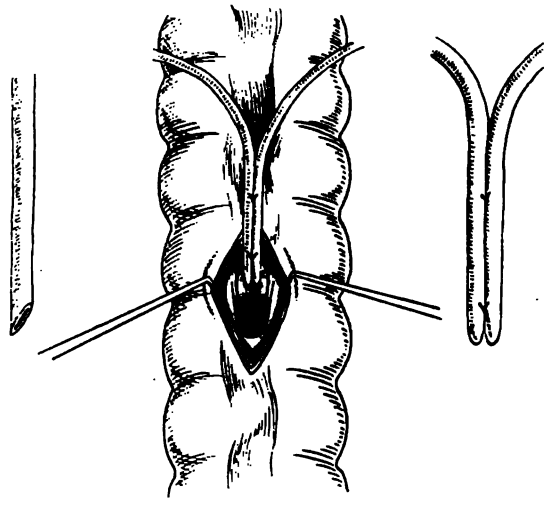

Fig. 516.—URETERO-RECTOSTOMY, BY FOWLER'S METHOD:—II. The U-shaped flap is incised and turned upward. The two beveled ureters are connected by two sutures, and then sutured to the mucous flap. (Modified from Fowler.)

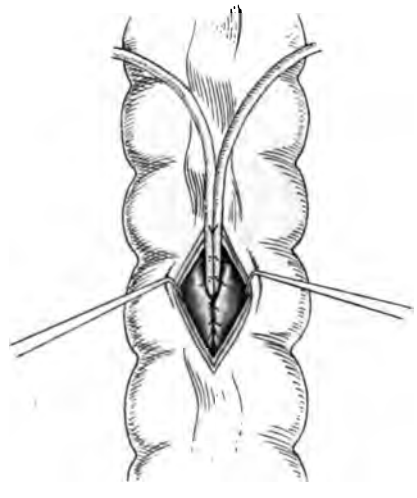

Fig. 517.—URETERO-RECTOSTOMY, BY FOWLER'S METHOD:—III. The mucous flap and attached ureters are then buried within the bowel by suturing the margins of the opening through the mucous membrane. (Modified from Fowler.)

mating the edges has been obliterated (Fig. 517). (9) Suture together the edges of the serous and muscular coats of the rectum with interrupted silk or

ureters. (They may be first divided transversely and then the proximal end beveled obliquely as above.) (5) Incise the anterior wall of the rectum longitudinally in its center, for about 7 cm. (2¾ inches)—the incision being so placed that its center will correspond with a convenient approximation of the cut ends of the ureters. This incision passes through the serous and muscular coats only. Dissect back, on either side, the serous and muscular coats, exposing a diamond-shaped area of submucous tissue—an assistant holding aside the margins with temporary traction-sutures or tenacula (Fig. 515). In the lower half of the exposed area of submucous tissue cut a U-shaped flap about 2.5 cm. (1 inch) long, with free end downward, incising through the mucous membrane into the lumen of the rectum. Turn the free end of this flap upward and outward upon itself, so that the apex will point to the base, and the mucous surface will be uppermost—forming a flap with mucous surface upon one side, and submucous upon the other—and suture the two surfaces of the reflected flap together along their lateral aspect (Fig. 516). (6) Unite the two ureters upon

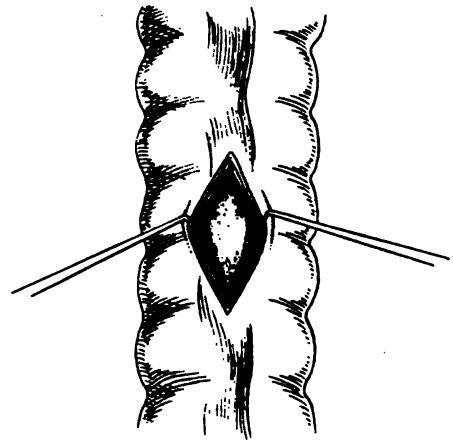

Fig. 515.—URETERO-RECTOSTOMY, BY FOWLER'S METHOD:—I. The serous and muscular coats of the rectum are incised and retracted. A U-shaped flap is outlined upon the mucous membrane. (Modified from Fowler.)

their inner aspects by two or three interrupted fine gut sutures passed through their fibrous and muscular coats, one placed near their free end, the second about 2 to 2.5 cm. (¾ to 1 inch) above, and a third may be similarly placed above the second, if there be room. The ureters will be thus so united as to leave the obliquely beveled ends pointing posteriorly. (7) The two parallel, united ureters are now so placed upon this flap of mucous and submucous tissue that their obliquely beveled surfaces will lie undermost, and in contact with the normal mucous surface of the reflected end of the flap—and with their tips in apposition with the upper part of the reflected flap (so as to leave ample free flap below to serve as a valve). Suture the free ends of both ureters to the mucous flap, by fine gut sutures passing through only the fibrous and serous coats of the ureters, and well into both thicknesses of the mucous flap. The ureters are also sutured above to the submucous tissue of the flap. (8) The suturing having been completed, carefully push the mucous flap and attached ends of the ureters back into the rectum. Then suture together, with continu-

ous or interrupted catgut, the edges of the opening through the submucous and mucous coats left by the flap, continuing the suturing upward a little beyond the base of the flap, and beneath the ureters, until the furrow caused by approxi-

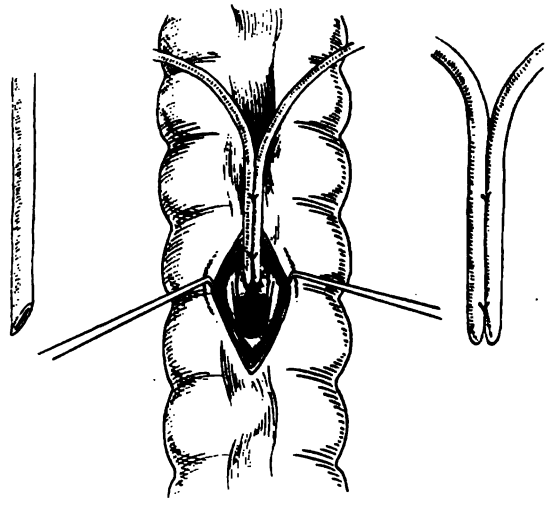

Fig. 516.—URETERO-RECTOSTOMY, BY FOWLER'S METHOD:—II, The U-shaped flap is incised and turned upward. The two beveled ureters are connected by two sutures, and then sutured to the mucous flap. (Modified from Fowler.)

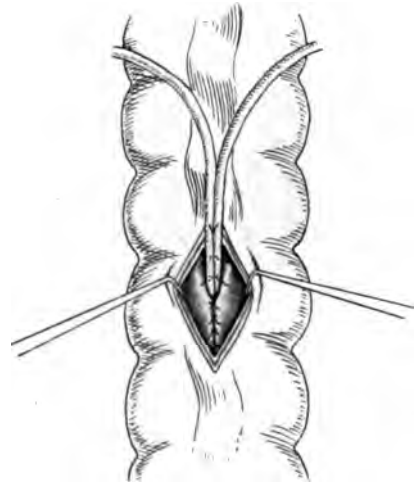

Fig. 517.—URETERO-RECTOSTOMY, BY FOWLER'S METHOD:—III, The mucous flap and attached ureters are then buried within the bowel by suturing the margins of the opening through the mucous membrane. (Modified from Fowler.)

mating the edges has been obliterated (Fig. 517). (9) Suture together the edges of the serous and muscular coats of the rectum with interrupted silk or

chromic gut, thus further burying in the tips of the ureters, and also burying in that portion of the ureters lying obliquely between the submucous and serous coats, insuring an oblique passage between the rectal coats of about 3 cm. (1¼ inches). One or two of the sutures, in this line of suturing, should include the outer coats of the ureters (not entering their lumen). The outer coats of the rectum, in this line of suturing, should be well sutured around the ureters at the site where they pass between these coats. (Fig. 518.) (10) Temporary drainage may be provided, if deemed necessary—otherwise the abdomen is closed as usual.

Comment.—(1) A permanent valve is thus formed, with a mucous surface to the ureter, and a mucous surface to the lumen of the gut, thus closing the ends of the ureters as the bowel distends with combined feces and urine, aiding the control and safety from infection—which the oblique passage of the ureters through the rectal wall further aids. (2) Various other methods of intestinal implantation have been done. Maydl transplanted both ureters, including an elliptical portion of the trigone of the bladder, into the rectum or sigmoid flexure—thus retaining the natural functioning of the ureteral openings.

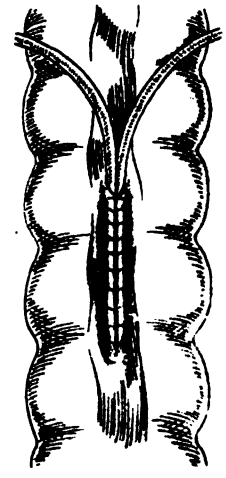

Fig. 518.—URETERO-RECTOSTOMY, BY FOWLER'S METHOD:—IV, The ureters and mucous flap are still further buried by suturing the edges of the incision through the serous and muscular coats. (Modified from Fowler.)

IMPLANTATION OF URETER UPON THE SKIN.

Description.—Implantation of the ureter upon the skin of the loin or abdomen. The implantation upon the former site is preferable—as extension of the ureter through the abdominal cavity furnishes a band for possible intestinal interference. Skin-implantation, however, is the least desirable form of implantation, because of the inconvenience and annoyance of this exit for the urine, and because of the likelihood of infection.

Operation.—(1) If the ureter to be implanted be encountered during an operation by the oblique lumbar incision,—after ligating the distal end of the severed ureter, the proximal end is loosened up by blunt dissection sufficiently to free it for the requisite length—and is then sutured into the skin of the lumbar wound—the remainder of the wound being closed by suture in the ordinary fashion. (2) If the ureter be encountered in the course of a median abdominal section, a counter lumbar opening is made and the ureter implanted as just described.

Comment.—The proximal end of the ureter may also be sutured to the skin at the nearest point possible to the bladder.

URETERECTOMY, IN GENERAL.

Description.—Excision of ureter, in whole or in part. Partial ureterectomy is the removal of a portion of the ureter, followed by either an uretero-ureterostomy between the remaining ends, or an implantation of the ureter into some locality. Complete ureterectomy consists in the removal of the entire

ureter—and implies, of course, the removal also of the corresponding kidney; that is, nephro-ureterectomy.

Ureterectomy may be done extraperitoneally or intraperitoneally. Extraperitoneal ureterectomy is generally done through the oblique lumbar incision. Intraperitoneal (transperitoneal) ureterectomy is usually done through an anterior abdominal section.

Indicated in tuberculosis and suppuration of the ureters. Partial ureterectomy is sometimes done accidentally in operating for other conditions.

PARTIAL URETERECTOMY

BY OBLIQUE LUMBAR INCISION.

Description.—The ureter is exposed extraperitoneally by the above incision, and a portion of its extent removed—followed by an uretero-ureterostomy, where the amount removed is not too great—or by an implantation, where the amount removed and the site of removal indicate it. A partial ureterectomy is sometimes accidentally done, especially in intrapelvic operations for the removal of tumor.

Preparation—Position—Landmarks—Incision.—As for exposure of kidney by oblique lumbar incision.

Operation.—If the ureterectomy be deliberately done—the kidney is exposed—the ureter isolated by tracing downward from pelvis of kidney—and is then dissected up from its bed by blunt dissection and by carefully peeling it away from the peritoneum. A limited portion is now excised with scissors—after ligating below the point of division—and clamping with special clamp above. The proximal and distal ends are then freed up sufficiently to enable the gap formed by the excision to be bridged. The ends are brought together and an uretero-ureterostomy (preferably by Van Hook's method, see page 867) is done—or an ureteral implantation is performed.

TOTAL URETERECTOMY, TOGETHER WITH REMOVAL OF KIDNEY,

BY ANTERIOR MEDIAN ABDOMINAL SECTION.

Description.—Total Nephro-ureterectomy consists in the removal of the kidney and of the entire ureter. Generally resorted to for tubercular or suppurative disease of kidney and ureter. The removal may be made extraperitoneally by the oblique lumbar incision, as just described in partial ureterectomy,—or intraperitoneally, by anterior abdominal section in the median or semilunar line.

Preparation—Position—Landmarks—Incision.—As for median abdominal section.

Operation.—Having opened the abdominal cavity and displaced the intestines toward the median line, divide the posterior peritoneum upon the outer aspect of the colon and reflect it toward the spinal column—thus exposing the kidney and ureter. The kidney is now freed and its pedicle tied off as described under total nephrectomy by the abdominal route. The ureter is similarly freed by blunt dissection. All vessels are ligated. Having severed the pedicle of the kidney, except the ureter, the kidney is separated from its bed—and, by gentle traction upon it and the ureter, the ureter is traced down to the bladder. The vesical end of the ureter is doubly ligated close to the bladder and divided between the ligatures. The free end of the ureteral stump may be

sterilized. The posterior peritoneum is dropped back into place over the site occupied by kidney and ureter—and may be sutured here and there with interrupted gut sutures, though it generally remains readily in place and adheres to the connective tissue from which raised. Temporary drainage may be established, where specially indicated—otherwise the abdomen is closed.

XIV. THE BLADDER.

SURGICAL ANATOMY.

Description.—The bladder is a musculo-membranous sac, mainly situated in the pelvic cavity, between pubes and rectum in male; and between pubes in front, and cervix uteri and upper part of vagina behind, in female,—entirely surrounded by recto-vesical fascia, and covered above by peritoneum. Consists of serous (peritoneal), muscular, submucous (areolar), and mucous coats. In infancy the bladder projects above the os pubis and is more of an abdominal organ than in the adult. When empty—in the adult, the bladder lies deeply in the pelvis, flattened antero-posteriorly. When moderately distended—it is rounded and still within the pelvis. When fully distended—it is ovoid and projects into the abdominal cavity. When greatly distended—it may extend nearly to the umbilicus. The long axis of the bladder, which inclines to the vertical, runs from a point between the os pubis and the umbilicus (dependent upon the amount of distention) downward and backward toward the tip of the coccyx. The vertical axis is greater in the male—the transverse greater in the female.

Relations.—(1) **Summit**:—Connected with abdominal wall by urachus (remains of part of allantois), which passes from apex of bladder, between transverse fascia and peritoneum, to umbilicus; obliterated hypogastric arteries, passing upward from side of bladder, on each side of urachus. (2) **Superior, or abdominal surface**:—Entirely covered by peritoneum, from summit and obliterated hypogastric arteries to base of bladder; sigmoid flexure (in male); part of vasa deferentia (in male); uterus (in female); small intestines (in both sexes). (3) **Antero-inferior, or pubic surface**:—Uncovered by peritoneum, and separated from the following structures by the cavum Retzii, or prevesical space; triangular ligament; symphysis pubis; levatores ani and internal obturator muscles; abdominal wall (when distended), separated by recto-vesical fascia. (4) **Lateral surfaces**:—Upper part covered by peritoneum, above and posterior to obliterated hypogastric arteries,—lower part, below and in front of obliterated hypogastric arteries, is covered by recto-vesical fascia, which separates the lateral surfaces from the levatores ani and surrounds the vesical vessels and nerves; obliterated hypogastric arteries, which cross lateral surfaces obliquely from below upward and forward; vasa deferentia, arching from before backward along subperitoneal aspect of lateral surfaces toward base, crossing obliterated hypogastric arteries, and passing between ureter and wall of bladder; entrance of ureter, at junction of posterior and lateral surfaces, about 5 cm. (2 inches) above the prostate; levatores ani and obturator internus muscles. (5) **Postero-inferior surface, or base**:—May be subdivided into two parts;—(a) Upper, Peritoneal Portion:—Recto-vesical pouch in male, generally from 1.3 to 2.5 cm. (½ to 1 inch) from prostate, up to as much as 5 cm. (2 inches) in marked bladder distention; utero-vesical cul-de-sac in female:—(b) Lower, Non-peritoneal Triangular Portion:—In Male, rests upon anterior surface of second part of rectum, inferior

part of vasa deferentia and vesiculæ seminales;—its boundaries being; **Base,** reflected recto-vesical fold; Sides, diverging vasa deferentia and vesiculæ seminales; Apex, summit of prostate;—In Female, adherent to anterior wall of cervix uteri, and to upper portion of anterior vaginal wall;—Neck of Bladder, beginning of urethra.

Ligaments.—(a) **Five true ligaments:**—(1) Two pubo-prostatic,—recto-vesical fascia and muscular tissue—from back of pubic bone to antero-inferior or pubic surface of bladder, passing over superior surface of prostate gland. (2) Two lateral,—recto-vesical fascia—from lateral aspects of prostate to sides of bladder and walls of pelvis. (3) Superior ligament, or urachus, —fibro-muscular structure between summit of bladder and umbilicus. (b) **Five false ligaments** (peritoneal folds):—(1) Two posterior, or recto-vesical folds of peritoneum (in male),—from side of rectum to side of bladder. (2) Two posterior, or utero-vesical folds of peritoneum (in female),—from sides of uterus to posterior surface and sides of bladder. (The posterior false ligaments form the lateral walls of the recto-vesical and utero-vesical cul-de-sac, and transmit the ureters, obliterated hypogastric arteries, with vessels and nerves.) (3) Superior ligament,—fold of peritoneum reflected over urachus and obliterated hypogastric arteries, from summit of bladder to umbilicus.

Relation of Peritoneal Fold to Anterior Abdominal Wall.—The reflection of peritoneum is carried upward as the bladder is distended. The maximum elevation of the peritoneal fold rarely exceeds 5 cm. (2 inches). Sometimes it fails to reach the upper border of the symphysis pubis.

Space of Retzius, or Prevesical Space.—Space between the reflection of peritoneum above and the symphysis pubis below,—and between the bladder posteriorly and the symphysis pubis anteriorly—and occupied by connective tissue.

Trigonum Vesicæ.—Triangular smooth surface at base of bladder—bounded at each posterior angle by the ureteral opening—and at the antero-inferior angle by the urethral orifice.

Orifices of Ureters.—Situated about 3.8 cm. (1½ inches) from base of prostate gland and beginning of urethra—and are a little less than 5 cm. (2 inches) apart, at either end of the base of the trigone.

Internal Urinary Meatus.—Lies, in the adult male, from 2 to 2.5 cm. (¾ to 1 inch) posterior to the symphysis pubis, and from 5 to 6.3 cm. (2 to 2½ inches) above the perineum. It generally lies opposite some part of the upper half of the symphysis pubis.

Arteries.—Superior, middle, and inferior vesical, and branches from the obturator and sciatic, in the male,—and the same, with additional branches from the uterine and vaginal, in the female,—all from the anterior trunk of the internal iliac.

Veins.—Form plexuses around neck, sides and base, and end in internal iliac vein.

Lymphatics.—Accompany the veins and end in the pelvic glands.

Nerves.—From hypogastric plexus of sympathetic, and from third and fourth sacral nerves.

SURFACE FORM AND LANDMARKS.

In young children, the apex of the empty bladder is about 2.5 cm. (1 inch) above the level of the symphysis pubis.

In the adult, the apex of the empty bladder is about on a level with the superior border of the symphysis pubis.

In marked distention the anterior bladder-wall comes closely into contact with the abdominal parietes—without the intervention of peritoneum between the two.

For the normal extremes of the peritoneal reflection, see Surgical Anatomy, page 876. For the position of the peritoneal reflection under surgical distention, see General Surgical Considerations, below.

The neck of the bladder is on a level with a line extending horizontally backward from just below the center of the symphysis pubis. Also see position of internal urinary meatus, Surgical Anatomy, page 876.

The depth from the perineal skin to the pelvic floor generally averages from 5 to 7.5 cm. (2 to 3 inches) in the posterior and external part of the perineum—and somewhat less than 2.5 cm. (1 inch) in the anterior part.

In the lithotomy position the bladder is about 6.3 or 7.5 cm. ($2\frac{1}{2}$ or 3 inches) from the perineal surface.

GENERAL SURGICAL CONSIDERATIONS.

When both bladder and rectum are empty, the apex of the bladder and the peritoneal reflection are slightly below the superior border of the symphysis pubis. When the apex of the bladder is as much as 5 cm. (2 inches) above the symphysis and resting against the anterior abdominal wall, the peritoneal reflection is about 2 cm. ($\frac{3}{4}$ inch) above the upper border of the symphysis.

Simple distention of the rectum alone tends to elevate the base of the bladder without correspondingly elevating the non-peritoneal prevesical space.

When the rectum is distended by a rubber bag filled with air or water, the prostatic portion of the urethra is elongated, and the bladder is thereby raised out of the pelvic cavity and the peritoneum pushed upward. The maximum elevation of the non-peritoneal prevesical space is obtained by distending the rectum first and then distending the bladder. The rectal bag is first filled with about 10 or 12 ounces of fluid—and then the bladder is filled with about 8 ounces. Thereby an additional space free of peritoneum is secured in the anterior line. The amount of space uncovered by peritoneum which is thus ordinarily secured generally amounts, altogether, to about 7.5 cm. (3 inches). The bladder, however, is often first filled—and up to 15 ounces may be used.

Gray states that after distending the rectum with 420 c.c. water—and then filling the bladder with 500 c.c.—the bladder will be elevated by the rectum sufficiently to make an interval between the lower peritoneal reflection and the upper border of the symphysis equal to 8.5 cm. ($3\frac{3}{16}$ inches).

As the point of reflection of peritoneum, therefore, is not fixed, and as it sometimes comes down to a level with the upper border, or even below, the symphysis pubis, it is never absolutely safe to plunge a trocar directly into the bladder, even immediately above the upper border of the symphysis. It is always better to expose the bladder-wall by a limited median incision before using the trocar.

Though not to be recommended, the bladder may be punctured from the rectum, in the lower, non-peritoneal surface at the base of the bladder.

No vessels of any size cross the median line of the abdomen or of the perineum—the two sites through which cystotomy is generally done.

The artery of the bulb, especially when arising normally, is not generally cut in perineal lithotomy. If the artery of the bulb arises from the accessory pudic it will lie more anteriorly than normal—and well out of the way. If, however, it arises from the pudic sooner than usual, it will cross the perineum more posteriorly and will be almost certainly cut.

Perineal incisions made into the neck of the bladder should not exceed the limits of the prostate.

The prostatic plexus of veins is likely to be wounded in lateral perineal lithotomy.

The ejaculatory duct is apt to be cut in the same operation if the incision be too far posterior.

INSTRUMENTS.

Scalpels; bistouries, straight and curved, sharp and blunt; lithotomy knives; scissors, straight and curved, blunt and sharp; forceps, dissecting and toothed; artery-clamp forceps, long and short; grooved director; special grooved directors and perineal guides; grooved lithotomy staffs, median and lateral; tenacula; probe; retractors, various; blunt dissector; sponge-holders; traction-loops; Clover's crutch; rectal bag; catheters; sounds; whalebone guides; tunneled sounds; lithotomy forceps; lithotomy scoop; lithotrite; evacuator; irrigating syringe; special bladder forceps; cystoscope; special electric illuminator; trocar and cannula; exploratory syringe; needles, straight and curved; needle-holder; ligatures and sutures, silk and gut; drainage-tubing; gauze.

INTRODUCTION OF SOUND OR CATHETER.

Description.—The general method of entering the male bladder by the urethra is the same in all essentials—whether by metallic sounds, catheters, lithotrites, or cystoscopes. Soft instruments are not subject to much guiding, but generally enter the bladder by being simply protruded through the urethral canal without special effort to direct them through the anatomical curves. The passage of instruments in the female is simple.

Passage in the Male.—(1) The glans and the meatal opening are cleansed. (2) The patient lies supine, near the edge of the table—shoulders slightly elevated—thighs slightly flexed and rotated outward by bending the knees (to relax the muscular tension). The surgeon stands on the left, just above the hips, facing the patient's side. (3) The sound, or catheter, warmed, lubricated, and disinfected, is held lightly in the right hand, between thumb and first two fingers—the handle at first parallel with the abdominal wall. Thus held, its point is introduced into the meatus, the lips of which are parted by the surgeon's left index and thumb to receive it—the glans and penis being held vertically in the surgeon's left fingers. As the instrument is pushed onward and downward, the penis is correspondingly drawn upward and over the instrument. (4) As soon as the instrument is felt to have entered about 10 or 13 cm. (4 to 5 inches), and to be rounding toward the subpubic arch, the handle is gradually elevated until the perpendicular is reached—allowing the instrument to gravitate through the canal and beneath the pubic arch. (5) As this occurs, the handle is continued in its sweep forward, directing the point through the triangular ligament—onward through the membranous and prostatic urethra—until the end is felt to glide into the bladder—when the handle will be found pointing directly away from the bladder and slightly downward—having passed through a semicircle in the vertical plane. (6) In withdrawal, the above steps should be exactly reversed.

Comment.—(1) The sound should first hug the floor of the spongy urethra, until the lacuna magna (on the roof, 2.5 cm. [1 inch] from the meatus) is passed—and then gently hug the roof for the balance of the way through the

spongy, membranous, and prostatic urethra. (2) By carrying the handle of the instrument forward and between the thighs too soon, the tip of the instrument is made to hug the roof of the urethra too suddenly and closely, and is apt to lodge against the upper part of the anterior aspect of the triangular ligament, and thus fail to enter the membranous urethra. (3) On the other hand, the instrument sometimes fails to pass the triangular ligament because of lodging against the lower part of the anterior aspect of the triangular ligament, the handle not being depressed enough—and, in such cases, is made to glide on by depressing the handle more—or by lifting the lodged point upward by the left index-finger in the rectum, or even by pressure against the perineum behind the scrotum. (4) The instrument may be at first introduced while held about parallel with the left Poupart ligament—that is, over the left groin—and then swept into the median line as it descends. (5) If the beak of the instrument revolves readily, the sound is in the bladder.

Passage of the Female Sound or Catheter.—(1) The patient lies supine, with hips and knees semiflexed, and thighs separated. (2) Separate the labia with left thumb and index. Holding the instrument between the right thumb and index, the index extending beyond the end of the instrument, pass the tip of the right index just within the vaginal orifice—withdraw the finger partly, hugging the upper wall of the vagina—and, as the finger glides out of the vagina upon the vestibule, the prominent urethral papilla is felt (about 1.3 cm., or ½ inch) above the junction of the vagina and vestibule—upon which is situated the meatus—into which the instrument is then introduced and protruded into the bladder.

PARACENTESIS VESICÆ.

Description.—Puncture of the bladder-wall by cannula and trocar, or by aspiratory syringe. Indicated in retention of urine. The bladder may be punctured immediately above the pubis, just below the symphysis pubis, through the rectum, or through the prostate gland. The suprapubic puncture is practically the only method of puncture now resorted to—and will be here described.

Preparation.—Ascertain that the bladder is well distended. Shave in the region of the median line, just above the symphysis pubis.

Position.—Patient supine,—or sitting upright, supported. Surgeon on patient's right, facing him.

Point of Puncture.—In median line, immediately above the upper border of the symphysis pubis.

Operation.—Having outlined the distended bladder by percussion—a curved cannula and trocar (which are better than the straight) are taken in the operator's right hand, with the convexity upward, and so held, with the index-finger upon the shaft of the instrument, that the depth to which it may enter the bladder is fixed in advance. The bladder is steadied by the surgeon's left thumb and index placed on each side of the median line. The instrument is thrust sharply but gently into the bladder, entering in the median line just above the symphysis pubis, and directed backward and downward—piercing skin, superficial fascia, passing between the inner borders of the recti and pyramidales (or through their muscular substance), prevesical space, anterior bladder-wall, and into the bladder. The trocar is then withdrawn and the cannula left *in situ* until the urine has come away, chiefly of its own accord, and partly aided by gentle pressure. Upon withdrawal of the instrument, the opening is at once closed by sterilized cotton and collodion.

Comment.—(1) Local anesthesia should be first used. (2) Incision of skin may be first made and then trocar introduced. This may be done either to avoid the most difficult part of the puncture mechanically, namely, the penetration of the tough skin with a comparatively dull instrument,—or it may be done, as mentioned under Surgical Considerations, for the purpose of first exposing the bladder before puncturing. (3) If the skin be drawn downward over the symphysis just before puncture, a valve-like opening will be formed. (4) In those rare cases in which the reflection of peritoneum comes very low down, to or behind the symphysis pubis, it will almost certainly be wounded—not being possible to avoid it, except, were it known in advance, by exposing the area by dissection and pushing the peritoneum upward before the puncture. Puncture of the peritoneum, however, is exceedingly rare provided the bladder be well distended, and a curved instrument be used.

CYSTOTOMY IN GENERAL.

By Cystotomy is meant the incision of the bladder. The less correctly used term "lithotomy" (or "stone-cutting," literally) is equivalent to "Cystotomy for removal of calculus."

Cystotomy is indicated in calculus, foreign body in the bladder, exploration, drainage, access to prostate, tumors, diseased conditions of the mucous membrane, catheterization of the ureters intravesically, etc.

Cystotomy may be suprapubic, median perineal, lateral perineal, bilateral perineal, medio-lateral perineal, medio-bilateral perineal, vaginal, and by external urethrotomy. The first three of these are, practically, all which are now done—and of these three, the suprapubic is the one which is most frequently performed.

For the removal of large stones, the suprapubic route should always be chosen—while it is preferable for the removal of any calculus. For the purposes of drainage alone, not weighing other considerations, the perineal route is the best.

SUPRAPUBIC CYSTOTOMY.

Description.—Incision of the bladder above the symphysis pubis, through the prevesical space. Indicated for calculi—especially large ones—or encysted small ones; exploration; drainage; tumors; foreign bodies; access to prostate gland. Much more frequently performed than median or lateral perineal cystotomy.

Preparation.—Pubes shaved; rectum emptied; rectal bag in rectum, well above the sphincters, in hollow of sacrum, and filled with 10 to 12 ounces of water (or with air); bladder irrigated and filled with 8 to 10 ounces of water (after the rectum has been distended); penis carefully ligated with rubber band to keep water in bladder.

Position.—Patient supine. Surgeon on patient's right. Assistant opposite.

Landmarks.—Median line; upper border of symphysis pubis.

Incision.—About 7.5 cm. (3 inches) in length—placed in the median line—beginning about 6.5 cm. (2½ inches) above the symphysis pubis and extending to a point about 1.3 cm. (½ inch) above the symphysis. The extreme upper and lower ends of this incision are not carried to the lowest depths of the wound—but are only superficial and are to allow for retraction of the parts.

Operation.—(1) Divide the skin and superficial fascia, clamping, if necessary, any bleeding vessels. Sometimes abundant fatty areolar tissue must be traversed. The interval between the inner borders of the recti and pyramidales is sought, but is frequently not demonstrated—and, if not, the muscle tissue is divided in the line of its fibers, without further needless search—the edges of the wound being well retracted as they are deepened (Fig. 519). (2) The transversalis fascia is encountered and similarly divided in the median line—and the prevesical space reached. The areolar tissue overlying the prevesical space is cautiously divided in the median line—extreme care being here used, for the purpose of recognizing the lower reflection of peritoneum, especially if it be prolonged unusually far down. The peritoneal fold must be sought from below (near the symphysis) upward, the dissection beginning immediately

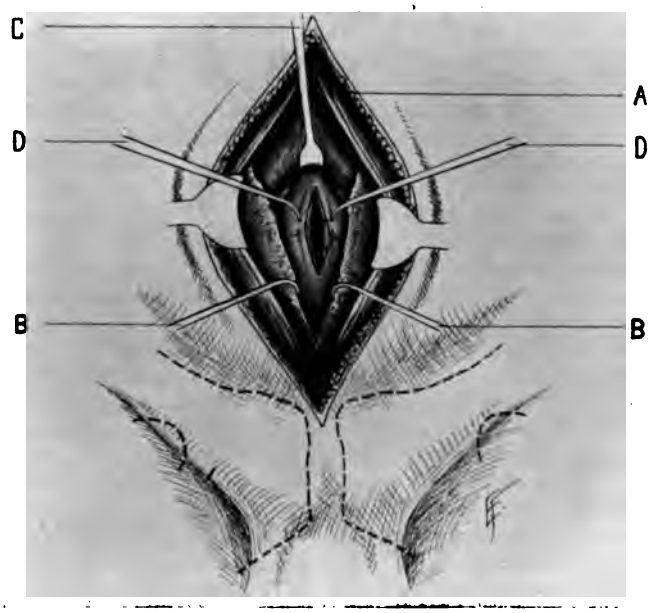

Fig. 519.—SUPRAPUBIC CYSTOTOMY:—A, Margins of recti and pyramidales muscles; B, B, Prevesical areolar tissue freed and retracted from bladder; C, Peritoneum retracted upward (unopened); D, D, Tenacula passed through serous and muscular coats of bladder and subsequently used to retract lips of bladder-wound.

above the upper border of the symphysis. As soon as encountered, the peritoneal fold is carefully pushed upward, with the left index, off the front of the bladder, so as to be out of the way of injury. All the prevesical fatty areolar tissue should be divided accurately in the middle line, until the bladder-wall is well exposed—which is generally recognized by its pink muscular appearance, convex contour, fluctuation, and elasticity. The lips of the wound should be well retracted—and any bleeding from the prevesical veins controlled. (3) The bladder is steadied by two tenacula passed transversely across the median line through the outer coats, at the extreme upper and lower limits of its exposed surface, and held in the two hands of the assistant. When all is in readiness, the operator, with sharp, narrow knife, by a quick, controlled thrust, stabs through the bladder-wall just below the upper tenaculum (in-

suring, by this method, the penetration of all coats of the bladder—and not the protrusion of the muscular coat ahead of the knife-point, as sometimes happens in a slowly made incision) and cuts downward in the middle line toward the lower tenaculum, increasing the extent of the incision as he draws the knife out. The contained fluid immediately escapes—but, owing to the holding up of the bladder, but a small amount enters the prevesical wound. Two silk retraction-sutures are now placed through the center of each lip of the bladder-wound—and the tenacula withdrawn. Some surgeons, instead of using the tenacula as above, originally place these traction-sutures, with a curved needle, passing through the outer coats of the bladder, parallel with the future incision, and about 1.3 cm. (½ inch) apart. Hemorrhage from the edges of the bladder-wound may occur at first, but generally is easily controlled. The ligature about the penis is now relaxed and the bladder emptied. (4) The assistant who held the tenacula now holds the bladder-lips apart by traction-sutures. The opening into the bladder is enlarged to the desired extent in the median line, upward and downward—carefully guarding the peritoneum above, which especially tends to prolapse when the bladder is empty. A finger is introduced and the cavity of the bladder examined—and the special object of the operation accomplished. If it be a calculus to be removed, special forceps, guided by the introduced finger, grasps the stone and withdraws it. The rectal bag may be emptied and withdrawn as soon as the bladder is entered—or, if not distended before, may be then distended to bring the fundus of the bladder more into the wound. (5) Where indicated—in healthy condition of the parts and where no great traumatism has been done—the bladder-wound may be closed at once. In suturing, retract the upper and lower angles of the bladder-wound by wound-hooks, thus approximating and paralleling the margins of the vesical wound. Withdraw the silk traction-sutures as soon as the wound-hooks are in place. The margins of the bladder are then neatly and closely brought together with fine chromic gut, upon a curved needle—placed interruptedly and passing through all the coats except the mucous membrane. It is probably well to reinforce this line of suturing with a second tier of interrupted Lemberts of silk or fine gut—the roughened connective-tissue coat of the bladder, being approximated in the Lembert fashion, uniting. Some surgeons use a first layer of sutures through the mucous membrane—and a second layer through the outer coats. Still others use a row of Lemberts through the outer coats only. (6) The superficial wound is now closed—except to a small extent immediately over the center of the bladder-wound—where temporary drainage is established for thirty-six or forty-eight hours, in case of leakage. Two tiers of sutures are used in the superficial wound—a buried chromic gut interrupted or continuous tier, uniting the divided muscle tissue,—and a superficial silkworm-gut, or silk, placed interruptedly through the skin and fascia. The sutures opposite the site of drainage may have been placed—and simply tightened upon the withdrawal of the drain.

Comment.—(1) The incision, superficial and deep, especially where done for exploration, may be less extensive than the above. (2) If in doubt about the position of the bladder, use an exploratory syringe. (3) Avoid detaching the anterior bladder-wall from the posterior surface of the symphysis. (4) If the peritoneum be accidentally wounded, immediately close it with fine gut sutures of the Lembert type. (5) Special forms of hooked gorgets have been made to hold up the bladder while exploring or operating upon its cavity. (6) Use round needles in suturing the bladder. (7) In some cases, for drainage, or other reason, the suprapubic wound is left open—and then the edges of the bladder are sutured with chromic gut to the deeper edges of the superficial

wound. (8) Some surgeons leave a catheter in the bladder for two or three days—to avoid overdistention and pressure upon the sutures. (9) In children, the bladder is naturally higher in the abdomen.

LATERAL PERINEAL CYSTOTOMY

FOR REMOVAL OF VESICAL CALCULUS.

Description.—Incision of bladder through left lateral region of perineum—generally performed for the removal of calculi. The operation is sometimes less correctly called Lateral Lithotomy. It is always performed upon the left side because the manipulations upon that side are more convenient to the surgeon. The operation, as here carried out, is applicable to any purpose for which it is indicated to approach and open the bladder by this route—but it is generally done for stone, although less frequently now than formerly. Calculi of moderate, but not the largest, size may be removed by this route. The special instruments required are:—a left dorso-laterally grooved lithotomy staff; probe-pointed knife (if preferred to straight-pointed); stout bistoury with cutting edge of about 5 cm. (2 inches); Clover's crutch, or some provision for maintaining the lithotomy position; wristlets and anklets (may be used).

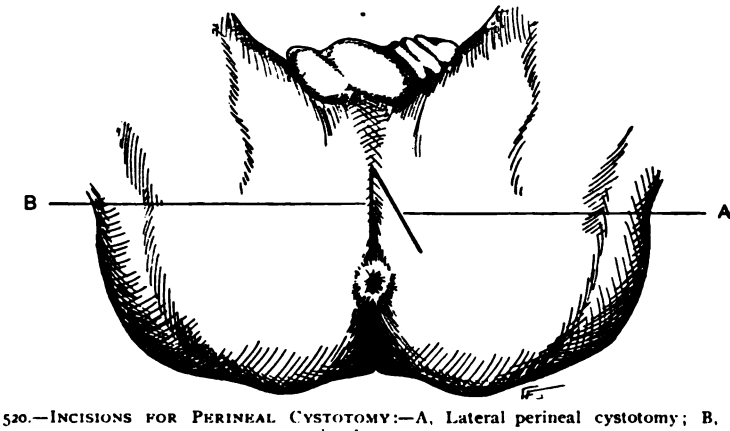

Fig. 520.—INCISIONS FOR PERINEAL CYSTOTOMY:—A, Lateral perineal cystotomy; B, Median perineal cystotomy.

Preparation.—Rectum empty and irrigated. Perineum shaved. Recognition of calculus by sound.

Position.—Patient rests upon back, and, in this position, is brought down to end of table, so that buttocks come well over the edge of the table. While steadied in this position, the special staff is passed into the bladder and given into the charge of an assistant, who, henceforth, holds it steadily and unvaryingly in the middle line. Clover's crutch (and anklets and wristlets, if desired) are then adjusted, and the thighs flexed back upon the abdomen—or an assistant on each side may hold a limb in the above position, without the use of the crutch—and the patient remains in the characteristic lithotomy position throughout the operation. The surgeon sits at the end of the table, facing the patient's perineum. The assistant, standing on the left, who holds the staff in his right hand, holds up the penis and scrotum with his left. Up to the entrance of the knife into the groove of the staff, the staff is held so that its handle

is nearly parallel with the abdominal wall, so that its convexity causes the membranous urethra to round out more prominently and nearer to the perineum, making it more accessible to the operator. When once the knife has entered the groove and the deeper part of the incision is being made, the staff is held with its handle perpendicular and its concavity up against the pubic arch and its point well in the bladder. When all is ready for the incision, and the staff is in position, the surgeon should examine, by rectum, for staff, prostate and ischial tuberosities—and then change gloves.

Landmarks.—Central tendinous point of perineum; median raphé; anus; ischial tuberosities.

Incision.—From a point about 8 mm. (⅓ inch) to left of median raphé and just posterior to the central tendinous point of the perineum (which is 3.2 to 3.8 cm., or 1¼ to 1½ inches, anterior to the adult anus)—to a point between the ischial tuberosity and the posterior portion of the anus, and one-third nearer the

Fig. 521.—Surface View of Perineum and Ischio-rectal Regions:—Superficial structures are seen on right, and deep on left. A, Incision for lateral perineal cystotomy; B, Incision for median perineal cystotomy; C, Bulb; D, Membranous urethra; E, Prostate gland; F, Vas deferens, vesicula seminalis, and base of bladder; G, Internal pudic artery; H, Superficial perineal vessels and nerves; I, Hemorrhoidal vessels and nerves; J, Anus. (Modified from Gray.)

tuberosity than the anus (according to others, midway between the tuberosity and the anus)—making a total incision of from 5 to 7.5 cm. (2 to 3 inches). (See Fig. 520, A, and Fig. 521, A.)

Operation.—(1) With the staff in the first of the positions indicated above, the superficial incision is made in the form of a thrust—the operator steadying the perineal tissues with his left fingers—and directing the point of his knife at a right angle to the perineum, with its back uppermost, enters its point at the upper limit of the above incision—and aims directly for the groove upon the lateral aspect of the staff, but does not attempt to actually reach it, though he may do so and enter it at once. The incision is made as the knife is withdrawn, following the above line of incision—is about 7.5 cm. (3 inches) in length, and grows less deep as it passes backward and outward. The structures cut in the superficial incision are, in order—integument; superficial and deep layers of

superficial fascia; transversus perinæi muscle; transverse perineal artery, veins, and nerves; lower margin of superficial layer of triangular ligament; hemorrhoidal vessels and nerves. (2) With the staff now in the second one of the positions indicated above, the left index is introduced into the upper angle of the wound and feels for the staff—and, with this finger held in position as a guide, with the nail turned so that it enters the groove, or is directly over it, the knife is passed, with the back of the blade uppermost, along the back of the forefinger and nail straight into the groove—either the knife with which the superficial incision was made, or a special probe-pointed lithotomy knife. The point of the knife having been well engaged in the groove of the staff, the second or deep incision is now made—by pushing the knife downward and backward, depressing the handle as the knife goes forward to prevent its leaving the groove, the point kept constantly in the groove, and the

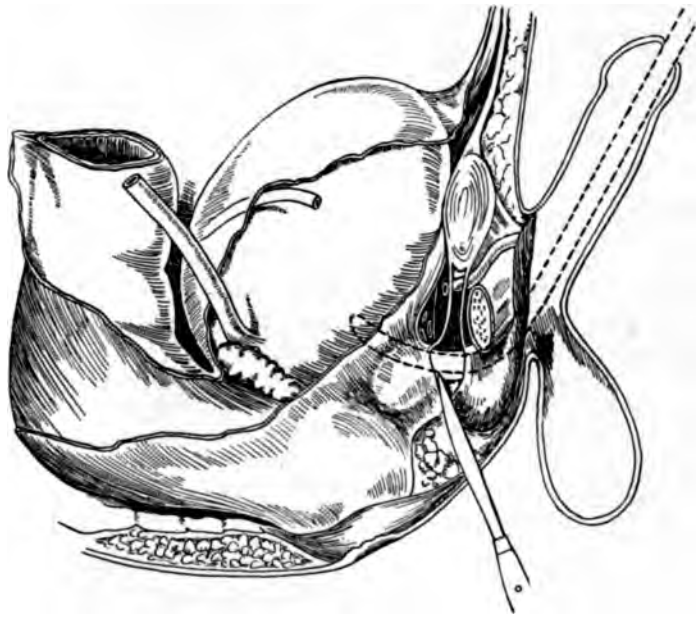

Fig. 522.—Sectional View of Perineal and Pelvic Regions:—The knife is seen passing through the perineal structures, and incising the membranous urethra between the bulb, in front, and the prostate gland, behind. (Modified from Gray.)

sides of the knife parallel with the edges of the now deep wound, and inclined to the left—until the lower end of the knife passes through the prostate gland and neck of the bladder—as evidenced by a gush of urine. The deep opening into the bladder is then enlarged to the extent considered necessary by bearing gently upon the cutting end as the knife is withdrawn—and ceasing to use pressure, and, therefore, cutting force, as the knife reaches the more superficial planes of the wound. The structures cut in the deep incision, are, in order—membranous and prostatic parts of the urethra; superior or deep layer of triangular ligament; compressor urethræ muscle; anterior portion of levator ani muscle; left lateral lobe of prostate gland. The incision through the urethra and prostate will be from near the median line obliquely backward and outward (Fig. 522). (3) In the case of a stone, the lithotomy forceps are intro-

duced closed, along the finger in the bladder as a guide, preceded or not by the dilatation of the bladder, as indicated—and the stone is grasped and removed, aided or not by the fingers in the bladder. (4) The interior of the bladder may be then irrigated—if débris or other cause call for it. (5) A perineal lithotomy drainage-tube is inserted—and the wound left open, or closed only at its extreme ends by suture.

Comment.—(1) Where the calculus is lodged behind an enlarged prostate gland, or held by the bladder-walls in some unusual position, or embedded, special manipulations of the lithotomy forceps is necessary. (2) Large stones may be broken by the lithoclast and removed in pieces. (3) Contraindications to lateral perineal cystotomy for the removal of stone, are—a large stone; enlarged prostate, and deep perineum—under which circumstances a suprapubic cystotomy would be done. (4) Hemorrhage during the steps of the operation is controlled by ligature, clamping, pressure, and hot douching. (5) Avoid cutting the bulb and its artery in front—the rectum behind—and the pudic artery laterally. (6) Incision too far posteriorly will cut the ejaculatory ducts. (7) Draw the penis well up over the staff as the deep cut is made—so as to pull the bulb up. (8) Incision through the neck of the bladder should not exceed about 2 cm. (¾ inch). (9) Stick to the groove in the staff, after once reaching it. (10) Some difficulties, peculiar to the smallness of the parts, are encountered in lateral lithotomy upon children.

MEDIAN PERINEAL CYSTOTOMY

FOR REMOVAL OF VESICAL CALCULUS.

Description.—Incision of bladder through median perineal region—generally performed for the removal of calculi. The operation is sometimes less correctly called Median Lithotomy. The bladder is reached by incising through the apex of the prostate gland and the membranous portion of the urethra. A less free and extensive opening is thus given than by either the suprapubic or lateral perineal cystotomy. Resorted to, especially formerly, for small calculi—which are generally now treated by litholapaxy. The special instruments required are:—a medially grooved lithotomy-staff, and a long, narrow, straight knife with a double cutting-point. The advantages of the median over the lateral cystotomy are the following:—smaller wound; less hemorrhage; quicker healing. There is better drainage than in the suprapubic operation. The disadvantages are:—that only small calculi can be removed—and that the bulb of the corpus spongiosum and rectum are more apt to be injured.

Preparation.—As for lateral perineal cystotomy.

Position.—As for lateral perineal cystotomy. The medially grooved staff is held as in the second position assumed in lateral perineal cystotomy (see page 883).

Landmarks.—Central tendinous point of perineum; median raphé; anus. (See Fig. 520, B, and Fig. 521, B.)

Incision.—Begins at a point about 1.3 cm. (½ inch) anterior to the anus, in the median raphé—and extends upward for 2.5 cm. (1 inch).

Operation.—(1) The operator puts his left gloved index-finger into the rectum and presses it against the staff, which has already been inserted and held as just mentioned—pressing against the staff at the apex of the prostate gland—thereby steadying and recognizing the deep relations, guarding the rectum, and following the penetration of the knife. (2) The long, narrow,

double-edged knife, with the main cutting-edge upward, held at a right angle to the perineum, is first thrust directly inward and made to at once strike and enter the grooved staff at the apex of the prostate, passing through the apex of the gland itself where the finger steadies it within the rectum. The knife is then made to cut upward in the groove of the staff—and, in the act of withdrawal, makes a wound in the soft parts of about 2.5 cm. (1 inch)—depressing the handle of the knife in cutting the urethra and elevating it in cutting the superficial parts,—incising the following structures:—integument; both layers of superficial fascia; anterior portion of external sphincter ani; central tendinous point of perineum; lower margin of triangular ligament; membranous urethra; compressor urethræ; apex of prostate gland. (3) As the knife is withdrawn, the index-finger is introduced into the bladder directly upon the original staff—or such an instrument as a Little's director is introduced upon the staff through the perineal wound and the original staff then removed—and the finger introduced upon the second director through the neck of the bladder, which is often entered with difficulty. The bladder cavity is thus examined through the original wound—or the opening through the neck of the bladder may be first dilated, if necessary. (4) The special object of the operation is then accomplished in the same manner as described under the lateral perineal cystotomy. (5) In completing the operation, a perineal lithotomy drainage-tube is not usually used—the wound being simply left open—protected by a thick perineal dressing.

CYSTORRHAPHY.

Description.—Suturing of bladder. Indications:—following cystotomy operations (the suprapubic only); wounds, occurring during operation or at other times; rupture of the organ; etc. The peritoneal or non-peritoneal aspects of the bladder may be involved—or both.

Operation.—The wound may be connected with any of the conditions mentioned above. The exposure of the wound, therefore, will be determined by the nature of the incision or injury. It will involve either the peritoneal or the non-peritoneal region of the bladder—or may involve both. The same form of suturing is used, whether peritoneal or non-peritoneal surface be the site of operation. Several methods of approximating the edges are in use:—(**a**) The margins of the bladder-wound are brought together and carefully adjusted by means of a single tier of fine chromic gut, interrupted or continuous, carried upon a curved needle, and passing through all the coats except the mucous. (**b**) The mucous membrane may be first united by interrupted or continuous gut suture—followed by the approximation of the outer coats by the stitch just described under "a," either fine gut or silk being used. (**c**) By interrupted chromic gut Lembert sutures passing through the outer coats only, extending slightly

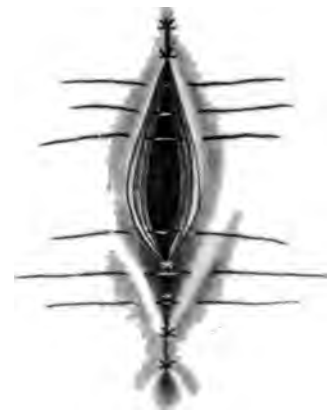

Fig. 523.—CYSTORRHAPHY:—First tier of sutures passes through outer coats and involves edges of bladder-wound (shown in upper sutures). Second tier consists of Lemberts through outer coats (shown in lower sutures—which are here also seen burying in the first tier).

beyond the wound at both ends. In the case of the peritoneal surface of the bladder, the serosæ adhere and unite. In the case of the non-peritoneal surface of the bladder, the raw connective tissue covering the surface unites. (d) By a combination of method "a" as a first tier—followed by method "c," as a second tier. (Fig. 523.)

Comment.—(1) Method "a" is probably the best—or method "b." (2) Gut should always be used in sutures passing through the mucous membrane. (3) In no form of suturing should the mucous membrane be included in a suture which, at the same time, will pass through the other coats. (4) If the circumstances of the wound and the technic of closure be such as to make the operator feel confident of result, the external wound may be closed as usual. In all cases of doubt—and the safest in all cases—the external wound may be closed in greater part—and temporary drainage be carried down to the bladder wound. (5) The bladder may be drained by the catheter for two or three days—to avoid distention of the organ and strain upon the sutures.

LITHOTRITY.

Description.—Crushing of vesical calculi at one or several intermittent sittings (from seven or eight, to three or four days apart) without general anesthesia—the debris of the stone being left to be evacuated by nature's efforts. The instrument used is an ordinary lithotrite—and the manner of using it is the same as in Litholapaxy, except no evacuator follows its use. The patient rests in bed, or may even remain up, while the disturbance of each sitting is passing by. The operation is now almost obsolete.

LITHOLAPAXY.

Description.—Crushing of vesical calculi and recrushing of the resulting fragments, followed by removal of the debris by irrigation, at one sitting, under general anesthesia. The crushing and removing are accomplished by special instruments—the lithotrite and evacuator.

Preparation.—Presence of stone verified by sound; bowels emptied; bladder and urethra in an aseptic condition and bladder moderately distended with a sterile fluid (about 4 or 5 ounces).

Position.—Patient supine, with buttocks well raised by support, to cause the gravitation of the stone to the fundus of the bladder—resting near the right edge of the table, with thighs separated. Surgeon stands upon the patient's right. Assistant opposite.

Operation.—(1) The lithotrite, with closed blades, is introduced into the bladder just as a sound would be—with the modification required by the straighter instrument more abruptly curved near its end—that is, when the bulbous portion of the urethra is reached, the handle of the lithotrite, instead of being at once depressed (which would cause the point of the instrument to hook against the roof of the bulbous urethra in front of the triangular ligament), is held upright, so as to allow its more sharply curved point to gravitate beneath the triangular ligament and glide into the membranous urethra and reach the prostate—and then only is the handle depressed, and slightly twisted from side to side, causing the tip to ride up through the prostatic urethra into the bladder—and glide along the trigone to the posterior wall of the organ. (2) Slow, methodical movement in the opening and closing of the blades, with a

pause between each movement—together with a systematic search of the bladder cavity, should be the method adopted. Hurried movements cause bladder-currents, which generally keep the stone moving and make the grasping of the calculus difficult. Irregular, random movements in directing the grasping blades of the instrument are unsurgical and generally futile. The instrument may encounter the stone immediately—and, if so, its position may be indicated and the blades opened for its seizure. If not, as the instrument rests quietly in the middle line of the base of the bladder, and steadily held in the one position, its blades are separated (by withdrawal of the male blade)—then followed by a few seconds' cessation of all movements (to allow stone to gravitate into the grasp of the instrument)—succeeded by a gentle screwing back of the male blade (the instrument being kept steadily, immovably in one position)—when

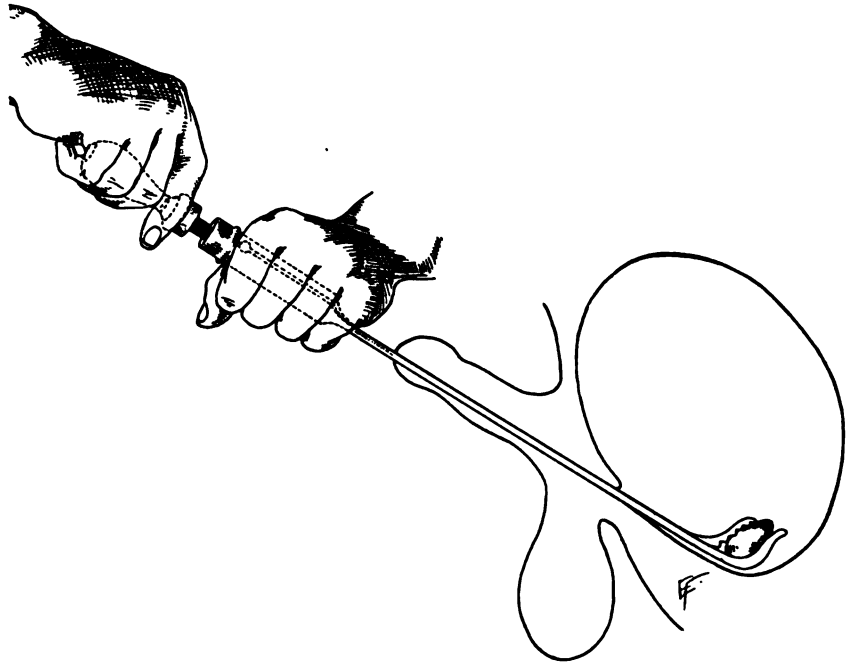

Fig. 524.—LITHOLAPAXY IN THE MALE:—The lithotrite in position.

the stone will often be felt in the grasp of the separated blades. "Open—pause—close" is the formula of movement. If unsuccessful, open again—turn blades to right side, through an angle of 45 degrees ("right oblique"), still keeping the instrument in the median line—close. Or turn it, from a vertical plane, through an angle of 45 degrees to the left ("left oblique")—open—close. Thus the instrument may pass from the vertical to a right or left oblique, or a right or left horizontal. It is better to open the blades before turning—as the stone may be pushed away by an opening blade. Depress the handle, keeping in the middle line or turning laterally—thus examining the anterior wall and sides of the bladder. Reverse the direction of the blades, so that they point downward, especially where the prostate is enlarged—and examine the floor of the bladder and behind the prostate gland—assuming the positions of reversed vertical, reversed right and left horizontal, and reversed right and left oblique.

Thus the entire cavity of the bladder is systematically searched. (3) Having grasped a calculus, the male blade is steadily and slowly screwed down into the female blade—until the stone is felt to break into two or more pieces. After pausing a moment, the blades are opened, kept quietly apart a few seconds, then closed—when probably several of the fragments will be caught and further crushed. This is repeated until the débris are considered to be fine enough to come through the tube of the evacuator. The blades of the lithotrite are then closely approximated while in the bladder and the instrument is withdrawn. (Fig. 524.) (4) The tube of the evacuator is then introduced into the bladder

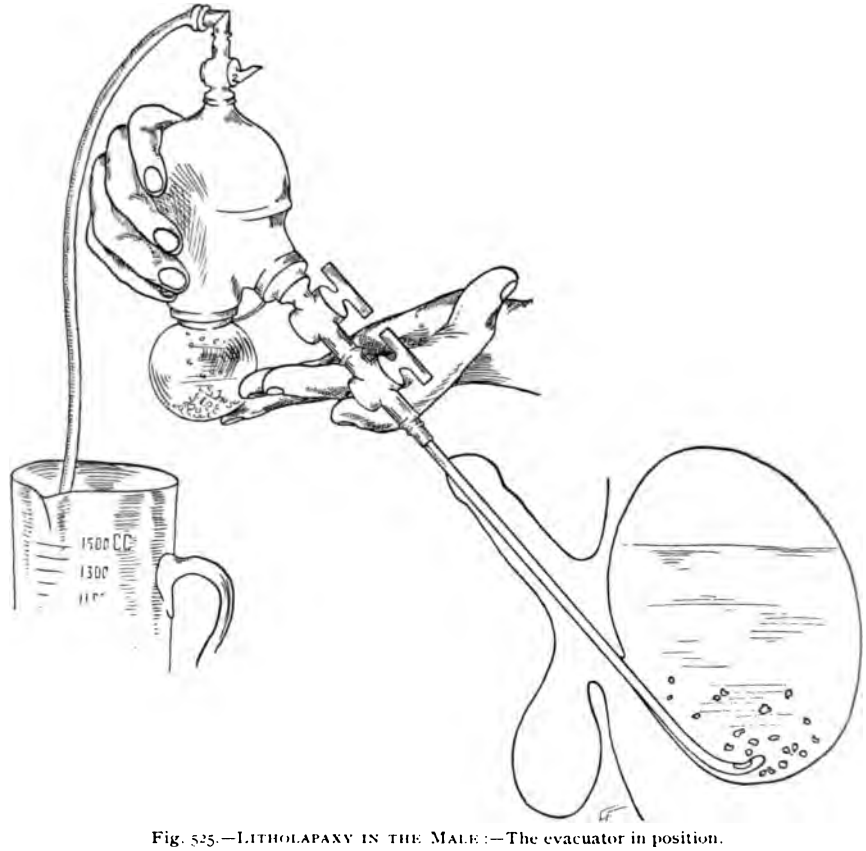

Fig. 525.—LITHOLAPAXY IN THE MALE:—The evacuator in position.

and the urine or other fluid of the bladder is in part withdrawn. The opening of the evacuator lies in the lowest part of the fundus of the bladder—so as to catch the gravitating stones. The bulb of the evacuator is then filled with warm boric acid solution and attached to the evacuator-tube. While the left hand steadies the rigid tube in the bladder, the right hand compresses the bulb and throws a part of its contents into the bladder (about 2 or 3 ounces). On relaxing the bulb, as much fluid as was thrown in is drawn out again (so that the original amount always remains in), and, with it, more or less of the débris of stone are brought out in the outflowing current. Wait a few moments and

then repeat the evacuating process—until all débris seem to have come away. If too large a fragment remains for evacuation, as determined by its ineffectual clicking against the evacuator, the lithotrite must be again introduced, the stone recrushed, and the evacuator reintroduced and the débris further removed. Removal of all débris is generally determined by the absence of clicking—which is often heard at a distance, but is generally to be detected by the ear placed near the bladder—and by the coming away of perfectly clear and clean water. The bladder may be finally irrigated—and the evacuator withdrawn (Fig. 525). (5) The patient is generally kept quietly in bed for a few days.

Comment.—(1) Avoid grasping the mucous membrane of the bladder in the instrument, the construction of which usually makes it impossible or diffi-

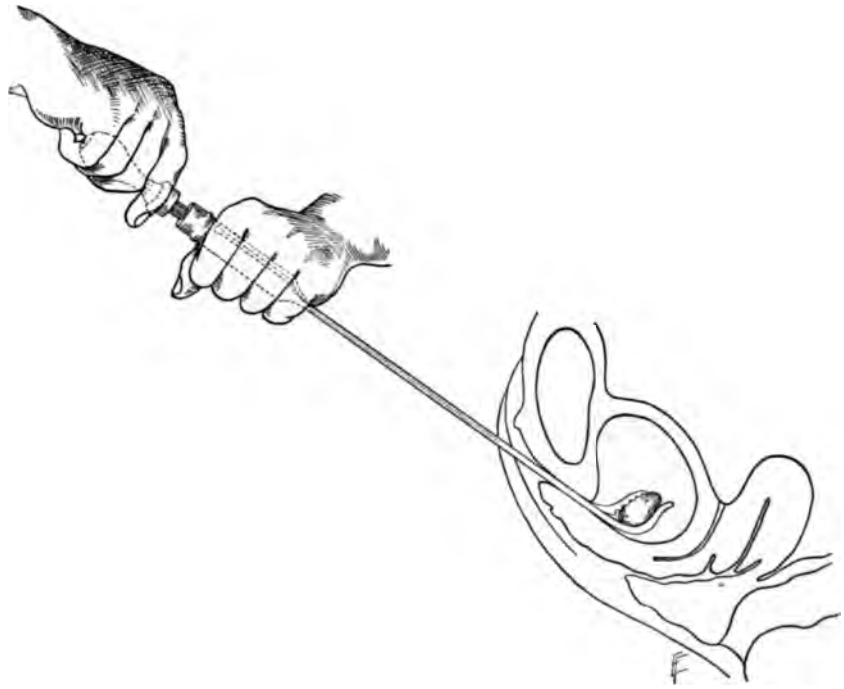

Fig. 526.—LITHOLAPAXY IN THE FEMALE:—The lithotrite in position.

cult. At any rate, before finally forcibly closing the blades, always shift the blades, so as to feel that they are free and have not included the bladder-wall. (2) In evacuating débris, the bladder should not be allowed to get empty of fluid—as the walls of the organ would have a tendency to be drawn into the evacuator by suction. (3) If air enter the bladder, depress the handle of the evacuator so as to raise its tip above the level of the bladder fluid, and suck the air out with the bulb. (4) If the instrument clogs and cannot, by persistent though gentle effort, be freed, it must be exposed and cleared through a suprapubic cystotomy. (5) Only a lithotrite with fenestrated blade should be used, thus lessening the chances of clogging. (6) It may be necessary to slightly incise the urinary meatus in order to get the beak of the instrument to enter the urethra. (7) Instruments of special size, as well as particular care, are neces-

sary in operating upon children. (8) Litholapaxy in women is much more easily performed than in men, because of the shorter, larger urethra (Fig. 526). (9) A simple instrument has been devised for combined crushing and evacuation by Chismore.

VESICAL DRAINAGE.

Description.—By vesical drainage is meant the drainage of the bladder contents through a natural or an artificial channel. While the bladder is being drained for consecutive days, daily irrigations with aseptic or mildly antiseptic solutions may be used. Where the bladder cavity is made directly continuous with the suprapubic or perineal regions, suprapubic or perineal cystotomy may be said to be done. Bladder drainage may be urethral, perineal, or suprapubic.

Urethral Bladder Drainage.—Consists in drainage by a soft catheter passed through the urethra into the bladder. Indicated for only brief drainage —not over three or four days, the usual limit of bladder toleration. A soft catheter is introduced until its eye has just entered the bladder, which is ascertained by withdrawing the catheter and retaining it in the position in which it was just before cessation of flow. Various devices are used for holding the catheter in the urethra. A 1 cm. (or ½ inch) width of rubber-plaster may be passed three-fourths of the way around the penis (to allow of expansion of the organ) just behind the corona, and to this the tube may be tied by silk suture passed with a needle through the outer wall of the tube and upper border of the plaster band.

Perineal Bladder Drainage.—Consists in drainage of the bladder through the perineum by means of a tube, or through the bare wound resulting from perineal cystotomy. Indicated, chiefly, in operations upon the bladder by the perineal route, and in cases of impervious urethra. Where the drainage is the primary consideration (as in aggravated cystitis and in other conditions of prostate, bladder or urethra) the membranous urethra is opened by median perineal incision, just as in external urethrotomy (page 907)—the catheter is carried through the prostatic urethra into the bladder, until its eye rests just within the bladder-cavity—and is then fastened to a T-bandage by a silk suture carried on a needle through the outer wall of the catheter. A long rubber tube is then connected with the catheter and carried to a bottle at the foot of, or under, the bed, and drains by siphonage.

Suprapubic Bladder Drainage.—Consists in drainage of the bladder through a suprapubic cystotomy wound. Indicated in some operations upon the bladder, aggravated cystitis, etc. The drainage may be accomplished by simple siphonage by catheter—or by various devices, some mechanical, and others by methods of suturing. (a) By Siphonage Tube ordinarily Sutured into the Bladder:—Following the suprapubic cystotomy, a pliable rubber tube, with large eye, is introduced through the bladder-wound, which has been partly closed from both ends—and so adjusted that its lower end barely reaches the lowest part of the bladder-cavity but does not press upon it. A safety-pin passed through its outer wall, at the skin level, rests transversely across the lips of the partially sutured wound and maintains the fixed depth of the tube. A large gauze-pad, with central perforation, is then placed around the tube, and a second safety-pin passed in just above the second pad to steady the tube. The free end is connected with a rubber tube, emptying into some reservoir for drainage. Where much hemorrhage is expected, or, for other reason, irrigation is needed, two parallel tubes may be used—one serving the above purpose,

and the other being used for throwing irrigating fluid into the bladder, which then siphons out by the first tube. (b) By Siphonage through a Tube introduced by Gibson's Method:—This is an application of the Kader Gastrostomy method to the bladder (see page 774). The bladder-wall is exposed as in the suprapubic cystotomy—an opening is made in the middle line of the bladder sufficiently large to admit the tube snugly—in the median line, in front and behind the tube, a Lembert suture of chromic gut is placed so as to closely embrace the tube. These sutures form the first tier. Then, a second tier of four sutures, two in front and two behind, is applied. (If necessary, a third tier might be used.) The tube is thus buried in—in a valve-like manner—so that when the tube is removed, the opening is closed by the tendency of the folds—and can be again readily re-introduced. A long tube is attached to this for siphonage and conducted to a reservoir, as in the other methods (Fig. 527).

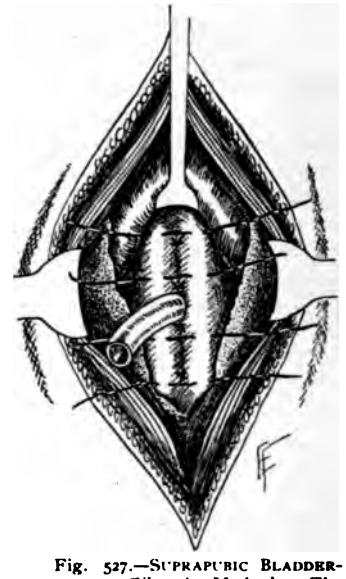

Fig. 527.—SUPRAPUBIC BLADDER-DRAINAGE (Gibson's Method):—The first tier of sutures are shown tied. The second tier are placed ready to be tied and further bury in the tube. The remaining structures are same as given in Fig. 519.

PARTIAL CYSTECTOMY.

Description.—Removal of a limited portion of the bladder. Generally performed for the removal of a tumor involving a part of the bladder-wall. The site of the tumor may be extraperitoneal or intraperitoneal—or both.

Operation.—The general features of the operation may be gotten from the description of the total removal of the bladder. The steps of the partial removal will depend upon the site of the growth demanding partial cystectomy. (1) When the tumor is upon the upper part of the bladder and the peritoneum can be pushed back, the involved portion of the bladder-wall is excised with scissors—and the lips of the wound then brought together and sutured (see Cystorrhaphy). (2) When the tumor is similarly placed but its removal involves the opening of the peritoneal cavity—the peritoneal wound is closed by suture and the bladder-wound dealt with as just described. (3) If the tumor be above the ureters, upon the posterior aspect of the bladder, it may be exposed through a suprapubic cystotomy and removed from within the bladder, followed by the approximation and suturing of the edges of the wound left and the establishment of drainage. (4) When the area involved lies upon the anterior bladder-wall, behind the symphysis, partial resection of the symphysis, or symphysiotomy, may be necessary. (5) If the involvement be at the mouth of a ureter, the site should be excised—the healthy ureter, after excision of its vesical end, should be implanted into a neighboring part of the bladder—and the wound made by the original excision closed. (6) Where the base of the bladder is involved and the openings of the ureters are healthy, these should be excised, *en masse*, and transplanted into the rectum—and the bladder removed. Following all partial excisions, the remainder of the bladder-walls should be brought together by

suture—temporary drainage established down to the sutured bladder—and a catheter introduced into the bladder for drainage, and to prevent overdistention and tension upon the sutures.

TOTAL CYSTECTOMY

BY SUPRAPUBIC MEDIAN VERTICAL AND TRANSVERSE INCISIONS.

Description.—Complete excision of the bladder, followed by implantation of the ureters. Indicated in malignant disease limited to the bladder. The operation as performed by Tuffier and Dujarier will be here described—consisting in an extraperitoneal abdominal excision of the bladder, followed by an implantation of the ureters in the sigmoid colon.

Preparation.—Bowels emptied; pubes shaved; bladder distended with aseptic fluid at an early stage of the operation.

Position.—Patient in the Trendelenburg position, near the edge of the table. Surgeon on patient's left. Assistant opposite.

Landmarks.—Median line; symphysis pubis; inguinal canals.

Incision.—⊥-shaped—the vertical incision is made in the median line, beginning at the symphysis pubis and passing upward for 10 to 12.5 cm. (4 to 5 inches). The transverse incision unites the inguinal canals, along the suprapubic border, to the vertical incision.

Operation.—(1) Incise vertically carefully in the median line, especially over the position of the peritoneum. Expose the bladder and the reflection of peritoneum—pushing the latter upward well off of the bladder. Clamp and tie all bleeding vessels. (2) Make the horizontal incision from one inguinal canal to the opposite, just above the border of the pubic bone and Poupart's ligament. Clamp or tie bleeding vessels in this line of incision. Dissect up the rectangular flaps thus outlined—and retract them upward and outward on both sides—thus giving free access to the bladder. (3) Separate the anterior aspect of the bladder from the pubis, down to its neck, by blunt dissection—exposing and isolating its neck—moderate traction being exercised upon the anterior and lateral walls by vulsella. (4) The neck of the bladder is clamped and divided above the clamps. (5) The peritoneum is carefully peeled off of the superior, posterior, and lateral aspects of the bladder, avoiding making any opening into the peritoneal cavity. (6) The inferior vesical arteries and ureters are secured close to the bladder, in curved clamps, and divided *en masse*. (7) The base of the bladder is separated from its remaining connections and the viscus removed. (8) The urethral and the ureteral openings are cauterized. (9) The vesical arteries are tied and the clamps relaxed. (10) The ureters are implanted within the sigmoid colon. (11) The deep wound is packed with gauze—drainage being brought out just over the symphysis pubis—all of the transverse and most of the vertical incisions being sutured.

Comment.—(1) Avoid opening the peritoneum if possible—and, if opened, suture at once—or, if the opening be too large, pack with gauze. (2) The authors, Tuffier and Dujarier, made the uretero-sigmoidostomy with Chalot's buttons. Fowler's method (page 870) may also be used.

CHAPTER VI.

OPERATIONS UPON THE MALE GENITAL ORGANS.

I. THE PENIS.

SURGICAL ANATOMY.

Description.—Consists of glans, body, and root. Body is composed of two corpora cavernosa and the corpus spongiosum.

Corpora Cavernosa.—Connected, side by side, in the median line, for their anterior three-fourths—an imperfect fibrous septum intervening. Separated, posteriorly, to form the crura, or roots. The crura are attached by their blunt, fibrous, posterior ends to the antero-internal aspects of the two rami of the pubes and ischia, above the tuberosities. The anterior ends of the cavernosa are received into the fossa formed by the base of the glans penis, or head. The superior median groove of the corpora cavernosa lodges the dorsal vein of the penis. The inferior median groove lodges the corpus spongiosum.

Corpus Spongiosum.—Encloses the urethra, which passes into the bulb nearer its superior aspect. It is received into the inferior median groove of the corpora cavernosa. It ends, anteriorly, in the glans penis, or head of the organ. It ends, posteriorly, in the bulb of the corpus spongiosum—between the diverging crura of the corpora cavernosa, and between the deep layer of the superficial fascia and the superficial layer of the deep fascia—being covered by a fibrous process from the anterior layer of the deep perineal fascia and surrounded by the accelerator urinæ muscle.

Suspensory Ligament of the Penis.—A fibrous band passing from the front of the symphysis pubis to the adjacent portion of the penis, merging with its fascial sheath.

Muscles of Penis.—Erector penis; accelerator urinæ; compressor urethræ; transversus perinæi.

Arteries.—(a) Of the corpora cavernosa:—arteries of the corpora cavernosa; dorsal arteries of the penis. All from internal pudic. (b) Of the corpus spongiosum:—artery of the bulb, from internal pudic.

Veins.—Some of the veins empty into the dorsal vein, which ends in the prostatic plexus. Other veins empty directly into the prostatic plexus, pudic plexus, pudic veins, and obturator veins. Others empty into the cutaneous veins of the penis and scrotum.

Lymphatics.—The superficial empty into the inguinal glands. The deep empty into the pelvic glands.

Nerves.—From the dorsal and superficial perineal branches of the pudic and from the hypogastric plexus of the sympathetic.

INSTRUMENTS.

Scalpels; narrow, straight bistoury; scissors; retractors; tenacula; dissecting and toothed forceps; artery-clamp forceps; blunt dissector; periosteal elevator;

rubber tourniquet (rubber catheter); needles, straight and curved; needle-holder; ligatures and sutures, silk and gut.

CIRCUMCISION.

Description.—Removal of greater portion of redundant or contracted prepuce. The amount of foreskin to be removed should be so calculated that two objects be accomplished:—first, that enough foreskin be removed to insure easy exposure of the entire glans penis, even during erection;—secondly, that enough foreskin be left to insure constant covering of the prominent corona glandis during relaxation of the organ, thereby securing retention of greater sensitiveness of the papillæ than when the corona is worn constantly bare, and, therefore, dry. Many mechanical contrivances have been devised for aiding in circumcision—but the operation can generally be more satisfactorily done with scissors alone—and, by this means, greater accuracy is usually obtained in providing the exact amount of prepuce which it is well to leave.

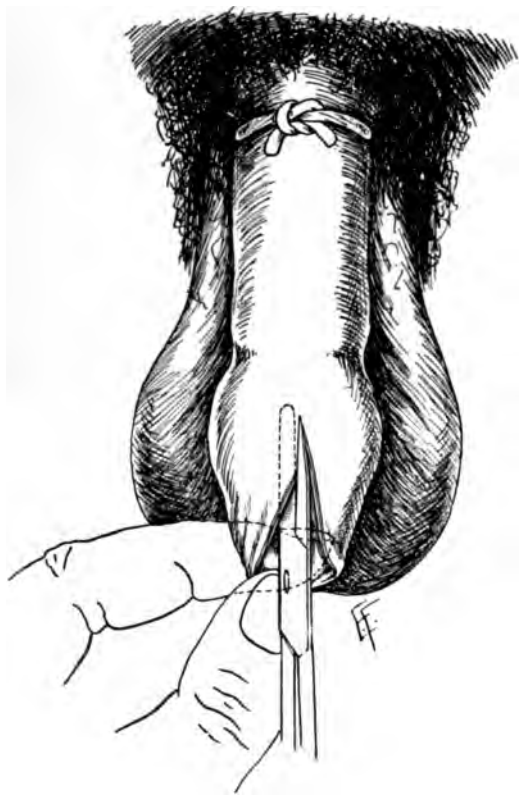

Fig. 528.—CIRCUMCISION:—I. Scissor-blade between glans and prepuce, cutting foreskin in median dorsal line up to level of its removal.

Preparation.—A constrictor, usually a rubber band, is applied around the base of the penis.

Position.—Patient supine, near the left edge of table. Surgeon on patient's right.

Landmarks.—Position of sulcus at junction of head and body of organ.

Operation.—(1) As there will be a much greater tendency for the skin-aspect of the prepuce to retract more than for the mucous-membrane-aspect, it is well, in all methods of circumcision, as a preliminary step to the actual division of preputial tissue, to take the skin and mucous surfaces of the foreskin between the left index and thumb (or between the blades of a pair of toothed forceps) and so dispose the parts that the mucous membrane is drawn slightly forward and the skin pushed slightly backward—so that there will be somewhat less disparity when the section is made. (2) Taking the foreskin in the left fingers, the surgeon inserts the lower blade of a pair of straight scissors beneath the upper aspect of the foreskin, between it and the dorsum of the glans—and

cuts through the prepuce with one stroke, up to the height upon the dorsum which it has been calculated will leave sufficient prepuce to cover the corona during relaxation of the organ (Fig. 528). (3) The scissors are then withdrawn from the vertical incision—and the position of the hands then changes. The left fingers grasp the left flap, the one nearer the surgeon, and, holding it slightly away from the glans, the scissors are made to cut through one-half of the circumference of the organ—the guide for the cut being that it should pass about parallel with the corona glandis, crossing the median line upon the under aspect of the prepuce just in front of (distal to) the frænum (Fig. 529). (4) The right flap is now dealt with in the same manner—completing the encircling of the organ. The incision will, therefore, slope obliquely from above downward and from behind forward. (5) Four primary chromic gut sutures are then applied in the midpoints—above, below and laterally—closely approximating the margin of mucous membrane to the margin of skin. These are followed by four or eight secondary sutures evenly distributed between the primary ones (Fig. 530). (6) The dressing is so applied as to leave an opening for urination.

Fig. 529.—CIRCUMCISION:—II. Division of the entire thickness of the prepuce transversely, at the upper limit of the median incision. While the entire redundant portion of prepuce is being drawn downward, the left thumb and index so manipulate the parts that more of the mucous membrane than of the skin is removed.

Comment.—(1) The usual error is to remove too much foreskin. A prepuce, appearing to be sufficient after the completing of the operation, often gets entirely and permanently behind the corona in subsequent retraction—at the expense of considerable loss of sensitiveness of the papillæ. (2) If any question arise, during operation, as to the width of the opening being too narrow, the vertical incision may be extended upward additionally high—the lateral incisions then being sloped downward so as to come just in front of the frænum. (3) The redundancy of the mucous membrane is apt to be much greater than that of the skin. (4) In using all forms of circumcision-clamps too much or too little prepuce is apt to be cut away. (5) If the penis is to have a preliminary constrictor applied, which would tend to draw back the foreskin into a somewhat unnatural position, greater accuracy in measurements may be obtained by first (before applying tourni-

quet) marking the site at which the removal is desired with a nitrate of silver stain. (6) Sometimes one or more vessels have to be twisted or gut-ligatured. (7) Do not leave too great an amount of tissue near the frænum. (8) It may be necessary, before suturing, to trim the edges somewhat with scissors, especially of the mucous membrane. (9) Where there is firm adhesion between prepuce and glans, especially in children, the prepuce must be carefully peeled off—by means of the fingers, aided by toothed forceps and the flat portion of a probe. (10) Often, in adherent prepuces, no instrument can be slipped up between the prepuce and glans—and the opening of the prepuce is too small to allow of retracting the membrane far backward—in which cases the redundant portion must be put upon tension and cut off transversely, after which the separation of adhesions may be more easily accomplished. (11) In operating in adherent cases, re-adhesion is prevented by removing an excess of mucous membrane and leaving a slight redundancy of skin. In completing the operation, the skin is sutured to the very short mucous membrane—and, being quite long, is doubled upon itself, and the part in contact with the glans eventually becomes of the nature, somewhat, of mucous membrane.

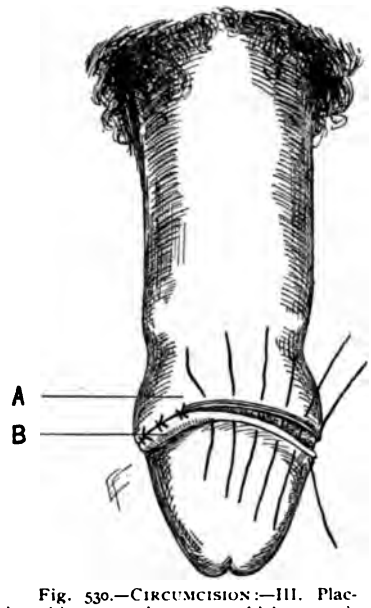

Fig. 530.—CIRCUMCISION:—III. Placing of interrupted sutures—which approximate the free edge of the skin (A) to the free edge of the mucous membrane (B).

PARTIAL AMPUTATION OF PENIS

BY FLAP METHOD.

Description.—Consists in the amputation of more or less of the free portion of the penis by a long anterior and short posterior flap—the freed urethra being brought through and sutured into the anterior flap. The stump is thus covered by two bluntly rectangular flaps.

Preparation.—A rubber tourniquet (usually a rubber catheter) is placed around the base of the organ. A short piece of soft catheter is passed into the urethra, down to the tourniquet, to emphasize the furrow between the corpora cavernosa and corpus spongiosum—or may be passed just before the transfixion.

Position.—Patient supine, at edge of table. Surgeon on patient's right. Assistant opposite.

Landmarks.—Line of section. Furrow between cavernosa and spongiosum.

Incision.—The anterior flap will have a width of one-half the circumference of the penis at the line of division, and a length of about one diameter of the penis. The posterior flap will have the same width of base, and a length of about a half diameter of the penis.

Operation.—(1) Having decided upon the line of section of the penis, an

anterior or dorsal flap, of skin and connective tissue, is cut, having a width of half the circumference of the organ at the line of division, and a length about equal to the diameter of the organ (Fig. 531). This is raised up by dissection

Fig. 531.—PARTIAL AMPUTATION OF PENIS BY FLAP METHOD:—I. Outlining of flaps; A, Long anterior flap; B, Short posterior flap.

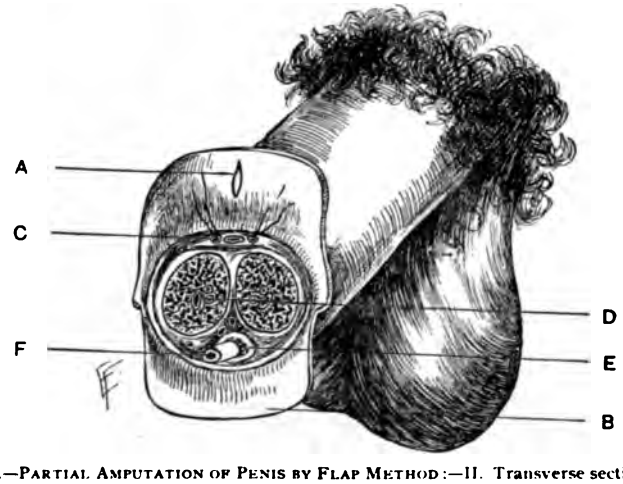

Fig. 532.—PARTIAL AMPUTATION OF PENIS BY FLAP METHOD:—II. Transverse section of stump; A, Long anterior flap turned back, showing slit for urethra; B, Short posterior flap; C, Dorsal vein and arteries; D, Corpora cavernosa and vessels; E, Corpus spongiosum; F, Urethra dissected out, and ready to be sutured into slit of anterior flap.

and turned back—the dorsal arteries being tied with gut. (2) On a level with the base of the anterior flap, the divisional groove between the corpora cavernosa and corpus spongiosum is recognized, aided by the soft catheter in the

urethra. A narrow-bladed knife, held flatwise, with back of blade backward, is thrust horizontally through the organ, between the cavernosa and spongiosum—and cuts its way through, passing at first directly forward in the groove and then rounding abruptly downward—thus forming an inferior flap of about one-half the diameter of the penis in length, composed of corpus spongiosum, with its included urethra and skin. (3) The urethra is now dissected out from the small inferior flap, back to a line with the base of the flaps. (4) The corpora cavernosa are divided transversely from within outward and upward, on a line with the highest point of transfixion (base of flaps) (Fig. 532). The arteries of the corpora cavernosa are tied with gut, or twisted. (5) Make a vertical incision in the center of the long anterior flap, opposite the urethra and just large enough to receive the urethra. The urethra is then drawn through this opening. If the urethra be much too long, the redundancy is cut off, leaving a protrusion of about 7 mm. ($\frac{1}{4}$ inch)—which is slightly slit above and below—and sutured into the margins of the opening in the anterior flap. (6) The two flaps are then united by suture, both where their free ends meet—and where in apposition laterally (Fig. 533). (7) A dressing is applied, leaving room for urination—at the same time exercising pressure of the flap against the stump of the penis.

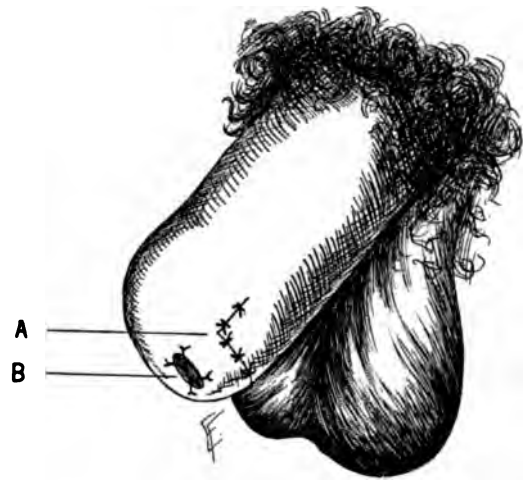

Fig. 533.—Partial Amputation of Penis by Flap Method:—III. The parts sutured; A, Suture-line of flaps; B, Urethra sutured into slit in long anterior flap.

Comment.—The arteries of the corpus spongiosum and of the septa may need ligating.

TOTAL AMPUTATION OF THE PENIS.

Description.—In the total amputation the entire organ is removed, except the posterior portion of the corpus spongiosum—the proximal portion of the urethra being made to open in the perineum.

Preparation.—Shave pubis and perineal region.

Position.—Patient supine, at end of table, in lithotomy position. Surgeon between limbs. Assistant to surgeon's right.

Landmarks.—Subpubic arch; scrotal and perineal raphé.

Incision.—The incision circularly surrounds the base of the organ, at its junction with the abdominal wall—and is then continued down the median line of the scrotum and into and along the median line of the perineum.

Operation.—(1) Incise the scrotal tissues exactly in the median line, from the under surface of the penis, at its junction with the scrotum, to and into the perineum. Separate the two scrotal sacs by blunt dissection, until the corpus spongiosum is reached. All bleeding vessels are clamped and ligated as en-

anterior or dorsal flap, of skin and connective tissue, is cut, having a width of half the circumference of the organ at the line of division, and a length about equal to the diameter of the organ (Fig. 531). This is raised up by dissection

Fig. 531.—PARTIAL AMPUTATION OF PENIS BY FLAP METHOD:—I. Outlining of flaps; A, Long anterior flap; B, Short posterior flap.

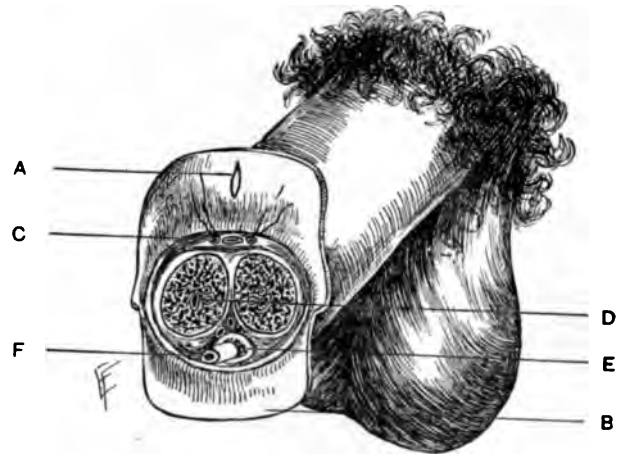

Fig. 532.—PARTIAL AMPUTATION OF PENIS BY FLAP METHOD:—II. Transverse section of stump; A, Long anterior flap turned back, showing slit for urethra; B, Short posterior flap; C, Dorsal vein and arteries; D, Corpora cavernosa and vessels; E, Corpus spongiosum; F, Urethra dissected out, and ready to be sutured into slit of anterior flap.

and turned back—the dorsal arteries being tied with gut. (2) On a level with the base of the anterior flap, the divisional groove between the corpora cavernosa and corpus spongiosum is recognized, aided by the soft catheter in the

scrotal portions of the wound and the circular area formerly occupied by the base of the penis, at the peno-abdominal junction, are all sutured in one straight antero-posterior line with continuous silk suture. (Figs. 535 and 536.)

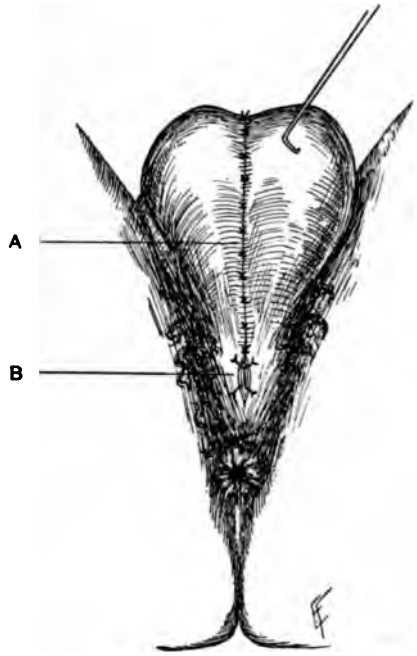

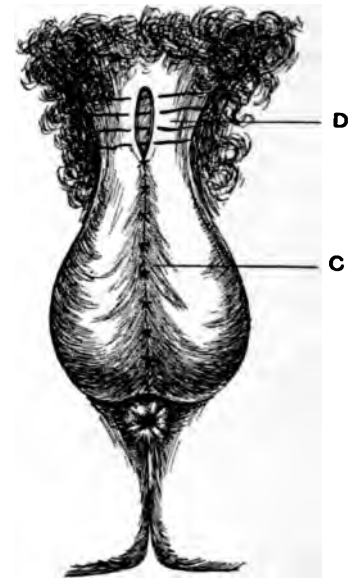

Fig. 535.—Total Amputation of Penis:—Scrotum drawn up on to abdomen; A, suture-line uniting scrotal sacs; B, proximal end of urethra sutured into perineum.

Fig. 536.—Same; Scrotum in normal position (patient on back); C, suture-line uniting scrotal sacs; D, interrupted sutures about to be tied, converting circular incision around base of penis into a linear cicatrix continuous with scrotal suture-line.

Comment.—(1) The urethra should be so sutured into the perineum that in the act of urination, in a sitting posture, the urine will not wet the scrotum. (2) The early passage of the metallic sound greatly aids in the splitting of the scrotum.

II. THE URETHRA.

SURGICAL ANATOMY.

(A) Male Urethra.

Description.—Extends from bladder-opening to external urinary meatus —from 20.5 to 23 cm. in length (8 to 9 inches). It consists of muscular, erectile, and mucous tissue. It is divided into prostatic, membranous, and spongy portions.

Prostatic Portion.—About 3.2 cm. (1¼ inches) long. Passes through the prostatic gland, near its upper aspect, from base to apex. The following objects are upon the floor of the prostatic urethra, from behind forward;—(**a**) verumontanum, an elevation of mucous membrane in the middle line;—(**b**) prostatic sinuses, one upon each side of the verumontanum, with the orifices

countered. If a metallic sound be previously introduced through the urethra, the incision and subsequent dissection are made easier (Fig. 534). (2) If a sound have not been previously introduced, a large-sized metallic sound is now passed through the urethra up to the triangular ligament, to aid in defining the corpus spongiosum. The corpus spongiosum is then dissected out until free in its entire circumference. The sound is then withdrawn—and the spongy urethra is divided well in front of the triangular ligament—and the proximal end of the spongy urethra is then freed back to the triangular ligament. (3) Carry the upper end of the vertical incision circularly around the base of the

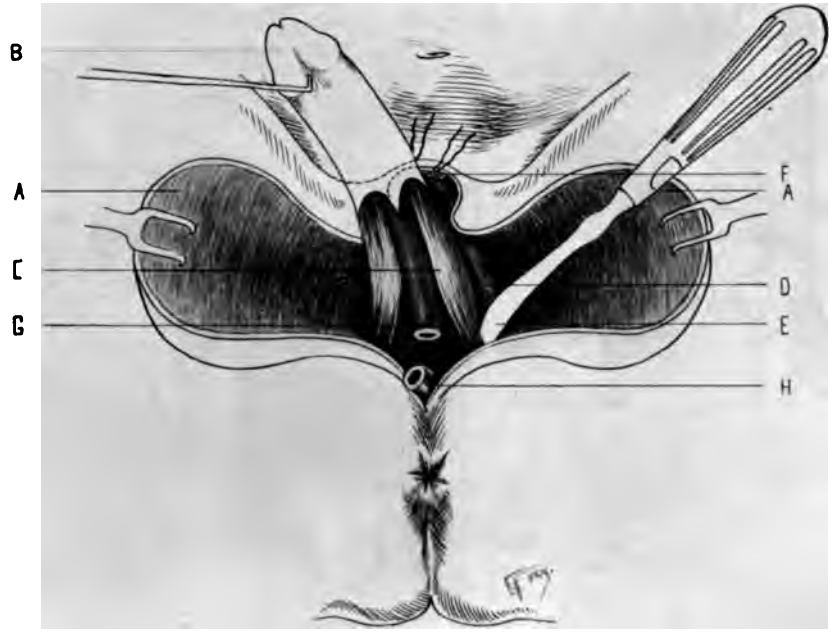

Fig. 534.—TOTAL AMPUTATION OF PENIS:—A, A, The two halves of scrotum split and retracted outward; B, Penis drawn downward and to one side, thus aiding separation of its crura; C, Corpora cavernosa (crura); D, Ramus of ischium; E, Periosteal elevator detaching left crus of penis from ascending ramus of ischium by blunt dissection; F, Dorsal vessels of penis divided and ligated. The suspensory ligament of penis and concavity of pubic arch are seen just below; G, Distal end of corpus spongiosum and urethra; H, Proximal end of urethra dissected out and ready to be sutured into perineum.

penis. Divide the suspensory ligament—and expose the corpora cavernosa. (4) The corpora cavernosa are to be followed down to their attachment to the rami of the pubes and ischia—and freed from their attachment chiefly by blunt, but partly by sharp, dissection. The dorsal arteries are tied after cutting through the suspensory ligament, and the arteries of the corpora cavernosa generally require ligation when the cavernosa are freed from the bone. Bleeding from the vesico-prostatic plexus of veins is often considerable, and is to be controlled by pressure and hot water. (5) The proximal end of the urethra is now turned downward and sutured into the perineum—the mucous membrane of the former being sutured to the skin of the lips of the perineal wound. If necessary, the urethra may be split so as to enable its lips to be more readily sutured into the perineal wound. (6) The remaining perineal and all the

after cutting down upon that portion emerging from the apex of the prostate gland.

For other general considerations, see Urethrotomy.

INSTRUMENTS.

Scalpels; bistouries; scissors; forceps, dissecting, toothed, and artery-clamp; tenacula; grooved director; sounds; catheters; filiforms; tunneled sounds; grooved and tunneled guides; probe-pointed scalpels; sponge-holders; retractors; thread-retractors; bulbous bougies; dilating bougies; prostatic catheters; medially and laterally grooved staffs; urethrotomes; Clover's crutch, wristlets and anklets; gorget; urethral dilator; dilating urethrotome; penis syringe; female catheters; needles, straight and curved; needle-holders; ligatures and sutures, of silk and gut; silkworm-gut; drainage-tubing; gauze.

INTRODUCTION OF SOUNDS AND CATHETERS.

See Introduction of Sounds and Catheters into the Bladder, page 878.

MEATOTOMY.

Description.—Incision of external urinary meatus. Indicated in contracted meatus, especially in cases where it is necessary to pass a full-sized instrument.

Preparation—Position.—As for Internal Urethrotomy.

Operation.—The penis is taken in the fingers of the operator's left hand—the lips of the meatus are parted by the index and thumb—a probe-pointed bistoury is passed just within the canal, its cutting-edge downward—and an incision made, as far as necessary, downward along the median line of the floor of the meatus, increasing the size of the meatus to the desired dimension. The lips of the wound, until healed, must be kept apart with a strip of gauze.

Comment.—The operation may be done by a meatome, a special instrument, which is inserted closed and the meatus is cut in the act of opening the instrument.

URETHROTOMY IN GENERAL.

Urethrotomy consists in the incision of the urethra, generally in its long axis.

Varieties of Urethrotomy.—Internal Urethrotomy and External Urethrotomy.

Internal Urethrotomy:—division of a strictured urethra from within the canal, by means of a special instrument, a urethrotome, introduced into the canal. Where simultaneous dilatation is indicated, a dilating urethrotome is used. Internal urethrotomy is usually confined to the penile portion of the organ, and the incision is generally made into the roof of the urethra.

External Urethrotomy:—division of a strictured urethra from without inward. External Urethrotomy is indicated—(**a**) In impermeable strictures anywhere and everywhere in the canal—(**b**) All strictures, whether permeable or not, at or posterior to the subpubic urethra.

Several grades of permeability of the urethra may exist—calling for ex-

ternal urethrotomies of several grades of severity. These grades of stricture, and the measures for their relief, are, in order:—(1) Grooved staff can be passed entirely through the strictured urethra,—and, upon this, the stricture is divided—constituting External Urethrotomy by Syme's Method. (2) Grooved staff cannot be passed, but a filiform guide can be introduced through the stricture into the bladder, and, over this guide, Gouley's grooved tunneled sound can be carried down to the stricture (but not through it),—and, upon this, the upper end of the stricture is exposed, and the filiform followed into the bladder and the stricture thus divided—constituting External Urethrotomy by Gouley's Method. (3) Grooved staff cannot be passed through stricture, nor can filiform be passed through, but a grooved staff can be passed down to the stricture (not through it),—and, upon this, the urethra is opened just in front of the stricture, a fine grooved director passed, and the stricture divided upon this—constituting External Urethrotomy by Wheelhouse's Method. (4) Neither grooved staff nor filiform can be passed through the stricture, the urethra being, practically, impassable to instruments of all kinds —therefore no attempt is made to use any form of guide—the urethra is opened, by the sense of touch and relations, posterior to the stricture and immediately anterior to the prostate—constituting External Perineal Urethrotomy without a guide (Perineal Section, or Cock's Operation).

The bladder is kept partly full in all urethrotomy operations, in order that entrance to it may be recognized by the escape of fluid.

For the anatomy involved in the perineal operations, see the description of Median Perineal Cystotomy.

INTERNAL URETHROTOMY

BY DILATING URETHROTOME.

Description.—Division of a strictured urethra from within the urethra, by means of a special instrument, a dilating urethrotome, introduced into the canal. If simultaneous dilatation be not indicated, a plain urethrotome may be used. Internal urethrotomy is generally confined to the penile portion of the organ, and the incision is usually made from behind forward, upon the roof of the urethra.

Preparation.—Locate the exact position of the stricture by a bulbous bougie, in the following manner,—introduce the largest-sized bulbous bougie which will pass the stricture—draw it back until its shoulder is felt against the posterior end of the stricture—bend the free portion of the bougie at the external meatus—draw the instrument outward until the bulb slips through the stricture—then push it back until the tip of the bulb rests against the anterior end of the stricture—then again bend the free portion of the bougie at the external meatus—and withdraw the instrument entirely—when the portion of the handle between the two bends will represent the extent and distance of the stricture from the meatus. A more accurate means of getting the desired position and extent of the stricture is accomplished by the urethrometer. The urethra should be irrigated with a mildly antiseptic solution before instrumentalization—and a cocain, or other anesthetic solution, thrown into the canal.

Position.—Patient supine at edge of table. Surgeon upon left, facing patient's penis.

Landmarks.—Previous data gotten from urethrometer, or bulbous bougie. Known anatomy of urethra.

Operation.—The dilating urethrotome, with closed blades and concealed cutting-edge, and well lubricated with aseptic lubricant, is introduced into the urethra after the fashion of a sound, until the concealed cutting-edge has passed directly opposite the posterior aspect of the stricture, as determined by the previous measurements of the urethrometer corresponding with the measurement and distances marked on the urethrotome. The dilating blades are then put upon the stretch until the strictured urethra is tensely distended —then the cutting-edge, turned toward the roof of the urethra, is sprung by the controlling screw in the handle—and drawn through the stricture, to its anterior limit, from behind forward. (Fig. 537.) It is then caused to sink below the blades—and the dilating blades again separated. If the

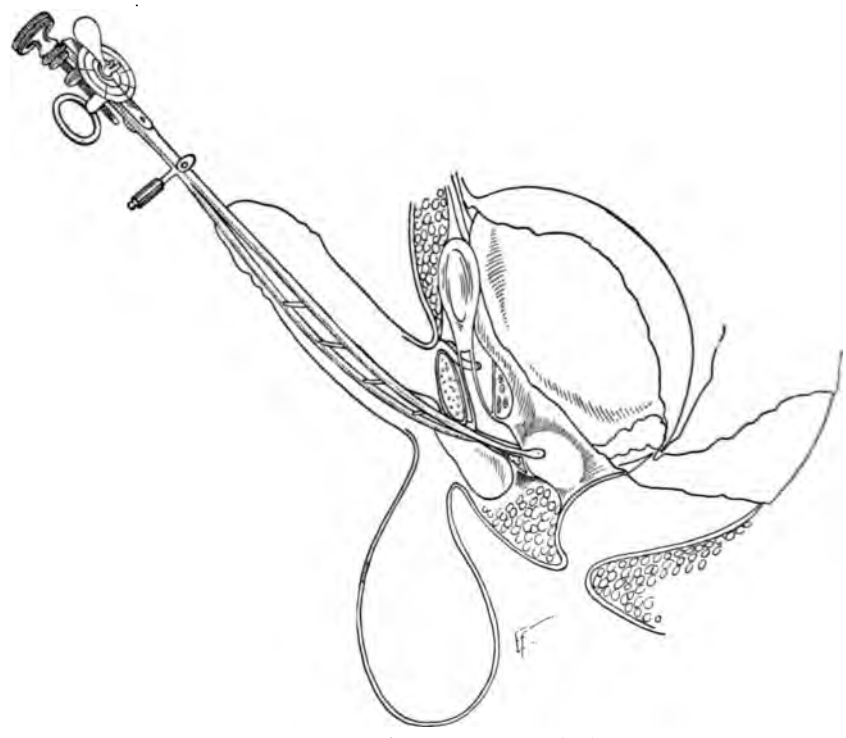

Fig. 537.—INTERNAL URETHROTOMY:—A dilating urethrotome is shown within the urethra—the limbs of the instrument being moderately dilated—and the knife-blade sprung so as to incise roof of spongy urethra anterior to the triangular ligament.

cutting has allowed of sufficient dilatation, it is not repeated—if not, while the urethra is under dilatation, the blade is sprung a second time, and again caused to sink—after which the dilating blades are again separated, to see if sufficient dilatation has been secured, as indicated by the dial upon the handle. If so, the blades are permanently closed and the instrument is withdrawn. If there should be marked bleeding, a large sound, dipped in sterile cold water, is passed into the urethra and the penis bound to it.

Comment.—The incision may be made from before backward—but from behind forward is better. It may also be made upon more than one site of the same stricture, but upon the roof generally suffices, and is safer than

upon the floor. Several strictures may be divided simultaneously. If the external meatus be too small to admit the urethrotome, meatotomy should be done. The subsequent passage of sounds is necessary, until healing is complete—and, at intervals, for a considerable time afterward.

EXTERNAL PERINEAL URETHROTOMY

UPON GROOVED STAFF—SYME'S METHOD.

Description.—A grooved staff can be passed entirely through the stricture—and, upon this, the stricture is divided from the perineum.

Special Instruments Required.—Syme's grooved staff, or an ordinary lithotomy staff of small size, grooved medially upon its convex aspect. Gorget, or grooved director, for entering the bladder from the perineal wound.

Preparation—Position.—As for median perineal cystotomy.

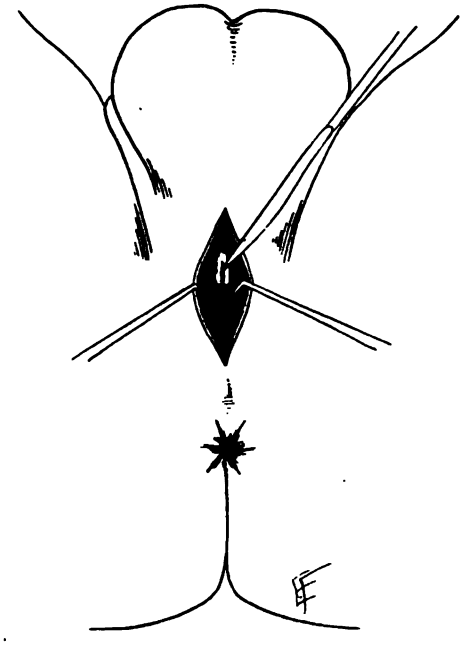

Fig. 538.—External Perineal Urethrotomy:—The perineum is shown incised and retracted. A Syme's shouldered, grooved staff is seen engaged within the membranous urethra—while the edge of a knife is shown incising the constricted urethra upon the groove of the instrument.

Landmarks.—Median perineal line; position of grooved staff in urethra, and especially the position of the stricture to be divided, as ascertained by previous use of the urethrometer, and also verified by the shouldered portion of the staff corresponding with the urethrometer measurements and resting against the anterior end of the stricture.

Incision.—Having introduced Syme's grooved staff, or a small, centrally grooved lithotomy staff, well lubricated, into the urethra and through the stricture—so that its shouldered projection rests against the anterior aspect

of the stricture, an incision is made in the median line of the perineum, so placed that the shoulder of the staff (that is, the anterior end of the stricture) will be exposed in the depth of the incision.

Operation.—(1) The steps of the operation are, practically, those of median perineal cystotomy, as to structures incised and the manner of dividing them. The cut is made directly toward the shoulder of the instrument—the groove is entered—and, with the back of the point of the knife in the groove, its cutting-edge is pushed in the direction of the neck of the bladder, until the entire stricture is felt to be divided along its floor. (Fig. 538.) (2) A gorget, or grooved director, is now passed along the grooved staff on into the bladder—and the staff is then withdrawn. (3) A soft-rubber catheter is passed through the urethra from the meatus—its end being guided through the perineal wound by the operator's fingers and on into the bladder, upon the grooved director, on the proximal side of the perineal gap. (4) The perineal wound is allowed to heal by granulation around this catheter—being left open in whole—or sutured only at the ends.

Comment.—(1) If the catheter cannot be constantly retained, a tube may be carried into the bladder through the perineal wound. But an instrument should be daily passed from the meatus into the bladder during healing, even though a full-length instrument cannot be constantly worn. (2) An extensive perineal wound should be closed in part, from the ends—leaving the center open for the tube and drainage.

EXTERNAL PERINEAL URETHROTOMY

UPON A FILIFORM GUIDE—GOULEY'S OPERATION.

Description.—In cases in which the grooved staff cannot be passed, and only a filiform whalebone guide can be made to enter the bladder—a grooved tunneled guide is carried over the filiform down to the stricture (but not through it)—and, upon this tunneled guide, the upper end of the stricture is exposed—and the filiform is then followed on down into the bladder and the stricture divided.

Special Instruments—Filiform whalebone guides; Gouley's (or other) grooved tunneled staff.

Preparation—Position.—As for median perineal cystotomy.

Landmarks.—Median raphé; scroto-perineal junction; anus.

Incision.—In median line, from base of scrotum to a point about 1.3 cm. (½ inch) anterior to the anus.

Operation.—(1) Having succeeded in getting a filiform whalebone guide into the bladder, Gouley's tunneled grooved staff is threaded upon this and carried down into the urethra upon it, with the right hand, while the left hand holds the filiform—until it is arrested at, or within, the strictured urethra. An assistant now takes the filiform and metallic staff in his right hand, and draws up the scrotum with his left. (2) The surgeon incises directly in the median line of the perineum, beginning at the scroto-perineal junction, and ending about 1.3 cm. (½ inch) in front of the anus. The incision at first passes only through skin and fascia. The lower end of the instrument in the urethra is then felt for, the surgeon's left index nail depressing the intervening structures over the groove—and all the intervening tissues are now divided down to and into the groove—in the same manner and order as in median perineal cystotomy. (3) A silk traction-loop is placed in either lip of the urethral wound and the lips are then drawn apart—thus clearly demon-

strating the interior of the urethral canal, from its normal lumen above to where it disappears below into an almost imperceptible lumen. (4) The metallic staff is now partly withdrawn and steadied by an assistant, using care to retain *in situ* the filiform, by holding it in the perineal wound as the staff is withdrawn over it. Nothing now remains at the immediate site of the operation but the whalebone guide passing into the bladder. (5) With a probe-pointed bistoury, the filiform is carefully followed backward and the stricture thus divided throughout its length and slightly beyond. The tunneled staff is then thrust into the bladder over the whalebone guide. (6) The filiform is then withdrawn. A grooved director or gorget is passed into the bladder, through the perineal wound, over the grooved staff—and the staff withdrawn. (7) The remaining steps are the same as in Syme's operation (see sections (3) and (4), including "Comment," page 908).

EXTERNAL PERINEAL URETHROTOMY

UPON GROOVED STAFF PASSED DOWN TO STRICTURE—WHEELHOUSE'S OPERATION.

Description.—In these cases the grooved staff cannot be passed through the stricture—nor can a filiform be passed through—but a grooved staff can be passed down to the stricture—and, upon this, the urethra is opened just in front of the stricture and a fine grooved director is passed through it—and the stricture is divided upon this last director. The urethra is thus opened in the median line about 6 mm. (¼ inch) in front of the stricture—the feature of the operation being that at least this much of the sound urethra should be exposed in front of the stricture.

Preparation.—Perineum shaved. Lubricated grooved sound introduced down to the stricture and steadily held in the median line.

Position.—Patient supine, in the lithotomy position at the end of the table. Surgeon seated opposite the perineum. Assistant on patient's left, holding staff.

Landmarks.—Median line; perineo-scrotal junction; anus.

Incision.—From reflection of superficial perineal fascia, at perineo-scrotal junction—to anterior border of sphincter ani.

Operation.—(1) Incision is made in the median line to the above extent, and the tissues of the perineum are divided as in median perineal cystotomy—separating the tissues in the direction of the sound until the urethra is reached. (2) The urethra is then divided to a limited extent upon the grooved sound—especial care being taken that the urethra is opened about 6 mm. (¼ inch) in front of the stricture—the opening not extending down to the stricture. Looped silk traction-ligatures are then put in through the lips of the divided urethra, upon either side, and the two lips of the urethra are thus drawn apart. (3) The grooved sound is then withdrawn a short distance—just far enough to free its end from the remaining 6 mm. (¼ inch) of intact urethra in which it had been, up until then, engaged—the sound is then turned through a half revolution upon its axis, so that its extremity now points outward—and thus hooks up upon its concavity the upper limit (angle) of the urethral wound. The urethral opening is thus stretched apart in a lozenge-shaped manner, by the hooked sound above, by the traction-ligatures on each side, and by the attachment of the intact urethra below. (4) While thus held apart and well exposed, a fine probe-pointed grooved director, or gorget, is insinuated into and along the strictured urethra, with its groove

uppermost. Even often when the opening cannot be seen, the director will find its way toward the bladder among a mass of distorted tissue. (5) The groove of the director is now turned downward—and the strictured portion of the urethra is divided upon its floor by a knife passed along the director. The knife is withdrawn and the groove of the director, still in the urethra, is turned upward—and a metallic catheter, or sound, is then passed from the meatus, and is guided through the opened urethra by the fingers in the perineal wound—and thence on to the groove of the director—and thus into the bladder. (6) The metallic instrument is allowed to remain *in situ* for three or four days during granulation of the parts around the new canal—and is then passed daily until the perineal wound heals. (7) The perineal wound may be partly closed by suture—but is left unsutured in part, at least, for drainage.

Comment.—If the staff hooked into the incised urethra be in the way, it can be dispensed with.

PERINEAL SECTION, OR EXTERNAL PERINEAL URETHROTOMY

WITHOUT A GUIDE—COCK'S OPERATION.

Description.—In these cases neither a grooved staff, nor even a filiform bougie, can be passed through the stricture. The urethra is practically impassable to all instruments (from the presence of several strictures, false passages, rupture, disease, and the like). No attempt is made to use any form of guide. The urethra is opened posteriorly to the stricture and immediately anteriorly to the prostate. The bladder is thus relieved—and the anterior portion of the urethra is subsequently treated.

Preparation.—Perineum shaved. Bladder partly full.

Position.—Lithotomy position at edge of table. Surgeon seated facing perineum. Assistant holds penis and testes out of the way.

Landmarks.—Median line; perineo-scrotal junction; anus.

Incision.—In median line, from perineo-scrotal junction, to within about 1.3 cm. (½ inch) of the anus.

Operation.—(1) The surgeon introduces the left index-finger into the rectum, with nail to the sacrum, and keeps the tip of his finger against the apex of the prostate gland. (2) A knife is then made to cut directly and boldly, in the median line of the perineum, toward the tip of the left index-finger—the entire cut being made with one sweep of the knife, the incision beginning above near the perineo-scrotal junction, passing inward to the prostatic urethra, and ending below about 1.3 cm. (½ inch) anterior to the anus. The incision of tissues is, practically, the same as that for median perineal cystotomy. The deepest part of this triangular incision will be at the apex of the prostate gland, and the most superficial at the upper and lower ends of the base of the triangle upon the perineum. The knife is at no time withdrawn until the full depth of the wound and apex of the prostate gland are reached, as its reinsertion would be uncertain. In the depth of the wound the knife-point is guided by the tip of the left index-finger—and the urethra, at the posterior part of the membranous portion, is divided in its median aspect, or slightly obliquely—the anterior part of the prostate often also being divided. (3) Having incised the urethra, the knife is withdrawn—but the left index is kept in the rectum in contact with the apex of the prostate. (4) While the edges of the deep perineal wound are well retracted, a fine probe-pointed director is inserted into the opened urethra, guided by a finger in the rectum—and pushed on into the bladder. (5) Perineal drainage is estab-

lished by passing a soft catheter, through the wound in the perineum, into the bladder—the catheter being held in place by the perineal bandage. (6) This operation is generally resorted to where the urethra is very extensively involved or destroyed. If, therefore, the perineal opening is not to be a permanent one, steps may be taken subsequently, after restoration of the structures in whole or in part, with reference to the opening up of the anterior portion of the urethra by dilatation or urethrotomy.

Comment.—While the original operation by Cock was done in this manner, and generally abandoned if the urethra was not reached in two or three attempts, there is no reason why (and this is now generally done) the tissues should not be divided more deliberately and the urethra more persistently sought for. One should be guided by an intimate knowledge of the anatomy of the parts, in the face of great difficulties—for often the structures are unrecognizably altered.

URETHRORRHAPHY.

Description.—Suturing of the urethra. Indicated in incised and ruptured wounds and in fistula.

Preparation—Position.—As for Urethrotomy.

Landmarks—Incision.—Determined by nature and site of wound.

Operation.—Having exposed the site of the wounded urethra, by external incision—a metal sound or soft catheter is passed through the urethra, using special care not to increase the wound. With fine chromic gut, or fine silk, carried in a curved needle held in a holder, the opposite edges of the wounded urethra are united by interrupted sutures passing through the entire thickness of the lips of the wound—except the mucous membrane. A soft catheter is worn for two or three days, until time has been given for the shutting-off of the wound from the interior of the urethra. The external wound is left open, being packed with gauze until the urethral wall has healed —to avoid the danger of urinary infiltration.

Comment.—There are several plastic operations which may be done for urinary fistula.

URETHROSTOMY.

Description.—Making of a more or less permanent opening of the urethra upon the perineum. Indicated where the anterior portion of the urethral canal is impermeable, as for stricture,—or in case of amputation of the penis.

Preparation—Position—Landmarks.—As for median perineal cystotomy.

Incision.—Determined by the special circumstances of the case.

Operation.—(**a**) For the establishment of Urethrostomy following amputation of the penis, see section 5, under "Operation," page 901. (**b**) In performing Urethrostomy in connection with a strictured urethra:—Having exposed the strictured site, divide the urethra transversely, just behind the stricture, and free the proximal end of the urethra to a limited extent. Slit the proximal end slightly upon its floor, or upon floor and roof—and suture the lips thus formed by slitting, into the skin of the perineum. Suture up the proximal end of the distal portion of urethra—and close the wound up to the margins of the implanted urethra.

III. THE SCROTUM AND TESTES.

SURGICAL ANATOMY.

(A) The Scrotum and Coverings of Testes and Cords.

Description.—The scrotum is a cutaneo-musculo-areolar sac, investing the testes and part of the spermatic cords. It is composed of skin and dartos—the remaining layers mentioned below being, more properly, coverings of the testes and cords.

Skin.—Of characteristic appearance. Continuous with the general integument. Marked in the middle line by a raphé, which divides the scrotum into two lateral halves superficially.

Dartos.—Proper tunic of the scrotum—composed of reddish, elastic, and unstriped muscle tissue—continuous with the superficial and deep layers of the superficial fascia. Septum scroti—formed by the dartos—extending from the raphé to the inferior surface of the penis—dividing the scrotum into two cavities for the two testes, the left cavity being the longer.

Intercolumnar or External Spermatic Fascia.—Derived from borders of pillars of external abdominal ring. Continuous with superficial perineal fascia and superficial fascia over the symphysis pubis. Loosely (Gray—closely, according to Morris) adherent to the dartos. Intimately adherent to the cremasteric fascia.

Cremasteric or Middle Spermatic Fascia.—Fibro-muscular layer derived from lower border of internal oblique muscle.

Infundibuliform Fascia (Fascia Propria, or Internal Spermatic Fascia).—Connective-tissue layer derived from both the infundibuliform process of the fascia transversalis and also from the subperitoneal connective tissue (which latter may be considered a separate or sixth layer).

Tunica Vaginalis.—Closely connected with the testicles, with which it is described.

Arteries.—Superficial and deep external pudic of femoral; superficial perineal of internal pudic; cremasteric of epigastric.

Veins.—Correspond with arteries and empty into pudic, long saphenous, and dorsal vein of penis.

Lymphatics.—End in innermost set of inguinal glands.

Nerves.—Ilio-inguinal; superficial perineal branches of internal pudic; inferior pudendal branch of small sciatic; genital branch of genitocrural.

(B) The Testes.

Description.—The testes consist of the testicles proper and the epididymes, the latter also being the beginnings of the vasa deferentia. The coverings of the testicles are—the tunicæ vaginalis, albuginea, and vasculosa.

Tunica Vaginalis.—A closed serous sac originally derived from the peritoneum, surrounding the testicle with two layers;—(**a**) Visceral Layer—closely adherent to testicle proper, to globus major, to external part of body of epididymis, and to lower 1.3 cm. (½ inch) of spermatic cord. Nearly all of the globus minor and inner and back parts of epididymis are uncovered, and here the vascular communications exist between the testis and coverings. (**b**) Parietal Layer—continuous with and reflected from the visceral layer at the posterior and inferior aspects of the testis and at the spermatic cord—adherent to the inner surface of the infundibuliform fascia, to which it is

attached by the prolongation from the subperitoneal areolar tissue—and extends up upon the antero-internal aspect of the cord and below the testis. (c) Cavity of the tunica vaginalis—interval between visceral and parietal layers.

Tunica Albuginea.—The dense, inelastic fibrous covering of the testicle —reflected into the interior of the testicle at its posterior aspect to form an incomplete septum and trabeculæ, the mediastinum testis.

Tunica Vasculosa.—A layer formed by a plexus of vessels running in the areolar tissue. Lines the tunica albuginea and trabeculæ.

Lobuli Testis.—Consist of tubuli seminiferi, resting in the trabecular spaces—forming the glandular structure of the testis.

Arteries.—Spermatic, of abdominal aorta (divides into branches which pierce the tunica albuginea at the back of gland).

Veins.—Spermatic (begin in testis—leave it posteriorly—and ascend cord, forming pampiniform plexus).

Lymphatics.—Follow spermatic vessels and empty into lumbar glands.

Nerves.—From aortic and hypogastric plexuses.

PARACENTESIS TUNICÆ VAGINALIS.

Description.—Penetration of the tunica vaginalis sac with a hollow needle or an exploratory trocar and cannula—for the purpose of withdrawing or injecting fluid. Generally indicated in hydrocele.

Preparation—Position—Landmarks.—As in operating for Hydrocele.

Operation.—The scrotum is grasped posteriorly by the surgeon's left hand in such a way as to render the anterior aspect of the tumor tense. The needle or trocar is so held with the right index near its point as to fix the maximum depth to which it can enter. Thus held, it is thrust sharply into the antero-inferior aspect of the sac, at about the upper limit of its lower third—passing, at first directly backward—and then upward (thus missing the testicle). The fluid having been withdrawn (or injected), the instrument is withdrawn—the opening sealed with sterile collodion and cotton—and the testicle supported by a compressing dressing.

Comment.—The testicle usually lies posterior to a tunica vaginalis filled with hydrocele fluid—but sometimes lies below—and sometimes lies in front.

PARTIAL EXCISION OF THE SCROTUM.

Description.—Removal of the lower portion of the scrotal tissues. Generally resorted to in relaxation and elongation of the scrotum, and as an aid in varicocele.

Preparation.—Scrotum shaved.

Position.—Patient supine, at edge of table. Surgeon on side of involved sac, or on patient's right. Assistant opposite.

Landmarks.—Lower limit of testicle.

Operation.—The testicle is pressed upward toward the external abdominal ring, to be well above the possibility of injury. The lower portion of scrotal tissue is clamped with special forceps, or any pair of long forceps whose blades will close lightly and parallel with each other—so that the lower border of the clamps will be on a level with the line upon which it is desired to remove the scrotal sac. Clamp sufficiently firmly to control hemorrhage. Divide

the scrotal tissues with a knife, cutting along the lower border of the clamps. Unclamp slightly, to reveal the position of bleeding vessels—which are then ligated with gut, that no subsequent bleeding may take place into the loose tissues. While the edges are still held in the clamps, they are sutured together, interruptedly or continuously—after which the clamps are relaxed. No drainage is used. The part is well supported and compressed by the dressing.

OPERATION FOR HYDROCELE

BY INCISION OF TUNICA VAGINALIS—VOLKMANN'S OPERATION.

Description.—The tunica vaginalis is incised vertically in its anterior aspect and stitched to the scrotal skin—its cavity being then packed with gauze and allowed to heal by granulation.

Preparation.—Scrotum shaved. Penis wrapped in gauze and held away from the field of operation.

Position.—Patient supine, at edge of table. Surgeon on side of operation. Assistant opposite.

Landmarks.—Position of the testicle proper.

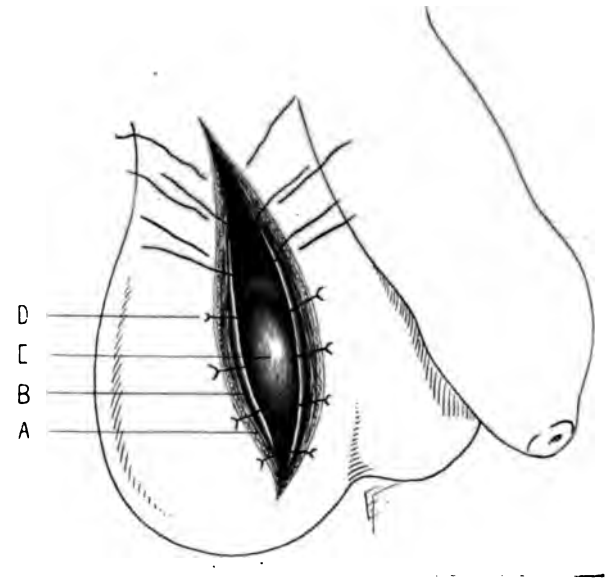

Fig. 539.—Volkmann's Operation for Hydrocele:—A, Lip of scrotal wound; B, Tunica vaginalis, incised; C, Testis; D, Suture passing through tunica vaginalis and entire thickness of lip of scrotal wound.

Incision.—About 5 cm. (2 inches) in length—along the antero-inferior aspect of the tumor.

Operation.—(1) The assistant so grasps the tumor as to render tense and prominent its anterior aspect—and, at the same time, keeps the testicle out of the way of injury. (2) An incision of about 5 cm. (2 inches) in extent is made along the antero-inferior aspect of the tumor—passing through the tissues overlying the tunica vaginalis (skin, dartos, intercolumnar fascia,

cremasteric fascia, and infundibuliform fascia) through the tunica vaginalis and into its cavity. (3) After the escape of the hydrocele fluid the edges of the tunica vaginalis are sutured to the edges of the scrotal skin by from four to eight chromic gut sutures—and the cavity itself, of the tunica vaginalis, is packed with gauze—and heals by granulation, thus obliterating the cavity. The scrotum is well supported and compressed by the dressing. (Fig. 539.)

OPERATION FOR HYDROCELE

BY INCISION, WITH PARTIAL EXCISION OF TUNICA VAGINALIS—VON BERGMANN'S OPERATION.

Description.—Incision of the tunica vaginalis, with removal of its parietal layer, followed by closure of the scrotal wound, with or without drainage.

Preparation—Position—Landmarks—Incision.—As for Volkmann's operation.

Operation.—(1) While the scrotum is held as in Volkmann's operation,

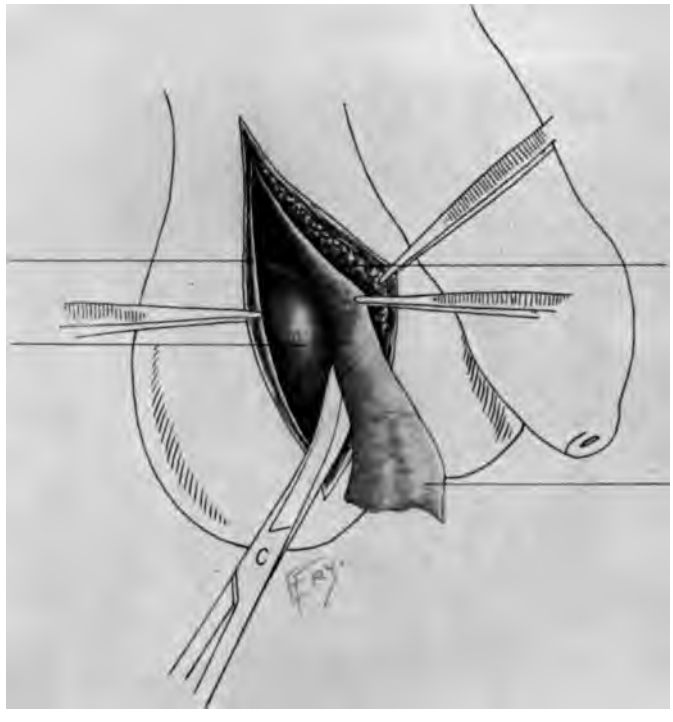

Fig. 540.—Von Bergmann's Operation for Hydrocele:—A, Margin of incised tunica vaginalis; B, Testis; C, Portion of visceral layer of tunica vaginalis being excised with curved scissors, while being drawn upon with forceps; D, Inner aspect of scrotal sac from which tunica vaginalis has been separated.

an incision is made over its antero-external aspect, about 7.5 cm. (3 inches) in length, down to the tunica vaginalis. (2) The tunica vaginalis is then incised in the same line, at first to the extent of about 1.3 cm. (½ inch).

Through this opening the finger is introduced and the cavity of the tunica vaginalis and the position of the testicle examined. (3) The collapsed tunica vaginalis is then incised to the full extent of the external wound with scissors. All bleeding vessels are clamped and tied. (4) The parietal layer of the tunica vaginalis is seized and partly peeled, partly dissected away from the scrotum, by fingers and forceps—nearly up to the epididymis, externally—and nearly up to the testicle internally—along which lines it is cut away with scissors. Bleeding from this step is controlled by pressure, hot douching, and gut-ligature. (Fig. 540.) (5) A drainage-tube is then usually inserted into the cavity and the lips of the scrotal wound closed by suturing up to the drainage-tube. Drainage may be omitted in favorable cases. The scrotum is well supported by the dressing.

ORCHIDECTOMY.

Description.—Orchidectomy, or castration, consists in the incision of the scrotum, followed by excision of the testicle and the structures of the lower part of the cord—and closure of the scrotal wound.

Preparation.—Scrotum and pubis shaved.

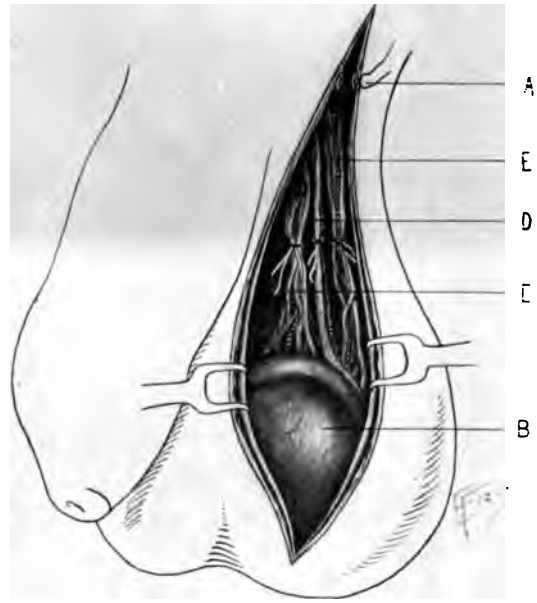

Fig. 541.—ORCHIDECTOMY:—A, Superficial vessel in lip of incised scrotum; B, Testis; C, Spermatic artery and pampiniform plexus of veins, ligated; D, Vas deferens and artery, ligated; E, Cremasteric artery and posterior spermatic veins, ligated.

Position.—Patient supine, near edge of table, with thighs separated. Surgeon to patient's right, in operating upon either side. Assistant opposite

Landmarks.—Testicle; cord; external ring.

Incision.—Vertical incision, from just below the external abdominal ring to the lower end of the scrotum, upon the antero-external aspect of the cord—

the scrotum being held in the palm of the left hand, with the index and thumb extending upward on either side and rendering the parts slightly tense. Where redundant or diseased tissue exists, an elliptical incision may be made—including and removing the redundant or involved tissue.

Operation.—(1) The vertical incision above described is made directly down through the overlying parts (skin, dartos, intercolumnar fascia, cremasteric fascia, infundibuliform fascia) to the cord and tunica vaginalis. (2) By blunt dissection, the testicle, surrounded by the unopened tunica vaginalis, is shelled out of its bed. The structures of the cord are similarly isolated, *en masse*, chiefly by blunt dissection, as high up as necessary—generally about 2.5 cm. (1 inch) below the external abdominal ring. (3) The component structures of the cord (see anatomy of the cord, page 917) are now ligated—which is best done by teasing them apart to the extent of dividing them up into three or four bundles of vessels and ligating each bundle separately with chromic gut, independently of whether composed of arteries, veins, or vas deferens. This is better than to include the entire mass in one or even in two ligatures, and is, practically, as satisfactory as attempting to recognize and tie the vessels separately. (Fig. 541.) (4) All bleeding vessels are controlled by clamping or ligation with gut—and are, usually, the superior external pudic, inferior external pudic, superficial perineal, and artery of the septum scroti. (5) The scrotal wound is then put upon a slight stretch and sutured throughout, so approximating the edges as to prevent in-turning—using interrupted sutures of chromic gut or silkworm-gut. If indicated, temporary drainage may be used in the lower part of the scrotal wound. The scrotum is well supported by dressing.

Comment.—(1) The tunica vaginalis is frequently opened before removing the testicle, for the purpose of examination. (2) In other cases the testicle and visceral layer are cut away from the parietal layer of the tunica vaginalis and removed, leaving the latter. (3) The cord may first be clamped and cut—and the vessels tied later. (4) If the arteries can be recognized and separately tied, it is somewhat more surgical.

IV. THE SPERMATIC CORD.

SURGICAL ANATOMY.

Structures of Cord.—Consist of the vas deferens (which begins in the globus minor of the epididymis), arteries, veins, lymphatics, nerves, processus vaginalis, and internal cremaster of Henle—all connected by areolar tissue and surrounded by the fasciæ which descend, together with the testes, from the internal abdominal rings, through the inguinal canals, into the scrotum to the summit of the testes.

Arteries of the Cord.—Spermatic, of abdominal aorta—lying anterior to vas deferens and surrounded by pampiniform plexus of veins; artery of vas deferens, of superior or inferior vesical—accompanying vas deferens upon its lateral aspect; cremasteric artery, of deep epigastric—lying superficially and upon the external aspect.

Veins.—Most of the spermatic veins pass through the inguinal canal and empty into the inferior vena cava on the right—and into the renal vein on the left. They may be divided into three sets;—(1) Anterior Set—much larger, form pampiniform plexus, accompany the spermatic artery and ascend the cord anterior to the vas;—(2) Posterior Set—much smaller, surround the vas

deferens and accompany the artery of the vas;—(3) Some independent veins.

Lymphatics.—Empty into the Lumbar Glands.

Nerves.—From the spermatic and pelvic plexuses.

Vas Deferens.—Lying posteriorly and recognized by its cordlike feeling.

Processus Vaginalis.—Remnant of obliterated tube of communication between tunica vaginalis and peritoneum.

Internal Cremaster of Henle.—Scattered bundles of muscle-fibers.

Fatty Areolar Tissue.—Connecting constituent structures of cord.

Epididymes.—Formed by vasa efferentia—which pierce the tunica albuginea and, becoming convoluted into the coni vasculosi, form the globus major, at the upper, inner aspect of the testicle. The vasa efferentia thus unite to form the body of the epididymis, along the inner aspect of the testicle—ending below in the globus minor, at the lower inner aspect of the testicle—which terminates in the vas deferens.

Vasa Deferentia.—Continuation of the epididymes—extending from the globus minor to the prostatic urethra. Ascends on the inner side of the epididymis and back of the testis—passing vertically up the cord, posterior to the spermatic vessels—enters the external abdominal ring—runs through the inguinal canal—emerging from the internal abdominal ring, it passes around the outer side of the origin of the deep epigastric artery and runs downward and inward, crossing the external iliac vessels into the pelvis to the side of the bladder, running under the peritoneum—thence curves backward and downward to the postero-lateral surface of the bladder—crossing over the cord of the obliterated hypogastric artery, and lying internal to the ureter, passing between the ureter and bladder—thence it ceases to be covered by peritoneum, running forward to the base of the prostate, lying between the bladder and rectum and attached to the former (bladder)—being placed internal to the vesiculæ seminales. Near the base of the prostate, each vas enlarges somewhat (ampulla) and joins the duct of the corresponding seminal vesicle, to form the ejaculatory duct of that side—the ejaculatory duct opening into the sinus pocularis of the prostatic portion of the urethra. After the vas ceases to be subperitoneal, it is invested by recto-vesical fascia and a prolongation of the subperitoneal tissue. The efferent ducts consist of cellular, muscular, and mucous coats. Its artery is the artery of the vas deferens, a branch of the superior vesical of the internal iliac. Its lymphatics end in the iliac glands. The angle of approximation of the ejaculatory ducts lies immediately above the prostate. For the anatomy of the ejaculatory ducts, see the vesiculæ seminales.

INSTRUMENTS.

See those mentioned under the urethra and penis.

PARTIAL VASECTOMY.

Description.—A division of the vas deferens, with a limited excision of its trunk. Sometimes resorted to in cases of hypertrophy of the prostate gland.

Preparation—Position—Landmarks.—As in operating for varicocele.

Incision.—In the course of the spermatic cord, beginning just below the external abdominal ring and extending downward for about 4 cm. (1½ inches).

Operation.—Incise skin and fascia—clamp and ligate superficial vessels. Expose the spermatic cord just below the external abdominal ring—locate the

vas—and isolate it from the accompanying structures. Place two gut ligatures upon it, about 2 cm. (¾ inch) apart, and excise about 1.3 cm. (½ inch) of its length. Close the wound with gut or silkworm-gut.

OPERATION FOR THE RADICAL CURE OF VARICOCELE.

BENNETT'S MODIFICATION OF HOWSE'S OPERATION.

Description.—Consists in an incision of the scrotum and cord, with a partial excision of the pampiniform plexus of veins (which is the set chiefly involved in varicocele)—followed by suturing of the proximal and distal ends of the severed plexus together.

Preparation.—Pubis and scrotum shaved.

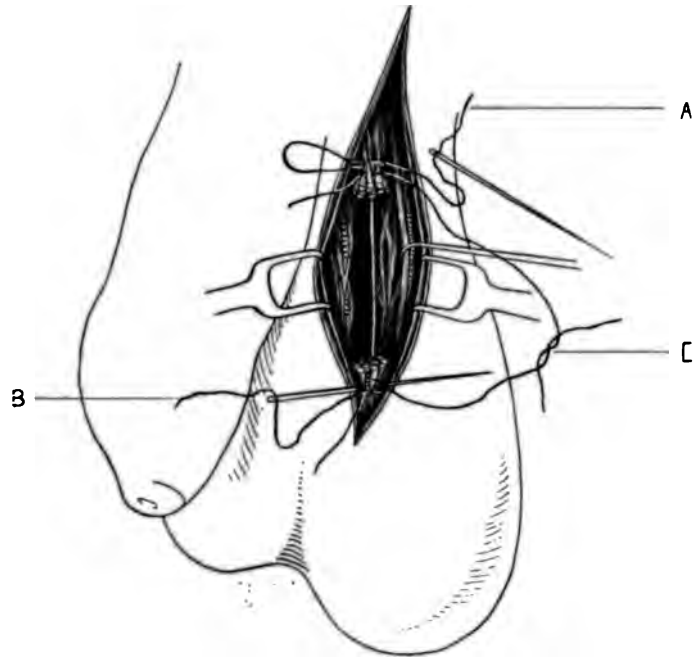

Fig. 542.—BENNETT'S MODIFICATION OF HOWSE'S OPERATION FOR VARICOCELE.—Between retracted lips of scrotal wound are seen two stumps left by excision of bulk of scrotal veins. A, One end of upper ligature being threaded through upper stump laterally; B, Same of lower stump and ligature. The long limbs of this ligature are tied together—and the short limbs together. C, Suture carried through the stumps antero-posteriorly and tied. The stumps are approximated by tightening the sutures.

Position.—Patient supine, at edge of table. Surgeon on side of operation. Assistant opposite.

Landmarks.—Site of varicose tumor. Position of testicle and cord. External abdominal ring.

Incision.—Longitudinal incision, about 4 to 5 cm. (1½ to 2 inches) in length, made over the structures of the cord, with its center over the site of the greatest varicosity.

Operation.—(1) As soon as the incision is made through skin and fascia, the bleeding vessels are clamped and tied—and two silk retraction-loops are put into the lips of the wounds and these lips well retracted—thus exposing the structures of the cord. (2) The vas deferens is the first structure of the cord to be identified—and this is done for the purpose of henceforth avoiding injuring it. This structure and its artery, and the posterior set of veins accompanying it, are kept as much out of the field as possible. (3) The pampiniform plexus of veins, together with the surrounding fascia especially preserved and unopened, are isolated from the more important structures and are freed for about 4 to 5 cm. (1½ to 2 inches), according to the size of the varicocele, by blunt dissection. (4) Strong chromic gut ligature is carried, up on an aneurism-needle, around the lower portion of the freed part of this plexus of veins and tied tightly, both ends being left long. The same is then done at the upper portion of the freed part—the ligatures being about 4 cm. (1½ inches) apart. About 2.5 cm. (1 inch) in extent of this venous plexus is now removed with scissors, which cut about 6 mm. (¼ inch) from each ligature. (5) One of the free ends of each ligature is now threaded and carried through its own end, so as to come out opposite the knot. The two ends which were threaded are then tied together. The other two ends are similarly treated and tied. The free ends of the venous plexuses left by the excision are thus approximated, together with their sheaths of surrounding fascia—thus shortening the cord and partially, perhaps, taking the weight of the lower part of the cord from the scrotum. (6) The wound is then gut-ligatured throughout (Fig. 542).

Comment.—(1) As much in length of the plexus may be removed as considered necessary in the special case. (2) Isolation of the veins to be ligated is aided by passing a director above, and one below, between the veins to come away and the structures to remain—and then separate the parts upward and downward in this line. (3) Especially avoid opening the fascial sheath surrounding the veins of the pampiniform plexus to come away—as they are much more readily manipulated when intact. (4) Avoid cutting the cremaster muscle. (5) Avoid removing an excess of vascular structures—for fear of damaging the blood-supply of the part too greatly.

V. THE VESICULÆ SEMINALES AND EJACULATORY DUCTS.

SURGICAL ANATOMY.

(A) Vesiculæ Seminales.

Description.—Two diverticular, membranous, seminal reservoirs placed between the bladder and the rectum—lying external to the ampullæ of the vasa deferentia—their upper extremities being subperitoneal. They average, in length, about 6.3 cm. (2½ inches)—breadth, about 1 cm. ($\frac{7}{16}$ inch)—thickness, about 6 mm. (¼ inch).

Relations.—**Superiorly**; base of bladder, from near entrance of ureters to base of prostate gland. **Inferiorly**; rectum, with the recto-vesical fascia intervening. **Anteriorly**; converging, unite with vasa deferentia (which lie to their inner side) to form the ejaculatory ducts. **Posteriorly**; the free ends diverge, overlapping the ureters, which pass between the vesiculæ seminales and the bladder. The recto-vesical pouch of peritoneum covers the upper part of the posterior aspect of the seminal vesicles.

(B) EJACULATORY DUCTS.

Description.—Formed by union of vasa deferentia and vesiculæ seminales of each side. They are about 2 cm. (¾ inch) in length. Beginning at base of prostate, they pass forward and downward between the middle and lateral lobes—perforate the prostatic fissure—and empty at or within the margins of the sinus pocularis, in the prostatic portion of the urethra. Its coats are fibrous, muscular, and mucous.

Arteries of Vesiculæ Seminales and Ejaculatory Ducts.—Artery of vas deferens, of superior vesical branch of internal iliac; inferior vesical, of internal iliac; middle hemorrhoidal, of internal iliac; middle vesical, of internal iliac.

Veins.—Accompany arteries.

Lymphatics.—End in pelvic glands.

Nerves.—From hypogastric plexus.

INSTRUMENTS.

See those used in operating upon the bladder.

TOTAL EXCISION OF VESICULÆ SEMINALES AND PART OF EJACULATORY DUCTS

BY SUPRAPUBIC RETROCYSTIC EXTRAPERITONEAL ROUTE—YOUNG'S OPERATION

Description.—The total excision of the seminal vesicles (Spermatocystectomy) and the partial excision of the ejaculatory ducts, by a suprapubic T-shaped incision. The posterior aspect of the bladder is exposed by a median suprapubic incision, with the addition of a transverse incision at its upper end. Through this incision, which does not pass into the peritoneal cavity, the peritoneum is peeled away from the posterior wall of the bladder, until the vesiculæ seminales are exposed. The seminal vesicles are then removed—and the ejaculatory ducts are traced to the internal abdominal rings and also removed at this point.

Preparation.—Bowels emptied. Bladder partly filled. Pubic and suprapubic regions shaved.

Position.—Patient in Trendelenburg position. Surgeon to patient's left. Assistant opposite.

Landmarks.—Symphysis pubis; median line; known relations of the parts.

Incision.—T-shaped. The median suprapubic incision is made from just above the umbilicus to the symphysis pubis. The transverse incision, about 7.5 cm. (3 inches) in length, extends across the upper end of the vertical incision, just above the umbilicus and in the linea transversa. The median incision passes between the recti muscles—and the transverse incision divides them as far as it extends.

Operation.—(1) The median incision is carried down in the median line just as in median abdominal section—passing through the fascia posterior to the recti—down to but not through the peritoneum. (2) The peritoneum, having been exposed, is carefully separated from the posterior wall of the bladder in the median line—keeping comparatively near the median line, to avoid severing many of the nutrient vessels of the bladder by separating the peritoneum too far laterally. Upward traction of the posterior bladder-wall—while, at the same time, pressing backward the rectum—aids the separation of the peritoneum from the back of the bladder. (3) The vasa deferentia are thus

exposed and freed from the bladder by blunt dissection—during which the vesiculæ seminales are encountered, lying slightly to the outer side, and are similarly freed. (4) Both vesiculæ seminales and vasa deferentia are divided by blunt dissection close to the upper border of the prostate gland. The vasa deferentia are then traced on outward over the lateral aspects of the bladder to the internal abdominal rings—and there ligated and divided. (5) In concluding the operation, the transversely divided recti are repaired with chromic gut. The longitudinal wound is sutured as in abdominal section—leaving the lower portion open—through which a temporary gauze drainage is usually conducted.

Comment.—(1) Hemorrhage is controlled by gut-ligaturing and gauze-packing. (2) Briefly summarizing the operation, the steps are:—Separation of peritoneum from base of bladder—Separation of rectum from base of bladder—Excision of vesiculæ seminales and of the vasa deferentia as far out as the internal abdominal rings. (3) Guard the ureters by adhering to the area as near the middle line as possible. They are made easier of detection by upward traction upon the bladder. (4) A sound introduced into the bladder during the progress of the operation will often be of aid. (5) The incision may pass through the upper half of the prostate and a portion of the prostate be thus removed, attached to the seminal vesicles—which is accomplished by an incision beginning at the upper part of the prostate, anterior to its junction with the vesiculæ seminales, and passing obliquely posterior to the urethra and terminating about the center of the posterior aspect of the prostate. (6) The seminal vesicles may be exposed by a transverse perineal incision—and also by the sacral route, as in the operations for excision of the rectum.

VI. THE PROSTATE GLAND.

SURGICAL ANATOMY.

Description.—A fibro-muscular glandular body in front of the neck of the bladder and surrounding the beginning of the urethra, placed posteriorly and inferiorly to the symphysis pubis and posteriorly to the triangular ligament, and resting upon the rectum. Its measurements are the following:—transversely at base, about 4 cm. (1½ inches); antero-posteriorly, about 2.5 cm. (1 inch); depth, about 2 cm. (¾ inch). The prostatic urethra pierces the gland generally one-third nearer the posterior than the anterior aspects,—though it sometimes passes nearer the anterior aspect,—and sometimes only the inferior three-fourths of the urethra is surrounded by the prostate. The ejaculatory ducts pierce the gland obliquely forward between the middle and lateral lobes, opening into the prostatic portion of the urethra. The glands of the prostate open into the prostatic sinuses. The prostatic sinuses lie upon either side of the verumontanum, in the prostatic part of the urethra.

Capsule of Prostate Gland.—Firm, thin, fibrous membrane derived from the recto-vesical portion of the pelvic fascia—separated from the superior layer of the deep perineal fascia by a plexus of veins.

Divisions of Prostate Gland.—(1) Two Lateral Lobes—deeply notched posteriorly and slightly furrowed anteriorly. (2) Middle Lobe—a small, irregularly shaped prominence upon the posterior aspect of the gland, between the two lateral lobes, lying above the sinus pocularis and between the ejaculatory ducts—and placed directly under the neck of the bladder, posterior to beginning of urethra.

Fixations.—Held in place by the anterior or pubo-prostatic ligaments of bladder; by the superior layer of the triangular ligament; and by the anterior part of the levatores ani.

Base of Prostate.—Directed upward and backward. Lies somewhat above level of center of symphysis pubis, resting upon and connected with neck of bladder.

Apex.—Directed downward and forward, resting upon superior layer of triangular ligament. Lies about 1.3 cm. (½ inch) behind and slightly inferior to the subpubic angle. By rectal examination, about 3 cm. (1¼ inches) above the edge of the anus.

Anterior Surface.—Convex. Lies about 2 cm. (¾ inch) posterior to lower aspect of symphysis. Covered by prostatic plexus of veins, by pubo-prostatic ligaments, and by vesico-pubic muscle.

Posterior Surface.—Flattened. Rests upon anterior aspect of rectum, some dense connective tissue and muscular fibers intervening.

Lateral Surfaces.—In relation with superior surfaces of levatores ani and the lateral portions of the venous plexuses. Extend upward as two indistinctly defined lobes.

Arteries.—Branches of inferior (and probably middle) vesical, from anterior trunk of internal iliac; branches of hemorrhoidal arteries; branches of internal pudic.

Veins.—Receive dorsal vein of penis and form plexuses about anterior and part of lateral aspects of gland—and empty into branches of internal iliac vein.

Lymphatics.—End in pelvic glands.

Nerves.—Form hypogastric plexus.

INSTRUMENTS.

See those used in operating upon the Bladder.

PROSTATOTOMY.

Description.—Incision of prostate gland. Indicated in abscess—and sometimes resorted to for division of the prostatic bar or collar at neck of bladder.

Operation.—While the prostate gland may be exposed by a median perineal incision, as in Cock's operation for perineal section, a more complete and satisfactory exposure may be obtained by the transversely curved perineal incision described under proctatectomy. For the exposure of the prostate by either of these incisions, therefore, see pages 910 and 925.

PROSTATECTOMY, IN GENERAL.

Description.—Consists in the removal of part or the entire prostate gland. Indicated chiefly in marked hypertrophy of the prostate. Prostatectomy may be complete or partial—dependent upon the amount of gland removed.

Varieties of Prostatectomy.—(1) Suprapubic—applicable to smaller growths, and especially applicable to enlargement of the middle lobe alone, or to enlargement of middle lobe together with the intravesical part of the lateral lobes. (2) Perineal Prostatectomy—applicable to larger involvements, and especially of the lateral lobes and to sub-urethral growths. Affords excellent

drainage. (3) Combined Suprapubic and Perineal Prostatectomy—giving freest access to largest growths. This method is probably the best. Even if the perineal operation be done immediately after, a suprapubic cystotomy enables the vesical aspect of the prostate to be thoroughly examined.

SUPRAPUBIC PROSTATECTOMY

BY MEDIAN VERTICAL INCISION.

Description.—Consists in the removal of the prostate gland through a median suprapubic incision. This operation is frequently only a partial prostatectomy, consisting in the removal of the median lobe of the prostate and the intravesical parts of the lateral lobes.

Preparation—Position—Landmarks—Incision.—As for suprapubic cystotomy (page 880).

Operation.—(1) Having irrigated the bladder, and partly filled the rectal bag with fluid (which should not be more than six or eight ounces if the prostate be large and hard), the operation is conducted precisely as in suprapubic cystotomy, up to the opening of the bladder, control of hemorrhage, and retraction of the lips of the bladder-wound with silk traction-loops. (2) This much having been accomplished, the condition of the prostate and urethral opening are carefully examined with the finger—using great care in all manipulations not to detach the bladder from its connective-tissue plane. (3) Enucleation of the enlarged prostate accessible from the bladder is now accomplished by fingers, blunt dissector, curved blunt scissors, a curette, and forceps (the instruments all having long handles). The mucous membrane overlying the hypertrophied middle lobe is incised vertically with scissors—and the enlarged growth is shelled out of its bed. The mucous membrane should be divided, as nearly as possible, in the median line, to allow of subsequent suturing, where feasible, though suturing is not absolutely necessary. Often pedunculated parts are simply cut away at their pedicles. Where a collar-like bar of hypertrophied gland around the beginning of the urethra is encountered, it is divided by inserting a blade of the scissors into the urethra and severing it by closure of the blades (if special scissors with serrated edges be used, hemorrhage will be less)—the forefinger is then inserted into the wound thus made—and, while an assistant pushes the prostate upward into the bladder by counter-pressure from the perineum, the surgeon continues the process of enucleation, removing as much of the lateral lobes as possible, in mass or in piecemeal—and as much of the sub-urethral prostate as can be reached and removed by sweeping the finger around the urethra and enucleating from between the urethral wall and capsule of the gland. (4) At the end of the operation, the edges of the mucous membrane should be sutured with catgut, if possible. If inaccessible, or too much torn up, they may be dropped into place without suturing. Patency of the urethra should be ascertained by the passage of a sound through the meatus and by digital examination of the prostatic urethra. (5) A large drainage-tube is inserted into the bladder through the suprapubic wound—around which the edges of the abdominal wound are closed as in suprapubic cystotomy.

Comment.—(1) The Trendelenburg position is convenient after opening the bladder. (2) Intravesical hemorrhage is controlled by hot douching and gauze pressure. In some cases excessive hemorrhage may necessitate the packing of the bladder with gauze. (3) The operation should be planned so as to secure a level, low floor at the bladder opening of the prostatic urethra.

(4) Some operators make a counter-opening in the perineum after the operation—which should be resorted to if much damage have been done—and both perineal and suprapubic drainage be used.

PERINEAL PROSTATECTOMY

BY TRANSVERSE CURVED INCISION.

Description.—The prostate is exposed by a transversely curved incision—the capsule of the gland being divided transversely and the gland tissue enucleated with the finger.

Preparation—Position.—As for perineal cystotomy (page 883).

Landmarks.—Ischial tuberosities; subpubic arch.

Incision.—Extends from one ischial tuberosity to the opposite, curving convexly forward toward the inferior margin of the subpubic arch (Fig. 543, A).

Operation.—(1) Incise the skin and superficial fascia—divide the ischiorectal fatty areolar tissue in the line of incision, passing down to the levatores ani. (2) Retract forward the superficial perineal vessels and nerves, the artery and nerve to the bulb, and the transversus perinæi muscle—and retract backward the inferior hemorrhoidal vessels and nerves—clamping and tying bleeding vessels. (3) Recognize the bulb and central tendinous point of the

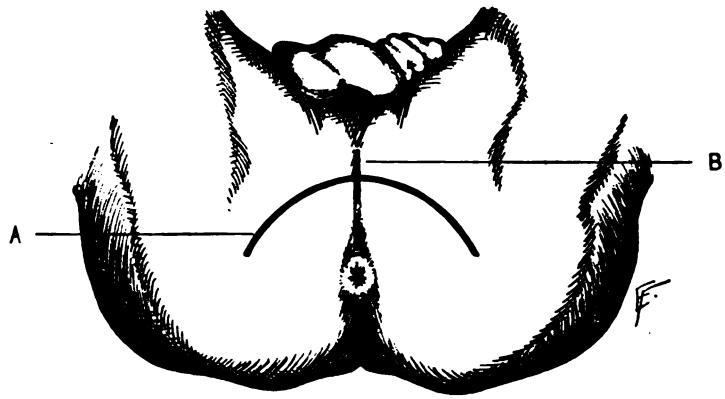

Fig. 543.—PERINEAL ROUTES FOR EXPOSING PROSTATE GLAND:—A, Transverse curved incision; B, Median perineal incision.

perineum (from which latter the transverse perineal muscles extend outward), all exposed in the wound. Divide transversely the external sphincter just posterior to its junction with the accelerator urinæ at the central tendinous point. Retract the bulb, transverse perineal muscles, and central tendinous point all forward. (4) Incise more deeply still along the transverse curved incision—and expose the compressor urethræ muscle, surrounding the membranous urethra from the prostate behind, to the bulbous urethra in front. Above the compressor urethræ lies the inferior aspect of the prostate gland, surrounded by dense connective tissue continuous with the pelvic fascia and forming a portion of the capsule of the gland. (5) Draw this fascia downward and the rectum backward, and incise the capsule of the prostate transversely, thereby exposing the posterior surface of the prostate gland. (6) The index-finger is then inserted through the incised capsule and the process of enucleation

of the gland substance from below upward to its upper border is accomplished in the same general manner as in Alexander's operation (paragraph 6, page 926). (7) The vasa deferentia lie a little deeper—and the vesiculæ seminales lie just to the outer sides of the vasa deferentia—both of which structures may be exposed and removed by this incision. (8) The prostate having been enucleated, a sound is passed through the entire urethra from the meatus—and especially the condition of the prostatic urethra examined. The urethra is not opened up, supposedly, by the perineal manipulations. (9) Drainage through the perineal wound is established—the lateral extensions of the wound being sutured from either end toward the median line.

PROSTATECTOMY BY THE COMBINED METHOD

BY MEDIAN SUPRAPUBIC AND MEDIAN PERINEAL INCISIONS—ALEXANDER'S OPERATION.

Description.—The prostate is first exposed through a regular suprapubic incision, for the purpose of examining the gland and to enable downward displacement of the prostate during the perineal operation—and the gland is then removed, as far as required, through the median perineal incision. The objects of the operation are to remove the obstructing portions of the prostate with the minimum damage to the bladder and urethra, and to furnish good drainage. The special method of Alexander involves the following anatomical features emphasized by its author (whose writing is largely followed in the subsequent description):—(a) The prostatic urethra consists of two parts;—(1) Vesical portion—which lies above the openings of the seminal ducts into the prostatic urethra; and which has thicker, stronger walls, permitting the freeing of the prostate without damage to the urethral mucous membrane. (2) Urethral portion—which lies below the openings of the seminal ducts into the prostatic urethra; and which has thinner, weaker walls, largely supported by prostatic tissue. (b) Fibrous trabeculæ extend from the central fibrous part of the prostate, behind the urethra, laterally outward to the fibrous capsule—dividing the lateral lobes into anterior and posterior parts by forming cleavage lines between them. (1) Anterior portion—placed in front of the fibrous trabeculæ, at the side of the urethra—which are the only parts of the lateral lobes whose hypertrophy causes interference with urination. (2) Posterior, or inferior, portion—placed posterior to the fibrous trabeculæ, posterior and inferior to the urethra and seminal ducts—the hypertrophy of which does not cause interference with urination. (c) Summary—the anterior portions of the lateral lobes, whose hypertrophy causes urinary obstruction, may, therefore, be enucleated *en masse*, without injury to the posterior portions or to the capsule.

Preparation.—Bowels emptied. Bladder irrigated and then distended with 8 or 10 ounces. Pubic and perineal regions shaved.

Position.—Patient as for suprapubic cystotomy, during the opening of the bladder—and in the lithotomy position during the perineal incision. Surgeon to patient's left at first—and then seated opposite the perineum. Assistant at first opposite surgeon and then to his right.

Landmarks.—Those for suprapubic cystotomy (page 880) and for median perineal cystotomy (page 886).

Incisions.—Same as for median suprapubic cystotomy (page 880) and for median perineal section (page 910). (Fig. 543, B.)

Operation.—(1) A median suprapubic cystotomy is done—making an

opening into the bladder large enough to insert the index-finger. The lips of the bladder wound are temporarily sutured to the lips of the abdominal wound, by one or two stitches on each side. The intravesical portion of the prostate is examined. The bladder wound is then protected with gauze. (2) A fairly large, centrally grooved sound is then passed into the bladder from the meatus of the penis—and steadily held in the middle line by an assistant. (3) The median perineal section is made just as in Syme's operation (page 907)—exposing the membranous urethra. Its floor is divided upon the grooved sound, from just posterior to the bulb in front, to the apex of the prostate gland behind. (4) As the sound is being withdrawn, the finger is passed into the bladder through the prostatic urethra, which is dilated by the finger. (5) The left index is introduced through the suprapubic wound into the bladder—and presses the prostate firmly toward the perineum, to bring it as fully into the perineal wound as possible. (6) The right index passes through the perineal wound into the prostatic urethra and begins the enucleation of the prostatic gland tissue—beginning by feeling along the lateral aspect of the prostatic urethra for the prominence caused by the inward bulging of the enlarged lateral lobe. The mucous membrane is broken through by the finger just in front of this eminence caused by the intrusion of the lateral lobe. The finger then works its way along the cleavage line of the fibrous trabeculæ, between the anterior and posterior parts of the lateral lobe. The obstructing part of the lateral lobe is separated with comparative ease laterally and posteriorly from the posterior portion of the gland and capsule. The obstructing mass is then separated from the mucous membrane at the neck of the bladder and from the superior part of the prostatic urethra—aided by being grasped with forceps and drawn toward the perineal wound—while the left index in the bladder aids in guarding the mucous membrane against being torn. (7) The procedure just described upon one lateral lobe is repeated upon the other lateral lobe, if indicated. (8) If an enlarged "middle lobe" exist, it is pressed down, by the finger in the bladder, into the perineal wound, into the area formerly occupied by the enucleated lateral lobes, when it is also enucleated in the same way from beneath the mucous membrane and without further injury to the mucous membrane—by sweeping the finger around through the space left by enucleating the lateral lobes. Thus the only part of the urethra which is torn during the operation is that portion just anterior to the opening of the seminal ducts. And no injury is done to the bladder or urethral mucous membrane except that done to the mucous membrane of the prostatic urethra above the openings of the vesiculæ seminales. (9) Hemorrhage is controlled by hot water and gauze pressure. The bladder and perineal wounds are irrigated with hot salt solution. A stout rubber catheter is passed into the bladder through the perineal wound—and another rubber drainage-tube is inserted into the bladder through the suprapubic wound. The suprapubic bladder wound is sutured about the tube by Gibson's method (page 892)—similar, in principle, to Kader's gastrostomy method. The perineal wound is partly closed by suture. The bladder is irrigated daily. The suprapubic tube is generally removed in four days and the perineal in seven—complete healing of both wounds being expected in about five weeks.

Comment.—(1) The perineal hemorrhage may require temporary gauze packing. (2) Guard against injury to the rectum, especially during work near the anterior portion of the prostatic urethra. (3) In conjunction with the regular suprapubic cystotomy, some surgeons make the transverse curved perineal incision. The prostate is exposed through the suprapubic bladder wound and depressed through the bladder into the perineum. The capsule of

the gland is then divided transversely through the perineal wound and enucleated by this route.

NOTE.

Other operations upon the Penis, Urethra, Scrotum, Testes, Spermatic Cord, Vesiculæ Seminales, Ejaculatory Ducts, and Prostate—as well as the operations upon the Epididymis, Vasa Deferentia, and Cowper's Glands—belonging more particularly to special Genito-Urinary Surgery, will not be considered here.

THE NEW YORK LIBRARY. ACADEMY OF MEDICINE.

CHAPTER VII.

OPERATIONS UPON THE FEMALE GENITAL ORGANS.

I. THE UTERUS.

SURGICAL ANATOMY.

(1) Uterus.

Description.—Situated in pelvic cavity, between bladder and rectum, supported by its ligaments—its cervix projecting into superior part of vagina, downward and backward—and its base upward and forward. Communicates with fallopian tubes and vagina. Consists of serous, muscular, and mucous coats. Length, about 7.5 cm. (3 inches)—breadth, about 5 cm. (2 inches)—thickness, about 2.5 cm. (1 inch). Its divisions are—fundus, body, cervix, uterine cavity, internal and external os, and openings of fallopian tubes.

Relations of Fundus and Body.—Anteriorly; covered by peritoneum and separated from posterior aspect of bladder by utero-vesical peritoneal pouch (generally occupied by coils of intestine). **Posteriorly;** covered by peritoneum and separated from anterior aspect of rectum by recto-uterine pouch of peritoneum (in which are generally some coils of intestines). **Laterally;** broad ligaments; fallopian tubes (above); round ligament (below); ligaments of ovaries (behind). **Superiorly;** covered by peritoneum.

Relations of Cervix Uteri.—(1) Intravaginal Portion;—surrounded by vagina, which extends higher posteriorly than anteriorly—and presents opening of os externum. (2) Supravaginal Portion;—one-half of entire cervix is supravaginal posteriorly, and two-thirds anteriorly. Presents opening of internal os. The relations of supravaginal portion are the following:—**Anteriorly;** bladder (areolar tissue intervening). **Posteriorly;** peritoneum of Douglas's pouch. **Laterally;** broad ligament; uterine vessels; ureters (which are about 1.3 cm., or ½ inch, away). (3) Vaginal Portion; zone of vaginal attachment—oblique—higher posteriorly than anteriorly.

Relations of Peritoneum.—Invests whole of posterior aspect of uterus, but only upper three-fourths of anterior aspect.

Ligaments.—Three pairs peritoneal—four pairs muscular (three of latter lying between folds of broad ligament and one between folds of posterior ligament). **Two Lateral or Broad Ligaments** (peritoneal):—duplication of peritoneum extending transversely outward from sides of uterus and vagina to sides of pelvis—the two peritoneal layers being continuous above at free border, but diverging below and laterally, and including various structures between their folds (v. Broad Ligament, page 930). **Two Anterior, or Vesico-uterine** (peritoneal):—reflected from top of bladder to anterior wall of uterus, at junction of supravaginal cervix. **Two Posterior, or Recto-uterine** (peritoneal):—peritoneal folds reflected backward from intraperitoneal part of cervix and vagina, on to second part of rectum—forming lateral boundaries of Douglas's pouch. **Two Utero-sacral** (muscular):—muscular bands lying

between folds of the posterior or recto-uterine ligaments. Extend from second and third pieces of sacrum forward and downward to sides of uterus at junction of body and supravaginal cervix (opposite os internum), crossing the sides of the rectum opposite the junction of its first and second parts. **Two Utero-pelvic Ligaments** (muscular):—muscular expansions, extending between folds of broad ligaments, from fascia over obturator internus muscles to sides of uterus and vagina, surrounding the utero-vaginal vessels and nerves. **Two Utero-ovarian Ligaments (Ligaments of the Ovaries)** (muscular):—prolongations of uterine muscular fibers in the form of round cords, extending between folds of broad ligaments, from upper angles of uterus to inner aspects of ovaries. **Two Round or Utero-inguinal Ligaments** (muscular):—fibro-muscular cords, 10 to 12.5 cm. (4 to 5 inches) long, placed between folds of broad ligaments, extending from superior angles of uterus through inguinal canals to labia majora (v. Round Ligaments, page 931).

Arteries.—Ovarian, of abdominal aorta—carried into broad ligament by infundibulo-pelvic ligament—divides into tubal artery and ovarian artery proper. Uterine, of internal iliac—runs downward along pelvic wall to base of broad ligament—thence inward near floor of pelvis toward cervix, which it reaches at junction of vagina, passing in front of ureter—and runs up side of cervix and uterus between folds of broad ligament, communicating with opposite uterine and branches of ovarian.

Veins.—Correspond with arteries. Veins from ovarian plexuses empty—right, into inferior vena cava—left, into left renal. Veins from uterine plexuses empty into internal iliac veins.

Lymphatics.—Those from body empty into lumbar glands—and those from cervix into pelvic glands.

Nerves.—From third and fourth sacral—and from hypogastric and renal plexuses.

(2) Broad Ligament.*

Description.—Duplicature of peritoneum, extending transversely from sides of uterus and vagina outward to sides of pelvic wall—the two layers being continuous superiorly at their free border—and diverging laterally and inferiorly to envelop various structures (v. i.).

Relations.—Superior or free Border (mesosalpinx):—summit of duplicature, where it envelops fallopian tube. Extends from side of uterus toward pelvic wall, to beyond the fimbriated extremity of fallopian tube. Infundibulo-pelvic ligament—that portion of superior border of broad ligament between fimbriated extremity of fallopian tube and lower attachment of broad ligament—a concave, rounded border—the ovarian vessels being conveyed in this ligament. **Inferior Border**:—attached to levator ani muscle and recto-vesical fascia. Ureters, vessels, and nerves pass through the subperitoneal areolar tissue between its layers. **Internal Border**:—attached to lateral walls of uterus and vagina. Utero-vaginal vessels and muscular bands pass between the two laminæ. **External Border**:—In contact with obturator fascia. Transmits uterine vessels and round ligament.

Structures between Two Layers of Broad Ligament.—Ovary—projects from posterior lamina. Ligament of ovary—from angle of uterus to lower or internal aspect of ovary. Fallopian tube—in upper free margin. Round ligament—forms a ridge beneath anterior lamina, on its way to inguinal canal. Parovarium (fetal relic)—between ovary and outer part fallopian tube. Duct of Gaertner; hydatid of Morgagni; small cysts—all fetal relics. Uterine,

* Here described because involved in Hysterectomy.

ovarian, and funicular vessels; lymphatics; and uterine plexus of nerves. Subperitoneal fatty areolar tissue. Involuntary muscular fibers—from obturator fascia to sides of uterus and vagina.

Broad ligament divides pelvic cavity into:—Anterior part—containing bladder, urethra, and vagina;—Posterior part—containing rectum.

Boundaries of Douglas's Recto-uterine Pouch.—Anteriorly; posterior wall of uterus, supravaginal cervix, upper fourth of vagina. Posteriorly; rectum, sacrum. Laterally; sacro-uterine ligaments. Superiorly; small intestines.

(3) Round Ligaments.*

Description.—Two flat, cord-like bundles of muscular, fibrous, and areolar tissue, vessels and nerves, continuous with uterine fibers, attached to superior angles of uterus just below and in front of fallopian tube—each passes upward, outward, and forward between layers of broad ligaments to pelvic wall, raising the anterior layer of broad ligament into a fold—curves around deep epigastric artery on inner side of external iliac artery—enters internal abdominal ring—passes through inguinal canal—emerges from external ring—its fibers then becoming lost in tissues of labia majora and mons veneris. May be accompanied by an invagination of peritoneum, the canal of Nuck (analogous to pouch of peritoneum accompanying descent of testes), which may remain patulous. Receives fibers in transit through inguinal canal—and gives off few fibers to pillars of ring. Average length—10 to 12.5 cm. (4 to 5 inches). Supplied by funicular branch of superior vesical of internal iliac.

(4) Vagina.

Note.—Vagina is here described in connection with Vaginal Hysterectomy.

Description.—Extends from orifice below through an opening in triangular ligament, to neck of uterus above—completely surrounding the cervix. Extends upward much further beyond posterior lip of uterus (about 2 cm., or ¾ inch) than beyond anterior lip. Length of anterior wall, about 6.3 cm. (2½ inches),—posterior wall, about 9 cm. (3½ inches). Fornices, anterior and posterior—consist of angles of reflection of vaginal on to uterine mucous membrane. Transverse section of vagina is H-shaped, when collapsed. Structure—fibrous, muscular, and mucous coats.

Relations.—Anteriorly; Base of bladder—loose subperitoneal fascia intervening. Urethra—subperitoneal areolar tissue intervening in upper one-third, but closely connected in lower two-thirds. Ureters—which enter bladder 3.2 cm. (1¼ inches) below level of os uteri. **Posteriorly;** Rectum—Douglas's peritoneal cul-de-sac intervening for about 2.5 cm. (1 inch) above—and subperitoneal areolar tissue intervening lower. Perineal body—below (separating vagina and rectum). **Laterally:**—Vaginal branch of uterine artery. Subperitoneal venous plexus at base of broad ligament. Ureters crossing upper third obliquely. Levatores ani, in relation with lower two-thirds.

Arteries.—Vaginal, internal pudic, vesical, and uterine branches of internal iliac; external pudic branches of femoral.

Veins.—Correspond with arteries—but form vaginal plexuses on each side of vagina.

Lymphatics.—Empty chiefly into pelvic—some into inguinal glands.

Nerves.—From fourth sacral and pudic nerves—and from hypogastric plexus.

* Here described because involved in Hysterectomy.

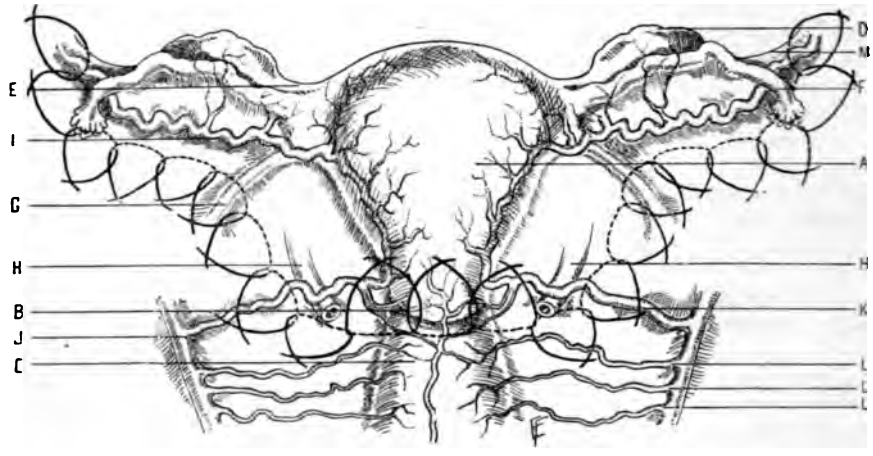

Fig. 544.—Diagram Showing Some of the Relations of the Uterus:—A, Uterus; B, Os uteri; C, Vagina; D, Ovary; E, Utero-ovarian ligament; F, Fallopian tube; G, Round ligament; H, H, Ureters; I, Ovarian artery; J, Internal iliac artery; K, Uterine artery; L, L, L, Vaginal arteries; M, Infundibulo-pelvic portion of broad ligament. The position of the ligatures about the vessels and broad ligament is shown (here shown as interlocking, which is unessential) as applied in total abdominal hysterectomy.

SURFACE FORMS AND LANDMARKS.

Utero-vesical fold of peritoneum is about on a level with the internal os uteri.

Utero-rectal fold of peritoneum is reflected for nearly 2.5 cm. (1 inch) on the posterior wall of the vagina.

The cervix may be divided into three zones:—the lower third is intravaginal;—middle third is, anteriorly, supravaginal (united to base of bladder)—and intravaginal posteriorly;—upper third is supravaginal—united to bladder anteriorly—and in relation with peritoneum posteriorly.

The ureters, in the case of a normal uterus, with empty bladder, lie nearly 1.3 cm. (½ inch) from the cervix. They pass parallel with the cervix and nearly 1.3 cm. (½ inch) away—running through the plexus of uterine veins and underneath the broad ligament—and, continuing near the vagina, run between the vagina and bladder, and enter the bladder about on a level with the center of the anterior wall of the vagina. The uterine arteries run over them, upon their inner aspect. For further description of the female ureter, see page 903. For the course of the uterine and ovarian arteries, see page 930 (also see Fig. 544, H, H).

INSTRUMENTS.

See those given under Abdominal Section (page 631)—in addition to which, may be mentioned:—vaginal retractors; broad ligament clamps; vulsella forceps; pedicle clamps; pedicle needles, straight and laterally curved; aneurism-needles, straight and laterally curved; tenaculum-forceps; long artery-clamp forceps; long scalpels; long scissors, straight and curved; long forceps, toothed and dissecting; uterine sound; urethral catheters.

PARTIAL ABDOMINAL HYSTERECTOMY, TOGETHER WITH REMOVAL OF OVARIES AND TUBES.

(PARTIAL ABDOMINAL HYSTERO-SALPINGO-OÖPHORECTOMY.)

Description.—The supravaginal portion of the uterus, together with the ovaries and tubes, are removed through a median abdominal incision. In Partial Abdominal Hysterectomy the supravaginal portion of the uterus only is removed, and the vagina is not opened. In Total Abdominal Hysterectomy the entire uterus, including the cervix, is removed, and the vaginal vault is opened. The ovaries may or may not be removed, in either case—they should be left when possible.

Preparation.—Bowels and bladder emptied. Median line and pubis shaved.

Position.—An upward tilt of patient's pelvis, of about 30.5 cm. (12 inches), in the Trendelenburg position aids by causing the intestines to fall away from the uterus. Surgeon stands on patient's right during most or the entire operation. Assistant opposite.

Landmarks.—Median line; navel; symphysis pubis; position of bladder and ureters.

Incision.—In median line, extending from umbilicus downward towards symphysis pubis. It may be extended above the umbilicus, passing directly through the navel, or may pass around it to the left. It averages from 10 to 15 cm. (4 to 6 inches) in length.

Operation.—(1) Median Abdominal Section:—Perform a median abdominal section in the usual manner—control hemorrhage—retract the edges of the abdominal wound—displace the small intestines and the sigmoid coil of the large intestine and keep them out of the pelvis with gauze pads, aided by the Trendelenburg position. Examine the contents of the pelvic cavity and learn the condition of the organs and the presence and extent of adhesions. (2) Freeing Uterus, Tubes, and Ovaries from Adhesions:—The weakest adhesions are separated by the fingers—firmer adhesions by scissors—the most extensive are divided between double chromic gut ligatures, as near the uterus as possible. The fundus of the uterus is seized with vulsella and drawn toward the pubis, and the rectum displaced backward, while freeing the posterior aspect—then to the right, while freeing the left aspect of the uterus, ovary, tube, and broad ligament,—and to the left while freeing the right aspect of the same structures. Dense adhesions are sometimes more easily broken up by following down the fallopian tubes and working up under the tube and ovary, than from above downward. Free more closely to the organ to be removed than to the structures to be left. A sound in the uterus will often aid in outlining the cleavage-lines of dense adhesions, along which separation must be accomplished by dissection with knife and forceps, or scissors. If completion of the freeing of adhesions in the usual way offers insuperable difficulties, it is sometimes best to stop and ligate the ovarian vessels and round ligament (in the manner and order described below) and divide the upper part of the broad ligament, making it possible to reach and free the tube and ovary from in front. (3) Enucleation:—(a) Ligate the left ovarian vessels with silk, at the outer end of the broad ligament, beneath the sigmoid colon—either dividing them between two silk ligatures, or between a clamp on the uterine and a ligature upon the pelvic side—cutting obliquely across the broad ligament to the round ligament. (b) The round ligament is similarly ligated with chromic gut, or clamped and ligated, and divided about 1.3 cm. (½ inch) from the uterus. (c) The vesico-uterine

peritoneum is detached from the uterus, by first incising the peritoneum along the concave line of its reflection, from left round ligament to right round ligament. While the uterus and adnexa are drawn up and to the opposite side, the vesical peritoneum is pushed off of the cervix with gauze or sponge grasped in a holder—thus separating bladder from cervix and baring the latter for about 3 cm. (1½ inches) and exposing the uterine vessels. (d) Grasp the cervix between the left index and thumb, and verify its lower termination and the site of the uterine arteries on each side. Ligate the left uterine vessels by silk ligature carried under them upon a curved aneurism-needle, passing from before backward and near to the cervix—but not carried too deeply alongside of the cervix, for fear of including the ureter. Place a clamp, or a second ligature, on the uterine side, and divide between them. (e) Amputate the cervix transversely, just above the vaginal attachment—so as to leave the stump of the cervix cupped antero-posteriorly and laterally. Protect the cut uterine canal with gauze from emptying its contents into the wound site. Cauterize the cervical canal—and stuff with gauze down into the vagina. (f) The uterus is drawn upward and to the opposite side—the right uterine vessels are exposed and are ligated and divided as on the left (or may be clamped at first and tied later). (g) The uterus is still further drawn up and to the opposite side—and the round ligament ligated as on the left and divided (or may be first clamped, and ligated later). (h) Cut obliquely across the broad ligament to the right ovarian vessels in the infundibulo-pelvic ligament—ligating and dividing them (or clamping first, and ligating later). The enucleation is now complete—and there is left a crescently denuded area in the pelvic cavity, broadest at its center, opposite the cervical stump, and coming to points at the brim of the pelvis, on either side, where the ovarian vessels were ligated. (4) Closure of the Cervical Canal:—The cupped surface of the cervical stump is sutured with chromic gut in such a way as to approximate the anterior and posterior aspects by from four to six interrupted sutures—entering the anterior lip exclusive of the vesical peritoneum, and emerging from the anterior lip anterior to the cervical canal—then passing over the cervical canal and entering the posterior lip just behind the cervical canal and emerging on the posterior peritoneal aspect of the cervical stump—thus closing the cervical canal, approximating the lips of the cervical stump, and controlling hemorrhage. The sutures are cut short and the stump dropped back into place. (5) Repair of the Pelvic Floor:—Having seen that all bleeding vessels are ligated (with chromic gut)—the denuded surfaces are entirely covered in, by suturing together the peritoneal surfaces with continuous gut—uniting the edges of the anterior peritoneal layer of the broad ligament and reflected vesical peritoneum in front, to the edges of the posterior peritoneum behind—beginning and ending at the stumps of the ovarian vessels—and suturing the vesical peritoneum opposite the cervical stump to the posterior peritoneum which has been included in the stitches which closed in the cervical canal. (6) Closure of the Abdominal Wound:—The abdominal wound is closed as usual—without drainage, unless specially indicated.

Comment.—(1) The broad ligament is everywhere divided between ligatures. Where the ligatures for the ovarian vessels, round ligament, and uterine vessels, above mentioned, do not extend entirely across the broad ligament, intervening separate ones are placed. (2) Especially guard against injuring the ureters while ligating the uterine arteries (see Anatomy, pages 861 and 932).

TOTAL ABDOMINAL HYSTERECTOMY, TOGETHER WITH REMOVAL OF OVARIES AND TUBES.

(TOTAL ABDOMINAL HYSTERO-SALPINGO-OÖPHORECTOMY.)

Description.—The entire uterus, including the cervix, as well as the ovaries and tubes, are removed, and the vaginal vault opened—all through a median abdominal section. The ovaries should be left when possible.

Preparation—Position—Landmarks—Incision.—As for Partial Abdominal Hysterectomy.

Operation.—The technic is so similar to that for Partial Abdominal Hysterectomy that only those points will be mentioned in which the technic of Total Abdominal Hysterectomy differs from the operation just described.

(1) The lips of the cervix are closed with strong silk sutures applied through the vagina, before the operation is begun—to protect the abdominal cavity from infection. The vagina is packed with gauze. (2) When the peritoneal reflection has been pushed away from the supravaginal part of the uterus, and the uterine arteries tied, as described in Partial Hysterectomy (down to 3—d, page 933)—instead of cutting through the cervix transversely, the upper limits of the vagina, anteriorly and posteriorly, are determined—and the vaginal vault is then opened in front, about 1 to 2 cm. ($\frac{3}{8}$ to $\frac{3}{4}$ inch) below the vaginal attachment of the uterus, by means of the thermocautery or scissors—aided by a vaginal sound passed into the anterior fornix, if necessary—the incision being continued around each side until the cervix is freed. The margin of the cut vagina is ligated, *pari passu*, with chromic gut at a right angle to its long axis, using interlocking ligatures if necessary—the sutures being placed parallel with and at a short distance from its margin. The sites of the ligatures required in total abdominal hysterectomy are shown in Fig. 544. All exposed areas are protected with gauze. (3) The anterior and posterior edges of peritoneum bordering the denuded area are sutured with continuous gut in a transverse line from one pelvic brim, across the pelvic floor, to the opposite pelvic brim, thus repairing the floor of the pelvis. The peritoneal edges are closed over the vaginal opening—but the opening in the vaginal vault is not sutured together—but, instead, a loose gauze pack is pushed through the opened vaginal vault up to the sutured overlying peritoneum. (4) The abdominal wound is closed in the ordinary manner.

Comment.—(1) If ureteral catheters are passed into the ureters prior to the operation, the positions of the latter are made more evident during operation. (2) The uterine arteries may be ligated further back in the pelvis, nearer their origin from the anterior branches of the internal iliacs—first assuring one's self of the position of the ureters by picking up the uterine artery and parallel tissues between the index and thumb—and then allowing them to slip out of the grasp. If this be done, the artery is caught and drawn up and the dissection of the connective tissue is carried on down to the uterus. (3) Veins, large single ones, and in plexuses, are apt to be encountered in the broad ligament and on the pelvic floor.

TOTAL VAGINAL HYSTERECTOMY.

Description.—Removal of entire uterus through the vault of the vagina—the incision being made from within the vagina. Indicated chiefly for malignant growth of the cervix, or for malignant disease limited to cervix and fundus.

Preparation.—Pubis, labia, and perineum shaved. Vagina cleansed. Bowels and bladder emptied.

Position.—Patient supine, at end of table, in lithotomy position. Surgeon sitting at foot of table. Assistant to surgeon's right, retracting posterior vaginal wall with large Sims or other retractor—while the lateral vaginal walls are retracted by lateral vaginal retractors.

Landmarks.—Anterior and posterior vaginal fornices; known position of ureters and uterine vessels.

Operation.—(1) The lips of the cervix are caught and drawn down with

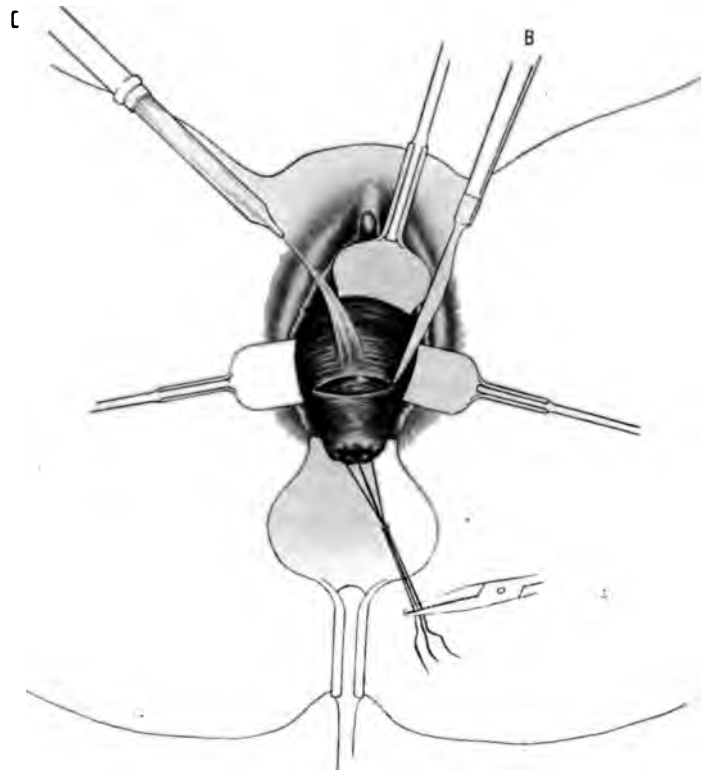

Fig. 545.—Vaginal Hysterectomy:—1. A, Sutures closing lips of uterus and serving as traction-loops, by which uterus is drawn out of vagina; B, Knife making incision through mucous membrane around cervix, at level with vaginal vault; C, Irrigator washing away blood. Vaginal walls are well retracted by four retractors. (Modified from Kelly.)

vulsella, or tenaculum-forceps—and are sutured together with strong silk (to prevent escape of contents). The silk ligatures may be left as long traction-loops. The uterus is thus drawn well down into the outlet (by forceps or loops)—while the vaginal walls are retracted downward and outward, as described above (Fig. 545). (2) With a knife, or sharp curved scissors, an incision is made entirely around the cervix, passing through the thickness of the vaginal vault down upon the substance of the cervix. (3) With the right index, the cellular tissue plane is opened up in front (between uterus

and bladder) and behind (between uterus and Douglas's cul-de-sac)—by pushing up and peeling back the tissues with the pulp of the finger always directed against the cervix, to prevent the fingers from slipping off violently in the wrong direction (Fig. 546). This separation is done anteriorly and posteriorly —but not done laterally, where the vessels enter from the broad ligament. Posteriorly, Douglas's cul-de-sac is recognized by a slight amount of fluid present within its cup-like cavity and by the smooth surfaces gliding over each other. This is caught with forceps, drawn down and incised with sharp

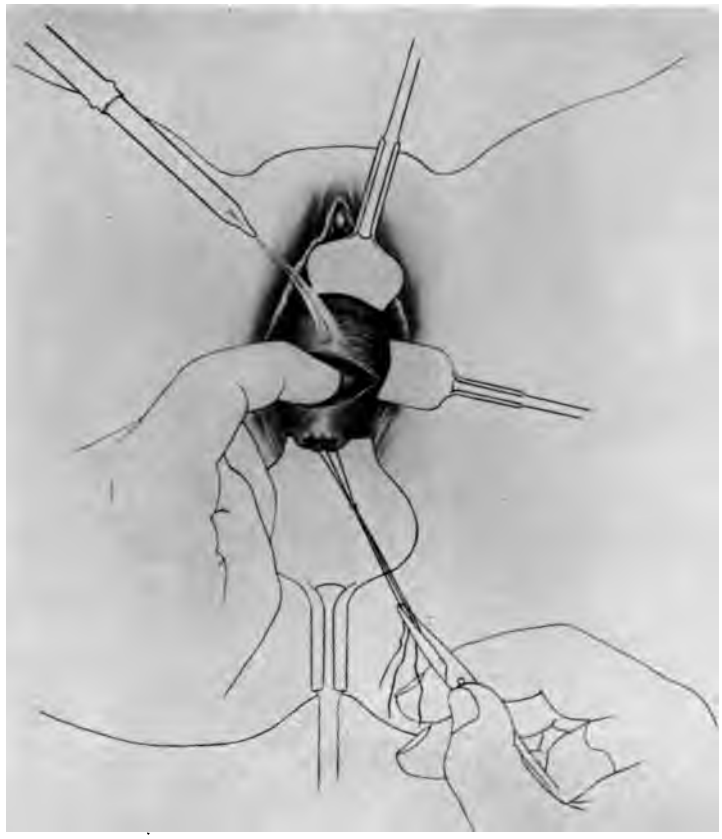

Fig. 546.—VAGINAL HYSTERECTOMY:—II. Index-finger opening up cellular tissue plane between uterus and bladder, anteriorly; and between uterus and Douglas's cul-de-sac, posteriorly. (Modified from Kelly.)

scissors to a slight extent, the opening being increased to the broad ligaments on each side by two fingers introduced and separated. Anteriorly, the separation is continued until the anterior vesico-uterine peritoneal fold is reached—which is recognized by its gliding surfaces—and which is drawn down with forceps and incised with sharp scissors to a limited extent—the opening being increased to the broad ligament on each side by fingers introduced and separated, guided, if necessary, by a sound in the bladder. The peritoneal cavity is thus opened in front and behind and the uterus is left hanging from the broad

ligaments (4) The broad ligaments are now tied off. The uterus is drawn well down and to the side opposite that upon which the ligature is to be passed, while the corresponding vaginal wall is retracted. The left index-finger is passed in through the posterior opening behind the broad ligament and near the cervix. A strong silk ligature, carried by a laterally curved aneurism-needle, is passed from before backward, and from above downward, and about 1 cm. (⅜ inch) to the outer side of the cervix, and including about 1 cm. (⅜ inch) of broad ligament tissue (Fig. 547). The ligature is firmly tied and the broad ligament included is immediately divided with scissors, rather nearer the

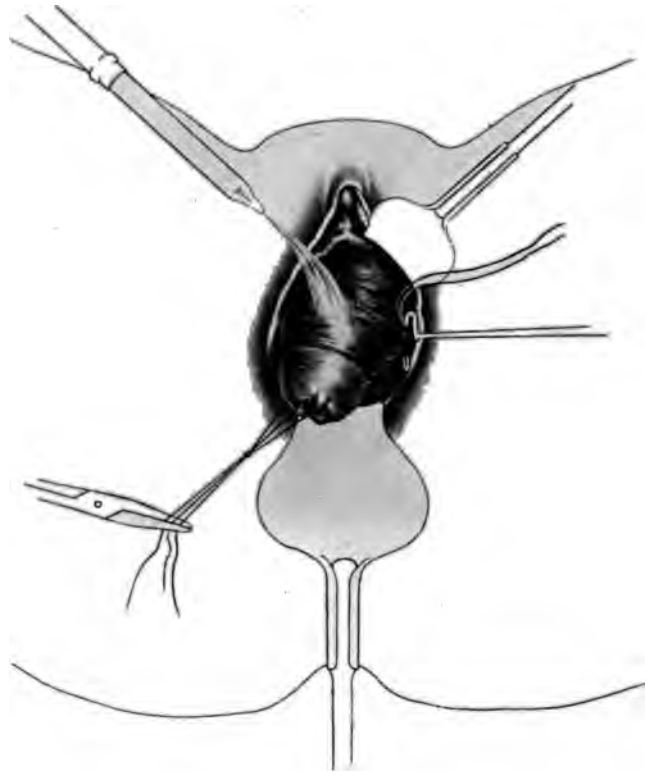

Fig. 547.—VAGINAL HYSTERECTOMY:—III. Ligating off the left broad ligament. (Modified from Kelly.)

uterus—being careful not to make the division higher than the ligature has gone. Two or three ligatures can generally be applied to one side before placing the same number on the opposite side, during downward traction of the uterus to the side where the first ligating was done (always drawing it to the side opposite the one upon which the greatest exposure is wished). Or the ligating may be continued up one side as far as convenient, even to the cornu of the uterus, and then upon the other side. The uterine vessels are generally included in the second or third ligature, being found close to the cervix uteri near the os internum. The position of the uterine artery should be determined

as soon as the opening through the posterior fornix is made. Especial care is here taken to avoid the ureter (see Surgical Anatomy, pages 861 and 932). When the ligating and division have progressed nearly to the cornu of that side, the finger can be passed in behind and hooked over the remaining broad ligament, fallopian tube, and round ligament, and these brought down and ligated —this last ligature being tied particularly well and the tissues cut at a distance. Often it is easier to alternate—by tying two or three ligatures on one side—then on the opposite, and so on. When all of one side and nearly all of the opposite broad ligament has been tied, the finger may be introduced and hooked around the fundus of the uterus and the organ delivered sidewise—the remain-

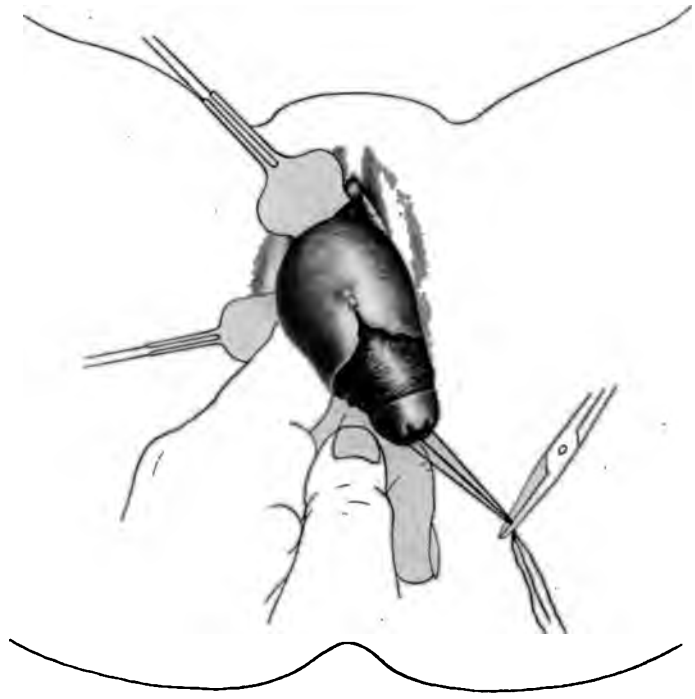

Fig. 548.—VAGINAL HYSTERECTOMY:—IV. Delivering the uterus by means of a finger introduced from behind and below. The right broad ligament has been entirely ligated and cut. (Modified from Kelly.)

ing ligatures being applied either from below upward or from above downward, as most convenient, while the organ lies in the vulval fissure (Fig. 548). Or, after progressing a part of the way, the fundus may be brought down, carrying the cervix up into the pelvic cavity and doubling the broad ligament upon itself—and thus applying the remaining ligatures in the reverse direction. But it is better, and more surgical, to deliver the uterus in its normal axis—continuing the ligating and division upon the two sides as first described. (5) The right and left groups of sutures are separated and held aside and the lower pelvic cavity irrigated and mopped or sponged out. Each line of broad ligament ligatures must be inspected—suspicious ones replaced—and additional ones

applied where indicated. The ligatures of each side are tied together in one group and cut near the knot, closely within the vagina. (6) The cut edge of the vesico-uterine peritoneal fold in front is sutured at its middle with gut to the middle of the cut edge of the utero-rectal peritoneal fold behind—either by a single mattress suture bringing the central portions of the two peritoneal folds together, or by a continuous suture bringing together the central portion—leaving, in either case, a gap at either side for possible drainage in cases where the vaginal vault is not sutured, or only sutured in part. Where the vaginal vault is entirely sutured, the two edges of the peritoneum should be sutured together throughout. (7) The vaginal vault may be left entirely unsutured—

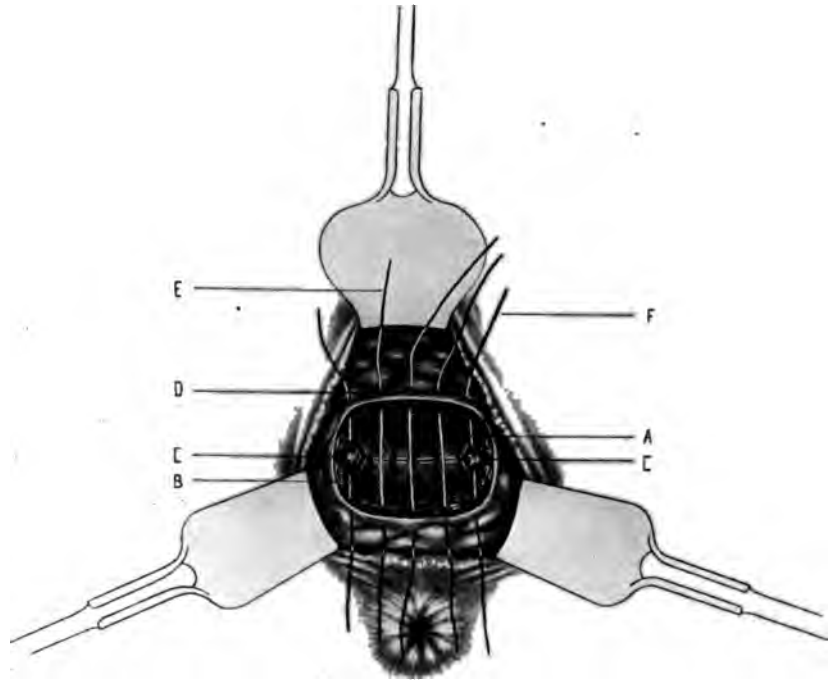

Fig. 540.—VAGINAL HYSTERECTOMY:—V. Peritoneal and vaginal suturing; A, Vesico-uterine peritoneal fold; B, Utero-rectal peritoneal fold. A transverse line of interrupted sutures unites the central portion of these folds. C, C, Vessels and broad ligament ligated. D, Vault of vagina. E, Sutures approximating cut edges of anterior and posterior vaginal fornix, thus repairing dome of vagina; F, Each lateral vaginal suture also passes through broad ligament stump, and thus brings it into lip of vaginal wound. (Modified from Kelly.)

in which cases it is packed loosely with gauze, and the vagina is then packed rather snugly. In other cases, which method is to be preferred, the vaginal vault is entirely closed by a line of continuous or interrupted gut sutures bringing the cut edges of the fornices together and crossing the dome of the vagina from before backward. But at each side the lower portion of the ligated broad ligament is caught and drawn down into the upper part of the vagina, and the sutures which pass through the lips of the vaginal vault also pass through and include some of the broad ligament stump—the stumps on the two sides thus projecting into the vagina, thus insuring drainage. (Fig. 540.)

Comment.—(1) Up to the opening of the peritoneal cavity, blood is removed by constant irrigation through a special glass tube held just above the vulva,—after opening the peritoneum, by gauze mops. (2) Catheters passed into the ureters before the operation enable the position of the ureters to be readily made out and guarded during operation. (3) If it be found, during operation, that it is desirable to remove the tubes and ovaries, ligatures are placed on the outer side of these. These ligatures are somewhat more difficult to apply and tighten than the others. (4) Especially guard the ureters near the cervix and behind the uterine arteries, while working near the cervix.

II. THE OVARIES.

SURGICAL ANATOMY.

(1) Ovaries.

Description.—Placed one on each side of the pelvis—connected with the posterior layer of the broad ligament, posterior and inferior to the fallopian tubes. Rests against the lateral wall of pelvis, with long axis nearly vertical in erect position of body (His). Length, about 3.8 cm. (1½ inches);—breadth, about 2 cm. (¾ inch);—thickness, about 1.3 cm. (½ inch). Position of ovary corresponds with a point about 5 cm. (2 inches) internal to the anterior superior iliac spine. In the position and relations given by His, the fallopian tube and fimbria almost completely envelop the ovary. In structure, the ovary consists of peritoneal serous covering and stroma.

Relations.—Mesial Surface;—Is free. Fimbriated extremity of fallopian tube is in contact to various extent. Mesosalpinx is also in relation. Coils of jejunum and ileum often to inner side of right ovary. Sigmoid colon may be to inner side of left ovary. **Lateral Surface;**—Lies in fossa ovarii, a peritoneal depression upon the lateral pelvic wall, generally just below the external iliac vessels—with the ureter often bounding the fossa below and behind. **Posterior Border;**—Is free. Directed toward rectum. Partly embraced by fimbriated end of fallopian tube. **Anterior Border;**—Furnishes attachment to broad ligament. Presents hilum (between two layers of broad ligament) for entrance of vessels and nerves. Fallopian tube. **Upper Extremity;**—Ovarian fimbria of fallopian tube are attached. Ligamentum suspensorium ovarii (ligamentum infundibulo-pelvicum) passes from brim of pelvis to upper extremity—conveying the ovarian vessels and nerves. **Lower Extremity;**—Ligament of ovary—from angle of uterus to lower or inner end of ovary.

Arteries.—Ovarian of abdominal aorta; anastomotic branches of uterine and internal iliac. The ovarian artery, crossing brim of pelvis, enters broad ligament and runs in infundibulo-pelvic ligament—and, passing between layers of broad ligament, runs to the ovary and upper part of uterus.

Veins.—Follow the arteries—and form the pampiniform plexus.

Nerves.—From ovarian plexus; from pelvic plexus; from uterine nerves.

Lymphatics.—Empty into prevertebral glands, in front of aorta and vena cava.

(2) Fallopian Tubes.

Description.—Average length, 10 to 12.5 cm. (4 to 5 inches). Begin at superior angle of uterus and extend—enclosed in upper free border of the

broad ligament—to the sides of the pelvis, ending in the fimbriated extremities, which are in relation with the corresponding ovaries. After enveloping the fallopian tubes, the layers of the broad ligament are continued down to the ovary. The tubes are made up of—the isthmus (inner third)—ampulla (from isthmus to neck)—neck (or ostium abdominale)—and fimbriated extremity. They are composed of serous, muscular, and mucous coats.

Course and Relations.—From the superior angles of the uterus, they run nearly horizontally outward, for about 1.3 to 2.5 cm. (½ to 1 inch) to the pelvic wall—thence ascend, sometimes tortuously, anteriorly to their ovaries—then curve backward over the ovaries, lying internal to the suspensory ligament—and end by passing downward along the inner and posterior borders of the ovaries. Ileo-jejunal convolutions are sometimes above and to inner side of right fallopian tube. Sigmoid rectum is sometimes in the same relation to the left tube.

Artery.—Tubal branch of ovarian.

OVARIECTOMY, OR OÖPHORECTOMY, WITH REMOVAL OF FALLOPIAN TUBE.

(SALPINGO-OVARIECTOMY, OR SALPINGO-OÖPHORECTOMY.)

Description.—Ovariectomy (or, less correctly, Ovariotomy) consists in the removal of the ovary through, generally, an abdominal section. When the fallopian tube is simultaneously removed, the operation becomes Salpingo-ovariectomy, or Salpingo-oöphorectomy. The ovary may be removed alone, or the tube may be removed alone. In the operation here described, the following structures will be removed:—entire ovary, entire fallopian tube, part of utero-ovarian ligament, and the arteries, veins, lymphatics, and nerves belonging to these structures.

Preparation.—Median line and pubis shaved. Bowels and bladder emptied.

Position.—Patient supine near edge of table at first—and subsequently elevated into slight Trendelenburg position after the abdomen is opened. Surgeon on side of operation—or always on patient's right, independently of ovary operated upon—or may prefer to cut upward, and then stands on patient's left in both cases. Assistant opposite.

Landmarks.—As for median abdominal section (page 631).

Incision.—In median line—about 5 to 10 cm. (2 to 4 inches) in length—extending upward from a point about 2.5 cm. (1 inch) above the symphysis pubis.

Operation.—(1) Perform a median abdominal section—control hemorrhage—and retract lips of abdominal wound. (2) Pass the first and second fingers into the wound, with the back of the hand to the abdomen—follow down the under surface of the abdominal parietes to the symphysis—thence down on to the bladder and uterus—and thence out laterally over the superior cornu of the uterus, with the palm of the hand still downward, to and along the broad ligament—along the posterior superior aspect of which the fallopian tube is found—and, just posterior to the tube, the ovary. These structures are drawn toward the median line, into an accessible position in the abdominal wound. (3) The ovarian artery and veins are first tied, with silk—the ligature being carried, upon a laterally curved aneurism-needle, through the clear space of the broad ligament and tied over the top of the infundibulo-pelvic ligament, outside of the fimbriated end of the fallopian tube, and close to the brim of the

pelvis (Fig. 550). (4) The utero-ovarian ligament, lying behind the fallopian tube, is ligated with chromic gut, rather nearer the uterus, carried upon a laterally curved aneurism-needle. (5) The inner end of the fallopian tube and the upper free part of the broad ligament are ligated with silk near the horn of the uterus—which ligature also controls the branches from the uterine artery. (6) The structures are now removed by cutting through the broad ligament well within the outer ligature of the ovarian vessels—and cutting through the fallopian tube and ovarian ligament well to the outer side of their ligatures—and



Fig. 550.—OVARIECTOMY, WITH REMOVAL OF FALLOPIAN TUBE:—A, Uterus; B, Aneurism-needle carrying ligature around utero-ovarian ligament; C, Ligature passing through broad ligament and surrounding fallopian tube and ovarian artery; D, Ligature passing through broad ligament and over top of infundibulo-pelvic ligament and surrounding ovarian artery; E, Round ligament; F, Bladder; G, Colon.

carrying the incision through the broad ligament well below the hilum of the ovary. Any doubtful ligature is strengthened, and any bleeding point is surrounded by an additional gut ligature. (7) The edges of the anterior and posterior layers of the broad ligament, left by the removal of the above structures, are sutured together with gut. The patient is lowered to the horizontal position—and the intestines and omentum are replaced. (8) The abdomen is closed, as after median abdominal section.

Comment.—(1) The main danger in the operation is from uncontrolled

hemorrhage. Where there is any danger of a ligature slipping, one end of the ligature may be carried through neighboring tissue and knotted to the opposite end. (2) The non-vascular portion of the broad ligament between the ligatures of the special structures may be left free—or, if ligated, should be so ligated as not to bind the pelvic and uterine aspects of the broad ligament together.

NOTE.

Other operations upon the Uterus and Ovaries, and the operations upon the Fallopian Tubes, Broad Ligaments, Round Ligaments, Labia Majora and Minora, Clitoris, Hymen, Glands and Ducts of Bartholin, Bulbi Vestibuli, Vagina, Female Perineum, Female Bladder, Female Urethra, and Female Ischio-rectal regions—all belonging more particularly to special Gynecological Surgery, will not be considered here.

CHAPTER VIII.

OPERATIONS FOR HERNIAE.

I. INGUINAL HERNIA.

SURGICAL ANATOMY.

THE structures encountered in the operations for inguinal herniæ and those in the immediate neighborhood of the site of operation, will be here briefly described—chiefly in the order encountered, from without inward.

Superficial Fascia.—Divisible into two layers, between which lie superficial arteries, veins, lymphatics, and nerves of the inguinal region.

Superficial Layer of Superficial Fascia.—Continuous with superficial fascia of abdomen, thigh, penis, scrotum, labia, and perineum.

Superficial Arteries.—Superficial epigastric branch of femoral. Superficial circumflex iliac of femoral. Superficial external pudic of femoral.

Superficial Veins.—Accompany arteries and end in internal saphenous vein.

Superficial Lymphatics.—Superior group, along Poupart's ligament. Inferior group, around saphenous opening.

Superficial Nerves.—Hypogastric branch of Iliohypogastric, Ilio-inguinal.

Deep Layer of Superficial Fascia (Scarpa's Fascia).—Attached to linea alba—continuous with superficial fascia over trunk—connected with fascia lata—helps form dartos—continuous with deep layer of superficial fascia of perineum.

External Oblique Muscle.—

Poupart's Ligament.—That portion of aponeurosis of external oblique extending from anterior superior iliac spine to spine of os pubis.

Gimbernat's Ligament.—That portion of aponeurosis of external oblique which is reflected from Poupart's ligament, at spine of os pubis, along the pectineal line.

Triangular Ligament.—That portion of aponeurosis of external oblique which is reflected from Gimbernat's ligament, at the pectineal line, upward and inward beneath the spermatic cord and behind the internal pillar of the external ring and in front of the conjoint tendon, to the linea alba, where it interlaces with its fellow of opposite side.

External or Superficial Abdominal Ring.—A triangular opening in aponeurosis of external oblique immediately above and just external to crest of os pubis. Bounded, inferiorly, by crest of os pubis,—Superiorly, by intercolumnar fibers, strengthened by intercolumnar fascia,—Internally, by inner or superior pillar,—Externally, by outer or inferior pillar. Transmits spermatic cord in male, and round ligament in female.

Internal Oblique Muscle.—

Conjoint Tendon of Internal Oblique and Transversalis.—Inserted into crest of os pubis and pectineal line, directly behind external abdominal ring.

Cremaster Muscle.—Corresponds with inferior fibers of internal oblique

—arising from center of Poupart's ligament, where they are continuous with the interno-inferior aspect of that muscle—descend along external and anterior aspect of spermatic cord—curve around testicle—and, ascending along inner aspect of cord, are inserted into crest of os pubis and anterior surface of sheath of rectus. The fascia cremasterica increases the strength of these fibers.

Transversalis Muscle.—

Transversalis Fascia.—

Inguinal Canal.—Transmits spermatic cord in male—and round ligament in female. Extends obliquely downward and inward for about 3.8 cm. (1½ inches)—parallel with and slightly above Poupart's ligament—beginning at the internal abdominal ring and ending at the external abdominal ring. Anterior boundaries,—skin; superficial fascia; aponeurosis of external oblique (throughout); internal oblique (outer third). Posterior boundaries,—triangular ligament; conjoint tendon of internal oblique and transversalis; transversalis fascia; subperitoneal fat; peritoneum. Superior boundaries,—curved fibers of internal oblique and transversalis. Inferior boundaries,—junction of fascia transversalis and Poupart's ligament.

Internal or Deep Abdominal Ring.—An oval opening lying in the transversalis fascia, half-way between the anterior superior iliac spine and symphysis pubis, and about 1.3 cm. (½ inch) above Poupart's ligament. Superior and External boundary,—curved fibers of transversalis. Inferior and Internal boundaries,—deep epigastric vessels. Transmits spermatic cord in male—and round ligament in female. Infundibuliform process of fascia transversalis strengthens its opening.

Subperitoneal Areolar Tissue.—

Deep Epigastric Artery, of External Iliac.—For Surgical Anatomy, see page 92.

Other anatomical points, necessary to the thorough understanding of the Inguinal Herniæ, are given under General Surgical Considerations.

GENERAL SURGICAL CONSIDERATIONS.

Definition of Inguinal Hernia.—Hernia passing through the abdominal wall in the inguinal region.

Varieties of Inguinal Herniæ.—(1) External or Oblique Inguinal Hernia,—neck of sac lies external to deep epigastric artery,—follows course of spermatic cord through inguinal canal. (2) Internal or Direct Inguinal Hernia,—neck of sac lies internal to deep epigastric artery,—hernia penetrates some portion of abdominal wall internal to deep epigastric artery.

(a) **Oblique or External Inguinal Hernia.**—

Coverings of Oblique Inguinal Hernia :—The hernia enters the external inguinal fossa (v. i.)—and, passing down from the abdominal cavity, receives the following coverings, in order:—(1) At Internal Abdominal Ring:—peritoneum; subserous areolar tissue; infundibuliform process of fascia transversalis; —(2) In Inguinal Canal:—(passes under curved fibers of internal oblique and transversalis, but does not receive a covering from them); cremaster muscle;—(3) At External Abdominal Ring:—intercolumnar fascia;—(4) In Scrotum:—superficial fascia; skin.

Position of Oblique Inguinal Hernia.—This variety of Inguinal Hernia always lies to the outer side of the deep epigastric artery—and generally lies anterior to the vessels of the spermatic cord—and rarely descends below the the testis (because of adhesion of the hernial coverings to the tunica vaginalis).

Seat of Stricture in Oblique Inguinal Hernia.—Most frequently at the internal ring,—may occur at the external ring,—or may occur in the canal, by fibers of internal oblique and transversalis.

(b) Direct or Internal Inguinal Hernia.—A correct understanding of this form of hernia depends upon a knowledge of the anatomy of the lower abdominal wall:—

Cord-like Structures upon Inner Aspect of Lower Abdominal Wall.—Seven cord-like structures are seen upon the inner aspect of the lower abdominal wall—ranging from near the median line upward:—(**a**) Plica Urachi—remains of fetal urachus in median line;—(**b**) Two Plicæ Hypogastricæ—obliterated hypogastric arteries on each side of median line, running upward toward the median line;—(**c**) Two Plicæ Epigastricæ—deep epigastric arteries running upward and toward median line;—(**d**) Two Poupart's Ligaments—running upward and outward.

Fossæ upon Inner Aspect of Lower Abdominal Wall.—Eight fossæ are formed by the peritoneum stretched over these prominent cord-like structures—by the depressions between them:—(**a**) Two Internal Inguinal Fossæ—between plicæ urachi and plicæ hypogastricæ;—(**b**) Two Middle Inguinal Fossæ—between plicæ hypogastricæ and plicæ epigastricæ;—(**c**) Two External Inguinal Fossæ—between plicæ hypogastricæ and Poupart's ligaments; (**d**) Two femoral fossæ—below Poupart's ligaments, to inner side of femoral vein.

Relations of Herniæ to Fossæ upon Inner Aspect of Lower Abdominal Wall.—(**1**) Through the External inguinal fossa, an oblique inguinal hernia occurs;—(**2**) Through either the Internal or Middle inguinal fossa, a direct inguinal hernia comes;—(**3**) Through the Femoral fossa, a femoral hernia occurs.

Fossæ within Hesselbach's Triangle through which direct Inguinal Hernia may come.—Hesselbach's Triangle is bounded—Externally; by deep epigastric artery;—Internally; by outer border of rectus muscle;—Inferiorly; by Poupart's ligament. The conjoint tendon of the internal oblique and transversalis is stretched across the inner two-thirds of Hesselbach's triangle. The remaining outer one-third has only the subperitoneal areolar tissue and transversalis fascia between the peritoneum and the external oblique aponeurosis. The plica hypogastrica divides Hesselbach's triangle into an internal inguinal fossa (which is the region of the conjoint tendon) and a middle inguinal fossa. Two forms, therefore, of direct inguinal hernia may occur—dependent upon whether the hernia escapes through the inner two-thirds or the outer one-third of Hesselbach's triangle.

Commoner Form of Direct Inguinal Hernia.—In which the hernia enters the internal inguinal fossa, and either forces its way through the conjoint tendon, in the inner two-thirds of Hesselbach's triangle—or carries the conjoint tendon before it—and escapes into the lower part of the inguinal canal. This form of direct inguinal hernia has the following coverings, in order:—(**1**) Within Abdomen:—peritoneum; subserous areolar tissue; general layer of fascia transversalis;—(**2**) On its way to lower part of Inguinal Canal;—conjoint tendon of internal oblique and transversalis (instead of cremaster muscle); and then enters lower part of inguinal canal, which it traverses to emerge at external abdominal ring;—(**3**) At External Ring:—intercolumnar fascia;—(**4**) In Scrotum:—superficial fascia; skin.

Rarer Form of Direct Inguinal Hernia.—In which the hernia enters the middle inguinal fossa, and escapes through the outer third of Hesselbach's triangle—external to the conjoint tendon—and enters the upper part of the in-

guinal canal. This form of direct inguinal hernia has the following coverings, in order:—(1) Within abdomen:—peritoneum; subserous areolar tissue; general layer of fascia transversalis (instead of infundibuliform process of transversalis fascia, as in the oblique form);—(2) In Inguinal Canal:—(which it now enters at its upper part, instead of entering at the internal abdominal ring, and travels through the rest of the way); cremaster muscle;—(3) At External Ring:—(from which it exits as does oblique hernia); intercolumnar fascia;—(4) In Scrotum:—superficial fascia; skin.

Position of Direct Inguinal Herniæ.—Both of the varieties of direct inguinal herniæ lie upon the inner side of the deep epigastric artery. They do not enter the upper opening of the inguinal canal, but pass through the tissues over the os pubis and then enter the canal lower down—but make their exit at the external abdominal ring. Both these direct herniæ generally descend along the inner and anterior aspect of the spermatic cord.

Seat of Stricture in Both Forms of Direct Inguinal Herniæ.—Most frequently at the neck of the sac,—may occur at the external ring. Where the hernia pierces the conjoint tendon, the stricture may be at the margin of the fissure.

Direction of Incision for Relief of Stricture.—Whether in operating for the relief of constriction in oblique inguinal hernia, or in either form of direct inguinal hernia—divide directly upward—which would be external to the deep epigastric artery in oblique inguinal hernia—and internal to it in direct inguinal herniæ.

INSTRUMENTS.

Scalpels; bistouries, straight and curved, sharp and blunt; scissors, straight and curved, sharp and blunt; forceps, dissecting and toothed; artery-clamp forceps; tenacula; grooved director; special hernia knife; special hernia-director retractors; probe; needles, straight and curved; needle-holder; ligatures and sutures, silk, plain gut, chromic gut, kangaroo tendon, silkworm-gut.

OPERATION FOR THE RADICAL CURE OF OBLIQUE INGUINAL HERNIA.

BASSINI'S METHOD.

Description.—Consists in the transplantation of the cord from its old to a new bed—between the internal oblique below, and the external oblique above—formed by suturing the lower borders of the conjoint tendon and the transversalis and internal oblique muscles above, to the shelving portion of Poupart's ligament below—and covering these by suturing the aponeurosis of the external oblique, fascia and skin over them. The hernial sac is ligated and removed at its neck. The constituents of the cord are not disturbed.

Preparation.—Bladder and bowels are emptied and pubic region shaved.

Position.—Patient supine near edge of that side of table upon which hernia is. Surgeon on side of hernia, cutting from above downward on right, and from below upward on left,—or he may stand upon the right in both cases. Assistant opposite.

Landmarks.—Internal and external rings; inguinal canal; spermatic cord; Poupart's ligament; anterior superior iliac spine.

Incision.—Begins at a point to the inner side of the anterior superior iliac spine, and about 1.3 cm. (½ inch) above Poupart's ligament—passes obliquely

downward parallel with and about 1.3 cm. (½ inch) above Poupart's ligament—and ends over the middle of the external abdominal ring—being about 7.5 to 9 cm. (3 to 3½ inches) long (Fig. 551, A).

Operation.—(1) Divide skin and superficial fascia, clamping bleeding vessels—and retract edges of wound, exposing aponeurosis of external oblique. (2) Demonstrate the external abdominal ring and pass a grooved director through its opening and carry it obliquely upward in the line of the fibers of the external oblique aponeurosis, and immediately beneath its surface, for a distance of about 6.3 cm. (2½ inches)—the instrument showing through its thin texture (Fig. 552). Slit up the fibers of the aponeurosis of the external oblique upon the grooved director with a scalpel, traveling in the cleavage line of the fibers. Dissect, by blunt separation, the upper edge of the cut aponeurosis in-

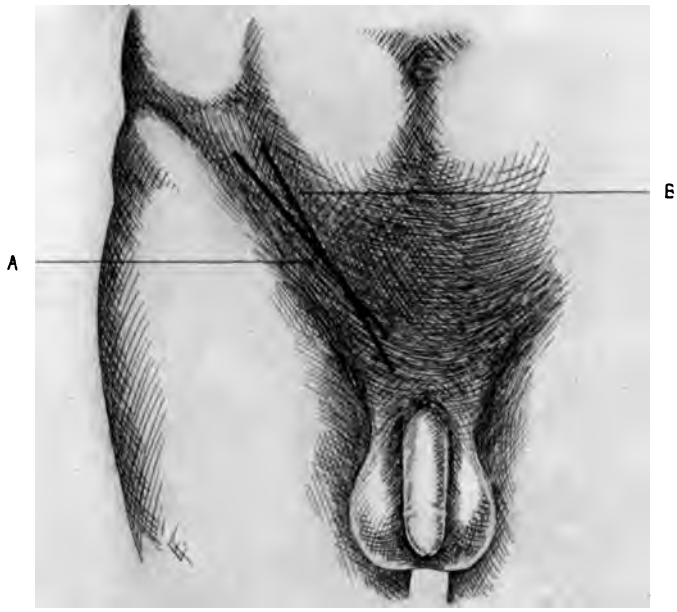

Fig. 551.—Incisions for Radical Cure of Oblique Inguinal Hernia:—A, Incision for Bassini's Operation; B, Incision for Halsted's Operation.

ward and upward nearly to the outer edge of the rectus sheath. Similarly dissect, by blunt separation, the lower edge of the cut aponeurosis of the external oblique downward and outward to the shelving portion of Poupart's ligament. The inguinal canal, except that part covered by the internal oblique, is thus exposed. (3) Grasp, with forceps, aided by the fingers, the mass of soft tissues just within, or emerging from the external abdominal ring, composed of cord and hernial sac—and, pushing aside the muscle-fibers with a blunt dissector, or closed ends of blunt, curved scissors, lift upward and outward the hernial sac and cord—drawing them partly from the direction of the inguinal canal, and partly from the direction of the scrotum—the hernia lying anteriorly, surrounded by the infundibuliform fascia, and the cord posteriorly—the sac and cord being more or less intimately adherent.

(4) Isolate the sac from the cord by blunt dissection—and carry on the freeing of the sac upward, retracting the internal oblique muscle outward to expose the outer aspect of the inguinal canal, until the sac begins to open out into the general peritoneum. If it be certain that the sac contains no adherent intestines or omentum, it need not be opened. If there be any question—and it is probably better in all cases to do so, whether question or not—the sac should be opened at some distance below the point of intended closure and examined. The contents of the sac, if any, are returned to the abdominal cavity. The sac is then to be treated in one of two ways:—If it be small, a double chromic gut ligature is carried through the center of that portion which is to form the line of occlusion—these two ligatures are crossed and are

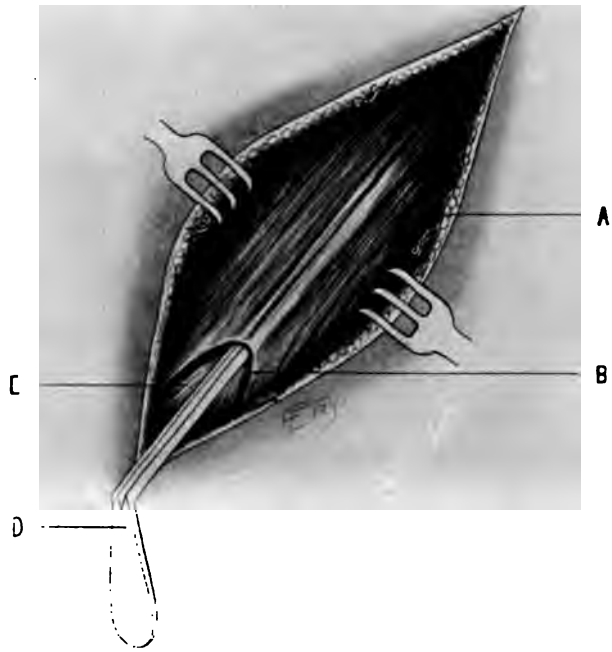

Fig. 552.—Bassini's Operation for Oblique Inguinal Hernia:—I. Splitting aponeurosis of external oblique; A, Aponeurosis of external oblique; B, External abdominal ring; C, Cord; D, Grooved director passed beneath aponeurosis of external oblique. (Modified from Bull and Coley.)

firmly tied on each side—and the sac cut off a safe distance from the ligatures. If the sac be large (so that ligating would cause too much puckering and probably slip off), its surfaces are to be sutured with chromic gut on a level with the site of division—and then cut off with scissors at a safe distance distal to the suture line. The sac is thus disposed of and returned to the abdominal cavity (Fig. 553). (5) The cord is now taken up in the left thumb and index and isolated from external to internal ring, *en masse*, without disturbing its component structures, and a strip of gauze is passed beneath it—whereby it is held up by an assistant well out of the way, until its new bed is made for it. (6) The lower borders of the internal oblique and transversalis muscles are now sutured to the shelving portion, or border of Poupart's ligament, with interrupted su-

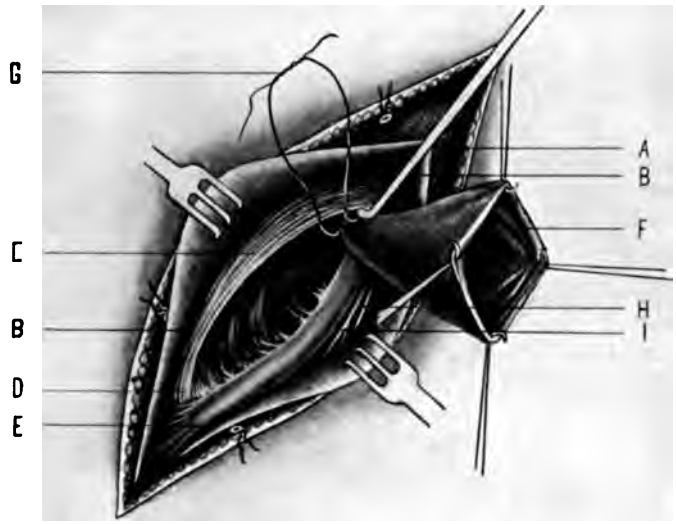

Fig. 553.—BASSINI'S OPERATION FOR OBLIQUE INGUINAL HERNIA:—II. Isolation of sac; A, External oblique muscle; B, B, Aponeurosis of external oblique; C, Internal oblique muscle; D, Conjoint tendon of internal oblique and transversalis; E, Cord; F, Sac, incised and drawn outward; G, Neck of sac surrounded by ligature; H, Ilio-inguinal nerve; I, Genitocrural nerve. (Modified from Bull, Coley and Kelly.)

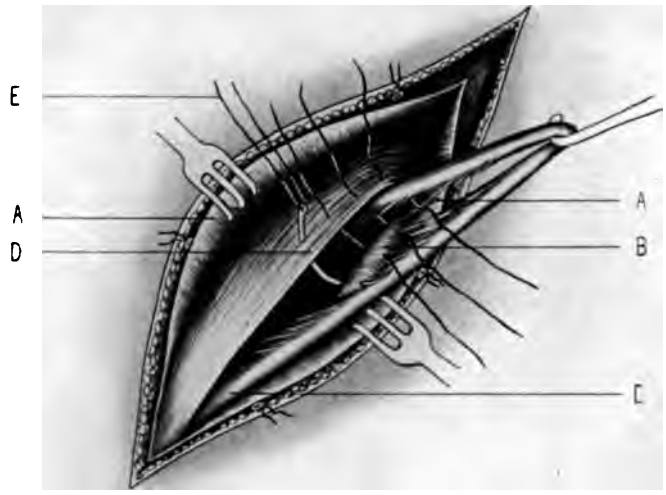

Fig. 554.—BASSINI'S OPERATION FOR OBLIQUE INGUINAL HERNIA:—III. Forming new floor for cord; A, A, Aponeurosis of external oblique; B, Shelving portion of Poupart's ligament; C, Cord, drawn out of canal by hook; D, Internal oblique and transversalis retracted strongly outward; E, Needle carrying sutures approximating internal oblique and transversalis, above, with shelving portion of Poupart's ligament, below. (Modified from Bull and Coley.)

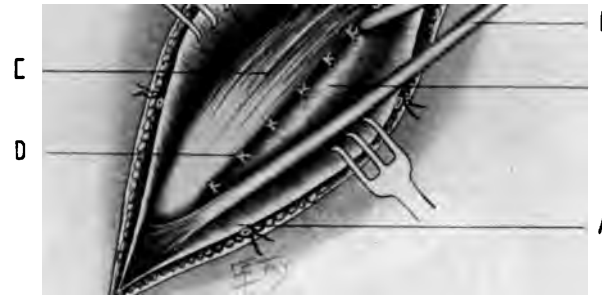

Fig. 555.—Bassini's Operation for Oblique Inguinal Hernia:—IV. New floor for cord
pleted; A, A, Aponeurosis of external oblique; B, Shelving portion of Poupart's ligament; C
ternal oblique and transversalis; D, Sutures forming new bed for cord, by approximating int
oblique and transversalis, above, to shelving portion of Poupart's ligament, below; E, Cord d
outward by hook. (Modified from Bull and Coley.)

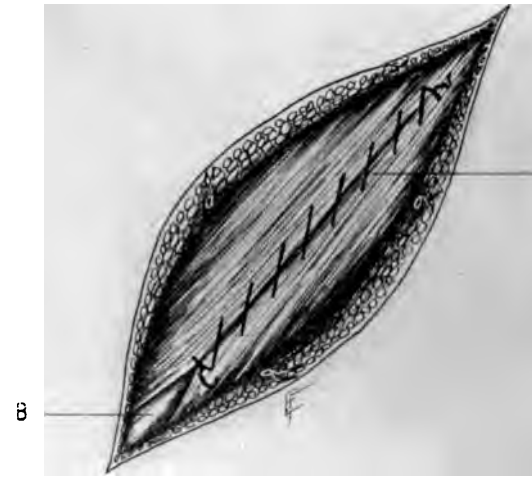

be isolated by the surgeon's fingers from the transversalis fascia, beginning at the conjoint tendon and extending outward to the internal abdominal ring. While passing the sutures, the surgeon's left index should be carried behind the conjoint tendon and also behind the lower borders of the internal oblique and transversalis muscles, so as to guide the needle-point. The first suture, near the upper end of the wound, pierces the internal oblique almost as far outward as the external border of the rectus muscle. It should just come in contact with the inner aspect of the cord when the latter is held at a right angle to the plane of the internal oblique muscle as it emerges from opposite the internal ring. A second suture is placed just above the cord, to strengthen the internal ring, the cord thus emerging between two sutures. As many similar sutures as are indicated (generally six or seven altogether) are thus placed. The last, lowest, suture passes through the conjoint tendon of the internal oblique and transversalis above, and the shelving portion of Poupart's ligament below. (Fig. 554.) (**7**) The cord is now dropped down upon its new bed made by suturing the conjoint tendon and the internal oblique and transversalis muscle to the shelving border of Poupart's ligament (Fig. 555). (**8**) The separated edges of the aponeurosis of the external oblique are now sutured directly over the cord with continuous kangaroo or chromic gut sutures—carefully avoiding too tightly suturing the edges over the cord at the lower end, the new external ring, where the cord escapes into the scrotum (Fig. 556). (**9**) The skin is closed throughout with interrupted sutures of fine catgut. No drainage is used. The first dressing usually comes off at the end of a week.

Comment.—No muscle tissue, except aponeurosis of external oblique, is cut.

OPERATION FOR THE RADICAL CURE OF OBLIQUE INGUINAL HERNIA.

HALSTED'S METHOD.

Description.—Like Bassini's operation, which it resembles in many respects, Halsted's operation consists not only in a transplantation of the cord from its natural to a new canal, but also in the making of a new, closely fitting internal ring. It differs from Bassini's method in the following respects:—(**a**) A new internal ring is made;—(**b**) Most of the veins of the cord are excised;—(**c**) The internal oblique and transversalis muscles and transversalis fascia are incised;—(**d**) The cord is finally made to lie between the aponeurosis of the external oblique and the skin.

Preparation—Position—Landmarks.—As for Bassini's operation.

Incision.—Begins at a point 3 cm. (1 inch) above and beyond the internal abdominal ring—and passes thence obliquely in a straight line to the spine of the os pubis (Fig. 551, B).

Operation.—(**1**) Incise skin and fascia—control hemorrhage—retract edges of wound—and expose external oblique aponeurosis and external abdominal ring. (**2**) Divide, in order, upon grooved director, in line of original incision, the external oblique aponeurosis, internal oblique muscle, transversalis muscle, and fascia—all upward and outward to a point about 2.5 cm. (1 inch) above the internal abdominal ring. (**3**) Expose and draw outward the hernial sac and cord—and separate the cord, *en masse*, from the sac. (**4**) Isolate the structures of the cord, recognizing vas, arteries, and veins. Excise all the veins except one or two, between gut ligatures placed beyond the upper and lower lines of excision. (**5**) Separate the sac from all structures and from the margins of the internal ring. Return its contents to the abdominal cavity—first opening

Fig. 557.—Halsted's Operation for Oblique Inguinal Hernia:—1. Forming new bed for cord; A, External oblique aponeurosis; B, Internal oblique and transversalis; C, Cord with its artery and a vein or two; D, Free end of bulk of veins excised from cord; E, Wire mattress sutures approximating aponeurosis of external oblique, internal oblique, transversalis muscle, transversalis fascia, above; to transversalis fascia, Poupart's ligament, and aponeurosis of external oblique, below. (Modified from Halsted.)

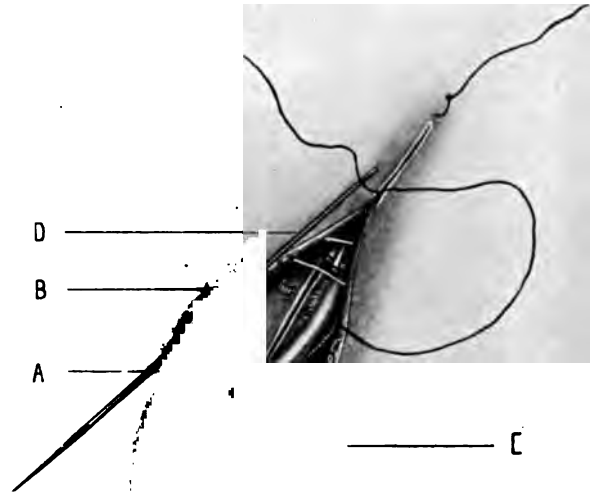

it, if necessary, or in doubt. Excise the sac beyond its neck, and shut off the peritoneal cavity by suturing the edges of its mouth with silk sutures (continuous or mattress). (6) Lift the cord out of the wound upon a blunt hook, and place about six or eight deep silver wire mattress sutures beneath it—passing through external oblique aponeurosis, internal oblique muscle, transversalis muscle, and transversalis fascia, on the upper side—and going through the transversalis fascia, Poupart's ligament, and fibers of aponeurosis of external oblique, on the lower side (Fig. 557). The two sutures placed most external will pierce muscle tissue upon both upper and lower sides of the wound—the cord escaping between them. Tighten all sutures so as to approximate the included parts snugly—twisting the wires, cutting them moderately short, and burying them. The cord is then allowed to fall upon its new bed. (7) The skin and fascia are closed directly over the cord, by a subcuticular, silver-wire suture—which is withdrawn after healing. No drainage is used (Fig. 558).

Comment.—(1) Avoid endangering the cord by the removal of too many vessels. (2) Avoid too tightly compressing the cord between the two outer sutures. (3) When the abdominal muscles and transversalis fascia are divided, the internal abdominal ring disappears—and the neck of the sac, its apparently constricted part, also disappears. (4) When the sac is isolated and opened, a gauze pad upon a string may be put into the abdominal cavity, to hold the intestines out of the way. The sutures are then placed in the mouth of the sac to bring its edges together—are temporarily separated to withdraw the gauze pad—and are then tightened—the sac being cut away safely above the suture-line. (5) If the muscles at the point at which the cord is brought out are thin, the cord is transplanted further outward.

II. FEMORAL HERNIA.

SURGICAL ANATOMY.

The structures encountered in the operations for Femoral Hernia, and those in the immediate neighborhood of the site of operation, will be here briefly described, chiefly as encountered, from without inward.

Superficial Fascia.—Between whose layers are superficial arteries, veins, lymphatics, and nerves.

Superficial Layer of Superficial Fascia.—

Superficial Arteries.—Superficial external pudic; superficial epigastric; superficial circumflex iliac—all from the femoral.

Superficial Veins.—Internal or long saphenous—receiving superficial external pudic, superficial epigastric, and superficial circumflex iliac.

Superficial Inguinal Glands.—Superior set—along Poupart's ligament. Inferior set—around saphenous opening.

Superficial Nerves.—Ilio-inguinal; crural branch of genito-crural.

Deep Layer of Superficial Fascia.—Cribriform fascia—that portion attached to borders of saphenous opening, in fascia lata.

Fascia Lata.—Iliac portion—outer portion of fascia lata. Pubic portion—inner portion of fascia lata.

Saphenous Opening.—Opening in fascia lata formed by iliac and pubic portions uniting—through which opening a femoral hernia escapes after traversing the crural canal.

Poupart's Ligament or Crural Arch.—See Inguinal Hernia.

Gimbernat's Ligament.—See Inguinal Hernia.

Crural or Femoral Sheath.—Formed by continuation downward of transversalis fascia in front and iliac fascia behind the femoral vessels—the two layers being united and continuous directly to the outer side of the vessels; but at a short distance from these vessels, upon the inner side, a space intervenes, usually occupied by a lymphatic gland, between the femoral vein and the inner limit of the sheath, constituting the crural or femoral canal. The femoral sheath is redundant and funnel-shaped opposite Poupart's ligament, but is adherent to the areolar sheath of the femoral vessels about 2.5 cm. (1 inch) below the saphenous opening.

Relations of Crural or Femoral Sheath.—Anteriorly:—iliac portion of fascia lata. Posteriorly:—pubic portion of fascia lata. Externally:—genito-crural nerve pierces. Internally:—internal saphenous vein and lymphatics pierce.

Septa of Crural or Femoral Sheath.—Outer antero-posterior septum—between femoral artery and femoral vein. Inner antero-posterior septum—between femoral vein and femoral canal.

Compartments within Crural or Femoral Sheath.—Three compartments are formed by the two above septa. Outer compartment is occupied by femoral artery. Middle compartment—by femoral vein. Inner compartment—constitutes femoral canal—which is generally filled up by lymphatic glandular and areolar tissue in the normal state.

Deep Crural Arch.—A thickened portion of fascia transversalis, passing from center of Poupart's ligament, across the anterior aspect of the crural sheath, to be attached to the pectineal line posterior to the conjoint tendon.

Crural or Femoral Canal.—Space between femoral vein and inner wall of femoral sheath—that is, the inner compartment of the sheath of the femoral vessels. Anterior wall—formed by transversalis fascia covered by falciform process of iliac portion of fascia lata. Posterior wall—formed by iliac fascia, resting upon pubic portion of fascia lata. External wall—formed by internal septum between it and femoral vein. Internal wall—formed by union of transversalis and iliac fasciæ bounding the femoral canal and resting against the base or outer border of Gimbernat's ligament. Upper opening of femoral canal—is the femoral or crural ring, and is closed by the septum crurale (condensed areolar tissue). Lower opening of femoral canal—is the saphenous opening, and is closed by the cribriform fascia.

Crural or Femoral Ring.—Superior opening of the femoral canal into the peritoneal cavity—oval, transverse in direction, about 1.3 cm. (½ inch) in extent—and having following boundaries:—Anteriorly:—Poupart's ligament; deep crural arch. Posteriorly:—os pubis; pectineus; pubic portion of fascia lata. Internally:—external border of Gimbernat's ligament; conjoint tendon; transversalis fascia; deep crural arch. Externally:—inner antero-posterior fibrous septum on inner aspect of femoral vein.

Relations of Structures in the Near Neighborhood of the Ring.—Superiorly:—spermatic cord in male (round ligament in female); deep epigastric vessels. Externally:—femoral vein; deep epigastric vessels. Anteriorly:—communicating branch between deep epigastric and obturator arteries. Internally:—no important structure. Posteriorly:—no important structure.

Obturator Artery.—Arises in common with deep epigastric once in every three and one-half subjects—and in such cases it follows one of two courses:—(1) Runs down upon inner aspect of external iliac vein, along the outer side of crural ring—and is, therefore, in safety. (2) Runs along free border of Gim-

bernat's ligament, along the inner side of crural ring—and, therefore, is apt to be cut in an outward incision for relief of stricture.

Septum Crurale.—Condensed areolar tissue closing upper opening of femoral ring.

Subperitoneal Areolar Tissue.—

Peritoneum.—

GENERAL SURGICAL CONSIDERATIONS.

Course of Femoral Hernia.—Coming from within the abdominal cavity outward, the hernia passes at first vertically through the femoral canal, from the femoral ring to the saphenous opening—thence (because the femoral sheath here narrows and is more closely connected to the vessels, and because of the closer connection of superficial fascia and crural sheath to the saphenous opening) forward through the cribriform fascia—thence upward upon the falciform process of the fascia lata and Poupart's ligament. In manipulation for the reduction of such a hernia, pressure should be applied in the reverse directions.

Coverings of Femoral Hernia.—Passing from within outward, the hernia carries with it the following structures, in order:—(1) Within the abdomen:—peritoneum; subserous areolar tissue. (2) At femoral ring:—septum crurale. (3) In Femoral canal:—femoral sheath. (4) At saphenous opening:—cribriform fascia. (5) Upon thigh:—superficial fascia; skin.

Seats of Stricture.—(1) At the border of the saphenous opening;—(2) At the union of the falciform process of the fascia lata and the curved edge of Gimbernat's ligament;—(3) At the femoral ring.

Direction of Division of Stricture.—Upward and inward—for 4 to 6 mm. (2 to 3 lines).

OPERATION FOR THE RADICAL CURE OF FEMORAL HERNIA.

BASSINI'S METHOD.

Description.—The hernial sac is exposed, emptied of contents, ligated, excised, and the neck returned to the abdominal cavity. The femoral canal is then closed by suturing Poupart's ligament and the falciform process of the fascia lata, above and externally—to the pectineal fascia (pubic portion of fascia lata) below and internally.

Preparation.—Pubic region and region of the saphenous opening shaved.

Position.—Patient supine at edge of table. Surgeon on side of hernia. Assistant opposite.

Landmarks.—Poupart's ligament; femoral vessels; saphenous opening.

Incision.—Parallel with and just below Poupart's ligament, with its center over the saphenous opening.

Operation.—(1) Incise skin and superficial fascia—clamp and tie vessels—retract edges of wound—and expose the saphenous opening. (2) Dissect out the hernial sac from its canal, as high up as possible. Open its lower part and return its contents to the abdominal cavity. Draw the sac well down and transfix its neck with double chromic ligature. Cross the ends of the ligatures and ligate and cut off the neck safely below the ligature—the stump receding into the abdomen. (3) Pass kangaroo tendon, or chromic gut sutures, in a curved needle, in the following manner:—(a) Pass three sutures to approximate Poupart's ligament to the pectineal fascia—the first, near the pubic

spine—the second, about 5 mm. (nearly ¼ inch) to the outer side of the first—and the third, about 1 cm. (⅜ inch) to the inner side of the femoral vein—each passing through the pectineal fascia below. These sutures are left temporarily untied. (**b**) Pass three or four other sutures through the falciform process of the iliac portion of the fascia lata, externally—and the pectineal fascia (which is the same as the pubic portion of the fascia lata) internally—the lowest su-

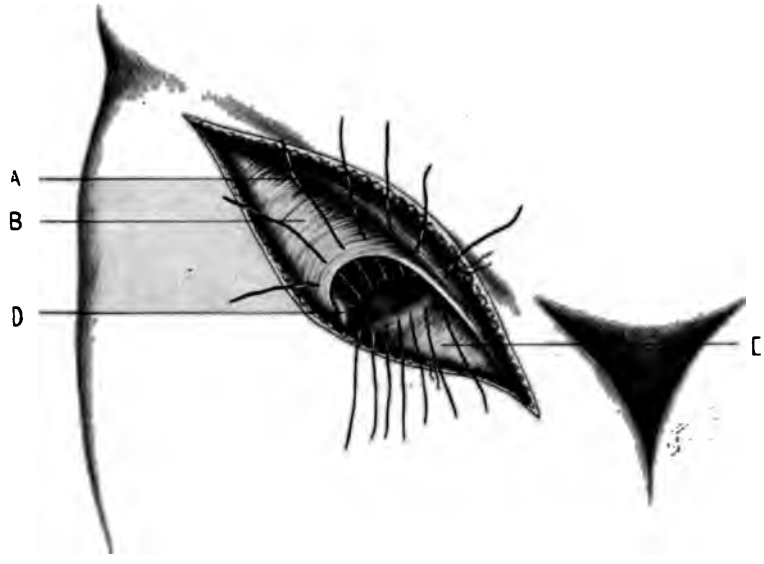

Fig. 559.—Bassini's Operation for Femoral Hernia:—A, Poupart's ligament; B, Falciform process of fascia lata; C, Pectineal fascia (pubic portion of fascia lata); D, Internal saphenous vein. Three sutures to right approximate Poupart's ligament to pectineal fascia. Remaining sutures pass through falciform process of fascia lata externally, and the pectineal fascia internally. (Note—the femoral opening is represented somewhat too far outward.)

ture passing just above the saphenous vein. (**4**) The upper sutures are then tightened and tied, bringing Poupart's ligament backward to the linea pectinea. The lower sutures are next tightened and tied, approximating the anterior and posterior walls of the femoral canal. (**5**) The skin incision is closed with silk. No drainage is used. (Fig. 559.)

III. UMBILICAL HERNIA.

SURGICAL ANATOMY.

Parts Passing through the Umbilicus Early in Fetal Life.—Urachus; umbilical arteries; umbilical vein; some of the fetal membranes and part of the digestive tract.

Congenital Umbilical Hernia.—A form of hernia existing at birth—owing to an error of development—the above conditions persisting.

Infantile Umbilical Hernia.—A form of hernia occurring in the early years of life (generally prior to ten years of age). It is that form of hernia

where, after birth, the intestines protrude through the umbilicus, which, in the latter part of fetal life, transmits only the umbilical vessels.

Method of Normal Closure of the Umbilicus.—(a) Several changes in the component structures take place:—(1) Contraction and shrinkage of the umbilical ring after birth—dividing, by its closure, the umbilical vessels running through the ring. (2) Clotting of the vessel contents—proliferation of connective tissue—and contraction of the muscle-fibers of the vessels. (b) As a result, a firm, fibrous scar is thus formed at the site of the umbilicus, with two sets of fibers decussating about it;—(1) One set of fibers decussating in the median line;—(2) Two sets of circular fibers interlacing upon the lateral aspects of the umbilicus.

Site of Umbilical Hernia.—Thus it is seen that the umbilical vessels and ring unite to form scar-tissue—which, remaining weak for a time—or subsequently submitted to strain—may yield to hernia. Hernia occurring after birth, therefore, may make its appearance by two routes:—(1) Exceptionally, hernia comes through the abdominal wall near to, but not through, the umbilicus. (2) Ordinarily, hernia comes through the umbilical ring—and usually through its upper third (where is the weaker scar-tissue about the umbilical vein)—and but seldom through the lower two-thirds (where is the stronger scar-tissue of the umbilical arteries and urachus).

Coverings of Umbilical Hernia.—(From within outward)—peritoneum; subserous areolar tissue; transversalis fascia; stretched and distended umbilical scar-tissue; superficial fascia, deprived of fat; integument.

OPERATION FOR THE RADICAL CURE OF UMBILICAL HERNIA

BY EXCISION OF SAC AND SUTURING OF FRESHENED EDGES OF RING.

Description.—The hernial sac, together with the redundant tissues covering it, is excised by an elliptical incision—followed by the suturing together of the freshened margins of the abdominal ring.

Preparation.—Site of hernia thoroughly scrubbed and shaved. Bowels emptied.

Position.—Patient supine at edge of table. Surgeon to patient's right. Assistant opposite.

Landmarks.—Site and form of hernia; umbilicus; median line.

Incision.—Elliptical in outline, with upper and lower ends in median line—and maximum separation of limbs of ellipse opposite the greatest width of the hernia, and determined by the size of the tumor. Laterally the lines of incision generally come near the base of the tumor, so as to remove the excess of skin.

Operation.—(1) Incise, at first, through skin and fascia only. (2) Carefully deepen the wound on one side until the abdominal aponeurosis (sheath of the recti) is reached—aiming to come down upon it a short distance to the outer side of the hernial neck. (3) Having once reached the rectal aponeurosis, similarly expose this aponeurosis and the neck of the hernial sac all around the outline of the ellipse. All bleeding is controlled by clamp and ligature. (4) The hernial sac is now incised and its contents dealt with as indicated. Adhesions are separated. Excess of omentum is ligated and excised. All remaining contents of the sac are returned to the abdomen—and kept in place by a large, anchored gauze pad—which is removed just before closure of the abdomen. (5) The entire sac, with the umbilicus and the coverings included in the ellipse, is now excised—dividing the peritoneum in an elliptical manner

about the neck of the sac. (6) The peritoneum—or the peritoneum and transversalis fascia together—is sutured with interrupted or continuous gut sutures. (7) The borders of the abdominal ring—formed by the sheaths and margins of the recti muscles—are freshened with curved scissors. The edges of the ring are then brought together with interrupted sutures of kangaroo tendon or chromic gut—using either the plain interrupted suture, or the mattress type. (8) The skin and fascia (unless the fascia be thick enough to require separate gut suturing) are sutured with interrupted silkworm-gut sutures. (9) The part is then well supported by an abdominal dressing.

Comment.—Various forms of operation have been devised—including the transposition of portions of the recti muscles over the site of hernia.

INDEX.

ABBE'S operation for stricture of esophagus, 562
Abdomen, puncture of, 651
Abdominal aorta, anatomy of, 78
ligation of, 80
section, anterior, through rectal sheath, 641
anterolateral, inferior, Fowler's angular incision, 645
anterolateral, inferior, Meyer's hockey-stick incision, 644
anterolateral, McBurney's intramuscular incision, 637
anterolateral, superior, oblique subcostal incision, 646
anterolateral, Weir's prolongation of anterolateral intramuscular incision through rectal sheath, 639
lateral, Vischer's lumbo-iliac incision, 646
median, 631
complications during, 636
inferior, Pfannenstiel's incisions, 643
Abdomino-pelvic region, operations upon, 624
general considerations, 629
Abdomino-pelvic wall, anatomy of, 624
operations upon, 624
instruments for, 631
visceral adhesions to, operation for, 650
Abscess, cerebellar, operation for, 497
cerebral, operation for, 496
Acupressure of veins, 129
Acupuncture for radical cure of aneurism, 124
Albert's method of gastrostomy, 760
Alexander's method of prostatectomy, 926
Allingham's operation for hemorrhoids, 754
Amputation, 229
about hands, general considerations, 294
Amputation, adjustment and suturing of musculo-periosteal or periosteo-capsular covering, 255
circular, cuff method, 263
division of muscles in, 239
modified, 264
ordinary, 261
drainage in, 258
dressing of wound, 259
elliptical, 273
flap, division of muscles in, 242
equal, of skin, 270
equal, of skin and muscle, 269
single, of skin, 269
single, of skin and muscles, 267
unequal, of skin, 272
unequal, of skin and muscles, 271
unequal rectangular, of skin and muscles, 272
freeing and retracting muscles in, 246
freeing skin and fascia in, 237
general considerations in, 229
general technic in, 232
hemorrhage in, control of, 230
incision of skin and fascia in, 234
instruments for, 229
irregular methods of, 275
ligating arteries and veins in, 253
location of limits of skin incisions in, 233
location of line of bone-section in, 232
making musculo-periosteal, or periosteo-capsular covering, 247
methods of, 259
selection of, 275
of arm at surgical neck, 322
general considerations, 319
in general, 319
lower third, 320
together with scapula and part of clavicle, 331
upper two-thirds, 321

Amputation of finger, little, with part of metacarpal, 296
with part of metacarpals, 295
of fingers, at first phalanx, by palmar flap, 286
at first phalanx, by short dorsal and palmar flaps, 287
at last phalanx, by palmar flap, 283
at last phalanx, in general, 283
at second phalanx, by palmar flap, 285
at second phalanx, by short dorsal and long palmar flaps, 285
at second phalanx, in general, 285
(excluding thumb), with parts of metacarpals, 297
general surgical considerations, 281
three innermost, with parts of metacarpals, 297
three inside, with parts of metacarpals, 296
two contiguous inside, with parts of metacarpals, 296
with parts of metacarpals, 295
of foot, general considerations, 347
of forearm, general considerations, 308
in general, 309
lower third, by circular method (cuff variety), 310
lower third, modified circular method, 309
upper two-thirds, 311
of leg, at lower third, 365
middle third, 367
supramalleolar region, 365
upper third, 368
upper third, bilateral hooded flaps, 370
of lower extremity, 333
of penis, partial, 898
total, 900
of thigh, at condyles of femur, 379
just above condyles of femur, 380
just below trochanters, 386
lower, middle, or upper third, anterior and posterior flaps, 382, 384
lower third, 382
of thumb, with part of metacarpal, 296
of toes, at first phalanx, 338
at first phalanx, circular method, 340
at first phalanx, oval method, 339
at last phalanx, 336
at last phalanx, by plantar flap, 336
at metatarsus, 348
at second phalanx, 338
Amputation of toes, at second phalanx, plantar flap, 338
general considerations, 335
with part of metatarsals, 347
of upper extremity, 279
osteoplastic, 394
oval, 265
position of assistant in, 229
position of patient in, 229
position of surgeon in, 229
preparation of patients in, 229
quilting of muscles, 256
racket, 266
removal of dressings, 259
removing splintered bone, 252
retraction of skin and fascia in, 238
retraction of soft parts, preparatory to sawing bone, 250
sawing bone, 251
stump, 276
bad, characteristics of, 277
cicatrix of, position, 278
function of, 278
good, qualities of, 276
suturing, 258
tissues of, contractility, 277
vitality of, conditions influencing, 277
treatment of nerves, tendons, and tags of muscle, fascia, and skin in, 255
trimming of flaps, 255
Anastomosis, intestinal, 675. See also *Entero-enterostomy.*
Anesthesia, regional, intraneural infiltration for, 151
paraneural infiltration for, 153
spinal, subarachnoid puncture for, 538
Aneurism, radical cure of, acupuncture for 124
introduction of wire for, 124
ligation for, 120
Matas' operation for, 121
needling for, 124
Angeiomata, injection of water at high temperature in, 125
Ankle-joint, anatomy, 358
excision of, 427
disarticulation of foot at, 360
disarticulations about, general considerations, 359
Annandale's osteoplastic resection of superior maxilla, 455
Anus artificial, closure of, operation for, 739

Anus, artificial, permanent, ileostomy for, 730
left inguinal colostomy for, 734
fistula in, operation for, 757
Aorta, abdominal, anatomy of, 78
ligation of, 80
Appendicectomy, 727
McBurney's method, 722
Appendix cæci, anatomy of, 658
Arm, amputations about, general considerations, 319
amputation of, 319
anatomy of, 317
Arterial forcipressure, 119
Arteriorrhaphy, 117
Arteriostrepsis, 120
Artery, abdominal aorta, anatomy of, 78
ligation of, 80
auricular, posterior, anatomy of, 42
ligation of, 42
axillary, anatomy of, 61
first part, ligation of, 62
third part, ligation of, 63
brachial, anatomy of, 64
ligation of, 65
carotid, common, anatomy of, 31
left, anatomy of, 32
ligation of, 33
right, anatomy of, 31
external, anatomy, 34
ligation of, 35
internal, anatomy of, 50
ligation of, 50
clearing of, for ligation, 22
dorsalis pedis, anatomy of, 106
ligation of, 107
epigastric, anatomy of, 92
ligation of, 93
exposure of, for ligation, 20
facial, anatomy of, 39
ligation of, 40
femoral, anatomy of, 93
common, ligation of, 95
superficial, ligation of, 97
gluteal, anatomy of, 88
ligation of, 89
iliac, common, anatomy of, 81
ligation of, 82
external, anatomy of, 90
external ligation of, 90
internal, anatomy of, 84
ligation of, 84
innominate, anatomy, 26
Artery, innominate, ligation of, 26
intercostal, anatomy of, 76
ligation of, 77
ligation of, 17
en masse, 117
for radical cure of aneurism, 120
in amputation, 253
intermediate, 117
temporary, 116
line of, 18
lingual, anatomy of, 37
ligation of, 38
mammary, internal, anatomy of, 59
internal, ligation of, 60
maxillary, internal, anatomy of, 44
ligation of, 44
meningeal, middle, anatomy of, 45
anterior branch, ligation of, 48
posterior branch, ligation of, 47, 49
topography of, 468
obturator, anatomy of, 85
ligation of, 85
occipital, anatomy of, 41
ligation of, 41
of cerebral hemorrhage, 461
opening sheath of, for ligation, 21
operations upon, 17
peroneal, anatomy of, 112
ligation of, 112
plantar, external, anatomy of, 113
ligation of, 114
internal, anatomy of, 115
ligation of, 115
popliteal, anatomy, 99
ligation of, 100
pressure of, 119
profunda femoris, anatomy of, 96
ligation of, 97
pudic, internal, anatomy of, 87
ligation of, 88
radial, anatomy of, 67
ligation of, 69
sciatic, anatomy of, 85
ligation of, 86
subclavian, anatomy of, 51
left, first portion, ligation of, 53
right, first portion, ligation of, 52
second portion, ligation of, 53
third portion, ligation of, 54
subscapular, anatomy of, 64
ligation of, 64
suprascapular, anatomy of, 58
ligation of, 59

Artery, suture of, 117
temporal, anatomy of, 43
ligation of, 43
thyroid, inferior, anatomy of, 57
ligation of, 57
superior, anatomy of, 37
ligation of, 37
tibial, anterior, anatomy of, 103
ligation of, 104
posterior, anatomy of, 108
ligation of, 109
torsion of, 120
transversalis colli, anatomy of, 57
ligation of, 58
ulnar, anatomy of, 73
ligation of, 74
vertebral, anatomy of, 55
ligation of, 56
Arthrectomy, 204
Arthrotomy, 204
Astragalus, excision of, 424
Auricular artery, posterior, anatomy of, 42
ligation of, 42
Axillary artery, anatomy of, 61
first part, ligation of, 62
third part, ligation of, 63
lymphatic glands, removal of, 139
region, anatomy of, 138

Bardenheuer's method of ligating innominate artery, 30
Barker's incision of hip-joint, 438
Bartholin's duct, anatomy of, 572
operations upon, 572
Bassini's operation for femoral hernia, 957
for oblique inguinal hernia, 948
Battle-Jalaguier-Kammerer method of anterior abdominal section, 641
Baum's operation for exposing facial nerve, 169
Bennett's modification of Howse's operation for hydrocele, 919
Billroth's method of pylorectomy, 795
Bisection of kidney, 849
Bladder, anatomy of, 875
drainage of, 892
perineal, 892
suprapubic, 892
urethral, 892
female, introduction of sound or catheter into, 879
Bladder, male, introduction of sound or catheter into, 878
operations upon, 875
general considerations, 877
instruments for, 878
puncture of, 879
stone in, lateral perineal cystotomy for 883
median perineal cystotomy for, 886
suture of, 887
Boeckel-Langenbeck excision of wrist-joint, 410
Bones, operations upon, 184
resection of, osteoplastic, 448
Bougie, esophageal, introduction of, 561
Bovée's method of uretero-ureterostomy, 866
Brachial artery, anatomy of, 64
ligation of, 65
plexus of nerves, anatomy of, 172
exposure of, 172
Brain areas, localization of, 469
bullet wound of, operation for, 493
parts of, 459
puncture of, exploratory, 488
skull, and scalp, anatomy of, 459
ventricles of, lateral, puncture and drainage of, 495
Braun-Loessen operation for exposure of superior maxillary nerve, 162
Breast female anatomy of, 579
excision of, ordinary, 585
excision of, partial, 581
excision of, radical, Halsted's operation, 582
excision of, radical, Warren's operation, 584
excision of, subcutaneous, 586
incision of, 580
operations upon, 579
operations upon, general considerations, 580
Bronchi, anatomy of, 622
operations upon, 622
Bronchotomy, 623
Bryant's method of colopexy, 742
of posterior thoracotomy, 593
operation for stricture of esophagus 562
Bullet wound of brain, operation for, 493
Bursæ, excision of, 228
incision of, 228
operations upon, 228
puncture of, 228

CALCULUS, vesical, lateral perineal cystotomy for, 883
median perineal cystotomy for, 886
Carden's amputation of thigh, 379
Cardiorrhaphy, 621
Carnochan's operation for exposure of superior maxillary nerve, 161
Cartilages, nasal, chondroplastic resection of, 455
Carotid artery, common, anatomy of, 31
left, anatomy, 32
ligation of, 33
right, anatomy of, 31
external, anatomy of, 34
ligation of, 35
internal, anatomy of, 50
ligation of, 50
Castration, 916
Catheter, eustachian, introduction of, 517
introduction of, into female bladder, 879
into male bladder, 878
into urethra, 878
Cerebellar abscess, operation for, 497
subarachnoid space, incision of, for drainage, 496
tumor, operation for, 499
Cerebellum, anatomy of, 461
function of, 472
Cerebral abscess, operation for, 496
hemispheres, cortex of basal surface of, functions, 471
extent of, 464
hemorrhage, artery of, 461
tumor, operation for, 498
Cerebrum, extent of, 465
fissures of, 459
lobes of, 460
mesial fissures and lobes of, 460
Cervical esophagectomy, partial, 560
esophagostomy, 556
esophagotomy, external, 558
nerves, first, second, third, posterior divisions, exposure of, 171
sympathetic ganglia and cord, anatomy of, 182
ganglia and cord, excision of, total, 183
Cheever's method of tonsillectomy, 565
Chiene's method of determining Rolandic fissure, 478
of exposing retropharyngeal space, 556
Chipault's method of cranio-cerebral localization, 472
Cholecystectomy, 821
Cholecystendysis, oblique or vertical subcostal incision, 819
Cholecystenterostomy, by Murphy button, 819
by simple suturing, 820
Cholecystolithotrity, 821
Cholecystotomy, oblique subcostal incision, 816
vertical subcostal incision, 817
Choledochotomy, 824
Cholelithotrity, 826
Chopart's disarticulation of anterior part of foot, 355
Circumcision, 896
Circumflex nerve, anatomy of, 173
exposure of, 173
Clavicle, excision of, 419, 420
Coccyx, excision of, 448
Cock's method of external perineal urethrotomy, 910
Coffey's method of entero-enterostomy, 701
Collar-bone, excision of, 419, 420
Colopexy, Bryant's method, 742
Colostomy, 731
inguinal, left, 732
inguinal, left, for permanent artificial anus, 734
inguinal, left, for temporary fecal fistula, 733
lumbar, left, 736
Convolution, frontal, ascending, topography of, 467
inferior, topography of, 467
middle, topography of, 467
superior, topography of, 467
Cranial contents, relations of, to cranial bones, 478
Craniectomy, partial, 487
Craniocerebral localization, Chipault's method, 472
Reid's method, 476
operations, general considerations, 478
instruments for, 480
region, operations upon, 459
topography, 464
Craniotomy, 480
circular, 481
for fracture of skull, 492
linear, 487
varieties of, 480
Cranium, landmarks of, 463
Crura cerebri, function of, 472

Crural nerve, anterior, anatomy of, 178
exposure of, 178
Cuneiform osteotomy, 187
Cushing's right-angled continuous suture of intestine, 668
Cystectomy, partial, 893
total, 894
Cystorrhaphy, 887
Cystotomy, 880
lateral perineal, for vesical calculus, 883
median perineal, for vesical calculus, 886
suprapubic, 880
Czerny-Lembert entero-enterostomy by interrupted suture, 685
interrupted suture of intestine, 666
Czerny's method of exposing tonsil, 566

DENTAL nerve, inferior, anatomy of, 166
exposure of, 166
Diaphragm, anatomy of, 595
exposure of, transthoracic, 596
operations upon, 595
Disarticulation about ankle-joint, general considerations, 359
about toes, general considerations, 335
at elbow-joint, anterior ellipse, 314
general considerations, 313
in general, 314
long antero-internal and short postero-external flaps, 316
posterior ellipse, 315
at hip-joint, anterior racket method, 393
external racket method, 392
general considerations, 388
Wyeth's method, 390
at knee-joint bilateral hooded flaps, 374
general considerations, 373
at shoulder-joint, anterior racket method, 327
external or deltoid flap, 330
external racket method, 329
general considerations, 325
in general, 326
at wrist-joint, anterior ellipse, 304
external lateral, or radial flap, 306
general considerations, 303
in general, 304
palmar flap, 305
of finger, index, at metacarpo-phalangeal joint, 290
index, with metacarpal, 298
inner, with metacarpal, 297
Disarticulation of finger, little, at metacarpo-phalangeal joint, 291
little, with metacarpal, 298
of fingers and thumb, at carpo-metacarpal joint, 302
at first interphalangeal joint, by palmar flaps, 286
at first interphalangeal joint, by short dorsal and long palmar flaps, 286
at first interphalangeal joint, in general, 286
at metacarpo-phalangeal joints, in general, 287
at metacarpo-phalangeal joints, oval method, 287
at second interphalangeal joint, by palmar flap, 284
at second interphalangeal joint, by short dorsal and long palmar flaps, 284
at second interphalangeal joint in general, 284
excluding thumb, with metacarpals, 301
three innermost, with metacarpals, 300
three inside, with metacarpals, 299
two contiguous inside, with metacarpals, 299
with metacarpals, 297, 301
of foot, anterior part, at medio-tarsal joint, 355
at ankle-joint, heel-flap, 360, 361
at subastragaloid joint, 356
at subastragaloid joint, heel flap, 358
at subastragaloid joint, large interno-plantar flap, 356
of lower extremity, 333
of thumb, at metacarpo-phalangeal joint, by oblique palmar flap, 290
at metacarpo-phalangeal joint, oval method, 289
with metacarpal, 298
of toe, great, at metatarso-phalangeal joint, 341
great, with metatarsal, 350
little, at metatarso-phalangeal joint, 341
little, with metatarsal, 352
with metatarsal, 350
of toes, at first interphalangeal joints, 338
at first interphalangeal joints, oval method, 338

Disarticulation of toes at metatarso-phalangeal joint, by equal short dorsal and plantar flaps, 342
at metatarso-phalangeal joints, 340
at second interphalangeal joint, 337
at second interphalangeal joint, by plantar flap, 337
at tarso-metatarsal joints, by short dorsal and long plantar flaps, 353
second, third, or fourth, at metatarso-phalangeal joint, 340
two adjoining, at metatarso-phalangeal joint, 342
two or three contiguous, with metatarsals, 353
with metatarsals, 349
of upper extremity, 279
Dorsalis pedis artery, anatomy of, 106
ligation of, 107
Dubrueil's method of disarticulation at wrist-joint, 306
Dura mater, venous sinuses of, 462

EAR, operations upon, 516
speculum, introduction of, for examination of membrana tympani, 517
Edebohls's method of nephropexy, 852
Ejaculatory ducts, anatomy of, 921
Elbowing, 672
Elbow-joint, anatomy of, 312
disarticulation at, 314
general considerations, 313
excision of, 412
Enterectomy, partial, 672
Entero-enterostomy, 675
by absorbable bobbins, 697
by absorbable buttons, 698
by absorbable mechanical devices left within intestine, 696
by Coffey's method, 701
by Czerny-Lembert interrupted suture, 685
by Halsted's inflatable rubber cylinder, 710
by Halsted's method of interrupted mattress suture, 686
by Laplace's intestinal anastomosis forceps, 718
by Lee's intestinal holder, 714
by Maunsell's invagination method, 688
by mechanical means, 710
by Murphy button, 703
Entero-enterostomy by non-absorbable mechanical devices left in intestine, 702
by simple continuous suture of all coats, followed by interrupted or continuous Lembert sutures of outer coats, 677
by simple suturing, 676
by Ullmann's modification of Maunsell's operation, 699
Enteroplasty, 742
Enterorrhaphy, 663
by continuous suture of all coats, followed by interrupted Lembert suturing of outer coats, 670
by Cushing's right-angled continuous suture, 668
by Czerny-Lembert interrupted suture, 666
by Halsted's interrupted mattress suture, 667
by Lembert's continuous suture, 668
by Lembert's interrupted suture, 665
for wounds of intestines, 670
Enterostomy, 727
inguinal, right, for permanent artificial anus, 730
for temporary fecal fistula, 728
Enterotomy, 663
Enucleation of eyeball, 515
Epididymes, anatomy of, 918
Epigastric artery, anatomy of, 92
ligation of, 93
Erasion of joint, 204
Esophageal bougie, introduction of, 561
Esophagectomy, cervical, partial, 560
Esophagoscopy, 561
Esophagostomy, cervical, 560
Esophagotomy, cervical, external, 558
internal, 561
thoracic, by posterior mediastinal osteoplastic flap operation, 623
Esophagus, anatomy of, 557
foreign bodies in, operation for, 561
operations upon, 557
general considerations, 558
instruments for, 558
stricture of, dilatation, direct, 562
dilatation, retrograde, 562
division, by string friction, Bryant's operation, 562
divulsion, direct, 562
divulsion, retrograde, 562
tubage, permanent, 562

Estlaender's operation of thoracoplasty, 604
Eustachian catheter, introduction of, 517
tube, operations upon, 516
Evisceration of eyeball, 516
Excision, 397
general considerations, 397
of ankle-joint, 427
external curved and internal angular incisions, 429
transversely curved external incision, 428
of astragalus, external angular and internal curved incision, 425
external curved incision, 424
of bones and joints about foot, 424
of bones and joints about toes, 422
of breast, female, ordinary, 585
partial, 581
radical, Halsted's operation, 582
radical, Warren's operation, 584
subcutaneous, 586
of bursæ, 228
of cervical sympathetic ganglia and cord, total, 183
of clavicle, 419
long axial incision, 420
of coccyx, 448
of collar-bone, 419
long axial incision, 420
of elbow-joint, 412
by posterior bayonet-shaped incision, 415
by posterior median incision, 413
of femur, 434
diaphysis, parts of, 435
of fibula, 431
by posterior vertical incision, 431
of fingers, 402
first interphalangeal joints, 406
first phalanges, 406
metacarpals, 407
metacarpo-phalangeal joints, 406
second interphalangeal joints, 403
second phalanges, 405
terminal phalanges, 403
of hand, 406
of hip-joint, 435
anterior straight incision, 438
external straight incision, 436
posterior angular incision, 439
of humerus, 416
long external incision, 417
of ileo-cæcum, 720
Excision of index-finger, second interphalangeal joint, 404
second phalanx, 405
of knee-joint, 432
curved transverse anterior incision, 433
of little finger, metacarpal, 408
second interphalangeal joint, 405
second phalanx, 406
of maxilla, inferior, 443, 445
inferior, single incision along inferior and posterior borders, 445
superior, 440, 441
superior, median incision, 441
of os calcis, 427
of parotid gland, 568
of patella, 432
of radio-ulnar articulation, superior, 416
of radius, 412
of rectum, 745. See also *Rectectomy*.
of rib, 447
of rib and costal cartilage, 447
of scapula, 420
by incisions along spine, 421
of scrotum, partial, 913
of shoulder-blade, 420
by incisions along spine, 421
of shoulder-joint, 417
by anterior oblique incision, 418
of sublingual gland, 572
of submaxillary gland, 571
of temporomaxillary articulation, 444
of tendon-sheaths, 224
of thumb, metacarpal, 408
of tibia, 430
by internal vertical incision, 430
of toes, first interphalangeal joint, 423
first phalanx, 424
metatarsal bones, 424
metatarso-phalangeal joints, 424
second interphalangeal joint, 423
second phalanges, 423
terminal phalanges, 423
of tongue, general considerations, 518
instruments for, 519
limited portions, 520
through mouth, after preliminary ligation of lingual arteries, 522
through mouth, without preliminary ligation of lingual arteries, 520
together with cervical and submaxillary glands, 522
of ulna, 411
of veins, 129

Excision of wrist-joint, 408
by radial and ulnar dorsal incision, 409
by single dorso-radial incision, 410
open method, 401
subperiosteal, 398
Exposure of brachial plexus of nerves, in neck, 172
of cervical nerves, first, second, third, posterior divisions, 171
of circumflex nerve, 173
of crural nerve, anterior, 178
of dental nerve, inferior, at mental foramen, 168
inferior, in mouth, 166
inferior, through ascending ramus of inferior maxilla, 167
of facial nerve, in front of mastoid process, 169
of gluteal nerve, superior, 179
of infraorbital nerve, 163
of intercostal nerve, 178
of interosseous nerve, 177
of lingual nerve, in mouth, 168
of maxillary nerve, inferior, 164
superior, by antral route, 161
superior, by orbital route, 162
superior, by pterygomaxillary route, 162
of median nerve, at bend of elbow, 174
in middle of arm, 174
of musculocutaneous nerve, 173
of musculospiral nerve, 176
of obturator nerve, 179
of occipitalis major nerve, 171
of popliteal nerve, external, 181
internal, 180
of pudic nerve, 179
of radial nerve, 177
of retropharyngeal space, 556
of sciatic nerve, great, 179
of spinal accessory nerve, 170
of supraorbital nerve, 160
of tibial nerve, anterior, 182
posterior, behind, internal malleolus, 181
posterior, between origin and ankle, 180
of ulnar nerve, above middle of arm, 175
just above internal condyle of humerus, 175
Eyeball enucleation of, 515
evisceration of, 516
operations upon, 514
Facial artery, anatomy of, 39
ligation of, 40
nerve, anatomy of, 169
exposure of, 169
topography of, 468
Fallopian tubes, anatomy of, 941
Farabeuf's amputation of leg at upp. third, 368
disarticulation at elbow-joint, 314
disarticulation of foot, 356
method of amputating leg at lower third, 365
method of disarticulation of index-finger at metacarpo-phalangeal joint, 290
method of disarticulation of little finger at metacarpo-phalangeal joint, 291
method of disarticulation of thumb at metacarpophalangeal joint, 290
Fascia in amputation, treatment of, 255
operation upon, 227
Fasciotomy, 227
Fecal fistula, closure of, operation for, 739
temporary, ileostomy for, 728
temporary, left inguinal colostomy for, 733
Femoral artery, anatomy of, 93
common, ligation of, 95
superficial, ligation of, 97
hernia, 955. See also *Hernia, femoral.*
Femur, excision of, 434
excision of parts of diaphysis, 435
Fergusson's excision of superior maxilla, 441
Fibula, excision of, 431
Finger, amputation of, with part of metacarpals, 295, 296
index-, disarticulation of, at metacarpo-phalangeal joint, 290
disarticulation of, with metacarpal, 298
second interphalangeal joint, excision of, 404
second phalanx, excision of, 405
inner, disarticulation of, with metacarpal, 297
little, disarticulation of, at metacarpo-phalangeal joint, 291
disarticulation of, with metacarpal, 298
metacarpal of, excision, 408
second interphalangeal joint, excision of, 405
second phalanx, excision of, 406
Fingers, amputation of, at first phalanx, 286
at last phalanx, 283

Fingers, amputation of, at second phalanx, 285
excluding thumb, with parts of metacarpals, 297
general surgical considerations, 281
with parts of metacarpals, 295
anatomy of, 279
and thumb, disarticulation of, at carpo-metarcarpal joint, 302
disarticulation of, at first interphalangeal joint, 286
at metacarpo-phalangeal joints, 287
at second interphalangeal joint, 284
excluding thumb, with metacarpals, 301
with metacarpals, 297
excision of, 402
excision of first interphalangeal joints, 406
excision of first phalanges, 406
excision of metacarpals, 407
excision of metacarpo-phalangeal joints, 406
excision of second interphalangeal joints, 403
excision of second phalanges, 405
excision of terminal phalanges, 403
three innermost, amputation of, with parts of metacarpals, 297
three innermost, disarticulation of, with metacarpals, 300
three inside, amputation of, with parts of metacarpals, 296
three inside, disarticulation of, with metacarpals, 299
two contiguous inside, amputation of, with part of metacarpals, 296
two contiguous inside, disarticulation of, with metacarpals, 299
Fissure, frontal, inferior, topography of, 466
superior, topography of, 466
intraparietal, topography of, 466
longitudinal, great, anatomy of, 459
topography of, 465
parieto-occipital, topography of, 466
postcentral, topography of, 466
precentral, topography of, 466
Rolandic, anatomy of, 460
topography of, 465
Sylvian, anatomy of, 459
topography of, 465
temporo-sphenoidal, superior, topography of, 467
transverse, great, topography of, 465
Fissures, mesial, and lobes of cerebrum, 460
of cerebrum, 459
Fistula, fecal, closure of, operation for, 739
temporary, ileostomy for, 728
temporary, left inguinal colostomy for, 733
Fistula-in-ano, operation for, 757
Foot, amputations about, general considerations, 347
anatomy of, 344
anterior part, disarticulation of, at medio-tarsal joint, 355
disarticulation of, at ankle-joint, 360
at subastragaloid joint, 356
excision of bones and joints about, 424
osteoplastic resection of, 452
Foramen of Winslow, anatomy of, 648
Forcipressure, arterial, 119
venous, 129
Forearm, amputation of, 309
amputations about, general considerations, 308
anatomy of, 307
Foreign bodies in esophagus, operation for, 561
in larynx, operation for, 548
in trachea, operation for, 553
Fowler's method of antero-lateral abdominal section, 645
method of uretero-rectostomy, 870
Fracture of skull, trephining for, 492
ununited, of olecranon, operation for, 200
of patella, operation for, by wiring or suturing, 198
of patella, operation for, Stimson's method, 197
operation for, by frame ligatures of bone, 196
operation for, by intramedullary pegging, 196
operation for, by ligation of bone, 195
operation for, by ligature and suture, 196
operation for, by nailing, pegging, or screwing ends of bones, 193
operation for, by Parkhill's clamp, 194
operation for, by resection of ends of bones, 189
operation for, by suturing, 193
operation for, by wiring ends of bones, 191
operations for, 188

GALL-BLADDER, anatomy of, 815
operations upon, 815
operations upon, general considerations, 816
operations upon, instruments for, 804
Gall-ducts, anatomy of, 823
operations upon, 823
operations upon, general considerations, 823
Ganglion, basal, function of, 472
topography of, 467
cervical sympathetic, and cord, anatomy of, 182
cervical sympathetic, and cord, excision of, total, 183
gasserian, anatomy of, 155
extracranial exposure of, 158
intracranial exposure of, 155
Meckel's, anatomy of, 160
operations upon, 141
Gasserian ganglion, anatomy of, 155
extracranial exposure of, 158
intracranial exposure of, 155
Gastrectomy, partial, followed by gastro-jejunostomy, closure of abdomen, and jejuno-jejunostomy, 798
total, 799
Gastric ulcer, operation for, 800
perforated, operation for, 800
Gastro-enterostomy, 776
anterior, by Murphy button, followed by Jaboulay-Braun method of intestinal anastomosis, 781
Wölfler's operation, 777
posterior, by Murphy button, 785
by von Hacker's method, 783
Gastrogastrostomy, Wölfler's method, 785
Gastrolysis, 789
Gastropexy, 788
Gastroplasty, 789
Gastroplication, 787
Gastrorrhaphy, 765
Gastrostomy, 766
Albert's method, 769
Hahn's method, 769
Kader's method, 774
Marwedel's method, 772
Ssabanajew-Franck's method, 767
Witzel's method, 769
Gastrotomy by median incision, 762
by oblique subcostal incision, 764
Genital organs, female, operations upon, 929
male, operations upon, 895
Gluteal artery, anatomy of, 88
ligation of, 89
nerve, superior, exposure of, 179
Gouley's method of external perineal urethrotomy, 908
Grafting, nerve-, 149
omental, 654
tendon-, 221
Gustatory nerve, anatomy of, 168
exposure of, 168
Guyon's supramalleolar method of amputating leg, 365

HAHN'S method of gastrostomy, 769
Halsted's inflatable rubber cylinder, entero-enterostomy by, 710
interrupted mattress suture of intestine, 667
method of entero-enterostomy by interrupted mattress suture, 686
operation for oblique inguinal hernia, 953
radical excision of breast, 582
Hand, anatomy of, 291
excision of, 406
Hands, amputations about, general considerations, 294
Hartley-Krause exposure of gasserian ganglion, 155
Hartley's method of ligating intercostal artery, 78
of preliminarily excising spinous process, 535
Head and face, bony (air) sinuses of, operations upon, 500
operations upon, 459
Heart, anatomy of, 619
and pericardium, exposure of, by excision of left fifth costal cartilage, 617
and pericardium, exposure of, by osteo-thoracoplastic resection of anterior chest-wall, 619
operations upon, 619
puncture of, 620, 621
right auricle of, paracentesis of, 620
right ventricle of, paracentesis of, 621
suture of, 621
Heineke-Mikulicz method of pyloroplasty, 789
Hemorrhage, cerebral, artery of, 461
in amputations, control of, 230
intracranial, operation for, 489

Hemorrhoids, clamp and actual cautery for, 756
excision of, Whitehead's operation, 755
ligation and excision of, Allingham's method, 754
Hepatectomy, partial, 814
Hepatopexy, 814
Hepatorrhaphy, 813
Hepatotomy, 805
anterior subcostal transperitoneal, 806
Hernia, femoral, anatomy of, 955
Bassini's operation for, 957
operations for, 955
general considerations, 957
inguinal, anatomy of, 945
oblique, Bassini's operation for, 948
Halsted's operation for, 953
operations for, 945
general considerations, 946
instruments in, 948
operations for, 945
umbilical, anatomy of, 958
operation for, 959
Hey's amputation of leg at middle third, 367
disarticulation of toes, 354
Hip-joint, anatomy of, 386
disarticulation at, 390
general considerations, 338
excision of, 435
Humerus, excision of, 416
Hydrocele, Volkmann's operation for, 914
Von Bergmann's operation for, 915
Hysterectomy, abdominal, partial, 933
total, 935
vaginal, total, 935
Hysterosalpingo-oöphorectomy, partial abdominal, 933
total abdominal, 935

ILEOCÆCUM, excision of, 720
Ileostomy, for permanent artificial anus, 730
for temporary fecal fistula, 728
Iliac artery, common, anatomy of, 81
ligation of, 82
external, anatomy of, 90
ligation of, 90
internal, anatomy of, 84
ligation of, 84
Implantation of ureters, 868
into bladder, 869
into large intestine, 870
upon skin of loin or abdomen, 873
Incision of bursæ, 228
Infraorbital nerve, exposure of, 163
Inguinal hernia, 945. See also *Hernia, inguinal.*
lymphatic glands, removal of, 140
Innominate artery, anatomy of, 26
ligation of, 26
Intercostal artery, anatomy of, 76
ligation of, 77
nerve, anatomy of, 177
exposure of, 178
Interosseous nerve, anatomy of, 177
exposure of, 177
Intestinal anastomosis, 675. See also *Entero-enterostomy.*
approximation, 675. See also *Entero-enterostomy.*
implantation, 675. See also *Entero-enterostomy.*
Intestines, adhesions to, operation for, 651
anatomy of, 655
large, anatomy of, 658
operations upon, 655
general considerations, 662
instruments for, 662
small, anatomy of, 655
suture of, 663. See also *Enterorrhaphy.*
wounds of, enterorrhaphy for, 670
Intraneural infiltration for regional anesthesia, 151
Intraparietal fissure, topography of, 466
Intravenous infusion of salt solution, 130
Intubation of larynx, 547
Island of Reil, anatomy of, 460
topography of, 467

JABOULAY-BRAUN'S method of multiple lateral intestinal anastomosis, 709
Jobert's operation for ligating popliteal artery, 100
Joints, erasion of, 204
operations upon, 204
puncture of, 204
resection of, osteoplastic, 448
Jonnesco's operation for excision of cervical sympathetic ganglia and cord, 183

KADER'S method of gastrostomy, 774
Keen's operation for exposure of posterior divisions of first, second, and third cervical nerves, 171

Kidneys anatomy of, 837
bisection of, 849
exposure of, by abdomino-lumbar operation, 847
retroperitoneal, by Koenig's angular lumbo-abdominal incision, 844
retroperitoneal, by lumbar intramuscular method, 845
retroperitoneal, by oblique lumbar incision, 841
transperitoneal, by median abdominal section, 847
transperitoneal, by vertical incision in linea semilunaris, 845
operations upon, 837
general considerations, 841
instruments for, 841
puncture of, exploratory, 848
suture of, 851
Knee-joint, anatomy of, 381
disarticulation at, 374
general considerations, 373
excision of, 432
Kocher's excision of hip-joint, 439
of tongue, 522
method of complete thyroidectomy, 575
of lateral pharyngotomy, 554
of partial thyroidectomy, 573
of pylorectomy, 792
Koenig's method of exposing kidney, 844
Kraske's method of excision of rectum, 745

LAMINECTOMY, 530
Langenbeck's excision of elbow-joint, 413
of hip-joint, 436
osteoplastic resection of superior maxilla, 456
Langenbuch's method of exposing kidney, 845
Laplace's intestinal anastomosis forceps, entero-enterostomy by, 718
Larrey's disarticulation at shoulder-joint, 320
Laryngectomy, complete, 545
partial, 546
Laryngoscopy, 548
Laryngotomy, 543
suprathyroid, 548
Laryngotracheotomy, 548
Larynx, anatomy of, 541
artificial, introduction of, 548
foreign bodies in, operation for, 548
Larynx, intubation of, 547
operations upon, 541
tamponing of, 548
Lauenstein's excision of ankle-joint, 428
Lee's intestinal holder, entero-enterostomy by, 714
Leg, amputation of, at supramalleolar region, 365
general considerations, 364
lower third, 365
middle third, 367
upper third, 368
anatomy of, 362
Lembert's continuous suture of intestine, 668
interrupted suture of intestine, 665
Ligaments, lengthening of, 226
operations upon, 226
shortening of, 226
suture of, 226
Ligation of abdominal aorta, by retroperitoneal method, 81
by transperitoneal method, 80
of artery, 17
after-treatment, 25
closure of wound, 25
comment, 26
control of circulation preliminary to, 18
dangers, 25
en masse, 117
for radical cure of aneurism, 120
general considerations, 17
in amputation, 253
incision, 19
indications, 17
instruments for, 17
intermediate, 117
materials for, 18
passing ligature, 22
position of patient, 17
preparation of patient, 17
results, 25
temporary, 116
tying ligature, 24
varieties, 17
of auricular artery, posterior, behind ear, 42
of auricular artery, posterior, near origin, 42
of axillary artery, first part, 62
of axillary artery, third part, 63
of brachial artery, at bend of elbow, 66
of brachial artery, in middle of arm, 65

Ligation of carotid artery, common, above omohyoid, 33
of carotid artery, common, below omohyoid, 34
of carotid artery, external, above digastric, 36
of carotid artery, external, below digastric, 35
of carotid artery, internal, near origin, 50
of dorsalis pedis, just below ankle-joint, 107
of epigastric artery, near origin, 93
of facial artery, near origin, 40
of facial artery, over inferior maxilla, 40
of femoral artery, common, at base of Scarpa's triangle, 95
of femoral artery, superficial, at apex of Scarpa's triangle, 97
of femoral artery, superficial, in Hunter's canal, 98
of gluteal artery, on buttock, 89
of iliac artery, common, by retroperitoneal operation, 82
of iliac artery, common, by transperitoneal operation, 84
of iliac artery, external, by retroperitoneal route, 90
of iliac artery, external, by transperitoneal route, 92
of iliac artery, internal, by retroperitoneal operation, 84
of iliac artery, internal, by transperitoneal operation, 84
of innominate artery, by angular incision, 26
of innominate artery, by oblique incision, 28
of innominate artery, by partial bony resection, through oblique incision, 29
of innominate artery, by partial bony resection, through transverse and vertical incisions, 30
of innominate artery, by splitting of manubrium sterni, 30
of intercostal artery, by intercostal incision, 77
of intercostal artery, by subperiosteal excision of rib, 78
of lingual artery, beneath hyoglossus, 38
of lingual artery, near origin 38
of mammary artery, internal, in second intercostal space, 60
Ligation of maxillary artery, internal, 44
of meningeal artery, middle, anterior branch, 48
of meningeal artery, middle, posterior branch, 49
of meningeal artery, middle, trunk of, 47
of obturator artery, at thyroid foramen, 85
of occipital artery, behind mastoid process, 41
of occipital artery, near origin, 41
of omentum, 653
of peroneal artery, in middle of leg, 112
of plantar artery, external, at origin, 114
of plantar artery, external, in sole of foot, 115
of plantar artery, internal, at origin, 115
of plantar artery, internal, in sole of foot, 115
of popliteal artery, in lower part, 101
of popliteal artery, in upper part, 100
of profunda femoris, near origin, 97
of pudic artery, internal, in perineum, 88
of pudic artery, internal, on buttock, 88
of radial artery, at lower third, 70
of radial artery, at middle third, 70
of radial artery, at upper third, 69
of radial artery, deep palmar arch, 72
of radial artery, on back of hand, 71
of sciatic artery, upon buttock, 86
of sinus, lateral, 490
of subclavian artery, left, first portion, 53
of subclavian artery, right, first portion, 52
of subscapular artery, 64
of suprascapular artery, at outer margin of sternomastoid, 59
of temporal artery, just above zygoma, 43
of thoracic duct, 133
of thyroid artery, inferior, 57
of thyroid artery, superior, 37
of tibial artery, anterior, in lower third, 105
of tibial artery, anterior in middle third, 105
of tibial artery, anterior, in upper third, 104
of tibial artery, posterior, behind internal malleolus, 111
of tibial artery, posterior, in lower third, 110
of tibial artery, posterior, in middle third, 109

Ligation of tibial artery, posterior, in upper third, 109
of transversalis colli, at outer margin of sternomastoid, 58
of ulnar artery, in lower third, 76
of ulnar artery, in middle third, 74
of ulnar artery, superficial palmar arch, 76
of veins, en masse, 129
in amputation, 253
lateral, 127
temporary, 128
transverse, 128
of vertebral artery, near origin, 56
Ligature, passing, in ligation of artery, 22
tying of, in ligation of artery, 24
Linea alba, anatomy of, 627
Linear osteotomy, by open method, 187
by subcutaneous method, 185
Lingual artery, anatomy of, 37
ligation of, 38
nerve, anatomy of, 168
exposure of, 168
Lisfranc's disarticulation of toes, 353
Lister's modification of Carden's amputation of thigh, 379
Litholapaxy, 888
Lithotrity, 888
Liver, anatomy of, 800
exposure of, by anterior subcostal transperitoneal route, 808
by chondro-plastic resection of right costal arch, 813
by intercostal subpleural route, 809
by lateral subcostal transperitoneal route, 809
by subpleural route, 810
by transpleural route, 812
operations upon, 800
general considerations, 802
instruments for, 804
puncture of, exploratory, 804
suture of, 813, 814
Lobuli testis, anatomy of, 913
Loreta's method of divulsion of stomach, 791
Lungs, anatomy of, 609
operations upon, 609
Lymphatic glands, axillary, removal of, 139
inguinal, removal of, 140
of neck, isolated, removal of, 137
of neck, removal of, 135
operations upon, 132
vessels, operations upon, 132
MACEWEN'S operation for radical cure of aneurism, 124
Mammary artery, internal, anatomy of, 59
ligation of, 60
gland, female, operations upon, 579. See *Breast, female.*
Markoe's method of uretero-ureterostomy, 866
Marwedel's method of gastrostomy, 772
Mastoid antrum, anatomy of, 501
exposure of, antrum operation of Schwartze, 504
exposure of, Schwartze-Stacke operation, 506
operations upon, 500
operations upon, general considerations, 503
operations upon, instruments for, 504
cells, anatomy of, 502
exposure of, antrum operation of Schwartze, 504
exposure of, Schwartze-Stacke operation, 506
operations upon, 500
operations upon, general considerations, 503
operations upon, instruments for, 504
Matas's apparatus for paraneural infiltration, 153
method for radical cure of aneurism, 121
Maunsell's invagination method of entero-enterostomy, 688
Maxilla, inferior, excision of, 443, 445
osteoplastic resection of, 457
superior, excision of, 440, 441
osteoplastic resection of, 454, 455, 456
Maxillary artery, internal, anatomy of, 44
ligation of, 44
nerve, inferior, anatomy of, 164
exposure of, 164
superior, anatomy of, 160
exposure of, 161
sinuses, anatomy of, 511
exposure of, through facial aspect, above alveolar margin, 513
exposure of, through second molar tooth, 514
operations upon, 511
operations upon, general considerations, 512
operations upon, instruments for, 513

McBurney's method of antero-lateral abdominal section, 637
of appendicectomy, 722
Meatotomy, 904
Meckel's ganglion, anatomy of, 160
Median nerve, anatomy of, 174
exposure of, 174
Mediastinum, anterior, anatomy of, 588
operations upon, 588
middle, anatomy of, 592
operations upon, 592
posterior, anatomy of, 592
operations upon, 592
superior, anatomy of, 587
operations upon, 587
Medulla, function of, 472
Membrana tympani, anatomy of, 516
introduction of ear speculum for examination of, 517
Meningeal artery, middle, anatomy of, 45, 461
anterior branch, ligation of, 48
posterior branch, ligation of, 49
topography of, 468
trunk of, ligation of, 47
Mesentery, anatomy of, 654
operations upon, 654
general considerations, 655
Meyer's method of inferior antero-lateral abdominal section, 644
Mikulicz's method of exposing tonsil, 566
Milton's osteoplastic anterior mediastinotomy, 588
Mixter's operation for exposure of inferior maxillary nerve, 164
Motor center, exposure of, operation for, 494
Mott's method of ligating innominate artery, 26
Murphy button, anterior gastro-enterostomy by, followed by Jaboulay-Braun method of intestinal anastomosis, 781
cholecystenterostomy by, 819
entero-enterostomy by, 703
posterior gastro-enterostomy by, 785
Muscle in amputation, treatment of, 255
suture of, 207
Muscle-lengthening, 208
Muscles, operations upon, 207
Musculocutaneous nerve, anatomy of, 173
exposure of, 173
Musculospiral nerve, anatomy of, 176
exposure of, 176
Myorrhaphy, 207
Myotomy, 207

NASAL cartilages, chondroplastic resection of, 455
cavities, operations upon, 518
Naso-lambdoidal line, topography of, 468
Neck, anatomy of, 541
antero-lateral aspect, anatomy of, 133
lymphatic glands of, isolated, removal of, 137
removal of, 135
operations upon, 541
instruments for, 542
Needling for radical cure of aneurism, 124
Neoplasms, vascular, injection of water at high temperature in, 125
Nephrectomy, partial, oblique lumbar incision, 859
subscapular, 860
total, by anterior transperitoneal operation, 860
by oblique lumbar incision, 858
Nephrolithotomy, 850
Nephropexy, by simple suturing, 857
Edebohls's method, 852
Tuffier's method, 856
Nephrorrhaphy, 851
Nephrotomy, 849
Nerve, circumflex, anatomy of, 173
circumflex, exposure of, 173
compressed, operation for, 151
crural, anterior, anatomy of, 178
crural, anterior, exposure of, 178
dental, inferior, anatomy of, 166
dental, inferior, exposure of, 166
facial, anatomy of, 169
exposure of, 169
topography of, 468
gluteal, superior, exposure of, 179
in amputation, treatment of, 255
infraorbital, exposure of, 163
intercostal, anatomy of, 177
exposure of, 178
interosseous, anatomy of, 177
exposure of, 177
lingual, anatomy of, 168
exposure of, 168
maxillary, inferior, anatomy of, 164
maxillary, inferior, exposure of, 164

Nerve, maxillary, superior, anatomy of, 160
maxillary, superior, exposure of, 161
median, anatomy of, 174
exposure of, 174
musculocutaneous, anatomy of, 173
exposure of, 173
musculospiral, anatomy of, 176
exposure of, 176
obturator, exposure of, 179
occipitalis major, anatomy of, 170
occipitalis major, exposure of, 171
popliteal, external, anatomy of, 181
popliteal, external, exposure of, 181
popliteal, internal, anatomy of, 180
popliteal, internal, exposure of, 180
pudic, exposure of, 179
radial, anatomy of, 176
exposure of, 177
sciatic, great, anatomy of, 179
sciatic, great, exposure of, 179
sphenopalatine, anatomy of, 160
spinal accessory, anatomy of, 170
spinal accessory, exposure of, 170
supra-orbital, anatomy of, 160
exposure of, 160
suture of, 144
tibial, anterior, anatomy of, 182
tibial, anterior, exposure of, 182
tibial, posterior, anatomy of, 180
tibial, posterior, exposure of, 180
trifacial, extracranial exposure of, 158
intracranial exposure of, 155
ulnar, anatomy of, 175
exposure of, 175
Nerve-avulsion, 143
Nerve-grafting, 149
Nerve-implantation, 149
Nerve-roots, posterior, intraspinal partial neurectomy of, 539
Nerves, brachial plexus of, anatomy, 172
exposure of, 172
cervical, first, second, third, posterior divisions, exposure of, 171
operations upon, 141
Neurectasy, 142
Neurectomy, 142
intraspinal, partial, of posterior nerve-roots, 539
Neuroplasty, 147
Neurorrhaphy, 144
Neurotomy, 141
Nose, operations upon, 518

OBTURATOR artery, anatomy of, 85
ligation of, 85
nerve, exposure of, 179
Occipital artery, anatomy of, 41
ligation of, 41
sinus, anatomy of, 462
Occipitalis major nerve, anatomy of, 170
exposure of, 171
O'Dwyer's method of intubation of larynx, 547
Olecranon, fracture of, ununited, operation for, 200
Ollier's excision of elbow-joint, 415
excision of wrist-joint, 409
Omentum, adhesions to, operation for, 651
anatomy of, 652
grafting with, 654
ligation of, 653
operations upon, 652
Oöphorectomy, 942
Orbit, anatomy of, 514
Orchidectomy, 916
Os calcis, excision of, 427
Osteoplastic amputations, 394
Osteoplasty, 202
Osteotomy, 184
cuneiform, 187
indications for, 184
instruments for 184
linear, by open method, 187
by subcutaneous method, 185
position in, 185
preparation of patient for, 185
varieties of, 184
Ovariectomy, 942
Ovaries, anatomy of, 941
operations upon, 941

PANCREAS, anatomy of, 833
operations upon, 833
Pancreatectomy, by gastrocolic route, 836
Pancreatotomy, by gastrocolic route, 835
Paracentesis abdominis, 651
of right auricle of heart, 620
of right ventricle of heart, 621
pericardii, 615
thoracis, 601
tunicæ vaginalis, 913
tympani, 517
vesicæ, 879
Paraneural infiltration for regional anesthesia, 153

Paravicini's method of exposing inferior dental nerve, 166
Parieto-occipital fissure, anatomy of, 460
topography of, 466
Parkin's incision of cerebellar subarachnoid space for drainage, 496
Parotid gland, anatomy of, 567
excision of, 568
operations upon, 567
Patella, excision of, 432
fracture of, ununited, operation for, by wiring or suturing, 198
fracture of, ununited, operation for, Stimson's method, 197
Pelviotomy, 850
Penis, amputation of, partial, 898
total, 900
anatomy of, 895
operations upon, 895
instruments for, 895
Pericardiorrhaphy, 619
Pericardiotomy, through intercostal incision, 616
Pericardium, anatomy of, 614
Pericardium and heart, exposure of, by excision of left fifth costal cartilage, 617
Pericardium and heart, exposure of, by osteothoracoplastic resection of anterior chest-wall, 619
operations upon, 614
puncture of, 615
suture of, 619
Peritoneum, adhesions of, operations for, 649
anatomy of, 647
operations upon, 647
general considerations, 649
Peroneal artery, anatomy of, 112
ligation of, 112
Pfannenstiel's method of median inferior abdominal section, 643
Pharyngotomy, lateral, 554
median, 554
subhyoid, 555
Pharynx, anatomy of, 553
operations upon, 553
instruments for, 553
Phlebectomy, 129
Phleborrhaphy, 126
Phlebostrepsis, 129
Phlebotomy, 126
Piles, operations for, 754. See also *Hemorrhoids.*
Pirogoff's disarticulation of foot at ankle-joint, 361
Plantar artery, external, anatomy of, 113
artery, external, ligation of, 114
artery, internal, anatomy of, 115
artery, internal, ligation of, 115
Pleura, anatomy of, 599
operations upon, 599
Pleuracentesis, 601
Pleurotomy, 601
Plexus of nerves, brachial anatomy of, 172
exposure of, 172
Plexuses, operation upon, 141
Pneumectomy, partial, through osteothoracoplastic flap, 612
Pneumotomy, through thoracoplastic flap, 611
Poggi's method of uretero-ureterostomy, 866
Pons, function of, 472
Popliteal artery, anatomy of, 99
ligation of, 100
nerve, external, anatomy of, 181
nerve, external, exposure of, 181
nerve, internal, anatomy of, 180
nerve, internal, exposure of, 180
Postcentral fissure, topography of, 466
Precentral fissure, topography of, 466
Proctectomy, 745. See also *Rectectomy.*
Proctopexy, 743
Proctotomy, 744
Profunda femoris, anatomy of, 96
ligation of, 97
Prostate gland, anatomy of, 922
operations upon, 922
Prostatectomy, 923
Alexander's operation, 926
perineal, 925
suprapubic, 924
Prostatotomy, 923
Psychical centers, area of, localization, 471
Pudic artery, internal, anatomy of, 87
ligation of, 88
nerve, exposure of, 179
Puncture and drainage of lateral ventricles of brain, 495
of abdomen, 651
of bladder, 879
of brain, exploratory, 488
of bursæ, 228
of heart, 620, 621
of joint, 204
of kidney, exploratory, 848

Puncture of liver, exploratory, 804
of pericardium, 615
of spleen, exploratory, 828
of thorax, 601
of tunicæ vaginalis, 913
of tympanum, 517
spinal, for drainage of subarachnoid space, 539
subarachnoid, for spinal anesthesia, 538
Pyelotomy, 850
Pylorectomy, 791
followed by end-to-end gastro-enterostomy, Billroth's method, 795
followed by posterior gastro-duodenostomy, Kocher's method, 792
Pyloroplasty, Heineke-Mikulicz method, 789
Pylorus, divulsion of, Loreta's operation, 791

RADIAL artery, anatomy of, 67
ligation of, 69
nerve, anatomy of, 176
exposure of, 177
Radio-ulnar articulation, superior, excision of, 416
Radius, excision of, 412
Re-amputation for improperly made flaps, 255
Rectectomy, by perineal route, 752
by sacral route, 745
Kraske's method, 745
Rehn-Rydygier osteoplastic flap method, 750
Rectopexy, Verneuil's method, 743
Rectotomy, external, 744
internal, 744
Rectum, anatomy of, 660
excision of, 745. See also *Rectectomy*.
Rehn-Rydygier method of excision of rectum, 750
Reid's method of cranio-cerebral localization, 476
Reil, island of, anatomy of, 460
topography of, 467
Resection of bones, osteoplastic, 448
of foot, osteoplastic, externo-lateral curved incision, 453
of foot, osteoplastic, transverse upper and lower and oblique lateral incisions, 452
of joints, osteoplastic, 448
Resection of maxilla, inferior, osteoplastic, 457
of maxilla, superior, osteoplastic, to expose nasopharynx by maxillary route, 456
of maxilla, superior, osteoplastic, to expose nasopharynx by palatine route, 455
of maxilla, superior, osteoplastic, vertical and horizontal incisions, 454
of nasal cartilage, chondroplastic, 455
of skull, osteoplastic, 483
of spine, osteoplastic, 534
of tarso-metatarsus, osteoplastic, 449
of tarsus, anterior, osteoplastic, 449
middle, osteoplastic, 450
posterior, osteoplastic, 451
Retropharyngeal space, exposure of, 556
Rib and costal cartilage, excision of, 447
excision of, 447
Rivinus, ducts of, anatomy of, 572
Robson's method of uretero-ureterostomy, 867
Rolandic fissure, anatomy of, 460
Chiene's method of determining, 478
topography of, 465
Rose's exposure of gasserian ganglion, 158

SALPINGO-OÖPHORECTOMY, 942
Salpingo-ovariectomy, 942
Salt solution, intravenous infusion of, 130
Scalp, skull, and brain, anatomy of, 459
Scapula, excision of, 420, 421
Scarpa's triangle, anatomy of, 139
Schede's operation of thoracoplasty, 607
Schwartze antrum operation, 504
Schwartze-Stacke operation for exposing mastoid antrum and cells, 506
Sciatic artery, anatomy of, 85
ligation of, 86
nerve, great, anatomy of, 179
great, exposure of, 179
Scrotum, anatomy of, 912
excision of, partial, 913
operations upon, 912
Seminal vesicles, anatomy of, 920
operations upon, 920
Sensori-motor area, localization of, 469
Sequestrotomy, 201
Shoulder-blade, excision of, 420, 421

Shoulder-joint, anatomy of, 323
disarticulation at, 326
general considerations, 325
excision of, 417
Sight area, localization of, 471
Sinus, lateral, anatomy of, 462
inferior, anatomy of, 462
ligation of, 490
superior, anatomy of, 462
thrombosis, operation for, 492
topography of, 468
occipital, anatomy of, 462
straight, anatomy of, 462
Sinuses, bony (air), of head and face, operations upon, 500
frontal, anatomy of, 508
exposure and drainage of, 510
operations upon, 508
maxillary, anatomy of, 511
exposure of, through facial aspect, above alveolar margin, 513
maxillary, exposure of, through second molar tooth, 514
maxillary, operations upon, 511
maxillary, operations upon, general considerations, 512
operations upon, instruments for, 513
venous, of dura mater, 462
Skin in amputation, treatment of, 255
Skull, fracture of, trephining for, 492
osteoplastic resection of, 483
scalp and brain, anatomy of, 459
thickness of, 479
Smell area, localization of, 471
Smith's method of amputating leg at upper third, 370
disarticulation at knee-joint, 374
Snuff-box, anatomy of, 68
Sound area, localization of, 471
Sound, introduction of, into female bladder, 879
into male bladder, 878
into urethra, 878
Speculum, ear, introduction of, for examination of membrana tympani, 517
Speech areas, localization of, 471
Spence's disarticulation at shoulder-joint, 327
Spermatic cord, anatomy of, 917
operations upon, 917
Sphenopalatine nerve, anatomy of, 160
Spinal accessory nerve, anatomy of, 170
exposure of, 170
Spinal anesthesia, subarachnoid puncture for, 538
cord, anatomy of, 526
operations upon, 526
general considerations, 528
instruments for, 530
tumors of, operation for, 539
puncture, for drainage of subarachnoid space, 539
Spine, anatomy of, 526
operations upon, 526
general considerations, 528
instruments for, 530
osteoplastic resection of, 534
Spleen, anatomy of, 827
exposure of, by subpleural route, 829
operations upon, 827
general considerations, 828
instruments for, 828
puncture of, exploratory, 828
suture of, 830
Splenectomy, partial, 831
total, 831
Splenopexy, 830
Splenorrhaphy, 830
Splenotomy, oblique subcostal incision, 829
Ssabanajew-Franck's method of gastrostomy, 767
Stenson's duct, anatomy of, 567
operations upon, 567
Stephen Smith's method of amputating leg at upper third, 370
method of disarticulation at knee-joint, 374
Stimson's operation for ununited fracture of patella, 197
Stomach, anatomy of, 760
cardiac orifice of, dilatation of. See *Esophagus, retrograde dilatation of*, 562
operations upon, 760
general considerations, 761
instruments for, 762
pyloric orifice of, divulsion, Loreta's operation, 791
suture of, 788
Stomach-tube, introduction of, 762
Stomach-wall, suture of, 765
Stone in bladder, lateral perineal cystotomy for, 883
median perineal cystotomy for, 886
Stricture of esophagus, dilatation, direct, 562
of esophagus, dilatation, retrograde, 562

Stricture of esophagus, division, by string friction, Abbe's operation, 562
of esophagus, divulsion, direct, 562
of esophagus, divulsion, retrograde, 562
of esophagus, tubage, permanent, 562
Subarachnoid puncture for spinal anesthesia, 538
space, cerebellar, incision of, for drainage, 496
drainage of, spinal puncture for, 539
Subclavian artery, anatomy of, 51
left, first portion, ligation of, 53
right, first portion, ligation of, 52
second portion, ligation of, 53
third portion, ligation of, 54
Subhyoid pharyngotomy, 555
Sublingual gland, anatomy of, 572
excision of, 572
operations upon, 572
Submaxillary gland, anatomy of, 570
excision of, 571
operations upon, 570
Subscapular artery, anatomy of, 64
ligation of, 64
Supra-orbital nerve, anatomy of, 160
exposure of, 160
Suprascapular artery, anatomy of, 58
ligation of, 59
Suprathyroid laryngotomy, 548
Suture of artery, 117
of bladder, 887
of heart, 621
of intestines, 663. See also *Enterorrhaphy*.
of kidney, 851
of ligaments, 226
of liver, 813, 814
of muscle, 207
of nerve, 144
of pericardium, 619
of spleen, 830
of stomach, 788
of stomach-wall, 765
of tendon, 213
of thoracic duct, 132
of ureters, 865
of urethra, 911
of veins, 126
Sylvian fissure, anatomy of, 459
topography of, 465
Syme's method of disarticulation of foot at ankle-joint, 360
of external perineal urethrotomy, 907
Syndesmotomy, 226

TABATIÈRE, anatomy of, 69
Tamponing of larynx, 548
of trachea, 553
Tarsometatarsus, osteoplastic resection of, 449
Tarsus, anterior, osteoplastic resection of, 449
middle, osteoplastic resection of, 450
posterior, osteoplastic resection of, 451
Taste area, localization of, 471
Tauffer's method of uretero-ureterostomy, 866
Teale's method of amputation by unequal rectangular flaps, 272
Temporal artery, anatomy of, 43
ligation of, 43
Temporomaxillary articulation, excision of, 444
Temporosphenoidal fissure, superior, topography of, 467
Tendon, suture of, 213
Tendon-grafting, 221
Tendon-lengthening, 216
Tendons in amputation, treatment of, 255
operations upon, 211
Tendon-sheaths, excision of, 224
operations upon, 211
ruptured, repair of, 223
Tendon-shortening, 220
Tenorrhaphy, 213
Tenotomy, 211
open, 212
subcutaneous, 212
Testes, anatomy of, 912
operations upon, 912
Thigh, amputation of, 379
at condyles of femur, 379
general considerations, 378
just above condyles of femur, 380
just below trochanters, 386
lower, middle, or upper third, 382
lower third, 382
anatomy of, 376
Thoracentesis, 601
Thoracic duct, anatomy of, 132
ligation of, 133
suture of, 132
tracheotomy, 553
Thoracoplasty, 604
Estlaender's operation, 604
Schede's operation, 607
Thoracotomy, by partial excision of one or more ribs, 602

Thoracotomy, intercostal, 601
mediastinal, anterior, by long median incision, 588
mediastinal, anterior, by osteoplastic resection of part of sternum, 590
mediastinal, posterior, 593
Thorax, anatomy of, 576
operations upon, 576
instruments for, 579
puncture of, 601
Thrombosis of lateral sinus, operation for, 492
Thumb, amputation of, with part of metacarpal, 296
disarticulation of, at metacarpo-phalangeal joint, 289
with metacarpal, 298
metacarpal of, excision, 408
Thyroid artery, inferior, anatomy of, 57
ligation of, 57
superior, anatomy of, 37
ligation of, 37
gland, anatomy of, 573
operations upon, 573
Thyroidectomy, complete, 575
partial, 573
Thyrotomy, 544
Tibia, excision of, 430
Tibial artery, anterior, anatomy of, 103
ligation of, 104
posterior, anatomy of, 108
ligation of, 109
nerve, anterior, anatomy of, 182
exposure of, 182
posterior, anatomy of, 180
exposure of, 180
Toe, disarticulation of, with metatarsal, 350
great, disarticulation of, at metatarso-phalangeal joint, 341
great, disarticulation of, with metatarsal, 350
little, disarticulation of, at metatarso-phalangeal joint, 341
little, disarticulation of, with metatarsal, 352
Toes, amputation of, at first phalanx, 338
at last phalanx, 336
at metatarsus, 348
at second phalanx, 338
general considerations, 335
with part of metatarsals, 347
anatomy of, 33
Toes, disarticulation of, at first interphalangeal joints, 338
at interphalangeal joint, 337
at metatarso-phalangeal joints, 340
at tarso-metatarsal joints, 353
general considerations, 335
with metatarsals, 349
excision of bones and joints about, 422
of first interphalangeal joint, 423
of first phalanx, 424
of metatarsal bones, 424
of metatarso-phalangeal joints, 424
of second interphalangeal joint, 423
of second phalanges, 423
of terminal phalanges, 423
second, third, or fourth, disarticulation of, at metatarso-phalangeal joint, 340
two adjoining, disarticulation of, at metatarso-phalangeal joint, 342
two or three contiguous, disarticulation of, with metatarsals, 353
Tongue, anatomy of, 518
excision of, 520
general considerations, 518
instruments for, 519
limited portions, 520
operations upon, 518
Tonsillectomy, complete, through mouth, 564
through neck, 565
partial, through mouth, 564
Tonsillotomy, 563
Tonsils, anatomy of, 563
operations upon, 563
general considerations, 563
instruments for, 563
Torsion of artery, 120
of veins, 129
Trachea, anatomy of, 548
foreign bodies in, operation for, 553
operations upon, 548
general considerations, 549
instruments for, 549
tamponing of, 553
Tracheo-laryngotomy, 552
Tracheoscopy, 553
Tracheotomy, high, 550
low, 552
thoracic, 553
by posterior mediastinal osteoplastic flap operation, 622
Transversalis colli, anatomy of, 57
ligation of, 58

Trephining, 481
circular, 481
for fracture of skull, 492
linear, 487
varieties of, 480
Trifacial nerve, extracranial exposure of, 158
intracranial exposure of, 155
Tuffier's method of nephropexy, 856
Tumor, cerebellar, operation for, 499
cerebral, operation for, 498
of spinal cord, operation for, 539
Tunica albuginea, anatomy of, 913
vaginalis, anatomy of, 912
puncture of, 913
vasculosa, anatomy of, 913
Tympanum, membrane of, anatomy of, 516
introduction of ear speculum for examination of, 517
puncture of, 517

ULCER, gastric, operation for, 800
perforated, operation for, 800
Ullmann's modification of Maunsell's method of entero-enterostomy, 699
Ulna, excision of, 411
Ulnar artery, anatomy of, 73
ligation of, 74
nerve, anatomy of, 175
exposure of, 175
Umbilical hernia, anatomy of, 958
operation for, 959
Ureterectomy, 873
partial, by oblique lumbar incision, 874
total, with removal of kidney, 874
Uretero-rectostomy, 870
Ureterorrhaphy, 865
Ureterotomy, 864
Uretero-ureteral anastomosis, 865
Uretero-ureterostomy, 865
Ureters, anatomy of, 861
exposure of, 863
implantation of, 868
into bladder, 869
into large intestine, 870
upon skin of loin or abdomen, 873
operations upon, 861
general considerations, 862
instruments for, 863
suture of, 865
Urethra, anatomy of, 902
female, anatomy of, 903
Urethra, introduction of sound or catheter into, 878
male, anatomy of, 902
operations upon, 902
suture of, 911
Urethrorrhaphy, 911
Urethrostomy, 911
Urethrotomy, 904
external perineal, Cock's method, 910
external perineal, Gouley's method, 908
external perineal, Syme's method, 907
external perineal, Wheelhouse's method, 909
internal, by dilating urethrotome, 905
Uterus, anatomy of, 929
broad ligament of, anatomy of, 930
operations upon, 929
instruments for, 932
round ligaments of, anatomy, 931

VAGINA, anatomy of, 931
Van Hook's method of uretero-ureterostomy, 867
Varicocele, Bennett's modification of Howse's operation for, 919
operation for radical cure of, 919
Vas deferens, anatomy of, 918
Vasa deferentia, anatomy of, 918
Vascular neoplasms, injection of water at high temperature in, 125
Vasectomy, partial, 918
Veins, acupressure of, 129
excision of, 129
infusion of salt solution into, 130
ligation of, en masse, 129
in amputation, 253
lateral, 127
temporary, 128
transverse, 128
operations upon, 126
pressure of, 129
suture of, 126
torsion of, 129
Venesection, 126
Venous forcipressure, 129
Ventricles, lateral, of brain, puncture and drainage of, 495
lateral, of brain, topography of, 468
Verneuil's method of rectopexy, 743
Vertebral artery, anatomy of, 55
ligation of, 56

Vesical calculus, lateral perineal, cystotomy for, 883
median perineal cystotomy for, 886
drainage, 892
Vesiculæ seminales and part of ejaculatory ducts, total excision of, Young's operation, 921
operations upon, 920
Vischer's method of lateral abdominal section, 646
Volkmann's operation for hydrocele, 914
Von Bergmann's operation for hydrocele, 915
Von Hacker's method of posterior gastro-enterostomy, 783

WARREN'S radical excision of breast, 584
Weir's method of antero-lateral abdominal section, 639
modification of Bircher's operation for gastroplication, 787
modification of Murphy's button, lateral anastomosis with, 708
Wharton's duct, anatomy of, 570
operations upon, 570
Wheelhouse's method of external perineal urethrotomy, 909
Whitehead's excision of tongue, 520
operation for hemorrhoids, 755
Winslow, foramen of, anatomy of, 648
Winslow's method of uretero-ureterostomy, 867
Witzel's method of gastrostomy, 769
Wladimiroff-Mikulicz osteoplastic resection of foot, 452
osteoplastic resection of foot, modification, 453
Wölfler's method of anterior gastro-enterostomy, 777
of gastrogastrostomy, 785
Wound, bullet, of brain, operation for, 493
Wounds of intestines, enterorrhaphy for, 670
Wrist-joint, anatomy of, 302
disarticulation at, 304
general considerations, 303
excision of, 408
Wyeth's disarticulation at hip-joint, 390
operation for vascular neoplasms, 125

YOUNG'S method of total excision of vesiculæ seminales and part of ejaculatory ducts, 921

SAUNDERS' BOOKS

on

Nervous and Mental Diseases, Children, Hygiene, Nursing, and Medical Jurisprudence

W. B. SAUNDERS & COMPANY

925 WALNUT STREET — PHILADELPHIA

NEW YORK — Fuller Building, 5th Ave. and 23d St.

LONDON — 9, Henrietta Street, Covent Garden

SAUNDERS' SUCCESSFUL PUBLISHING

A factor of no little moment in establishing the remarkable success of Saunders' publications is the wide publicity given them. Besides an immense amount of circular matter constantly being distributed, the Firm's announcements appear in practically all the leading weekly medical journals of America and England; and recently there has been added to the list the **Indian Lancet,** the leading medical weekly in India. This unprecedented medical publicity really means that the announcements of W. B. Saunders & Company are weekly placed in the hands of 120,000 English-speaking physicians.

A Complete Catalogue of Our Publications will be Sent upon Request

Peterson *and* Haines' Legal Medicine & Toxicology

A Text-Book of Legal Medicine and Toxicology. Edited by FREDERICK PETERSON, M. D., Clinical Lecturer on Psychiatry and Instructor in Neurology, College of Physicians and Surgeons, New York; and WALTER S. HAINES, M. D., Professor of Chemistry, Pharmacy, and Toxicology, Rush Medical College, in affiliation with the University of Chicago. Two imperial octavo volumes of about 750 pages each, fully illustrated. Per volume: Cloth, $5.00 net; Sheep or Half Morocco, $6.00 net. *Sold by Subscription.*

AN ENTIRELY NEW WORK—JUST READY

The object of the present work is to give to the medical and legal professions a comprehensive survey of forensic medicine and toxicology in moderate compass. This, it is believed, has not been done in any other recent work in English. Under "Expert Evidence" not only is advice given to medical experts, but suggestions are also made to attorneys as to the best methods of obtaining the desired information from the witness. An interesting and important chapter is that on "The Destruction and Attempted Destruction of the Human Body by Fire and Chemicals." A chapter not usually found in works on legal medicine is that on "The Medicolegal Relations of the X-Rays." This section will be found of unusual importance. The responsibility of pharmacists in the compounding of prescriptions, in the selling of poisons, in substituting drugs other than those prescribed, etc., furnishes a chapter of the greatest interest to every one concerned with questions of medical jurisprudence. Also included in the work is the enumeration of the laws of the various states relating to the commitment and retention of the insane.

CONTRIBUTORS

Samuel T. Armstrong, M.D., Ph.D., New York.
Pearce Bailey, M.D., New York City.
Lewis Balch, M.D., Ph.D., New York City.
W. T. Belfield, M.D., Chicago, Ill.
Chas. Gilbert Chaddock, M.D., St. Louis, Mo.
John Chalmers DaCosta, M.D., Philadelphia.
Joseph F. Darling, A.M., LL.B., New York.
Edward P. Davis, A.M., M.D., Philadelphia.
Charles A. Doremus, M.D., Ph.D., New York.
W. A. Newman Dorland, M.D., Philadelphia.
J. T. Eskridge, M.D., Denver, Col.
Marshall D. Ewell, A.M., M.D., LL.D., Chicago
James Ewing, M.D., New York City.
Leonard Freeman, A.M., M.D., B.S., Denver.
A. L. Goldwater, M.D., New York City.
Walter S. Haines, M.D., Chicago, Ill.
Josiah N. Hall, M.D., Denver, Col.
Graeme M. Hammond, LL.B., M.D., N. Y.
Charles Harrington, M.D., Boston, Mass.
Ludvig Hektoen, M.D., Chicago, Ill.
James W. Holland, M.D., Philadelphia, Pa.
Reid Hunt, M.D., Ph.D., Baltimore, Md.
Edward Jackson, A.M., M.D., Denver, Col.
Smith Ely Jelliffe, A.M., M.D., Ph.D., N. Y.
Walter Jones, Ph.D., Baltimore, Md.
F. W. Langdon, M.D., Cincinnati, Ohio.
Carlos F. MacDonald, A.M., M.D., New York.
Harold N. Moyer, M.D., Chicago, Ill.
Oscar Oldberg, Pharm.D., Chicago, Ill.
Frederick Peterson, M.D., New York City.
Albert B. Prescott, M.D., LL.D., Ann Arbor.
Jerome Probst, Ph.G., LL.B., Chicago, Ill.
Jerome H. Salisbury, A.M., M.D., Chicago.
Allen J. Smith, A.M., M.D., Galveston, Tex.
Geo. Knowles Swinburne, A.B., M.D., N. Y.
Victor C. Vaughan, M.D., LL.D., Ann Arbor.
Edward S. Wood, A.M., M.D., Boston, Mass.

Church and Peterson's Nervous *and* Mental Diseases

Nervous and Mental Diseases. By ARCHIBALD CHURCH, M. D., Professor of Nervous and Mental Diseases and Head of Neurologic Department, Northwestern University Medical School, Chicago; and FREDERICK PETERSON, M. D., President New York State Commission on Lunacy; Chief of Clinic, Department for Nervous Diseases, College of Physician and Surgeons, New York. Handsome octavo, 875 pages; 322 illustrations. Cloth, $5.00 net; Sheep or Half Morocco, $6.00 net.

FOURTH EDITION, THOROUGHLY REVISED—JUST ISSUED

This work has met with a most favorable reception from the profession at large, four editions having been called for in as many years. It fills a distinct want in medical literature, and is unique in that it furnishes in one volume practical treatises on the two great subjects of Neurology and Psychiatry. In this edition the book has been thoroughly revised in every part, both by additions to the subject matter and by rearrangement wherever necessary, to make it more acceptable to the practitioner and the student. Several sections have been entirely rewritten, and there have been added a number of new illustrations, an increased amount of tabular matter, and a series of diagrams that have proved of assistance in the solution of diagnostic problems.

OPINIONS OF THE MEDICAL PRESS

American Journal of the Medical Sciences

"This edition has been revised, new illustrations added, and some new matter, and really is two books. . . . The descriptions of disease are clear, directions as to treatment definite, and disputed matters and theories are omitted. Altogether it is a most useful text-book."

Journal of Nervous and Mental Diseases

"The best text-book exposition of this subject of our day for the busy practitioner. . . . The chapter on idiocy and imbecility is undoubtedly the best that has been given us in any work of recent date upon mental diseases. The photographic illustrations of this part of Dr. Peterson's work leave nothing to be desired."

New York Medical Journal

"To be clear, brief, and thorough, and at the same time authoritative, are merits that ensure popularity. The medical student and practitioner will find in this volume a ready and reliable resource."

Barton and Wells' Medical Thesaurus

A NEW WORK—JUST ISSUED

A Thesaurus of Medical Words and Phrases. By WILFRED M. BARTON, A. M., Assistant to Professor of Materia Medica and Therapeutics, and Lecturer on Pharmacy, Georgetown University, Washington, D. C.; and WALTER A. WELLS, M. D., Demonstrator of Laryngology and Rhinology, Georgetown University, Washington, D. C. Handsome octavo of about 650 pages. Cloth, $0.00 net; Sheep or Half Morocco, $0.00 net.

THE ONLY MEDICAL THESAURUS EVER PUBLISHED

This work is the only Medical Thesaurus ever published. It aims to perform for medical literature the same services which Roget's work has done for literature in general; that is, instead of, as an ordinary dictionary does, supplying the meaning to given words, it reverses the process, and when the meaning or idea is in the mind, it endeavors to supply the fitting term or phrase to express that idea. To obviate constant reference to a lexicon to discover the meaning of terms, brief definitions are given before each word. As a dictionary is of service to those who need assistance in interpreting the expressed thought of others, the Thesaurus is intended to assist those who have to write or to speak to give proper expression to their own thoughts. In order to enhance the practical application of the book cross references from one caption to another have been introduced, and terms inserted under more than one caption when the nature of the term permitted. In the matter of synonyms of technical words the authors have performed for medical science a service never before attempted. Writers and speakers desiring to avoid unpleasant repetition of words will find this feature of the work of invaluable service. Indeed, this Thesaurus of medical terms and phrases will be found of inestimable value to all persons who are called upon to state or explain any subject in the technical language of medicine. To this class belong not only teachers in medical colleges and authors of medical books, but also every member of the profession who at some time may be required to deliver an address, state his experience before a medical society, contribute to the medical press, or give testimony before a court as an expert witness.

Brower and Bannister on Insanity

A Practical Manual of Insanity. For the Student and General Practitioner. By DANIEL R. BROWER, A. M., M. D., LL. D., Professor of Nervous and Mental Diseases in Rush Medical College, in affiliation with the University of Chicago; and HENRY M. BANNISTER, A. M., M. D., formerly Senior Assistant Physician, Illinois Eastern Hospital for the Insane. Handsome octavo of 426 pages, with a number of full-page inserts. Cloth, $3.00 net.

FOR STUDENT AND PRACTITIONER

This work, intended for the student and general practitioner, is an intelligible, up-to-date exposition of the leading facts of psychiatry, and will be found of invaluable service, especially to the busy practitioner unable to yield the time for a more exhaustive study. The work has been rendered more practical by omitting elaborate case records and pathologic details, as well as discussions of speculative and controversial questions.

American Medicine

"Commends itself for lucid expression in clear-cut English, so essential to the student in any department of medicine. . . . Treatment is one of the best features of the book, and for this aspect is especially commended to general practitioners."

Bergey's Hygiene

The Principles of Hygiene: A Practical Manual for Students, Physicians, and Health Officers. By D. A. BERGEY, A. M., M.D., First Assistant, Laboratory of Hygiene, University of Pennsylvania. Octavo volume of 495 pages, illustrated. Cloth, $3.00 net.

FOR STUDENTS, PHYSICIANS, AND HEALTH OFFICERS

This book is intended to meet the needs of students of medicine in the acquirement of a knowledge of those principles upon which modern hygienic practices are based, and to aid physicians and health officers in familiarizing themselves with the advances made in hygiene and sanitation in recent years. The book is based on the most recent discoveries, and represents the practical advances made in the science of hygiene up to date.

Buffalo Medical Journal

"It will be found of value to the practitioner of medicine and the practical sanitarian; and students of architecture, who need to consider problems of heating, lighting, ventilation, water supply, and sewage disposal, may consult it with profit."

GET THE BEST

American Illustrated Dictionary

THE NEW STANDARD

Third Revised Edition—Just Issued

The American Illustrated Medical Dictionary. A new and complete dictionary of the terms used in Medicine, Surgery, Dentistry, Pharmacy, Chemistry, and kindred branches; with over 100 new and elaborate tables and many handsome illustrations. By W. A. NEWMAN DORLAND, M. D., Editor of "The American Pocket Medical Dictionary." Large octavo, nearly 800 pages, bound in full flexible leather. Price, $4.50 net; with thumb index, $5.00 net.

Gives a Maximum Amount of Matter in a Minimum Space, and at the Lowest Possible Cost

THIRD EDITION IN THREE YEARS—12,500 COPIES

The immediate success of this work is due to the special features that distinguish it from other books of its kind. It gives a maximum of matter in a minimum space and at the lowest possible cost. Though it is practically unabridged, yet by the use of thin bible paper and flexible morocco binding it is only 1⅝ inches thick. The result is a truly luxurious specimen of book-making. In this new edition the book has been thoroughly revised, and upward of one hundred important new terms that have appeared in recent medical literature have been added, thus bringing the book absolutely up to date. The book contains hundreds of terms not to be found in any other dictionary, over 100 original tables, and many handsome illustrations, including 24 colored plates.

PERSONAL OPINIONS

Howard A. Kelly, M. D.,

Professor of Gynecology, Johns Hopkins University, Baltimore.

"Dr. Dorland's dictionary is admirable. It is so well gotten up and of such convenient size. No errors have been found in my use of it."

Roswell Park, M. D.,

Professor of Principles and Practice of Surgery and of Clinical Surgery, University of Buffalo.

"I must acknowledge my astonishment at seeing how much he has condensed within relatively small space. I find nothing to criticize, very much to commend, and was interested in finding some of the new words which are not in other recent dictionaries."

Galbraith's Four Epochs of Woman's Life

Second Revised Edition—Just Issued

The Four Epochs of Woman's Life: A Study in Hygiene. By ANNA M. GALBRAITH, M. D., Fellow of the New York Academy of Medicine, etc. With an Introductory Note by JOHN H. MUSSER, M. D., Professor of Clinical Medicine, University of Pennsylvania. 12mo volume of 200 pages. Cloth, $0.00 net.

MAIDENHOOD, MARRIAGE, MATERNITY, MENOPAUSE

In this instructive work are stated, in a modest, pleasing, and conclusive manner, those truths of which every woman should have a thorough knowledge. Written, as it is, for the laity, the subject is discussed in language readily grasped even by those most unfamiliar with medical subjects.

Birmingham Medical Review, England

"We do not as a rule care for medical books written for the instruction of the public. But we must admit that the advice in Dr. Galbraith's work is in the main wise and wholesome."

Pyle's Personal Hygiene

A Manual of Personal Hygiene: Proper Living upon a Physiologic Basis. By Eminent Specialists. Edited by WALTER L. PYLE, A. M., M. D., Assistant Surgeon to Wills Eye Hospital, Philadelphia. Octavo volume of 344 pages, fully illustrated. Cloth, $1.50 net.

PROPER LIVING UPON A PHYSIOLOGIC BASIS

The object of this manual is to set forth plainly the best means of developing and maintaining physical and mental vigor. It represents a thorough exposition of living upon a physiologic basis. There are chapters upon Hygiene of the Digestive Apparatus, Skin and its Appendages, Vocal and Respiratory Apparatus, Eye, Ear, Brain, and Nervous System, and a chapter upon Exercise.

Boston Medical and Surgical Journal

"The work has been excellently done, there is no undue repetition, and the writers have succeeded unusually well in presenting facts of practical significance based on sound knowledge."

Draper's Legal Medicine

A Text-Book of Legal Medicine. By FRANK WINTHROP DRAPER, A. M., M. D., Professor of Legal Medicine in Harvard University, Boston; Medical Examiner of the County of Suffolk, Massachusetts, etc. Handsome octavo volume of nearly 600 pages, fully illustrated. Cloth, $0.00 net.

A NEW WORK—PREPARING

The subject of Legal Medicine is one of great importance, especially to the general practitioner, for it is to him that calls to attend cases which may prove to be medicolegal in character most frequently come. The medicolegal field includes not only deaths of a homicidal nature, but also suits at law—the fatal railway accident, machinery casualties, and the like, to which the neighboring physician may be called, and later, perhaps, summoned to court. It is evident, therefore, that every practitioner should be thoroughly versed in all branches of medicolegal science. This volume, although prepared as a help to medical students, will be found no less valuable and instructive to practitioners. The author has not only cited illustrative cases from the standard treatises on forensic medicine, but these he has supplemented with details from his own exceptionally full experience—an experience gained during his service as Medical Examiner for the city of Boston for the past twenty-six years. During this time his investigations have comprised nearly seventy-seven thousand deaths under a suspicion of violence. It will be seen, therefore, that the work is authoritative, and, written by an experienced teacher, the language is clear and concise.

Jakob *and* Fisher's Nervous System and its Diseases

Atlas and Epitome of the Nervous System and Its Diseases. By PROFESSOR DR. CHR. JAKOB, of Erlangen. *From the Second Revised German Edition.* Edited, with additions, by EDWARD D. FISHER, M. D., Professor of Diseases of the Nervous System, University and Bellevue Hospital Medical College, New York. With 83 plates and copious text. Cloth, $3.50 net. *In Saunders' Hand-Atlas Series.*

The matter is divided into Anatomy, Pathology, and Description of Diseases of the Nervous System. The plates illustrate these divisions most completely; especially is this so in regard to pathology. The exact site and character of the lesion are portrayed in such a way that they cannot fail to impress themselves on the memory of the reader.

Philadelphia Medical Journal

"We know of no one work of anything like equal size which covers this important and complicated field with the clearness and scientific fidelity of this hand-atlas."

American Text-Book of Diseases of Children

American Text-Book of Diseases of Children. Edited by LOUIS STARR, M. D., Consulting Pediatrist to the Maternity Hospital, etc.; assisted by THOMPSON S. WESTCOTT, M. D., Attending Physician to the Dispensary for Diseases of Children, Hospital of the University of Pennsylvania. Handsome octavo, 1244 pages, profusely illustrated. Cloth, $7.00 net; Sheep or Half Morocco, $8.00 net.

SECOND REVISED EDITION

To keep up with the rapid advances in the field of pediatrics, the whole subject-matter embraced in the first edition has been carefully revised, new articles added, some original papers amended, and a number entirely rewritten and brought up to date. The volume has thus been increased in size by a very considerable amount of fresh material.

British Medical Journal

"May be recommended as a thoroughly trustworthy and satisfactory guide to the subject of the diseases of children."

Gould and Pyle's Curiosities of Medicine

Anomalies and Curiosities of Medicine. By GEORGE M. GOULD, M. D., and WALTER L. PYLE, M. D. An encyclopedic collection of rare and extraordinary cases and of the most striking instances of abnormality in all branches of Medicine and Surgery, derived from an exhaustive research of medical literature from its origin to the present day, abstracted, classified, annotated, and indexed. Handsome octavo volume of 968 pages, 295 engravings, and 12 full-page plates. Popular Edition: Cloth, $3.00 net; Sheep or Half Morocco, $4.00 net.

As a complete and authoritative Book of Reference, this work will be of value not only to members of the medical profession, but to all persons interested in general scientific, sociologic, and medicolegal topics; in fact, the absence of any complete work upon the subject makes this volume one of the most important literary innovations of the day.

New York Medical Journal

"We would gladly exchange a multitude of the relatively useless works which but encumber all branches of medicine, for one so comprehensive, so exhaustive, so able, and so remarkable in its field as this."

Hofmann and Peterson's Legal Medicine

Atlas of Legal Medicine. By DR. E. VON HOFMANN, of Vienna, Edited by FREDERICK PETERSON, M. D., Chief of Clinic, Nervous Department, College of Physicians and Surgeons, New York.. With 120 colored figures on 56 plates and 193 half-tone illustrations. Cloth, $3.50 net. *In Saunders' Hand-Atlas Series.*

By reason of the wealth of illustrations and the fidelity of the colored plates, the book supplements all the text-books on the subject. Moreover, it furnishes to every physician, student, and lawyer a veritable treasure-house of information.

The Practitioner, London

"The illustrations appear to be the best that have ever been published in connection with this department of medicine, and they cannot fail to be useful alike to the medical jurist and to the student of forensic medicine."

Chapman's Medical Jurisprudence

Medical Jurisprudence, Insanity, and Toxicology. By HENRY C. CHAPMAN, M. D., Professor of Institutes of Medicine and Medical Jurisprudence in Jefferson Medical College, Philadelphia. Handsome 12mo of 329 pages, fully illustrated. Cloth, $1.75 net.

JUST ISSUED—THIRD REVISED EDITION, ENLARGED

This work is based on the author's practical experience as coroner's physician of the city of Philadelphia for a period of six years. Dr. Chapman's book, therefore, is of unusual value.

This third edition has been thoroughly revised and greatly enlarged, so as to bring it absolutely in accord with the very latest advances in this important branch of medical science. There is no doubt it will meet with as great favor as the previous editions.

Journal of the American Medical Association — *In Reviewing the Second Edition*

"It is an excellent manual in which an accurate epitome is given of the existing knowledge on the subject."

Davis' Obstetric and Gynecologic Nursing

Obstetric and Gynecologic Nursing. By EDWARD P. DAVIS, A. M., M.D., Professor of Obstetrics in the Jefferson Medical College and Philadelphia Polyclinic; Obstetrician and Gynecologist, Philadelphia Hospital. 12mo of 400 pages, illustrated. Buckram, $1.75 net.

This volume is designed for the obstetric and gynecologic nurse. Obstetric nursing demands some knowledge of natural pregnancy and of the signs of accidents and diseases which may occur during pregnancy. It also requires knowledge and experience in the care of the patient and child. Gynecologic nursing is really a branch of surgical nursing, and as such requires special instruction and training. This volume presents this information in the most convenient form.

The Lancet, London

"Not only nurses, but even newly qualified medical men, would learn a great deal by a perusal of this book. It is written in a clear and pleasant style, and is a work we can recommend."

Watson's Nursing

A Handbook for Nurses. By J. K. WATSON, M.D., Edin. Assistant House-Surgeon, Sheffield Royal Hospital. American Edition, under the supervision of A. A. STEVENS, A. M., M. D., Professor of Pathology, Women's Medical College, Philadelphia. 12mo, 413 pages, 73 illustrations. Cloth, $1.50 net.

This work aims to supply in one volume that information which so many nurses at the present time are trying to extract from various medical works, and to present that information in a suitable form. Nurses must necessarily acquire a certain amount of medical knowledge, and the author of this book has aimed judiciously to cater to this need with the object of directing the nurses' pursuit of medical information in proper and legitimate channels.

Journal of the American Medical Association

"The intelligent nurse will find this a most convenient manual, and there are many things in it that the physician might find of use. In recommending text-books to nurses it could be put in the first rank."

Golebiewski and Bailey's Accident Diseases

Atlas and Epitome of Diseases Caused by Accidents. By DR. ED. GOLEBIEWSKI, of Berlin. Edited, with additions, by PEARCE BAILEY, M. D., Attending Physician to the Almshouse and Incurable Hospitals, New York. With 71 colored illustrations on 40 plates, 143 text-illustrations, and 549 pages of text. Cloth, $4.00 net. *In Saunders' Hand-Atlas Series.*

This work contains a full and scientific treatment of the subject of accident injury; the functional disability caused thereby; the medicolegal questions involved, and the amount of indemnity justified in given cases. The work is indispensable to every physician who sees cases of injury due to accidents, to advanced students, to surgeons, and, on account of its illustrations and statistical data, it is none the less useful to accident-insurance organizations.

The Medical Record, New York

"This volume is upon an important and only recently systematized subject, which is growing in extent all the time. The pictorial part of the book is very satisfactory."

Stoney's Materia Medica for Nurses

Practical Materia Medica for Nurses, with an Appendix containing Poisons and their Antidotes, with Poison-Emergencies; Mineral Waters; Weights and Measures; Dose-List, and a Glossary of the Terms used in Materia Medica and Therapeutics. By EMILY A. M. STONEY, Superintendent of the Training School for Nurses at the Carney Hospital, South Boston, Mass. Handsome octavo volume of 306 pages. Cloth, $1.50 net.

The present book differs from other similar works in several features, all of which are intended to render it more practical and generally useful. The consideration of the drugs includes their names, their sources and composition, their various preparations, physiologic actions, directions for handling and administering, and the symptoms and treatment of poisoning.

Journal of the American Medical Association

"So far as we can see, it contains everything that a nurse ought to know in regard to drugs. As a reference-book for nurses it will without question be very useful."

Griffith's Care of the Baby

The Care of the Baby. By J. P. CROZER GRIFFITH, M. D., Clinical Professor of Diseases of Children, University of Penn.; Physician to the Children's Hospital, Phila. 12mo, 436 pp. Illustrated. Cloth, $1.50 net.

JUST ISSUED—THIRD EDITION, THOROUGHLY REVISED

The author has endeavored to furnish a reliable guide for mothers. He has made his statements plain and easily understood, in the hope that the volume may be of service not only to mothers and nurses, but also to students and practitioners whose opportunities for observing children have been limited.

New York Medical Journal

"We are confident if this little work could find its way into the hands of every trained nurse and of every mother, infant mortality would be lessened by at least fifty per cent."

Crothers' Morphinism

Morphinism and Narcomania from Opium, Cocain, Ether, Chloral, Chloroform, and other Narcotic Drugs; also the Etiology, Treatment, and Medicolegal Relations. By T. D. CROTHERS, M. D., Superintendent of Walnut Lodge Hospital, Hartford, Conn. Handsome 12mo of 351 pages. Cloth, $2.00 net.

The Lancet, London

"An excellent account of the various causes, symptoms, and stages of morphinism, the discussion being throughout illuminated by an abundance of facts of clinical, psychological, and social interest."

Abbott's Transmissible Diseases

The Hygiene of Transmissible Diseases: Their Causation, Modes of Dissemination, and Methods of Prevention. By A. C. ABBOTT, M. D., Professor of Hygiene and Bacteriology, University of Pennsylvania. Octavo, 351 pages, with numerous illustrations. Cloth, $2.50 net.

SECOND REVISED EDITION

During the interval that has elapsed since the appearance of the first edition investigations upon the modes of dissemination of certain of the specific infections have been very active. The sections on Malaria, Yellow Fever, Plague, Filariasis, Dysentery, and Tuberculosis have been both revised and enlarged.

The Lancet, London

"We heartily commend the book as a concise and trustworthy guide in the subject with which it deals, and we sincerely congratulate Professor Abbott."

Stoney's Nursing

Practical Points in Nursing: for Nurses in Private Practice. By EMILY A. M. STONEY, Superintendent of the Training School for Nurses at the Carney Hospital, South Boston, Mass. 466 pages, fully illustrated. Cloth, $1.75 net.

JUST ISSUED—THIRD EDITION, THOROUGHLY REVISED

In this volume the author explains the entire range of *private* nursing as distinguished from *hospital* nursing, and the nurse is instructed how best to meet the various emergencies of medical and surgical cases when distant from medical or surgical aid or when thrown on her own resources. An especially valuable feature will be found in the directions how to *improvise* everything ordinarily needed in the sick-room.

The Lancet, London

"A very complete exposition of practical nursing in its various branches, including obstetric and gynecologic nursing. The instructions given are full of useful detail."

Stoney's Bacteriology and Surgical Technic for Nurses

Bacteriology and Surgical Technic for Nurses. By EMILY A. M. STONEY, Superintendent of the Training School for Nurses at the Carney Hospital, South Boston, Mass. 12mo, 200 pages, profusely illustrated. Cloth, $1.25 net.

The work is intended as a modern text-book on Surgical Nursing in both hospital and private practice. The first part of the book is devoted to Bacteriology and Antiseptics; the second part to Surgical Technic, Signs of Death, and Autopsies. The matter in the book is presented in a practical form, and will prove of value to all nurses who are called upon to attend surgical cases.

Trained Nurse and Hospital Review

"These subjects are treated most accurately and up to date, without the superfluous reading which is so often employed. . . . Nurses will find this book of the greatest value both during their hospital course and in private practice."

American Pocket Dictionary

Fourth Edition, Revised

AMERICAN POCKET MEDICAL DICTIONARY. Edited by W. A. NEWMAN DORLAND, M. D., Assistant Obstetrician to the Hospital of the University of Pennsylvania. Containing the pronunciation and definition of the principal words used in medicine and kindred sciences, with 64 extensive tables. Handsomely bound in flexible leather, with gold edges, $1.00 net; with patent thumb index, $1.25 net.

"I can recommend it to our students without reserve."—J. H. HOLLAND, M. D., *Dean of the Jefferson Medical College*, Philadelphia.

Warwick and Tunstall's First Aid

FIRST AID TO THE INJURED AND SICK. By F. J. WARWICK, B. A., M. B. Cantab., Associate of King's College, London; and A. C. TUNSTALL, M. D., F. R. C. S. Edin., Surgeon-Captain Commanding the East London Volunteer Brigade Bearer Company. 16mo of 232 pages and nearly 200 illustrations. Cloth, $1.00 net.

"Contains a great deal of valuable information well and tersely expressed. It will prove especially useful to the volunteer first aid and hospital corps men of the National Guard."—*Journal American Medical Association.*

Saunders' American Year-Book

AMERICAN YEAR-BOOK OF MEDICINE AND SURGERY. A Yearly Digest of Scientific Progress and Authoritative Opinion on all Branches of Medicine and Surgery, drawn from journals, monographs, and text-books of the leading American and foreign authors and investigators. Arranged, with critical editorial comments, by eminent American specialists, under the editorial charge of GEORGE M. GOULD, A. M., M. D. In two volumes: Vol. I.—*General Medicine*, octavo, 715 pages, illustrated; Vol. II.—*General Surgery*, octavo, 684 pages, illustrated. Per volume: Cloth, $3.00 net; Sheep or Half Morocco, $3.75 net. *Sold by Subscription.*

"It is much more than a mere compilation of abstracts, for, as each section is entrusted to experienced and able contributors, the reader has the advantage of certain critical commentaries and expositions . . . proceeding from writers fully qualified to perform these tasks."—*The Lancet*, London.

Shaw on Nervous Diseases and Insanity

Third Edition, Revised

ESSENTIALS OF NERVOUS DISEASES AND INSANITY: their Symptoms and Treatment. A Manual for Students and Practitioners. By the late JOHN C. SHAW, M. D., Clinical Professor of Diseases of the Mind and Nervous System, Long Island College Hospital, New York. 12mo of 204 pages, illustrated. Cloth, $1.00 net. *In Saunders' Question-Compend Series.*

"Clearly and intelligently written; we have noted few inaccuracies and several suggestive points. Some affections unmentioned in many of the large text-books are noted."—*Boston Medical and Surgical Journal.*

Chapin's Insanity

A COMPENDIUM OF INSANITY. By JOHN B. CHAPIN, M. D., LL.D., Physician-in-Chief, Pennsylvania Hospital for the Insane; Honorary Member of the Medico-Psychological Society of Great Britain, of the Society of Mental Medicine of Belgium, etc. 12mo, 234 pages, illustrated. Cloth, $1.25 net.

"It is not a made book, but a genuine condensed thesis, which has all the value of ripe opinion and all the charm of a vigorous and natural style."—*Philadelphia Medical Journal.*

Griffith's Weight Chart

INFANTS' WEIGHT CHART. Designed by J. P. CROZER GRIFFITH, M. D., Clinical Professor of Diseases of Children in the University of Pennsylvania; Physician to the Children's Hospital, to the Methodist Episcopal Hospital, and to St. Agnes' Hospital, Philadelphia. 25 charts in each pad. Price per pad, 50 cents net.

Printed on each chart is a curve representing the average weight of a healthy infant so that any deviation from the normal can readily be detected.

Powell's Diseases of Children

Third Edition, Revised

ESSENTIALS OF THE DISEASES OF CHILDREN. By WILLIAM M. POWELL, M. D., author of "Saunders' Pocket Medical Formulary," etc. Revised by ALFRED HAND, JR., A. B., M. D., Dispensary Physician and Pathologist to the Children's Hospital, Philadelphia. 12mo volume of 259 pages. Cloth, $1.00 net. *In Saunders' Question-Compend Series.*

"One of the best books of this excellent Question Series, and one which will prove very popular."—*The Medical World*, Philadelphia.

Starr's Diets for Infants and Children

DIETS FOR INFANTS AND CHILDREN IN HEALTH AND IN DISEASE. By LOUIS STARR, M. D., Consulting Pediatrist to the Maternity Hospital, Philadelphia; editor of "American Text-Book of the Diseases of Children." 230 blanks (pocket-book size), perforated and neatly bound in flexible Morocco, $1.25 net.

"The diets are various and well selected, and are adapted to children of all ages. At the end of the book are a few simple recipes which can be detached and given to the nurse."—*British Medical Journal.*

Grafstrom's Mechano-Therapy

A TEXT-BOOK OF MECHANO-THERAPY (Massage and Medical Gymnastics). By AXEL V. GRAFSTROM, B. Sc., M. D., late House Physician, City Hospital, Blackwell's Island, New York. 12mo. 130 pages, illustrated. Cloth, $1.00 net.

"Certainly fulfills its mission in rendering comprehensible the subjects of massage and medical gymnastics."—*New York Medical Journal.*

Meigs' Feeding in Infancy

FEEDING IN EARLY INFANCY. By ARTHUR V. MEIGS, M. D., Physician to the Pennsylvania Hospital, Philadelphia. Bound in limp Cloth, flush edges, 25 cents net.

LANE MEDICAL LIBRARY

To avoid fine, this book should be returned on or before the date last stamped below.

FEB 18 1917
OCT 23 1917
MAR 8 1918
APR 30 1919
JUN 3 1919
JAN 23 1920

M32 Bickham, W.S. 10778
B57 Text-book of operative
1903 surgery

NAME	DATE DUE
F. E. Blaisdell ret.	May 19, 1917.
Dr. Craig ret.	Oct. 19, 1917.
F. E. Blaisdell ret.	Oct. 15, 1918
M. McCall	APR 30 1919
M. C. Funnell	JUN 3 1919
Dr. Vorne	MAY 31 1919
	JAN 29 JAN 6 19